

МИНИСТЕРСТВО ЗДРАВООХРАНЕНИЯ РЕСПУБЛИКИ БЕЛАРУСЬ
БЕЛОРУССКИЙ ГОСУДАРСТВЕННЫЙ МЕДИЦИНСКИЙ УНИВЕРСИТЕТ
КАФЕДРА СТОМАТОЛОГИИ ДЕТСКОГО ВОЗРАСТА

Н. В. ШАКОВЕЦ, Ж. М. БУРАК, М. И. КЛЕНОВСКАЯ

**КАРИЕС ВРЕМЕННЫХ И НЕЗРЕЛЫХ
ПОСТОЯННЫХ ЗУБОВ**

**CARIES OF PRIMARY AND IMMATURE
PERMANENT TEETH**

Учебно-методическое пособие



Минск БГМУ 2017

УДК 616.314-002-053.2(075.8)-054.6

ББК 56.6 я73

Ш17

Рекомендовано Научно-методическим советом университета в качестве учебно-методического пособия 21.06.2017 г., протокол № 10

Рецензенты: канд. мед. наук, доц., зав. курсом детской стоматологии каф. ортопедической стоматологии и ортодонтии с курсом детской стоматологии Белорусской медицинской академии последипломного образования В. А. Андреева; канд. мед. наук, доц., зав. каф. общей стоматологии Белорусского государственного медицинского университета Н. М. Полонейчик; канд. филол. наук, доц., зав. каф. иностранных языков Белорусского государственного медицинского университета М. Н. Петрова

Шаковец, Н. В.

Ш17 Кариес временных и незрелых постоянных зубов = Caries of primary and immature permanent teeth : учебно-методическое пособие / Н. В. Шаковец, Ж. М. Бурак, М. И. Кленовская. – Минск : БГМУ, 2017. – 27 с.

ISBN 978-985-567-873-2.

Посвящено проблеме кариеса зубов у детей. Освещены вопросы этиологии и патогенеза кариеса временных и незрелых постоянных зубов, номенклатура кариеса, подробно изложены особенности клинических проявлений острого и хронического кариозного процесса при различной глубине поражения. Особое внимание уделено методам диагностики начального и скрытого кариеса, представлены современные подходы к лечению кариеса зубов у детей в зависимости от активности и глубины процесса. Подробно разобраны факторы риска и особенности течения кариеса зубов у детей раннего возраста.

Предназначено для студентов 3-5-го курсов медицинского факультета иностранных учащихся, обучающихся по специальности 1-79 01 07 «Стоматология» на английском языке.

УДК 616.314-002-053.2(075.8)-054.6

ББК 56.6 я73

ISBN 978-985-567-873-2

© Шаковец Н. В., Бурак Ж. М., Кленовская М. И., 2017
© УО «Белорусский государственный
медицинский университет», 2017

Anatomical and physiological features of the primary and immature permanent teeth

Features of primary teeth

The period of eruption of primary teeth is between 6 months and 3 years of age (tab.1). During this period children are most susceptible to acquiring St. mutans (so called first “window of infectivity”) and they are at higher risk of caries development.

Table 1

Terms of development of primary teeth

	Central incisor	Lateral incisor	Canine	First molar	Second molar
Maxillary (upper) teeth					
Initial calcification	14 weeks in utero	16 weeks in utero	17 weeks in utero	15,5 weeks in utero	19 weeks in utero
Crown completed	1,5 months	2,5 months	9 months	6 months	11 months
Root completed	1,5 years	2 years	3,25 years	2,5 years	3 years
Mandibular (lower) teeth					
Initial calcification	14 weeks in utero	16 weeks in utero	17 weeks in utero	15,5 weeks in utero	18 weeks in utero
Crown completed	2,5 months	3,5 months	9 months	5,5 months	10 months
Root completed	1,5 years	1,5 years	3,25 years	2,5 years	3 years

Temporary teeth are not reduced copies of permanent teeth. There are some features (anatomical, morphological) of primary teeth interacting with course of dental pathology in children.

Generally *crowns of primary teeth* have the following differences with the permanent ones:

- the crowns are shorter;
- the crowns have narrower occlusal table;
- the crowns are constricted in the cervical portion;
- thinner enamel and dentin layers;
- enamel rods in the cervical area directed occlusally;
- broad and flat interproximal contacts;
- color is usually lighter.

Primary *crown anatomy* has also the following features for every group of teeth:

- Mandibular Incisors: central incisor is symmetrically flat when viewed from buccal, the lateral one has a more rounded DI angle;
- Maxillary Central Incisor is only tooth that has a greater width than height;
- Maxillary 1st Molar has unique look (3 cusps);
- Mandibular 1st Molar has 4 cusps and transverse ridge dividing occlusal surface;

- Maxillary Canine is long and sharp, Mandibular Canine has similar shape but it is smaller;
- Maxillary 2nd Molar resembles permanent maxillary first molar but is smaller;
- Mandibular 2nd Molar resembles permanent mandibular first molar but is smaller.

The **roots** of primary teeth have the following differences with the permanent ones:

- roots of anterior teeth are narrower mesiodistally;
- posterior teeth have longer and more slender roots in relation to crown size;
- molar roots flare more as they approach the apex;
- apical foramina may be larger;
- additional canals are often larger and more numerous.

There are some **morphological features** of primary teeth:

- microcracks and micropores are in the superficial layer of the enamel;
- thickness of the enamel is less (about 0.5–0.7 mm) than in permanent teeth and approximately the same over the whole crown;
- the level of enamel mineralization is the least in the cervical area and proximal surfaces;
- dentin is thinner and less mineralized;
- peritubular dentine is absent or expressed weakly;
- dentinal tubules are wide and short;
- there are no “immune zones” in primary teeth.

Summarizing the above, we can distinguish the following **features of temporary teeth** that interact with the course of caries and selection of its treatment technique:

- thin enamel and dentin layers;
- pulp horns are closer to the outer surface than in permanent teeth;
- mesial pulp horn is much higher, very close to occlusal surface;
- relatively larger pulp chamber than in permanent teeth;
- enamel rods direct slightly occlusally in the cervical area;
- cervical area is constricted significantly.

Therefore the progress of caries is much faster in the primary dentition than in the permanent one. The caries turning into pulpitis is very fast also. The younger is primary tooth the more immature are its dentin and enamel and faster is pathological process.

Features of young permanent teeth

Young permanent teeth are those recently erupted teeth in which normal physiological apical root closure has not occurred. Normal physiological apical root closure of permanent teeth may take 2–3 years after eruption. Enamel is characterized by low mineralization during 6–7 years. Calcification of the enamel in-

creases in 93 % during the first year after eruption. Young permanent teeth are in developmental stage in children from 6 years of age until mid-teens.

It is very important to remember that human tooth with immature apex is a developing organ. The proliferation and differentiation of various cells are activated especially in the apical region of the young tooth to make it complete.

Period of eruption of permanent teeth is usually between 6 and 12 years of age (tab. 2). But first permanent tooth may erupt as early as the age of 4 the second “window of infectivity” is present in this time (2–6 years old children are less susceptible to acquiring *St. mutans*). The children acquire additional strains of MS when they get older and new teeth erupt. Fully erupted teeth yielded greater number and proportion of *St. mutans*. Partially erupted teeth yielded *A. israeli*. Partially erupted teeth with initial caries have greater number and proportion of *St. salivarius* but full erupted — *St. mutans*.

Table 2

Terms of development of primary teeth

Stages/ tooth number	1	2	3	4	5	6	7	8
Follicle forming	8 months in utero	8 months in utero	8 months in utero	2 years	3 years	5 months in utero	3 years	5 years
Initial mineralization	6 months	9 months	6 months	2,5 years	3,5 years	9 months in utero	3,5 years	8 years
Crown completed	4–5 years	4–5 years	6–7 years	5–6 years	6–7 years	2–3 years	7–8 years	various
Eruption	6–8 years	8–9 years	10–11 years	9–10 years	11–12 years	6 years	12–13 years	various
Root completed	10 years	10 years	13 years	12 years	12 years	10 years	15 years	various

Immature permanent teeth have some features interacting with caries development (tab. 3).

Table 3

Differences between immature and mature permanent teeth

Immature (young) permanent teeth	Mature permanent teeth
Surfaces of recently erupted teeth are covered with pronounced enamel rods and perikymata.	There is generalized loss and flattening of perikymata.
No attrition presents.	Attrition or wear of occlusal surfaces and proximal contacts as a result of mastication.
Mammelons are clearly visible.	Mammelons are absent.
Surface of enamel works like a semipermeable membrane; slow passage of water from surrounding and substances having small molecular size pass through pores.	Localised increase of elements such as nitrogen and fluorine is found in superficial layer of enamel of older teeth; enamel becomes less permeable with advancing age.
Primary dentin is present which is composed of mantle and circumpulpal dentin.	Secondary dentin is present. Sclerotic and reparative dentine may also be present.

Immature (young) permanent teeth	Mature permanent teeth
Young pulp has high number of undifferentiated mesenchymal cells, high cellular content, high vascularity and low calcium and phosphorus content.	Mature pulp has decreased number of undifferentiated cells in the pulp, low vascularity and high calcium and phosphorus content.

As a result young permanent teeth are more susceptible to dental caries than teeth that have remained free from caries for a few years after eruption.

Classifications of caries

Caries is defined (according to WHO) as localized post eruptive pathological process of external origin involving softening of the hard tissue and proceeding to the formation of cavity.

According to Shafer, Hine, Levy it is defined it as a microbial disease of the calcified tissues of the teeth, characterized by demineralization of the inorganic portion and destruction of the organic substance of the tooth.

There are a big number of dental caries classifications in the world, which are based on anatomical site (fig. 1); caries progression; virginity of lesion; extent of caries; tissue involvement; chronology; whether caries is completely removed or not and surfaces to be restored.

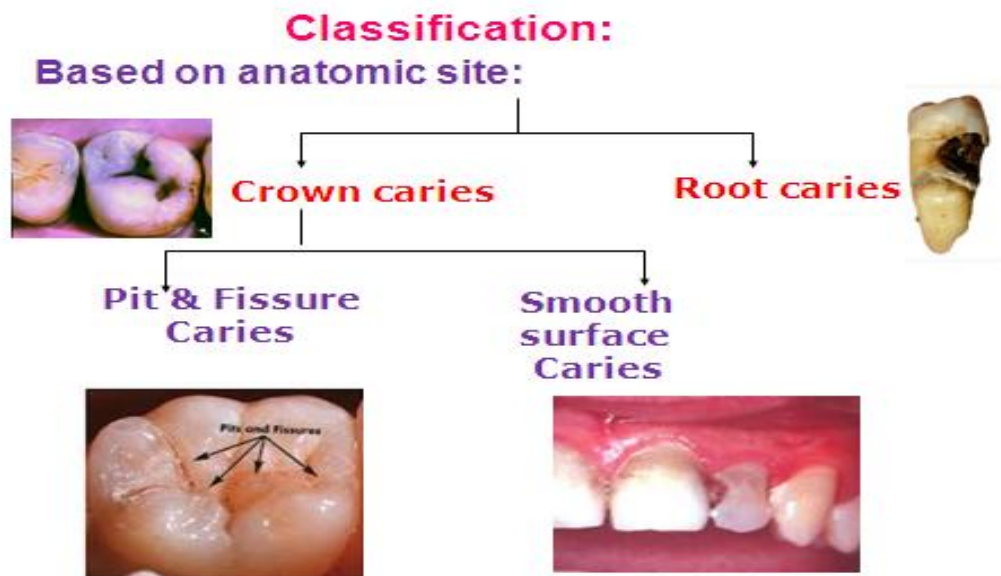


Figure 1. Dental caries classification based on anatomical site

Dental caries classification is based on tissue involvement:

Initial caries (White spot lesion) — demineralization;

Superficial caries — enamel;

Moderate caries (Caries media) — dentin caries;

Deep caries (Caries profunda) — dentin close to the pulp;

Deep complicated caries (Caries profunda complicata) — pulp involvement.

Dental caries classification is based on surfaces to be restored (the most widespread clinical utilization):

- | | | | |
|---|------------------------|---|----------------------|
| O | for occlusal surfaces; | F | for facial surfaces; |
| M | for mesial surfaces; | B | for buccal surfaces; |
| D | for distal surfaces; | L | for lingual surface. |

Various combinations are also possible, such as MOD—for mesio-occluso-distal surfaces. Black classification has the similar base (fig. 2).

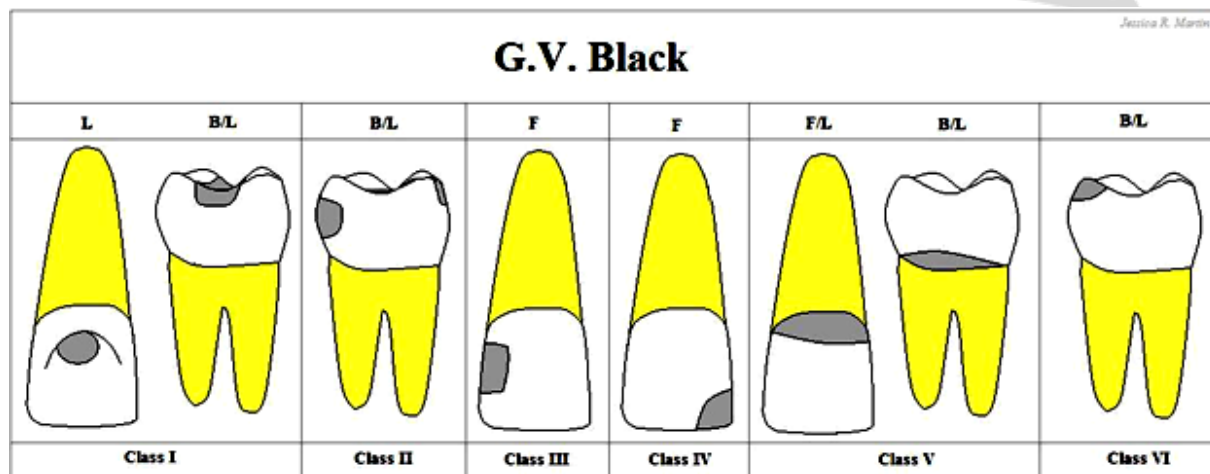


Figure 2. Dental caries classification according to G.V. Black

International Classification of Diseases-10:

- Caries — K.02;
- Caries of the enamel — K.02.0;
- Caries of the dentine — K.02.1;
- Caries of the cementum — K.02.2;
- Arrested caries — K.02.3;
- Another caries — K.02.8;
- Caries unspecified — K.02.9.

Classification is based on tissue involvement:

- Initial caries (white spot lesion) — demineralization;
- Superficial caries — enamel;
- Moderate caries (caries media) — dentin caries;
- Deep caries (caries profunda) — dentin close to the pulp;
- Deep complicated caries (caries profunda complicata) — pulp involvement.

Classification according to Mc Ghee:

- Superficial caries — surface of enamel affected;
- Simple caries — penetration into DEJ;
- Deep seated caries — cavity of sufficient depth;
- Caries with nearly exposed pulp — large well defined cavity;
- Caries with pulp involvement;
- Caries with perforation laterally or through the floor of the pulp;
- Loss of crown of the tooth from caries;
- Caries of remaining root.

WHO classification (based on the shape and depth of the carious lesion):

D1. Clinically detectable enamel lesions with intact (non cavitated) surfaces;

D2. Clinically detectable cavities limited to enamel;

D3. Clinically detectable cavities in dentine;

D4. Lesions extending into the pulp.

According to its extent dental caries is divided into incipient (reversible) and cavitated (irreversible). Special kind of caries — occult (hidden) caries—should be marked also. This term is used to describe such lesion, which is not clinically diagnosed but detected only on radiographs or other noninvasive adjuncts.

According to the virginity of the lesion dental caries is divided into primary and secondary (recurrent).

Primary caries occurs on health enamel. Recurrent caries occurs immediately next to a restoration. It may be the result of poor adaptation of a restoration, which allows for a marginal leakage, or it may be due to inadequate extension of the restoration. In addition, caries may remain if there has not been complete excavation of the original lesion, which later may appear as a residual or recurrent caries.

According to the process progression dental caries is divided into rampant (very aggressive process), acute (fast progression) and chronic/slow/arrested (slow progression).

Clinical features of caries in primary and immature permanent teeth

Dental caries features in primary teeth

Due to anatomical and morphological features of primary teeth acute caries is more common in children with primary dentition. Usually the younger the child is the more acute carious process is. Some children have so-called rampant caries — very aggressive process, when almost all teeth are affected.

Features of acute caries in primary dentition:

- rapid development of destructive changes in the hard tissues of the tooth, rapid involvement of the pulp;
- affected tissues are soft, slightly colored (light yellow, grayish-white shade), moist, easily excavated;
- some involved surfaces in one tooth;
- the involvement of proximal surfaces of lower anterior teeth, cervical lesions of many teeth;
- more often in children who have nursing bottle feeding or with poor immunity.

Features of chronic/slow/arrested caries in primary dentition:

- slow current process (some years);
- caries process distributes mainly in a planar direction;
- carious tissues are solid, colored in brown or dark brown color;
- few teeth are affected;
- caries occurs in practically healthy children.

There are some features of dental caries of the primary teeth in different stages of forming. Dental caries during root formation is also named early childhood caries (ECC).

Features of dental caries of the primary teeth during root formation:

- the first caries lesions can develop as soon as the primary upper incisors erupt (fig. 3);
- the lesions develop rapidly, often soon after teeth emerge and they occur in tooth surfaces that usually are at low risk of caries development (fig. 4);
- first primary molars are more frequently affected compared with second molars, as they emerge approximately 1 year ahead of second molars.

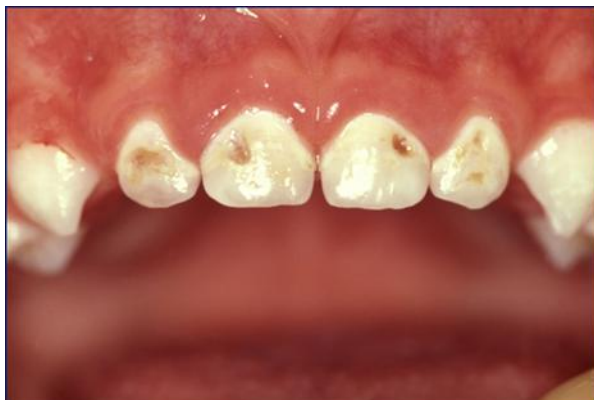

Figure 3. Early childhood caries.
Upper incisors are affected

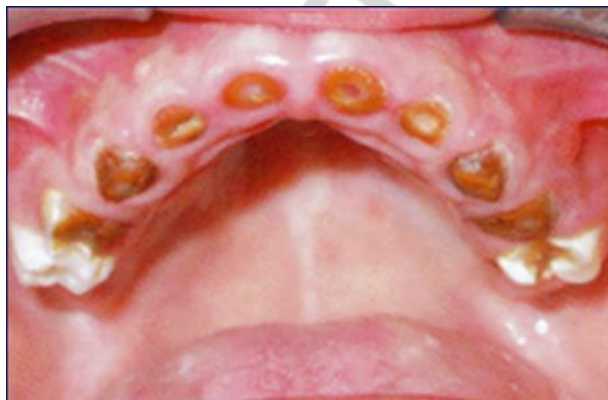

Figure 4. Early childhood caries.
Fast progression of the process

Features of dental caries of the primary teeth during developed root:

- at the age of 4–6 years carious lesions are situated on the proximal surfaces of the incisors and molars predominantly (fig. 5);
- carious lesions are often acute;
- dentin is dark and hard in arrested carious lesions;
- acute carious lesion on proximal surface of the primary molars is often the feature of pulp inflammation.

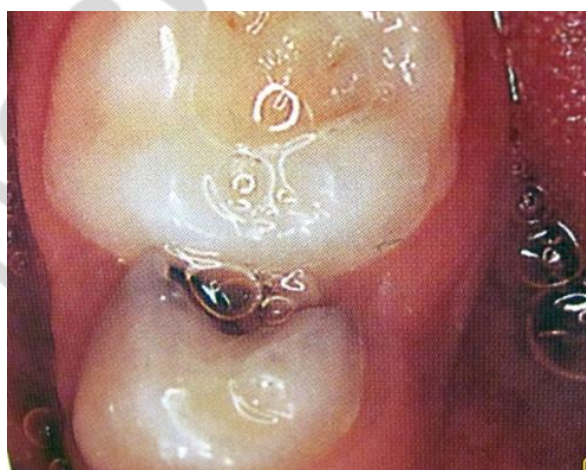

Figure 5. Carious cavity on distal surface of first lower primary molar

Features of dental caries of the primary teeth on the stage of root resorption:

- many proximal lesions on primary molars with pulp involvement;
- carious lesions without pulp involvement are arrested and prevalent in children with low or moderate level of caries intensity, good health and immunity;
- acute carious lesions are diagnosed rarely on this stage. Usually these children have somatic diseases.

Dental caries features in immature permanent teeth

The eruption of the anterior teeth usually causes great excitement, as it is associated with 'the fluttering of tooth fairy wings'. However, the eruption of the first permanent molars largely goes unnoticed until there is a problem. It takes 12–18 months for the first or second molar to erupt fully.

The first permanent molars are teeth that commonly exhibit disrupted enamel; the reported incidence of defects range from 3.6–25 %. The occlusal surfaces of these molar teeth account for about 90 % of caries in children.

Generally young permanent teeth are more sensitive to dental caries than mature permanent teeth. Therefore it is very important to assess caries risk in children. The idea of a caries risk assessment for each child patient is to ensure that the chosen diagnostic tests, preventive treatment, and any provided restorations, are geared specifically to the need of that patient.

Factors requiring consideration to assess caries risk are the following:

- 1) present caries activity;
- 2) past caries activity;
- 3) parent /sibling caries activity;
- 4) sugar consumption;
- 5) oral hygiene;
- 6) fluoride exposure;
- 7) teeth morphology;
- 8) Streptococcus mutans levels;
- 9) saliva characteristics, flow rate, and consistency.

Factors 1–7 will become clear when a full history and examination are carried out; while 8 and 9 will only come into play if there is rampant caries, which the dentist cannot explain from the history.

Diagnosis of dental caries

Dental caries diagnosis is based on complaints, anamnesis (patient history and nutrition analysis) and objective examination. Objective examination, in its turn, consists of dental examination, general consideration of disease activity and detection of defects.

The primary objective of caries diagnosis is to identify those lesions that require restorative treatment, those that require non-surgical treatment, and those

persons who are at high risk for developing carious lesions. There are two main methods of detection of the defects:

- visual examination (light and mirror) of wet and dried enamel to note a spot, its color and localization;
- probing to detect a cavity, its depth, edge, consistence of enamel and dentin.

Some decades ago these two methods supplemented by bitewing radiographs were the only tools available for clinical diagnosis of caries. For epidemiologic surveys and for examination of most patients, these are still useful tools.

However, a variety of innovative technologies have been developed and introduced in the last few years to aid clinicians not only in early caries detection but make a firm diagnosis and to treat cases conservatively. These technologies use the alteration in fluorescence, reflectance, electrical conductance or impedance, and ultrasound transmittal properties of enamel with demineralization to monitor changes in caries lesion over time.

Temporary separation

The temporary separation using orthodontic rubbers permits the direct visual inspection and tactile examination of the approximal surfaces thanks to creation of interdental space around 0.8 mm. This technique is well-accepted by children. But even if visio-tactile assessment of approximal surface is possible, doubts in diagnosis may remain. The interdental space is not always large enough to provide good view. Furthermore, several dentine lesions may not be cavitated. Other dentine lesions may be associated with microcavities, however, without exposing the dentine. This is a limitation of this method. However, since there is no other available possibility to detect the presence of cavities, the temporary separation should be used when a cavity is suspected, especially if it is confirmed by visual signs or radiographs.

Radiographic Methods

Radiographic examinations include:

- Bitewing radiographs;
- IOPA radiographs using paralleling technique;
- Dental panoramic tomography.

The most commonly used radiographic method for detecting caries lesions is the *bitewing technique*. It is meant to find lesions that are hidden from a clinical visual examination, such as when a lesion is hidden by an adjacent tooth, as well as help the dental professional estimate how deep the lesion is. To get the radiographic images, a central beam of X-rays is positioned to pass at right angles to the long axis of the tooth. If film is used, a beam-aiming device on the film holder guides the position, directing the beam at right angles to the film.

We can use the following criteria to diagnose fissure caries lesions by the bitewing technique:

- 0 — no radiolucency visible;
- 1 — radiolucency visible in the enamel;

2 — radiolucency visible in the dentin but restricted to the outer third of the dentin (fig. 6);

3 — radiolucency extending to the middle third of the dentin (fig. 7);

4 — radiolucency in the pulpal third of the dentin.

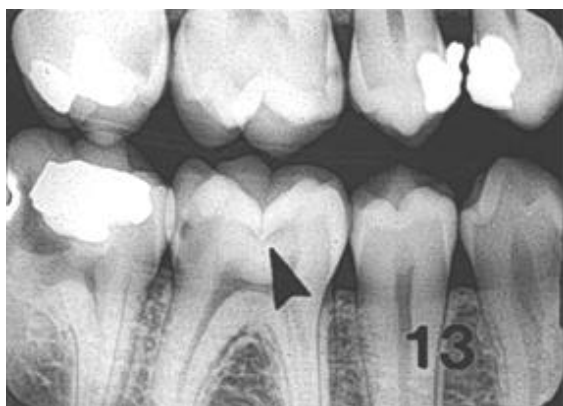


Figure 6. Incipient occlusal lesions

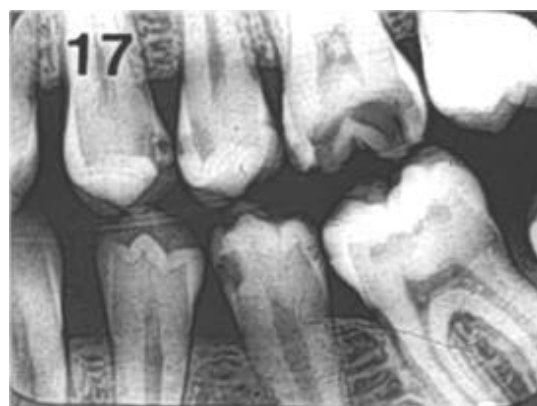

Figure 7. Moderate occlusal lesions

Digital radiography is replacing radiography based on film. It has been proven as accurate as traditional radiography for detecting caries, but it comes with additional advantages of using a lower radiation dose, being less time-consuming, and does not require wet chemicals in the processing of the image.

A digital radiograph (or a traditional radiograph that has been digitised) is comprised of a number of pixels. Each pixel carries a value between 0 and 255, with 0 being black and 255 being white. The values in between represent shades of grey, and it can be quickly appreciated that a digital radiograph, with a potential of 256 grey levels has significantly lower resolution than a conventional radiograph that contain millions of grey levels. This would suggest that digital radiographs would have a lower diagnostic yield than that of traditional radiographs. Research has confirmed this; with sensitivities and specificities of digital radiographs being significantly lower than those of regular radiographs when assessing small proximal lesions.

However, digital radiographs offer the potential of image enhancement by applying a range of algorithms, some of which enhance the white end of the grey scale (such as Rayleigh and hyperbolic logarithmic probability) and others the black end (hyperbolic cube root function).

When these enhanced radiographs are assessed their diagnostic performance is at least as good as conventional radiographs, with reported values of 0.95 (sensitivity) and 0.83 (specificity) for approximal lesions. When these findings are considered, one must remember that digital radiographs offer a decrease in radiographic dose and thus offer additional benefits than diagnostic yield.

Digital images can also be archived and replicated with ease.

Digital radiovisiography is the latest X-ray technology in dentistry. Digital radiovisiograph is equipped with special image analysis software, and in digital technology it is possible to enlarge the images and their saving in the patient's file.

Some of the advantages of digital radiovisiography are the following:

- reduced radiation of the patient compared with classic X-ray up to 80 %;

- faster imaging without X-ray film and developing images;
- digital intraoral sensor is used instead of X-ray film;
- immediate imaging on the computer screen;
- high quality of the digital image that can be analyzed and processed;
- saving images in the patient's file;
- children friendly for reduced radiation, if imaging is necessary.

Digital radiograph offers a number of opportunities for image enhancement, processing and manipulation. One of the most promising technologies in this regard is that of **radiographic subtraction** which has been extensively evaluated for both the detection of caries and also the assessment of bone loss in periodontal studies.

The basic premise of subtraction radiology is that two radiographs of the same object can be compared using their pixel values. If the images have been taken using either a geometry stabilising system (i.e. a bitewing holder) or software has been employed to register the images together, then any differences in the pixel values must be due to change in the object. The value of the pixels from the first object is subtracted from the second image. If there is no change, the resultant pixel will be scored 0; any value that is not 0 must be attributable to either the onset or progression of demineralisation, or regression (fig. 8).

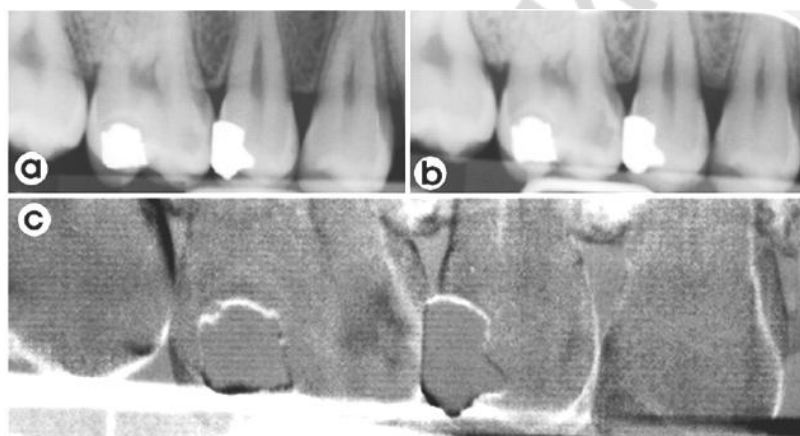


Figure 8. Example of a subtraction of two digital bitewing radiographs: *a* — radiograph showing proximal lesion on mesial surface of first molar; *b* — follow-up radiograph taken 12 months later; *c* — the areas of difference between then two films are shown as black, i.e. in this case the proximal lesion has become more radiolucent and hence has progressed

Subtraction images therefore emphasise this change and the sensitivity is increased. It is clear from this description that the radiographs must be perfectly, or as close to perfect as possible, aligned. Any discrepancies in alignment would result in pixels being incorrectly represented as change.

Fiber-optic transillumination (FOTI)

Fiber-optic transillumination (FOTI) as a caries detection technique is based on the fact that carious enamel has a lower index of light transmission than sound enamel. The light is absorbed more when the demineralization process disrupts the crystalline structure of enamel and dentin. In essence this gives that area a more darkened appearance.

This method of caries detection uses a light source, preferably bright, to illuminate the tooth. Caries or demineralised areas in dentin or enamel are shown up as darkened areas with this technique. This effect can be achieved with a fiber optic illuminator, which is readily available at the handpiece coupler of the dental operatory and has been used for detection of approximal and occlusal caries.

Posterior approximal caries can be diagnosed with the light probe positioned on the gingivae below the cervical margin of the tooth, whereby the light passes through the tooth structures and approximal decay produces a dark shadow on the occlusal surface.

Although this device has the advantage that the examination is done with an operating light source already available in general practice, it is only useful for approximal and occlusal lesions; its sensitivity and specificity are not sufficient for detection of very early caries lesions. Besides, it is not quantitative method and therefore not useful as a caries monitor over time. However, studies on the diagnostic efficacy of this device present conflicting results.

Digital imaging fiber-optic transillumination (DIFOTI)

This is a digitized and computed version of the FOTI.

While FOTI was designed for detection of approximal and occlusal caries, digital imaging fiber-optic transillumination DIFOTI is used for detection of both incipient and frank caries in all tooth surfaces. DIFOTI can also be used to detect fractures, cracks, and secondary caries around restorations.

DIFOTI uses white light to transilluminate each tooth and to instantly create high-resolution digital images of the tooth. It is based on the principle that carious tooth tissue scatters and absorbs more light than surrounding healthy tissue. Decay near the imaged surface appears as a darker area against the more translucent brighter background of surrounding healthy anatomy.

A single fiber-optics illuminator in the mouthpiece delivers light to one of the tooth's surfaces. As this light travels through layers of enamel and dentin, it scatters in all directions toward the nonilluminated surface usually the opposite surface. The light is then directed through the mouthpiece to a miniature electronic charge coupled device CCD camera in the handpiece. The camera digitally images the light emerging from either the smooth surface opposite the illuminated surface or the occlusal surface.

These images are displayed on a computer monitor in real time and stored on the hard drive for easy retrieval for comparative review of images over time. Image acquisition is controlled with software and a foot pedal. Images of the teeth can be viewed by both the clinician and patient, and therefore can be used for patient education and motivation.

It is important to note that DIFOTI images the light emerging from surface closest to the CCD camera. It does not image the tooth material between the light source and the CCD camera, and therefore cannot indicate the depth of lesion penetration.

Schneiderman et al. demonstrated a method of using DIFOTI to quantitatively monitor lesion progression and reported a successful result. Inherent with the high sensitivity of the device, dark areas in DIFOTI images may sometimes be due to stains or calculi on tooth surface; therefore it is suggested that prophylaxis should be carried out prior to the use of the device in order to increase the specificity.

Quantitative Light-induced Fluorescence (QLF)

It is another dental diagnostic tool for detection of early carious lesions, which is based on auto-fluorescence of teeth.

When the teeth are illuminated with high intensity blue light, the resultant auto-fluorescence of enamel is detected by an intraoral camera which produces a fluorescent image. The emitted fluorescence has a direct relationship with the mineral content of the enamel. Thus, the intensity of the tooth image at a demineralised area is darker than the sound area.

The software of QLF systems can process the image to provide user quantitative parameters such as lesion area, lesion depth, and lesion volume. These parameters can detect and differentiate the lesions at very early stages, and make the QLF system more sensitive to changes of caries over time. The image can be stored for longitudinal study and be used as patient's motivators in a preventative practice.

QLF uses a blue light (488 nm) to illuminate the tooth, which normally fluorescence a green colour. At the same time, Hafström-Björkman and others found a sensitivity of 0.72–0.76 and a specificity of 0.79–0.81 for this technique. Teeth should be dried before its application.

QLF can also be used to image plaque and calculus, and therefore be useful in identifying active caries. This technique has found many applications in clinical trials, research, patient education, and preventive clinical practice. It can effectively monitor demineralization and remineralisation of teeth in vitro and a good correlation has been reported with other techniques measuring mineral loss, such as transverse microradiography analysis. Also it can be used to measure erosive potential of a range of mouth washes in vitro and to see early secondary lesion beneath the amalgam restorations.

However it cannot differentiate between decay and hypoplasia; has inability to detect or monitor interproximal lesions and is limited to measurement of enamel lesions of at most several hundred micrometers depth.

Laser fluorescence — DIAGNODent (DD), DIAGNODent pen

The *DIAGNODent* instrument (KaVo, Germany) is another device employing fluorescence to detect the presence of caries lesion.

Using a small laser the system produces an excitation wavelength of 655 nm which produces a red light. This is carried to one of two intra-oral tips; one de-

signed for pits and fissures, and the other for smooth surfaces. The tip both emits the excitation light and collects the resultant fluorescence.

Unlike the QLF system, the DD does not produce an image of the tooth; instead it displays a numerical value on two LED displays. The first displays the current reading while the second displays the peak reading for that examination.

A small twist of the top of the tip enables the machine to be reset and ready for another site examination and a calibration device is supplied with the system. Due to this limitation, a new version of the method was designed and introduced, named *DIAGNOdent pen*. This new version permits the assessment of both occlusal and proximal surfaces. The device works on the principles of the old version, but the design is different. The tip is rotatable around the axis of its length, enabling the operator to assess mesial and distal surfaces from both sides (buccal and lingual). The tip designed for proximal surfaces is made of sapphire fiber with a prismatic shape, and the light is directed laterally to the longitudinal axis of the tip. Another cylindrical tip is recommended for occlusal surfaces, and the direction of its light is perpendicular to the axis of the length of the tip. After excitation, the tip collects the fluorescence and translates it into a numerical scale from 0 to 99.

This device could be used as an alternative to the radiographic method to aid the dentist in the decision-making process after visual inspection.

Nevertheless, the evidence concerning the use of the method in clinical practice is limited, and further studies are necessary to evaluate whether the method could be useful.

Electronic caries monitor (ECM)

The ECM device employs a single, fixed-frequency alternating current which attempts to measure the 'bulk resistance' of tooth tissue. This can be undertaken at either a site or surface level. When measuring the electrical properties of a particular site on a tooth, the ECM probe is directly applied to the site, typically a fissure, and the site is measured.

Tooth demineralization due to caries process causes increased porosity of tooth structure. This porosity contains fluid containing ions. This leads increased electrical conductivity, conversely, leads to decreased electrical resistance or impedance. There are also a number of physical factors that will affect ECM results. These include:

- the temperature of the tooth;
- the thickness of the tissue;
- the hydration of the material (i.e. one should not dry the teeth prior to use);
- the surface area.

A major advantage of the ECM is to present objective readings, which have the potential for monitoring lesion progression, arrest, or remineralization.

The sensitivity and the specificity of this machine have been reported to be very high, 0.75 and 0.77, respectively, when used to detect occlusal caries in vivo and ex vivo, indicating that it is a valid indicator for detecting the presence or ab-

sence of lesion porosity. A strong relationship between both lesion depth and mineral content in enamel has been shown with ECM readings. The only drawback is the fact that it is time consuming to use in a routine full-mouth examination.

Endoscopic filtered fluorescence method (EFF)

Pitts and Longbottom explored the use of EFF for the clinical diagnosis of carious lesions and compared results with conventional alternatives on occlusal and approximal site. The EFF method has been shown to be highly sensitive for occlusal caries in enamel but sensitivity is poor for occlusal caries in dentin.

Specificity is poor for occlusal surfaces but high for approximal lesions at both thresholds. The method is reasonably good at detecting approximal lesions in enamel but not lesions in dentin.

Midwest Caries I.D.

It detects differences of optical behaviour inside the tooth related to change in the tooth structure and it is therefore not sensitive to bacterial content.

The Midwest Caries I.D. uses infrared and red light emitting diodes LEDs and a fiber optic to distribute light to the observed area present at the probe tip. The second fiber optic collects light from the observed area to a photodetector that measures returned collected light. This photodetector then transmits the signal to a microprocessor that compares signal levels with defined parameters.

When the result is positive, the processor deactivates the third green LED and pulses at a higher intensity than the red LED. When the detection is negative i.e., healthy tooth area, the green LED is dominant resulting in a green illumination when healthy structure is detected and red illumination when caries are detected.

A buzzer also beeps with different frequencies to indicate the intensity of demineralization detected.

The Midwest Caries I.D. can be used for approximal caries detection during the examination by slightly angling and moving the probe along the marginal ridge just over the vulnerable approximal area. Interproximal detection using the Midwest Caries I.D. and X rays as a gold standard showed sensitivity of 80 % and specificity of 98 %.

However, this device can give false positive signals in cases of teeth with growth malformations in the enamel or the dentin, teeth with thick, dark stains, hypermineralization, hypocalcification, dental fluorosis, and atypically shaped teeth due to alteration in the translucency of enamel caused by these conditions.

Light penetration is limited into the enamel and up to 3 mm in approximal area. Midwest Caries I.D. cannot be used on composites or amalgams but can be used to check the marginal ridges of occlusal amalgams.

If the probe is tipped at too much of an angle when checking for approximal caries, total surface light reflection can occur giving a false positive. Opaque artifacts plaque, calculus, and organic plug can cause false positives.

Caries detection with chemical dyes

Dyes are a diagnostic aid for detecting caries in questionable areas (i.e., for locating soft dentin that is presumably infected).

Fusayama introduced a technique in 1972 that used a basic fuchsin red stain to aid in differentiating layers of carious dentin. Because of potential carcinogenicity, basic fuchsin was replaced by another dye, acid red 52, which showed equal effectiveness. Products based on acid red 52 are marketed by a number of manufacturers e.g. Caries Detector, Kuraray, Osaka, Japan. Many clinicians also have had good success with acid reds 50, 51, 54, and other commercially available caries detectors.

Some caries detection products contain a red and blue disodium disclosing solution (e.g., Cari-D-Tect, Gresco Products, Stafford, Texas). These products stain infected caries dark blue to bluish-green.

Studies show dye stains are about 85 % effective in detecting all caries in a tooth. Clinical removal of caries without the aid of a dye is 70 % effective.

Technique is the following:

1. The area to be tested is rinsed with water and then blotted dry (excess water dilutes a stain).
2. The tooth is treated with a 1 % acid red 52 solution for 10 seconds.
3. The tooth is rinsed with water and suctioned and then excess water is removed. After rinsing with water for 10 seconds, some tooth structure shows discoloration.
4. Stained decay is removed with a spoon excavator and evaluated by tactile sensation.

When removing stained caries, it is important to be conservative near the pulp. Any questionable stained dentin should be left in place; remineralization will occur in this area, and the bacterial activity will be arrested once the tooth is restored.

CarieScan

This device is based on the proven technology of alternating current impedance spectroscopy and involves the passing of an insensitive level of electrical current through the tooth to identify the presence and location of the decay. The frequency domain is based on a sinusoidal signal applied to a sample at known amplitude and frequency. The response waveform is then measured and the impedance calculated by a transfer function relationship of the applied voltage perturbation and acquired response current.

It is the first dental diagnostic tool to use ac impedance spectroscopy to quantify dental caries early enough to enhance preventative treatment.

The device is indicated for the detection, diagnosis, and monitoring of primary coronal dental caries occlusal and accessible smooth surfaces, which are not clearly visible to the human eye.

For assessment of caries, while tufted sensor brush contacts the tooth surface being examined, a soft tissue contact, which is a disposable metal clip that is

placed over the lip in the corner of the patient's mouth, connects to the CarieScan via a soft tissue cable to complete the circuit.

During measurement, a green color display indicates sound tooth tissue, while a red color indicates deep caries requiring operative, and a yellow color associated with a range of numerical figures from 1 to 99 depicts varying severity caries, which require only preventive care.

Cone beam computed tomography (CBCT)

The application of CBCT in dental caries diagnosis has not been widely studied. The first and the only study that compared caries diagnosis ability of two CBCT systems, NewTom 3G Quantitative Radiology and 3DX Accuitomo, and two intraoral modalities, Digora-fmx Soredex and film Kodak Insight, with histological technique serving as the validation standard concluded that the NewTom 3G CBCT had a lower diagnostic accuracy for detection of caries lesions than intraoral modalities and the 3DX Accuitomo CBCT.

The Accuitomo CBCT had a higher sensitivity than the intraoral systems for detection of lesions in dentin, but the overall true score was not higher.

The investigation is applied in caries diagnosis stems from its numerous advantages when compared to all current forms of x-ray imaging.

CBCT utilizes the least amount of radiation to obtain a diagnostic image while remaining cost effective for patients.

Ultrasound techniques

The using of the ultrasound in caries detection was first suggested over 30 years ago, although developments in this field have been slow.

The principle behind the technique is that sound waves can pass through gases, liquids and solids and the boundaries between them. Images of tissues can be acquired by collecting the reflected sound waves. In order for sound waves to reach the tooth they must pass first through a coupling mechanism, and a number of these have been suggested, but those with clinical applications include water and glycerine.

A number of studies have been undertaken using ultrasound, with differing levels of success. A final in vivo study was undertaken using a device described as the Ultrasonic Caries Detector (UCD) which examined 253 approximal sites and claimed a diagnostic improvement over bitewing radiography. Despite these encouraging findings, no further research has been undertaken using the device and the research has only been published as abstracts.

Treatment of dental caries in children

The treatment goals in modern caries management should be:

- to prevent new lesions from forming;
- to detect lesions in early stage and treat and arrest them with non-operative means.

If these attempts have failed, restorations will be required to restore the integrity of the tooth surface.

The activity of caries should be determined and causative factors should be evaluated. Caries risk should be assessed before treatment is planned. Treatment should include preventive measures too.

Treatment of dental caries in primary teeth

Interceptive *treatment of early carious lesions* in the primary dentition includes general and local intervention.

General intervention has its aim to improve oral health behaviors and consists of diet counseling (do not use of bottle in bed at night), oral hygiene instruction (toothbrushing after first tooth eruption), use of fluorides (a smear size of fluoridated dentifrice 500 ppm) and antiseptics (chlorhexidine predominantly).

Local intervention has its aim to reverse arrest or postpone progression of specific lesions. This is achieved by healing (fluorides, glass ionomer cements, chlorhexidine).

Treatment principles for the arrest of carious lesions are the following:

1. Healing: remineralization by the application of fluorides (varnish), antiseptics (chlorhexidine and possibly other chemotherapeutics).
2. Sealing: restriction of nutrient supply to the cariogenic microbes in the lesion.
3. Restoring: removal and replacement of carious tissue.

Healing. Nowadays we can use the following scheme of antiseptics usage:

1. 0.05 % chlorhexidine solution — daily during 2 weeks with one month break;
2. Cervitek varnish (1 % chlorhexidine and 1 % thymol) — applications once in three months.

Earlier dentists used 10 % Povidone Iodine, but it is not recommended now due to side effects.

One of modern methods of microbial control is the using of ozone. A high oxidation potential effectively destroys microbial cells — there is sterilization of dental tissues. It uses before the mineralization, sealing and filling.

Remineralization. Classic course of remineralizing agents includes 10–15 procedures of:

- application of 10 % solution of calcium gluconatis (10 min);
- application of 2 % sol. NaF (3 min).

The course is very difficult to perform due to long lasting of procedure, the numerous visits to the dentist and absence of visible result after the several remineralizing procedure. Nowadays Ca-P remineralizing agents are used for home procedures by parents. Such medications as “GC Tooth Mousse” and “R.O.C.S medical minerals gel” should be applied daily 1 month (repeat course 3–4 times a year).

Fluoride varnishes seem to be the most practical in pre-school children and have been proved to be effective in the primary dentition according to the literature. The varnish should be applied at least twice a year, after taking the individual caries risk and use of other fluoride vehicles into consideration.

Sealing. Glass-ionomer cements seem to be optimal sealant in primary dentition. The retention of glass ionomers is poorer than that of resins, but the caries inhibiting effectiveness of glass ionomers seems to be good, probably because of their fluoride releasing properties.

The treatment of active caries in primary dentition should be based on principles for the treatment of an infectious disease. Control of cariogenic microflora should therefore be the major goal of general and local interventions. Since the disease process may be reversed or arrested in its early stages, identification of risk individuals and early intervention should be a priority in future pediatric dentistry.

Management of the advanced carious lesions in children at 0–3 years is based on the conception of minimal intervention dentistry. The conception includes prevention, remineralization and removal of affected tissue only.

In case of enamel caries the aim is to arrest caries. The treatment consists of grinding of the enamel following fluoride application; flossing with fluoride paste in case of proximal lesions; follow-up examinations.

The technique of fluoride application: the lesions are carefully cleaned with a rubber cup and a slow speed equipment and a fluoride varnish is applied. This procedure is repeated at least every three months during the first year.

In case of caries of the dentin restorative treatment should be used. It includes atraumatic restoration technique (ART), usage of antiseptic, glass ionomer cement as filling material and vaselin isolation.

If dentine caries occurs on occlusal surfaces of primary molars, excavation is needed because the lesion is not situated in a self-cleaning area. Sharp hand instruments and/or slow-speed drilling can be used to remove soft dentin caries before the placement of a temporary filling of zinc oxide-eugenol cement (or a similar cement).

It should be noted that it is important to remove caries from the enamel margins.

Strip crown technique may be used in case of extensive decay of primary incisors. The procedure is very technique sensitive, and any lapses in patient selection, moisture and hemorrhage control, tooth preparation, adhesive application and resin composite placement can lead to failure. The technique includes caries removal and reduction of all surfaces of a primary incisor, selection of an adequately-sized celluloid crown form, trimming of the crown form, acid etching and conditioning of the prepared tooth, filling of the crown form with a composite resin material, and seating of the filled crown onto the tooth. Then the composite resin is polymerized and the celluloid crown form is peeled off or “stripped” with a hand scaler. The remaining composite resin is finished at the margins and polished.

Management of the advanced carious lesions in children 4–6 years of age.

There is no need to remove more tooth substance than is necessary for the removal of degraded and infected dentin. Importantly, the enamel margins should be caries free. The following means of minimal intervention dentistry can be used:

- “Carisolv” (a combination of chemicals for softening and partially removing decayed dentin);
- ART;
- laser;
- ultrasonic abrasion.

It has been suggested that GIC used to seal extensive lesion will encourage the remineralisation of demineralised dentin at the floor of the cavity. The effective adhesion would prevent bacterial leakage and arrest the progress of demineralisation through the calcium, phosphate and fluoride ions from the cement. Consequently, it should not be necessary to remove all carious dentine from the floor of the cavity. Therefore it is not recommended to deliberately leave infected dentin at the floor of a cavity under a permanent restoration.

Management of the deep carious lesions in children 4–6 years of age. The routine technique includes:

- stepwise excavation: there should be no history of pain other than sporadic in connection with food intake, and no radiographic visible signs of pathology;
 - filling with ZOE (zinc-oxid eugenol paste/cement);
 - restoration with glassionomer/resin modified glass ionomer in 6–8 weeks.
- NB! Calcium hydroxide usage is not recommended in primary teeth.

Management of the advanced carious lesions in children 7–11 years of age (mixed dentition). After the first permanent molars have reached occlusion, a more radical treatment philosophy for primary molars can be applied, such as grinding and temporary restorations.

Primary first molars with extensive carious lesions should be extracted.

As exfoliation approaches, symptomless superficial dentin lesions can be treated interceptively.

Special attention should be paid to the distal surface of the second primary molar in caries active children and preventive measures should be instituted in order to prevent caries on the mesial surface of the first permanent molar.

Caries treatment in immature permanent teeth

Interceptive treatment of early carious lesions in the young permanent teeth generally is the same as for the primary ones.

In case of enamel caries on exposed smooth surfaces operative intervention is not required prior to cavitation but even cavitated lesions can be arrested. A wider range of fluorides can be used in schoolchildren thanks to their greater self-control: mouth rinse, solution, gel, varnish.

A special micro-invasive treatment of early, non-cavitated caries — “*Icon-Caries Infiltrant*” can be also used. The method permits to avoid unnecessary loss of healthy hard tissue and have a good esthetic effect. The treatment is based on carious enamel infiltration with a low viscous light cured resin.

In case of enamel caries in pits and fissures invasive sealing and preventive restoration should be used.

The preventive restoration a conservative occlusal restoration that involves replacement of discrete areas of carious structure with resin material (preventive resin restoration — PRR) or glass-ionomer cement (preventive glass-ionomer restoration — PGIR) followed by application of an overlying fissure sealant.

Management of the advanced carious lesions is based on the conception of minimal intervention dentistry. Minimally invasive dentistry cancels the classical rules of preparation: demineralized dentin is retained, we save the enamel without dentin support. Preparation is carried out by very small burs (spherical or conical) or by using the alternative methods of preparation (air abrasion, ultrasound, laser).

The cavities should be of spherical form (tooth stress resistance is greater) In case of small proximal cavities tunnel preparation and slot-preparation should be used (fig. 9).

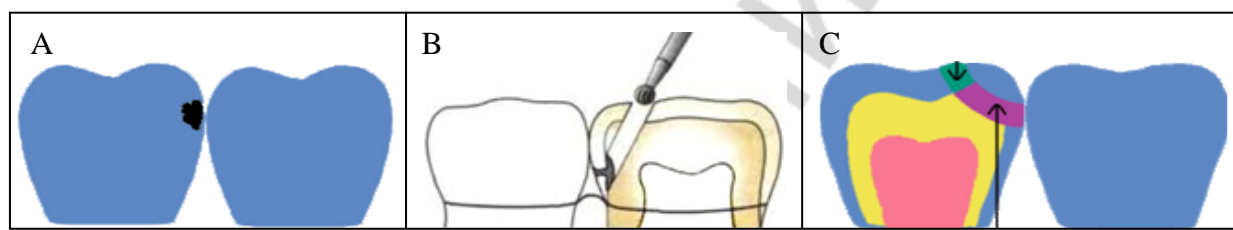


Figure 9. Tunnel preparation (A — initial situation, B — technique, C — final situation)

The most suitable filling materials for the restoration of cavities on the proximal surface are light-hardened glass ionomer resin cements.

The following principles of choice of filling material for young permanent teeth and high caries activity should be used:

- first restoration with light-hardened glass ionomer resin cements;
- after 2–3 years change the GIC on composites (GIC stays as a layer).

NB! Never use composites in young permanent teeth without protective layer (=> pulpal necrosis).

Organization and planning of dental care for children according to caries risk

Children with different risk of caries development need different frequency of follow-up and intensity of preventive procedures.

Organization and planning of dental care for children with low caries risk:

1. Visit to the dentist (education of patients and their parents, selection of tools and methods of oral hygiene, training in oral hygiene, diet recommendation and control of implementation of recommendations) — 2 times a year.

2. Professional oral hygiene and application of topical fluoride — 2 times a year.
3. Control of proximal surfaces — as the contact points are formed.
4. Non-invasive sealing of first permanent molars — as teething occurs.
5. Home mineralizing procedures — mouth foam or mouth rinse with Ca / Ca and F (depending on the patient's age).
6. Home oral hygiene — toothpaste with fluoride in accordance with age of the patient, dental floss (by parents until 10–12 years).

Organization and planning of dental care for children with moderate caries risk:

1. Visit to the dentist (education of parents, selection of tools and methods of oral hygiene, training in oral hygiene, diet recommendation and control of implementation of recommendations) — 3–4 times a year.
2. Professional oral hygiene and application of topical fluoride — 3–4 times a year.
3. Control of proximal surfaces — as the contact points are formed.
4. Invasive sealing of primary molars — if it is necessary.
5. Non-invasive sealing of permanent molars — as teething occurs and control of sealant is necessary.
6. Home mineralizing procedures — mouth foam, gel or mouth rinse with Ca / Ca and F (depending on the patient's age).
7. Home oral hygiene — toothpaste with fluoride in accordance with age of the patient, dental floss (by parents until 10–12 years).

Organization and planning of dental care for children with high caries risk:

1. Visit to the dentist (education of parents, selection of tools and methods of oral hygiene, training in oral hygiene, diet recommendation and control of implementation of recommendations) — 6 times a year.
2. Professional oral hygiene and application of topical fluoride — 6 times a year.
3. Control of proximal surfaces — as the contact points are formed.
4. Invasive sealing of primary molars — if it is necessary.
5. Non-invasive sealing of permanent molars and (if it is necessary) premolars — as teething occurs.
6. Home mineralizing procedures — mouth foam, gel or mouth rinse with Ca / Ca and F (depending on the patient's age).

Home oral hygiene — toothpaste with fluoride — 500 ppm for preschoolers and 1450 ppm for schoolchildren, olaflur is preferable fluorine compound, dental floss (by parents until 10–12 years).

LITERATURE

1. *Детская терапевтическая стоматология : учеб. пособие / Т. Н. Терехова [и др.] ; под ред. Т. Н. Тереховой.* Минск : Новое знание, 2017. 496 с.
2. *Abu-Hussein, M. Strip Crowns Technique for Restoration of Primary Anterior Teeth: Case Report / M. Abu-Hussein, A. Abdulgani Azzaldeen, M. .Abdulgani // Journal of Dental and Medical Sciences. Vol. 14. I. 12. Ver. VIII (Dec. 2015). P. 48–53.*
3. *Duggal, M. S. Paediatric dentistry at a glance / M. S. Duggal, A. Cameron, J. Toumba.* UK : John Wiley @ Sons LTD, 2013. 120 P.
4. *McDonald, R. E. Dentistry for the child and adolescent. Ninth Edition / R. E. McDonald, D. R. Avery, J. A. Dean Elsevier, 2011. 704 P.*

РЕПОЗИТОРИЙ БГМУ

CONTENT

Anatomical and physiological features of the primary and immature permanent teeth	2
Features of primary teeth	3
Features of young permanent teeth	4
Clinical features of caries in primary and immature permanent teeth	8
Dental caries features in primary teeth	8
Dental caries features in immature permanent teeth.....	10
Diagnosis of dental caries	10
Temporary separation	11
Radiographic Methods	11
Fiber-optic transillumination (FOTI).....	13
Digital imaging fiber-optic transillumination (DIFOTI)	14
Quantitative Light-induced Fluorescence (QLF).....	15
Laser fluorescence — DIAGNODent (DD), DIAGNODent pen.....	15
Electronic caries monitor (ECM).....	16
Endoscopic filtered fluorescence method (EFF)	17
Midwest Caries I.D.	17
Caries detection with chemical dyes.....	18
CarieScan	18
Ultrasound techniques.....	19
Treatment of dental caries in children	19
Treatment of dental caries in primary teeth	20
Caries treatment in immature permanent teeth	22
Organization and planning of dental care for children according to caries risk.....	23
Literature	25

Учебное издание

Шаковец Наталья Вячеславовна
Бурак Жанна Михайловна
Кленовская Маргарита Игоревна

**КАРИЕС ВРЕМЕННЫХ И НЕЗРЕЛЫХ
ПОСТОЯННЫХ ЗУБОВ**

**CARIES OF PRIMARY AND IMMATURE
PERMANENT TEETH**

Учебно-методическое пособие

На английском языке

Ответственная за выпуск Т. Н. Терехова
Переводчики Н. В. Шаковец, Ж. М. Бурак, М. И. Кленовская
Компьютерная верстка С. Г. Михейчик

Подписано в печать 01.12.17. Формат 60×84/16. Бумага писчая «Снегурочка».
Ризография. Гарнитура «Times».
Усл. печ. л. 1,63. Уч.-изд. л. 1,6. Тираж 50 экз. Заказ 753.

Издатель и полиграфическое исполнение: учреждение образования
«Белорусский государственный медицинский университет».
Свидетельство о государственной регистрации издателя, изготовителя,
распространителя печатных изданий № 1/187 от 18.02.2014.
Ул. Ленинградская, 6, 220006, Минск.

Репозиторий БГМУ