

A. N. ANTONENKO, ZH. M. BURAK

# OUTPATIENT PEDIATRIC ORAL SURGERY

ISBN 978-985-21-0058-8



9 789852 100588

Minsk BSMU 2018

МИНИСТЕРСТВО ЗДРАВООХРАНЕНИЯ РЕСПУБЛИКИ БЕЛАРУСЬ  
БЕЛОРУССКИЙ ГОСУДАРСТВЕННЫЙ МЕДИЦИНСКИЙ УНИВЕРСИТЕТ  
КАФЕДРА СТОМАТОЛОГИИ ДЕТСКОГО ВОЗРАСТА

**А. Н. АНТОНЕНКО, Ж. М. БУРАК**

**ДЕТСКАЯ ПОЛИКЛИНИЧЕСКАЯ  
ХИРУРГИЧЕСКАЯ СТОМАТОЛОГИЯ**  
**OUTPATIENT PEDIATRIC ORAL SURGERY**

Учебно-методическое пособие



Минск БГМУ 2018

УДК 616.31-089-039.57-053.2(075.8)-054.6

ББК 56.6я73

A72

Рекомендовано Научно-методическим советом университета в качестве учебно-методического пособия 18.04.2018 г., протокол № 8

Рецензенты: д-р мед. наук, проф. И. О. Походенько-Чудакова; д-р мед. наук, проф. А. С. Ластовка; канд. филол. наук, доц. М. Н. Петрова

**Антоненко, А. Н.**

A72 Детская поликлиническая хирургическая стоматология = Outpatient pediatric oral surgery : учебно-методическое пособие / А. Н. Антоненко, Ж. М. Бурак. – Минск : БГМУ, 2018. – 47 с.

ISBN 978-985-21-0058-8.

Посвящено вопросам воспалительных заболеваний челюстно-лицевой области у детей, как части дисциплины «Стоматология детского возраста и профилактика стоматологических заболеваний». Изложены современные представления об этиологии и патогенезе воспалительных процессов челюстно-лицевой области у детей, рассмотрены клинические проявления, особенности диагностики, дифференциальной диагностики и лечения таких клинически значимых патологий, как периоститы, остеомиелиты, верхнечелюстные синуситы и фурункулы. Разобраны показания и методика проведения местной и общей анестезии у детей, а также техника удаления временных и постоянных зубов.

Предназначено для студентов 4-го курса медицинского факультета иностранных учащихся, обучающихся по специальности 1-79 01 07 «Стоматология» на английском языке.

УДК 616.31-089-039.57-053.2(075.8)-054.6

ББК 56.6я73

ISBN 978-985-21-0058-8

© Антоненко А. Н., Бурак Ж. М., 2018

© УО «Белорусский государственный медицинский университет», 2018

## **LOCAL ANESTHESIA DURING SURGICAL PROCEDURES IN CHILDREN. INDICATIONS AND CONTRAINDICATIONS. COMPLICATIONS OF LOCAL ANESTHESIA AND THEIR PREVENTION**

*Local anesthesia* is the major type of anesthesia in dentistry. It is indicated in all painful dental procedures, being contraindicated only if a patient is hypersensitive to local anesthetic. Regional anesthesia blocks transmission of nerve impulses between a target part of the body and the central nervous system, causing loss of sensation in the target body part. A patient under regional or local anesthesia remains conscious.

Local anesthesia helps to prevent pain sensation during dental procedures, build trust relationship of the child and the dentist, avoid fear and anxiety and promote a positive attitude to dental procedures. The technique of local anesthetic administration, age-appropriate nonthreatening terminology, as well as distraction should be the main concerns in pediatric patient behavior management.

In pediatric dental practice, the following types of local anesthesia are used: non-injection (chemical, physical) anesthesia and injection (infiltration, block) anesthesia.

### **NON-INJECTION METHODS OF ANESTHESIA**

They include:

1) Physical methods: skin freezing (chloroethyl); electric anesthesia (electrical block anesthesia) — a technique that involves using constant electric current to block the reception or generation of pain signals to the tooth pulp; the pain control can be transient.

2) Chemical methods: topical (surface, applicative) anesthesia. It is carried out by non-injection application of an anesthetic on the tissue surface. The anesthetic blocks the receptors and terminal nerve endings. Topical anesthetic is effective in surface tissues (up to 2–3 mm deep). The application of a topical anesthetic may help to minimize discomfort caused during administration of local anesthesia, as it will reduce painful needle penetration of the oral mucosa.

**Indications for topical anesthesia are:**

- anesthesia of the point of injection;
- extraction of mobile temporary teeth with the roots resorbed as a result of physiological change;
- removal of small benign tumors of oral mucosa (papillomas, local hyperplastic gingivitis, etc.).

Topical anesthetic is applied or sprayed onto the previously dried oral mucosa on a narrow gauze or cotton ball for several seconds. In 20–30 seconds surgical intervention is performed (fig. 1). Topical anesthetic agents are available in gel, liquid, ointment, patch, and aerosol forms. The examples of topical anesthetics are: 3 % lidocaine gel; 2–3 % lidocaine ointment; 5 % piromecain ointment; 10 % lidocaine spray, etc.

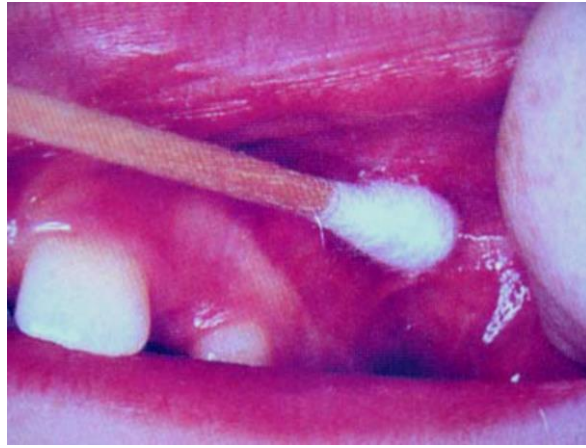

Fig. 1. Applicative Anesthesia

### INJECTION METHODS OF ORAL ANESTHESIA

Injection anesthesia is concerned with a temporary loss of pain sensation from the corresponding part of the body by injecting an anesthetic solution close to:

- a) peripheral nerves and their terminals (infiltration anesthesia);
- b) nerve trunk (regional nerve block).

**Infiltration anesthesia** is a technique, in which the anesthetic solution medicates the tissues around the point of injection and blocks the large nerve branches directly supplying this area.

*Indications for infiltration anesthesia are:*

- extraction of upper primary teeth;
- incision of subgingival and submucosal abscesses;
- removal of small benign tumors and tumor-like formations of mucosa (papillomas, fibromas, retention cysts, etc.)
- surgical treatment of wounds;
- plastic of lip frenulum and tongue, etc.

Injection toolkit for children includes the following instruments: 2 ml disposable plastic syringes with 10–25 mm needles; cartridge syringes with 10–25 mm needles; 1 ml disposable insulin syringes.

All local anesthetic agents used in dentistry work by reducing the permeability of a Na<sup>+</sup> channel, which is essential for the initial phases of neuronal action potential. This mechanism inhibits the development and propagation of the action potential by preventing depolarization.

Many local anesthetic agents are available to facilitate pain management in a dental patient. There are two common types of local anesthetic chemical formulations: esters (procaine, benzocaine, tetracaine) and amides (lidocaine, mepivacaine, prilocaine, articaine). Absolute contraindication for local anesthetics is a registered local anesthetic allergy. True allergy to amides is exceedingly rare.

Selection of local anesthetic agents should be based upon:

- the patient's medical history and mental/developmental status;
- the anticipated duration of the dental procedure;

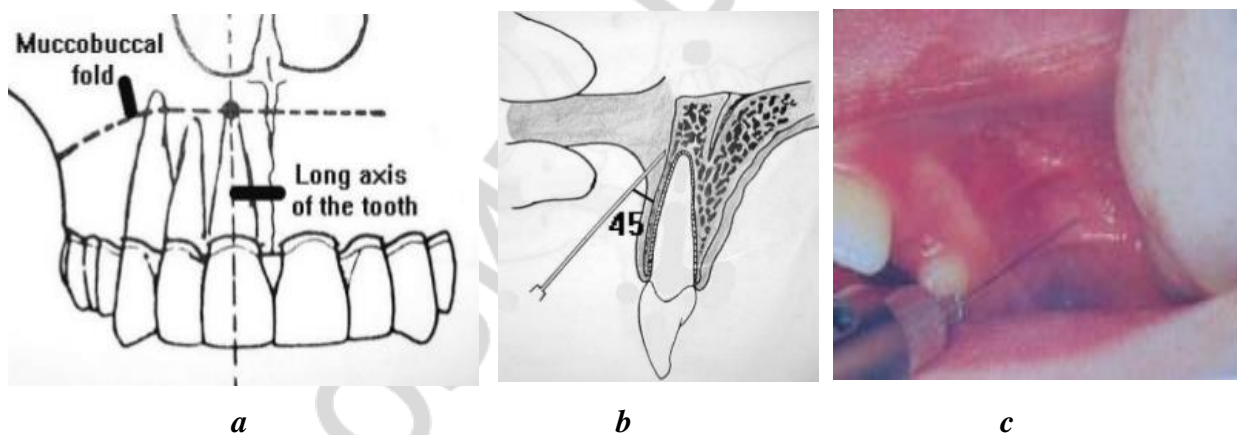
- the need for hemorrhage control;
- the practitioner's knowledge of the anesthetic agent.

In pediatric dentistry, the dental professional should be aware of proper dosage (based on the body weight) to minimize the chance of toxic effect and unnecessary duration of anesthesia, which can lead to accidental trauma of the lip, tongue, or soft tissue. Knowledge of neuroanatomy of the head and neck allows for proper application of the anesthetic solution and helps to minimize possible complications. Information from the patient's medical history is essential to decrease the risk of aggravation of a medical condition in dental care.

A pediatric dentist must have at least two different types of anesthetics for injecting anesthesia:

- 1) Anesthetic solution without vasoconstrictor (VC) — plain:
  - 2 % lidocaine solution;
  - 4 % articaine solution (Septanest SVC);
  - 3 % mepivacaine solution (Scandonest SVC).
- 2) Local anesthetics with vasoconstrictor:
  - 2 % lidocaine (1 : 100 000 / 1 : 50 000);
  - 4 % articaine (1 : 100 000 / 1 : 200 000) — Ultracaine; Septanest; Ubistesin.

The dentist distracts the child's attention and asks the little patient to take a deep breath before injection. Then the doctor compresses the tissue and slowly injects the local anesthetic solution (1 ml — 15–20 sec). The injection site for infiltration anesthesia is the mucobuccal fold at 45° to the long axis of the tooth at the bone contact. In 2–3 min surgical intervention is performed (fig. 2).



*Fig. 2. Infiltration Anesthesia Technique:*

*a — scheme, frontal view; b — scheme, sagittal view; c — view in the oral cavity*

**Regional nerve block:** injection of anesthetic solution along the nerve trunks and plexuses resulting in the loss of sensitivity in the area of their innervation.

*Indications for peripheral nerve block:*

- Extraction of upper and lower temporary and permanent teeth;
- Cystotomy and cystectomy;
- Surgical treatment of wounds;

- Splinting of fractures of the jaw;
- Dental/orthodontic treatment (in case of ineffectiveness of other methods of anesthesia);
- Removal of tumors, etc.

Pediatric dentist usually uses a *palatal*, *mandibular* and *incisal* anesthesia.

**Palatal anesthesia:** the injection point is midway between the gingival margin of the tooth and median palatal raphe. The greater palatine foramen is situated on the midway between the last tooth and median palatal raphe 0.5 mm back from the border of the soft and hard palate (fig. 3).

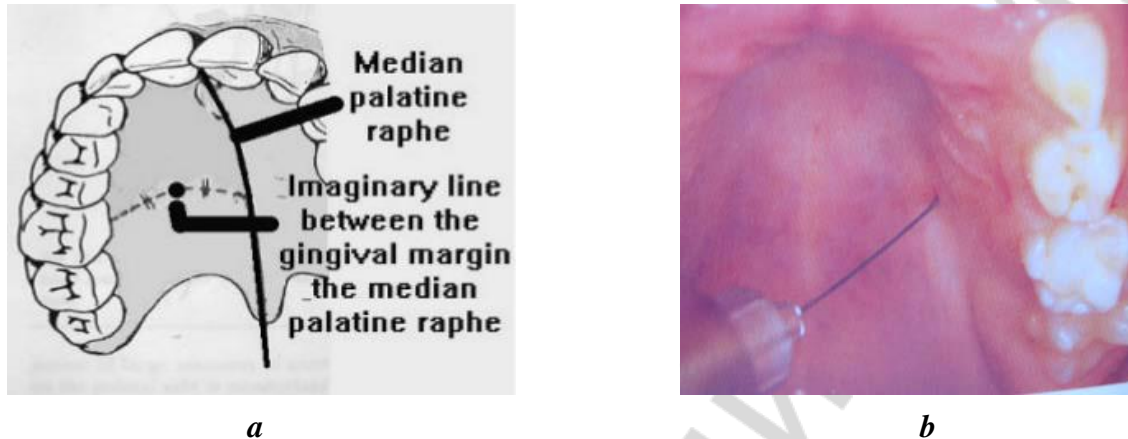

Fig. 3. Palatal Anesthesia:  
a — scheme; b — view in the oral cavity

**Area of anesthesia:** mucosa and periosteum until mid-canine. The dose of anesthetic solution is 0.3 ml.

**Incisive canal nerve block** is a painful injection. The aim is to anesthetize the nasopalatine nerve. The injection needle is directed towards the crest of incisive papilla making an angle of 45° to palatal mucosa (fig. 4).

**Area of anesthesia:** the mucosa and periosteum from the right mid-canine to the left mid-canine, the anesthetic dose is 0.1–0.2 ml.

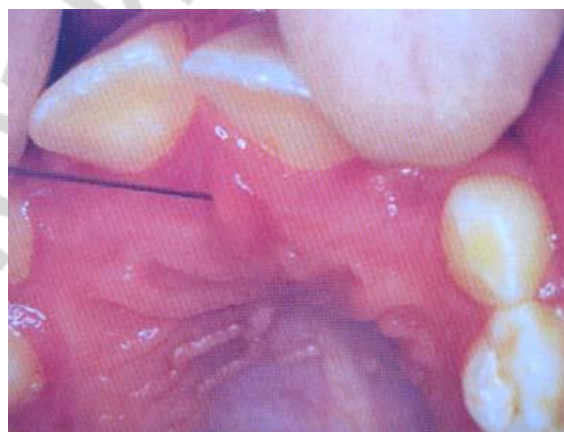

Fig. 4. Incisive Canal Nerve Block

**Inferior alveolar nerve block** can be performed in 3 ways:

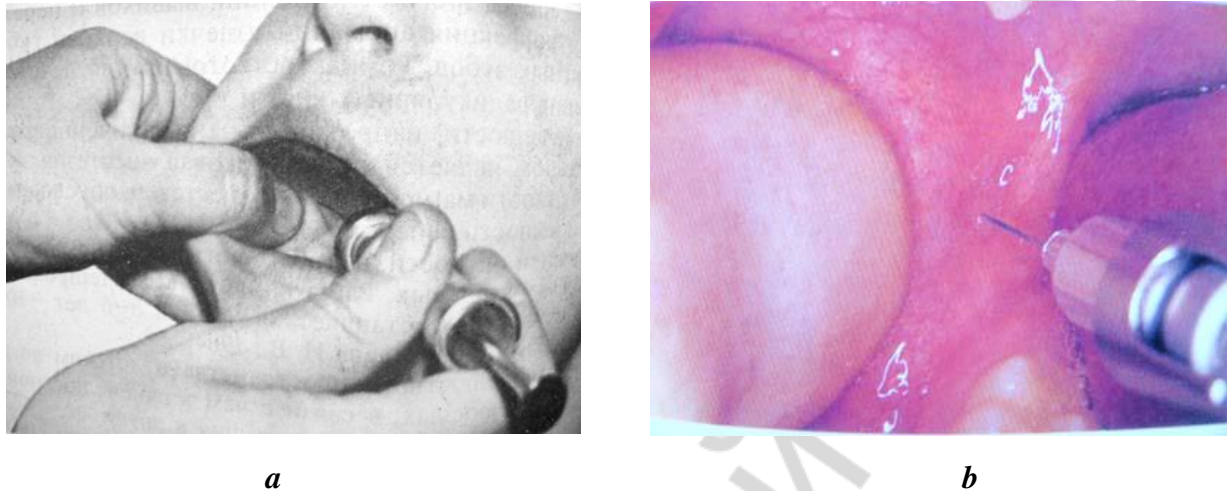
- 1) The needle is injected into the lateral side of pterygomandibular raphe;



2) Retromolar fossa is palpated by the forefinger and the needle is introduced at the surgeon's mid nail into the lateral side of the pterygomandibular raphe;

3) If the patient doesn't have teeth, the injection is introduced into the lateral side of pterygomandibular raphe between the middle and lower third.

The needle should be buried until the bone. The syringe is situated on the opposing teeth (fig. 5).



*Fig. 5. Right Inferior Alveolar Nerve Block:  
a — general view, b — view in the oral cavity*

*Area of anesthesia:* mandibular molars, premolars, canines, and incisors; the lingual mucosa and periosteum at half of the jaw; frontal  $\frac{2}{3}$  of the tongue; half of the lower lip; the vestibular mucosa and periosteum except molar area. The dose of anesthetic solution is 2–3 ml (not more than 4 ml).

*Specifics of the inferior alveolar nerve block technique in children:*

– In children under 5 years the injection point is located just below the occlusal surfaces of the lower teeth, and in children over 5 years it is a little superior to the occlusal surface;

– Vessel injury is more likely during anesthesia in children and teenagers;  
You can use shorter needles than for adults.

**Alternative techniques of local anesthesia.** The majority of local anesthesia procedures in pediatric dentistry involve traditional methods of infiltration or nerve block techniques with a dental syringe, disposable cartridges, and needles as described so far. Several alternative techniques, however, are available. These include computer-controlled local anesthetic delivery, periodontal injection techniques, needleless systems and intraseptal or intrapulpal injection. These techniques may improve comfort of injection by better control of the administration rate, pressure, and location of anesthetic solutions and/or result in successful and more controlled anesthesia.

As with traditional methods, alternative techniques of oral local anesthesia are safe if the practitioner understands the principles of their use. Some of these techniques are desirable, especially in infants, children, teenagers, and handicapped patients, since



specific teeth may be anesthetized with less residual anesthesia, avoiding discomfort and potential self-mutilation associated with block anesthesia. The mandibular bone of a child is usually less dense than that of an adult, permitting more rapid and complete diffusion of the anesthetic. Mandibular buccal infiltration anesthesia is as effective as inferior nerve block anesthesia for some operative procedures.

Infiltration anesthesia may cause complications of general and local nature.

### COMMON COMPLICATIONS OF INJECTION ANESTHESIA

Administration of local anesthetics is a daily routine for most dental practitioners. Normally, the effect is achieved and no adverse effects are seen. However, complications, even very serious ones, can occur in daily practice.

**Anesthetic toxicity (overdose).** While rare in adults, young children are more likely to develop toxic reactions because of their lower weight. Such reactions often occur within 5–10 minutes of injection. Overdosage of local anesthetics is caused by high levels of anesthetic in blood as a result of an inadvertent intravascular injection.

Local anesthetic toxicity is preventable by following proper injection technique, i. e., aspiration during slow injection. Clinicians should be knowledgeable of maximum dosages based on weight.

**Fainting (syncope):** brief loss of consciousness due to acute cerebral hypoxia as a result of vasospasm. Causes of syncope can be fear and anxiety before dental treatment, strong negative emotions, acute pain, and long waiting time before attendance.

The *signs and symptoms* of syncope are divided into early and late. At the early stage, the patient exhibits a loss of color with an ashen-gray skin tone, heavy perspiration, «feeling sick», slightly lower blood pressure and tachycardia. At the late stage, the clinical manifestations include dizziness, hypotension, bradycardia and loss of consciousness.

*Emergency care:*

- the patient is placed into supine position, legs slightly elevated;
- ensure the inflow of fresh air;
- stimulate respiratory and vascular centers by inhalation of ammonia spirit;
- In case of prolonged syncope, inject intravenously or intramuscularly (but not subcutaneously) 1 ml of 10 % solution of caffeine sodium benzoate.

**Collapse (vasovagal shock):** one of the acute forms of vascular insufficiency characterized by reduction of vascular tone and acute decrease of circulating blood volume, patient conscious.

*The clinical features of vasovagal shock.* Consciousness is retained, but it can be confused. The child is conscious, but apathetic. The skin is pale and cyanotic. The patient also exhibits shallow breathing, lower blood pressure and tachycardia.

*Emergency care:*

- Patient is placed into supine position;
- Ensure the inflow of fresh air, oxygen;

– Injection of prednisolone 1–2 mg / kg of body weight intravenously or intramuscularly;

– Injection of cordiaminum or mesaton solution subcutaneously. If there is no effect, 0.5 ml injection of epinephrine. After that patient must be hospitalized.

**Anaphylactic shock:** immediate allergic hypersensitivity reaction to the introduction of the drug, which is characterized by sharp deterioration in the activity of the cardiovascular system with the development of acute cardiovascular insufficiency and loss of consciousness. It is a life-threatening condition. The reactions occur even within 1 minute after injection.

*Clinical signs* may differ in severity. The patient exhibits anxiety, chest and abdominal pain. Locally, redness, itching and swelling of the eyelids, nasal mucous membranes, mouth and larynx may develop. Laryngeal and glottic edemas are associated with the risk of suffocation. Severe reactions may lead to hypotension, tachycardia and then to respiratory and cardiac arrest, loss of consciousness.

*Emergency care:*

– Stop the drug injection, call in an ambulance;

– The patient must be placed into supine position, legs slightly elevated.

Oxygen inhalation must be provided;

– Inject intravenously 0.3–0.5 ml of 0.1 % epinephrine solution (0.05 ml / year of life) in 5 ml of isotonic sodium chloride solution or glucose;

– Injection of prednisolone (3–5 mg – 1 kg body weight) intravenously;

– Injection of 2 % solution of dimedrol (0.5 mg – 1 kg of body weight) or 2% suprastin intravenously;

– For bronchospasm removal, 2.4 % eufhyllinum intravenously in age-specific doses (less than 1.0 ml);

– Provide intravenous fluid injection to increase blood volume and blood pressure stabilization. After that the patient must be hospitalized.

#### LOCAL COMPLICATIONS OF INJECTION ANESTHESIA

***Pain and burning during injection.*** These sensations are always short-time and can be prevented. Factors depending on the solution are low pH-value that may irritate the tissue, and the temperature of the solution, warmer solution feeling more comfortable than cold. The cartridge can be warmed in the practitioner's hand or in warm water before injection.

The practitioner-related factors relate to the technique used. Fast injections and high injection pressures cause pain. This can be avoided only by a slower injection (1 cartridge — 1 min).

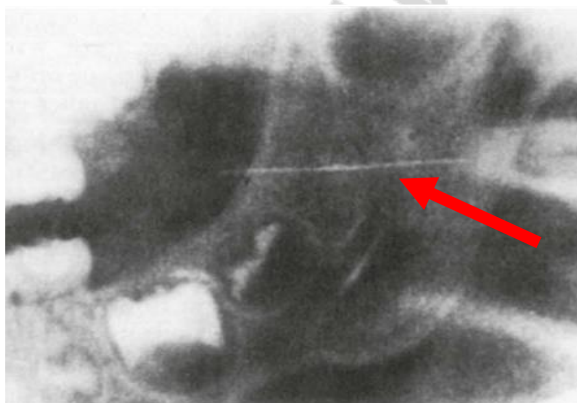
***Paresthesia (residual anesthesia).*** It is the persistence of anesthetic symptoms beyond the expected duration. Clinical manifestations are small change or decrease of sensitivity, which is never accompanied by the lesion of the whole nerve. Incorrectly performed injection or usage of higher concentrations of anesthetic solution (4 % prilocaine solution) can cause paresthesia. Treatment is not required, paresthesia subsides spontaneously within a few weeks or months.

**Postinjection traumatic contracture (trismus).** Clinical manifestations are limitations of mouth opening of various degrees. It can occur even in 2–5 days after injection anaesthesia. Trismus after anaesthesia is usually caused by intramuscular injection of the anaesthetics in the pterygomandibular space. This complication often develops after inferior alveolar block anaesthesia. Trismus can also follow multiple injections into the same area, or a large haematoma.

It usually disappears within a few days without a need for further treatment. Treatment in severe cases should presuppose heat therapy, analgesics, soft diet, muscle relaxants or physiotherapy.

Awareness of the anatomical landmarks and muscles, careful insertion of the needle and bone contact before injecting are good methods for avoiding the painful trismus.

**Needle breakage.** An injection needle breaks at the junction between the needle and cannula. It often occurs at mandibular nerve block. Modern disposable needles are broken extremely rarely. Smaller diameter needles break more often. Reasons for needle breakage can be categorized into three different groups: a sharp movement of the syringe from one position to another, sudden movement of the child's head at the time of injection and inserting the needle full length down to the cannula (fig. 6).



*Fig. 6.* Injection needle in soft tissues after inferior alveolar nerve block (X-ray)

Treatment includes removal of the needle by pulling out the protruding end with the tweezers. If the needle fragment is completely immersed into the tissue and can't be extracted, hospitalization and surgical intervention are required.

**Infecting.** The injection should be done according to the rules of aseptic and antiseptic treatment (not touching the teeth and tongue with the needle and etc.).

**Haematoma.** It is caused by perforating the vessel with the needle or by an intravascular injection, which causes trauma to the affected blood vessel. Trauma causes bleeding into the tissue and the formation of a haematoma.

It is important to learn adequate techniques and anatomical landmarks and to avoid dislocating the needle to different sides inside the tissue. Haematoma formation can be avoided by careful aspiration before injecting the anaesthetic and by gentle removal of the needle. Prevention includes injection of local anaesthetic solution before the needle moved forward and aspiration test.

**Postoperative soft tissue injury.** Accidental biting or chewing of the lip, tongue or cheek is a problem often seen in children. Soft tissue anesthesia lasts longer than pulpal anesthesia and may persist for up to 4 hours after the procedure. The most common area of trauma is the lower lip and, to a lesser extent, the tongue, and most rarely the upper lip. The lip and cheek-biting lesions usually heal without complications, although bleeding and infection are possible. Using mandibular infiltration instead of nerve blocks is not of great value in prevention of these injuries, since the duration of soft tissue anesthesia may not be reduced significantly (fig. 7).

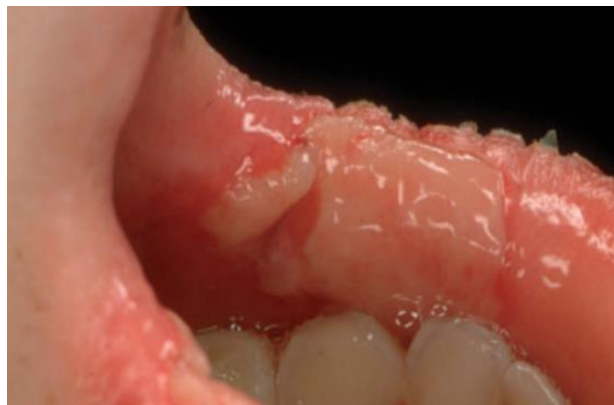

Fig. 7. Self-trauma of lower lip after mandibular nerve block

Caregivers responsible for postoperative supervision should be informed of expected duration of numbness and of the possibility of soft tissue trauma. Visual examples may help emphasize the importance of observation during the period of numbness. Patient should delay eating and avoid hot drinks until the effects of the anesthesia are totally dissipated.

#### TEST FOR SELF-CONTROL

##### 1. Types of local anesthesia are:

- |                      |                            |
|----------------------|----------------------------|
| a) mask anesthesia;  | c) applicative anesthesia; |
| b) block anesthesia; | d) physical anesthesia.    |

##### 2. Indications for topical anesthesia in children are:

- |  |                                    |
|--|------------------------------------|
| a) extraction of temporary teeth;        | c) anaesthesia of injection point; |
| b) extraction of mobile temporary teeth; | d) plastic of upper lip frenulum.  |

##### 3. Indications for infiltration anesthesia in children are:

- |                                   |                                   |
|-----------------------------------|-----------------------------------|
| a) extraction of Teeth 55 and 65; | c) extraction of Teeth 16 and 26; |
| b) extraction of Teeth 36 and 46; | d) surgical treatment of wounds.  |

##### 4. What types of block anesthesia are commonly used in pediatric surgical dental practice?

- |                                   |                                |
|-----------------------------------|--------------------------------|
| a) high tuberosity block;         | c) mental nerve block;         |
| b) inferior alveolar nerve block; | d) incisive canal nerve block. |

##### 5. Local complications of local anesthesia are:

- |               |              |                |             |
|---------------|--------------|----------------|-------------|
| a) haematoma; | b) bleeding; | c) dry socket; | d) syncope. |
|---------------|--------------|----------------|-------------|

## 6. Common complications of local anesthesia are:

- a) paraesthesia;
- b) diabetes mellitus;
- c) anaphylactic shock;
- d) syncope.

**Keys:** 1 – b, c, d; 2 – b, c; 3 – a, c, d; 4 – a, c, d; 5 – a, b, c; 6 – c, d.

## GENERAL ANAESTHESIA. INDICATIONS AND CONTRAINDICATIONS FOR PLANNED GENERAL ANAESTHESIA

*General anesthesia (narcosis)* is a medically induced state of unconsciousness with the absence of pain sensation all over the body, through the administration of general anesthetic drugs. The purposes of general anesthesia are the following: pain relief (analgesia), blocking memory of the procedure (amnesia), producing unconsciousness, inhibiting normal body reflexes (making surgery safe and easier to perform) and relaxing the muscles of the body.

Anesthesia performed with general anesthetics occurs in four stages: analgesia, excitement, surgical anesthesia, medullary paralysis. Child examination before general anaesthesia includes: complete blood count (clotting and blood platelets); blood group and rhesus; blood chemistry; general urine test; fecal test for helminth eggs; electrocardiogram; pediatrician opinion; conclusion of experts in the presence of comorbidities.

*Classification of general anesthesia.* General anesthesia is divided into inhalational (mask, nasopharyngeal, endotracheal intubation) and non-inhalational (intravenous, intramuscular, intrarectal) (fig. 8).

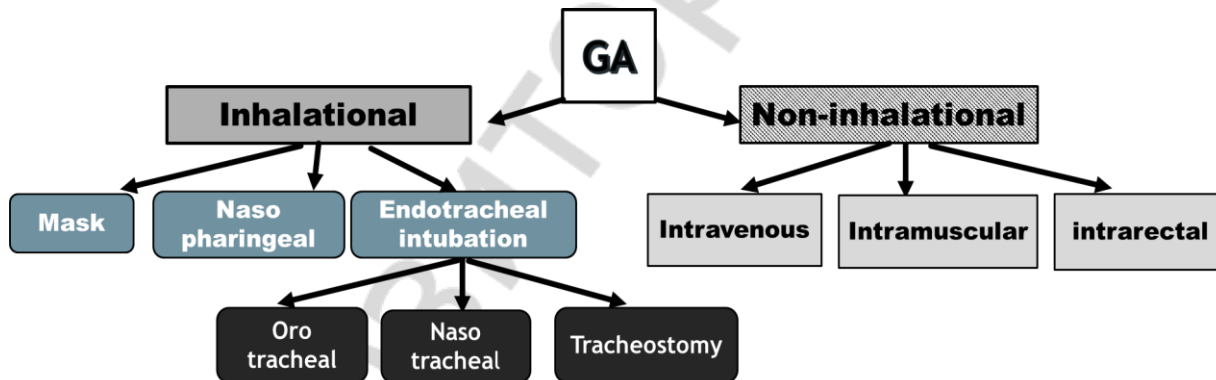


Fig. 8. Types of general anesthesia

**Indications** for general anaesthesia in children are:

1. Malformations (diseases) of central nervous system (oligophrenia, Down's syndrome and etc.);
2. Epilepsy;
3. Intolerance of local anesthetics;
4. Increased psycho-emotional anxiety of child;
5. Diseases of the cardiovascular system in the compensation stage;
6. Bronchial asthma;
7. Children up to 5 years;



8. Odontogenic inflammatory diseases (abscesses, phlegmon, etc.), where local anaesthesia is painful and ineffective;
9. A time-consuming operation in which a local anesthetic is inadequate;
10. Big number of teeth to be treated during one visit;
11. The desire of parents (except for contraindications).

**Contraindications** for general anaesthesia in children:

1. Acute upper respiratory tract diseases or exacerbation of chronic diseases;
2. Acute diseases of parenchymal organs (liver and kidneys) or exacerbation of chronic diseases;
3. Uncompensated diabetes mellitus, rickets;
4. Diseases of the cardiovascular system in the stage of decompensation;
5. Increased body temperature (infectious diseases, viral infections, etc.);
6. A full stomach (not earlier than 4 hours after a meal);
7. Difficulty in nasal breathing (for nasopharyngeal anaesthesia);
8. Acute stomatitis, including viral;
9. Constitution anomalies associated with hypertrophy of the thymus;
10. Haemorrhagic diathesis (hemophilia).

If a child needs emergency care (in case of trauma, inflammatory diseases), many of the above contraindications are not taken into account or the child is prepared in a special way for an emergency operation under general anaesthesia.

**Inhalation anaesthesia** is narcosis, wherein anaesthetics in gaseous or vapor state are introduced into the respiratory system. Anaesthetics can be delivered via inhalation through an anaesthesia mask, laryngeal mask airway or tracheal tube. Types of inhalation general anaesthesia are mask, nasopharyngeal and endotracheal anaesthesia (through nose, mouth or tracheostomy (fig. 9)).

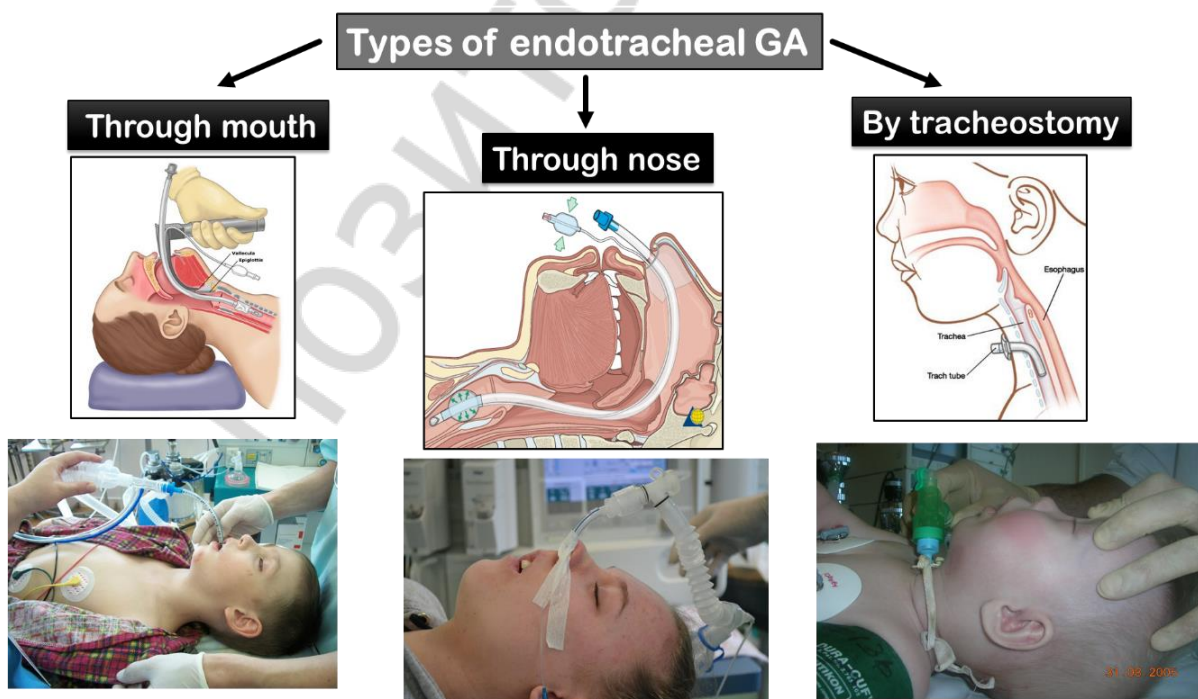


Fig. 9. Endotracheal intubation



Inhalation anesthetics are fluorotane, halothane, pentran, nitrous oxide, galan, etc. In pediatric dentistry fluorotane (halothane) — nitrous oxide — oxygen mixture is most often used.

Inhalation anesthesia is easily controlled, which is an advantage: children quickly fall asleep and quickly wake up after ceasing the narcosis. However anesthetic masks complicate operations in maxillofacial area and oral cavity. In addition, the mask and nasopharyngeal narcosis is dangerous of asphyxia. Endotracheal anesthesia is used to prevent it and perform the most traumatic operations. It is the main kind of anesthesia in a hospital, the safest for the patient and comfortable to the surgeon.

**Non-inhalation anesthesia** is a narcosis, which is caused by general anesthetics introduced into the body by non-inhalation way.

It is often used in short operations. The anaesthesia starts in 4–6 minutes and lasts for 1 hour. Types of non-inhalation general anesthesia are the following: intravenous, intramuscular and intrarectal. Intravenous anesthesia as an independent method is most often used in children. Non-inhalation anesthetics include sodium thiopental, hexenal, sodium hydroxybutyrate, ketamine and etc. Advantages of non-inhalation anesthesia are availability, simplicity and free access to the oral cavity. The disadvantages are the following: bad controllability and risk of asphyxia.

Pharmacological preparation for general anesthesia and surgical operation is called **premedication**. It aims at creation of emotional comfort; facilitation of anesthesia administration; decreasing the dose of the drug; prevention of reflex reaction and decreasing the salivary glands secretion.

On this basis, premedication drugs are the following: sleeping pills (phenobarbital or other barbiturates); antihistamines (diphenhydramine, suprastin); analgetics (promedol, analgin); tranquilizers (seduxen, elenium) and atropine.

**Reanimation** is resuscitation of the patient in cardiac arrest and apnea (respiratory arrest). During clinical death (3–5 minutes), if emergency measures are taken, it is possible to save the patient's life. All physicians must know how to restore cardiac activity and breathing by simple methods.

**Respiratory arrest** occurs most often due to the obstruction of the upper respiratory tract, dislocation of the tongue, aspiration of liquids, obstruction by blood clots or other objects. To restore breathing, open the patient's mouth, remove foreign bodies from it, tilt the head back and move the lower jaw forward. If breathing has not recovered, perform artificial pulmonary ventilation using mouth-to-mouth or mouth-to-nose methods, or a breathing apparatus (blowing frequency: 20–30 times per minute).

**Cardiac arrest** is the most dangerous complication, requiring immediate indirect heart massage with artificial pulmonary ventilation. The patient should lie on his back on a hard surface. The doctor performs chest compressions, 100 per minute, to 5 cm depth. Heart massage is performed with two fingers in children under one year, with one hand in children under 10 years and two hands in older children. The ratio of heart massage and artificial ventilation is 30 : 2 (fig. 10).

Outpatient resuscitative measures should be carried out before the arrival of emergency care. Patients after cardiac and respiratory arrest are requiring intensive care in a hospital.

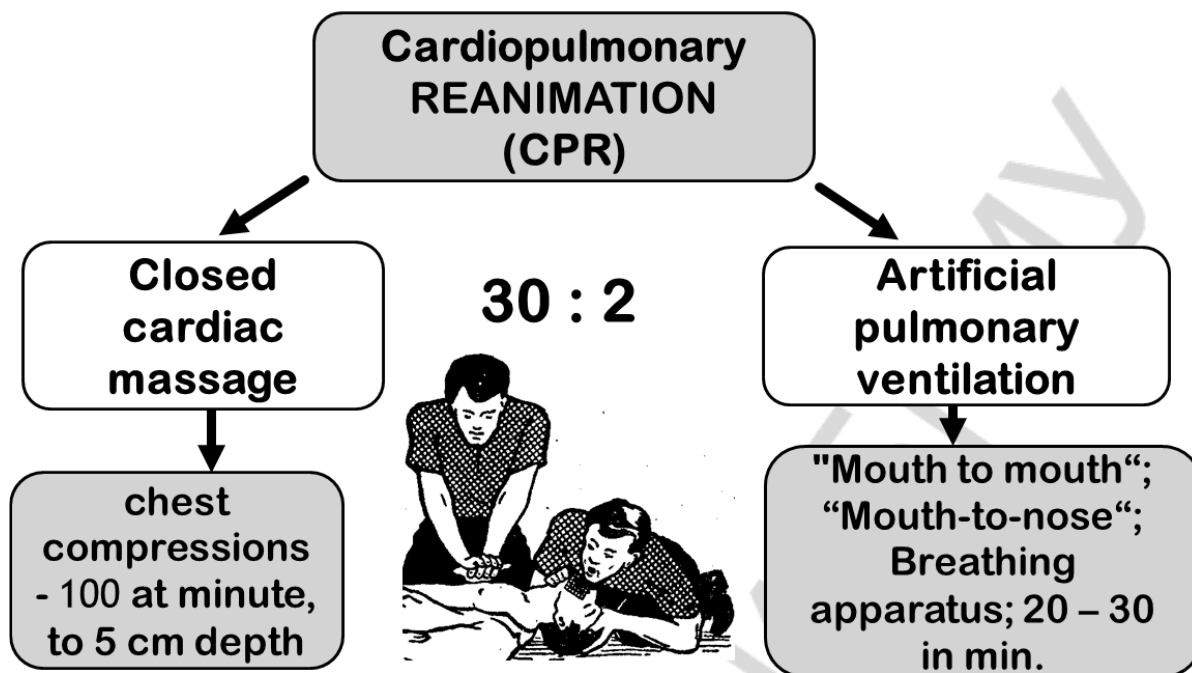


Fig. 10. Resuscitative Measures

#### TEST FOR SELF-CONTROL

**1. Types of general anesthesia are:**

- a) inhalational anesthesia;
- b) intravenous anesthesia;
- c) topical anesthesia;
- d) intramuscular anesthesia;
- e) infiltration anesthesia.

**2. Indications for general anesthesia in children are:**

- a) child under 5 years;
- b) cardiovascular diseases in the stage of decompensation;
- c) acute bronchitis;
- d) epilepsy;
- e) allergy to local anesthetics.

**3. Contraindications for planned general anaesthesia are:**

- a) full stomach;
- b) dry socket;
- c) hyperthermia;
- d) cardiovascular diseases in the stage of decompensation;
- e) psychoemotional excitability in the child.

**4. Select inhalation anesthetics:**

- a) halothane;
- b) lidocaine;
- c) nitrous oxide;
- d) articaine;
- e) galan.

**Keys:** 1 – a, b, d; 2 – a, d, e; 3 – a, c, d; 4 – a, c, e.

## **TOOTH EXTRACTION IN CHILDREN: INDICATIONS, CONTRAINDICATIONS, FEATURES OF EXTRACTION TECHNIQUES, COMPLICATIONS AND THEIR PREVENTION**

### ***Orthodontic indications for teeth removal:***

1. Absolute macrodontia (greater than or equal to 35 mm).
2. Relative macrodontia (32–34 mm).
3. Significant disparity in the size of temporary molars and permanent premolars in one or both jaws.
4. Mesial displacement of lateral teeth to 4 mm and more.
5. The mesial inclination of canine and premolar germs by 35° and more in relation to the occlusal plane.
6. Underdevelopment or excessive development of jaws.
7. Open bite combined with tight position of the front teeth.
8. Hotz's method of serial removal of teeth.

### ***Indications for teeth extraction in inflammatory processes:***

1. Chronic apical periodontitis of deciduous teeth:
  - teeth with resorbed roots (before exfoliation 1–1.5 years);
  - in case of involvement of tooth germ in the inflammatory process (radiographically confirmed threat of death of the permanent tooth germ);
  - in case of death of permanent tooth germ confirmed radiologically;
  - teeth with destroyed crowns;
  - roots of primary teeth;
  - in case of prolonged and unsuccessful treatment with frequent exacerbations.
2. Chronic periodontitis of permanent teeth: destroyed teeth, except the roots of single-root teeth, which can be restored by orthopedic reconstructions.
3. Acute purulent periostitis: remove «causative» temporary teeth and roots of permanent «causative» teeth.
4. Chronic periostitis: remove all temporary «causative» teeth and permanent «causative» multirooted teeth.
5. Acute and chronic osteomyelitis: remove all «causative» temporary and permanent multi-rooted teeth.
6. Acute and chronic lymphadenitis: «causative» teeth are removed, as in periodontitis.
7. Odontogenic phlegmon: remove «causal» temporary and multirooted permanent teeth, as in osteomyelitis.

### ***Indications for teeth extraction in case of traumatic injuries:***

- temporary and permanent teeth, if they interfere with the reposition of fragments;
- teeth with root fractures;
- teeth with complicated caries;
- dislocated teeth.

Temporary teeth with broken roots as well as permanent teeth with longitudinal, oblique, comminuted, transverse root fractures and multi-rooted teeth should be removed.

In teeth avulsion, temporary teeth are removed, permanent teeth with broken roots, in destruction of the tooth socket or the development of inflammatory process in it, and if more than 7–10 days have passed after trauma. In children under 2 years and over 5 years temporary frontal teeth with subluxation should be removed. In impacted luxation, the temporary tooth is removed if it threatens the permanent tooth germ or the inflammatory process develops. Permanent teeth are saved.

Temporary and permanent *teeth that caused tumor or tumor-like formation* (follicular, radicular tooth-containing cysts, odontoma, etc.) *should be removed*.

**Contraindications** for planned teeth extraction in a polyclinic are relative and can be general and local.

**General:** blood disease, acute infectious diseases, acute diseases of the parenchymal organs, cardiovascular system in the stage of decompensation, hyperthermia.

**Local:** inflammatory processes in the pharynx and oral cavity (sore throat, herpetic infection, stomatitis), tumors (especially those of unknown etiology).

The technique of removing temporary teeth has its own peculiarities.

There are some features in the technique of temporary teeth extraction. This is connected with the small size of a child's jaw, presence of the germs of permanent teeth and anatomical features of temporary teeth. Temporary teeth are smaller than permanent ones, the teeth crowns are thin, and the divergence of the roots is greater. Don't push forceps blades to a greater depth, don't use elevators and do curettage, because of the danger of damage to teeth germs. However, all manipulations of teeth extraction in children require special care.

*Tooth extraction in children, as in adults, consists of several steps:*

1. Separation of the gingival attachment from the tooth, or syndesmotomy;
2. Imposition and pushing of forceps;
3. Fixation of the blades;
4. Luxation (to oral and buccal side, only for molars and 1-st upper premolars) or rotation (only for incisors and canines) of the tooth;
5. Extraction of the tooth from its socket, or traction.

Forceps for teeth removal are two levers connected with each other. They consist of blades, a joint (neck) and handles (fig. 11).

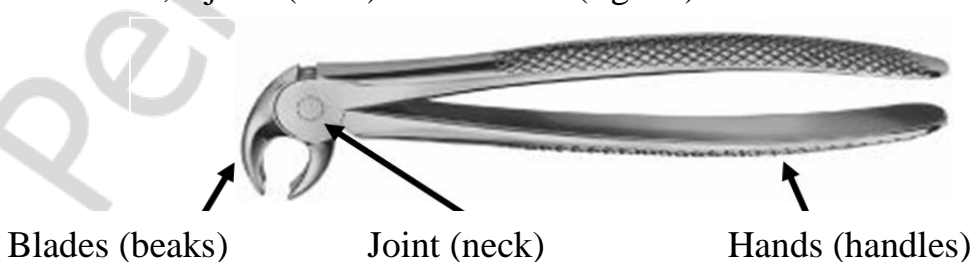


Fig. 11. Forceps for teeth extraction

There are special forceps for removing teeth in the maxilla and the mandible. Straight and curved forceps (S-shaped and bayonet-shaped) are used to remove *upper teeth* (fig. 12). To remove upper incisors and canines use straight forceps. Their blades can be wide, medium and narrow. Bayonets are used to extract the roots of these teeth. To remove molars in the upper jaw, S-shaped forceps with a pin can be used. The forceps for the right teeth have a pin on the left beak, while forceps for the left teeth have it on the right beak. Thus, when forceps are fixed on the tooth, the pin is in the *bifurcation* of the roots.

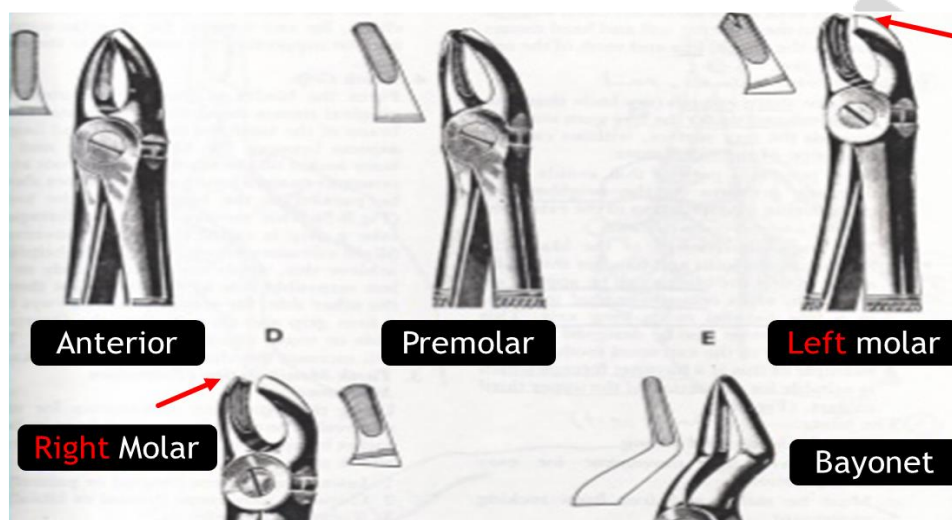

Fig. 12. Upper forceps

Lower teeth require beak-shaped forceps (fig. 13). They can be crown and root. Beak crown forceps have non-meeting blades to avoid tooth crown fracture during extraction. The last one is used to extract incisors and canines. Beak crown forceps to remove molars have a pin on each blade for fixation on the root bifurcation.

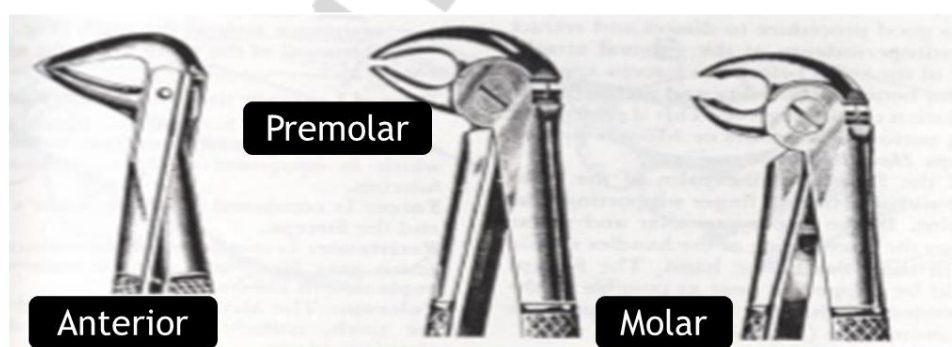
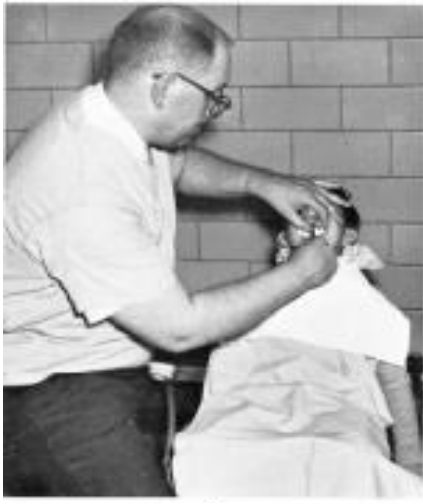

Fig. 13. Forceps for lower teeth

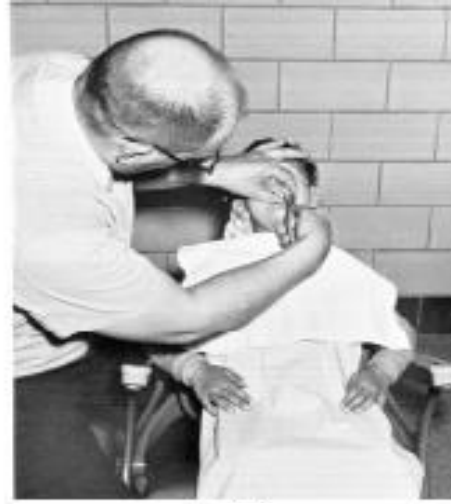To remove temporary teeth, it is better to use children's set of forceps, which is smaller in size.

Also, it is necessary to have tweezers, a spatula for tongue or a dental mirror for tooth extraction.

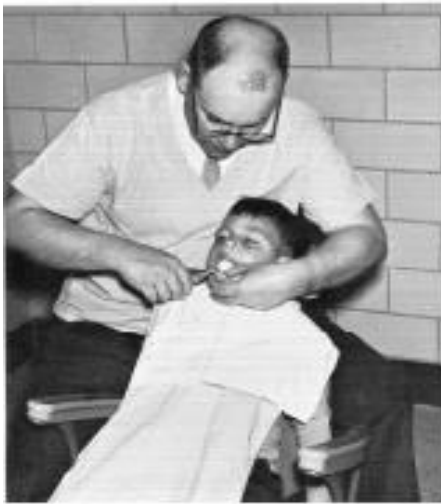The position of the dentist and the location of his hands during tooth extraction are shown in figure 14.



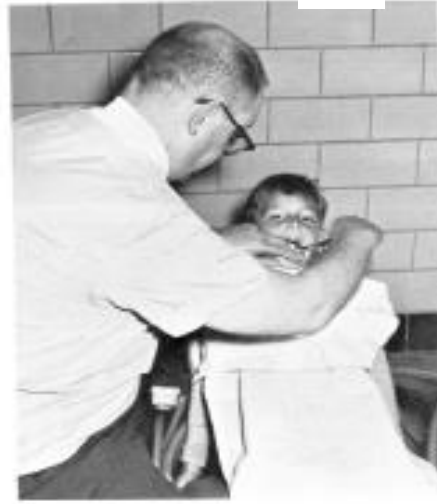*a*



*b*



*c*



*d*

*Fig. 14.* Dentist's position during tooth extraction:  
*a* — upper frontal teeth, *b* — upper lateral, *c* — lower right, *d* — lower left teeth

**Complications** after tooth extraction are the following:

1. Accidental dislocations and fractures of adjacent teeth.
2. Damage of soft tissues of the alveolar process and adjacent areas of the oral cavity.
3. Fracture of small areas of bone tissue; fracture of the alveolar process and even fracture of the jaw caused by the high pressure put on the jaw during extraction.
4. Incomplete extraction, in which a tooth root remains in the jaw.
5. Nerve injury —associated with extractions of lower teeth — can occur on the removal of any tooth if the nerve is near the extraction site. Typically caused by damage from a surgical drill, nerve injuries are rare and usually temporary.
6. Tooth pushing through the soft tissues.
7. Children can aspirate their teeth and roots due to violation of the tooth extraction technique, restless behavior, and lack of alertness of the doctor. In case



of this complication the child needs sending to bronchoscopy urgently, or in case of the signs of asphyxia, immediate tracheotomy should be performed.

8. Damage of the permanent tooth germs.
9. Dry socket.
10. Maxillary sinus perforation.
11. Bleeding from the socket of the removed tooth.

Removable dentures are used to replace the defect in the anterior part of the dental arches and removable and non-removable dentures (crowns with spacers) in the lateral areas in the period of temporary and mixed bite in children. Indications for prosthetics are confirmed by X-ray examination of the alveolar process, i. e. orthopantomography. The irritating effect of the prosthesis stimulates the growth of the jaw and the eruption of permanent teeth. During the period of permanent bite, removable dentures are also used, but for patients over 14 (end of growth of the bones of the facial skeleton) fixed dentures are to be used.

### TEST FOR SELF-CONTROL

#### 1. Extraction of Tooth 74 in children presupposes the use of:

- |                                  |                        |
|----------------------------------|------------------------|
| a) straight forceps;             | d) beak crown forceps. |
| b) S-shaped left molar forceps;  | e) bayonet forceps.    |
| c) S-shaped right molar forceps; |                        |

#### 2. Extraction of the roots of Tooth 16 in children presupposes the use of:

- |                                  |                     |
|----------------------------------|---------------------|
| a) straight forceps;             | d) beak forceps;    |
| b) S-shaped left molar forceps;  | e) bayonet forceps. |
| c) S-shaped right molar forceps; |                     |

#### 3. Extraction of Tooth 26 with preserved crown in children presupposes the use of:

- |                                  |                     |
|----------------------------------|---------------------|
| a) straight forceps;             | d) beak forceps;    |
| b) S-shaped left molar forceps;  | e) bayonet forceps. |
| c) S-shaped right molar forceps; |                     |

#### 4. Extraction of the roots of tooth 36 in children presupposes the use of:

- |                                     |                        |
|-------------------------------------|------------------------|
| a) beak forceps with meeting beaks; | d) beak crown forceps; |
| b) S-shaped left molar forceps;     | e) bayonet forceps     |
| c) S-shaped right molar forceps;    |                        |

#### 5. Complications of tooth extraction are:

- |                                    |                     |
|------------------------------------|---------------------|
| a) bleeding from the tooth socket; | d) periostitis;     |
| b) anaphylactic shock;             | e) tooth contusion. |
| c) jaw fracture;                   |                     |

#### 6. Select parts of dental extraction forceps:

- |            |           |             |
|------------|-----------|-------------|
| a) blades; | c) joint; | e) handles. |
| b) shank   | d) loop;  |             |

**Keys: 1 – d; 2 – e; 3 – b; 4 – a; 5 – a, c, e; 6 – a, c, e.**

## **FEATURES OF INFLAMMATORY DISEASES OF THE MAXILLOFACIAL REGION IN CHILDREN. PATHWAYS OF ODONTOGENIC INFECTION. ODONTOGENIC PERIOSTITIS. ETIOLOGY, CLINICAL PICTURE, DIAGNOSIS, TREATMENT, PREVENTION**

There are some *anatomical features* of the structure of tissues of the maxillofacial region and physiological features of a child's organism that affect the clinical course of inflammatory reactions in children. Teeth constantly develop in children. There are periods of intra-maxillary development, eruption, tooth growth, formation and resorption of roots. Dentinal tubules of milk teeth are wider and shorter. Periodontal fissure is not often formed. Spongy substance predominates over the compact one in the children's jaws. Bone mineralization is less pronounced than in adults. The periosteum is thick, powerful and well vascularized, but loosely connected with the bone. High hydrophilicity of soft tissues is typical. Subcutaneous and intermuscular fat are more friable. Soft tissues are more hydrophilic, which leads to extensive swelling.

The development of immunological system finishes by the age of seven. Children have a high intensity of blood circulation in tissues, immaturity of parenchymal organs, and high permeability of blood-brain barrier.

Imperfection of the tissue barrier causes a rapid transition of one nosological form of disease into another. Common reactions often outstrip the development of local inflammatory process. Frequent lesions of lymph nodes, and high degree of intoxication of the body are reported.

However, development of *primary chronic forms* of inflammation (osteomyelitis, sialadenitis, lymphadenitis) is possible in children.

**Odontogenic inflammatory process** can spread directly by *hematogenous* (into the blood with development of sepsis) way, and *lymphogenous* (with possible development of lymphadenitis and adenophlegmon) way and *along the length* (with the development of periostitis, osteomyelitis, as well as abscesses and phlegmon of adjacent soft tissues).

The inflammatory process of the *upper jaw teeth* can be complicated by sinusitis, phlegmon of the orbit, thrombosis of the cavernous sinus, meningitis, as well as abscesses and phlegmons of infraorbital, buccal, temporal, infratemporal, parotid and other areas.

The odontogenic inflammatory process from *lower teeth* can spread to the neck resulting in the formation of neck phlegmon and mediastenitis, as well as into the surrounding soft tissues with the development of submandibular, submental, parotid and other phlegmons.

**Odontogenic periostitis** is the inflammation of the periosteum of the jaw bones.

*Classification* of odontogenic periostitis.

- a) acute:
  - serous;
  - purulent.

- b) Chronic:  
– simple;  
– hyperplastic.

**Acute serous odontogenic periostitis** is rarely diagnosed in children due to its fast development into the purulent form.

Parents and their children often *complain of* tooth pain during chewing and painful edematous swelling of the cheek and the mucosa of alveolar process.

*Clinical picture* is characterized by asymmetry of the face due to edema of the soft tissues (fig. 15). «Causal» tooth is injured by chronic apical periodontitis and has painful percussion. Mucogingival fold is hyperemic, swelled on one side (often on the vestibular) and painful on palpation. There is no fluctuation. No specific X-ray pictures.

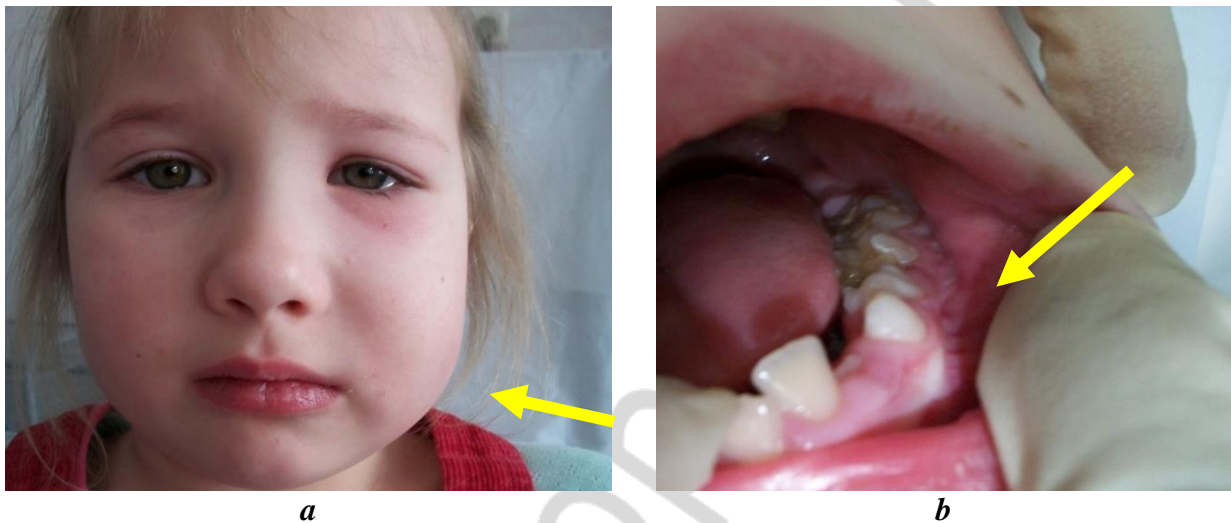

Fig. 15. Acute serous odontogenic periostitis on the left:  
*a* — face view, *b* — view in the oral cavity

*Treatment.* The dentist should make a decision about possibility of conservative treatment or extraction of «causal» tooth, depending on its functional status, stage of the root resorption of primary tooth, the child's age and behavior. Antimicrobial and antihistaminic drugs must be prescribed. Periostotomy is carried out if there is no relief after tooth extraction to decrease the tissue pressure in the inflamed area.

**Acute purulent odontogenic periostitis** develops as the next stage of inflammatory process. This form is mainly observed in 6–8-year old children with mixed dentition.

Patients usually complain of facial deformation of the lower or upper jaw area, difficulties during chewing on the injured side. Weakness, headache, body temperature increases to 38 °C, loss of appetite is present.

*Clinical picture* is characterized by facial asymmetry due to soft tissue swelling. Regional lymphadenitis on the injured side can be observed.

Oral mucogingival fold on vestibular side is reddened and swelled near the «causal» tooth and 1–2 adjacent teeth. There is fluctuation. «Causal» tooth is destroyed or filled, mobile and painful on percussion. There is no specific X-ray picture, except apical changes of «causal» tooth.

*Differential diagnosis* should be made versus chronic periodontitis, osteomyelitis, and purulent radicular and follicular cysts of the jaw, and malignant tumors.

*Treatment* of acute periostitis is complex and involves urgent surgical intervention and drug therapy. Local anesthesia — infiltration anesthesia or nerve block — is often used. General anesthesia is also used, especially in young children.

Primary teeth and permanent roots should be extracted. When the permanent tooth is involved into the inflammatory process the drainage of pus through the root canal should be performed.

Periostotomy (the incision should be made along the mucogingival fold as deep as bone contact) and drainage should be provided. After the surgical intervention the dentist prescribes antimicrobial, antihistaminic drugs and physiotherapeutic procedures. On the next day a mouth bath with antiseptics and dymexid packs are administered as well.

**Chronic odontogenic periostitis** is more common in older children. However, this form is rarely observed in pediatric dentistry. Odontogenic periostitis is classified into *simple* and *hyperplastic*. It is a primary chronic disease. Chronic odontogenic infection is the cause of odontogenic periostitis. It is a slow, localized inflammation of the jaw periosteum.

The main complaints include unpainful thickening of the jaw that are connected with periodic toothache. The lower jaw is most often affected.

The dentist notes changed facial configuration due to the enlargement of the certain area of the jaw with the normal skin over it. The alveolar process is thickened, dense and painless near the «causal» tooth. The oral mucosa over the growth is cyanotic or without changes. The causal tooth has a deep cavity or a big restoration and is painful on percussion.

The general condition is not impaired. Submandibular lymph nodes are enlarged, dense and painless on one side.

On the X-ray symptom of «onion» — excessive bone formation in the form of bone strips under the periosteum that is disposed parallel to the jaw edge — is present (fig. 16).

*Treatment.* Primary and permanent multirouted causative teeth must be extracted. The dentist prescribes antibacterial (having tropism to bone tissue) and antihistaminic drugs for 10–14 days. Physiotherapeutic

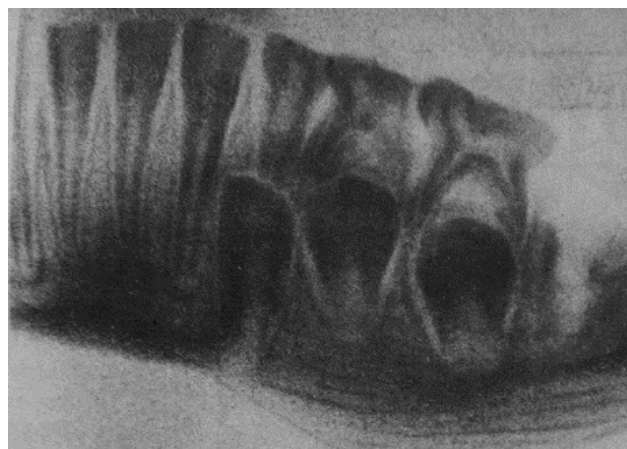


Fig. 16. X-ray picture of chronic odontogenic periostitis of the mandible (symptom of «onion»)

procedures are an important component of treatment (electrophoresis of potassium iodide and lidase, laser, ultrasound).

In the absence of positive dynamics, surgical removal of excessively formed bone tissue («onion») is performed, which usually produces a positive result.

### TEST QUESTIONS FOR SELF-CONTROL

**1. Odontogenic periostitis is:**

- a) inflammation of the periosteum of the jaw bones;
- b) purulent-necrotic inflammation of the jaw bone.

**2. Inflammatory process in the teeth of the upper jaw can be accompanied by:**

- a) meningitis;
- b) sinusitis;
- c) orbit phlegmon;
- d) abscess of the buccal region;
- e) parotid phlegmon;
- f) mediastinitis.

**3. Inflammatory process in the teeth of the lower jaw can be accompanied by:**

- a) phlegmon of neck;
- b) submandibular phlegmon;
- c) submental phlegmon;
- d) thrombosis of the cavernous sinus;
- e) temporal abscess.

**4. Local clinical features of acute odontogenic periostitis are:**

- a) mobility of a group of teeth;
- b) pain on percussing on the «causal» tooth;
- c) Vincent's symptom;
- d) edema and hyperaemia of mucous membrane of the mucogingival fold;
- e) pain on percussing on a group of teeth.

**5. Chronic odontogenic periostitis is characterized by:**

- a) symptom fluctuation;
- b) «onion» symptom in the radiograph;
- c) mobility and acute pain on percussion of the «causal» tooth;
- d) edema of the mucous membrane of the mucogingival fold;
- e) thickening of the alveolar bone.

**6. Acute odontogenic serous periostitis is characterized by:**

- a) edema of the mucous membrane of the mucogingival fold;
- b) asymmetry of the face;
- c) fluctuation;
- d) pain in the «causal» tooth;
- e) skin hyperaemia.

**7. Treatment of chronic odontogenic periostitis in children includes:**

- a) drug treatment;
- b) removal of the «causal» milk tooth;
- c) periostotomy;
- d) treatment of the «causative» milk tooth;
- e) physiotherapy.

**8. Odontogenic periostitis is often complicated by:**

- a) phlegmon of maxillofacial area;
- b) abscesses of maxillofacial area;
- c) furuncles of maxillofacial region.

**Keys:** 1 – a; 2 – a, b, c, d, e; 3 – a, b, c; 4 – b, d; 5 – b, e; 6 – a, b, d; 7 – a, b, e; 8 – a, b.

## ACUTE OSTEOMYELITIS OF THE JAWS IN CHILDREN: ODONTOGENIC, HEMATOGENIC, TRAUMATIC. ETIOLOGY, CLINICAL PICTURE, DIAGNOSIS AND TREATMENT

**Osteomyelitis** is an infectious purulent and necrotic process that develops in all bone structures and surrounding soft tissues against a background of preliminary sensitization of the body.

Only microbial contamination is not enough for the development of osteomyelitis. There must be factors increasing the virulence of microorganisms or weakening the child's body protective defenses. Imperfection of protective defensive mechanisms of the body and local tissue immunity plays the main role of the disease development in young children. Osteomyelitis of the jaw is often preceded by hypothermia, acute infectious diseases, treatment of teeth with complicated caries, etc.

The causative agents of osteomyelitis of the jaws are staphylococci, streptococci, gram-negative and gram-positive rods, enterococci, diplococci, anaerobic microflora, and etc., both in monoculture and in associations (most often). *All bone components* are involved in the inflammatory process in osteomyelitis: bone marrow, spongy and cortical bone substance, periosteum, etc.

Osteomyelitis of the jaws are *classified* by pathways of infection into the bone as *odontogenic, hematogenic and traumatic*. *Odontogenic osteomyelitis* is the most wide spread disease in children (over 90 %), less often it is traumatic and very rarely hematogenous.

### ACUTE ODONTOGENIC OSTEOMYELITIS

**Odontogenic osteomyelitis** is an infectious purulent and necrotic inflammatory process in jaws, wherein the tooth with chronic apical periodontitis is most often the source of infection.

The reason of **osteomyelitis** is chewing teeth, especially *temporary molars* and the *first permanent molar*.

Odontogenic osteomyelitis occurs most often in *7–12 year-old* children that associated with high intensity of dental caries in this age.

The osteomyelitis is most often observed on the *lower jaw* and rarely — on the upper one.

*Clinical features* of acute odontogenic osteomyelitis depend on the age of the child - the smaller the age, the more severe the disease is. The disease begins acutely and is characterized by *general* and *local* symptoms. An exacerbation of chronic apical periodontitis precedes the disease.

*General manifestations* of acute odontogenic osteomyelitis are: body temperature increase to 38–39 °C, headache, weakness, anxiety, sleep disturbance, loss of appetite, pallor of the skin and others. *Changes in the peripheral blood* are always present. Patients have leukocytosis with left shift and increased sed rate. *C-reactive protein* appears in the blood serum. There are traces of protein, leukocytes, erythrocytes in the urine.



*Local manifestations* of the disease. Children complain of pain in the tooth, in several teeth or even in the jaw. Pain can irradiate into the ear, temple or the other jaw. Vincent's symptom can present in case of osteomyelitis of the mandible — the violation of sensitivity of the half lower lip and chin.

There is *facial asymmetry* due to soft tissue swelling. Sharply painful inflammatory *infiltrate* of the soft tissues surrounding the jaw is determined on palpation. The skin above it can be *hyperemic*. Regional lymph nodes are *enlarged and painful* (fig. 17, a).

In the oral cavity «causal» tooth has a deep carious cavity, is mobile and sharply painful on percussion. Adjacent 2–3 teeth are painful on percussion and mobile.

Mucosa is swelling, hyperemic, infiltrated on both sides of the alveolar process. The mucogingival fold is smoothed. Palpation is painful and the symptom of fluctuation is detected, which indicates the formation of subperiosteal abscesses. These symptoms are often described as a muff-like thickening of the jaw (fig. 17, b).

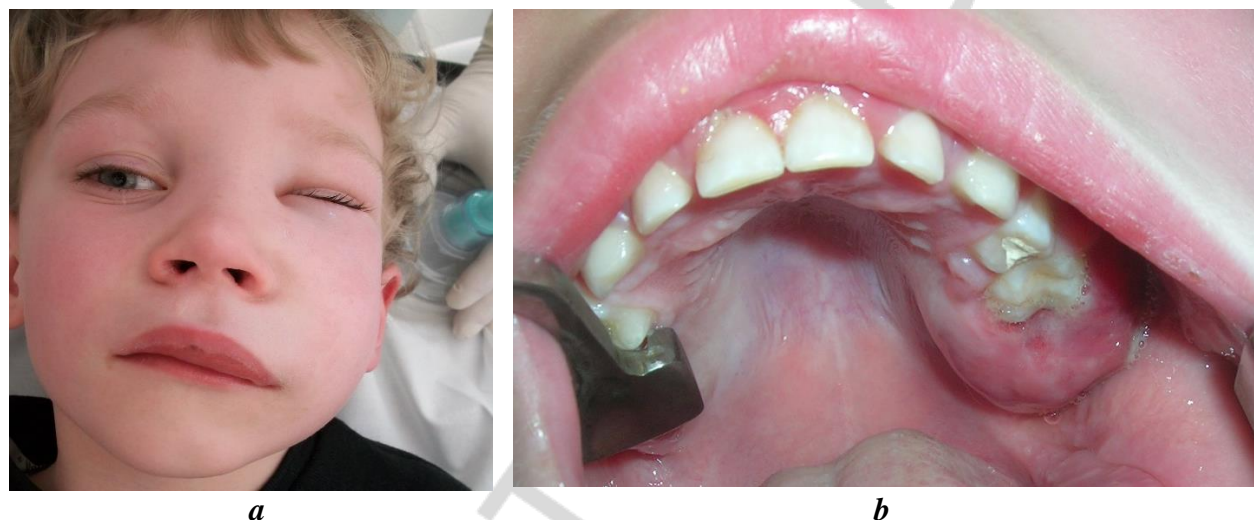


Fig. 17. Acute odontogenic osteomyelitis of the upper jaw on the left:  
a — appearance; b — oral view

Radiographical pathological changes in acute odontogenic osteomyelitis of the jaws are not determined. However, there are always x-ray changes in the root apex area of the «causative» tooth with chronic apical periodontitis.

Acute osteomyelitis of the *upper jaw* in children runs *easier* than osteomyelitis of the lower one. This is due to the anatomical features of these bones.

Acute odontogenic osteomyelitis of the lower jaw in children is more *severe* and more often complicated by submandibular phlegmon, often leads to the chronic stage of the disease.

**Treatment** of these children should be done in a hospital at the department of maxillofacial surgery. Surgery is performed under general anesthesia.

First of all, It is necessary to determine the «fate» of the tooth which became the cause of the disease. All temporary and multirouted permanent «causal» teeth must be removed. Single rooted «causative» permanent teeth are preserved. They

must be trepanized and drained through the root canal on the day of patient's treatment. Subsequently, these teeth should be sealed after relief of acute inflammatory process up to healing of postoperative wounds and under the «cover» of antibacterial therapy.

Periostotomy is immediately performed after removal (or trepanation) of the «causative» tooth. It is carried out from the vestibular and lingual (palatal) sides of the alveolar process. The incisions must be wide enough for a good outflow of pus. If a child has abscesses or phlegmons of soft tissue, as a complication of acute osteomyelitis, they are also opened during surgery. Wounds are washed with antiseptic solutions and drained. An aseptic bandage with hypertonic solution is applied to external operation wounds.

The doctor prescribes antibacterial, detoxifying, hyposensitizing, symptomatic therapy, as well as physiotherapy. Passive immunization can be performed in severe cases. Antibiotic therapy is prescribed in accordance with sensitivity of child's microflora to antibiotics.

**Complications** of acute odontogenic osteomyelitis in children are phlegmons, maxillary sinusitis, temporomandibular joint arthritis, meningitis, mediastinitis, sepsis, etc., and it can lead to the chronic stage of the disease as well. Phlegmons and chronic odontogenic osteomyelitis are most common complications in children.

## ACUTE HEMATOGENOUS OSTEOMYELITIS OF THE JAWS

**Hematogenous osteomyelitis of the jaw** is an infectious, purulent, inflammatory process in bones that occurs as a result of a hematogenous drift of infection from distant primary purulent foci into the bone marrow. In fact, it is the manifestation of one of the forms of septicopyemia.

Etiological factors are omphalitis (inflammation of the navel); pustular skin lesions; mastitis in the mother; microtraumas of the oral mucosa of the child. Hematogenous osteomyelitis of the jaw can also develop with otitis, stomatitis, osteomyelitis of other bones and various combinations of these factors.

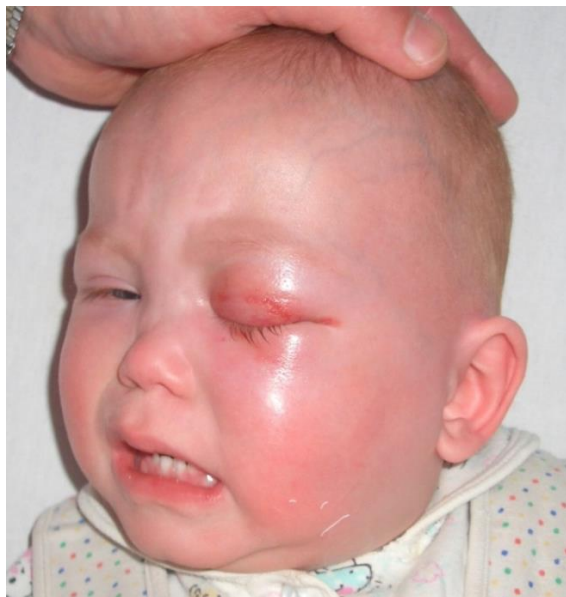Hematogenous osteomyelitis of the jaw develops mainly in newborns (up to 1 month), less often in infants (up to 1 year). The disease often occurs in weakened and premature babies.

Hematogenous osteomyelitis in the maxillofacial region has a favorite localization. The upper jaw is most often affected. It can be explained by multiple zones of maxilla growth, which come in contact with other bones (zygoma, nasal, frontal, etc.). These zones have high intensity of blood circulation. The condylar process is affected on the lower jaw, as it is the growth zone of its.

The onset of hematogenous osteomyelitis of the jaw is acute. Body temperature increases to 39–40 °C, the child can't sleep, is restless and refuses to eat. Vomiting, convulsions, even loss of consciousness can be observed. There are signs of severe purulent-inflammatory process in peripheral blood.

The *local clinical picture* depends on the *localization* of inflammatory process.

***Hematogenous osteomyelitis of the upper jaw.*** Swelling of the soft tissues of buccal and infraorbital areas is determined during the external examination. The eye is closed, chemosis of the conjunctiva is possible. Exophthalmos can occur. Nasal breathing through one nostril is difficult or absent. Purulent discharge from one nostril can be present (fig. 18).



*Fig. 18.* External view of the child with acute hematogenous osteomyelitis of the upper jaw on the left

In the oral cavity hyperaemia and edema of transitional fold and palatal mucosa. Fluctuation is determined by palpation. Subperiosteal oral abscesses often open by themselves with pus exudation.

***Hematogenous osteomyelitis of the lower jaw*** has favorite localization on condylar process. The local clinical picture is expressed very mild. In 3–4 days swelling and inflammatory infiltration of parotid-masticatory area appears, and this process is usually taken for lymphadenitis, otitis or mumps. The mouth opening is limited. Purulent exudate often spreads to external auditory canal and accompanied by pus flow from it.

***Treatment.*** Patients with hematogenous osteomyelitis are hospitalized immediately in the intensive care department (sepsis) and treated by the maxillofacial surgeon.

Timely and radical surgical intervention quickly leads to an improvement of general condition of the child and prevents passing into the chronic stage of the disease. Subperiosteal abscesses of the upper jaw are dissected on a hard palate and along a transitional fold, washed and drained. Surgical treatment can be also performed with external access according to indications. Abscesses of condylar process of the mandible are often dissected externally (incision borders angle of the lower jaw).

Antibacterial therapy (intravenously and intramuscularly) is conducted with broad-spectrum antibiotics at first, and then, in accordance with sensitivity of microflora to antibiotics.

Normalization of the child's homeostasis is carried out by transfusion of blood substitutes, glucose, normal saline, etc. Passive immunization is indicated in the acute stage.

Nowadays, treatment of acute hematogenous osteomyelitis often leads to recovery. Inflammatory process rarely passes into the chronic stage.

**Frequent complications** of hematogenous osteomyelitis of facial bones are pneumonia, myocarditis, abscess of nasal septum, atrophy of optic nerve, bone growth retardation, ankyloses of TMJ, death of teeth germs, malformations of the teeth.

### ACUTE TRAUMATIC OSTEOMYELITIS

**Traumatic osteomyelitis is a purulent-necrotic process in the area of bone injury characterised by necrosis of bone tissue, formation of sequestrs and bone regeneration.**

Traumatic osteomyelitis occurs in 10-12% of cases as a complication of fractures of facial bones. It is a complication of a traumatic fracture of the mandible in most cases. Traumatic osteomyelitis occurs in 7-8% cases of all osteomyelitis of the jaws (odontogenic, hematogenous and traumatic). The inflammatory process spreads along the edges of fracture.

A direct relationship between the frequency of traumatic osteomyelitis of the jaw and time of hospitalization of patient has been established - the *later* hospitalization is done, the *more often* traumatic osteomyelitis develops.

**Three main factors in the development of the pathological process are:**

– belated, unsatisfactory and insufficient prolonged immobilization of jaw fragments;

– presence of teeth or their roots in the jaw fracture;

– infection contamination of the jaw fracture by oral microorganisms. Acute traumatic osteomyelitis proceeds *more easily* than odontogenic and hematogenous ones. Acute inflammation develops in the area of the fracture within the first 3–5 days. There are inflammatory infiltrates, subperiosteal abscesses or diffuse phlegmon of surrounding soft tissues. The body temperature rises to 38–39 °C. A purulent discharge appears from the fracture line. The X-ray reveals osteoporosis in the area of the fracture line.

**Treatment** of traumatic osteomyelitis of the jaw is carried out immediately after the appearance of first signs of suppuration in the area of the jaw fracture. The abscesses are dissected by the intraoral or external incision. The tooth in the fracture line should be removed when the inflammatory process develops. Dentist prescribes antibacterial drugs (having tropism to bone tissue) and symptomatic therapy. Physiotherapeutic procedures are an important component of treatment (laser, UHF-therapy).

**Prevention of traumatic osteomyelitis:**

1) teeth extraction from the fracture line (teeth with complicated caries, root fractures, dislocated teeth, temporary and permanent teeth, if they interfere with the reposition of fragments;

- 2) early, reliable and sufficiently prolonged immobilization of the jaw fragments;
- 3) thorough oral care;
- 4) antibacterial therapy.

### TEST FOR SELF-CONTROL

**1. Odontogenic osteomyelitis is:**

- a) a inflammation of the periosteum of the jaw bones;
- b) a purulent-necrotic inflammation of the jaw bone.

**2. The odontogenic osteomyelitis is most often observed on the:**

- a) maxilla;
- b) zygoma;
- c) mandible;
- d) temporal;
- e) frontal bone.

**3. Hematogenous osteomyelitis of the jaws occur most often at the age of:**

- a) under 3 years;
- b) 4–5 years;
- c) 6–7 years;
- d) 8–11 years;
- e) 12–14 years.

**4. What is a favorite localization of hematogenous osteomyelitis in the maxillofacial region?**

- a) maxilla;
- b) zygoma;
- c) mandible;
- d) temporal;
- e) frontal bone.

**5. Clinical and radiological signs of acute odontogenic osteomyelitis of the jaw are:**

- a) C-reactive protein in the blood serum;
- b) pain on percussion and mobility of a group of teeth;
- c) a symptom of Vincent;
- d) a symptom of Dupuytren;
- e) foci of bone destruction on the X-ray.

**6. What «causative» teeth should be removed in acute odontogenic osteomyelitis in children:**

- a) all temporary and all permanent teeth;
- b) all temporary and multi-rooted permanent teeth;
- c) multi-rooted temporary and permanent teeth;
- d) single-rooted temporary and multi-rooted permanent teeth;
- e) multi-rooted temporary and single-rooted permanent teeth

**7. Acute odontogenic osteomyelitis of the jaws occurs most often at the age of:**

- a) 1–3 years;
- b) 4–5 years;
- c) 6–7 years;
- d) 8–11 years;
- e) 12–14 years.

**8. Acute odontogenic osteomyelitis complications in children are:**

- a) phlegmons;
- b) chronic periostitis;
- c) maxillary sinusitis;
- d) chronic apical periodontitis;
- e) chronic osteomyelitis.

**9. Prevention of traumatic osteomyelitis includes:**

- a) prolonged immobilization of the jaw fragments;

- b) periostotomy;
- c) teeth extraction from the fracture line;
- d) treatment of «causative» milk tooth;
- e) antibacterial therapy;

**Keys:** 1 – b; 2 – c; 3 – a; 4 – a; 5 – a, b, c; 6 – b; 7 – c, d; 8 – a, c, e; 9 – a, c, e.

## **CHRONIC OSTEOMYELITIS OF JAWS IN CHILDREN. ETIOLOGY, CLINICAL PICTURE, DIAGNOSIS, TREATMENT, PREVENTION**

**Chronic osteomyelitis** of the jaw occurs more often in children with weakened immunity against the background of prolonged sensitization of the body in presence of chronic foci of infection: destructive, productive and productive – destructive.

*Predisposing factors of the disease are:*

- late seeking medical advice;
- late diagnosis of the disease;
- prolonged conservative treatment of «causative» teeth;
- irrational prescription of antibiotics in the acute stage of the disease;
- non-radical surgical intervention.

Inflammatory process of the bone transits to a chronic stage *within 2–3 weeks* from the onset of the disease. Sometimes chronic osteomyelitis of the jaw can develop without acute stage preceding — *primary-chronically*.

Chronic inflammation of the bone is characterized by destructive processes in the bone substance — the formation of necrosis areas. But reparative changes that restore the bone tissue are also present. Reparation occurs due to intrasosseous bone formation (endosteal way) and due to bone production by periosteum (aperiostal way).

### **CHRONIC ODONTOGENIC OSTEOMYELITIS OF JAWS**

According to predominance of processes of destruction or proliferation of the bone tissue there are *3 clinical and X-ray forms* of chronic odontogenic osteomyelitis of jaws in children: destructive, productive and productive-destructive.

**Destructive form** of the disease occurs more often in children *under 7 years* old. It is characterized by predominance of bone tissue *destruction processes*. The main source of infection in chronic odontogenic osteomyelitis of the jaw is temporary and permanent molars.

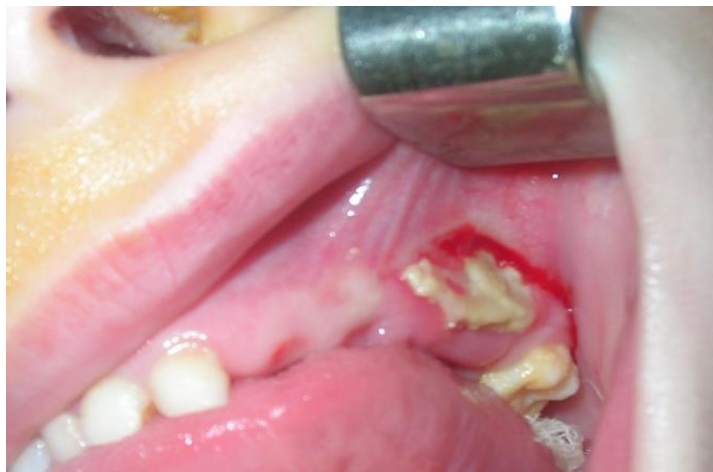*General condition* of children with chronic odontogenic destructive osteomyelitis of the jaw in the stage of remission is satisfactory. Children can complain of moderate pain in the jaw area, subfebrile fever in the evening, teeth mobility, etc.

*Local manifestations* of the disease. Asymmetry of the face is revealed during external examination, jaw thickening occurs due to infiltration of soft tissues of the affected jaw. Infiltrate is painful or slightly painful on palpation. There are



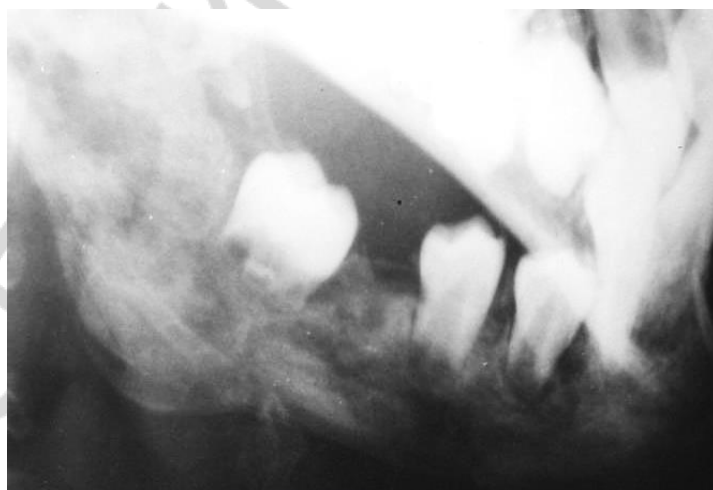
fistulas with purulent discharge or granulations near surgical wounds that occurs after dissecting of abscesses and phlegmons. Regional lymph nodes are enlarged and painful.

In the oral cavity alveolar sockets of removed «causative» and other teeth have not healed. They contain purulent discharge or granulations. Dentists can detect large or small sequestrs (fig. 19), dead germs of permanent teeth when probing alveolar sockets. Teeth are mobile, painful on percussion in focus of inflammation. After periostomy wounds also did not heal completely. There are fistulas with purulent discharge and granulations around them.



*Fig. 19.* Sequestration in chronic odontogenic osteomyelitis

*The X-ray* reveals extensive foci of destruction of the jaw bone with unclear borders. Large sequestrs of the bone tissue are present against the background of destruction. The death of germs of permanent teeth can be detected. It is characterized by destruction of cortical plate around the tooth germ. Aperiostal and endosteal development of the bone tissue is expressed (fig. 20).



*Fig. 20.* X-ray picture of chronic osteomyelitis of mandible (destructive form)

*In the stage of exacerbation* of chronic osteomyelitis, general and local signs of acute inflammation in the bone and surrounding soft tissues appear in addition to above mentioned clinical and radiologic symptoms.

*The treatment* of the children with chronic destructive osteomyelitis of the jaw is *complex*. Conservative (antibacterial, desensitizing, immunotherapy, vitamin therapy, physiotherapy) therapy as well as surgical treatment (opening abscesses, phlegmons) is carried out at the stage of exacerbation. Dentists should extract «causal» teeth, multi-rooted permanent teeth in sequesters and multi-rooted teeth in foci of distraction. Immunotherapy, vitamin therapy, restorative therapy and physiotherapy are indicated in the remission period. It is necessary to sanitize all available chronic foci of dental infection. Sequestrectomy should be performed no earlier than 2–3 months after the onset of the disease.

Sequestrectomy is indicated in case of:

- the presence of large, free-ranging sequesters without a tendency to self-resorption;
- dead germs of permanent teeth;
- threats of amyloidosis of internal organs.

**Productive form** of chronic odontogenic osteomyelitis is usually observed in older children. The disease is most often primary-chronic, i.e. without acute stage preceding. Chronic odontogenic productive osteomyelitis is a cyclic process. Patients note the relationship of pain in «causative» tooth with a thickening of jaw. It increases in volume with each exacerbation of the process. The *general condition* of the patient is not violated. There are no complaints of pain. Changes in the peripheral blood may not be present. Sometimes sed rate is increased. The main complaint is the thickening of the lower jaw.

*Extraoral examination.* There is facial asymmetry due to the thickening of body, angle, and sometimes branch of the lower jaw. Mandible is painless on palpation. The skin color above is not changed, freely assembled into the fold. Enlarged, weakly painful and mobile regional lymph nodes are palpated.

*Intraoral examination.* There is a «causal» tooth in the oral cavity. This is most often a lower molar. It is stable and painless during percussion. The alveolar process near «causative» tooth is thickened, dense and painless on palpation. Its mucosa is pale pink or cyanotic. There are no fistulas on the alveolar process.

*X-ray pattern.* The thickening of the body, angle and often branch of the lower jaw is determined in chronic productive odontogenic osteomyelitis. Excess endosteal and aperiostal bone formation prevails. «Marble pattern» is present due to alternation of foci of bone destruction and osteosclerosis foci. However, sequestrants are not formed (fig. 21).

*The treatment* of the children with hyperplastic osteomyelitis depends on the *duration* of the disease. At the beginning of the disease tooth extraction, active antibacterial anti-inflammatory and physiotherapy lead to recovery. Active immunization, courses of physiotherapy give good therapeutic effect. Surgical intervention is necessary in case of long-term hyperplastic osteomyelitis. It includes removal of the pathological and excessively formed bone, affected tooth germs, jaw modeling and etc.

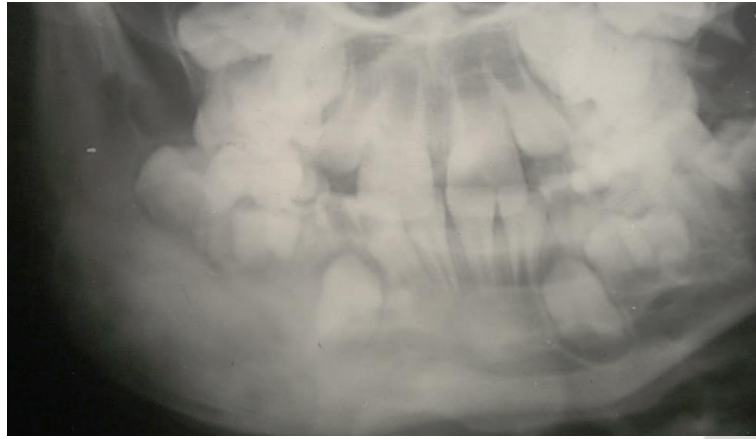

Fig. 21. X-ray picture of chronic osteomyelitis of mandible (productive form)

**Productive-destructive form** of chronic odontogenic osteomyelitis is characterized by the balance between the processes of destruction and the bone production. Children of any age can have this form of chronic osteomyelitis. Separated foci of destruction and small sequestrars are formed. Sequestrars dissolve or go out with pus through fistulas.

*Clinical features.* There are fistulas with purulent discharge, mobile teeth, deformations of the jaw, and others.

*X-ray pattern.* Alternation of foci of rarefaction with osteosclerosis areas of the bone reveals on the radiograph. Mottled, patchy pattern prevails in the bone. Death of germs of permanent teeth may occur (fig. 22).

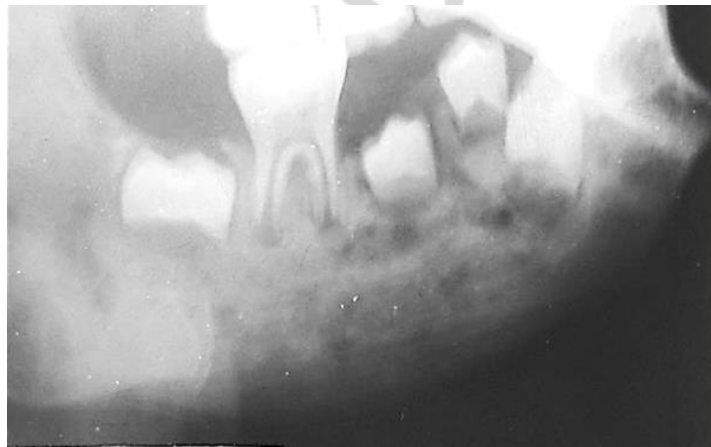


Fig. 22. X-ray picture of productive-destructive form of chronic osteomyelitis of the low jaw

### **CHRONIC HEMATOGENOUS OSTEOMYELITIS OF THE JAWS IN CHILDREN**

Chronic hematogenous osteomyelitis clinically and radiologically corresponds to the *destructive form* of chronic odontogenic osteomyelitis. It develops after acute hematogenous osteomyelitis of the jaw.

*The upper jaw and condylar process* of the mandible are most often affected. *Early sequestration* of the bone tissue, involvement in the process and death of teeth germs (8–9 days from the onset of the disease) are features of chronic hematogenous osteomyelitis in children.

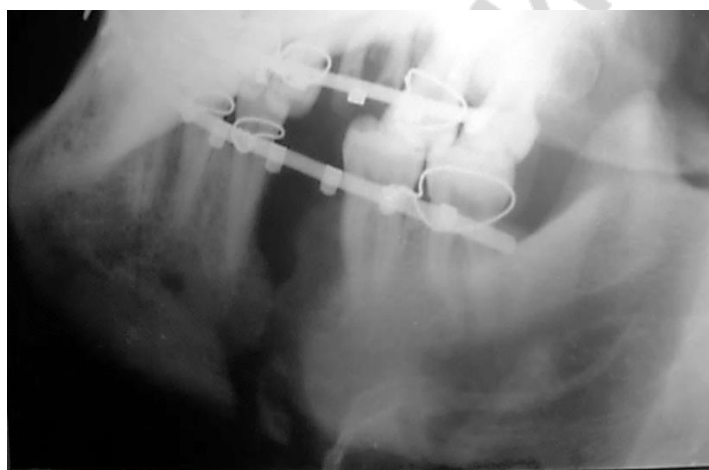
*Radiologic changes* are detected during the first week of the disease in children. Diffuse bone destruction prevails in newborns. Small sequestrants are formed more often. But large anatomical formations (the condylar process, distal part of the jaw branch, palatine plate, the upper jaw wall) are sometimes sequestered. Osteoporosis also develops in bones. Aperiosteal bone formation causes a deformation of the jaw in form of its thickening.

### **CHRONIC TRAUMATIC OSTEOMYELITIS OF JAWS IN CHILDREN**

Chronic traumatic osteomyelitis of the jaw develops *after* acute traumatic osteomyelitis or as a *primary-chronic* disease.

The greatest danger of development of chronic traumatic osteomyelitis in children occurs at 3–5 *day* after trauma. In addition to clinical signs of chronic osteomyelitis, the signs of a *jaw fracture* are present.

*X-ray* pattern. It reveals osteoporosis of the fracture line and its enlargement. Foci of bone resorption, osteosclerosis and an aperiosteal reaction (jaw thickening) are also noted (fig. 23). Sequestrants of the alveolar process, the mandible margin may begin to form after 2–3 week of the disease. The inflammatory process may involve permanent tooth germs.



*Fig. 23.* X-ray picture of chronic traumatic osteomyelitis of the mandible

### **COMPLICATIONS OF CHRONIC OSTEOMYELITIS IN CHILDREN**

Delayed complications of chronic osteomyelitis in children are the following: bone defects, pathological fractures, false joints, jaw deformity, adentia, malocclusion, temporomandibular joint disease (arthritis, arthrosis, ankylosis), delayed jaw growth (microgenia), scar deformations of soft tissues.

All these complications lead not only to pronounced cosmetic disorders, but also to gross functional changes in the child.

Prevention of these complications is high-quality medical care rendered in full. The children with chronic osteomyelitis should be on a long-term dispensary observation with the period of inspections at least twice a year together with an orthodontist. Such little patients should be examined at least twice a year by attending doctor and orthodontist.

## TEST FOR SELF-CONTROL

**1. Clinical and X-ray forms of chronic odontogenic osteomyelitis are the:**

- a) traumatic form;
- b) destructive form;
- c) hematogenous form;
- d) productive-destructive form;
- e) productive form.

**2. What does chronic destructive osteomyelitis of jaws in children characterize by?**

- a) age under 7 years;
- b) age over 10 years;
- c) the disease is the outcome of acute osteomyelitis of the jaw;
- d) the disease usually develops chronically;
- e) the upper jaw is most often affected.

**3. When does acute odontogenic osteomyelitis transit to chronic form in children?**

- a) a week after the onset of the disease;
- b) 2–3 weeks from the onset of the disease;
- c) a month from the onset of the disease;
- d) 2 months from the onset of the disease;
- e) 3 months after the onset of the disease.

**4. Clinical features of chronic odontogenic osteomyelitis destructive form in children are:**

- a) fistulas with purulent discharge or granulations;
- b) fluctuation;
- c) alveolar sockets with purulent discharge or granulations;
- d) chronic periostitis;
- e) vincent's symptom.

**5. Radiological signs of chronic odontogenic osteomyelitis in children are:**

- a) the alternation of foci of bone destruction and osteosclerosis foci («marble pattern»);
- b) the foci of jaw bone destruction with clear borders;
- c) the presence of sequestrs;
- d) the spiculated periosteal reaction;
- e) no radiological signs.

**6. Indications for «causal» teeth extraction at chronic odontogenic osteomyelitis are:**

- a) all temporary and all permanent teeth;
- b) multi-rooted permanent teeth in sequestrs;
- c) single-rooted temporary and single-rooted permanent teeth;
- d) all temporary and multi-rooted permanent teeth;
- e) multi-rooted temporary teeth and single-rooted permanent teeth;

**7. The treatment of the children with chronic destructive osteomyelitis includes:**

- a) immunotherapy;

- b) antibacterial therapy;
- c) sequestrectomy;
- d) treatment of «causative» milk tooth;
- e) physiotherapy.

**8. Sequestrectomy is indicated in case of:**

- a) the presence of large, free-ranging sequestrers;
- b) the presence of small sequestrers;
- c) threats of amyloidosis of internal organs;
- d) foci of destruction of the jaw bone;
- e) pathological jaw fracture.

**9. Delayed complications of chronic odontogenic osteomyelitis in children are:**

- a) false joints;
- b) chronic periostitis;
- c) maxillary sinusitis;
- d) temporomandibular joint arthrosis;
- e) malocclusion.

**Keys:** 1 – d, e; 2 – a, c; 3 – b; 4 – a, c; 5 – a, c; 6 – d; 7 – a, b, c, e; 8 – a, c; 9 – a, d, e.

**ODONTOGENIC MAXILLARY SINUSITIS IN CHILDREN.  
FURUNCLES OF FACES IN CHILDREN. ETIOLOGY, CLINICAL  
MANIFESTATIONS. DIAGNOSIS. TREATMENT. PREVENTION**

**ODONTOGENIC MAXILLARY SINUSITIS**

**Odontogenic maxillary sinusitis** is the inflammation of the maxillary sinus as a result of infection from the teeth of the upper jaw. It is a *less common* disease than nasosinusitis.

Children suffer from odontogenic sinusitis *much rarer* than adults. This is due to anatomical peculiarities of the upper jaw and maxillary sinus in children. The maxillary sinus is smaller and less pneumatized in young and middle age children. The upper milk teeth are separated from the maxillary sinus by a thick layer of the bone with germs of permanent teeth. These anatomical features significantly inhibit the contamination of the maxillary sinus directly from the periapical odontogenic foci of infection.

Odontogenic sinusitis often occurs in the *constant bite in children over 12 years old*. «Causative» teeth most often are 16, 15, 25, 26 teeth. Inflammation of the maxillary sinus is caused either by the direct spread of infection from the odontogenic focus to sinus or through the blood or lymphatic vessels. Odontogenic sinusitis can occur at endodontic treatment of these teeth: by pushing necrotic tissues, endodontic instruments or filling material into the sinus. Perforation of bottom of the maxillary sinus or pushing the roots at teeth extraction as well as odontogenic osteomyelitis of the upper jaw or exacerbation of maxillary odontogenic cyst may be etiological factors too.

Decrease of local and general immunity also plays an important role in initiating odontogenic sinusitis. The causative agents of odontogenic sinusitis are vari-

ous strains of staphylococcus, streptococci, diplococci, gram-negative microflora, viruses, etc.

*Classification of odontogenic sinusitis are the following:*

- a) Acute;
- b) Chronic:
  - catarrhal;
  - purulent;
  - hyperplastic.

**Acute odontogenic sinusitis** in children most often occurs as a complication of acute osteomyelitis of the upper jaw.

*General symptoms* of a purulent-inflammatory disease will prevail in a child: violation of sleep, appetite, fever, leukocytosis with left shift, increased sed rate and etc.

*Local clinical signs* of acute osteomyelitis of the maxilla will be edema of soft tissues of cheek and infraorbital regions, skin hyperemia, painful palpation of inflammatory infiltrate and etc. «Causal» tooth on the affected side (with carious cavity) is in the oral cavity. This tooth and adjacent 2–3 teeth are painful on percussion and mobile. The mucous membrane of the alveolar process is hyperemic, infiltrated and painful on palpation. The fluctuation in the mucogingival fold is determined.

The child also experiences pain and pressure in affected sinus, has difficulty in nasal breathing and mucopurulent or purulent discharge from the half of the nose.

Anterior rhinoscopy, x-ray of the paranasal sinuses in a direct projection, orthopantomography and diagnostic puncture of the maxillary sinus are also diagnosis methods of odontogenic maxillary sinusitis.

*The X-ray of the paranasal sinuses* reveals uniform decrease in the transparency of the maxillary sinus (fig. 24). Chronic periapical foci of "causal" teeth are identified in orthopantomogram.

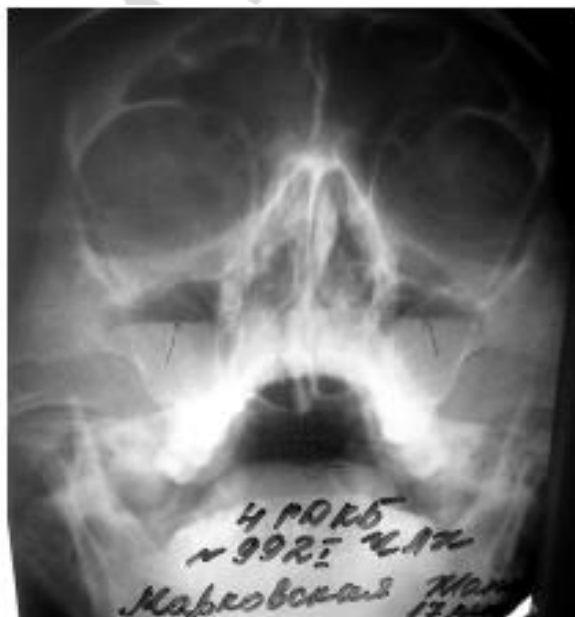

Fig. 24. X-ray picture of acute bilateral maxillary sinusitis



*The treatment* of the children with acute odontogenic sinusitis should be given in a hospital at the department of maxillofacial surgery. Surgery is performed under general anesthesia.

At first surgeon extract «causal» tooth which is the source of the infection, then dissects subperiosteal abscesses or phlegmons. Antibacterial, desensitizing, restorative and physiotherapy are prescribed. Irrigation of the nasal cavity with vasoconstrictors is also performed as well as the puncture of the maxillary sinus and washing it with antibiotics.

*Sinusotomy is indicated only in case of:*

- empyema of the maxillary sinus;
- involvement of orbit, other paranasal sinuses into the inflammatory process;
- threat of intracranial complications.

**Chronic odontogenic maxillary sinusitis** in children often is a *primary chronic* disease without preceding acute stage. It develops as a result of a prolonged infection of the sinus from chronic odontogenic foci.

*Older children* usually have chronic maxillary sinusitis. There are 3 clinical and radiological forms of the disease: *catarrhal, purulent and polypous*. Like any chronic disease chronic odontogenic sinusitis can occur at the stage of remission and exacerbation of the disease.

*General condition* disorder, such as a low-grade fever, loss of appetite, and increased fatigue can sometimes present.

*Local symptoms* of inflammation in a chronic process are less pronounced. Complaints of patients are uncertain, sometimes children have headaches, heaviness in the head, unilateral disruption of nasal breathing, decreased sense of smell, discharge from the nose. Dull pain on percussion of the zygomatic bone area is revealed.

*Intraoral examination.* There are upper permanent molars or premolars under the filling or with a deep carious cavity on affected sides. Teeth are stable, painless, or slightly painful on percussion. There are clinical and radiological signs of chronic apical periodontitis of these teeth.

*The x-ray* of the paranasal sinuses in the chin-nasal projection is necessary to evaluate pneumatization of all sinuses and to detect liquid in the affected sinus (fig. 25). The most informative method is zonography of the sinus. Special methods of X-ray examination of the maxillo-facial system are also used: panoramic radiographs and tomograms. The X-ray of the child with chronic odontogenic maxillary sinusitis reveals parietal or total darkening of one maxillary sinus. Presence of some liquid (pus) in the sinus is characterized by the clear border of the liquid level on radiographs.

Chronic odontogenic maxillary sinusitis must be *differentiated*, first of all, from radicular cysts and neoplasms of the upper jaw.

*Treatment* of chronic odontogenic maxillary sinusitis can be conservative and surgical. In case of acute sinusitis treatment begins with the elimination of the odontogenic focus of the inflammation. «Causal» teeth are removed.

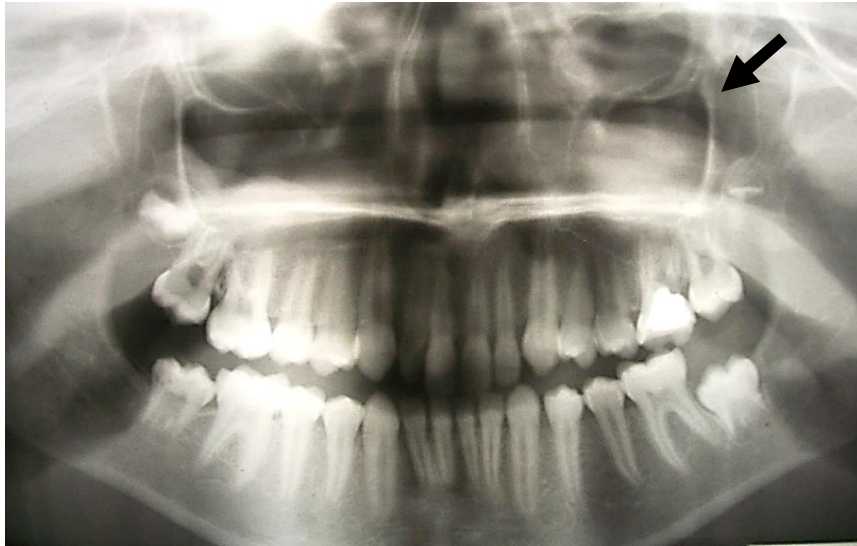

Fig. 25. X-ray picture of chronic odontogenic polypous maxillary sinusitis on the left

*Conservative treatment* consists of the prescription of vasoconstrictors, sinus puncture or drainage and washing it with antibiotics, enzymes, hormonal drugs.

*Radical surgery* in the maxillary sinus is rarely indicated, only at presence of fistula of the maxillary sinus and in case of polypous and hyperplastic forms.

#### **PERFORATING OF THE BOTTOM OF THE MAXILLARY SINUS**

The main causes of perforating the bottom of the maxillary sinus are:

- 1) destruction of tissues over the root apex of the tooth by a pathologic process;
- 2) anatomical and topographic proximity of the sinus floor to tooth roots;
- 3) violation of the rules of tooth extraction.

The sudden appearance of junction between the oral cavity and maxillary sinus is accompanied by subjective and objective clinical signs.

*Subjective symptoms:* complaints of unusual sensations of air entering the nasal cavity; a change in the voice timbre, signs of rhinolalia.

*Objective signs:* bleeding from the nose after tooth extraction; blood with air bubbles excretes from the socket of a tooth; copious suppuration in the socket; liquid enters nose at washing tooth socket.

*Oral test:* when you hold your nostrils with your fingers and try to inflate your cheeks, the air goes out into your mouth through the hole, blood with bubbles is appeared.

*Nasal test:* when you try to inflate your cheeks, air comes out through your nose and you can't inflate your cheeks.

The obtained data confirm the presence of perforation of the bottom of the maxillary sinus.

If there are no inflammatory process and foreign bodies in the maxillary sinus, immediate surgical treatment is necessary. Perforation of the bottom of the

maxillary sinus should be closed by a primary plastic of mucosa-periosteal flap or suturing of socket margins tightly.

In presence of contraindications an iodoform swab is placed to the socket attached to teeth or mucous membrane for 5–7 days. Perforation of the bottom of the maxillary sinus also can be closed with a protective plate made on a plastic model.

The maxillary sinus is washed through the fistula in presence of an inflammatory process in it. Then gentle maxillary sinusotomy with plastic of sinus-oral fistula is performed after conservative treatment.

### FACE FURUNCLES

**Furuncle (boil)** is an acute purulent-necrotic inflammation of the hair follicle and surrounding connective tissue. The causative agents of the disease are most often golden staphylococcus, less often white staphylococcus. Furuncles are usually located in the areas of the lip, chin and nose. Boils of the upper lip in the region of the nasolabial triangle have especially severe clinical progression. Furuncles of the face are often accompanied by regional lymphadenitis. It was found that more than 20 % of patients with diabetes mellitus suffer from furunculosis.

*Predisposing factors of boils are:*

- skin contamination;
- extrusion of acne;
- cooling, overheating of the body;
- disorders of the nervous, endocrine systems;
- avitaminosis and etc.

There are 3 stages of furuncle development: infiltration, abscessing and scarring.

At first, the child notes slightly painful, limited redness and swelling of the skin. A limited nodule is formed within 1–2 days. Underlying tissues become infiltrated, hyperemia increases and sharp pain appears. This is the stage of *infiltration* (fig. 26).

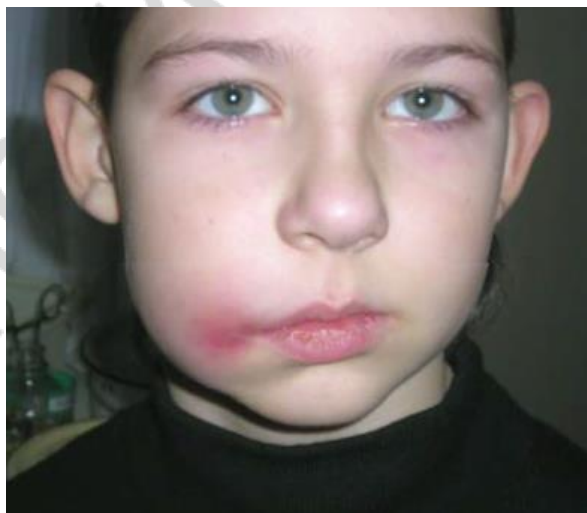

Fig. 26. Furuncle of the right cheek in its infiltration stage

The second stage of the development of a furuncle is *abscess formation*. It is characterized by suppuration and necrosis (fig. 27). Purulent tissue necrosis occurs after 3–4 days of the onset of the disease. It is clinically manifested by fluctuation. After a spontaneous or surgical opening of the boil, a small amount of pus with an admixture of blood is noted. Infiltration and swelling of borderline tissues decreases.

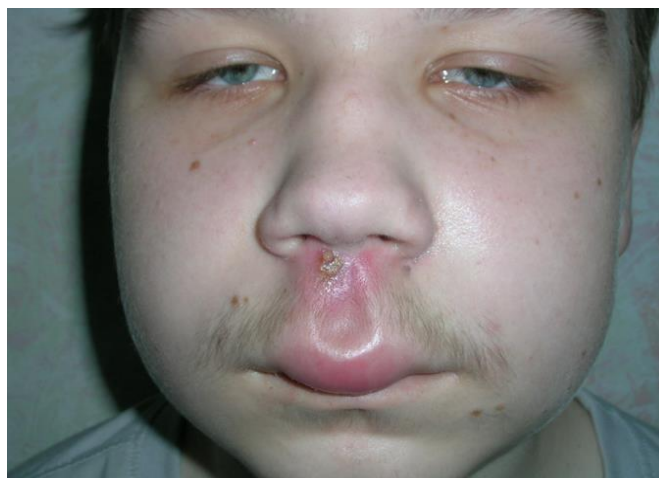

Fig. 27. Furuncle of the upper lip in the stage of abscess formation

The third stage of *scarring* is characterized by healing of the wound with the formation of a slightly retracted scar.

The furuncle of the facial area can be complicated by the formation of a *carbuncle*. Several follicles are simultaneously affected in it. Unlike the boil, the carbuncle is a diffuse purulent-necrotic inflammation of the deep skin sections and subcutaneous fat.

**Complications** of the furuncle are thrombophlebitis of the facial veins and cavernous sinus, sepsis, meningoencephalitis. It occurs more often if the furuncle is localized in the region of the nasolabial triangle.

**Treatment** of boils in the *first stage* is conservative and outpatient. Patients should avoid any external stimuli — the slightest trauma of tissues in the area of the boil. The facial skin around the boil is treated with 2 % salicylic alcohol, 70 ° ethyl alcohol or ichthyol, then an aseptic bandage is applied.

Blockade with novocaine and antibiotics can be also prescribed. It is often repeated 2–3 times. The injection of novocaine into surrounding tissue infiltrate should be given slowly and evenly.

The second phase of the inflammation (abscessing) requires surgical treatment with drainage of the purulent focus (fig. 28). Doctor also prescribes antibiotics, sulfonamides plus acetylsalicylic acid according to generally accepted schemes.

Physiotherapeutic methods are very important in the complex therapy of furuncles. UV rays, electric field of ultra-high frequencies are effective in the initial stages of furuncle development. Hypothermia with chloroethyl is especially effective in treatment of face furuncles. Helium-neon laser is also effective as this method is painless, atraumatic and non-contact.

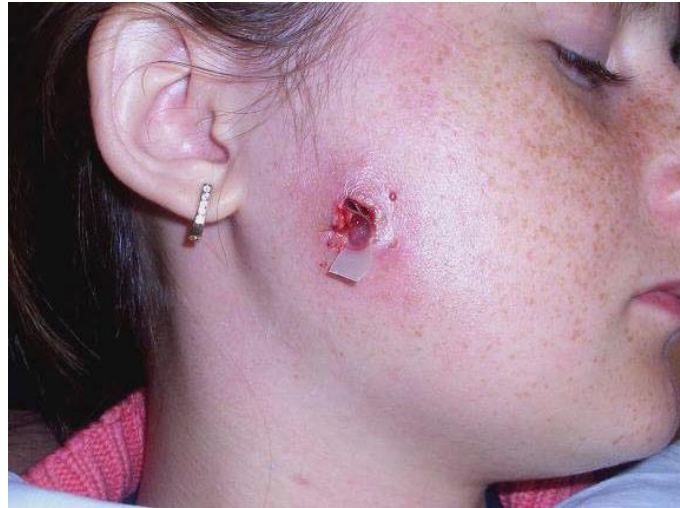

Fig. 28. Furuncle of the right parotid region (drainage of a purulent focus)

**Prevention** of boils is prevention of pustular skin diseases, sanitation of the oral cavity and nose, increasing body's defenses, treatment of diseases associated with a violation of carbohydrate metabolism (diabetes mellitus).

#### TEST FOR SELF-CONTROL

**1. Acute limited purulent-necrotic inflammation of the hair follicle and surrounding connective tissue is the:**

- a) erysipelatos inflammation; c) carbuncle; e) abscess.
- b) furuncle; d) noma;

**2. Odontogenic sinusitis often occurs in the:**

- a) primary bite; b) mixed bite; c) constant bite.

**3. Predisposing factors to furunculosis are:**

- a) exudative diathesis; d) diabetes mellitus;
- b) avitaminosis; e) a congenital heart disease.
- c) rickets;

**4. Causative teeth of odontogenic sinusitis in children most often are:**

- a) 54 and 64 teeth; d) 16 and 26 teeth;
- b) 55 and 65 teeth; e) 17 and 27 teeth.
- c) 13 and 23 teeth;

**5. Clinical signs of chronic odontogenic sinusitis are:**

- a) the deformation of the upper jaw;
- b) a purulent discharge from one nostril;
- c) eyelids swelling;
- d) maxillary sinuses darkening on the roentgenogram on both sides;
- e) maxillary sinus darkening on the roentgenogram on one side.

**6. In case of the maxillary sinus perforating at tooth extraction, it is necessary to:**

- a) suture the tooth socket;
- b) tamp the tooth socket during 7–8 days;

- c) conduct the maxillary sinusotomy with the subsequent suturing the tooth socket;
- d) fix the iodoform swab above the socket for 7–10 days;
- e) extract another tooth.

**7. The most unfavorable localization of boils on the face are the:**

- a) area of the chin;
- b) area of the lower lip;
- c) area of the upper lip;
- d) forehead area;
- e) zygomatic area.

**8. Furuncles of the face in children at the stage of abscessing should be treated:**

- a) with the help of cryotherapy;
- b) by UHF therapy;
- c) by opening an abscess;
- d) by tooth extraction;
- e) by laser therapy.

**Keys: 1 – b; 2 – c; 3 – b, d; 4 – d; 5 – b, e; 6 – a, d; 7 – c; 8 – c.**



## LITERATURE

1. *Бернадский, Ю. И.* Основы челюстно-лицевой хирургии и хирургической стоматологии / Ю. И. Бернадский. Витебск, 1998. 404 с.
2. *Заусаев, В. И.* Хирургическая стоматология / В. И. Заусаев. Москва : Медицина, 1981. С. 57–73.
3. *Козлов, В. А.* Неотложная стационарная стоматологическая помощь / В. А. Козлов. Москва : Медицина, 1988. С. 15–37.
4. *Корсак, А. К.* Поликлиническая и госпитальная детская хирургическая стоматология: учеб.-метод. пособие / А. К. Корсак наук, А. Н. Кушнер, Н. Ф. Адащик, Н. И. Петрович. Минск: БГМУ, 2007. 88 с.
5. *Кручинский, Г. В.* Одонтогенный верхнечелюстной синусит / Г. В. Кручинский, В. И. Филиппенко. Минск, 1991.
6. *Cameron, A. C.* Handbook of Pediatric Dentistry / A. C. Cameron, R. P. Widmer. Mosby, 2008. P. 60–80.
7. *Koerner, K. R.* Manual of minor oral surgery for the general dentist / K. R. Koerner. Blackwell Publ. Comp., 2006. P. 19-49.
8. *Moore, U. J* Principles of Oral and Maxillofacial Surgery / U. J. Moore. Blackwell Science Ltd, 2001. 257 p.
9. *Neelima, A. M* Textbook of Oral and Maxillofacial Surgery / A. M. Neelima. JP Medical Ltd, 2012. P. 583–611.



## CONTENT

Local anesthesia during surgical procedures in children. Indications and contraindications. Complications of local anesthesia and their prevention.....	3
Non-injection methods of anesthesia.....	3
Common complications of injection anesthesia .....	8
Local complications of injection anesthesia .....	9
Test for self-control .....	11
General anaesthesia. Indications and contraindications for planned general anaesthesia .....	12
Test for self-control .....	20
Features of inflammatory diseases of the maxillofacial region in children. Pathways of odontogenic infection. Odontogenic periostitis. Etiology, clinical picture, diagnosis, treatment, prevention .....	21
Test questions for self-control .....	24
Acute osteomyelitis of the jaws in children: odontogenic, hematogenic, traumatic. Etiology, clinical picture, diagnosis and treatment .....	25
Acute odontogenic osteomyelitis.....	25
Acute hematogenous osteomyelitis of the jaws.....	27
Acute traumatic osteomyelitis .....	29
Test for self-control .....	30
Chronic osteomyelitis of jaws in children. Etiology, clinical picture, diagnosis, treatment, prevention .....	31
Chronic odontogenic osteomyelitis of jaws.....	31
Chronic hematogenous osteomyelitis of the jaws in children .....	34
Chronic traumatic osteomyelitis of jaws in children .....	35
Complications of chronic osteomyelitis in children .....	35
Test for self-control .....	36
Odontogenic maxillary sinusitis in children. Furuncles of faces in children. Etiology, clinical manifestations. Diagnosis. Treatment. Prevention.....	37
Odontogenic maxillary sinusitis .....	37
Perforating of the bottom of the maxillary sinus .....	40
Face furuncles .....	41
Test for self-control .....	43
Literature.....	45

Учебное издание

**Антоненко** Анна Николаевна  
**Бурак** Жанна Михайловна

**ДЕТСКАЯ ПОЛИКЛИНИЧЕСКАЯ  
ХИРУРГИЧЕСКАЯ СТОМАТОЛОГИЯ**  
**OUTPATIENT PEDIATRIC ORAL SURGERY**

Учебно-методическое пособие

На английском языке

Ответственная за выпуск Т. Н. Терехова  
Переводчики А. Н. Антоненко, Ж. М. Бурак  
Компьютерная верстка А. В. Янушкевич

Подписано в печать 19.06.18. Формат 60×84/16. Бумага писчая «Хероx office».  
Ризография. Гарнитура «Times».  
Усл. печ. л. 2,79. Уч.-изд. л. 2,67. Тираж 130 экз. Заказ 439.

Издатель и полиграфическое исполнение: учреждение образования  
«Белорусский государственный медицинский университет».  
Свидетельство о государственной регистрации издателя, изготовителя,  
распространителя печатных изданий № 1/187 от 18.02.2014.  
Ул. Ленинградская, 6, 220006, Минск.

Репозиторий БГМУ