

# **CLINICAL ORTHODONTICS**

Part I

Minsk BSMU 2021

Депозитарий БГМУ

ISBN 978-985-21-0892-8



МИНИСТЕРСТВО ЗДРАВООХРАНЕНИЯ РЕСПУБЛИКИ БЕЛАРУСЬ  
БЕЛОРУССКИЙ ГОСУДАРСТВЕННЫЙ МЕДИЦИНСКИЙ УНИВЕРСИТЕТ  
КАФЕДРА ОРТОДОНТИИ

# КЛИНИЧЕСКАЯ ОРТОДОНТИЯ

## CLINICAL ORTHODONTICS

Учебно-методическое пособие

В двух частях

**Часть 1**



Минск БГМУ 2021

УДК 616.314-089.23(075.8)-054.6

ББК 56.6я73

К49

Рекомендовано Научно-методическим советом университета в качестве учебно-методического пособия 21.04.2021 г., протокол № 4

А в т о р ы: д-р мед. наук, проф. И. В. Токаревич; ассист. С. А. Хомич; ассист. А. П. Полещук; ассист. А. С. Хомич; ассист. М. А. Новик

Р е ц е н з е н т ы: канд. мед. наук, доц. каф. ортопедической стоматологии А. И. Головки; каф. стоматологии детского возраста

**Клиническая ортодонтия = Clinical orthodontics** : учебно-методическое пособие. В 2 ч. Ч. 1 / И. В. Токаревич [и др.]. – Минск : БГМУ, 2021. – 79 с.

ISBN 978-985-21-0892-8.

Описана этиология, клиническая картина, современные методы диагностики и лечения аномалий зубов, зубных рядов и прикуса в различные возрастные периоды, рассмотрены наиболее часто допускаемые ошибки при лечении. Представлены основные аспекты диагностики и лечения пациентов с врожденной патологией челюстно-лицевой области. Описаны клинические этапы применения мультибондинг-системы, особенности протезирования дефектов зубов, зубных рядов и челюстей в детском и подростковом возрасте, сохранения пространства в зубном ряду у детей при преждевременном удалении зубов, управления пространством в зубном ряду у детей, а также лечение зубочелюстных аномалий с применением современных ортодонтических аппаратов.

Предназначено для студентов медицинского факультета иностранных учащихся, обучающихся на английском языке по специальности «Стоматология».

УДК 616.314-089.23(075.8)-054.6

ББК 56.6я73

ISBN 978-985-21-0892-8 (Ч. 1)

ISBN 978-985-21-0893-5

© УО «Белорусский государственный медицинский университет», 2021

## INTRODUCTION

Anomalies of dentofacial system take one of the first places among diseases of maxillofacial region. The prevalence of dentoalveolar anomalies in the Republic of Belarus ranges from 15.5 to 78 %, which corresponds to average and high level. This situation requires development and implementation of modern, effective methods of diagnostics and treatment of dentofacial system pathology.

Diagnostics of dentoalveolar anomalies is based on clinical examination of patient and laboratory data.

The treatment tactics of dentoalveolar anomalies is determined by a number of factors, such as: type of pathology, its severity and patient's age (i.e., the period of bite formation). The main goal for orthodontist in early stages is to create conditions for normal growth and development of dentition and facial skeleton of a child, which is achieved by elimination of bad habits and normalization of functions. At older ages, these measures are joined by treatment with orthodontic appliances, often with use of surgical interventions. Combination of different treatment methods ensures results sustainability.

## PRACTICAL SESSION 1

### MOTIVATIONAL CHARACTERISTICS OF THE TOPIC

Anomalies of shape, size, terms of eruption, color and structure of dental hard tissues lead, as a rule, not only to functional, but also to aesthetic disorders. Treatment of such pathology should be carried out in cooperation with dentists of related specialties.

**Topic:** Anomalies of tooth development (eruption, hard tissues structure, shape and size). Etiology, clinics, diagnostics, treatment methods, mistakes and complications.

**Total time of session:** 7 academic hours.

**Aims and objectives of the lesson.** To study the reasons of development of eruption, hard tissues structure, shape and size of the teeth anomalies; clinical picture, principles of diagnostics, methods of prevention and treatment.

**Requirements for the initial level of knowledge.** Student should know:

1. Specific features of setting, formation and development of organs of dentofacial system.
2. Sequence and timing of eruption of temporary and permanent teeth.
3. Biometric and anthropometric methods of diagnostics.

**Practical questions of related disciplines:**

1. Terms of eruption, formation and resorption of roots of deciduous teeth.
2. Terms of formation and eruption of permanent teeth.
3. Periods of tooth development.

**Practical questions:**

1. Etiology, clinics, diagnostics and treatment of dental anomalies.

2. Etiology, clinical picture, diagnostics and treatment of teeth size anomalies.
3. Etiology, clinics, diagnostics and treatment of teeth eruption anomalies.
4. Etiology, clinics, diagnostics and treatment of structural anomalies of teeth hard tissues.

## TOOTH SIZE AND SHAPE ANOMALIES

Individual teeth anomalies include anomalies of number of teeth, terms of eruption, shape and size, structure of hard tissues, individual teeth position.

### TOOTH SHAPE ANOMALIES

Teeth with an irregular shape are most often found among permanent and less frequently among temporary teeth. Tooth crown can be spiny (Fig. 1), cuboid, rosaceous and other ugly forms (teeth of Hutchinson, Fournier, Turner). Syphilitic vasculitis during birth can damage the developing tooth buds and lead to dental anomalies. Hutchinson teeth are abnormal permanent upper central incisors that are peg-shaped and notched, usually with obvious thinning and discoloration of enamel in the area of notching; they are widely spaced and shorter than the lateral incisors; width of a biting surface is less than that of a gingival margin. Mulberry molars (also known as Moon or Fournier molars) are multicuspid first molars in which the tooth's grinding surface, which is narrower than that at the gingival margin, has many small cusps instead of a usual four well-formed cusps. Enamel itself tends to be poorly developed. X-ray studies can lead to diagnosis, even while deciduous teeth are still in place. Deciduous teeth are largely unaffected except for a possible predisposition to dental caries.

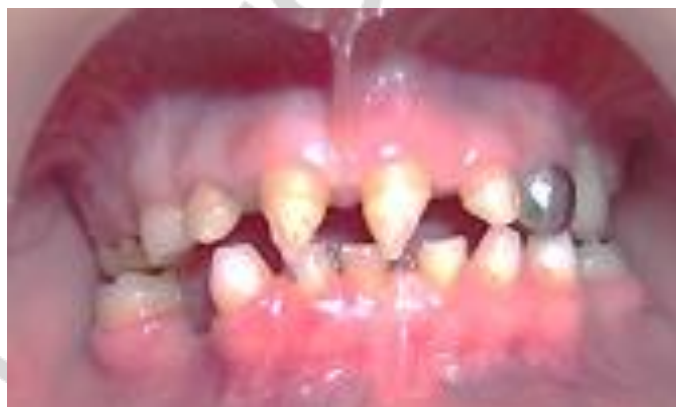

Figure 1. Peg-shaped crowns of upper central incisors

*Etiology.* Most often, dental abnormalities occur with partial anodontia (missing teeth) due to various diseases, as well as congenital cleft lip and palate, congenital syphilis. Less often, tooth shape has a hereditary etiology, for example, taurodontism (bovine tooth) refers to such anomalies. This anomaly is characterized by a tendency for tooth body to enlarge at expense of the roots. Pulp chamber is elongated and extends deeply into the region of the roots. A similar condition is seen in teeth of cud-chewing animals such as bull (Latin *taurus*).

Another anomaly of tooth shape are enamel pearls, which can be located on the roots of a tooth in the bifurcation area. Most often, they are discovered during radiography on molars of upper jaw.

*Treatment.* If shape of anterior teeth is irregular, then it can be corrected using artificial crowns. Alteration of tooth shape can also be done by using veneers and laminates made from composite filling materials, ceramics. Teeth are covered with crowns, veneers, laminates after roots formation are completed.

### TOOTH SIZE ANOMALIES

Anomalies of teeth size include increase (macrodontia) or decrease (microdontia) of tooth crown size. Reduced and enlarged sizes can have all teeth (generalized form) or individual teeth (localized form).

*Diagnostics of macrodontia.* Significant increase in tooth crown size can be determined by examining oral cavity. It is difficult to reveal insignificant increase in tooth crown size during examination. In these cases, it is necessary to measure mesiodistal dimensions of tooth crowns and compare obtained data with the average tooth size according to V. D. Ustimenko's table (for permanent teeth) or Vetzal's table (for temporary teeth).

In clinical practice, Zubkova's approach is often used to diagnose anomalies of tooth size, according to which, sum of mesiodistal dimensions of four upper and lower incisors is determined. If obtained value varies from 28 to 32 mm (for upper incisors) and from 22 to 24 mm (for lower incisors), then normodontia is diagnosed; 33–34 mm (for upper incisors) and 25–27 mm (for lower incisors) — relative macrodontia; more than 35 and 28 mm for incisors of upper and lower jaws, respectively — absolute macrodontia (Fig. 2), less than 28 mm (for upper incisors) and 22 mm (for lower incisors) — microdontia.

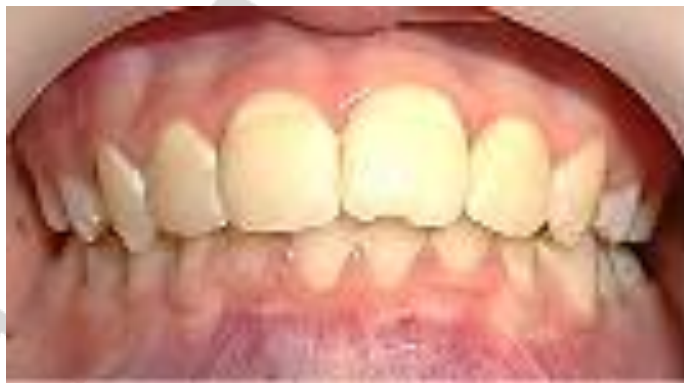

Figure 2. Absolute macrodontia

*Diagnosis and treatment planning* should be carried out taking into account face width.

**Macrodontia** causes a discrepancy in tooth size with the size of the alveolar process and, therefore, usually leads to teeth position abnormalities of.

*Treatment of macrodontia.* To normalize the position of teeth and shape of dentition, individual teeth are removed. Then the position of teeth and shape of

dentition are corrected. Reduction of teeth size in some cases can be obtained by grinding their interproximal surfaces (IPR). You can grind the enamel manually with abrasive strips or a drill using disks or burs, followed by application of fluoride preparations. It is necessary to take into account the thickness of enamel at different levels of teeth contact surfaces (equator, neck).

*Diagnosis of microdontia.* Often there is a decrease in size of upper lateral incisors. Generalized form of microdontia has, as a rule, hereditary origin, and also occurs in hypohidrotic ectodermal dysplasia (HED, also known as Christ-Siemens-Touraine syndrome (CST)) patients and Down's syndrome (DNS) patients.

Microdontia is diagnosed during oral cavity examination. The degree of teeth width decrease is determined by measuring their width and comparing results with the table of average norm.

Microdontia is the cause of dentition structure disruption, since at normal dimensions of alveolar bone, the teeth are located with gaps. Microdontia of lateral incisors can cause lateral tipping or bodily movement of central incisors and formation of diastema between them. Diastema and gaps can lead to speech disturbance.

*Treatment of microdontia.* Microdontia of lateral incisors can be corrected by crowns or aesthetic restorations with composite resins to improve appearance. In case of central incisors displacement and diastema formation, correct position of central incisors should be obtained first, then the anatomical shape of lateral incisors is restored.

With a generalized microdontia, prosthetics are indicated, if height of occlusion is reduced, and patient complains of pain in temporomandibular joint, functional disorders and aesthetic imperfection.

## ERUPTION DISTURBANCES

Significant deviations from average age of primary and permanent teeth eruption are attributed to anomalies of eruption.

**Premature eruption** of temporary teeth can occur at child's birth. Accelerated eruption of permanent teeth can occur in the background of systemic diseases (neurofibromatosis, rickets, endocrine diseases) for 1–1.5 years before the average term of eruption.

*Treatment.* With premature eruption of temporary teeth, their removal is indicated in case of atypical shape, eruption outside of dental arch, traumatizing of alveolar process of the opposite jaw, and trauma to mother's breast during feeding. In other cases, a temporary tooth is retained and (or) ground.

In cases of premature eruption of permanent teeth, it is necessary to cover them with fluoride preparations in order to prevent caries, since the enamel of this tooth is poorly mineralized.

**Delayed eruption.** Causes of delayed eruption:

1. Primary teeth:
  - a) Constitutional delay;



- b) Vitamin D deficiency in ricket patients (affects calcium metabolism, causing delayed teeth eruption and bone abnormalities);
- c) Hypothyroidism (low synthesis of thyroid hormone causes delayed development, including delayed teeth eruption);
- d) Hypopituitarism (results in developmental delay and DTE);
- e) Cleidocranialdysostosis;
- f) Gardner syndrome;
- g) Apert syndrome;
- h) Down syndrome;
- i) Cerebral palsy;
- j) Protein-energy malnutrition, or protein-calorie malnutrition (a form of malnutrition caused by inadequate protein intake that occurs most frequently in infants and young children and is the leading cause of death in children in some developing countries).

## 2. Permanent teeth:

- a) All of the factors that cause delayed emergence of primary teeth can also cause delayed eruption of permanent teeth;
- b) Teeth crowding and space deficiency;
- c) Supernumerary teeth and odontomas;
- d) Odontogenic cysts or other pathologic lesions;
- e) Persistent primary teeth or remaining roots;
- f) Tooth deformity and defective tooth development;
- g) Sclerotic gingiva or bone barrier covering the tooth.

**Unerupted (retained) teeth** — tooth eruption delay after completion of formation of its roots. The phenomenon of retention was described by Profitt and Vig and is defined as a primary abnormality in the process of eruption of non-ankylosing teeth with a lack of growth opportunities.

*Etiology.* The reasons for this anomaly vary. Examples of local factors that can interfere with normal eruption processes include supernumerary teeth, odontomas, cysts, other pathologic conditions, primary tooth ankylosis, remaining primary tooth roots, fibrotic soft tissue, bone barriers, lack of space due to early primary tooth loss, retained primary teeth, primary periapical lesions that may hasten permanent eruption, or habits and muscle dysfunction. In addition, primary teeth extraction has some effect on the eruption of their permanent successors. Multiple teeth retention can be hereditary in nature or be a consequence of severe endocrine diseases, rickets, congenital syphilis, mandibulofacial disostosis et al.

Unerupted individual teeth cause tooth dislocation, dental arch reduction in size, changes in teeth-antagonists position and malocclusion, aesthetic disorders.

*Diagnostics.* The final diagnosis of retention is based on the analysis of radiograph, which indicates the end of tooth root formation and apical foramen closure.

*Treatment.* The principle of treatment depends on the reason of delay, position of tooth in the alveolar process, presence of space in dental arch. It is necessary to gain space for a tooth and eliminate obstacles on the way of its

eruption for beginning of treatment (supernumerary teeth, persistent temporary teeth, pathological inflammatory processes in the region of alveolar process). Then the process of eruption can be stimulated mechanically (massage of alveolar process, handling the removable denture) or physiotherapy (electrophoresis of chonsuride and lidase in the region of alveolar process with retained tooth). Success of these methods can be achieved with a favorable (vertical) position of tooth in alveolar bone and proximity of tooth crown to the edge of the alveolar process. The most effective is a complex method of treatment of uneruption which is used in cases of oblique position of retained tooth in alveolar process and (or) a significant distance from the place of eruption. It is necessary to expose the crown of the retained tooth with its insignificant rotation in the bone ( $7^\circ$  in both directions, up to  $14\text{--}15^\circ$  cumulative) to relieve the periodontal ligaments (surgical stage) with the subsequent extension with orthodontic apparatus (instrumental stage). Orthodontic treatment is accelerated if a compact osteotomy of the alveolar process on the path of the tooth is performed.

A dystopic retained tooth and (or) a tooth occupying an unfavorable position in the jaw are removed.

Delay in eruption can be caused by ankylosis and impaction of teeth.

**Ankylosis** is a fusion of cement of tooth root with surrounding bone tissue. In this case, there is no periodontal ligament on the X-rays, or it is “intermittent”. Such teeth must be removed.

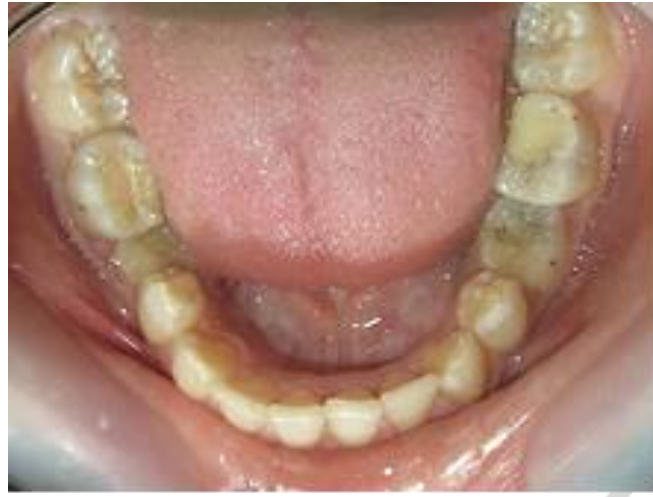**Impaction** (impact — collision) — this is a delay in tooth eruption, due to the presence of a mechanical obstacle in the way of its eruption. The reason for this may be a lack of space in the dentition in the background of close position of teeth, an improper position of tooth bud, presence of supernumerary teeth, scar-altered mucous tissue, etc. Tooth impaction is an intraosseously displaced position of teeth and an abnormal eruption pathway that results in a prognosis of delayed or failed eruption. Impacted teeth are a commonly found anomaly in dental practice. Any tooth can be impacted, but the following most frequently impacted teeth are:

- 1) Mandibular third molars;
- 2) Maxillary canines;
- 3) Maxillary third molars;
- 4) Maxillary and mandibular second premolars;
- 5) Maxillary central incisors.

### **RETENTION OF PRIMARY TOOTH**

Overretained (persistent) are those temporary teeth that were preserved in dentition 3 years after the period of their physiological change (Fig. 3).

Primary teeth with agenesis of their succedaneous tooth usually have a very long stage of root resorption and exfoliation, as literature reports. Depending on occlusion and their relationship to adjacent and opposing teeth, they may stay intact for a long period of time.



*Figure 3.* Overretained lower second primary molars

There have been reports of preserving primary teeth without permanent successors as an orthodontic option for management of missing permanent teeth in literature. These kinds of overretained primary teeth can be kept if the permanent successor is missing, provided that the condition of primary tooth roots and occlusion indicate good prognosis. Before deciding to retain the primary molars in patients who are missing their permanent successors, the orthodontist must consider the age of a patient, the occlusal status, the condition of infraoccluded tooth, including the degree of infraocclusion and root resorption, and adjacent alveolar bone levels. If the primary tooth is in normal condition and in normal relationship to adjacent and opposing teeth (excluding the aforementioned abnormal condition) but the succedaneous tooth is missing, it can be preserved as long as it remains naturally. Retained primary tooth has an advantage as a space maintainer and serves an esthetic and functional purpose. In addition, alveolar bone can also stay intact for future implant or prosthetic replacement. In cases of infraocclusion of primary molars, building the occlusal surface with composite is recommended. When the primary molar is nonmobile, functioning, and meets a patient's esthetic standards, its retention can be another management option in patients with missing premolars. Other advantages include psychologic benefits of a person keeping his or her own teeth and ability for that tooth to maintain the surrounding bone and soft tissue intact. Although restoration of infraoccluded teeth to occlusal plane may provide a good immediate result, progressive infraocclusion, which can happen during facial growth, or root resorption continuation, and later exfoliation, often is not a long-term solution. Management of a missing premolar by retaining the primary molar is not the best option in all cases (premolar hypodontia concomitant with severe crowding in another area of dentition that may need extraction). Depending on the age of the patient and the type of occlusion, treatment of choice in these conditions can be extraction of primary molar and space closure.

## COLOR AND STRUCTURE ANOMALIES OF TEETH HARD TISSUES

Causes of non-carious lesions of teeth are chronic intoxication of body with fluoride, long-term nutritional disorders, infectious diseases, common diseases before teeth eruption, metabolic disorders, rickets, mother's diseases during pregnancy (toxoplasmosis, rubella, influenza, etc.), traumatic damage to the buds of permanent teeth, etc.

*Discolorations* include tetracycline teeth, brown or yellow teeth in people ignoring oral hygiene and/or consuming tobacco leaves and other herbs.

*The fluorosis* of teeth is a systemic disorder of development of hard tissues, manifested by a change in color of teeth (mottling of the enamel) and disorders of their integrity of varying severity with relatively greater resistance to caries. Pathology arises from prolonged intake of fluorine from the environment (water, food, atmosphere) during development of the tooth. After teeth eruption, the enamel becomes matte, acquires a yellowish tint or a brown color. On the crowns of teeth appear stripes and spots of different colors, hues and sizes. In severe cases, the intensity of staining increases, and defects of enamel appear in form of pits, grooves, and fractures.

With non-endemic motility, formation of enamel is manifested by a change in its color and transparency. There are limited and diffuse opacification of the enamel.

*Hypoplasia* of enamel is a disorder of calcification and formation of hard tooth tissues. Clinically, hypoplasia is revealed by presence of point, cup-shaped depressions, transverse grooves, which adhere the tooth at a certain level. Hypoplasia is more often localized closer to incisal edges of incisors and in the region of dental tubercles. The incisal edges of incisors are often broken off. In connection with disorder of occlusal contact of opposing teeth, there is a dentoalveolar lengthening and a malocclusion in vertical plane appear. Enamel can be considerably thinned, so that dentin is visible through it. Color of enamel is shallow, yellow or brown. With systemic hypoplasia all teeth or a group of teeth developing in the same period are affected.

Hereditary disorders of structure of hard tissues of teeth include *amelogenesis imperfecta*, *dentinogenesis* and *odontogenesis*. On clinical grounds, these conditions are similar. They are rare. Etiology is unknown. The color of enamel varies from light yellow to dark brown, and softening and chipping of enamel is also observed. Underdevelopment of enamel is often combined with underdevelopment of dentin. At the same time, dentin is exposed, hardness of which is also reduced. Teeth with imperfect hard tissues are non-sensitive to different irritant.

Often, teeth quickly become worn and broken off (Fig. 4).

Excessive *attrition* is a progressive loss of hard tissues on the occlusal surfaces of teeth, exceeding normal wear. Sometimes hypersensitivity of teeth can be observed. In patients with II and III degrees of attrition of hard tissues of teeth, the occlusion height decreases, which entails disturbances in structure of temporomandibular joint and can be manifested by crunch and pain in the joint.

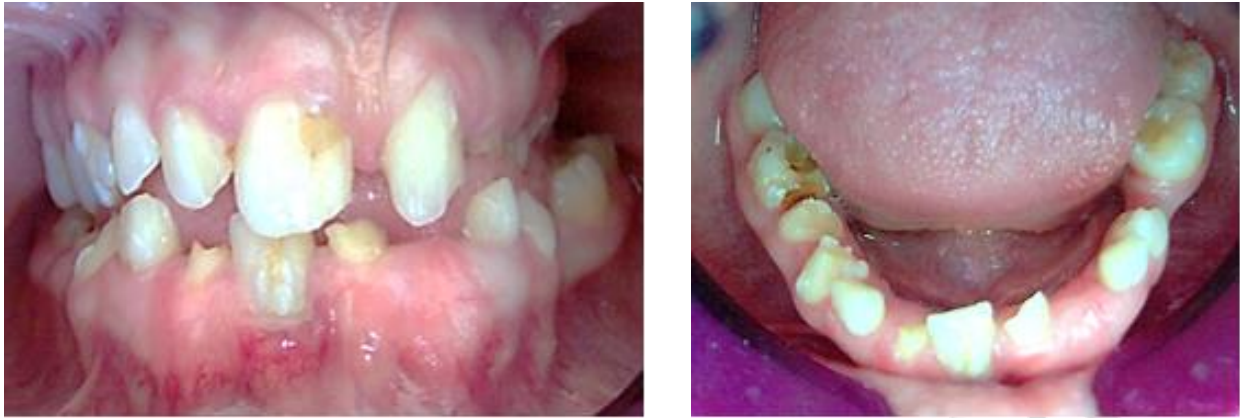


Figure 4. Amelogenesis imperfecta in combination with multiple anodontia and anomalies of the position of individual teeth

Insufficient attrition of crowns of temporary teeth often prevents closure of dentition, which is in charge of functional shifting of lower jaw forward and to the side occurrence. Mesial occlusion can develop. Most often, the cusps of primary canines remain unworn, since the period of their eruption comes later than in other temporary teeth. Timely artificial reduction (grinding) of sharp unworn cusps of primary teeth is a preventive measure, which prevents development of malocclusion.

*Abrasion* (grinding, wedge-shaped defect, abfraction) is a progressive loss of tooth surface, resulting from forced grinding of various objects and substations, such as tooth powder, hard toothbrushes, hard objects (nails, smoking pipes), and in presence of occlusal interferences with teeth-antagonists. Depending on place of application of abrasive factors, hard tissues of tooth acquire different shape, so there are V-shaped (wedge-shaped) defect, notch in the incisive part, defects of irregular shape (after ritual grinding). In addition to symptomatic treatment of teeth crowns defects, it is necessary to correct occlusion and position of individual teeth, to eliminate occlusive trauma.

*Erosion* of teeth is a progressive loss of enamel and dentine due to their gradual dissolution by acids and mechanical removal of softened tissues. The cause of erosion can be a prolonged exposure of teeth to acidic foods (for example, citrus fruits and other acidic fruits and juices), medicines with low pH, steams of acid in manufactures. The areas of demineralization of enamel during erosion are found between the equator and the cervical region of tooth. They quickly abrade, forming saucer-shaped defects.

Treatment of abnormalities of color and structure of hard tissues of teeth is symptomatic. It is necessary to eliminate etiological factors of the disease, conduct remineralization therapy according to indications, aesthetic filling, use of prosthetic method. To prevent hereditary dysfunctions of teeth it is important to carry out genetic consultancy.

## TASKS FOR INDEPENDENT WORK OF STUDENTS

### 1. Appliances used for distal movement of first permanent molars include:

- a) a plate with a sectoral split and an extension screw;
- b) Gashimov–Gerling appliance;
- c) Bynin's splint;
- d) appliance of Gashimov–Khmelevsky;
- e) Ainsworth's appliance.

### 2. Anomalies of position of individual teeth in sagittal plane include:

- a) rotation of tooth around its longitudinal axis;
- b) mesial or distal position of posterior teeth;
- c) medial or lateral position of anterior teeth;
- d) vestibular or oral position of anterior teeth;
- e) vestibular or oral position of posterior teeth.

### 3. Etiological factors of adentia include:

- a) bad habits;
- b) Mother's illness during pregnancy;
- c) heredity;
- d) diseases suffered by child;
- e) systemic diseases.

### 4. It is advisable to treat diastema:

- a) during mixed bite;
- b) during period of temporary bite;
- c) before eruption of canines;
- d) after eruption of canines;
- e) before upper lip frenulum surgery.

## PRACTICAL SESSION 2

### MOTIVATIONAL CHARACTERISTICS OF THE TOPIC

Anomalies of individual teeth number and position usually are combined with the dentition pathology and malocclusions, i.e. they are associated with other types of anomalies of the maxillofacial region. Correction of the pathology of individual teeth should be carried out taking into account this relationship and depending on the period of bite formation.

**Topic:** Anomalies of teeth number and position in dental arch.

**Total time of session:** 7 academic hours.

**Aims and objectives of the lesson.** To study the etiology of the teeth number and position anomalies; clinical features, diagnosis principles, prevention methods and treatment planning.

**Requirements for initial level of knowledge.** Student should know:

1. From the morphology course — features of the setting, formation and development of the dentition organs.
2. From the course of dental diseases prevention — periods of bite formation.
3. From the orthodontics course — biometric and anthropometric research methods, screws and springs for moving individual teeth and their groups, forces and conditions necessary for moving teeth.

**Practical questions of related disciplines:**

1. Anatomical landmarks for the passage of the mid-sagittal, occlusal and tubular planes.
2. Force of action and reaction, their application in orthodontics.

**Practical questions:**

1. Etiology, clinic, diagnosis and treatment of teeth number anomalies.
2. Etiology, clinic, diagnosis and treatment of the teeth position anomalies in sagittal plane.
3. Etiology, clinic, diagnosis and treatment of the teeth position anomalies in vertical plane.
4. Etiology, clinic, diagnosis and treatment of the teeth position anomalies in horizontal plane.

### ANOMALIES OF TEETH NUMBER

Anomalies of the number of teeth include a decrease (congenital missing) or an increase (supernumerary teeth) of their number in comparison with the norm.

**Tooth agenesis (hypodontia)** is the most common craniofacial malformation; it can occur as an isolated condition (non-syndromic) or in association with other developmental anomalies (syndromic). Lack of one or more teeth is a congenital defect that occurs during the initiation and proliferation stages of tooth formation.

The large number of genes involved in the odontogenic process means that there are numerous opportunities for mutations to disrupt this process. Recent advances at genetic techniques have begun to identify the complex process of reciprocal interactions in tooth development and the genetic mechanisms that underlie the odontogenic process.

Congenital absence of teeth has great potential to disrupt normal occlusal development; it can result in abnormal spacing, tipping of adjacent teeth, abnormal tooth relationships, and disturbed intercuspation and interdigitation. Inclined teeth can result in occlusal trauma to the affected teeth, areas of stagnation susceptible to caries, periodontal problems, bone loss, and mandibular shift. Missing anterior teeth can disturb physiologic functions such as speech and mastication and can seriously impair the patient's esthetics. These issues can profoundly affect the patient's self-esteem and confidence, resulting in psychological problems.

Timely management of hypodontia can be a great benefit to the oral health and occlusion of children with such anomalies. Early intervention reduces the complexity of the problems and, in some situations, may eliminate the need for a second phase of treatment.

**Terminology.** *Hypodontia* is a general term used for the congenital absence of teeth. This anomaly can appear as absence of a single tooth, agenesis of several teeth, or even complete tooth agenesis in patients with ectodermal dysplasia syndrome.

*Oligodontia* or *partial hypodontia* is a term that has been used to describe the absence of multiple teeth. Some investigators use this term to refer to the absence of three or more tooth buds, while others have defined this term as the congenital absence of at least four teeth. Oligodontia can be present concomitant with syndromic conditions or can arise in individuals without a syndromic condition or any general abnormalities.

*Anodontia (total hypodontia)* or absence of all teeth is a very rare anomaly that has occurred in some patients with ectodermal dysplasia.

Excluding third molars, the incidence of other missing teeth has been reported to be between 1.6 % and 9.6 %. Almost all reports show a higher prevalence in girls than in boys. The teeth most frequently absent are the maxillary lateral incisors, mandibular second premolars and third molars.

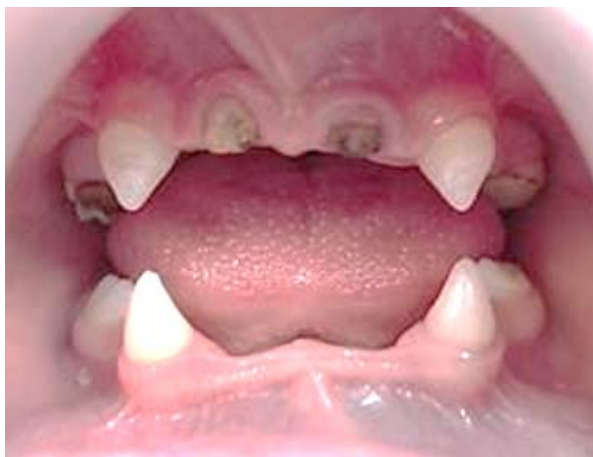**Etiology.** Different etiologic factors have been proposed for this anomaly:

1. Genetic factors.
2. Environmental factors: allergy, facial trauma, maternal medications during pregnancy, endocrine disturbances, maternal health during pregnancy, maternal rubella (German measles) during pregnancy, evolutionary dental changes, localized inflammation and infection during the initial stage of tooth formation, systemic conditions (rickets, syphilis), dysplastic syndromes (ectodermal dysplasia) and abnormalities of the ectodermal structures, chemotherapy and irradiation.

This anomaly leads to disruption in the position of the teeth and functional overload of some of them, underdevelopment of the alveolar process, deformation of the dentition, decrease in the bite height, difficulty in eating, crushing, aesthetic



disturbances (Fig. 5). The anodontia of lateral incisors, second premolars and third permanent molars are observed more often. When studying the diagnostic models of jaws obtained in parents of patients with partial anodontia, a decrease in the width of the crowns of permanent teeth is found.



*Figure 5. Oligodontia*

The significant disorders in the dento-facial region are observed in case of hypohidrotic ectodermal dysplasia, the diagnosis of it is characterized by the identification of a complex of clinical symptoms: anhidrosis, hypotrichosis, multiple anodontia, facial and skull dysplasia, and soft tissue dysmorphogenesis of the oral cavity.

**Treatment.** The treatment planning for hypodontia is based on the clinical picture and age of the child. The goals of treatment: improvement of the chewing function, prevention of secondary deformities and improvement of the appearance of the child. Most children with hypodontia need dentures. Orthodontic treatment is carried out as a preparatory stage before prosthetics.

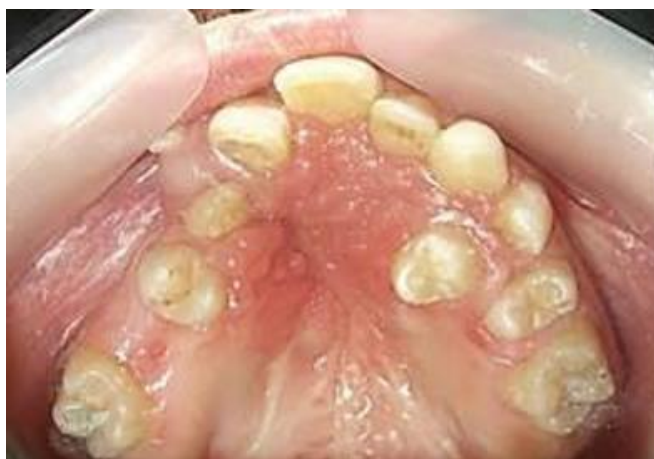### **SUPERNUMERARY TEETH**

**Etiology.** The etiology of supernumerary teeth is unknown. The presence of supernumerary teeth in the dental arch is usually harmful to adjacent teeth and occlusion. Depending on the number, location, size, and type of supernumeraries, different kinds of irregularity of occlusion may result:

1. Delayed eruption.
2. Impaction.
3. Ectopic eruption.
4. Displacement of adjacent teeth.
5. Damage to tooth structure, including root resorption, malformation, dilaceration, and loss of vitality of adjacent teeth.
6. Crowding.
7. Spacing.
8. Premature contact and occlusal interference.
9. Cystic formation.

As a rule, the damage to adjacent teeth varies depending on the number, type, and position of supernumeraries. The more supernumerary teeth, the greater the damage to occlusion; management is more complicated. Supernumerary teeth in the maxillary anterior region can prevent eruption and cause crowding, tooth rotation, abnormal diastemata, ectopic eruption, and impaction. Mandibular supplemental supernumerary teeth can cause crowding, midline shift, and arch asymmetry.

Most often, they are located in the anterior segment of the dental arch, less often in the posterior segments. In permanent dentition, supernumerary teeth are found more often than in the temporary one. Crowns of such teeth, as a rule, have an anomalous shape. Supernumerary teeth are detected during a clinical examination of the oral cavity (Fig. 6). If presence of a supernumerary tooth is suspected, special radiographic techniques such as orthopantomograms, occlusal radiographs, and computed tomograms are helpful to detect and localize the supernumerary tooth. Computed axial tomography (CAT or CT) is the process of using a computer to generate a three-dimensional image from flat, two-dimensional radiographs, one slice at a time. CT scans of internal organs, bone, teeth, and soft tissue provide greater clarity and reveal more details than regular radiographs.



*Figure 6.* Supernumerary teeth in the left segment of maxilla

**Treatment.** Treatment depends on the disorders caused by them. In most cases, supernumerary teeth are extracted, but sometimes, if they do not lead to malocclusion and aesthetic disturbances, they are retained.

The indications for immediate removal and orthodontic treatment include the following:

1. When the supernumerary tooth is erupted and causing space problems for the adjacent teeth.
2. When the presence of the supernumerary tooth is preventing or delaying eruption or damaging adjacent teeth.
3. When the supernumerary tooth is displacing adjacent teeth.
4. When a pathologic lesion such as a cyst is evident.
5. When the supernumerary tooth is an obstacle to active orthodontic tooth movement.

The indications for postponed extraction and continued monitoring include the following:

1. When the supernumerary tooth is located extremely high in the apex area of permanent teeth and surgical removal can damage root development.

2. When the supernumerary tooth is very high and does not interfere with urgent interceptive tooth movement (the extraction can be postponed until after the initial phase of treatment).

The following are important points to be considered before, during, or after removal of supernumerary teeth:

- If the supernumerary has not erupted and delayed eruption of permanent teeth is predicted, the space for unerupted teeth must be maintained.

- Long-delayed eruption and the forces of mastication might have caused formation of fibrous tissue or a bone barrier that will have to be removed to facilitate eruption.

- In many cases of neglected supernumeraries and delayed eruption of permanent teeth, the adjacent teeth often shift, creating a space deficiency for unerupted teeth. In these situations, besides removal of the supernumerary, space regaining is also recommended.

- If the permanent tooth or teeth are located high in the arch and/or displaced, it is necessary to bond an attachment for orthodontic traction at the time of extraction of the supernumerary tooth.

## ANOMALIES OF THE TOOTH POSITION

**Diagnostics.** Determination of the anomalous position of individual teeth must be carried out in three mutually perpendicular planes:

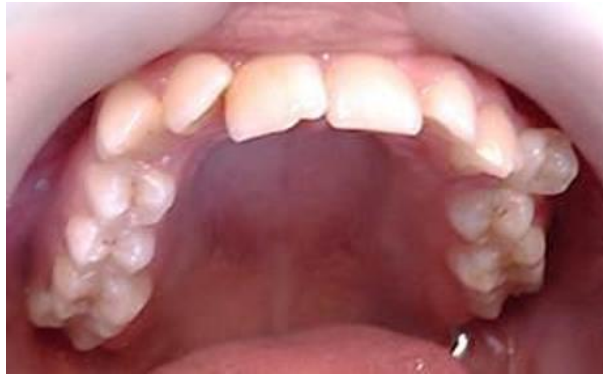1. In the sagittal direction: the mesial or distal position of the posterior teeth, the vestibular or oral position of the anterior teeth, the transposition of the teeth.

3. In the vertical direction: supraposition of the upper teeth or infraposition of the lower teeth, infraposition of the upper teeth or supraposition of the lower teeth; turning of the tooth around the longitudinal axis.

4. In the horizontal direction: the medial or lateral position of the anterior teeth; vestibular or oral position of the lateral teeth.

The vestibular (labial-buccal) position is characterized by the eruption of teeth outside the dentition. In the vestibular position can be a group of teeth or individual teeth and, as a rule, this is the result of a lack of space in the dentition, the presence of supernumerary teeth, improper position of the teeth buds, macrodontia, mouth breathing, improper swallowing, bad habits, discrepancy in the jaw size (Fig. 7).

**Treatment.** If there is a place in the dentition, the treatment consists in shifting the teeth orally. You can use a plate with occlusal patches and a screw, which is welded into a plate in untwisted form. Gradually twisting the screw shifts the posterior teeth orally. Individual teeth can be moved with a plate with a vestibular arch. To activate the device, it is necessary to activate the arc and cut the plastic base at the neck of the moved tooth in order to provide it with a free path.



*Figure 7.* Vestibular position of teeth 1.3, 1.2 and 2.4

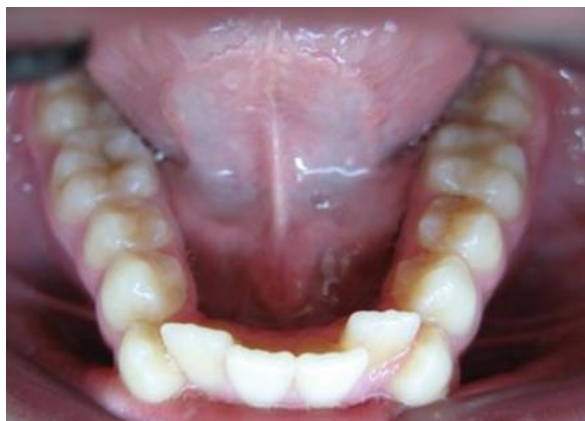The vestibular position of the anterior teeth (proclination) can easily be treated with gaps between the teeth. You can use a plate with a labial retraction bow of various designs; the vestibular plate adjacent to the vestibular surface of the anterior teeth and the alveolar process; the Angle's sliding arc; multibonding system, etc.

In cases where the protrusion of the anterior teeth is combined with the narrowing of the dentition in the posterior segments, correction of the anomalies is carried out simultaneously with the expansion of the dentition. To do this, use plates with the screw for expansion, labial bow and functionally-directing elements for disocclusion. The arc is activated by reducing the width of the U-shaped bend. Simultaneously, the plastic is cut in the region of the necks of the anterior teeth. The screw is activated  $\frac{1}{4}$  turn twice a week.

Often the cause of protrusion of individual teeth is the lack of space in the dentition. In such cases, treatment begins with the removal of supernumerary teeth or the least valuable teeth in a functional and aesthetic sense (most often these are the first premolars).

Along with the appliance's treatment, myotherapy for training circular muscle of the mouth, a set of exercises to eliminate bad habits is often prescribed.

The oral position of the teeth is characterized by the eruption of teeth inside the dentition (Fig. 8). Oral position of the teeth arises due to improper insertion of the teeth buds, premature loss of temporary teeth, mesial displacement of posterior teeth, bad habits, the presence of supernumerary teeth, mouth breathing, improper swallowing and speech formation.



*Figure 8.* Retroclined lower incisors

As a result of the oral position of the anterior teeth (retroclination), the dental arch is deformed, which acquires a trapezoidal shape. Retrusion of the anterior teeth leads to a shortening of the anterior segment of the dental arch, crowding of the teeth, deep bite, periodontal disease.

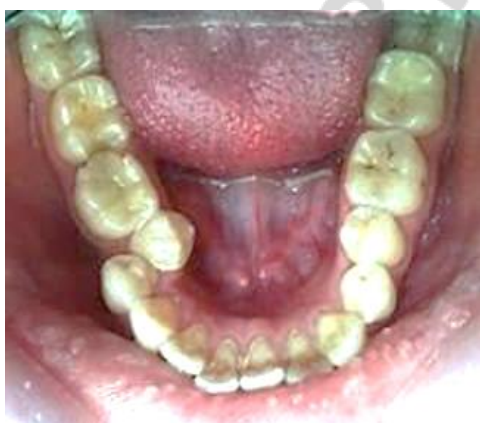**Treatment.** A place in the dental arch for the posterior teeth is created by the mesial movement of the anterior teeth, the distal movement behind or removing individual ones. After space creation orthodontic devices are used: removable (plates with protracting springs and screws of various designs), non-removable (multibonding system, Engle appliances with additional bands or crowns with hooks on the moved teeth). The tooth is moved with a wire or rubber ligature, pulling it to the arc of Angle.

To eliminate the retroclination of the anterior teeth, orthodontic devices with protracting springs and screws, Angle apparatus, Brucle's apparatus, Schwartz's splint or multibonding system are used. According to the indications, the occlusion is disconnected with the help of occlusal linings or a bite pad.

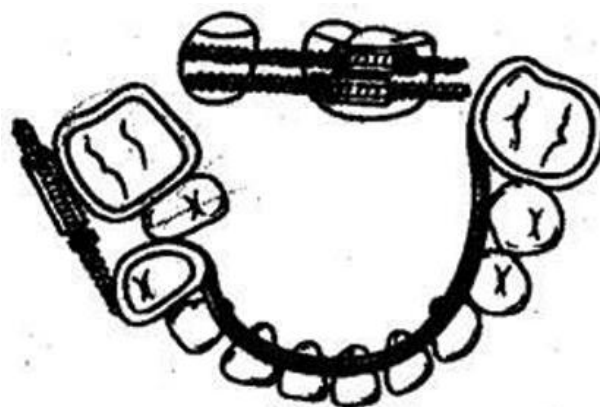
The mesial position of the posterior teeth means their displacement anteriorly, which can be the result of carious destruction of the approximal surfaces of the tooth crowns, early loss of temporary or permanent teeth, anodontia or retention, bad habits, mouth breathing.

As a result of mesial displacement of the posterior teeth, the dentition is shortened, the place in the dental arch to align the permanent canines and premolars decreases, which is the reason for the eruption of the teeth outside the dental arch, their impaction or retention (Fig. 9).

**Treatment.** With mesial displacement of the posterior teeth less than 4 mm, it is expedient to carry out their distal movement. The most widely used devices for distal movement of teeth are a plate with hand-shaped springs (cantilever), a plate with a sectoral cut and a screw for the elongation, the face bow, the non-removable devices of Hashimov–Khmelevsky, Hashimov–Gerling's (Fig. 10), Distal Jet, Jones Jig, First Class Leone, Tokarevich–Moskaleva's apparatus, Pendulum apparatus.



*Figure 9.* Mesial displacement of molars on the lower jaw results in lingual position of the tooth 4.5



*Figure 10.* The apparatus of Hashimov–Gerling for molar distalization

If the mesial displacement of the posterior teeth is more than 4 mm, a comprehensive method of treatment is used: removal of individual permanent teeth and subsequent treatment using mechanically acting orthodontic devices.

The medial position of the incisors is due to microdontia, the presence of supernumerary teeth, the narrowing of the dental arches, the early loss of individual teeth. There is a close arrangement of the teeth, their rotation around the axis, the displacement of individual teeth from the dental arch.

Treatment is carried out by removing supernumerary teeth, expanding the dental arch, lateral movement of the incisors and distal movement of the posterior teeth.

The lateral position of the anterior teeth is such that the tooth is farther from the midline than in the norm. The displacement of the anterior teeth in relation to the mid-sagittal plane passes in the horizontal direction (lateral deviation of the incisors). Lateral position of the anterior teeth leads to the formation of spaces between the teeth (diastema and gaps).

Diastema occurs during the formation of the dental arch and is often a family feature. It is also formed as a result of thickening of the of the upper lip frenulum, the fibers of which are intertwined in the interalveolar septum and the apex of the interdental papilla. Diastema and gaps are observed with excessive development of the jaws or with normally developed jaws and microdontia.

On the basis of clinical examination, study of diagnostic models of jaws, radiographs of the incisors and alveolar processes F. Ya. Khoroshilkina suggests differentiate between the following **types of diastema**:

- type I — lateral deviation of the crowns of the central incisors with the correct arrangement of the apexes of the roots (Fig. 11, *a*);
- type II — body deviation of incisors (Fig. 11, *b*);
- type III — medial inclination of the crowns of the central incisors and lateral deviation of the roots (Fig. 11, *c*).

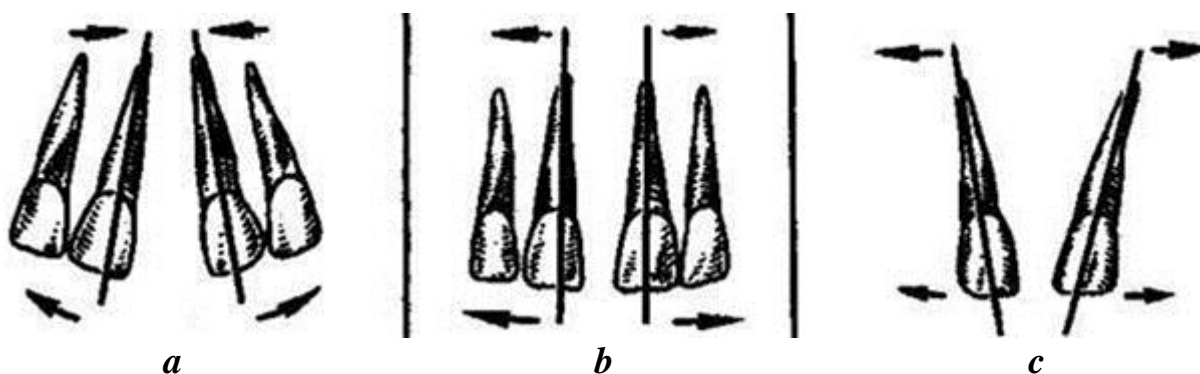


Figure 11. Types of diastema depending on the location of the central incisors in relation to the sagittal plane:

*a* — type I; *b* — type II; *c* — type III

Diastema treatment should be performed during the period of mixed dentition before the eruption of permanent canines. Treatment begins with the extraction of supernumerary teeth, elimination of bad habits, normalization of the swallowing function.

It is expedient to remove type I diastema by removable or non-removable mechanically acting appliances for the medial incline of the incisors: plates with hand-sprung springs, a plate with a labial bow and springing processes (Schwartz apparatus). Of the fixed, the Korkhaus apparatus is used (metal bands for central incisors with vertical bars welded closer to their medial surface and rubber pull).

For the treatment of type II diastema, rail constructions are used: crowns with horizontal tubes on the central incisors. The tubes are sawed along and inserted into the wire, after which the tubes are compressed with forceps to reduce their diameter. Incisors are brought together by means of rubber pull.

For the treatment of type III diastema, a multibonding system is used.

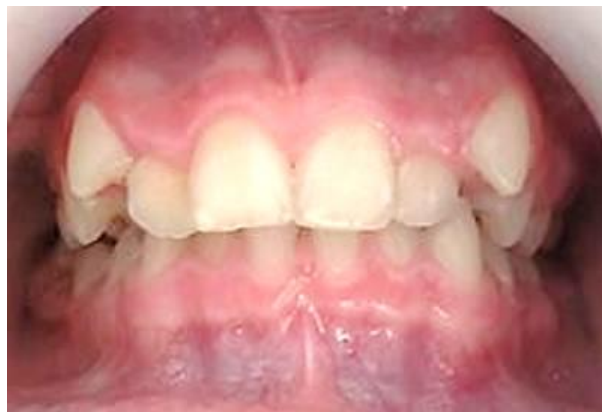The frenuloplasty is carried out after the closure of the diastema. If, after its elimination, the lateral incisors are placed close to the central incisors, an abnormality is not observed.

In the presence of microdontia, anomalies in the shape and structure of the hard tissues of the incisors, it is possible to eliminate the diastema by a prosthetic method (veneers, crowns).

The cause of distal position of the posterior teeth may be supernumerary teeth, large crowns of temporary molars, distal position of the teeth buds. Treatment of the distal position of the posterior teeth consists in the extraction of individual posterior teeth, supernumerary teeth and persistent primary molars. Mesial movement can occur independently after eliminating the cause that caused the anomaly. In the presence of fissure-tubercular occlusal contacts, it is possible to use removable (plate with hand-type springs and a bite pad, a plate with a sectoral cut and a previously untwisted screw) and non-removable (Mesial Jet, Angle's bow, multibonding system) devices.

Infraocclusion of the teeth on the upper jaw is an arrangement of the teeth in which the cutting edges or chewing surfaces of the teeth cross the occlusal plane and are below it. This offset tooth is formed in the absence of antagonist teeth.

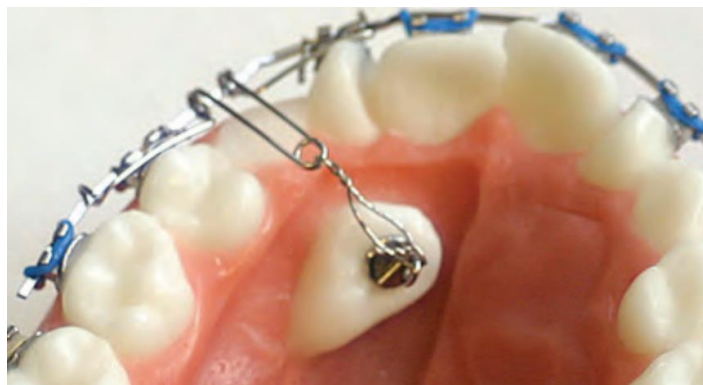Infraoccluded teeth on the lower jaw is characterized by the location of the teeth below the occlusal plane. This is often the result of a lack of space in the dentition. Supraposition on the upper jaw is an anomaly when the upper tooth does not reach the occlusal plane (Fig. 12). This is often the result of a lack of space in the dentition, as well as a parafunction of the tongue or bad habits.



*Figure 12.* Supraocclusion of the upper canines

The supraposition on the lower jaw is an anomaly when the tooth crosses the occlusal plane and is located above it. Most often in the supraposition on the upper jaw are canines, the first premolars, less often — incisors. Supraposition of teeth on the upper jaw occurs as a result of a lack of space when the dentition is narrowed. Supraocclusion of the lower teeth occurs with deep bite due to excessive development of the alveolar process in the anterior region. The causes of this position of the teeth may be bad habits, supernumerary teeth, inflammatory processes, neoplasms, dysplasia of the tooth.

**Treatment.** Most designs of orthodontic appliances for vertical movement of teeth are intended for stretching impact and retained teeth. After creating a place in the dentition on the tooth to be moved, the band with a hook, button or other device is fixed and achieved traction of the tooth with a removable plate device with a spring or fixed appliances. In combination with the multibonding system, the springs Kilroy I (Fig. 13) and Kilroy II are used to pull down the palatally and buccally located retained teeth.



*Figure 13.* Kilroy I spring for the extrusion of the palatally positioned tooth 1.3

To obtain the active force of the spring Kilroy anchorage in adjacent teeth is used. To counter unwanted forces on the supporting teeth, fix full-sized rectangular wires, which are tied to the brackets with the help of metal ligatures. For the intrusion of the tooth, devices are used that increase the pressure in the vertical direction: a plate with springs, a plate for the opposite jaws with a bite pad or occlusal lining.

**Torsion (rotation)** — rotation of the tooth around its longitudinal axis (more often incisors and canines), which occurs as a result of macrodontia, narrowing of the dental arches and lack of space in the dentition for individual teeth, displacement of a number of located teeth with premature removal of temporary teeth, supernumerary or retained teeth, bad habits, etc.

**Treatment.** After creating a place in the dental arch for an axially rotated tooth, it is placed in the correct position by means of removable or fixed appliances using opposing forces. In removable appliances, the labial bow and the oral protracting spring are more often used. From fixed appliances, the Angle's appliance in combination with a band on the moved tooth, rubber or ligature traction, a multi-bonding system. Rotation along the axis of the posterior teeth



occurs with microdontia, removal of individual teeth, proficiency of the place in the dental arch. Rotated posterior teeth occupy more space in the dental arch. To create an ideal occlusion, it is necessary to diagnose the axial position of the first upper permanent molars by the method of R. M. Ricketts (1989) or R. A. Moseyko (2004), if necessary, to carry out their derotation with the help of the Gozhgorian's appliance, Quad helix, facial bow.

Transposition — the wrong position of the teeth, in which they mutually change places. The cause of this anomaly is the incorrect insertion of the teeth buds.

The choice of method of treatment — surgical (extraction of individual teeth) or orthodontic — depends on the degree of their displacement and the inclination of the roots. Prosthetic treatment consists in changing the shape of the crowns of teeth by prosthetics.

## **TASKS FOR INDEPENDENT WORK OF STUDENTS**

To make a diagnosis in two different patients (or based on diagnostic models of the jaws) with the number or position of teeth anomalies and make a treatment plan.

### **1. The appliances are used for distal movement of first permanent molars include:**

- a) a plate with a sector cut and a screw for elongation;
- b) Gashimov–Gerling appliance;
- c) Bynina bite pad;
- d) Gashimov–Khmelevsky appliance;
- e) Ainsworth appliances.

### **2. Anomalies in the position of individual teeth in the sagittal plane include:**

- a) rotation of the tooth around its longitudinal axis;
- b) mesial or distal position of the lateral teeth;
- c) medial or lateral position of the front teeth;
- d) vestibular or oral position of the front teeth
- e) vestibular or oral position of the lateral teeth.

### **3. The etiological factors of anodontia include:**

- a) bad habits;
- b) mother's disease during pregnancy;
- c) heredity;
- d) diseases suffered by the child;
- e) systemic disease.

### **4. The treatment of the diastema it is advisable to:**

- a) during the period of mixed bite;
- b) during the period of primary bite;
- c) before the eruption of canines;
- d) after the eruption of canines;
- e) before plastic surgery of the upper lip frenulum.

## PRACTICAL SESSION 3

### MOTIVATIONAL CHARACTERISTICS OF THE TOPIC

Anomalies of the dentition are combined with malocclusion, disturbance of the individual teeth position, functional disorders of the dental system. Correction of dentition anomalies should be carried out taking into account the specified relationship and depending on the period of bite formation.

**Topic:** Anomalies of dental arch.

**Total time of session:** 7 academic hours.

**Aims and objectives of the lesson:**

To study the etiology of dentition abnormalities, types of dentition abnormalities, clinical picture, diagnostic principles, methods of prevention and treatment. To teach students to diagnose and treat dental anomalies using modern methods of treatment.

**Requirements for the initial level of knowledge.** Student should know:

1. From histology: embryonic development of the dental system.
2. From orthodontics: the timing and order of eruption of temporary and permanent teeth; anthropometric research methods in orthodontics.

**Practical questions of related disciplines:**

1. Name the sequence of primary teeth eruption.
2. Name the sequence of permanent teeth eruption.

**Practical questions:**

1. Anomalies of dentition in the sagittal plane. Etiology, diagnosis and treatment.
2. Anomalies of dentition in the vertical plane. Etiology, diagnosis and treatment.
3. Anomalies of dentition in the horizontal plane. Etiology, diagnosis and treatment.

**Educational grants. Anomalies of dental arches.** In three mutually perpendicular planes, the following abnormalities of the dental arches are distinguished:

1. In the sagittal plane:
  - a) lengthening of dental arch;
  - b) shortening of dental arch;
2. In the vertical plane:
  - a) dento-alveolar shortening in separate segments of dental arch;
  - b) dento-alveolar lengthening in separate segments of dental arch;
3. In the horizontal plane:
  - a) narrowing (constriction) of the dental arch;
  - b) expansion (widening) of dental arch.

## ANOMALIES OF DENTITION IN THE SAGITTAL PLANE

### LENGTHENING OF DENTAL ARCHES

The total length (Nance method) and the length of the anterior segment of the dental arch (Korkhaus method) determine elongation of dental arches.

**Etiology.** The causes of this anomaly are the disorders of nasal breathing (oral or mixed breathing), impaired swallowing, inappropriate articulation of the tongue, bad habits (thumb sucking, pencil sucking), macrodontia, supernumerary teeth (located in the dental arch), protrusion of incisors, distal eruption of lateral teeth.

The front teeth protrude from under the lip, between them often spaces, or teeth are located closely, and the lower lip is in the area of the sagittal gap between the incisors. Disorders usually combined with malocclusion in the sagittal, vertical and horizontal planes.

**Treatment.** Elimination of bad habits, normalization of the functions of the dentoalveolar system contribute to self-regulation of disorders in the period of temporary teeth. Vestibular plates can be used according to the indications (Fig. 14).



Figure 14. Standard Schoncher's vestibular plate

In the period of mixed and permanent dentition, in addition to the above measures, orthodontic appliances of various designs are used; according to the indications, some teeth can be extracted. Shortening of the dentition is achieved with the help of mechanically acting orthodontic appliances, if necessary combining their action with intermaxillary and extraoral traction. In cases with close teeth position, a space in the dental arch creates for the teeth to be moved.

From 6 to 10 years, pre-orthodontic trainers give positive results (Fig. 15).

In the case of elongation of the anterior segment of the dentition due to the protrusions of the incisors and the presence of the diastema and spaces, a plate with Adams clasp is applied on the molars and a vestibular arch with two semicircular bends is used (Fig. 16). Oral movement of incisors is achieved at one-time activation of the vestibular arch and sawing out the base plastic of the appliance in the front segment.



Figure 15. Preorthodontic trainer

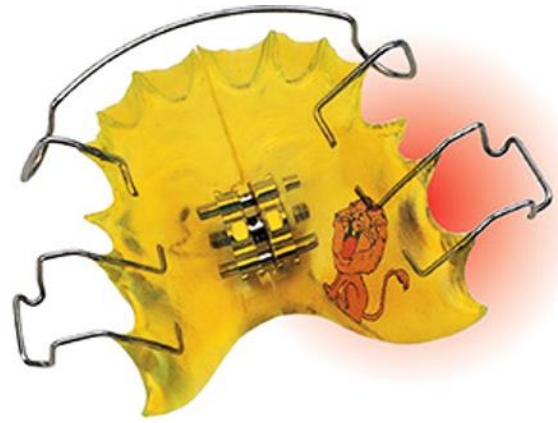


Figure 16. Plate with Adams clasps and labial bow with semicircular bend

**Etiology.** The shortening of the dentition can be the result of anomalies of the form, the size (microdontia), the number (anodontia) and the location of the teeth (the retraction of the incisors, the mesial displacement of the lateral teeth), the underdevelopment of the jaw, the bad habits of sucking or biting the lip, tongue, or any subjects.

The main reason of the shortening of the dentition is the mesial displacement of lateral teeth. There are several reasons cause mesial displacement of premolars and molars: the carious destruction of the proximal surfaces of the crowns of teeth, the early loss of temporary or permanent teeth, anodontia, retention of the teeth, the irregular arrangement of the permanent teeth buds or their eruption outside the dental arch (Fig. 17).

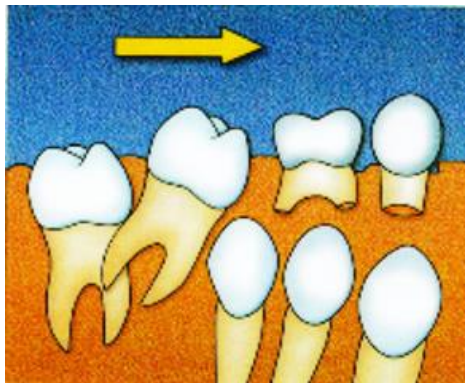


Figure 17. Mesial displacement of the 1<sup>st</sup> permanent molar with early loss of the 2<sup>nd</sup> deciduous molar

Often a close position of teeth is combined with vestibular or oral teeth inclination, retention of some teeth (often canines). The disorders can be one-sided or two-sided. Sinking of the lip is noted, and with deep bite — shortening of the lower part of the face. Shortening of the lower dentition is often observed with distal malocclusion; shortening of the upper dentition — with mesial malocclusion.

**Treatment.** To extend the dental arch, orthodontic appliances are used: plates with screws, springs, lingual arcs and other appliances, as well as with sectoral cuts (Fig. 18). When the screw is activated in a plate with a sectoral cut,

the vestibular incline of the incisors and the distal displacement of the lateral teeth occur for elongation (Fig. 19). A screw is placed parallel to the occlusal plane, its long axis is set in the direction of movement teeth. The cut is made at the level of the middle of the canine crowns. When making cuts, it is necessary to provide conditions for moving the sector and preventing its jamming when the screw is activated.

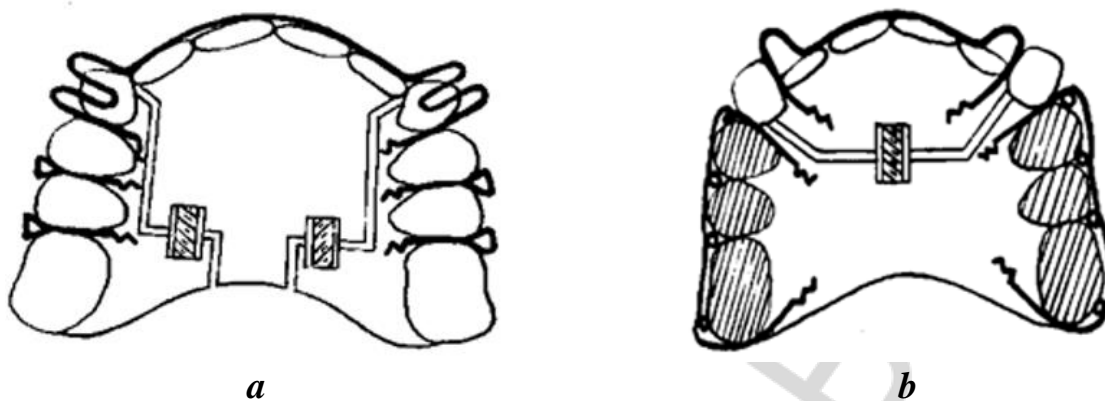


Figure 18. Plates for elongation of the upper dentition:  
*a* — with screws; *b* — with sectoral cuts

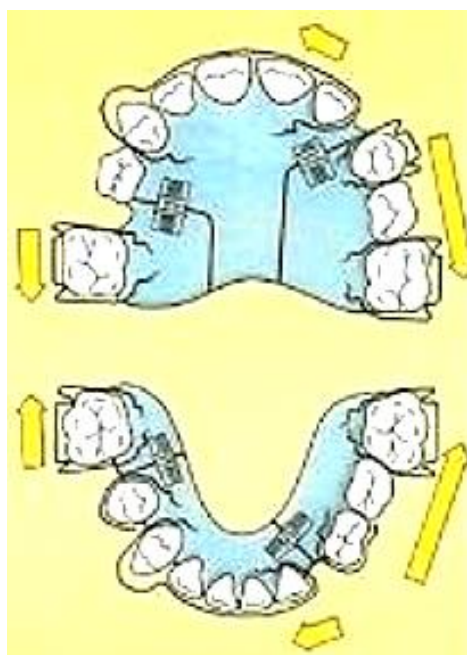


Figure 19. Direction of movement of teeth when screws are activated in plates with sectional cuts

In case with reverse incisal overlap the front teeth should be separated with the help of occlusal planes. The sectoral cut is made in the lateral region of the dentition. The basis of the appliance allows to lengthening the dentition due to distalization of premolars and molars. Moving the lateral teeth in the distal direction toward the wider part of the dental arch, contributes not only elongation, but also to the expansion of the dentition.

For distalization of premolars and molars, both removable and non-removable orthodontic appliances are used: Hashimov–Gerling’s device (Fig. 20, *a*),

Pendulum (Fig. 20, *b*), Angle, braces system. It is important to choose the right design of the orthodontic appliances taking into account the biomechanical principles of active and reactive force.

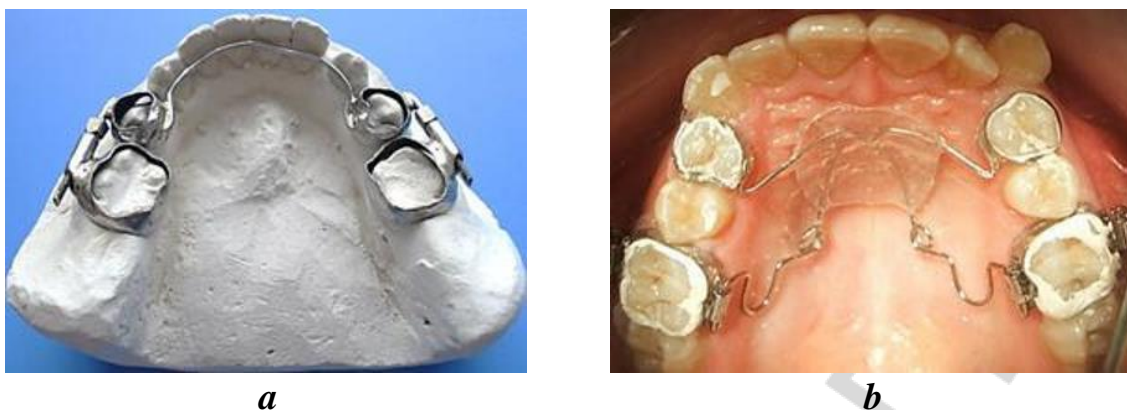

Figure 20. Apparatus for distalization of lateral teeth:  
*a* — the Hashimov–Gerling’s device; *b* — Pendulum

Lengthening of the dentition is also achieved by the use of functional appliance (Andresen activator, Frankel’s function regulator, etc.) (Fig. 21), stimulating the growth of the jaw in the sagittal direction. To these appliances it is possible to attach screws, springs and other devices to affect individual teeth or groups of teeth.




Figure 21. Functional appliances:  
*a* — Andresen activator; *b* — Frankel function regulator

## ANOMALIES OF DENTITION IN THE VERTICAL PLANE

Dentoalveolar shortening or dentoalveolar lengthening is observed in separate segments of dental arches. Such disorders combined with vertical anomalies of occlusion — open and deep malocclusion. It should be emphasized that different types of disorders can be combined in different segments of the same dentition. For example, in case of open malocclusions in the anterior segment of the dental arches dentoalveolar shortening can be observed, while dentoalveolar lengthening can be observed in the lateral segments of the upper dental arch, and in the case of deep malocclusion, vice versa (Fig. 22).

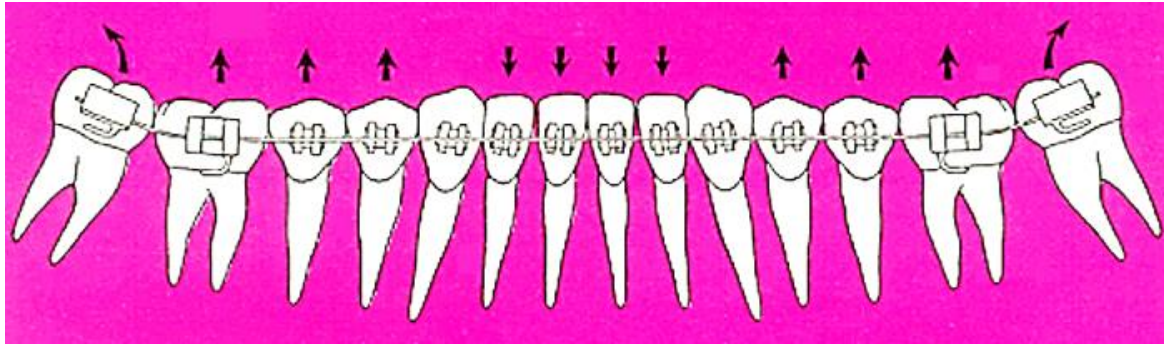


Figure 22. Dentoalveolar lengthening in the anterior region and shortening in the lateral (scheme for eliminating disorders)

### DENTOALVEOLAR ELONGATION

An important role in the etiology of abnormalities of dental arches in the vertical direction belongs to the genetic predisposition. The frequent cause of dental alveolar lengthening in the anterior segment of the dentition is a carious or non-carious lesion of the solid tissues of the lateral teeth, including erosion, early loss of deciduous molars, the first permanent molars or other lateral teeth, dysfunction of the dental system.

The harmful habits of sucking or biting fingers and other objects cause the incline of the front teeth. It causes breaking of their contacts with the opposing teeth, which leads to a decrease in the height of the bite, the establishment of the first permanent molars at wrong occlusal level and the underdevelopment of the alveolar processes in the lateral area.

**Diagnostics.** Absence of contacts between the front teeth causes dentoalveolar lengthening in this area. A disruption of the alveolar processes growth along the vertical plane are caused by proclination or retroclination of frontal teeth on one or both jaws, misalignment of the lower jaw, uneven development of the bases of the jaws, shortening of the branches of the lower jaws, a decrease in the angles of the jaw.

Functional disorders with dental alveolar extrusion are manifested in a decrease in chewing efficiency, periodontal overload of anterior teeth and, often, trauma of the mucous membrane, which contributes to the development of periodontal diseases, the abrasion of the cutting edges of the incisors and mounds of other teeth. Mouth breathing, improper swallowing and speech impairment contribute to narrowing of the dental arches, changing the location of the front teeth and deepening the incisive overlap.

**Diagnosis** based on clinical research, the study of diagnostic models of the jaws, examination of the face photos in the facial and profile, as well as cephalometry of the head, evaluating the data of panoramic radiography examination of the jaws.

Treatment of dentoalveolar lengthening in the anterior segment of the dental arch is most effective in the period of eruption of the first and second permanent molars, the eruption of incisors (periods of physiological bite enhancement).

**Treatment.** Treatment of dental alveolar elongation in the anterior part of the dental arch is most effective during the eruption of first and second permanent molars, the replacement of temporary incisors with permanent ones (periods of physiological increase in bite). The main objectives of treatment is eliminating the causes that prevent dentoalveolar lengthening in the region of the side teeth, and their separation; the creation of obstacles for dentoalveolar lengthening in the region of the front teeth; correction of the shape of dental arches, position of individual teeth and their groups; normalization of mandible position and growth of the jaws.

The existing disorders eliminates in various ways and methods taking into account the etiology, the period of formation of the dentition, its correspondence to the age and sex of the patient.

During the period of temporary occlusion it is recommended to feed children with solid foods, which stimulates the normal development of the jaws, alveolar processes and dentition. The crowns of temporary molars destroyed by caries should be restored, which achieves with the help of seals, inserts, restoration crowns. In the presence of bad habits: sucking fingers, lips, various objects, pulling the cheeks into the oral cavity and biting by the lateral teeth — it is important to wean children from them at an early age. For this purpose, vestibular plates are used.

In case of incorrect attachment of the frenulum of the tongue, plastic surgery is performed. Prematurely lost temporary molars should be replaced with removable dentures in order to prevent the occurrence of deep incised overlap.

From 5.5 to 9 years, you should start active orthodontic treatment. Disocclusion of lateral teeth in period of the eruption of the first permanent molars contributes to dental alveolar elongation in the lateral section, it helps to decrease the depth of the incisal overlap. A plate with a bite pad in posterior segments for upper jaw should be used.

At the age of 9 to 12 years old, it is important to use physiological bite increasing when premolars, canines and second permanent molars erupt to occlusion. Apply the same orthodontic devices as in the previous age period, and use some fixed orthodontic devices.

Dentoalveolar shortening can be observed in the area of canines and incisors, rarely has a large extent, when the incisors, canines, premolars, sometimes molars do not contact. In this case only the posterior teeth are in a contact.

The most common cause of development of dental alveolar shortening is the presence of bad habits in children (sucking fingers, tongue, lips, cheeks, pencils and various objects, sleep with the head thrown back, laying the tongue in the defect of the dentition after an early loss of temporary or permanent teeth). The gap between the teeth usually corresponds to the shape of the object that the child sucks.

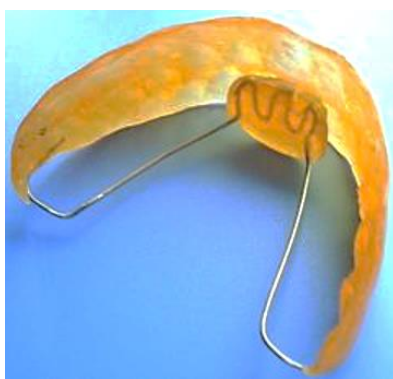Violations of speech (incorrect articulation of the tongue) leads to undereruption of the teeth and the formation of an open bite in the anterior region of the dental arches. The shortened frenulum of the tongue makes it difficult to move, which leads to an incorrect position of its tip.



These etiological factors cause significant functional disturbances: eating, chewing, swallowing, pronunciation of sounds; changes nose breathing to the mouth, which causes dryness of the mucous membrane of the upper respiratory tract, susceptibility to infectious diseases and a predisposition to periodontal disease.

The main tasks of treating dental alveolar shortening are elimination of bad habits, normalization of the position of the tongue at rest and during the function, the achievement of nasal breathing, the closing of the lips, the proper swallowing and pronunciation of the sounds of speech. To perform these tasks, according to the indications, the plastic is made of a shortened frenulum of the tongue, a myotherapy for facial muscles.

To disaccustom the children from the harmful habit of sucking the tongue and normalize the function of swallowing, use functionally appliances, such as Kraus vestibuloral plate (Fig. 23), preorthodontic trainer are used.



*Figure 23.* Kraus's vestibular oral plate

In the treatment of adolescents and adults, in addition to mechanically acting single-jaw plates with an emphasis on the tongue, springs, arches, often non-removable devices are used for dental alveolar lengthening (the Angle arch, a braces system with reversible wires).

## **ANOMALIES OF DENTITION IN THE HORIZONTAL PLANE**

The constriction of the dental arches is characterized by a change in their shape, caused by a decrease in the distance between the median plane and the teeth located laterally from it. The anomaly of the shape of the upper dentition is determined against the median palatine suture, the lower one against to the midline of the face and jaw.

**Etiology.** The constriction of the dentition can be due to genetics and is mostly hereditary. The main factors of dentition and their apical bases constriction are as follows: obstructed nasal or mouth breathing (with leads to an incorrect position of a tongue in the oral cavity and does not exert sufficient pressure on the alveolar process and the teeth to the upper dentition, which leads to its constriction); bad habits, for example sucking fingers or objects, increase the pressure of the cheeks on the dentition as a result of slightly opening the mouth; violations of the functions of swallowing, speech, parafunction of

mimic and chewing muscles, muscles of the tongue lead to the development and fixing of an incorrect neuromuscular stereotype.

Due to the tension of the facial muscles, the pressure of their tendons in the region of the corners of the mouth on the dentition, the deformation takes place, most pronounced in the region of canines and premolars.

Weak pressure on the teeth because of inactive tongue with its shortened frenulum and the prevalent action of the muscles of the lips and cheeks cause the dentition constriction and the lack of space for the front teeth. Sluggish chewing and or one-side chewing leads to disruption of normal development and growth of the jaws. The constriction of the dental arches in turn complicates the lateral movements of the lower jaw.

Early carious tooth decay (especially temporary molars) and their loss promotes the movement of the lateral teeth in the mesial direction toward the narrower part of the dental arch, which causes its constriction.

**Forms.** Constriction of dentition can be observed with neutral, distal or mesial malocclusion, as well as with vertical malocclusion. Distinguish dentoalveolar and skeletal forms of constriction of dentition. Skeletal constriction of the upper dentition is often determined curvature of the vomer.

There are dentoalveolar, skeletal, or combined forms of the constriction exist. The following forms of constricted dentition are distinguished:

- 1) saddle, when the constriction is most pronounced in the molar region;
- 2) V-shaped, when the dentition is constricted in the lateral areas, and the front part appears as an acute angle;
- 3) trapezoid, when the front portion of the dentition is constricted and flattened;
- 4) generalized constriction, when all teeth (front and side) are located closer to the median plane than in the norm.

The constriction may be one-sided or bilateral, symmetrical or asymmetric, on one or both jaws. There are constrictions of the dental arch:

- 1) with protrusion of the front teeth without spaces;
- 2) with protrusion of the front teeth and their close position;
- 3) with protrusion of the front teeth and spaces between them.

Often close position of the front teeth, the rotation of individual teeth along the axis, the inclination of one or more teeth in the vestibular or oral direction, the retention of individual teeth can be observed.

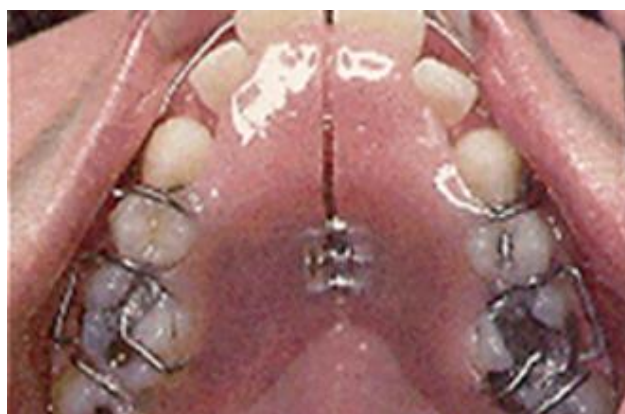**Diagnostics.** Diagnosis is established based on clinical and X-ray examinations, as well as the study and measurement of diagnostic dental casts of the jaws. Clarify the width of the dental arch in the region of premolars and molars (according to Pont, Linder and Harth) and the width of the apical base (according to N. G. Snagina, Howes). Comparison of the obtained data with the individual norm allows us to determine the severity of the constriction and choose the method of treatment. Should be taken into consideration:

1. The ratio of lateral teeth (neutral, distal, mesial).
2. Narrowing of the arch (dentoalveolar, skeletal).

3. The position of the lateral teeth, whether the close position of the anterior teeth is due to underdevelopment of the jawbone basis or other causes.

4. Whether the anomaly can be eliminated by orthodontic treatment or the use of auxiliary methods of treatment, including surgical ones, is required.

Treatment consists of expansion of the dental arches, the straitened of teeth in the correct position, as well as in determining orthodontic indications for individual teeth extraction or other surgical manipulations (compact osteotomy, decortication, plasty of the shortened frenulum of the tongue). Dental arch expansion is achieved with removable or fixed orthodontic appliances. To expand the dental arch, removable orthodontic appliances with screws or springs are used. More often — a plate with a screw and sagittal cut for equal expanding of the dentition (Fig. 24). Various designs of screws are used: skeletonized (large and small), screws with a closed body, with springs.

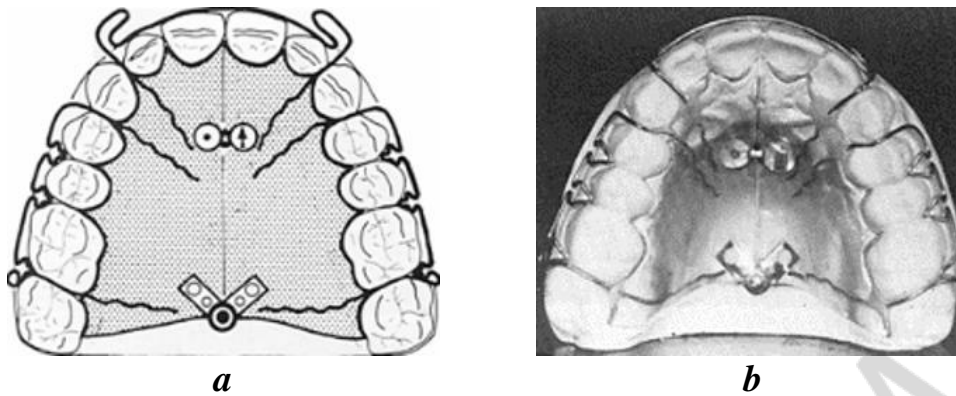


*Figure 24.* A plate with a skeletonized screw and a cut for expansion of the upper dentition

The greatest constriction of the upper dentition usually observed in the premolar region, so the screw is installed in this region in sagittal cut of the plate. The distance between the dental cast and the screw should be 0.5–0.7 mm. The cut of the upper dentition plate is made along the line of the median palatine suture. When cutting, the plates are oriented to the position of the central incisors, to the tongue frenulum and the place of attachment of the lip frenulum. A plate with a labial bow and an expanding screw is used to simultaneously expand and shorten the dentition.

Asymmetric expansion of the upper dentition is achieved with the help of plates with a screw and sectoral cuts. In the region of the lateral teeth the occlusal pads separate the occlusion. In order to expand the upper dentition larger in the anterior region and smaller in the lateral region, special screws are used (Fig. 25). When they expand, both halves of the plate diverge in a fan-like manner, which is achieved with a screw with a restrictive hinge located in the distal part of the plate on the upper jaw.

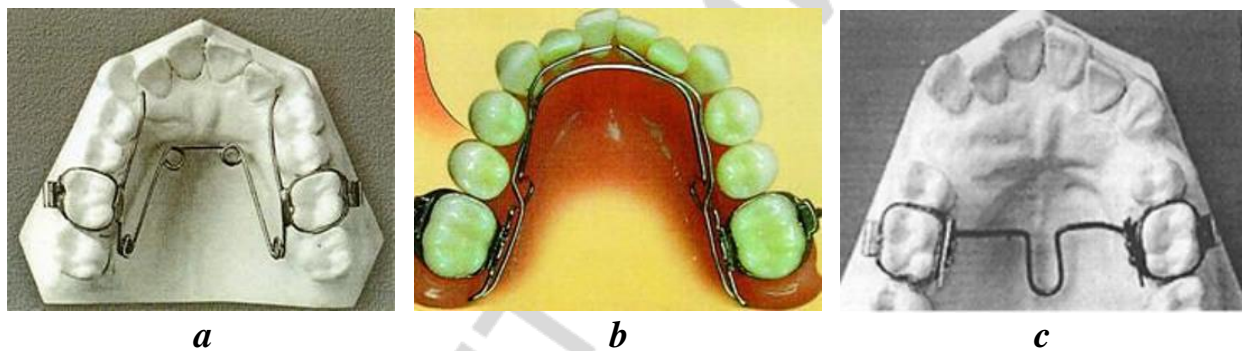
Plates are used in periods of temporary, mixed and permanent dentition. In addition to single-jawed orthodontic devices, functionally acting monoblocks (the Janson bionator, the Frankel function regulator, etc.), as well as the vestibular plates, are used to expand the dentition rows.



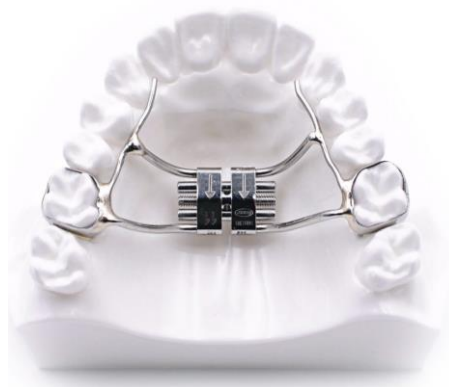*Figure 25. Plate for unequal expansion of the upper dentition:  
a — a scheme of the appliances; b — appliances on dental cast of upper jaw*

From the group of non-removable mechanically acting appliances for expanding the dentition, the palatine Quad helix and Bi helix springs (Fig. 26, *a, b*), the Gozhgarian's spring (Fig. 26, *c*), the HYRAX appliance (Fig. 27).

The duration of treatment depends on the period of formation of the dentition, the severity of the narrowing and its appearance (dentoalveolar or skeletal form, unilateral or bilateral narrowing, a presence of a reverse overlapping of the posterior teeth).



*Figure 26. Springs for expansion of dentition:  
a — Quad helix; b — Bi helix; c — the Gozhgarian's spring*



*Figure 27. HYRAX appliance*

The retention of the achieved results is provided mainly with the help of single-jaw plate with clasps and other devices for their fixation.

## THE EXPANSION OF THE DENTAL ARCHES

The expansion of the dental arches characterized by an increase in the distance between the median plane and laterally located teeth.

**Etiology.** The main etiological factors of expansion of dentition are the following: bad habits, parafunctions, improper insertion of tooth rudiments, delay in the replacement of temporary teeth; at skeletal forms — hereditary or acquired macrognathia, tumors (for example, teratoma), displacement of the lower jaw to the side, anomaly of position of the lower lateral teeth.

The expansion of the dental arch is much less common than constriction, it is combined with the malocclusion in the sagittal, vertical and horizontal planes.

**Types.** The expansion of the dental arch can be unilateral, bilateral, symmetric and asymmetric, on one jaw, on both jaws.

**Treatment.** Treatment is orthodontic or in combination with surgical. For the normalization of the shape of the dental arch, removable and fixed appliances (plates with screws, Angle's arc, braces system) are often used. In the case of the use of functional appliances, for example the Frenkel's function regulator, on the expansion side, the side shield should be adjacent to the teeth and the alveolar process.

### TASKS FOR INDEPENDENT WORK OF STUDENTS

Repeat anthropometric methods of research and study diagnostic models, by defining:

1. The length of the dentition according to the Nance method.
2. The width of the dentition in premolars and molars according to the Pont method.
3. The length of the anterior segment of the dental arches according to the Korkhaus method.
4. The ratio of the dental segments according to the Gerlach method.
5. The length and width of the apical basis according to the N. G. Snagina method method.

#### **1. Name the anomalies of the dental arches in the sagittal direction:**

- a) shortening or lengthening of dental arches;
- b) shortening or lengthening of dental arches;
- c) dento-alveolar shortening of the teeth.

#### **2. For correction of the dentition form in the permanent dentition period is used:**

- a) functional appliances;
- b) functional-directing appliances;
- c) mechanically-acting appliances.

#### **3. For equal expansion of the lower dentition using skeletal screws:**

- a) with one guide pin; b) with two guide pins; c) with four-sided guide pins.

## PRACTICAL SESSION 4

### MOTIVATIONAL CHARACTERISTICS OF THE TOPIC

Frequency of occurrence of dentoalveolar anomalies in Republic of Belarus is 11.4–71.7 %. Frequency of occurrence of distal occlusion prevails over the other dental anomalies (40–45 %). To know diagnostics, prevention and treatment of this disease — is one of the basic requirements for a qualified physician-dentist.

**Topic:** Distal occlusion. Anomalies of teeth, dentition, jaws and temporomandibular joint disorders, leading to formation of distal occlusion. Clinical features. Diagnosis. Treatment. Forecast. Results. Mistakes and complications.

**Total time of session:** 7 academic hours.

**Aims and objectives of the lesson.** Students should learn the basics of diagnostics and principles of treatment of distal malocclusion based on the period of bite formation.

**Requirements for initial level of knowledge.** Student should know:

1. Anatomy of face muscles and bones.
2. Functions of maxillofacial system.
3. Changes occurring in the maxillofacial system in case of impaired respiratory function.
4. Methods of treatment of malocclusion in orthodontics.

**Practical questions from related disciplines:**

1. Permanent teeth eruption timing.
2. Principles of action of functional appliances, indications.
3. Anatomy of face muscles and bones.

**Practical questions:**

1. Definition of distal occlusion. Synonyms of distal occlusion.
2. Etiology of distal occlusion.
3. Morphological disturbances on teeth level, dentition level and skeletal level specific for distal malocclusion.
4. Basic principles of treatment of distal malocclusion in primary dentition.
5. Basic principles of treatment of distal malocclusion in mixed dentition.
6. Treatment of distal malocclusion in permanent dentition.
7. Mistakes and complications in treatment of distal malocclusion.

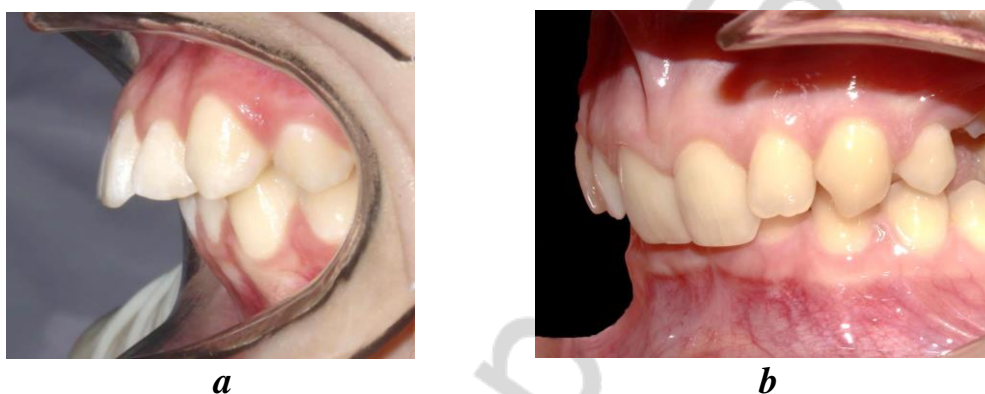### DEFINITION, ETIOLOGY, FACIAL FEATURES AND MORPHOLOGICAL DISTURBANCES

Distal bite belongs to sagittal plane anomalies and is characterized by a large variety of clinical forms and manifestations. Clinical symptom of distal bite is a prognathic relationship between dentitions. Knowledge of basics of diagnostics, principles of prevention and treatment of this pathology is one of the main requirements for a qualified dentist.

The main feature of distal bite is a discrepancy of relationship of dentitions in sagittal direction due to distal position of lower teeth in relation to upper ones. E. Angle in his classification of dentoalveolar anomalies considered such relationship as class II and characterized it by the following intraoral signs: mesio-buccal cusp of upper first permanent molar is located in front of the transversal sulcus of lower first molar; upper canine (permanent or temporary) is positioned in front of the contact point between third and fourth teeth of lower dentition.

Different authors use the following terms to name this pathology:

- 1) II class relationship by Angle: subdivision-1, subdivision-2 (Fig. 28);
- 2) prognathia;
- 3) prognathic bite;
- 4) prognathic distal bite;
- 5) posterior bite;
- 6) distocclusion.



*Figure 28. The distal occlusion:  
a — class II subdivision 1; b — class II subdivision 2*

**Etiology.** Distal occlusion can be inherited, i.e. the discrepancy between size and location of teeth and jaws caused genetically. It can also be the result of congenital disorders of facial skeleton formation (during embryonic development). However, most often distal occlusion is a result of influence of various factors of General and local character. The General factors include: diseases associated with mineral metabolism disorders (rickets), diseases of musculoskeletal system (scoliosis), injuries of maxillofacial region (especially in lower jaw), inflammatory diseases of lower jaw (osteomyelitis). Local factors: improper feeding (natural and artificial), long-term use of a pacifier, a wrong position of child during sleep (head thrown back), pathology of soft tissues of the mouth (short frenulum of a tongue), bad habits (finger sucking, biting of lower lip) and dysfunctions of dentofacial system, namely, mouth breathing, swallowing and chewing disorders.

#### **FACIAL SIGNS OF DISTAL BITE**

A face profile of a patient with distal bite is convex, often, lower part of the face is shortened, lips usually do not close, lower lip enters the gap between upper and lower incisors, upper incisors are located on lower lip, supramental fold is expressed and double chin is formed (Fig. 29).

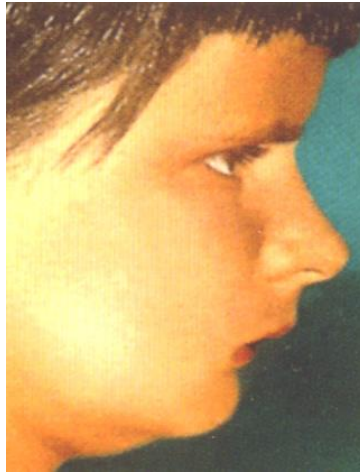


Figure 29. Profile of the patient with distal bite

There are two morphological types of the distal occlusion — dental and skeletal.

**Morphological disorders of dentoalveolar system** in distal bite can be at the level of jaws, dentition and individual teeth:

1. At the level of jaws: anterior position of maxilla (prognathia), posterior position of lower jaw (retrognathia), increased size of upper jaw (macrognathia), smaller lower jaw (micrognathia).

2. At the level of dentition: shortening of upper dentition in distal segments, shortening of lower dentition in anterior segment.

3. At the level of individual teeth: mesial displacement of upper lateral teeth, distal eruption of lower lateral teeth.

Functional disorders of dentoalveolar system in distal bite. Mouth breathing contributes to disturbance of sealing function of lips, decreases tone of muscles surrounding the mouth, muscles, lifting the lower jaw. Respiratory dysfunction changes the position of the tongue — it sinks to the bottom of the mouth (gloops). Under pressure of tongue muscles, lips and cheeks, the position of teeth changes, upper dentition constricts, protrusion or retrusion of anterior teeth develops, overbite worsens. Pronunciation of sounds is disturbed; articulation of tongue is changed. The presence of positive overjet, the lack of contact between incisors is the cause of biting difficulties.

**Diagnostics.** Diagnostics of distal bite is carried out on the basis of clinical examination, study of patient's anamnesis and additional methods — analysis of diagnostic models of jaws, lateral cephalometry, photos of the face, functional methods of examination of masticatory and mimic muscles.

On diagnostic models of jaws in patients with distal occlusion we study the compliance between total length of dentition and teeth size of its components (methods of Nance and Lundstrom), length of anterior segment of dentition (Korkhaus' method), width of dentition (Pon's method), parameters of apical bases of the jaws (Snaginas' method), mesial displacement of lateral teeth (Smudt's method), correspondence of segments of upper and lower dentitions (Gerlach's method).



Lateral cephalograms are studied to determine the morphological disorders of structure of facial skeleton, type and period of growth of facial skeleton.

To determine the period of growth of facial skeleton, radiography of patient's hand is also carried out.

During clinical examination, clinical diagnostic tests are used for differential diagnosis of varieties of distal bite, reasons and direction of displacement of mandible are studied.

**Eshler–Bitner's clinical test.** The patient is offered to advance the mandible to a normal relationship of lateral teeth. If profile of the face is improved, the distal bite is associated with underdevelopment of lower jaw or its distal position. If profile of the face worsens — the cause of malocclusion is in the size or position of upper jaw. If during advancement of lower jaw expression of the face at first improves, and then worsens, distal bite is caused by disturbance of size or position of both jaws.

**Clinical functional tests of Ilyina–Markosyan.** The following four samples can be used to determine the direction, cause and degree of displacement of mandible:

1. In the first stage (state of rest) we evaluate the face of a patient in anterior and lateral view, pay attention to position of lower jaw at rest, during conversation. Reveal facial signs of malocclusion.

2. In the second stage (study of habitual occlusion), the patient compresses his teeth without blurring his lips. In cases of functional displacement of mandible, facial signs of disturbance are more pronounced according to direction of displacement of the jaw. Mesial displacement of mandible is determined by shape of the face profile, lateral — by the shape of its face.

4. In the third stage (study of lateral displacements of lower jaw), the patient is offered to open mouth wide and determine displacement of lower jaw to the side. With its lateral displacement, the asymmetry of the face increases, decreases or disappears depending on the condition of its occurrence. Compare positions of face midline to dentition central line.

5. In the fourth stage (comparative study of habitual and central occlusion) assess the harmony of the face after setting mandible into correct position (without its usual displacement) and compare from an aesthetic point of view with the harmony of the face when setting lower jaw in habitual position.

**Basic principles of treatment of distal occlusion according to a period of bite formation.** Treatment of distal occlusion, as well as other dentoalveolar anomalies (with the exception of malocclusion, connected with congenital cleft of maxillofacial area) is advisable to start from 5–6 years. This is due to the peculiarities of the child's psychics.

**Period of temporary occlusion.** *Main task for orthodontist:* creation of optimal conditions for jaws growth and development, deblock mandible in the area of lateral and anterior teeth.

**Methods of treatment:** primary — myotherapy, additional — instrumental method (orthodontic appliances).

Treatment of distal bite should begin with the elimination of acquired etiological factors. First of all, it is necessary to normalize nasal breathing and other functions of dentofacial system (swallowing, chewing), as well as functions and tone of muscles of the maxillofacial region, to eliminate harmful habits. For this purpose, myotherapy is used.

In oral or mixed types of breathing, patient should be directed to otorhinolaryngologist to detect and eliminate the causes of impaired function (enlarged Palatine-pharyngeal tonsils, chronic diseases of upper respiratory tract, curved nasal septum, etc.). When nasal breathing is impaired, the tone of circular muscle of the mouth (the valve function of the lips is disturbed), as well as the masticatory muscles pushing the lower jaw, decreases. The position of tongue changes — it falls to the bottom of the mouth, which leads to narrowing of upper dentition and fixes the distal position of lower jaw. Such patients are prescribed a complex of myotherapy exercises aimed at training the circular muscle of the mouth and chewing muscles, pushing and holding the lower jaw. If swallowing function is impaired, exercises are prescribed to train the muscles of anterior and middle third of the tongue.

In case of impaired speech function, patient is directed to speech therapist to normalize the situation, articulation of the tongue and pronunciation sounds.

With destruction of crowns of deciduous teeth or their premature removal, orthopedic (prosthetic) method should be applied, which means treatment and rehabilitation with thin-walled crowns.

For treatment of distal occlusion in the period of deciduous bite oral screens are widely used: standard vestibular Muppy plate (Fig. 30), individual vestibular plate of Kerbits' (Fig. 31), standard vestibular Sonher's plate (Fig. 32), vestibulo-oral plate of Krause (Fig. 33), preorthodontic trainers (Fig. 34), LM-activators (Fig. 35).



Figure 30. Standard vestibular plates MUPPY

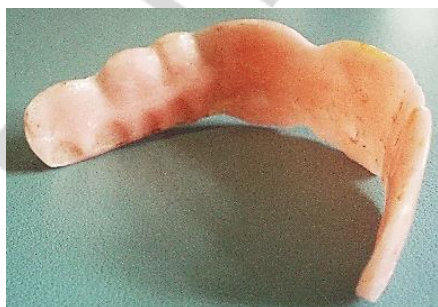

Figure 31. Individual vestibular plate of Kerbits'

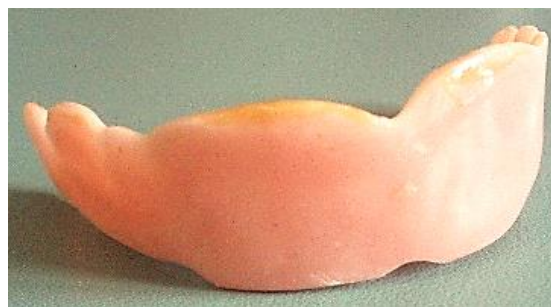
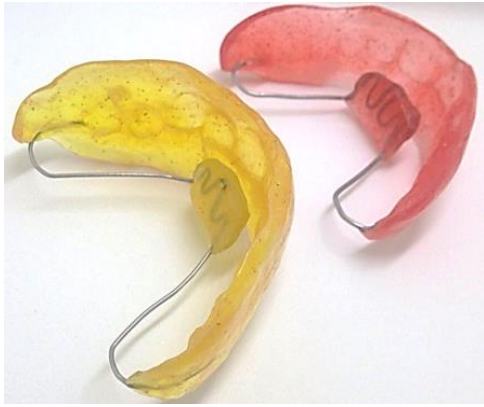
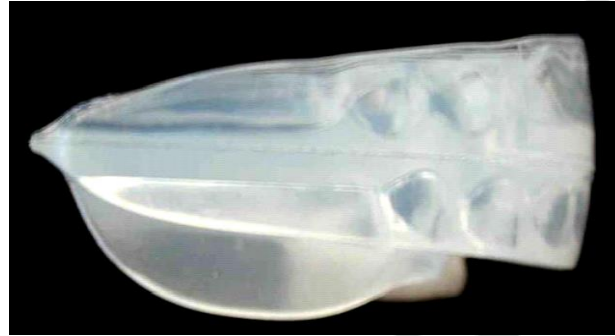
Figure 32. Standard vestibular Sonher's plate



*Figure 33. Kraus plate*



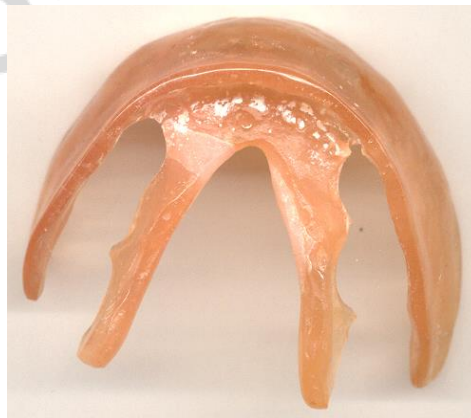*Figure 34. Preorthodontic trainers*



*Figure 35. LM-activator*

Such appliances eliminate the pressure of cheeks on lateral departments of dentitions that contributes to expansion of the dentition in these areas and transfer muscular pressure on anterior group of teeth (eliminates protrusion of the upper incisors) in addition, oral screens can normalize the disturbed functions of breathing and swallowing, and help to eliminate bad habits like thumb sucking, lower lip sucking. Standard vestibular Sonher and Muppy screens can be used during myotherapy to train circular muscle of the mouth and muscles of the tongue.

In severe cases you can use Muleman's propulsor (Fig. 36), preserving positive qualities of shield appliances and contributing to acceleration of growth of the lower jaw in combination with inhibiting the growth of maxilla in sagittal direction.



*Figure 36. Muleman's propulsor*

**Period of mixed dentition.** *Main goal for orthodontist* is to optimize growth of lower jaw, restrain growth of upper jaw.

**Methods of treatment:** major — orthodontic, additional — myotherapy. Less commonly used is complex method of treatment.

In the period of mixed dentition attention should be given to elimination of acquired etiological factors of distal bite and to normalization of impaired functions of dental system (breathing, swallowing, chewing) and muscular tone of maxillofacial region, to eliminate bad habits. For this purpose *myotherapy* is used.

*At the age of 6–9 years* (initial period of mixed bite) for treatment of distal malocclusion standard functional appliances, like preorthodontic trainers (Fig. 34), LM-activators (Fig. 35), myobrases (Fig. 37) are used. Also at this age, the use of Frenkel's function regulators type I and II (Fig. 38) is effective. These devices provide changes only at dentoalveolar level.

Standard functional appliances are recommended to be worn for at least 4 hours during day and at night (during sleep).



Figure 37. Myobrace



Figure 38. Frankel functional regulator

*After 9 years (the final period of mixed bite)* for treatment of distal occlusion Frenkel's function regulator (Fig. 38) and monoblock functional devices should be applied, as their use is most expedient during periods of active growth of jaws. Such appliances include activator of Andresen–Haupt (Fig. 39), open Klammt's activator (Fig. 40), Janson's bionator (Fig. 41), bionator of Khoroshilkina–Tokarevich (Fig. 42), etc. Fundamental differences in application of activators don't exist. The basis of their action consists in determining of constructive occlusion (advancement of mandible to neutral relationship of the jaws) during manufacture.

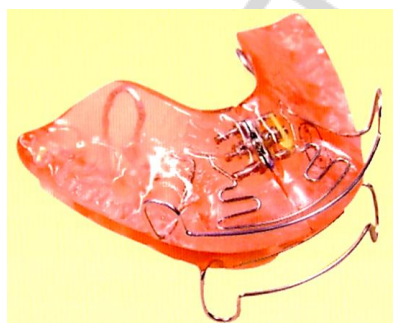


Figure 39. Andresen–Haupt's closed activator



Figure 40. Klammt activator

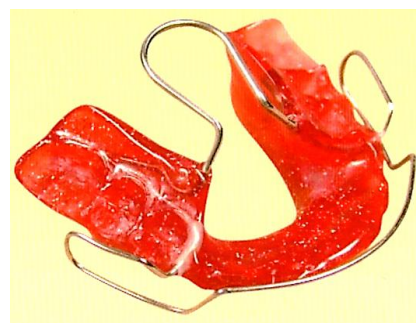

Figure 41. Janson's bionator

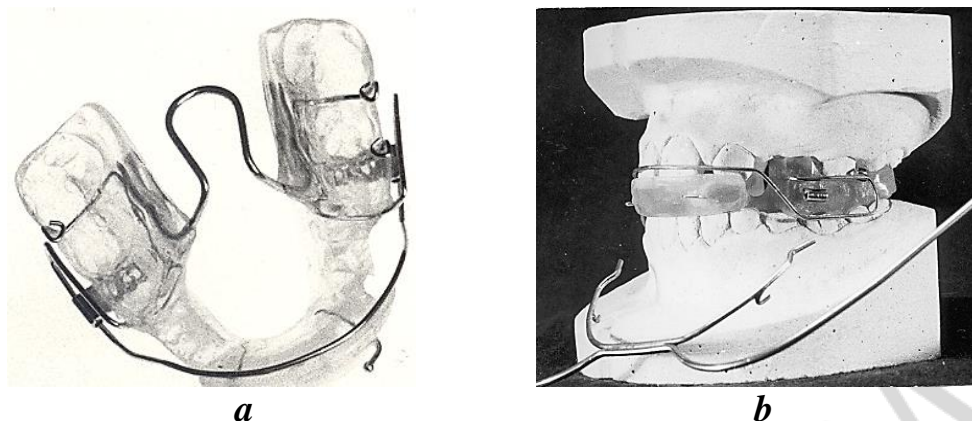


Figure 42. Bionator of Khoroshilkina–Tokarevich:  
*a* — top view; *b* — on diagnostic models with front arch

It should be noted that before treatment with activators and bionators orthodontist should *normalize the shape of dentition* (elimination of constriction of upper dentition, shortening of lower dentition) and *eliminate retrusion of upper incisors*. To expand upper dentition and normalize position of upper incisors mechanical removable orthodontic appliances — plates with screws and springs — are used.

To enhance the impact of functional devices on upper anterior teeth (elimination of protrusion) and upper jaw growth, it is possible to use facial bow in combination with activators (Fig. 42, *b*).

Complex method of treatment in this period is carried out not very often. It's used in severe cases and cases with absolute macrodentia. In such situations, often sequential extractions by Hotz in upper jaw are used.

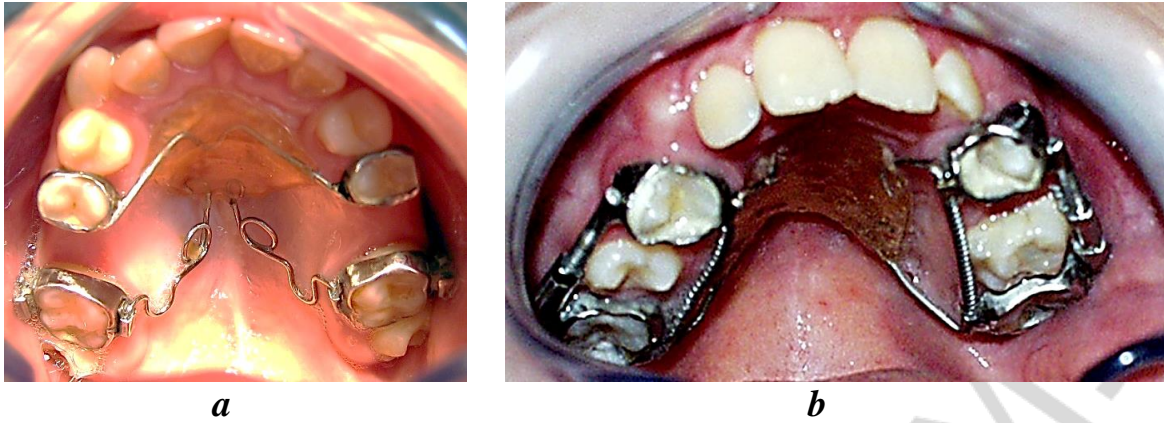
**Period of permanent bite.** *Main goal for orthodontist:* to reduce the size of upper dentition and normalize occlusion (for a complex method of treatment).

**Methods of treatment:** orthodontic (appliances), complex, surgical.

The choice of treatment in permanent dentition period depends on ongoing or completed growth of facial skeleton.

In case of continuation of active growth of the jaws (*emerging permanent occlusion*) for correction of distal occlusion monoblock functionally acting orthodontic appliances — activator of Andresen–Haupl, open Klammt's activator, bionator of Janson, etc — could be used.

After completion of active growth of jaws (*formed permanent occlusion*) correction of distal occlusion using different appliances is possible in cases when it is caused by mesial displacement of lateral teeth. Application of molar distalization devices is reasonable for patients with a neutral and the horizontal type of jaw growth with mesial displacement of lateral group of upper jaw teeth and with discrepancy in size of temporary and permanent lateral teeth crowns. For distal movement of molars Pendulum appliance is used (Fig. 43, *a*) and appliance of Tokarevich–Moskaleva (Fig. 43, *b*). After distalization of molars, to produce distal movement of premolars and canines, to normalize position of anterior teeth, shape and relationship of dentitions, bracket-system is used.




*Figure 43. Appliances for distalization of molars:  
a — Pendulum apparatus; b — Tokarevich–Moskalevas' apparatus*

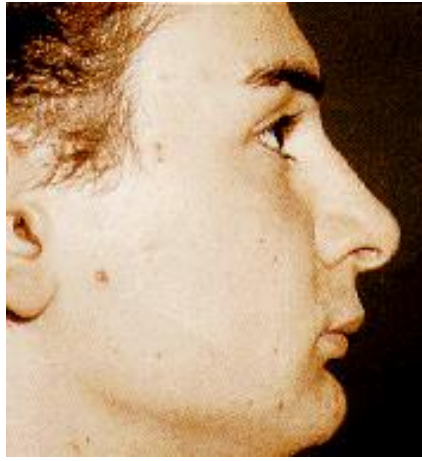*Complex method* of treatment of distal occlusion in formed permanent bite is used to reduce the size of upper dentition by extracting individual teeth (most often teeth 1.4, 2.4, and 1.5, 2.5 are being extracted) and subsequent application of bracket-system. Complex method of treatment is recommended in dentoalveolar and non-significantly expressed skeletal forms of distal occlusion.

In cases of lower micrognathia and retrognathia in combination with horizontal type of growth of jaws, normalization of relationship of the jaws in sagittal plane can be carried out with the help of fixed functional appliances, like Herbst (Fig. 44, *a*) and Sabbagh springs (Fig. 44, *b*), which can be used alone or in combination with bracket-system. Currently, this method of treatment is widely used and is an alternative to orthognathic surgeries.

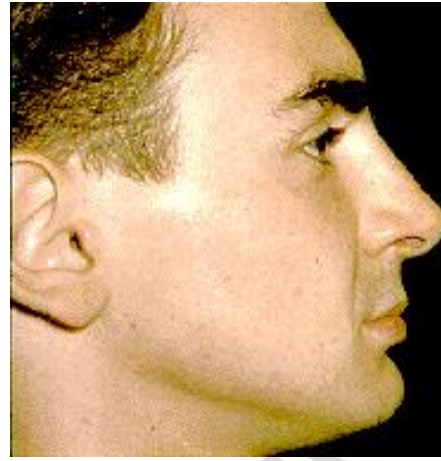In cases of skeletal form of distal occlusion, after complete formation of dentition, surgical treatment — reconstructive surgery on jaws that allows you to change the size and position of the jaws — is indicated (Fig. 45). Main task for doctor-orthodontist in such cases, is to normalize the position of individual teeth and shape of dentitions with bracket-system before operation (decompensation) and postoperative correction of upper and lower teeth relationship and contacts adjustment.



*Figure 44. Non-removable functional devices:  
a — Herbst's appliance; b — Sabbagh universal spring*



*a*



*b*

Figure 45. The method of surgical treatment of distal occlusion:  
*a* — the patient's face before treatment; *b* — the patient's face after treatment

Basic principles of distal occlusion's treatment depending on bite formation period are shown in Table 1.

Table 1

Basic principles of treatment of distal bite

Occlusion formation stage	Treatment method		Appliance
	Main	Additional	
Temporary bite	Myotherapy	Instrumental	Standard and customized vestibular and vestibular-oral plate; preorthodontic trainers, Muhleman's propulsor
Mixed bite	Instrumental	Myotherapy	Muhleman's propulsor, open and closed activators, bionators, Frankel's function regulator
Permanent bite	Complex	Orthodontic, surgical	Bracket-system, Herbst's appliance, appliances for molars distalization.

**Retention of achieved results of treatment is carried out:**

– during period of temporary and mixed bite — with devices that were used in treatment;

– during period of permanent bite — with single-jaw plates with labial bows, fixed retainers, Osama retainers.

In cases of treatment with fixed functional appliances, for retention removable functional appliances are used.

Duration of retention period is individual. The results of treatment are stable after normalization of dentoalveolar system functions and achievement of multiple fissure-cusp contacts between upper and lower dentitions.

**Possible mistakes in treatment of distal occlusion:**

1. Treatment begins with extension of lower jaw, but not with expansion of upper dentition.

2. Retrusion of upper incisors is not eliminated at first stage of treatment.

3. Optimization of lower jaw growth in patients with distal open bite, characterized by vertical type of jaw growth.
4. Orthodontic treatment only in cases of severe overjet more than 10 mm (complex treatment required).
6. Functional appliances are used in inactive periods of jaw growth.
7. Dysfunctions are not yet corrected.
8. Full intercuspation is not achieved during treatment.

## **TASKS FOR INDEPENDENT WORK OF STUDENTS**

### **1. Principles of treatment of distal bite in mixed dentition:**

- a) optimization of mandibular growth;
- b) optimization of maxillary growth;
- c) inhibition of mandibular growth;
- d) inhibition of maxillary growth.

### **2. For canines distal movement, the following orthodontic appliances can be used:**

- a) an orthodontic appliance with labial bow and two semicircular bends;
- b) an orthodontic appliance with labial bow with double U-loops and bilateral hooks;
- c) an orthodontic appliance with labial bow with M-shaped bends;
- d) an orthodontic appliance with labial bow and finger-springs;
- e) an orthodontic appliance with screw and two guiding pins.

### **3. For treatment of distal occlusion in mixed dentition the following orthodontic appliances are used:**

- a) Klammt functional appliance;
- b) Frankel functions regulator;
- c) Frankel activator;
- d) Johansson bionator;
- e) Bimler appliance.



## PRACTICAL SESSION 5

### MOTIVATIONAL CHARACTERISTICS OF THE TOPIC

Mesial bite is a type of malocclusion in sagittal plane. Frequency of occurrence of dentoalveolar anomalies in Republic of Belarus is 11.4–71.7 %. Despite low incidence of mesial malocclusion orthodontic correction of this pathology is the most difficult. To know diagnostics, prevention and treatment of this disease — is one of the basic requirements for a qualified physician-dentist.

**Topic:** Mesial occlusion. Anomalies of dentition, jaws and temporomandibular joint disorders, leading to formation of mesial bite. Clinical features. Diagnostics. Treatment. Mistakes and complications.

**Total time of session:** 7 academic hours.

**Aims and objectives of the lesson.** Students should learn the basics of diagnostics and principles of treatment of mesial occlusion based on the period of bite formation.

**Requirements for the initial level of knowledge.** Student should know:

1. Anatomy of face muscles and bones.
2. Functions of maxillofacial system.
3. Changes occurring in the maxillofacial system in case of impaired respiratory function.
4. Methods of treatment of malocclusion in orthodontics.

**Practical questions from related disciplines:**

1. Permanent teeth eruption timetable
2. Principles of action of functional appliances, indications.
3. Anatomy of face muscles and bones.

**Practical questions:**

1. Definition of mesial occlusion.
2. Etiology of mesial occlusion.
3. Morphological disorders of facial skeleton in patients with mesial occlusion.
4. Principles of treatment of mesial occlusion in primary dentition.
5. Principles of treatment of mesial occlusion during mixed and permanent dentition.
6. Possible mistakes in treatment of mesial occlusion.

Mesial occlusion is an anomaly of dentition in sagittal plane, characterized by the following intraoral symptoms: the mesiobuccal cusp of maxillary first permanent molar is located posteriorly to the mesiobuccal groove of mandibular first molar, upper canine (permanent or primary) is located posteriorly between lower canine and premolar (Fig. 46).

Synonyms for mesial bite are the following terms:

- progenia;
- progenic bite;
- anterior cross bite;

- Angle class III;
- mesioocclusion.

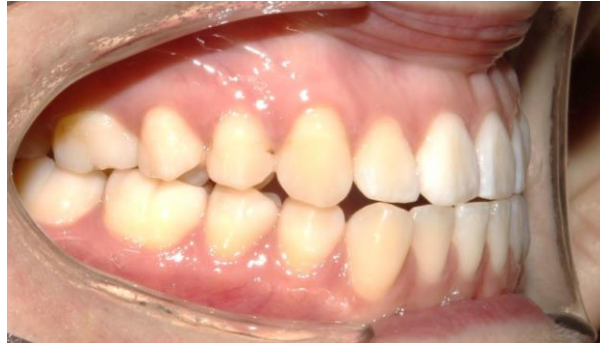

Figure 46. Intraoral symptoms of mesial bite

**The etiology of mesial malocclusion.** Often mesial bite is genetically determined disease: inherited macrognathia of lower jaw or micrognathia of maxilla. Moreover, the cause of development of such pathology can be congenital disorders such as cleft lip or palate, birth injury. Among the acquired factors should note such as anodontia, unerupted teeth on the upper jaw, the presence of supernumerary teeth on the lower jaw, macroglossia, harmful habits (sucking the upper lip, functional shift of the lower jaw, an incorrect position during sleep), impaired abrasion of cusps of primary teeth, inflammation (osteomyelitis), early loss of teeth on the upper jaw.

**Facial features of mesial bite.** Profile of the patient with mesial bite is a concave, lower jaw is protruded, the upper lip sinks, the lower part of the face can be increased (in case of deep anterior cross bite may be reduced), a retrusive nasomaxillary area (Fig. 47, *a*).

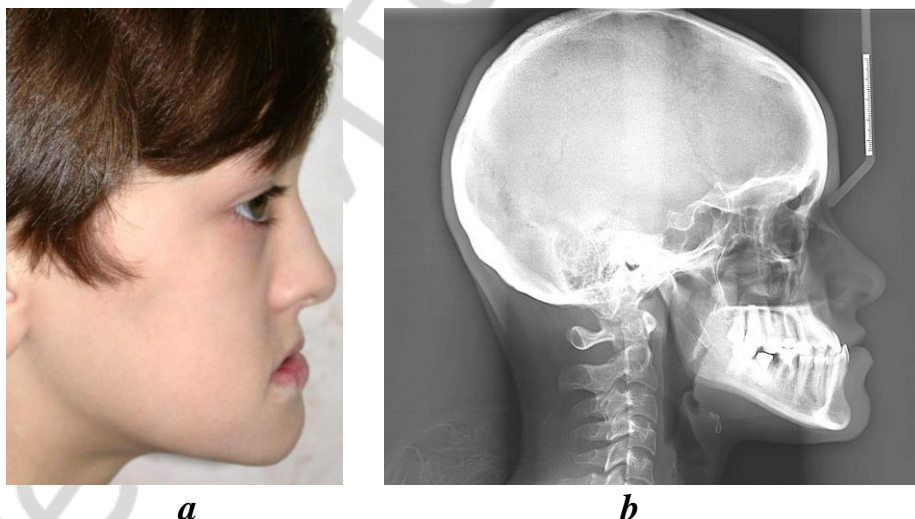


Figure 47. The patient with mesial malocclusion:  
*a* — photo of the face in profile; *b* — lateral cephalogram

Morphological forms of mesial bite:

- dentoalveolar, gnathic, combined;
- with functional shift of lower jaw and without.

**Morphological disorders** in dentition that are typical for mesial bite:

1) *at the level of the jaws*: retro position of the upper jaw (retrognathia of maxilla), reducing the size of the maxilla (micrognathia); anterior position of the mandible (prognathia), increased size of the lower jaw (macrognathia);

2) *at the level of dentition*: shortening of the upper dentition in the anterior segment, lengthening of the lower dentition in the anterior segment;

3) *at the level of the teeth*: mesial displacement of the lower posterior teeth.

**Functional disorders of the dental system with mesial bite.** Patients with mesial bite have problems with biting and chewing of food, impaired swallowing function, articulation of a tongue, pronunciation of sounds.

Diagnosis of different types of mesial bite is based on clinical examination, the results of clinical application of functional tests, measurement of diagnostic models of the jaws and facial photos, analysis of orthopantomograms, analysis of lateral cephalograms of the head (Fig. 47, *b*).

On diagnostic models of the jaws of the patients with mesial malocclusion Nance method, Lundstrom, measurement of the length of the anterior segment of dentition (Korkhaus method), measurement of width of dentition (Pont method), measurement of apical bases of the jaws (Snagina method), Gerlach method can be used.

Lateral cephalograms of the head are used to determine the morphological structure of the facial skeleton disorders, type and period of the facial skeletal growth.

To diagnose dentoalveolar or gnathic forms of mesial malocclusion clinical method is used: if the patient may put the lower jaw posteriorly edge to the edge (incisors) and when the ratio of the first permanent molars becomes close to the neutral occlusion (Angle class I), than we put the diagnose: dentoalveolar form of mesial malocclusion with functional shift of lower jaw.

**The basic principles of treatment with the mesial malocclusion during its development.** Treatment of mesial bite starts at the age of 3–4 years with the elimination of the acquired etiological factors that have contributed to malocclusion.

**The period of primary dentition.** The main task of the orthodontist: create optimal conditions for the growth of the upper jaw, and prevention of the mandible growth.

**Methods of treatment:** the main — using orthodontic appliances, an additional — myotherapy. Less commonly used is complex method of treatment.

The method of treatment depends on the overbite and value of reverse overjet.

1. If the anterior crossbite and overbite under  $\frac{1}{2}$  of the height of lower incisor crowns the primary canines and incisors of both jaws are trimmed and contoured in one or more visits depending on contact with the patient and tooth sensitivity. After trimming of enamel required complex remineralization therapy.

The most effective appliance for the prevention of growth of the mandible in the period of primary dentition is a chin cap therapy with occipital (sagittal) pull (Fig. 48).

When mesial malocclusion combined with protrusion of the lower incisors and impaired functions of the dentofacial system further individual and standard orthodontic plates are used.

2. In the case of deep anterior crossbite the treatment of mesial malocclusion together with trimming of cutting edges of primary incisors and canines of both jaws is advisable to use devices with bite planes (plate on the upper jaw with bite planes). To prevent the growth of the mandible is used a chin cap with occipital pull (Fig. 48).

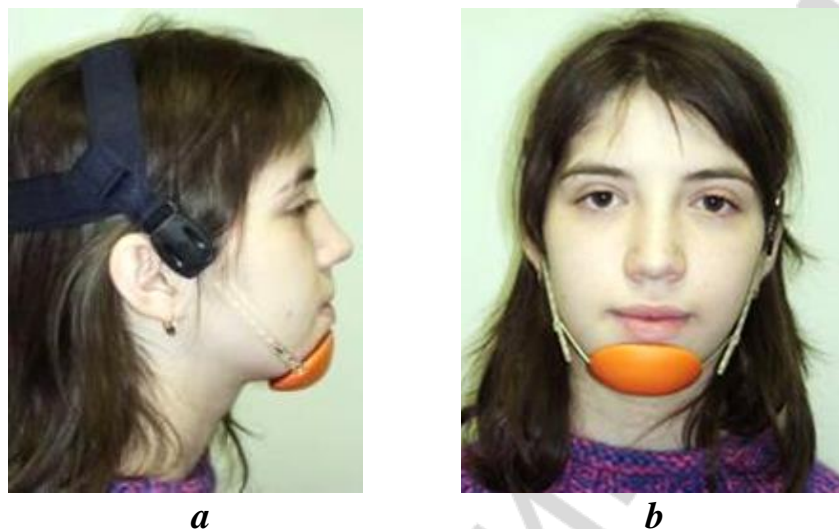


Figure 48. The chin cap with occipital pull:  
*a* — profile; *b* — front view

In cases of reduced adaptation to orthodontic appliances, a complex method of treatment should be used (Nespryadko method): extraction of the primary lower incisors and canines which block the growth of the upper jaw. After extraction of canines and incisors it is recommended to wear a chin cap with sagittal pull to prevent the growth of the lower jaw.

3. In the cases with large reverse overjet between the upper and lower incisors (5 mm) in patients aged 4–5 years sustained positive results can be achieved by using the appliance proposed on the department of pediatric dentistry in MGMI (Fig. 49). The appliance consists of intraoral and extraoral parts. Intraoral part is a plate on the upper jaw with bite planes, in the anterior segment of base plate 2 parts of Angle appliance are installed (Fig. 49, *a*), which protrude from the mouth through the clamping lips. Extraoral part is a chin cap with sagittal pull which prevent the growth of the lower jaw (Fig. 49, *b*, *c*). Intraoral part of the appliance are connected with extraoral by means of metal (steel) tape and segments of Angle arch (Fig. 49, *b*, *c*). Due to the properties of a flexible metal tape occurs optimization of upper jaw growth.

Modern counterparts of the above appliance are facial masks — Delaire mask (Fig. 50, *a*) and Petit mask (Fig. 50, *b*). Face masks are used in conjunction with rapid maxillary expanders on the upper jaw with bite planes and provide optimization of the growth of the upper jaw and lower jaw growth inhibition.

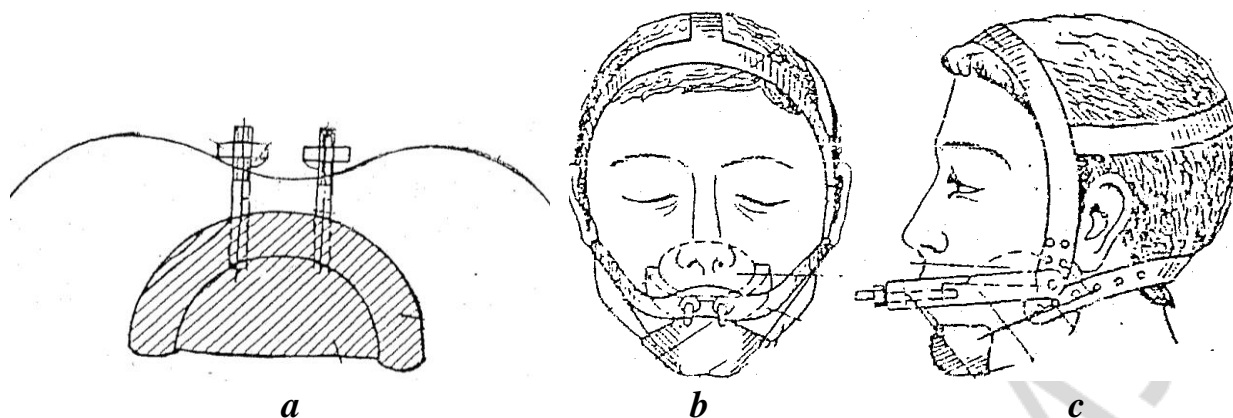


Figure 49. Appliance proposed on the department of Pediatric Dentistry MGMI (Tokarevich–Melnichenko appliance):  
*a* — intraoral part; *b, c* — extraoral parts

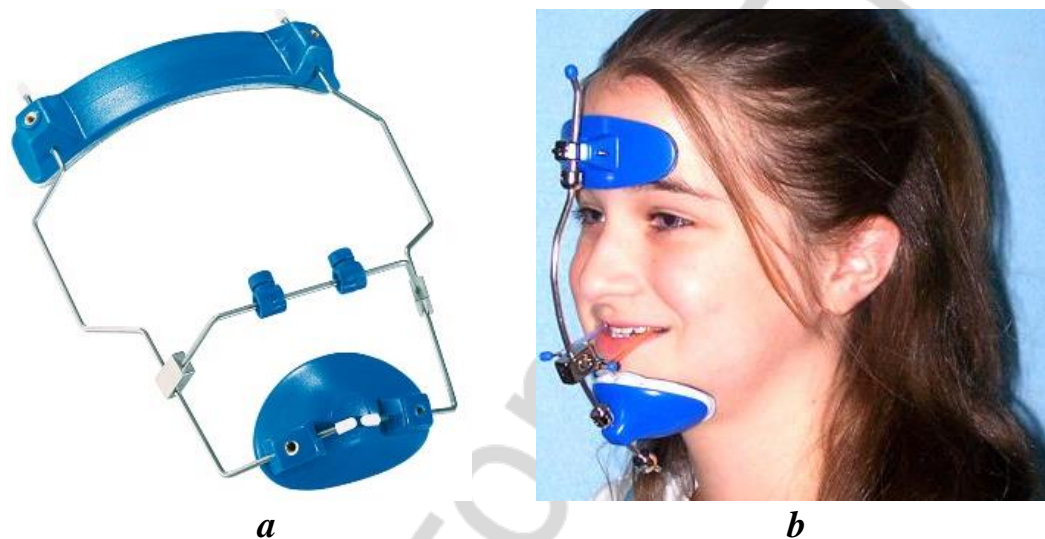

Figure 50. Face masks:  
*a* — Delaire mask; *b* — Petit mask

Optimal duration of wearing of appliances is 8–10 hours a day.  
 For the treatment of mesial malocclusion with significant sagittal discrepancy in children 4–5 years old may be used Frankel clasp activator (Fig. 51).



Figure 51. Frankel activator

Application of plate on the upper jaw with sectoral screw for vestibular moving of the upper incisors, and Brückl appliance (the lower jaw plate with an inclined plane) in a primary dentition is impractical. Despite the fast positive results of treatment in most cases relapse is possible in mixed and permanent dentition. Apical parts of the roots of the vestibular inclined primary upper incisors push the buds of permanent incisors, contributing to their oral eruption.

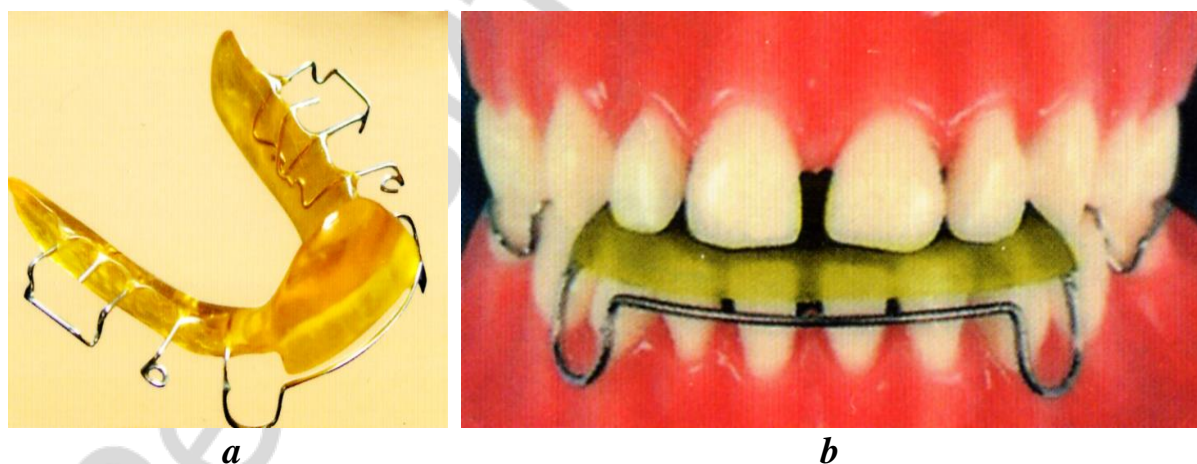
**Period of mixed dentition.** The main task of the orthodontist: optimizing growth of the upper jaw and lower jaw growth inhibition in the sagittal direction.

**Methods of treatment:** the main is application of the orthodontic appliances, an additional — myotherapy. In some cases — complex method.

Mesial malocclusion in this period of development of the dental arches is often associated with cross bite in posterior segment, which is caused by the maxillary deficiency, much more rarely, the constriction of the upper dentition. One common mistake in treatment of such disorders is an expansion of the upper dentition by means of plate with screw or spring. Such manipulations exacerbate disorders in the sagittal direction. Therefore, expansion of the upper dentition must be carried out only after completion of treatment of sagittal disorders or dental Angle class III.

1. In cases with anterior crossbite and overbite under  $\frac{1}{2}$  of the height of lower incisor the primary canines of both jaws are trimmed and contoured in one or more visits depending on contact with the patient and tooth sensitivity. After trimming of enamel complex remineralization therapy is required. For elongation of the anterior segment of the upper dentition and the normalization of the incisive overlap plates with bite planes and screws for moving forward the upper incisors are used.

2. In cases with deep anterior crossbite with overjet under 3 mm is effective Brückl appliance (Fig. 52) providing vestibular deviation of the upper incisors.



*Figure 52. Brückl appliance:  
a — view of the appliance; b — the device on the diagnostic models*

The patient should be taught to have the upper teeth on the inclined plane, without moving the lower jaw forward, and talk without opening the teeth.

Functional shift of lower jaw is possible to treat using two appliances: Brückl appliance with chin cap with sagittal pull. Extraoral device worn 8–10 hours per day, Brückl — all day.

3. For the treatment of mesial malocclusion with significant sagittal discrepancy Frankel activator (Fig. 51) or Vunderer activator with Weise screw (Fig. 53) are recommended.

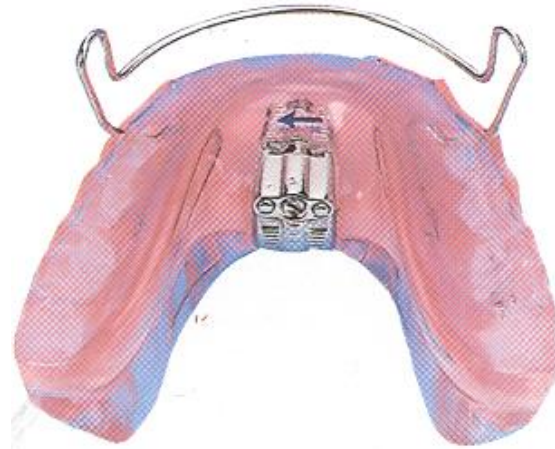


Figure 53. Vunderer activator with Weise screw

To solve the problem of choosing the orthodontic appliance is necessary to assess a patient's ability to put the lower jaw edge to edge (incisors). If the patient can do it, functionally active devices may be used: closed Andresen–Häupl activator, Klammt activator, Frankel type III regulator (Fig. 54), Bimler activator type III. The most widely used is Klammt activator, due to ease of manufacture and relatively quick patient's adaptation.

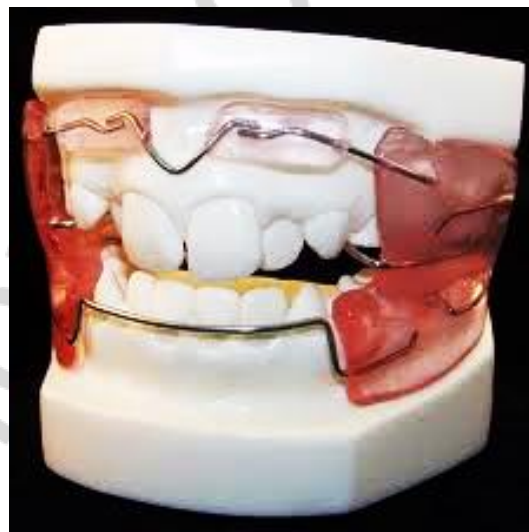

Figure 54. Frankel regulator type III

Cephalometric examination must be done if patients with mesial malocclusion have significant discrepancy in size and position of the jaws (large overjet). In cases where such malocclusion is combined with lower prognathism and or upper micrognathia, upper jaw retro position — it is advisable to use

a complex method of treatment. During the initial mixed dentition (in patients aged from 6 to 9 years) such anomaly can be treated by Hotz method.

**Period of permanent dentition.** The main task of the orthodontist is: to reduce the size of the lower dentition for normalization of relationship between upper and lower jaws (complex method).

**Methods of treatment:** application of orthodontic appliances, complex, surgical.

With minimal reverse overjet (under 5 mm) formed due to the retro position or hypoplasia of upper jaw, the method of treatment with application of orthodontic devices may be used. The most effective devices for patients with such disorders are Frankel's activator or Wunderer's activator with Weise screw. The average duration of treatment of mesial malocclusion in permanent dentition in these patients is the same as in the mixed dentition. One of the most common complications is the formation of an open bite in the posterior segments which disappears in 6–12 months after completion of active orthodontic treatment.

Complex method can be used in clinical cases with significant sagittal discrepancy with the lower jaw prognathism. In complex method of treatment extraction of individual teeth of lower jaw is performed. From the functional and aesthetic point of view the most desirable is extraction of the first premolars. Extraction of second premolars, canines and incisors is rarer.

When you choose a complex method for the correction of mesial malocclusion you should pay attention to the size of the tongue and its position, the position of the lower incisors and the presence of space between them.

Complex method for treatment of mesial malocclusion is not indicated in cases of:

1. Macroglossia — extraction of teeth on the lower jaw significantly reduces volume of the mouth, the tongue exerts increased pressure on the jaw and causing relapse of malocclusion.

2. Presence of space between lower incisors — which can be an indication of macroglossia and mandibular macrognathia. Eliminating of macrognathia by reducing the size of lower dentition is ineffective. In such cases it is advisable to use surgical method of treatment.

4. Significant oral inclination of lower incisors — after extraction of teeth on the lower jaw and further oral inclination of lower incisors, these teeth will not be stable during biting and can be dislocated.

Correction of mesial malocclusion with a complex method of treatment is carried out by mechanically acting, functional and combined appliances. Bracket-system is used most commonly.

In case of mesial malocclusion, coupled with a significant sagittal discrepancy caused by mandibular macrognathia or maxillary micrognathia, it is advisable to use the surgical method of treatment (Fig. 55). The object of the orthodontist in such cases is to normalize the position of individual teeth and form of dentition using a bracket-system before surgery and post-operative correction of dentitions relationship.



After completion of active orthodontic treatment in permanent bite period, for prevention of relapse it is recommended to remove the tooth buds of third molars in the lower jaw. Extraction of third lower molars is made to prevent the lower jaw growth, their eruption may cause relapse of anterior crowding.

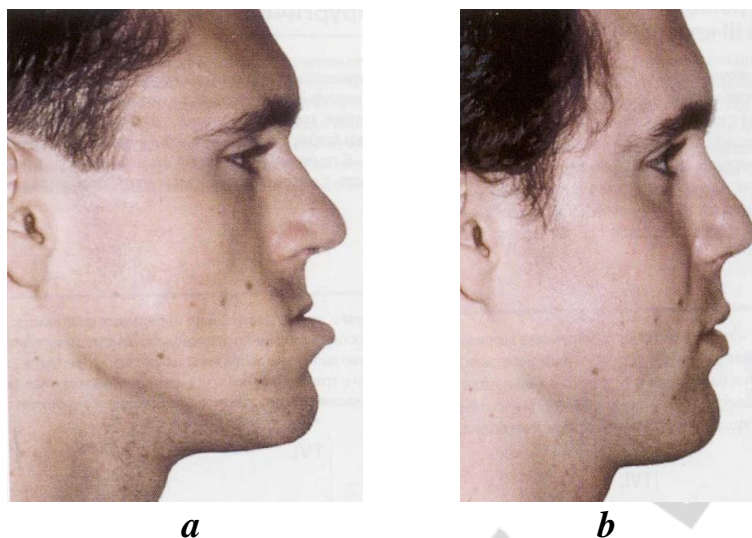


Figure 55. Surgical treatment of mesial malocclusion:

*a* — the profile of the patient before the treatment; *b* — the profile of the patient after treatment

Analysis of the immediate and long-term results of treatment of mesial occlusion in different periods of bite formation, in view of possible variants of clinical manifestations, disturbances in sagittal and vertical planes, identified the following principal approach to the treatment of such anomalies:

1. The choice of treatment and the orthodontic devices in period of primary dentition must be performed depending on the depth of overbite of anterior cross bite. Application of the Brückl appliance in primary dentition is impractical.

2. During mixed dentition the most effective treatment is application of orthodontic appliances — using Frankel activator. When patients are able to put lower incisors in to edge to edge position — functionally active appliances can be used.

3. Complex method of treatment in mixed and permanent dentitions can't be used in cases with lower macrognathia, macroglossia and gaps in between the incisors, with significant oral inclination of lower incisors without crowding.

**The most common mistakes in the treatment of mesial malocclusion include:**

1. Using a chin cap without plates with occlusal pads.
2. Untrimmed cusps of primary canines after completion of treatment, which leads to relapse of the anomaly.
4. At the age of 3–5 years in cases of deep anterior cross bite plates with posterior bite planes are used. The depth of overbite increases.
5. Treatment with Brückl appliance is not combined with wearing of chin cap with a sagittal pull. Patient routinely displaces the lower jaw forward and upper teeth are located behind the inclined plane, the reverse overjet is increased.

6. High inclined plane contacts with palatal cusps of the moving teeth, which leads to open bite.

7. After reaching the positive overjet, no measures are taken to eliminate open bite in posterior region, which leads to overload of anterior teeth and their loosening.

8. Using a chin cap with sagittal pull after completion of jaws growth.

### **TASKS FOR STUDENTS INDEPENDENT WORK**

**1. Methods used for treatment of deep mesial malocclusion with anterior crossbite in primary dentition are:**

- a) a chin cap;
- b) bracket-system with intermaxillary elastics;
- c) Nespryadzko method and wearing a chin cap;
- d) Bruckle appliance.

**2. The contraindications for the application of a combined method for the treatment of mesial bite in permanent dentition are:**

- a) spaced teeth and diastema in the maxilla;
- b) oral inclination of the lower incisors without their close position;
- c) lower macrognathia;
- d) macroglossia;
- e) spaced teeth and diastema between the lower incisors.

**3. The examination method used to determine the type of jaws growth is:**

- a) orthopantomography;
- b) cephalometry;
- c) face-photometry;
- d) clinical examination.

РЕПОЗИВ

## PRACTICAL SESSION 6

### MOTIVATIONAL CHARACTERISTICS OF THE TOPIC

A deep bite is a type of malocclusion in a vertical plane. Timely diagnostics and treatment will prevent the development of other types of anomalies and functional disorders of the maxillofacial region.

**Topic:** Deep bite. Developmental anomalies of teeth, dentition, jaws, leading to formation of deep bite. Etiology. Diagnostics. Treatment. Mistakes and complications.

**Total time of session:** 7 academic hours.

**Aims and objectives of the lesson.** Students should learn the basics of diagnostics and principles of treatment of deep bite based on the period of bite formation.

**Requirements for the initial level of knowledge.** Student should know:

1. Anatomy of face muscles and bones.
2. Functions of maxillofacial system.
3. Changes occurring in the maxillofacial system in case of impaired respiratory function.
4. Methods of treatment of malocclusion in orthodontics.

**Practical questions of related disciplines:**

1. Permanent teeth eruption terms.
2. The principle of action of functional appliances, indications.
3. Anatomy of face muscles and bones.

**Practical questions:**

1. Etiology, clinical features of deep bite.
2. Morphological variations of deep bite.
3. Principles of treatment of deep bite in primary dentition. Mistakes, complications of treatment.
4. Principles of treatment of deep bite in mixed dentition. Mistakes, complications of treatment.
5. Principles of treatment of deep bite in permanent dentition. Mistakes, complications of treatment.

**Educational grants.** A deep bite is a kind of malocclusion in the vertical plane. Timely diagnosis and treatment will prevent the development of other types of anomalies and functional disorders of maxillofacial region.

### DEFINITION, ETIOLOGY, FACIAL FEATURES AND MORPHOLOGICAL DISORDERS

**The deep bite** refers to vertical anomalies and is characterized by the incisive overlap of more than  $\frac{2}{3}$  of the height of the teeth crowns (Fig. 56). Synonymous with the concept of “deep bite” are the following: “decreasing bite”, “traumatic bite”, “deep incisor overlap”.

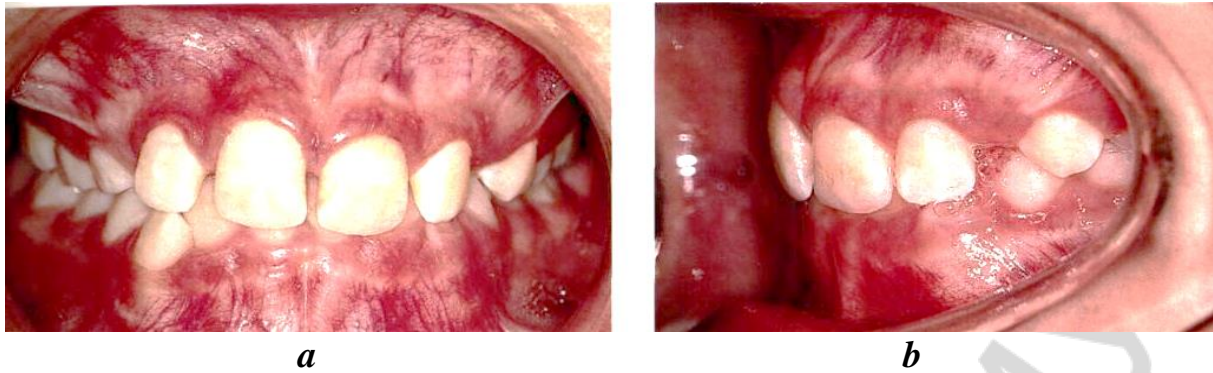


Figure 56. Deep bite:  
a — face; b — profile

### Morphological disorders of the deep bite:

1. At the level of the jaws:
  - 1) rotation of the upper jaw body relative to the transversal axis downwards and forward;
  - 2) rotation of the body of mandible up and backwards;
  - 3) maldevelopment of the jaws: the upper macrognathia, micrognathia of the mandible.
2. At the level of the dentition:
  - 1) dentoalveolar shortening in the posterior segments (intrusion);
  - 2) dentoalveolar lengthening in the anterior jaws (extrusion).
3. At the level of individual teeth:
  - 1) supraposition of lower front teeth;
  - 2) infraposition of upper front teeth;
  - 3) atypical shape of the crowns of the upper incisors.

**Etiology.** The most common cause of deep bite is carious or non-carious lesions of the hard tissues of the posterior teeth, uneven wear, early loss of teeth (temporary molars, first permanent molars). Bad habits sucking and biting fingers, various objects causing the deflection of the front teeth, the disturbance of their proximal contacts with the opposing teeth, which leads to a reduction of the height of the bite, the establishment of the first permanent molars on the wrong occlusal level and the underdevelopment of the alveolar processes of the lateral sections. The disruption of contacts between the anterior teeth causes extrusion in this area. The formation of a deep bite, change in location of anterior teeth, loss of support and extrusion contribute to the disturbance of the functions of breathing, swallowing, speech. To formation of deep bite also leads the presence of supernumerary teeth, diastema, adentia, individual macrodentia and microdentia, shift in timing of eruption of permanent teeth.

Disruption of growth of alveolar processes vertically leads to protrusion or retrusion of the anterior teeth of one or both jaws, shortening the rami of the mandible, reducing the value of its angles.

**Clinical features** of deep bite depend on its combination with neutral, distal or mesial bite. Facial signs can be expressed in the form of shortening of the lower

part of the face, deepening of supramental folds, thickening of the lower lip and associated disorders of distal or mesial bite.

*In cases of a neutral occlusion* the flattening of the dental arches and crowding of anterior teeth or protrusion of upper incisors and retrusion of lower are observed. The cutting edges of the lower incisors sometimes injure the mucosa of the hard palate, and the upper interdental papillae from the vestibular side of the lower teeth and contribute to their detachment.

*In case of a distal bite with protrusion of upper incisors*, the lower ones often injure the mucous membrane of the palate, rarely do not come into contact with it. In cases of *distal bite with retrusion of upper anterior teeth*, dental arches are usually shortened, deep bite — blocking, preventing the growth of the lower jaw. The extension of the lower jaw is limited, which affects the function of chewing.

*In cases of mesial bite* and negative overjet, the shape of the dental arches depends on the location of the teeth, the displacement of the lower jaw.

**Functional disorders of the deep bite** are expressed in reducing the efficiency of chewing, overloading the periodontal tissues of the anterior teeth and, often, in traumatizing the mucous membrane, which contributes to the emergence and development of periodontal diseases, erasing the cutting edges of the teeth, etc.

**Diagnosis.** The diagnosis is based on clinical studies, studies of diagnostic casts and their measurement, the study of the photometry of the person in full face and profile, as well as the lateral cephalometry evaluation data, panoramic x-ray studies of the jaws.

*In the analysis of lateral cephalometry* it is very important to determine the type of growth of the jaws according to the following formula:

$$\frac{S - Go * 100 \%}{N - Me}$$

where S – Go — posterior facial height, N – Me — anterior facial height (Fig. 57).

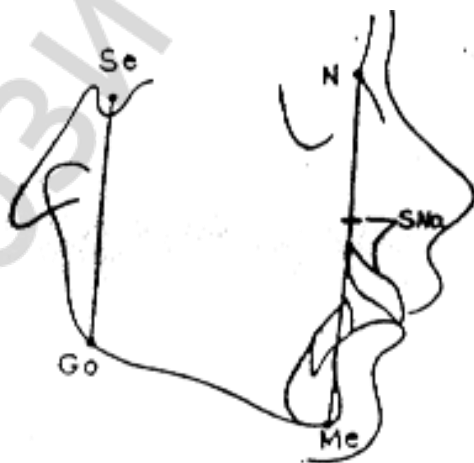


Figure 57. Vertical parameters of skull's facial area

The growth type is considered neutral, when the ratio is equal to 62–65 %. At lower values the growth of the jaws is considered to be vertical, while at higher values — horizontal, which is unfavorable for treatment of deep bite.

## DEEP BITE TREATMENT, INCLUDING THE PERIOD OF BITE FORMATION

Treatment of the deep bite is most effective during the period of eruption of temporary teeth, first permanent molars, changing of temporary incisors with permanent, eruption of second permanent molars.

*The main objectives of treatment* are to eliminate the causes that prevent extrusion in the lateral teeth area, to separate them, to create obstacles to extrusion in the anterior teeth area; to correct the shape of the dental arches, the position of individual teeth and their groups, to normalize the position of lower jaw and jaw's growth.

**During the period of temporary occlusion** it is recommended to teach children to chew solid food, that stimulates the normal development of alveolar processes and dental arches. In the case of caries and destruction of the crowns of deciduous molars, they can be restored using fillings, inlays, replacement of crowns. In the presence of harmful habits of sucking fingers, lips, various objects vestibular plates are used. In case of incorrect attachment of the tongue frenulum, plastic surgery is performed. If temporary molars have been lost early, they have to be replaced with partial dentures.

When it's combined with sagittal malocclusion, the following treatment is recommended:

- 1) oral screen with bite plane for incisors (Fig. 58);
- 2) myotherapy to normalize the function of muscles surrounding the teeth;
- 3) therapeutic exercises to improve posture.

**In period of mixed bite at the age of 5.5 to 8 years old** active orthodontic treatment should be started. The disocclusion of the lateral teeth during the eruption of the first permanent molars contributes to their extrusion to contact with opposing teeth, and therefore the depth of the incisional overlap decreases. In cases of neutral bite, a removable plate for upper jaw with anterior bite plane can be used to separate the lateral teeth (Fig. 59).



Figure 58. Vestibular plate



Figure 59. Plate with a bite plane with and screw

The bite plane should be 2 mm higher than the distance between the teeth in physiological state of rest (4 mm); it should not be smooth, but with the imprints

of the cutting edges of incisors and canines of the lower jaw to eliminate its displacement forward or aside. In case of upper dental arch constriction, absence of gaps between the incisors, their close position, a screw for expansion can be installed to a plate like that. For treatment of distal deep bite, the activator of Andresen–Hauptl (Fig. 60), Klammt’s open activator (Fig. 61), Janson’s bionator (Fig. 62), Muleman’s propulsor (Fig. 63), Frankel’s appliance (Fig. 64) type I and II, preortodontic trainer (Fig. 65) can be used. In treatment of deep mesial bite Bruckles’ appliance (Fig. 66) and a chin cap are indicated.

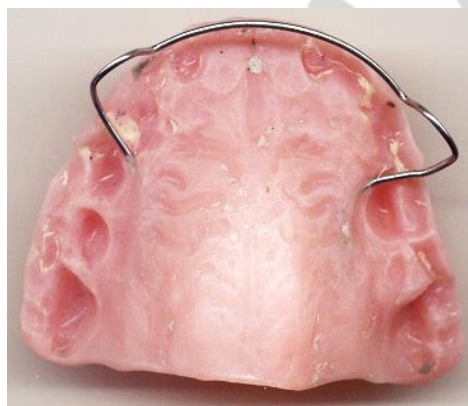
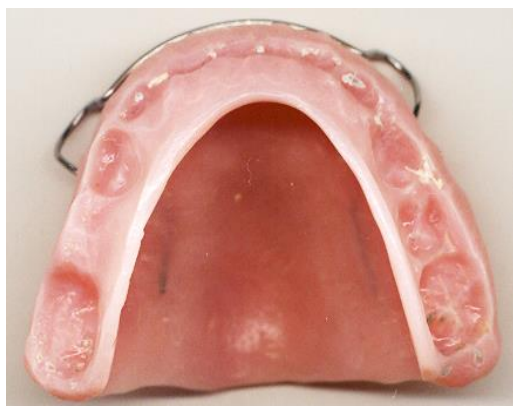
Figure 60. Activator of Andresen–Hauptl

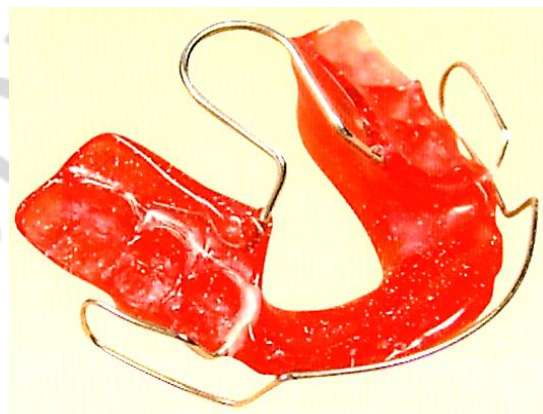
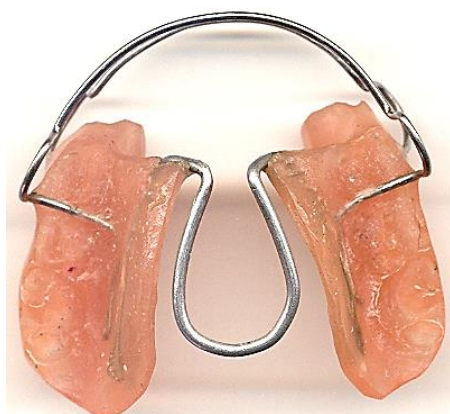
Figure 61. Klammt’s open activator

Figure 62. Janson’s bionator



Figure 63. Muleman’s propulsor

Figure 64. Frankel’s functions regulator



Figure 65. Preorthodontic trainers

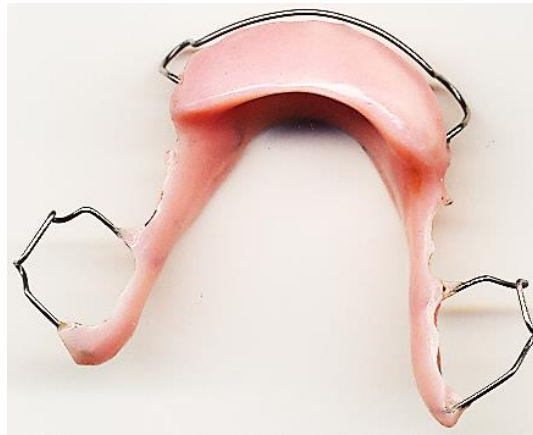
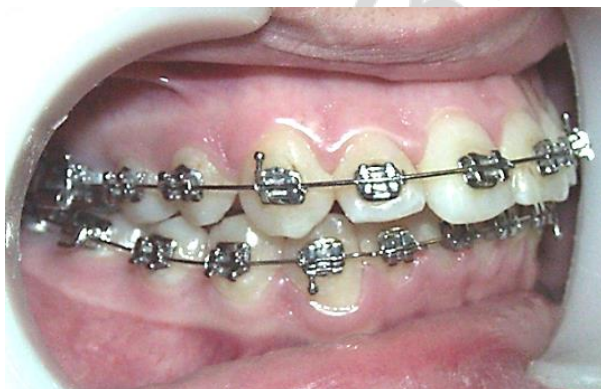
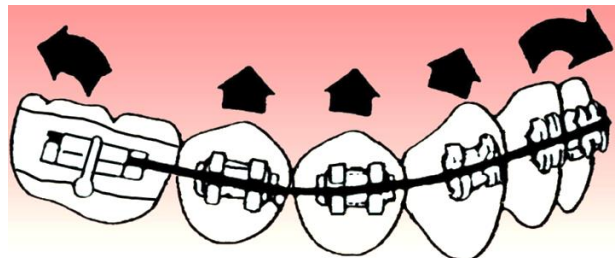
Figure 66. Bruckles' appliance

**In a mixed bite, in its final period, i.e. at the ages of 9 to 12 years old** physiological increase of occlusion is achieved by proper eruption of premolars, canines and incisors. The same appliances as in the previous period are used, as well as non-removable devices (bracket-system) in combination with removable appliances — plate with anterior bite plane.

**In the period of permanent dentition** over the age of 12 years to eliminate the pronounced dentoalveolar anomalies, combined with a deep overbite, bracket-system should be used (Fig. 67).



*a*



*b*

Figure 67. Multibonding system:  
*a* — in the mouth; *b* — scheme of movement of teeth



These appliances are used together with removable plates with anterior bite and inclined planes, and reverse arches for vertical teeth movement. Before starting treatment corticotomy is recommended.

The main methods of prevention and treatment of deep bite are shown in Table 2.

Table 2

The main methods of prevention and treatment of deep bite

The period of bite formation	Methods of prevention and treatment
Temporary bite	<ol style="list-style-type: none"> <li>1. Formation of active chewing.</li> <li>2. Restoration of the destroyed crowns of temporary teeth with fillings, tabs, thin-walled crowns.</li> <li>3. Elimination of bad habits.</li> <li>4. Short tongue tie surgery.</li> <li>5. Replacement of dentition defects with dentures.</li> <li>6. Trimming of unworn cusps of deciduous molars and canines (after 4 years).</li> <li>7. Using oral screens with bite planes.</li> <li>8. Elimination of impaired functions using myogymnastics</li> </ol>
Mixed bite	Combination of the above-mentioned methods with appliance treatment (preortodontic trainers, plates with bite or inclined planes, Frenkel's functions regulator type I and II, Klammt's activator, Janson's bionator)
Permanent bite	<ol style="list-style-type: none"> <li>1. Appliances:               <ol style="list-style-type: none"> <li>a) functionally acting and functionally directing appliances until the end of active growth of the jaws;</li> <li>b) mechanically acting devices: removable and non-removable, including braces.</li> </ol> </li> <li>2. A combination of instrumental methods with surgical.</li> <li>3. Prosthetic method.</li> <li>4. Surgical method.</li> <li>5. Complex method</li> </ol>

**The prognosis of treatment** is preferable if it is taken in the initial period of changing teeth, and during treatment not only morphological, but also functional disorders are eliminated, and deep bite is not a genetic feature with a horizontal type of jaw growth. The duration of the retention depends on the period of bite formation, the use of functional or mechanical devices. After multiple contacts between the dentitions are achieved with the help of an activator, bionator, function regulator, the retention period is not required. If the treatment is carried out by mechanically acting apparatus and functional disorders are not completely eliminated, the retentive appliance should be used. The duration of use of devices is individual, on average it is equal to the period of active orthodontic treatment.

In the treatment of deep bite the following **mistakes** occur:

1. Treatment of deep bite with plates with bite planes in anterior area in cases of teeth crowding. To achieve a positive result, it is necessary to eliminate crowding of teeth by extension of the dental arch or extraction of individual teeth.

2. Elimination of protrusion of incisors leads to deepening of overbite, which should be considered when planning the treatment in different periods.

## TASKS FOR INDEPENDENT WORK OF STUDENTS

**1. The orthodontic appliance used for treatment of deep bite with anterior crossbite is:**

- a) Bruckle's appliance;
- b) a plate for maxilla with bite plane;
- c) a plate for lower jaw with a screw.

**2. It is advisable to start active orthodontic treatment of deep bite at the age of:**

- a) in the period of deciduous teeth;
- b) since its detection;
- c) in the period of permanent teeth;
- d) 5.5 years;
- e) 13 years.

**3. Treatment of protrusion of upper incisors causes:**

- a) a deep bite;
- b) an open bite.

РЕПОЗИТОРИЙ

## PRACTICAL SESSION 7

### MOTIVATIONAL CHARACTERISTICS OF THE TOPIC

Open bite is a type of malocclusion in a vertical plane, characterized by the vertical gap. Timely identification and correction of the etiological, pathogenetic factor contribute to the self-regulation of open bite and help to prevent the development of other types of anomalies and functional disorders of the maxillofacial region.

**Topic:** Open bite. Developmental anomalies of teeth, dentition, jaws, leading to formation of an open bite. Etiology. Diagnosis. Treatment. Mistakes and complications.

**Total time of session:** 7 academic hours.

**Aims and objectives of the lesson:**

Students should learn the basics of diagnostics and principles of treatment of open bite based on the period of bite formation.

**Requirements for the initial level of knowledge.** Student should know:

1. Infantile and somatic types of swallowing.
2. Periods of bite formation.
3. Methods of treatment of malocclusion in orthodontics.

**Practical questions of related disciplines:**

1. Indications for using of mechanical active orthodontic appliances.
2. The principle of action of functional appliances, indications.
3. Appliances for retention.

**Practical questions:**

1. Etiology, clinical features of open bite.
2. Morphological variations of open bite.
3. Principles of treatment of open bite in primary dentition. Mistakes, complications of treatment.
4. Principles of treatment of open bite in mixed dentition. Mistakes, complications of treatment.
5. Principles of treatment of open bite in permanent dentition. Mistakes, complications of treatment.

Open bite (Fig. 68) refers to vertical abnormalities of the occlusion and is characterized by the presence of a vertical gap between the teeth in the central occlusion; often occurs in the anterior part of the dental arches (symmetrical, asymmetric or in the lateral segments — bilateral, unilateral). The absence of contact between the teeth can be observed in the area of the incisors and canines, rarely has a greater length, when the incisors, canines, premolars, sometimes single molars do not contact. In this case, only the posterior teeth are in contact.

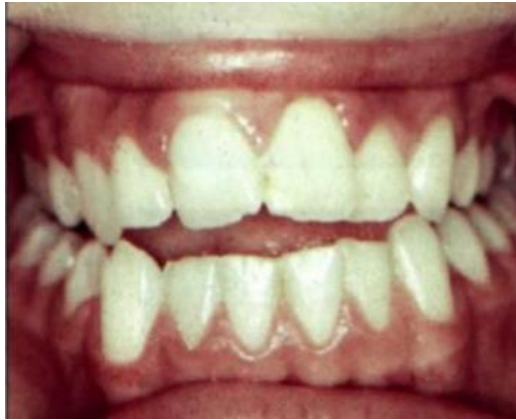

Figure 68. Anterior open bite

**The etiology of open bite.** Open bite can be caused by:

- 1) dysplasia of the jaws with unfavorable heredity;
- 2) congenital pathology (illness of the mother during pregnancy, improper position of the fetus, birth trauma);

3) acquired pathology due to the influence of local factors (sucking fingers, tongue, lips, pencils and other objects, sleep with the head thrown back, placing the tongue in the defect of the dentition after early loss of temporary teeth). Important is the difficulty of nasal breathing, forcing to keep the mouth open, the wrong position with the laying of the tongue between the dentition. The increase in pharyngeal tonsils promotes the displacement of the tongue forward, its incorrect position and the development of an open bite. The shortened frenulum of the tongue makes it difficult to move, which leads to an incorrect position of the tongue.

Speech impairment (improper articulation of the tongue with surrounding tissues contributes to under-eruption of the teeth and the formation of an open bite in the anterior segment of the dental arches). The size and shape of the tongue, available during the period of embryonic development of the oral cavity, can predetermine the development of an open bite, most often in the lateral segments.

Open bite can develop at different age periods. It can be observed in patients with normal sagittal relationship, and also accompany distal and mesial bite. The degree of severity of anomalies is determined by the magnitude of the vertical gap: 1<sup>st</sup> degree — up to 5 mm, 2<sup>nd</sup> degree — 5–9 mm, 3<sup>rd</sup> degree — more than 9 mm.

**Morphological disorders specific for open bite:**

I. At the level of the jaws:

1. Rotation of the body of upper jaw relative to transversal axis up and forward.
2. Rotation of the body of lower jaw down and backward.

II. At the level of the dentition:

1. Extrusion of teeth in the posterior segments of the upper and lower arches.
2. Intrusion of incisors and canines.
3. Supraocclusion of the lower teeth.
4. Infraocclusion of the upper posterior teeth.

If there is a gap of 8.0 mm or more between the incisors, the shape of the face is usually distorted, the lower part prevails over the middle and upper, the upper lip is shortened, and the tongue is visible. The angle of the lower jaw is more than 135 degrees. If the lips are closed, the face looks strained. When the open bite is combined with the distal or mesial, the facial features are characteristic of both types of the bite.

An open bite is accompanied by a narrowing of the dental arches, crowding of anterior teeth, and hypoplasia of enamel is often observed.

When the bite is open, eating, chewing, swallowing, speech functions are impaired, breathing changes, which causes dryness of the mucous membrane.

**Management of open bite.** The main goals of the treatment are elimination of dysfunctions, preventing extrusion in the region of the anterior segments, their disocclusion, creation of an obstacle for extrusion in the region of the posterior teeth; correction of shape of the dental arches, position of individual teeth and their groups, normalization of position of lower jaw and the growth of the jaws.

*Primary dentition:*

1. Myotherapy for circular muscle of the mouth and other muscles, depending on the types of pathology.

2. Normalization of function of swallowing, breathing, elimination of bad habits.

3. Surgery of tongue frenulum.

4. Oral screens (Fig. 69), positioners, function regulators.

5. Chin cap with high pull.

When combined with sagittal anomalies of occlusion, it is recommended:

1) oral screen with a bite pad for incisors;

2) therapeutic gymnastics for normalization of function of the muscles surrounding the dentition;

3) therapeutic gymnastics to improve posture.



Figure 69. MUPPY plate with tongue stop

*Mixed dentition:*

1. Combination of myotherapy with the appliances.

2. Preorododontic trainers (Fig. 70).

3. Appliances (plates with tongue locks (Fig. 71), plates with occlusal pads, function regulators).

4. Disocclusion of the anterior teeth — removable plate on the upper jaw with bite pad.
  5. Andresen activator, Klammt, Janson bionator.
  6. Frankel's function regulator (Fig. 72).
- At the end of the period of mixed bite — fixed app.
7. Frankel's activator (Fig. 73).
  8. Complex method.




Figure 70. Preorthodontic trainers

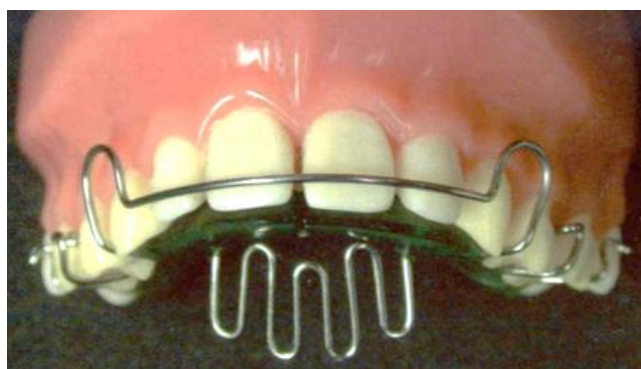

Figure 71. Upper base plate with tongue stop

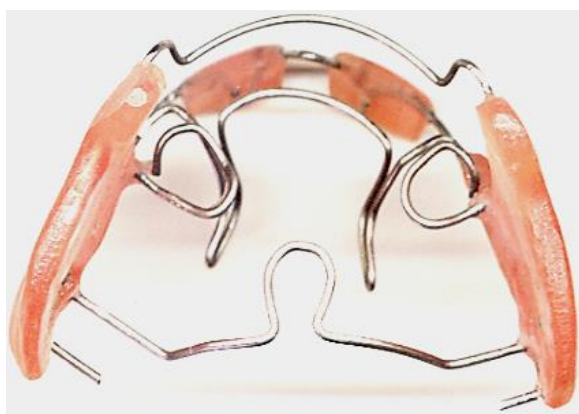

Figure 72. Frankel's function regulator

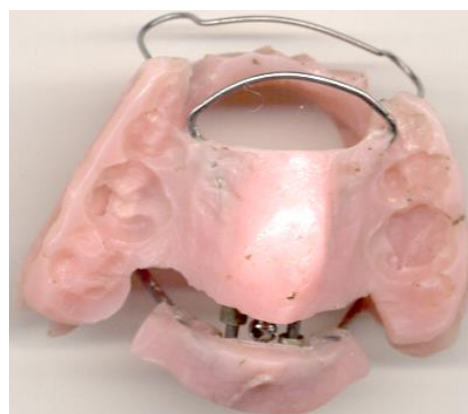

Figure 73. Frankel's activator

*Permanent dentition:*

1) appliances:

- functionally acting and functionally directing devices until the end of active growth of the jaws;
- mechanical: removable and fixed (Fig. 74);

- 2) complex method;
- 3) prosthetic method;
- 4) surgical method.

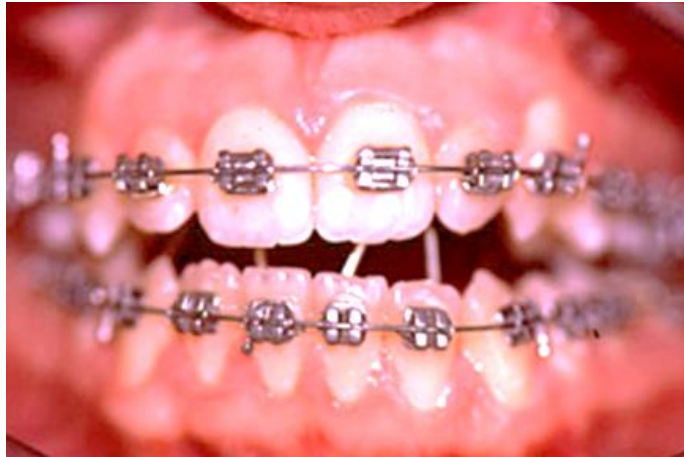

Figure 74. Multibonding system combined with tongue stop

## TASKS FOR INDEPENDENT WORK OF STUDENT

### 1. Anomalies of teeth position in vertical plane are:

- a) tooth rotation around its longitudinal axis;
- b) vestibular or oral position of the front teeth;
- c) mesial or distal position of posterior teeth;
- d) superposition of tooth;
- e) infraposition of tooth.

### 2. Etiology of open bite:

- a) bad habits;
- b) fluorosis;
- c) hereditary factors.

### 3. Classification of open bite:

- a) 1<sup>st</sup> degree — less than 5 mm;
- b) 3<sup>rd</sup> degree — more than 7 mm;
- c) 2<sup>nd</sup> degree — 5–7mm;
- d) 4<sup>th</sup> degree — 9–12 mm.

## PRACTICAL SESSION 8

### MOTIVATIONAL CHARACTERISTICS OF THE TOPIC

Crossbite is a type of malocclusion in a horizontal plane. Occurrence of crossbite is connected with other anomalies and functional disorders of the maxillofacial region. Knowing diagnostics, prevention and treatment of this disease is one of the basic requirements of a qualified dental practitioner. Timely identification and correction of the etiological, pathogenetic factor contributes to the self-regulation of crossbite and helps to prevent the development of other types of anomalies and functional disorders of the maxillofacial region.

**Topic:** Crossbite, etiology, pathogenesis, clinical features, diagnosis, treatment. Mistakes and complications.

**Total time of session:** 7 academic hours.

**Aims and objectives of the lesson.** Students should learn the basics of diagnostics and principles of treatment of crossbite based on the period of bite formation.

**Requirements for the initial level of knowledge.** Student should know:

1. Infantile and somatic types of swallowing.
2. Periods of bite formation.
3. Methods of treatment of malocclusion in orthodontics.

**Practical questions of related disciplines:**

1. Indications for use of mechanically active orthodontic appliances.
2. The principle of action of functional appliances, indications.
3. Appliances for retention.

**Practical questions:**

1. Definition of crossbite, synonyms, etiology.
2. Classification of crossbite.
3. Morphological, functional and aesthetic disorders in crossbite.
4. Differential diagnosis of crossbite with and without mandibular shift.
5. Treatment of crossbite without mandibular shift.
6. Treatment of crossbite with the mandibular shift.

**Lecture materials.** Crossbite refers to anomalies in the horizontal plane. Various definitions are applied to characterize the crossbite: asymmetrical, vestibular occlusion, buccal occlusion, lingual occlusion, posterior forced bite and others.

The development of cross bite may be associated with the following **causes:**

I. Heredity (violation of the position of the jaws relative to the base of the skull is inherited).

II. Congenital pathology:

A. Congenital malformations of the facial skeleton (cleft upper lip, alveolar process, hard and soft palate, facial hemiatrophy).

B. Congenital malformations of the spine (scoliotic spinal deformity).

C. Congenital pathology of the TMJ.



D. Birth trauma.

E. Incorrect placement of the buds of the teeth and their retention;

F. Macroglossia.

III. Acquired pathology:

1. General factors: rickets, osteomyelitis, poliomyelitis, postural abnormality.

2. Local factors: dento-facial system disorder, bad habits (supporting the cheeks with the hand; sucking the fingers, cheeks, tongue, etc.) the position of the child during sleep, sequence disorder of teeth eruption, unworn cusps of temporary teeth, early destruction and loss of temporary molars.

Among the etiological factors, special attention should be paid to diseases of the temporomandibular joint, such as ankylosis and arthritis of various etiologies. The causes of arthritis can be different:

1. Traumatic inflammation of the joint.

2. Acute and chronic purulent otitis.

3. Infectious arthritis.

4. Hematogenous osteomyelitis of the articular process.

The variety of etiological factors creates difficulties for diagnosis and, therefore, for the prevention and orthodontic treatment of cross bite.

**Crossbite classification:**

I. Buccal — when the jaws are closed in the central occlusion buccal tubercles of the lower posterior teeth are placed buccally to the long fissures (Fig. 75).

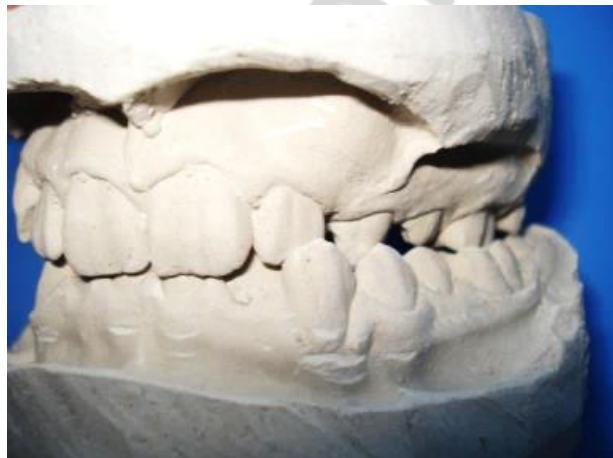

Figure 75. Buccal crossbite left

II. Lingual — when the jaws are closed in the central occlusion buccal tubercles of the lower posterior teeth are placed lingually to the long fissures (Fig. 76, b).

Buccal and lingual types of cross bite can be **with the displacement of the lower jaw** (Fig. 77, a) and **without the displacement of the lower jaw** (Fig. 77, b).

III. Combined (buccal-lingual) cross bite.

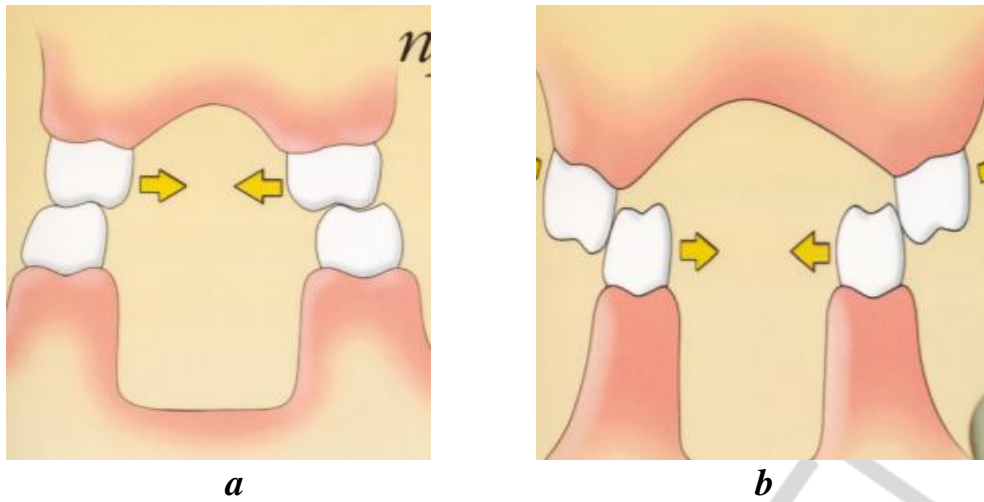


Figure 76. Types of crossbite:  
*a* — buccal; *b* — lingual

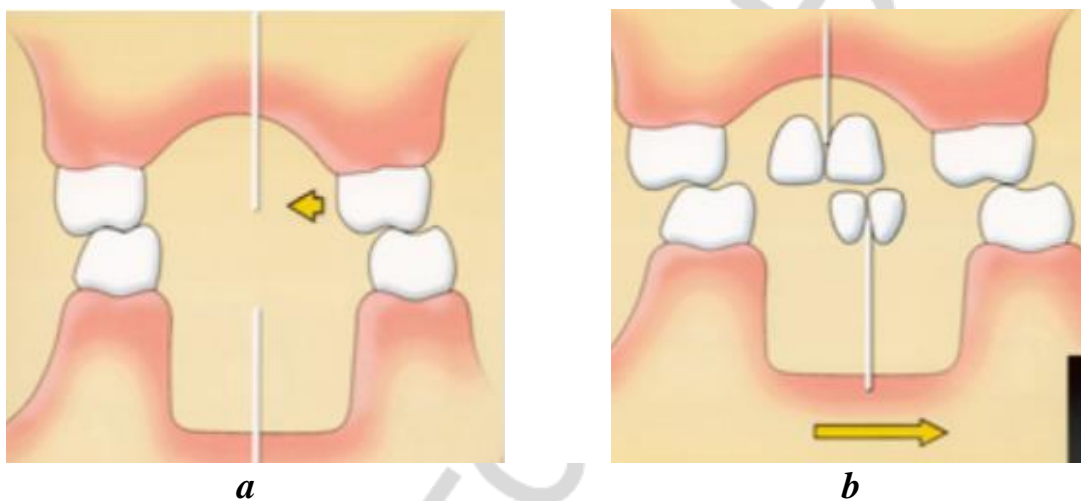


Figure 77. Types of crossbite:  
*a* — without displacement of the mandible; *b* — with displacement of the mandible

There are the following **morphological forms of crossbite**:

- 1) dento-alveolar — narrowing or expansion of the dento-alveolar curve on one or both jaws;
- 2) gnathic — narrowing or widening of the basis of the jaw (underdevelopment, excessive development);
- 3) articular — displacement of the lower jaw to the side (parallel midsagittal plane or diagonal).

**Morphological abnormalities in crossbite:**

1. At the jaw level:
  - a) rotation of the body of the upper jaw relative to the vertical axis to the left or to the right; rotation of the body of the low jaw is inadequately relative to the upper jaw;
  - b) unilateral underdevelopment and/or excessive development of the upper or lower jaw.

2. At the level of the dentition:

- a) unilateral lengthening or shortening of the upper or lower dentition;
- b) unilateral narrowing or expansion of the upper or lower dentition;
- c) unilateral narrowing or expansion of the upper or lower dentition.

3. At the level of individual teeth: vestibular position of buccal teeth on one jaw with oral position of the buccal teeth of the other jaw.

In patients with crossbite chewing and speech function are impaired. The external examination of the patient with cross bite often reveals facial asymmetry.

**Differential diagnosis of forms of crossbite with the displacement of the lower jaw and without displacement of the mandible:**

Symptoms of crossbite without lower jaw displacement:

1. Facial asymmetry is absent or not severe.  
2. Type of occlusion in sagittal plane — I, II, III Angle's class is the same on both sides.

3. Type of occlusion in horizontal plane: 1) Buccal bite (unilateral or bilateral); 2) Lingual bite (unilateral or bilateral).

4. Dentitions — Narrowing or expansion of one dentition.

5. Midline is retained or may not match.

**Crossbite with mandible displacement:**

1. Facial asymmetry is severe.

2. Type of occlusion in sagittal plane:

a) on one side — I Angle's class, on another side — II or III class;

b) on one side — II Angle class, on another side — II Angle class.

3. Type of occlusion in horizontal plane: on one side is buccal on another it is lingual bite.


4. Dentitions — defects of dentitions shape is not characteristic.

5. Midlines do not coincide.

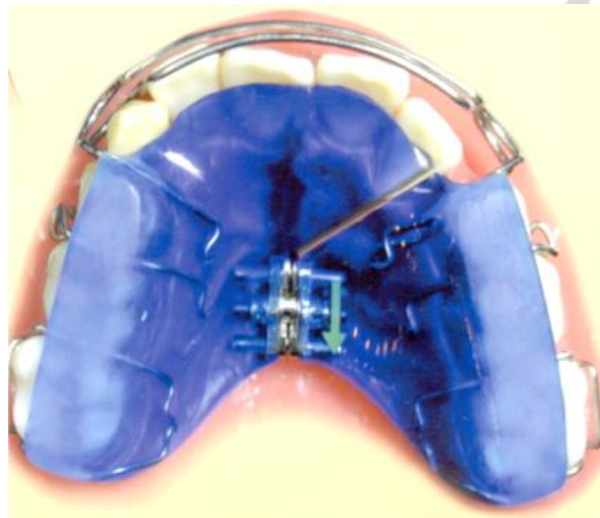
**Treatment of crossbite without displacement** of the lower jaw.

**In the temporary bite**, the orthodontist's task is to normalize the shape of dentitions by creating optimal conditions for growth and development of the jaws. The main method of treatment is myotherapy, an additional one is instrumental. Treatment includes elimination of the cause of anomaly, combating bad habits, trimming of cusps of first primary molars and canines, normalization of lips closing, prosthetics with early loss of temporary teeth. Standard or individual oral screens are used to eliminate pressure of cheeks on underdeveloped areas of jaws (Fig. 78).

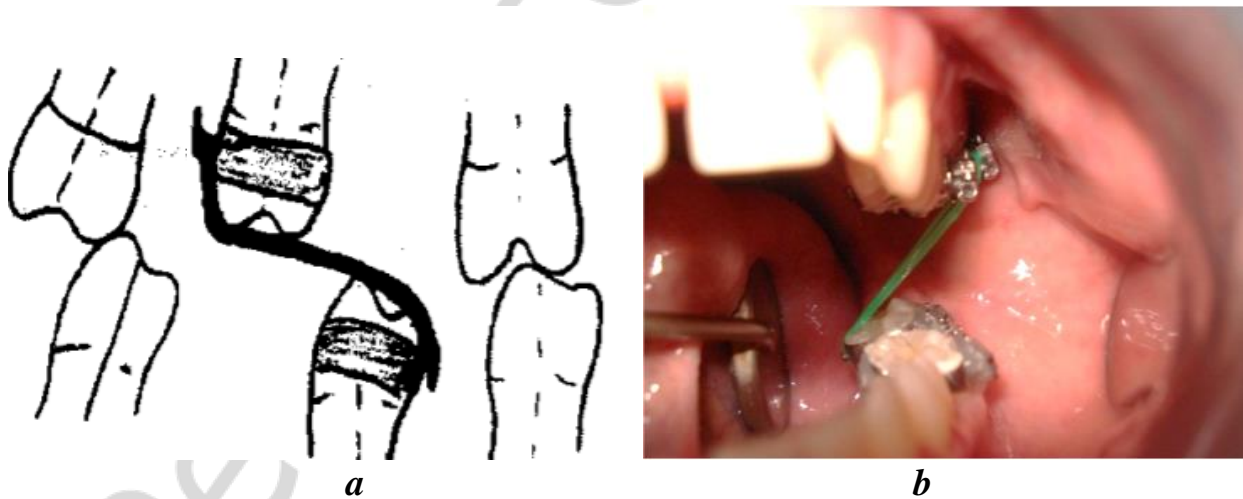
**In mixed dentition**, the task of treatment is the normalization of the shape of the dentition, that caused the formation of cross bite. The main method of treatment is orthodontics, an additional method is myotherapy. In addition to the above measures, mechanical instruments are widely used: plates on the upper jaw with occlusal pads and a screw, a sectoral split (Fig. 79); plates with occlusal pads and a screw for uneven expansion of upper or lower dentition; bands with hooks on first permanent molars and cross elastics (Fig. 80); trimming of cusps of temporary teeth.



*Figure 78. Standard oral screens:  
a — Shonher; b — Muppy with bite plate, c — Muppy with a wire stop for the tongue*



*Figure 79. Base plate on the upper jaw with occlusal pad and screw, sectoral split*



*Figure 80. Bands with hooks on the first permanent molars and cross elastic:  
a — schema; b — view in the oral cavity*

In the period of **permanent occlusion** the main methods of treatment are complex and instrumental. In this period dentists most widely use fixed mechanical devices (multibonding system, Derichsweiler apparatus, Quad Helix

and Bi Helix apparatuses (Fig. 81). Based on indications compactosteotomy is carried out in the area of replaced teeth followed by the use of mechanical orthodontic instruments.

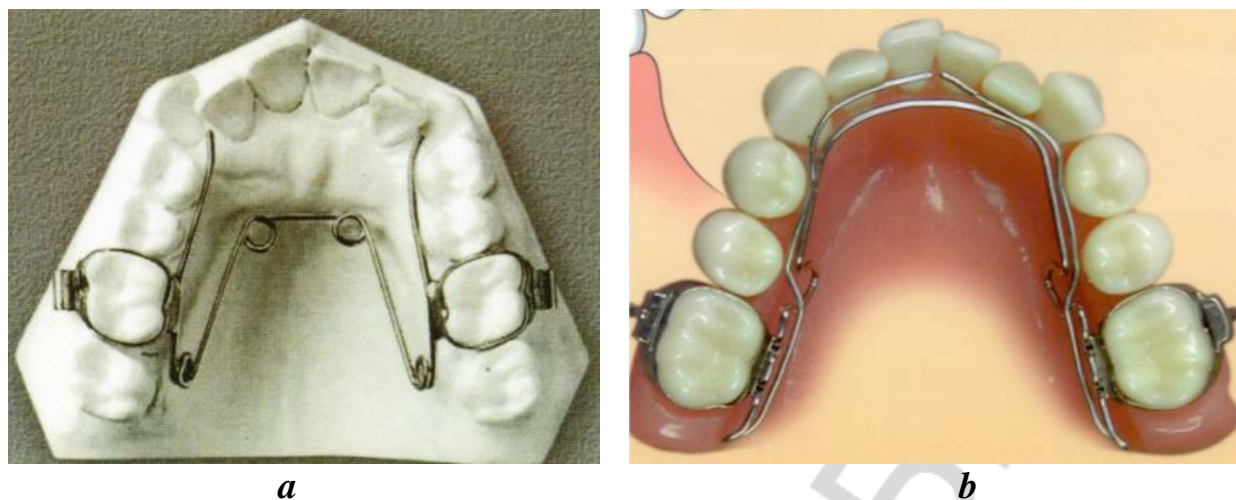


Figure 81. Mechanical devices for expansion:  
*a* — Quad Helix; *b* — Bi Helix

### TREATMENT OF CROSSBITE WITH DISPLACEMENT OF LOWER JAW

In **temporary bite**, the tasks of orthodontic treatment are the following:

1. Creating optimal conditions for the growth of the jaws.
2. Control of the growth of the lower jaw with a combination of crossbite with mesial bite. The main method of treatment is instrumental, an additional one is myotherapy. The solution of these problems is achieved by the use of functionally acting (vestibular plates, activators and regulators of functions) and functionally directing appliances (plates on the upper or lower jaw with inclined plane in buccal areas).

Treatment begins with elimination of the cause of anomaly. For the treatment chin cup and unilateral rubber elastic are widely used; trimming of tubercles and cutting edges of temporary teeth; myotherapy.

In **mixed bite**, the task of orthodontic treatment is normalization of the bite due to the displacement of the lower jaw in the correct position. The main method of treatment is instrumental, an additional one is myotherapy. Treatment begins with the normalization of the shape of the dentitions. This is achieved using single-jaw plates with screws and springs. After that use monoblock apparatus with functional actions (Frankel's functional regulators, Janson's bionator, Klammt's activator).

During periods of active growth of the jaws, in addition to functionally acting appliances, functionally directing appliances are also used (plates with inclined plane and occlusal pads).

In the period of **permanent occlusion** the main methods of treatment are instrumental and complex. In addition to the apparatus used in the mixed bite, bracket system with oblique rubber elastics can be used.

The first premolars are removed in the upper jaw on the side of II Angle class, on the lower jaw — on the side of III Angle class.

**The prognosis of crossbite** treatment is favorable mainly after the early elimination of the dentoalveolar crossbite forms, including those combined with displacement of the lower jaw. In the treatment of permanent bite such an anomaly can be eliminated, but preservation of facial asymmetry is not excluded. Prognosis of orthodontic treatment of gnathic crossbite type is more favorable at the beginning of treatment of a temporary bite. In permanent bite with severe pathology it is possible to eliminate the anomaly only surgically.

The following **mistakes are observed in the treatment of crossbite**:

3. Expansion or narrowing of dentition on the side of crossbite without eliminating of occlusal interference (occlusal pads).

4. Failure to eliminate the displacement of lower jaw in gnathic and articular crossbite forms.

*Table 3*

**The scheme of the approximate basis of action to prevent and treat crossbite**

<b>Periods bite formation</b>	<b>Methods of prevention and treatment</b>
Temporary bite	<ol style="list-style-type: none"> <li>1. Elimination of bad habits, normalization of respiratory function and swallowing.</li> <li>2. Grinding of cutting edges of temporary canines.</li> <li>3. Myotherapy depending on the specific type of pathology.</li> <li>4. Prosthetics in case of early loss of temporary teeth.</li> <li>5. Positioners, removable bite splints.</li> <li>6. Chin cap with a rubber elastic</li> </ol>
Mixed bite	<ol style="list-style-type: none"> <li>1. Combination of myotherapy with instrumental treatment method.</li> <li>2. Instrumental treatment method (positioners, activators, bite splint with inclined planes, functional regulators, at the end of the period — bracket system in combination with removable devices, etc.).</li> <li>3. Combination of instrumental and surgical methods</li> </ol>
Permanent bite	<ol style="list-style-type: none"> <li>1. The instrumental method (all of the above devices; wide use of bracket system in combination with removable devices).</li> <li>2. Combination of instrumental and surgical methods.</li> <li>3. Prosthetic method</li> </ol>

## **TASKS FOR STUDENTS INDEPENDENT WORK**

### **1. The definition of buccal crossbite is:**

a) buccal cusps of the lower posterior teeth overlap buccal cusps of the upper posterior teeth;

b) buccal cusps of the lower posterior teeth are located medially from the upper longitudinal fissures of the posterior teeth;

c) when teeth are closed in central occlusion the lower incisors overlap the upper ones;

d) when teeth are closed in central occlusion the lingual cusps of the lower posterior teeth overlap the palatal cusps of the upper posterior teeth.

**2. Teeth position anomalies in the horizontal plane are:**

- a) medial or lateral position of the front teeth;
- b) infraposition or supraposition of the teeth;
- c) vestibular or oral position of posterior teeth;
- d) protrusion or retrusion of the front teeth.

**3. The main objectives of an orthodontist in the treatment of crossbite with mandibular displacement during the period of deciduous teeth are:**

- a) to create optimal conditions for the growth of the jaws;
- b) to check the mandibular growth in case of combination of crossbite with mesial bite;
- c) to optimize the mandibular growth;
- d) to check the upper jaw growth.

РЕПОЗИТОРИЙ БГМУ

## CONTENT

Introduction .....	3
Practical session 1 .....	3
Practical session 2 .....	13
Practical session 3 .....	24
Practical session 4 .....	36
Practical session 5 .....	47
Practical session 6 .....	57
Practical session 7 .....	65
Practical session 8 .....	70

РЕПОЗИТОРИЙ БГМУ



Учебное издание

**Токаревич Игорь Владиславович**  
**Хомич Светлана Андреевна**  
**Полещук Анна Павловна и др.**

# **КЛИНИЧЕСКАЯ ОРТОДОНТИЯ**

## **CLINICAL ORTHODONTICS**

Учебно-методическое пособие

На английском языке

В двух частях

**Часть 1**

Ответственный за выпуск И. В. Токаревич  
Переводчики И. В. Токаревич, А. П. Полещук, С. А. Хомич, А. С. Хомич,  
О. Л. Коваленко, М. А. Новик  
Компьютерная вёрстка Н. М. Федорцовой

Подписано в печать 04.09.21. Формат 60×84/16. Бумага писчая «Хероx office».

Ризография. Гарнитура «Times».

Усл. печ. л. 4,65. Уч.-изд. л. 4,54. Тираж 60 экз. Заказ 448.

Издатель и полиграфическое исполнение: учреждение образования  
«Белорусский государственный медицинский университет».  
Свидетельство о государственной регистрации издателя, изготовителя,  
распространителя печатных изданий № 1/187 от 18.02.2014.  
Ул. Ленинградская, 6, 220006, Минск.

Репозиторий БГМУ