

МИНИСТЕРСТВО ЗДРАВООХРАНЕНИЯ РЕСПУБЛИКИ БЕЛАРУСЬ
БЕЛОРУССКИЙ ГОСУДАРСТВЕННЫЙ МЕДИЦИНСКИЙ УНИВЕРСИТЕТ
КАФЕДРА МОРФОЛОГИИ ЧЕЛОВЕКА

Ю. М. МЕЛЬНИЧЕНКО, В. В. ЗАТОЧНАЯ

ЧАСТНАЯ ГИСТОЛОГИЯ

SPECIAL HISTOLOGY

Практикум

Минск БГМУ 2026

УДК 611.018(075.8)-111
ББК 28.705я73
М48

Рекомендовано Научно-методическим советом университета в качестве
практикума 21.05.2025 г., протокол № 9

Рецензенты: канд. мед. наук, доц. кафедры гистологии, цитологии и эмбриологии
Белорусского государственного медицинского университета Н. А. Юзефович; каф.
гистологии, цитологии и эмбриологии Гомельского государственного медицинского
университета

Мельниченко, Ю. М.

М48 Частная гистология = Special histology : практикум / Ю. М. Мельниченко,
В. В. Заточная. – Минск : БГМУ, 2026. – 52 с.

ISBN 978-985-21-2169-9.

Содержит текстовые и графические задания, таблицы для самостоятельной работы студентов.
Предназначен для студентов медицинского факультета иностранных учащихся, обучающихся по
специальности «Стоматология» на английском языке.

УДК 611.018(075.8)-111
ББК 28.705я73

Учебное издание

Мельниченко Юлия Михайловна
Заточная Валентина Владимировна

ЧАСТНАЯ ГИСТОЛОГИЯ
SPECIAL HISTOLOGY

Практикум

На английском языке

Ответственный за выпуск С. Л. Кабак
Компьютерная вёрстка А. В. Янушкевич

Подписано в печать 04.02.26. Формат 60×84/8. Бумага «Снегурочка».
Ризография. Гарнитура «Times».

Усл. печ. л. 6,04. Уч.-изд. л. 2,7. Тираж 70 экз. Заказ 90.

Издатель и полиграфическое исполнение: учреждение образования
«Белорусский государственный медицинский университет».

Свидетельство о государственной регистрации издателя, изготовителя,
распространителя печатных изданий № 1/187 от 24.11.2023.

Ул. Ленинградская, 6, 220006, Минск.

ISBN 978-985-21-2169-9

© Мельниченко Ю. М., Заточная В. В., 2026
© УО «Белорусский государственный
медицинский университет», 2026

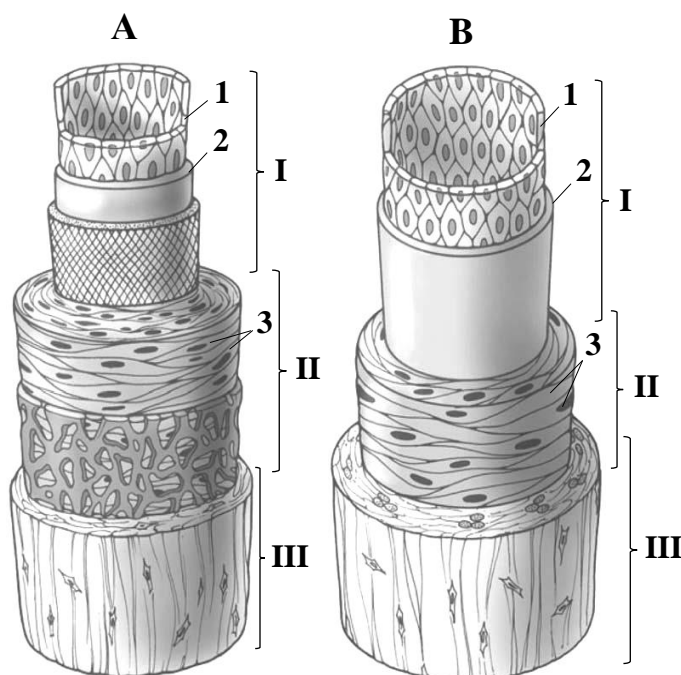
Topic 1. CARDIOVASCULAR SYSTEM. MICROSCOPIC STRUCTURE OF BLOOD VESSELS AND THE HEART WALL

Control questions:

1. Classification of blood vessels. General structural plan of the vessel wall and its embryological origin.
2. Arteries. Classification. The relationship between arterial wall structure and hemodynamic conditions.
3. Veins. Classification. The influence of hemodynamic factors on the structural organization of the venous wall.
4. Microcirculatory bed. Structure and function of arterioles, venules, and capillaries. Structure and significance of arteriovenous anastomoses.
5. Lymphatic vessels. Classification and structural characteristics.
6. Heart. Embryological origins. Histological structure of the cardiac wall layers.
7. Cardiac conduction system: a comparative analysis of the structural and functional characteristics of contractile, conducting, and secretory cardiomyocytes.

MATERIAL FOR INDEPENDENT WORK

BLOOD VESSEL WALL



Name structures, indicated by the numbers:


- I. _____
 II. _____
 III. _____
 1. _____
 2. _____ layer
 3. _____

Color the following structures, using a different color for each:

- internal elastic lamina
 external elastic lamina

Muscular artery (A) and muscular vein (B) (scheme)

MUSCULAR ARTERY AND MUSCULAR VEIN



Draw and indicate the following structures:

I. Tunica intima

1. Endothelium
2. Subendothelial layer
3. Internal elastic lamina

II. Tunica media

4. Smooth muscle cells
5. Elastic fibers

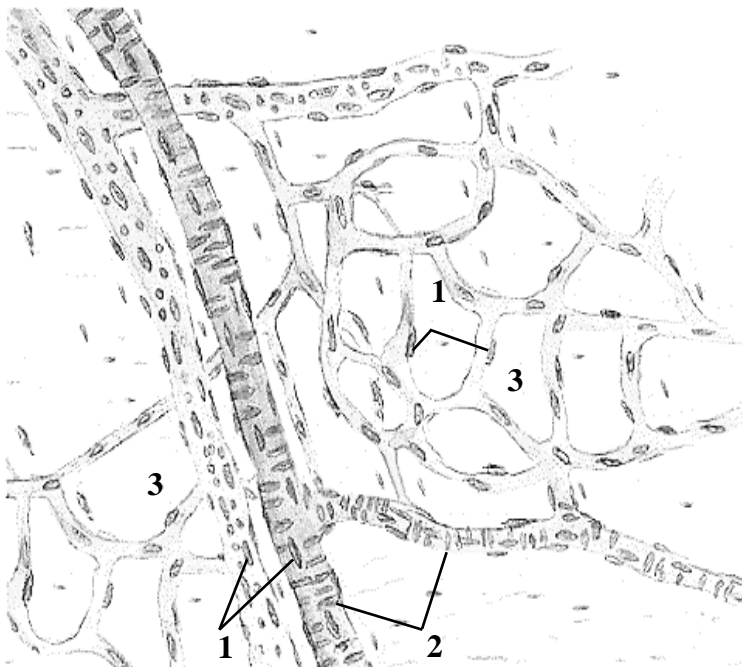
III. Tunica adventitia

6. Nuclei of connective tissue cells
7. Vasa vasorum

Histology slide

*(cross-section of muscular artery and muscular vein,
H&E)*

MICROCIRCULATION



*Color the following structures, using
a different color for each:*

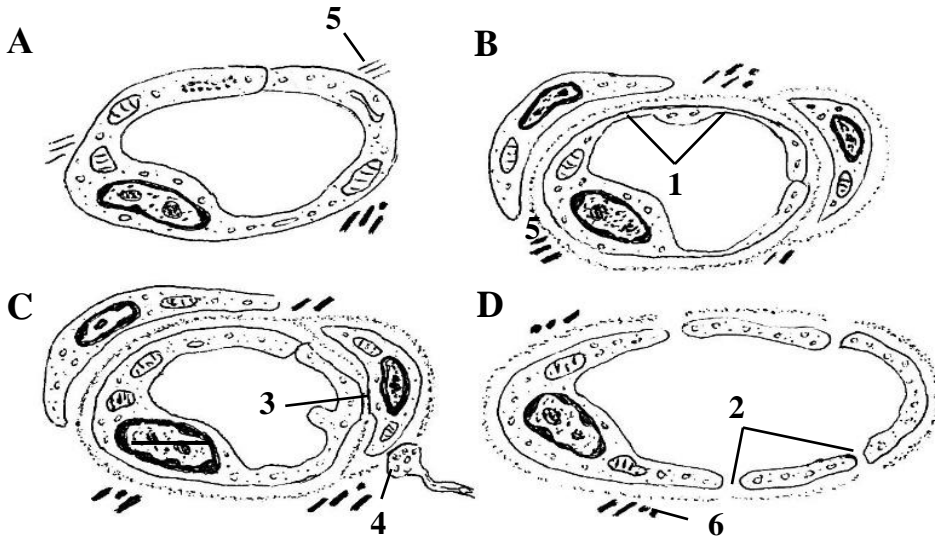
- arterioles
- venules
- capillaries

*Name structures, indicated by the
numbers:*

1. _____
2. _____
3. Loose connective tissue

Arterioles, venules and capillaries in pia mater (scheme)

CAPILLARIES



Color the following structures, using a different color for each structure:

- endothelial cell
- basement membrane
- pericyte
- adventitial cell

Scheme

Name structures, indicated by the numbers and letters:

A. Lymphatic capillary

B. _____

C. _____

D. _____

1. _____

2. _____

3. Contact between endothelial cell and pericyte

4. Nerve ending

5. Anchoring filaments

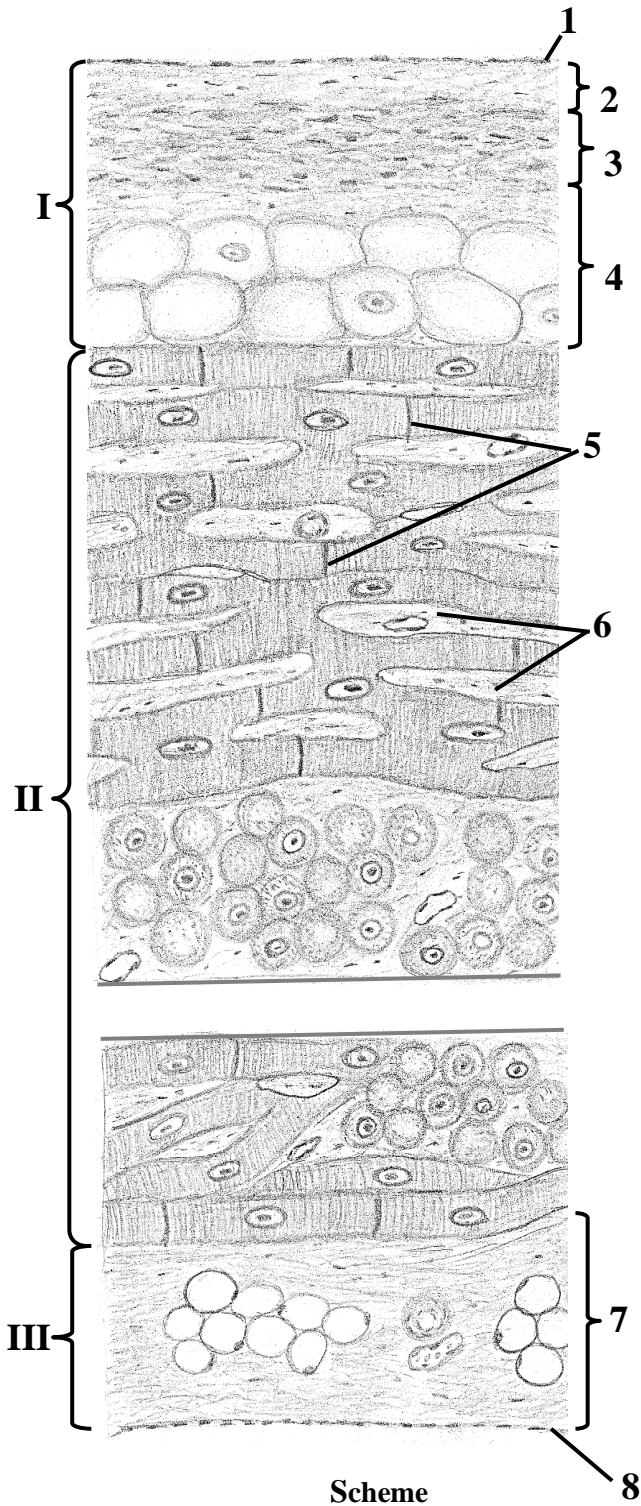
6. Collagen fibers

TISSUE COMPOSITION AND EMBRYONIC ORIGINS OF THE HEART WALL LAYERS

Fill the table:

Layer	Tissue composition	Source of development
Endocardium	1. _____ 2. _____ 3. _____	
Myocardium	1. _____ 2. _____	
Epicardium	1. _____ 2. _____	

VENTRICULAR HEART WALL



Name structures, indicated by the numbers:

- I.** _____
 1. _____
 2. _____ layer
 3. _____
 4. _____ layer
II. _____
 5. _____ discs
 6. Loose connective tissue
III. _____
 (visceral layer of the serous pericardium)
 7. Layer of connective tissue with fat cells
 8. _____

Color the following structures, using a different color for each structure:

- contractile cardiomyocytes
- Purkinje fibers
- fat cells

THE LESSON IS COMPLETED

Teacher _____

« _____ »

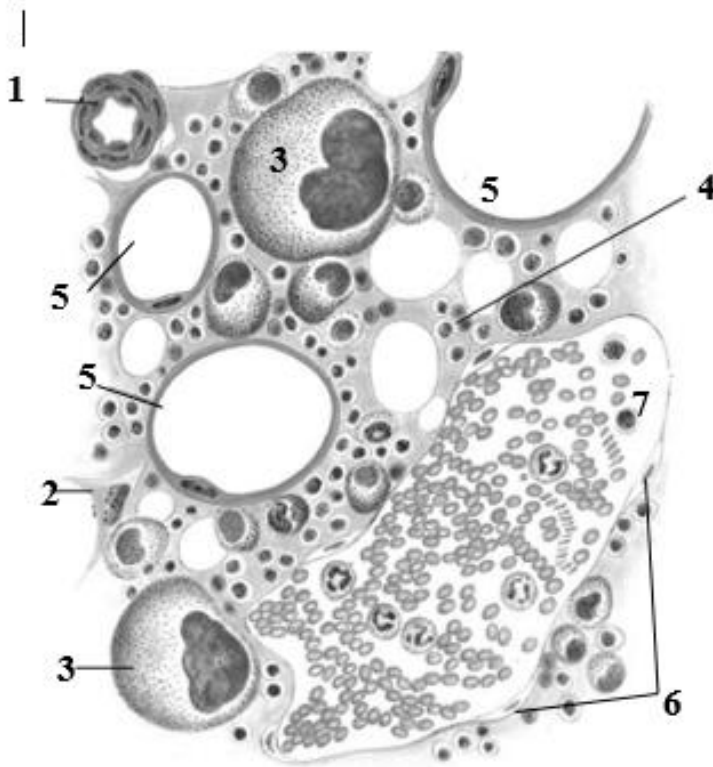
Topic 2. PRIMARY LYMPHOID ORGANS. RED BONE MARROW. THYMUS

Control questions:

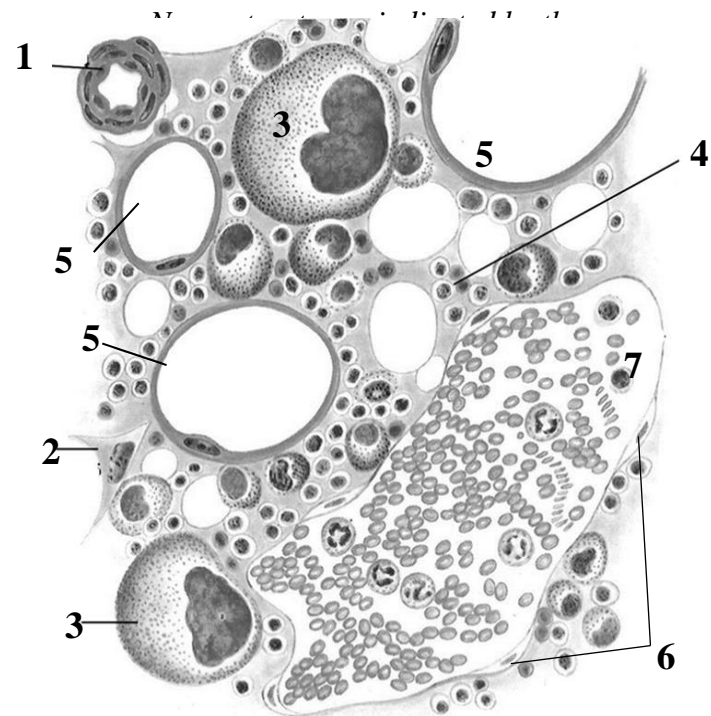
1. Primary (central) lymphoid organs: concept and overview.
2. Red bone marrow: embryological development, histological structure and functions. Age-related changes in the red bone marrow.
3. Thymus. Development, histological structure and functions.
4. Blood-thymus barrier: structure and significance. Physiological (age-related) vs. accidental thymic involution.
5. Endocrine functions of the thymus: thymic hormones and their biological roles.

MATERIAL FOR INDEPENDENT WORK

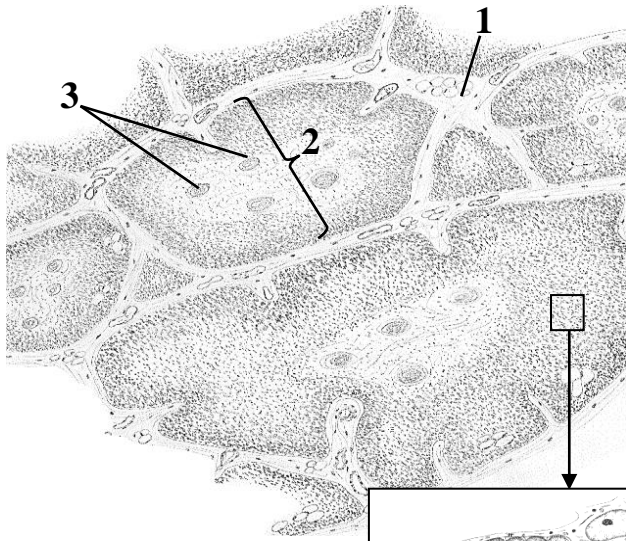
RED BONE MARROW



Scheme



THYMUS



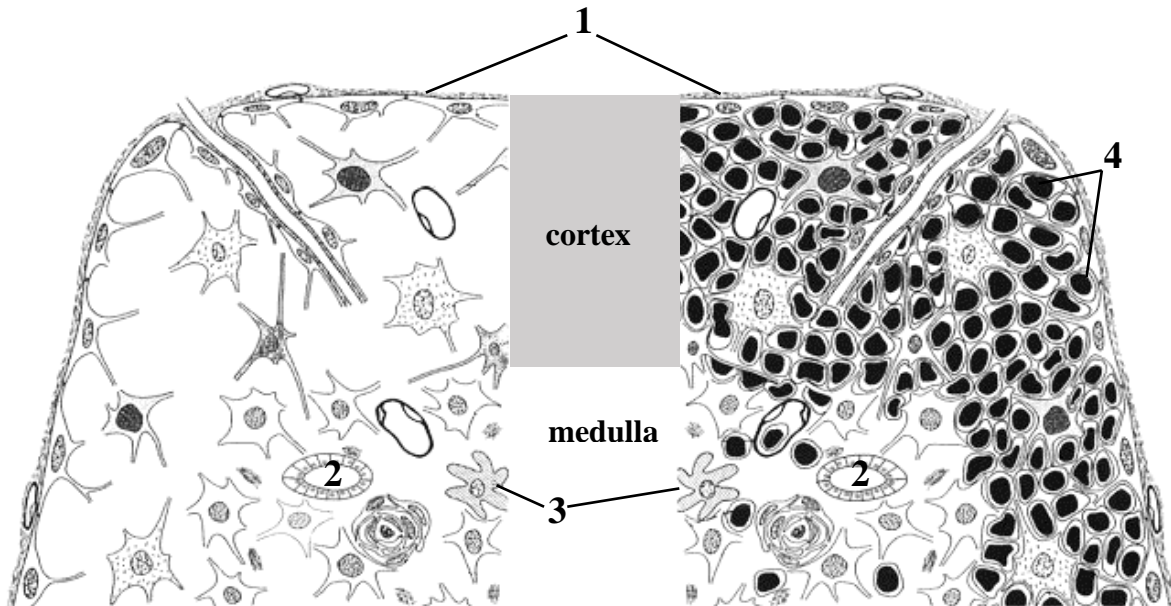
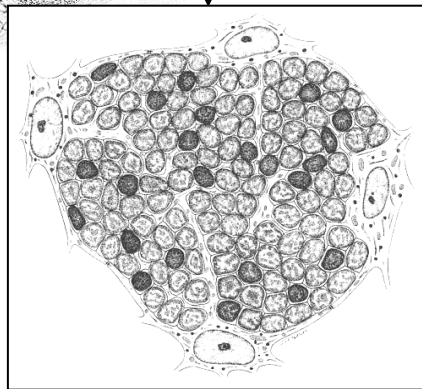
Name structures, indicated by the numbers:

1. _____
2. _____
3. _____

Color the following structures, using a different color for each:

- capsule
- cortex
- medulla
- epithelioreticular cells
- thymocytes

Schematic drawing



Scheme of histological structure

Name structures, indicated by the numbers:

1. _____
2. _____
3. Dendritic cells
4. _____

Color the following structures, using a different color for each:

- epithelioreticular cells
- thymic corpuscles



Histology slide
(H&E, high-power magnification)

Draw and indicate the following structures:

1. Cortex
2. Medulla
3. Thymic corpuscles
4. Thymocytes
5. Blood vessels

For notes:

THE LESSON IS COMPLETED

Teacher _____

« _____ » _____

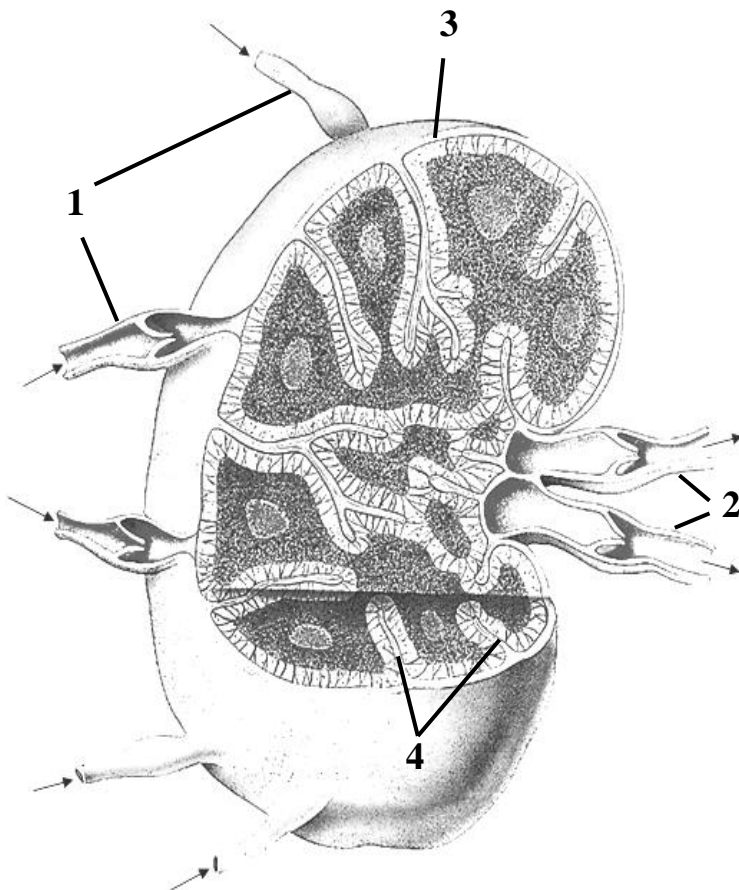
Topic 3. SECONDARY LYMPHOID ORGANS. LYMPH NODE. SPLEEN. TONSIL

Control questions:


1. Structural organization of secondary lymphoid organs: general principles. Lymph nodes: embryonic development, histological architecture, functions, and age-related modifications.
2. Lymph node histology: the organization and dynamic changes of T-cell and B-cell zones during an immune response.
3. Spleen: embryonic development, histological structure, and physiological functions. Special features of blood circulation within the spleen.
4. Organization of splenic compartments: histological structure and functional roles of T- and B-cell zones. Age-related structural and functional changes in the spleen.
5. Mucosa-associated lymphoid tissue (MALT). Development, structure, and functions of the tonsils.

MATERIAL FOR INDEPENDENT WORK

LYMPH NODE



Scheme

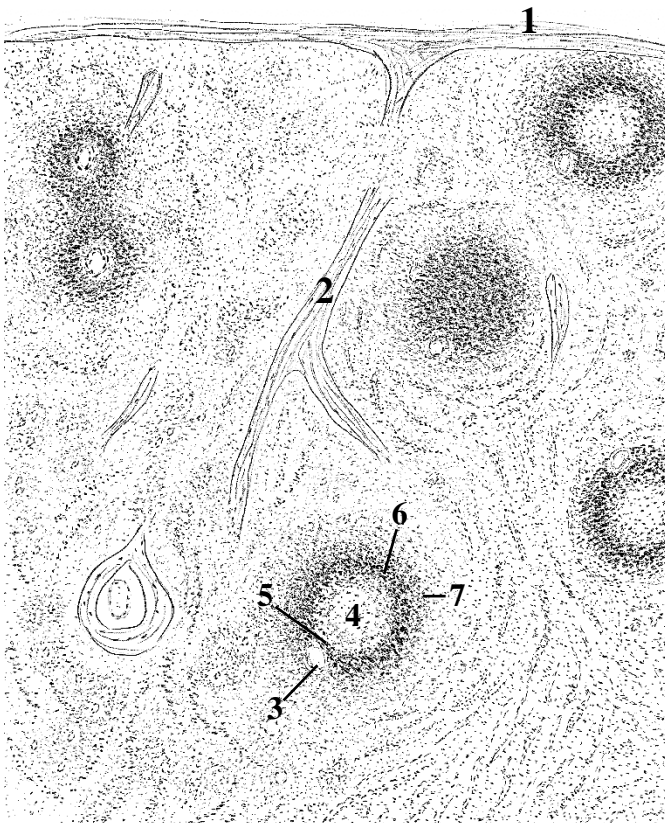


Draw and indicate the following structures:

- I. Cortex
- II. Paracortex
- III. Medulla
- 1. Capsule
- 2. Subcapsular sinus
- 3. Trabecules
- 4. Paratrabecular sinuses
- 4. Lymphoid follicle
 - a. mantle zone
 - б. germinal center
- 5. Medullary sinuses
- 6. Medullary cords

Histology slide
(H&E, high-power magnification)

SPLEEN




Name structures, indicated by the numbers and color the white and red pulp using a different color for each:

- white pulp (lymphoid follicles)
- red pulp

- 1. _____
- 2. _____
- 3. _____ artery
- 4. Germinal center
- 5. _____ sheath
- 6. _____ zone
- 7. _____ zone

Scheme

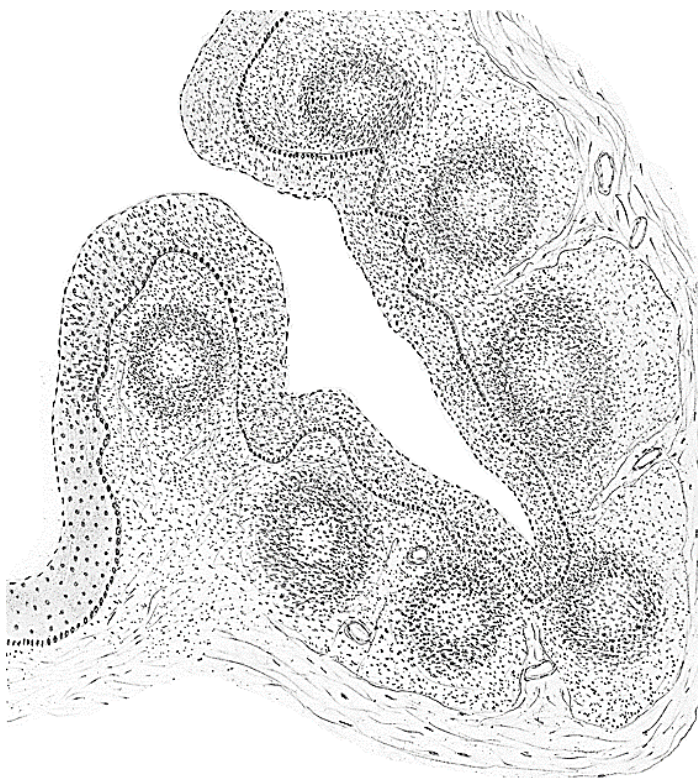


Draw and indicate the following structures:

1. Trabecules
2. Central artery
3. Germinal center
4. Periarterial lymphoid sheath (PALS)
5. Mantle zone
6. Marginal zone

Histology slide
(H&E, high-power magnification)

PALATINE TONSIL



Color the following structures, using a different color for each:

- stratified squamous non-keratinized epithelium
- lymphoid follicles (B-cells)
- interfollicular areas (T-cells)
- capsule
- trabecules

Scheme

THE LESSON IS COMPLETED

Teacher _____

« _____ » _____

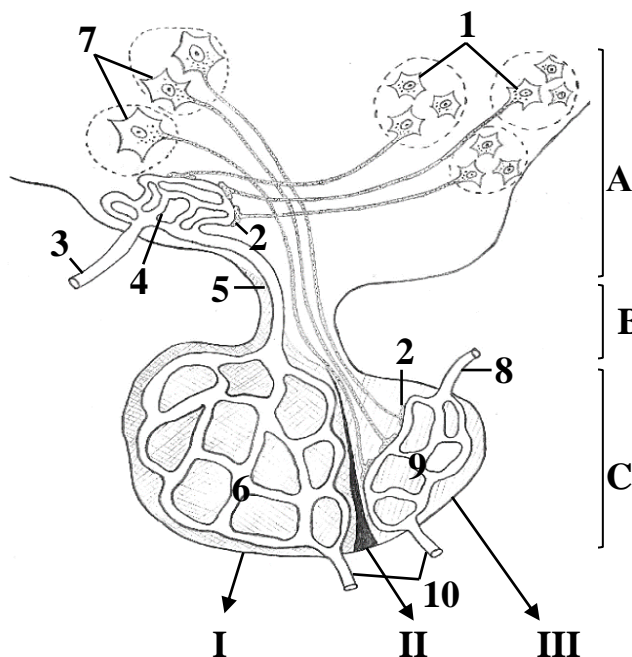
Topic 4. ENDOCRINE GLANDS. MICROSCOPIC STRUCTURE OF THE PITUITARY GLAND, EPIPHYSIS, THYROID AND PARATHYROID GLANDS, ADRENAL GLAND

Control questions:

1. Endocrine System: major endocrine organs and diffuse endocrine cells. Principles of endocrine regulation
2. Hypothalamus: microscopic structure, functional roles, and regulation of the pituitary gland (hypothalamic-pituitary axis).
3. Pituitary gland (hypophysis): embryogenesis, histological architecture, hypophyseal portal system, and endocrine functions of adenohypophysis and neurohypophysis.
4. Pineal gland (epiphysis cerebri): embryological development, histological structure, and endocrine functions.
5. Thyroid and parathyroid glands: embryological development, histological structure, and physiological roles. Structure–function dynamics of the thyroid follicular cell secretory cycle
6. Adrenal gland: embryological development and histological organization of the cortex and medulla. The hypothalamic–pituitary–adrenal (HPA) axis. Age-related structural and functional involution.

MATERIAL FOR INDEPENDENT WORK

HYPOTHALAMO-HYPOPHYSEAL SYSTEM



Color the following structures, using a special color for each: arteries — red, capillaries — purple, veins — blue, neurohypophysis — yellow, adenohypophysis — green

- A. Hypothalamus**
B. Hypophyseal stalk (infundibulum)
C. Pituitary (hypophysis)

Name structures, indicated by the letters.

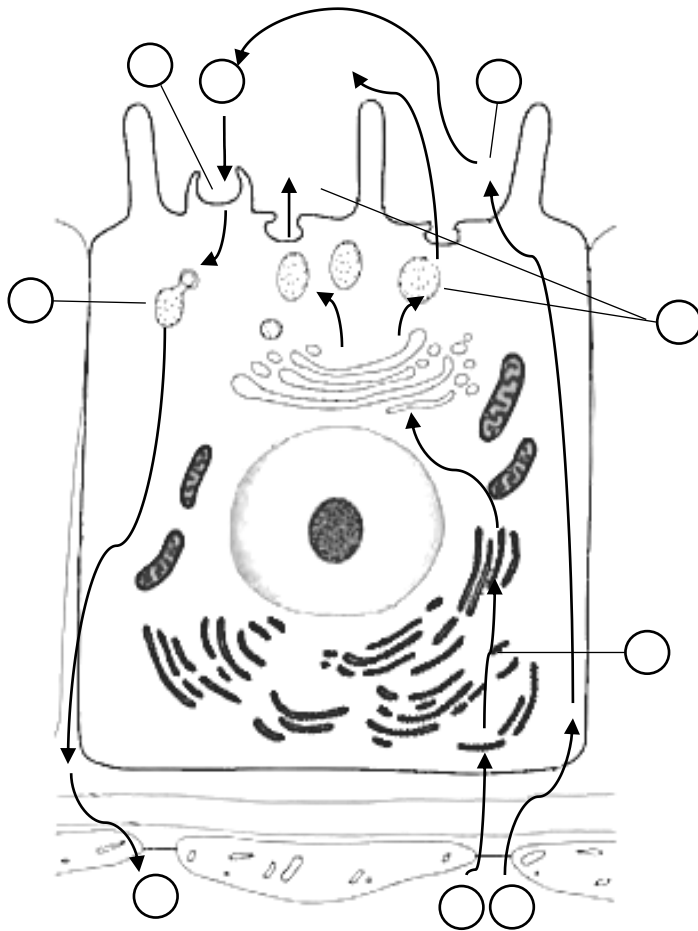
- I. _____
 II. _____
 III. _____

5. _____ vein
 6. _____ plexus
 7. _____ of supraoptic and paraventricular nuclei
 8. _____ artery
 9. _____ plexus of pars nervosa
 10. _____ veins

Scheme of histological structure of pituitary

1. _____ of ventral medial, dorsal medial and infundibular nuclei
2. _____ synapses
3. _____ artery
4. _____ plexus

THYROID AND PARATHYROID GLANDS




Color the following structures, using a different color for each:

- endothelium
- endothelial basement membrane
- basement membrane of thyrocyte

Arrange the numbers according to the stages of the secretory cycle of follicular thyrocyte:

1. Amino acids (tyrosine)
2. Uptake of iodide
3. Synthesis of thyroglobulin
4. Exocytosis of thyroglobulin
5. Oxidation of iodide to iodine
6. Iodination of thyroglobulin
7. Endocytosis of iodinated thyroglobulin
8. Thyroglobulin processing by lysosome enzymes
9. Release of T3 and T4 into the blood




Draw and indicate the following structures:

1. Thyroid follicles
2. Follicular cells
3. Colloid
4. Resorption vacuoles
5. Cords of parathyrocytes
6. Connective tissue
7. Blood vessels

Histology slide
(H&E, high-power magnification)

ADRENAL GLAND



Scheme of histological structure

Name structures, indicated by the numbers:

- I. _____
- II. _____
- III. _____
- 1. _____
- 2. _____

Color the following structures, using a different color for each:

- zona glomerulosa
- zona fasciculata
- zona reticularis

THE LESSON IS COMPLETED

Teacher _____

« _____ » _____


**Topic 5. PERIPHERAL NERVOUS SYSTEM.
MICROSCOPIC STRUCTURE OF THE NERVE, SENSORY
AND AUTONOMIC GANGLIA**

Control questions:

1. Embryonic origins and structural organization of the nervous system.
2. Structural components and classification of reflex arcs.
3. Histological structure of a peripheral nerve trunks and sensory ganglia.
4. Autonomic nervous system: sympathetic and parasympathetic divisions. Central and peripheral organization of autonomic pathways.
5. Cellular composition of autonomic ganglia: neurons and supporting glial cells.

MATERIAL FOR INDEPENDENT WORK

PERIPHERAL NERVE



Draw and indicate the following structures:

1. Axon
2. Myelin
3. Endoneurium
4. Nerve fascicles
5. Perineurium
6. Epineurium
7. Fat cells

Histology slide

(H&E, high-power magnification)

DORSAL ROOT (SPINAL) GANGLION



Draw and indicate the following structures:

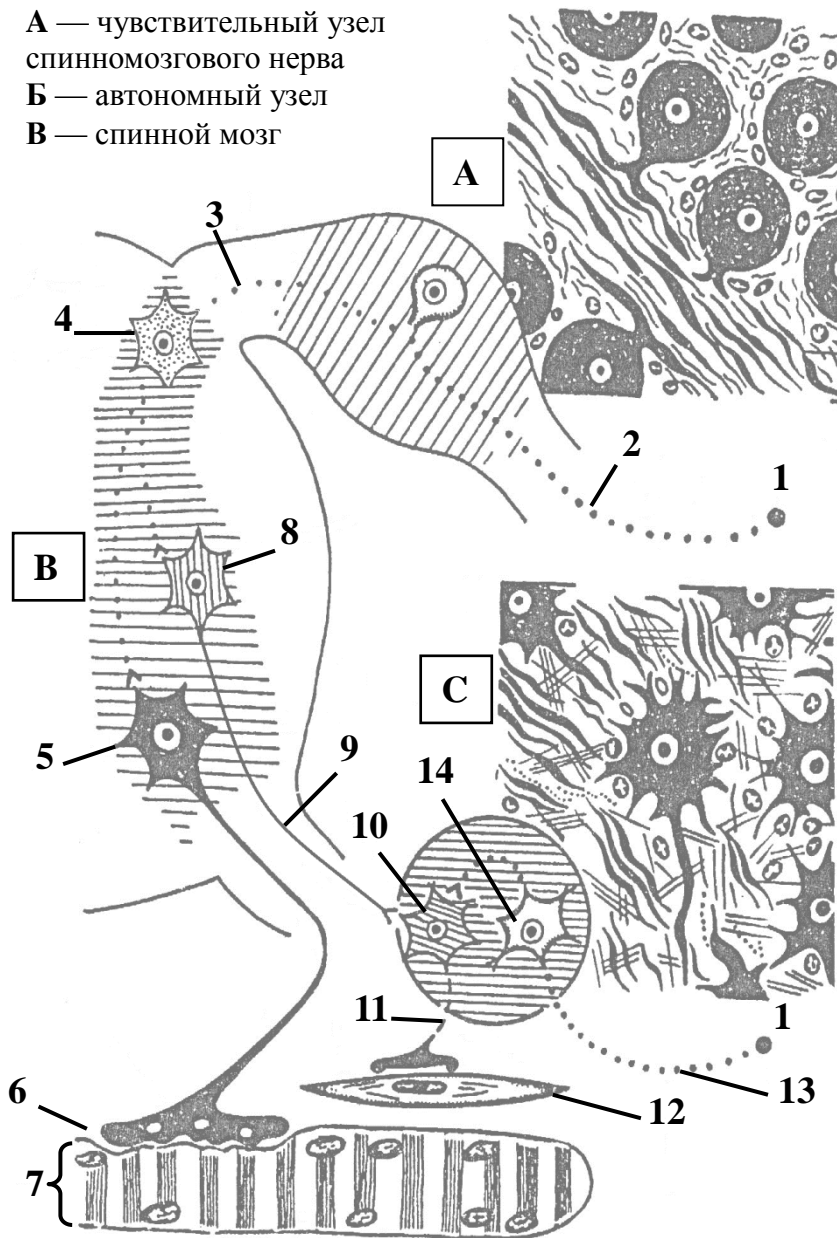
1. Capsule
2. Ventral root
3. Dorsal root
4. Spinal nerve
5. Nerve fibers
6. Bodies of pseudounipolar neurons
7. Satellite cells

Histology slide

(H&E, high-power magnification)

SCHEME OF REFLEX ARCS OF SOMATIC AND AUTONOMIC REFLEXES

А — чувствительный узел
спинномозгового нерва
Б — автономный узел
В — спинной мозг



Name structures, indicated by the numbers and letters:

- A. _____ ganglion
- B. _____
- C. _____ ganglion
- 1. Receptor
- 2. Peripheral process of _____ neuron
- 3. Central process of _____ neuron
- 4. _____ neuron
- 5. Somatic motoneuron
- 6. _____ synapse
- 7. _____ fiber
- 8. _____ neuron
- 9. _____ fiber
- 10. _____ neuron
- 11. _____ fiber
- 12. Smooth muscle cell
- 13. Dendrite of autonomic _____ neuron
- 14. _____ neuron

Color reflex arcs, using a different color for each:

- Somatic – red color
- Autonomic (central) – yellow color
- Autonomic (peripheral) – green color

THE LESSON IS COMPLETED

Teacher _____
« _____ » _____

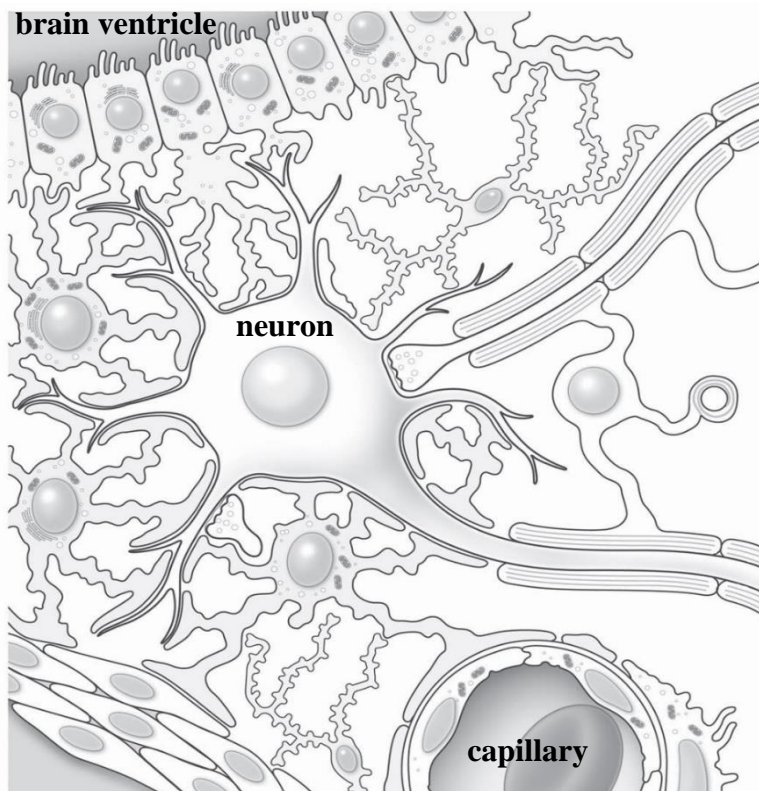
Topic 6. CENTRAL NERVOUS SYSTEM. MICROSCOPIC STRUCTURE OF THE SPINAL CORD, CEREBELLAR CORTEX AND CEREBRAL CORTEX

Control questions:

1. Spinal cord: histological organization of gray and white matter.
2. Cerebral cortex: morphological classification of cortical neurons.
3. Cytoarchitectonic and myeloarchitectonic maps of the cerebral cortex. Granular versus agranular cortical types.
4. Cerebellum: histology and neuronal organization of the cerebellar cortex.
5. Histological structure of the meninges: dura mater, arachnoid mater, and pia mater.
6. Blood-brain barrier and blood-cerebrospinal fluid barrier: structure and physiological significance.

MATERIAL FOR INDEPENDENT WORK

NEUROGLIA OF THE CENTRAL NERVOUS SYSTEM



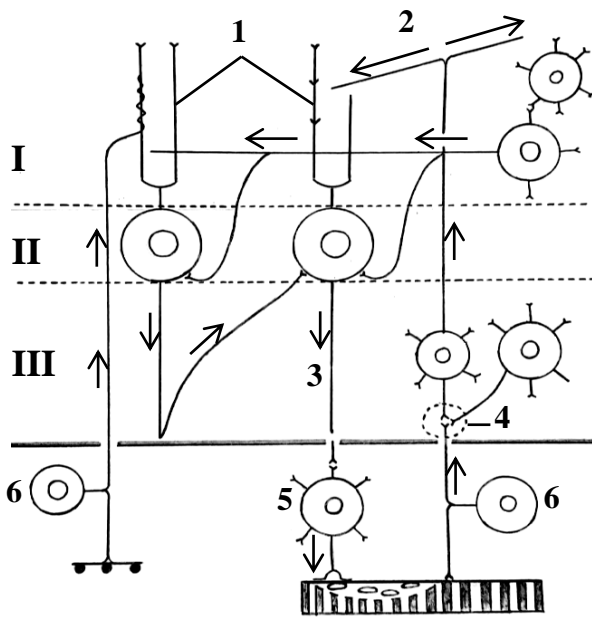
Color the following glial cells, using a different color for each:

- astrocytes
- microglia
- ependymocytes
- oligodendrocytes

Highlight components of blood-brain barrier in red

Scheme of relationship between neurons and neuroglia in CNS

CEREBELLAR CORTEX



**Neural organization of the cerebellar cortex
(scheme)**

Name structures, indicated by the numbers:

- I. _____ layer
- II. _____ layer
- III. _____ layer
- 1. Dendrites of the _____ cells
- 2. Parallel fiber
- 3. Axon of the _____ cells
- 4. _____ of the cerebellum
- 5. Somatic motor neuron
- 6. Sensory neuron

Color the following structures, using a different color for each:

- mossy fiber
- climbing fiber
- Golgi cell
- granule cell
- Purkinje cell body
- stellate cell
- basket cell



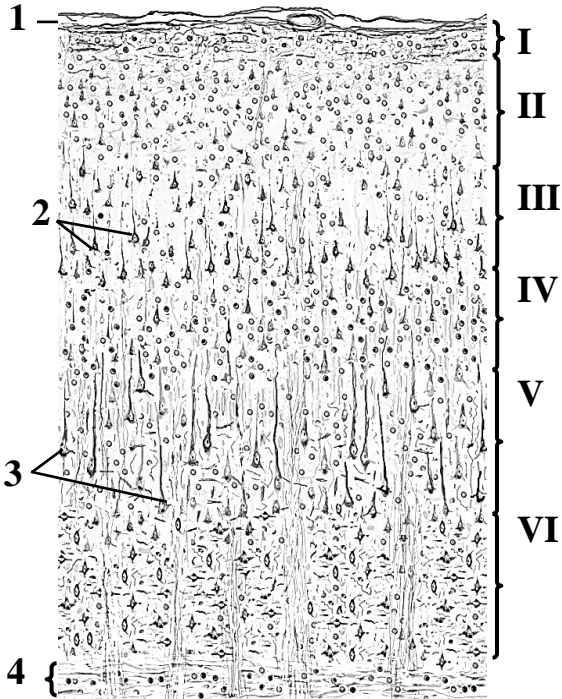
Draw and indicate the following structures:

- 1. Molecular layer
- 2. Purkinje cell layer
 - a. Purkinje cell bodies
 - b. baskets of nerve fibers
- 3. Granule cell layer

Histology slide

(H&E, high-power magnification)

CEREBRAL CORTEX



Color the following structures, using a different color for each:

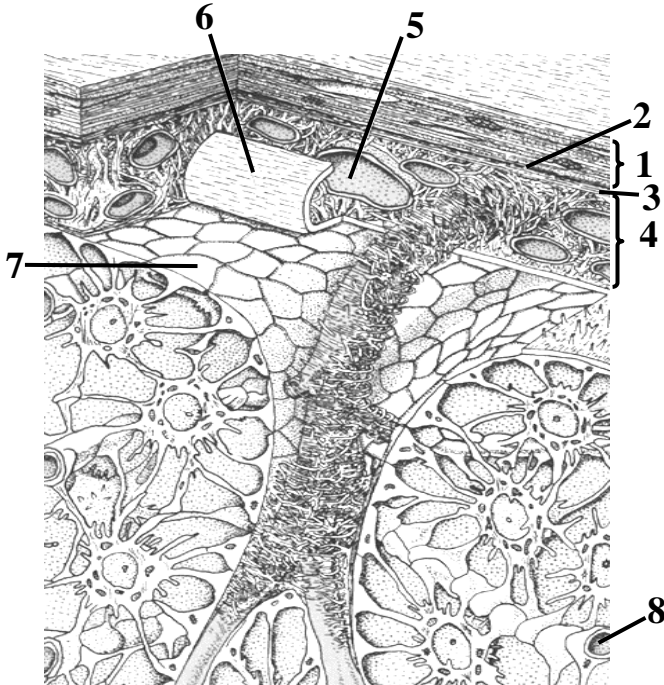
- I. _____ layer
- II. _____ layer
- III. _____ layer
- IV. _____ layer
- V. _____ layer
- VI. _____ layer

Name structures, indicated by the numbers:

- 1. _____ mater
- 2. Small _____ cells
- 3. Large _____ cells
- 4. White matter

Scheme of histological structure

MENINGES OF THE BRAIN



Color the astrocytes.

Name structures, indicated by the numbers:

- 1. _____ mater
- 2. _____
- 3. _____ space
- 4. _____ mater
- 5. _____ space
- 6. Blood vessel
- 7. _____ mater (folded)
- 8. Glia limitans
- 9. Blood capillary

Scheme of histological structure

THE LESSON IS COMPLETED

Teacher _____

« _____ » _____


Topic 7. SENSE ORGANS. MICROSCOPIC STRUCTURE OF THE EYEBALL AND INNER EAR

Control questions:

1. Classification of sensory organs. Organization of sensory systems: receptors, neural pathways, and cortical processing. General characteristics of sensory receptor cells.
2. Embryonic origins of the eyeball: contributions of neural ectoderm, surface ectoderm, and mesenchyme.
3. Fibrous tunic: histological structure of the sclera and cornea.
4. Vascular tunic (uvea): microscopic anatomy of the choroid, ciliary body, and iris.
5. Histological organization of the retina.
6. Development and structural organization of the inner ear.
7. Histological structure of the membranous vestibular labyrinth.
8. Histological structure of the cochlear duct and the spiral organ of Corti. Cellular mechanisms of auditory transduction.
9. Embryonic development and histological structure of taste buds. Cellular mechanisms of gustatory reception.
10. Embryonic development and histological structure of the olfactory epithelium. Cellular mechanisms of olfactory reception.

MATERIAL FOR INDEPENDENT WORK

CORNEA

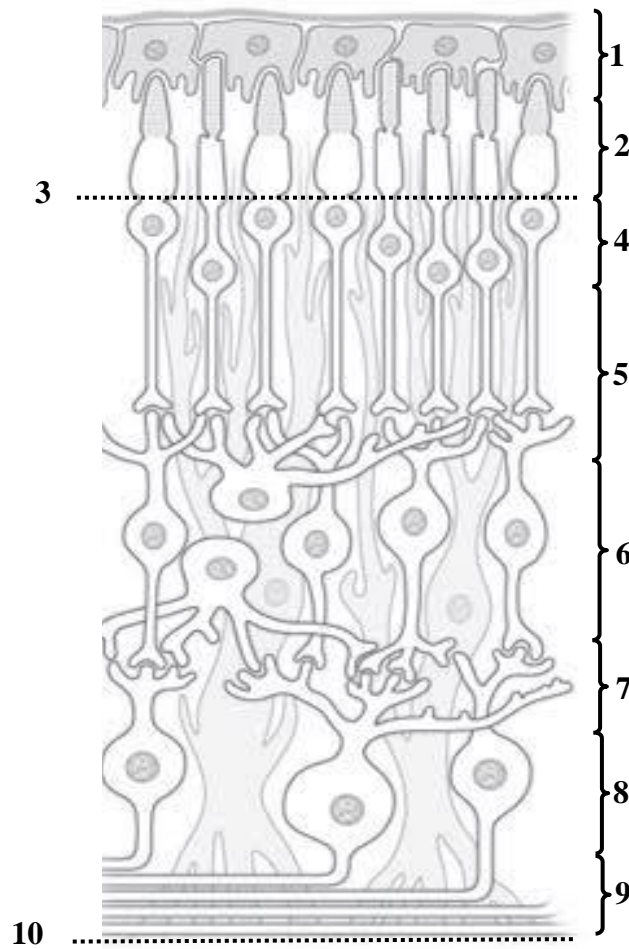


Name and color the following structures, using a different color for each:

- 1. _____ epithelium
- 2. _____ limiting membrane
- 3. Corneal _____
- 4. _____ limiting membrane
- 5. _____

Scheme of histological structure

RETINA



Scheme of histological structure

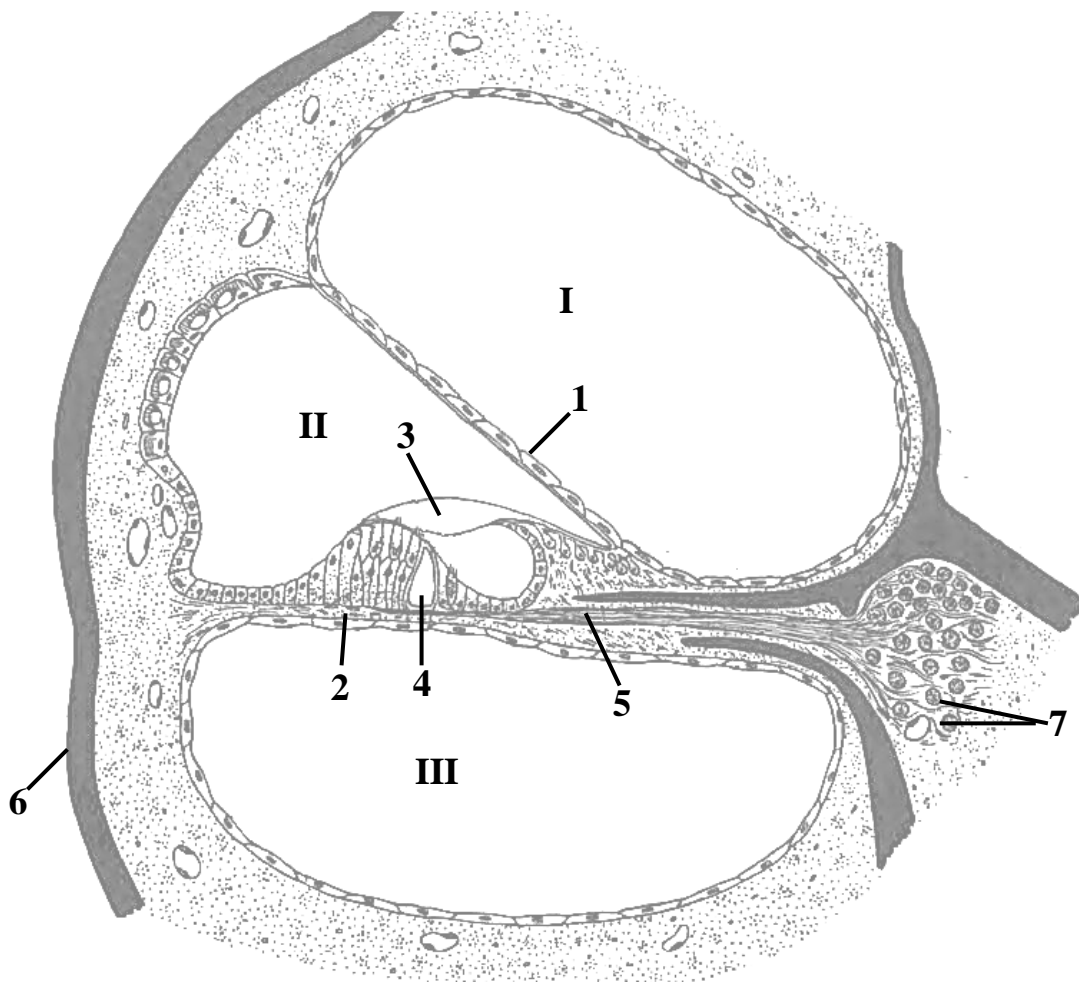
Name layers of retina, indicated by the numbers:

1. _____ epithelium
2. _____ layer
3. Outer _____ membrane
4. Outer _____ layer
5. Outer _____ layer
6. Inner _____ layer
7. Inner _____ layer
8. _____ layer
9. _____ layer
10. Inner _____ membrane

Color the following structures, using a different color for each:

- pigmented cells
- rods (the thinner cells)
- cones (the thicker cells)
- amacrine cell
- horizontal cell
- Muller cell (supporting glial cell)
- bipolar neurons
- ganglion cells and their axons

CROSS-SECTION OF THE COCHLEAR CANAL



Histological scheme of the organ of Corti

Name structures, indicated by the numbers:

I. Scala _____

II. _____ duct (scala media)

III. Scala _____

1. _____ membrane

2. _____ membrane

4. _____

5. Nerve fibers

6. Bone

7. Bipolar neurons of _____ ganglion

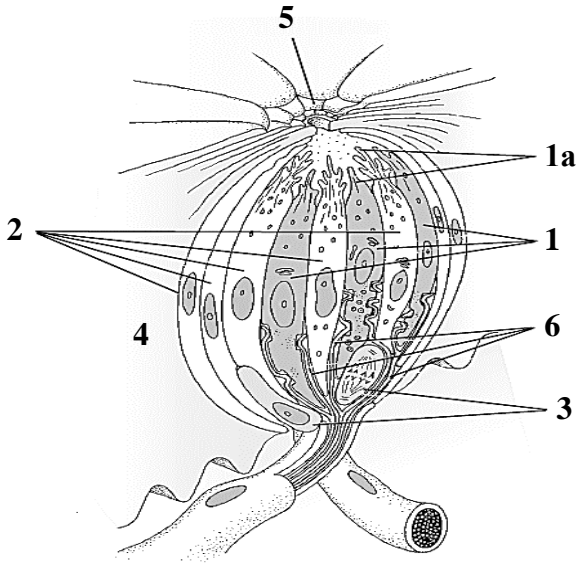
Color the following structures, using a different color for each:

Spiral organ

stria vascularis

tectorial membrane

TASTE BUD

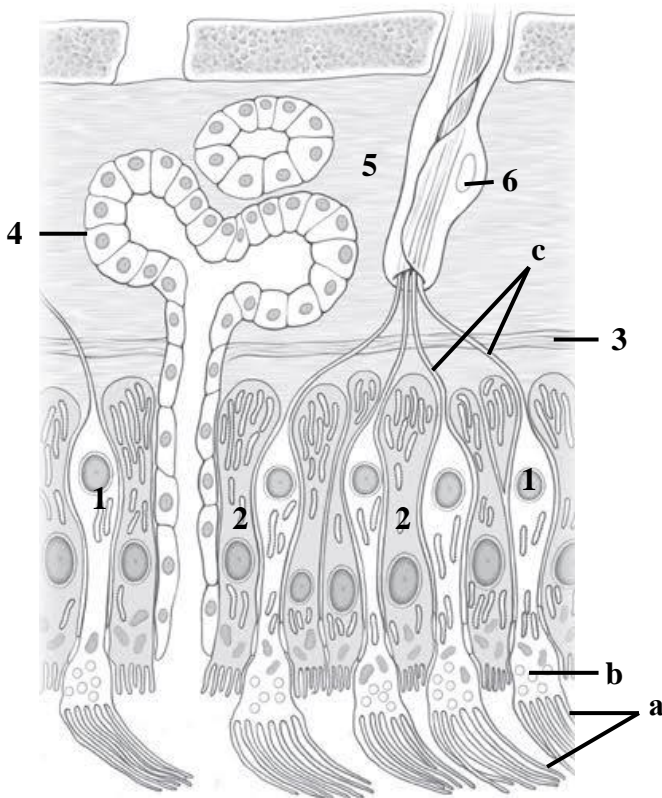


Name and color following structures, using a different color for each:

- 1. _____ cells
- 1a. microvilli
- 2. _____ cells
- 3. _____ cells
- 4. Stratified squamous non-keratinized epithelium
- 5. Taste pore
- 6. Afferent nerve fibers

Scheme of histological structure

OLFACTORY ORGAN



Name and color following structures, using a different color for each:

- 1. _____
- a. olfactory _____
- b. dendritic _____
- c. _____
- 2. _____
- 3. _____ membrane
- 4. Bowman's gland
- 5. Lamina propria
- 6. Schwann cell

Scheme of histological structure of the olfactory mucosa

THE LESSON IS COMPLETED

Teacher _____

« _____ » _____


Topic 8. DIGESTIVE SYSTEM. MICROSCOPIC STRUCTURE OF THE ORAL MUCOSA. LIP, GINGIVA, CHEEK, PALATE, TONGUE

Control questions:

1. Embryonic origins of the structures of the oral cavity.
2. Masticatory and lining oral mucosa: comparative histology and structural characteristics.
3. Histological structure of the lip and labial glands.
4. Histology of the gingiva.
5. Histological organization of the buccal mucosa and buccal glands.
6. Hard palate: comparative histology of its different anatomical zones.
7. Histological specializations of the soft palate mucosa.
8. Tongue: microscopic structure and functional organization. Lingual tonsil, taste buds, and mechanism of gustatory transduction.
9. Histological changes in the oral mucosa with age.

MATERIAL FOR INDEPENDENT WORK

ORAL MUCOSA AND UNDERLYING TISSUES



Name and color structures indicated by the numbers:

1. _____ epithelium
2. _____ propria
- papillary layer
- reticular layer
3. _____

COMPARATIVE CHARACTERISTICS OF MASTICATORY AND LINING MUCOSA

Fill in the table (insert missing words, cross out unnecessary words):

Feature	Masticatory mucosa	Lining mucosa
Regions		
Epithelium	stratified squamous _____	stratified squamous _____
Lamina propria (connective tissue papillae)	long/short	long/short
Submucosa	well defined/poorly defined or absent	well defined/poorly defined or absent

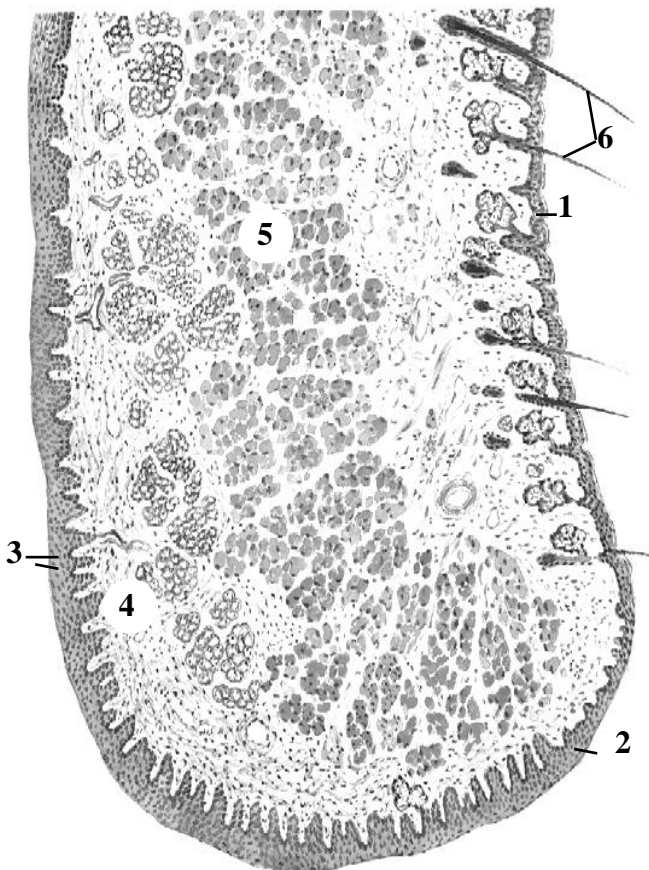
LIP

Name and color structures indicated by the numbers:

1. Epithelium of _____ lip
2. Epithelium of _____ zone of the lip
3. Epithelium of _____ mucosa
4. _____ propria
5. Orbicularis oris muscle
6. Hairs

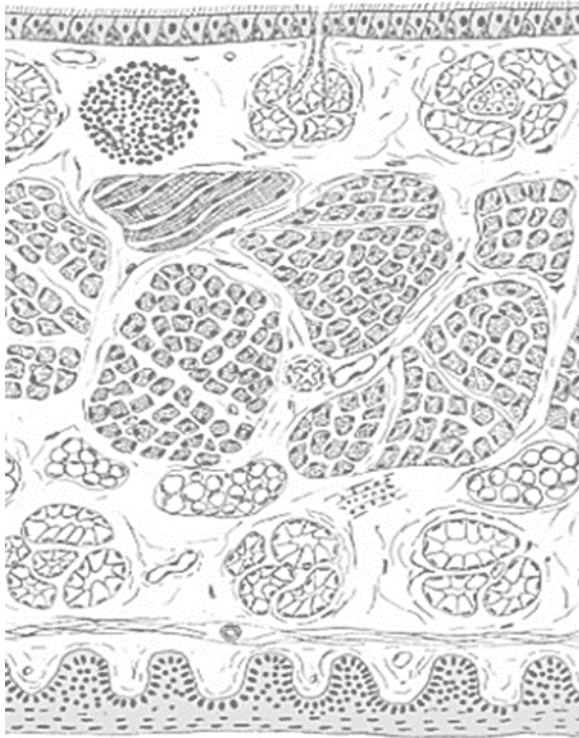Color the following structures, using a different color for each:

- sebaceous glands
- labial glands



Schematic diagram of microscopic structure

SOFT PALATE

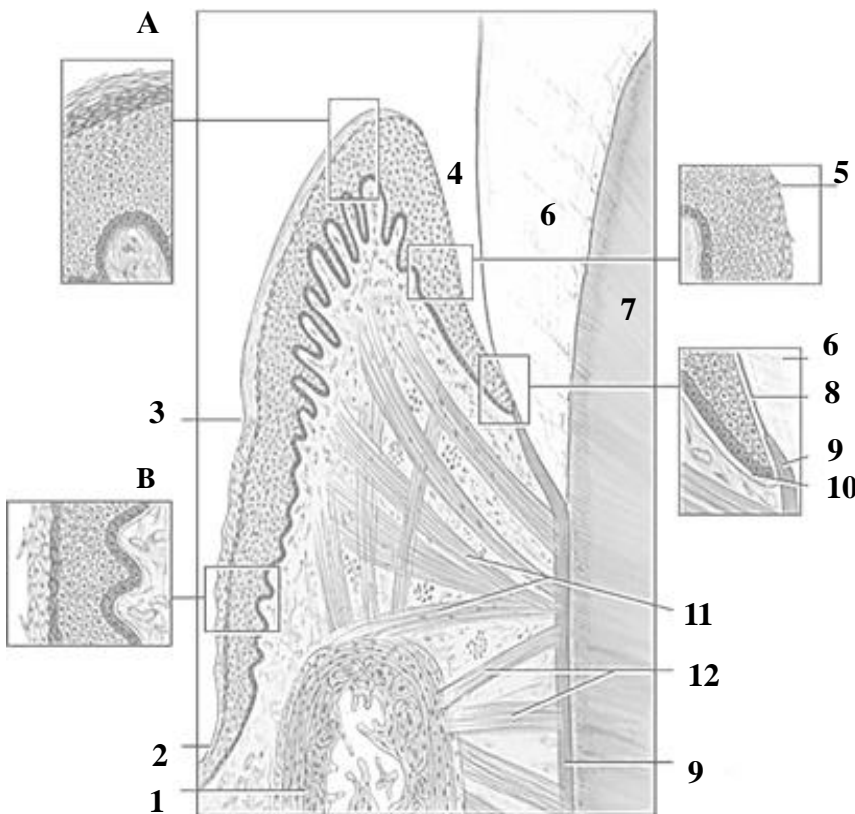


Schematic diagram of microscopic structure

Color structures indicated by the numbers:

- stratified squamous epithelium
- lymphoid follicle
- muscle fibers
- minor mucus lands in submucosa
- pseudostratified ciliated epithelium

GINGIVA

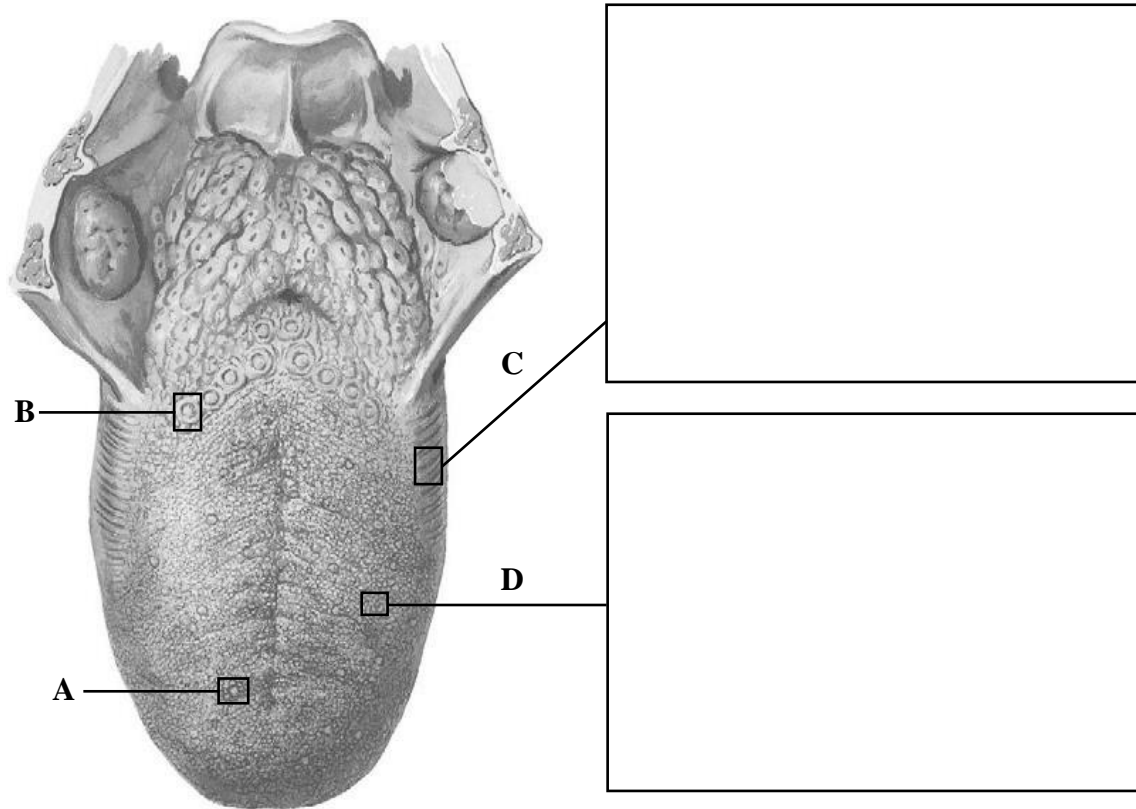


Schematic diagram of microscopic structure

Use different color to indicate stratified squamous keratinized epithelium, sulcular epithelium and junctional epithelium. Name structures, indicated by letters and numbers:

- A. _____ gingiva
- B. _____ gingiva
- 1. _____ bone
- 2. _____ mucosa
- 3. _____ groove
- 4. Gingival _____
- 5. _____ epithelium
- 6. _____
- 7. _____
- 8. Internal _____ lamina
- 9. _____
- 10. External _____ lamina
- 11. Gingival fibers
- 12. Dentoalveolar fibers

TONGUE



Macroscopic structure of the tongue (in the center) and photomicrographs of longitudinal histological sections of lingual mucosa (H&E, low-power magnification)

Name structures indicated by the letters:

A. _____ papilla

B. _____ papilla

Draw the following structures:

C. foliate papillae

D. filiform papillae

THE LESSON IS COMPLETED

Teacher _____

« _____ » _____

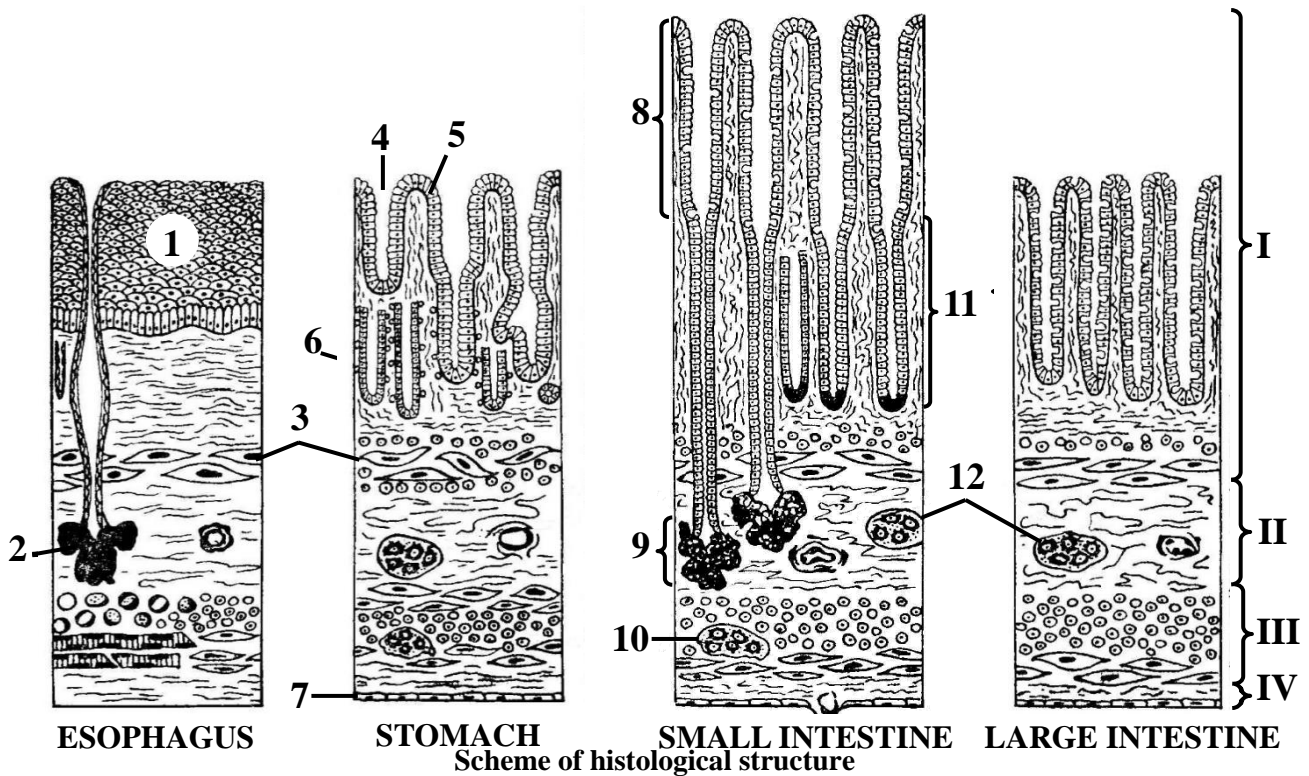
Topic 9. DIGESTIVE SYSTEM. MICROSCOPIC STRUCTURE OF THE WALL OF THE PHARYNX, ESOPHAGUS, STOMACH

Control questions:

1. General histological organization of the digestive tract wall.
2. Histological features of the pharyngeal wall.
3. Histological structure of the esophageal wall.
4. Histological structure of the gastric wall.
5. Histological differences in the gastric mucosa across anatomical regions: cardia, fundus, body, and pylorus.
6. Histology of gastric glands: cellular composition and epithelial renewal mechanisms.

MATERIAL FOR INDEPENDENT WORK

WALL OF GASTROINTESTINAL TUBE




Name structures, indicated by the numbers:

- I. _____
- II. _____
- III. _____
- IV. _____
1. _____ epithelium
2. Mucous secreting glands
3. _____ mucosae

4. Gastric _____
5. _____ epithelium
6. Gastric gland
7. _____
8. Intestinal _____
9. Intestinal _____
10. Myenteric ganglion
11. Intestinal _____
12. Submucosal ganglia

ESOPHAGUS



Draw and indicate the following structures:

I. Mucosa:

1. Stratified squamous non-keratinized epithelium
2. Lamina propria
3. Muscularis mucosae

II. Submucosa:

4. Mucous secreting glands

III. Muscularis externa:

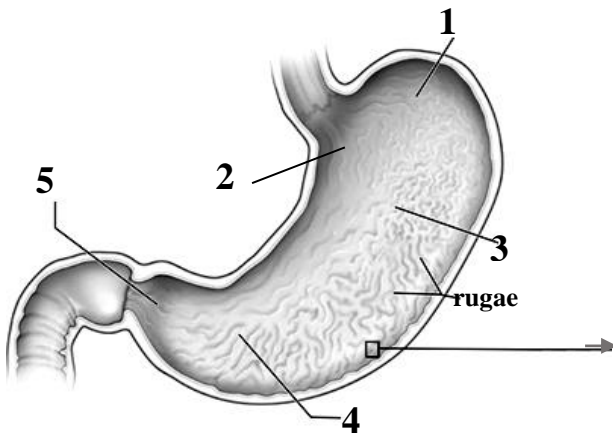
5. Inner circular layer
6. Outer longitudinal layer

IV. Adventitia

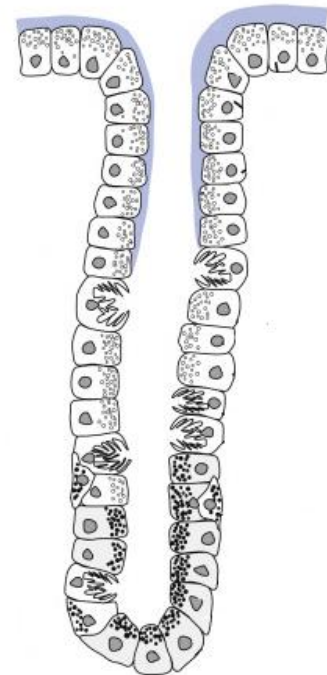
Histology slide

(cross-section of the middle third of the esophagus, H&E, low-power magnification)

STOMACH



Scheme of structure



Name structures, indicated by the numbers.

*Color the **parts of stomach** using a different color for each:*

- 1. _____
- 2. _____
- 3. _____
- 4. Pyloric _____
- 5. Pyloric _____

Color the cells of simple columnar epithelium and cells of gastric glands, using a different color for each:

- surface mucous cells
- mucous neck cells
- parietal cells
- endocrine cells
-

THE LESSON IS COMPLETED

Teacher _____

« _____ » _____

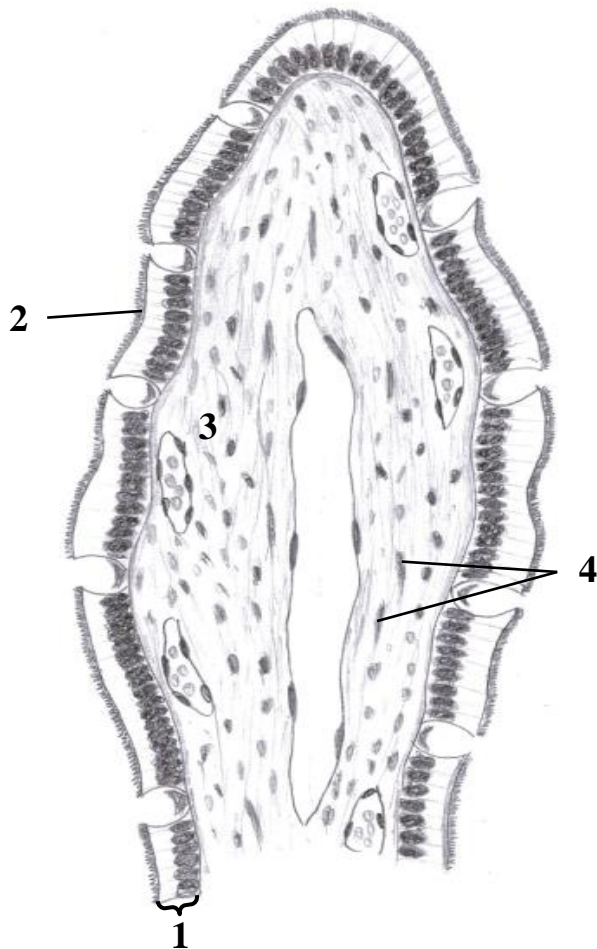
Topic 10. DIGESTIVE SYSTEM. MICROSCOPIC STRUCTURE OF THE WALL OF THE SMALL AND LARGE INTESTINES

Control questions:

1. Embryonic origins of the small intestine. Comparative histology of the duodenum, jejunum, and ileum.
2. Histophysiology of the intestinal crypt-villus system. Epithelial renewal in the small intestine.
3. Microscopic structure of the large intestine.
4. Histological structure and functional characteristics of the vermiform appendix.
5. Histological organization of the rectum and anal canal.

MATERIAL FOR INDEPENDENT WORK

SMALL INTESTINE



Name and color structures, indicated by the numbers:

1. _____

enterocytes

goblet cells

2. Brush border

3. _____ propria

lacteal

blood capillaries

4. Smooth muscle cells

Scheme of histological structure of the intestinal villus

DUODENUM



Draw and indicate the following structures:

I. Mucosa:

1. Simple columnar epithelium
2. Lamina propria
3. Muscularis mucosae

II. Submucosa:

4. Duodenal glands

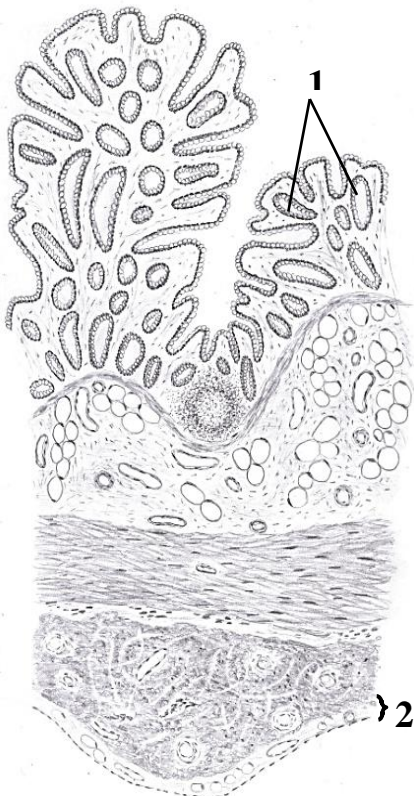
III. Muscularis externa:

5. Inner circular layer
6. Outer longitudinal layer

IV. Serosa

Histology slide
(H&E, low-power magnification)

LARGE INTESTINE



Name structures, indicated by the numbers:

1. _____
2. _____

Color the following structures, using a different color for each:

- simple columnar epithelium (colonocytes)
- lamina propria
- lymphoid follicle
- muscularis mucosae
- submucosa
- inner circular layer of muscularis externa
- outer longitudinal layer of muscularis externa (taenia coli)

THE LESSON IS COMPLETED

Teacher _____

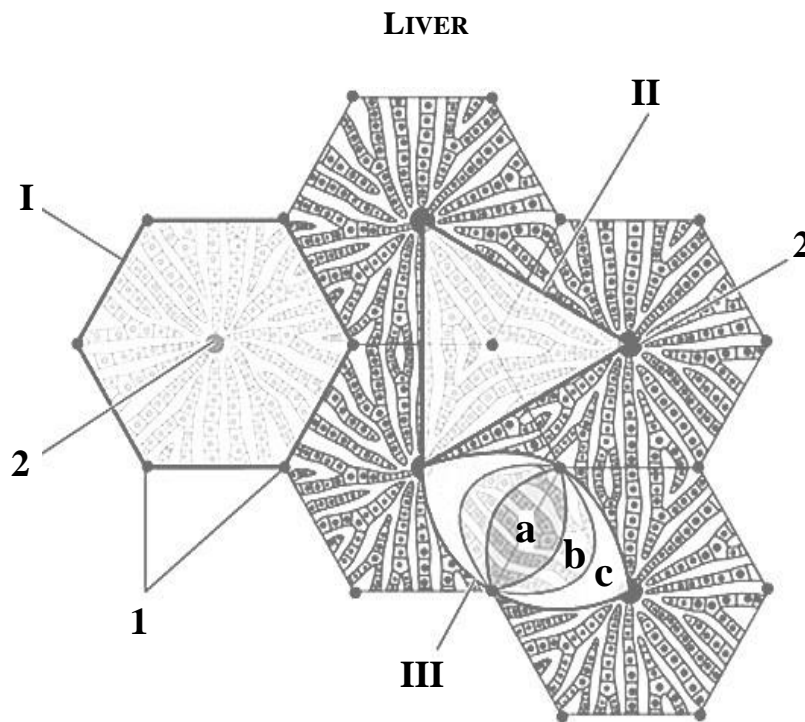
« _____ » _____

Topic 11. DIGESTIVE SYSTEM. MICROSCOPIC STRUCTURE OF THE LIVER AND PANCREAS

Control questions:

1. Embryogenesis of the liver and its major physiological functions.
2. Structural and functional units of the liver: the classic hepatic lobule, portal lobule, and liver acinus.
3. Hepatic microcirculation: blood flow and sinusoidal organization.
4. Age-related histological changes in the liver and its regenerative capacity.
5. Histological structure of the bile ducts and gallbladder wall.
6. Embryological development and functional organization of the pancreas: exocrine and endocrine components.
7. Histological organization of the exocrine pancreas.
8. Histological organization of the endocrine pancreas (pancreatic islets).

MATERIAL FOR INDEPENDENT WORK



Structural and functional units of the liver (scheme)

Color the classical liver lobule, portal lobule and liver acinus.

Name structures, indicated by the numbers:

I. _____

II. _____

III. _____

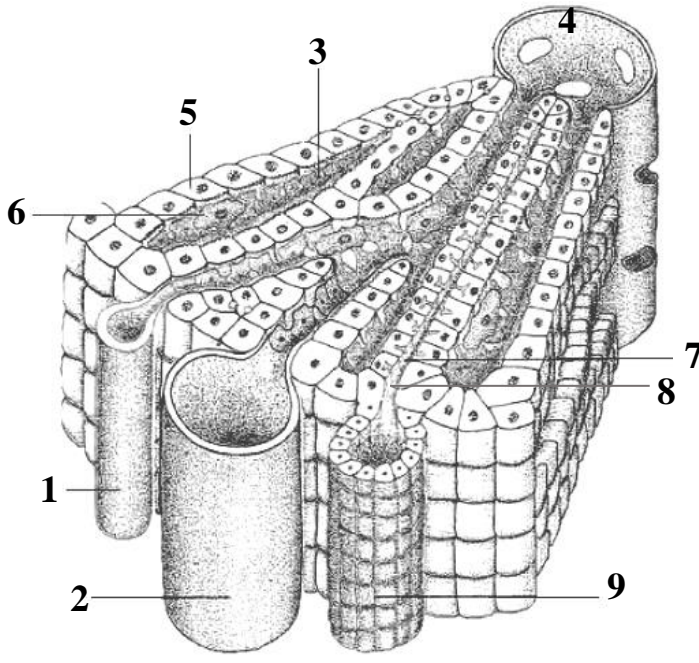
a. _____ zone

b. _____ zone

c. _____ zone

1. Portal _____

2. Central _____




Draw the classical liver lobule, name and indicate the following structures:

- 1. _____ artery
- 2. _____ vein
- 3. _____
- 4. _____ vein
- 5. Plates (cords) of hepatocytes
- 6. Kupffer cell
- 7. _____ canaliculus
- 8. Cholangiole
- 9. _____ duct



Histology slide
(H&E, high-power magnification)

PANCREAS

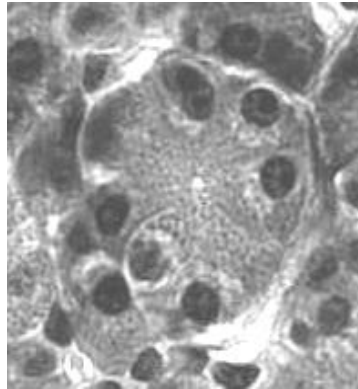
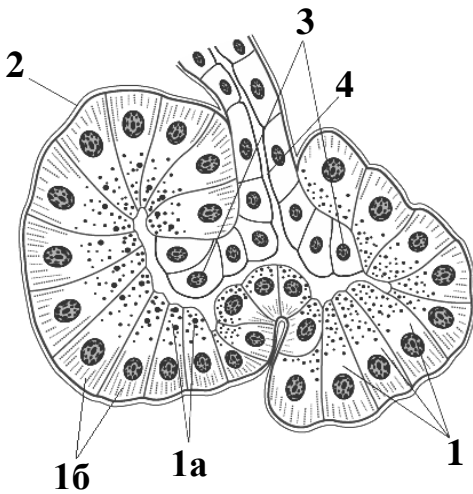


Draw and indicate the following structures:

- I. Lobule
- II. Interlobular connective tissue
 1. Pancreatic acini
 2. Islets of Langerhans
 3. Interlobular duct
 4. Blood vessels

Histology slide

(H&E, high-power magnification)



Name structures, indicated by the numbers.

Color the poles of the pancreatic exocrine cell:

1. _____ cell

- eosinophilic apex
 basophilic base

2. Basement membrane

3. Centroacinar cells

4. _____ duct

Scheme and histology slide of the pancreatic acinus

(H&E, high-power magnification)

THE LESSON IS COMPLETED

Teacher _____

« _____ » _____

Topic 12. INTEGUMENTARY SYSTEM. MICROSCOPIC STRUCTURE OF THE SKIN AND ITS DERIVATIVES

Control questions:

1. General histological characteristics and embryonic origins of the skin.
2. Cellular composition and functional dynamics of the epidermis: keratinization and regeneration.
3. Histological organization and functional roles of the dermis.
4. Comparative histology of the papillary and reticular layers of the dermis.
5. Blood supply, innervation, and the sensory receptor apparatus of the skin.
6. Development, structure, and function of sweat and sebaceous glands.
7. Hair: development, types, and histological structure.

MATERIAL FOR INDEPENDENT WORK

THIN SKIN

Name structures, indicated by the numbers:

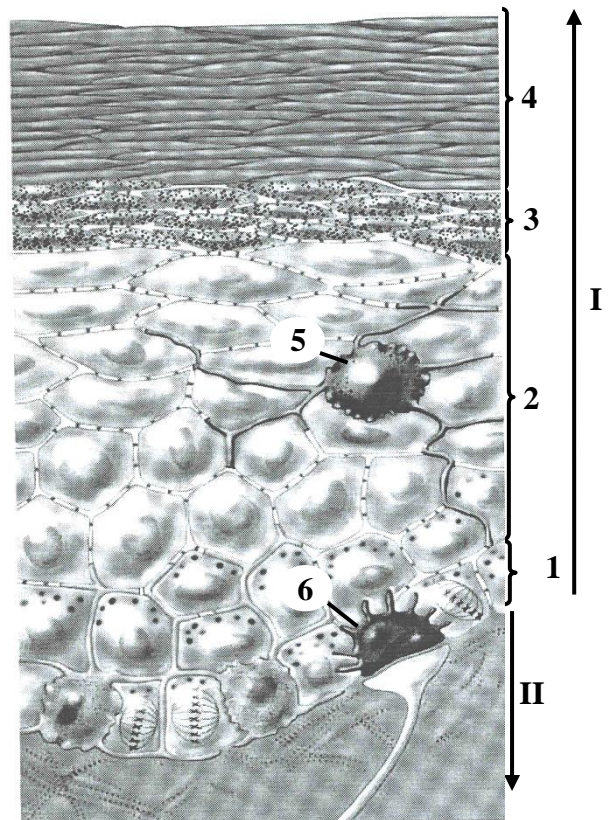
I. _____

II. _____

1. Stratum _____
2. Stratum _____
3. Stratum _____
4. Stratum _____
5. _____
6. _____ cell


Color the following epidermal cells using a different color for each:

- keratinocytes
- melanocytes



Scheme of histological structure

THICK SKIN



Histology slide
(H&E, low-power magnification)

Draw and indicate the following structures:

I. Epidermis

1. Stratum basale
2. Stratum spinosum
3. Stratum granulosum
4. Stratum lucidum
5. Stratum corneum
6. Excretory duct of sweat gland

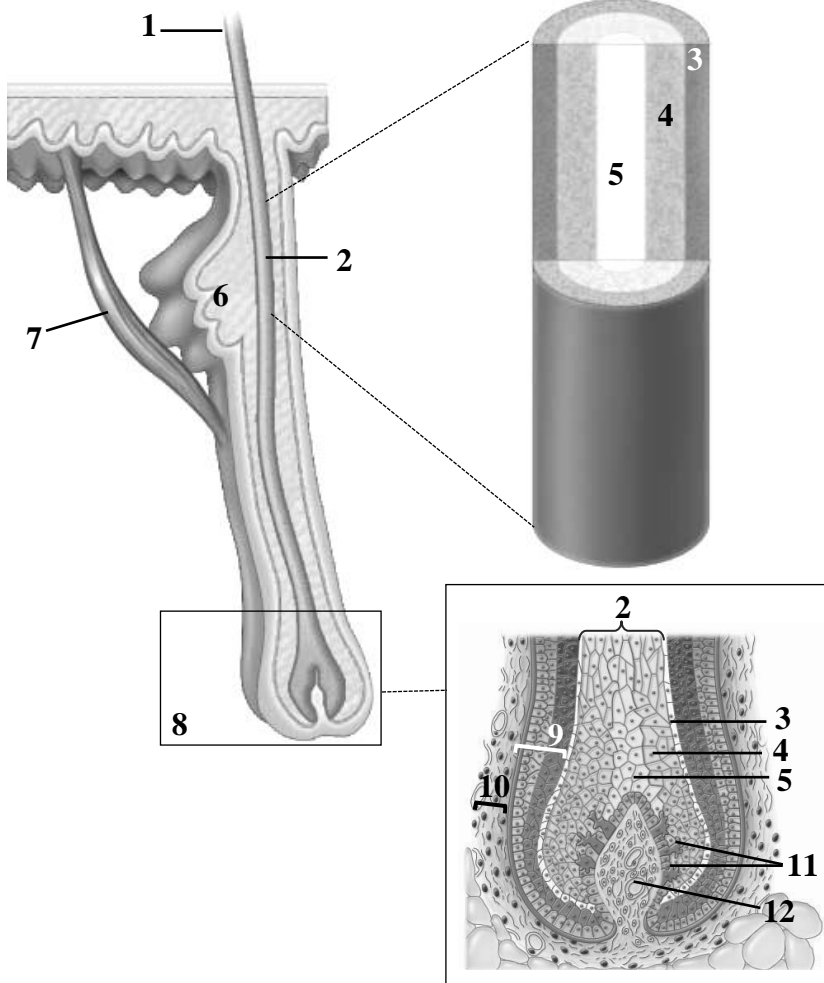
II. Dermis

8. Papillary layer
 - a. Meissner's corpuscle
9. Reticular layer
 - b. Secretory portions of sweat glands

III. Hypodermis

10. Adipose cells

HAIR



Name structures, indicated by the numbers:

1. Hair _____
2. Hair _____
3. _____
4. _____
5. _____
6. _____ gland
7. Arrector pili muscle
8. Hair _____
9. Hair _____
10. Dermal _____
11. Melanocytes
12. Dermal _____

Scheme of histological structure

Fill in the table.

HISTOLOGICAL TYPES OF SKIN		
	<i>Thick skin</i>	<i>Thin skin</i>
Epidermis (thickness of stratum corneum)		
Sweat glands (presence and type of secretion)		
Hairs (present/absent)		
Sebaceous glands (present/absent)		

Fill in the table.

EPIDERMAL CELLS			
	<i>localization</i>	<i>functions</i>	<i>embryonic origin</i>
keratinocytes			
melanocytes			
Langerhans cells			
Merkel cells			

For notes:

THE LESSON IS COMPLETED

Teacher _____

« _____ » _____

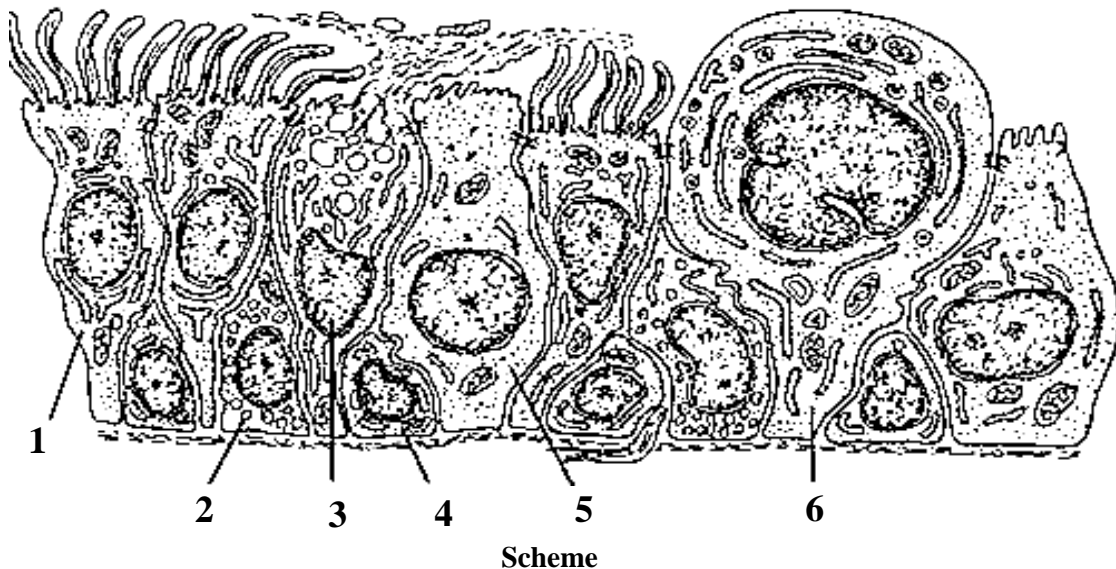
Topic 13. RESPIRATORY SYSTEM. MICROSCOPIC STRUCTURE OF THE CONDUCTING AND RESPIRATORY PORTIONS

Control questions:

1. Structural organization of the respiratory system: conducting and respiratory portions.
Embryonic development of the lower respiratory tract.
2. Comparative histology of the mucosa in the nasal cavity, nasopharynx, and larynx.
3. Histological structure of the tracheal wall.
4. Comparative histology of bronchi and bronchioles.
5. Histological structure of the respiratory portions: respiratory bronchioles, alveolar ducts, alveolar sacs, and alveoli.
6. Structure and function of the blood-air barrier. Role of pulmonary surfactant.

MATERIAL FOR INDEPENDENT WORK

RESPIRATORY EPITHELIUM



Name and color the cells of respiratory epithelium:

- 1. _____ cell
- 2. Endocrine cell
- 3. _____ cell
- 4. _____ cell
- 5. _____ cell
- 6. Club cell

TRACHEA



Draw and indicate the following structures:

I. Mucosa:

1. Respiratory epithelium
2. Lamina propria

II. Submucosa:

3. Secretory portions of glands

III. Fibro-musculo-cartilaginous layer:


4. Perichondrium
5. Hyaline cartilage

IV. Adventitia

Histology slide

(H&E, high-power magnification)

LUNG

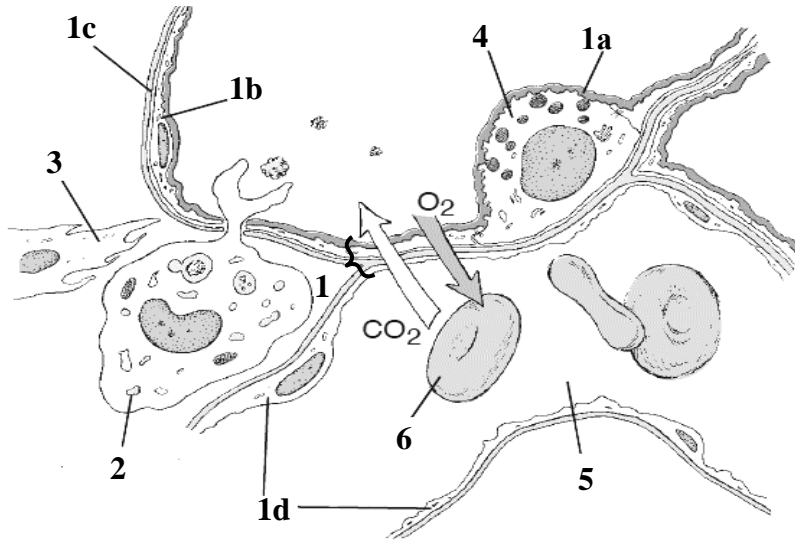


Draw intrapulmonary bronchus (A), bronchiole (B) and terminal bronchiole (C) and indicate the following structures:

1. Respiratory epithelium
2. Lamina propria
3. Muscularis mucosae
4. Bronchial glands
5. Perichondrium
6. Hyaline cartilage
7. Adventitia
8. Alveoli
9. Inter-alveolar septa

Histology slide

(H&E, low-power magnification)



Scheme of the structure of interalveolar septum and blood-air barrier

Name structures, indicated by the numbers. Color the components of blood-air barrier:

1. Blood-air barrier

- a. _____
- b. type _____ pneumocyte
- c. _____
- d. endothelial cells

2. Dust cell

3. Fibroblast

4. _____

5. Lumen of capillary

6. Erythrocyte

For notes:

THE LESSON IS COMPLETED

Teacher _____

« _____ » _____

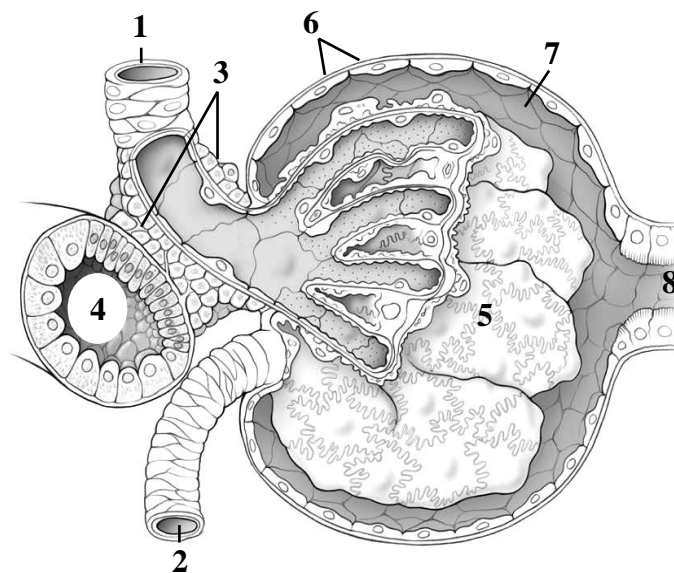
Topic 14. URINARY SYSTEM. MICROSCOPIC STRUCTURE OF THE KIDNEY, URETER, BLADDER

Control questions:

1. Embryonic development of the kidney. Histological organization of the renal cortex and medulla: cortical labyrinth, medullary rays, renal pyramids, and columns.
2. Structural and functional organization of cortical and juxtamedullary nephrons.
3. Structure and function of the renal corpuscle: the filtration membrane.
4. Histophysiology of the renal tubule (proximal convoluted tubule, loop of Henle, distal convoluted tubule) and collecting duct.
5. Cellular and histological basis of urine formation.
6. Renal blood supply: vascular organization and the unique circulation of the juxtamedullary nephrons.
7. Endocrine functions of the kidney: the juxtaglomerular apparatus and hormonal regulation of urine formation.
8. Histological organization of the ureter and urinary bladder walls.

MATERIAL FOR INDEPENDENT WORK

DIAGRAM OF THE RENAL CORPUSCLE



Scheme of histological structure

Name structures, indicated by the numbers:

1. _____ arteriole
2. _____ arteriole
3. Juxtaglomerular cells
4. _____ tubule
5. _____
6. _____ layer of
Bowman's capsule
7. Capsular space
8. _____ tubule

Color the following structures, using a different color for each:

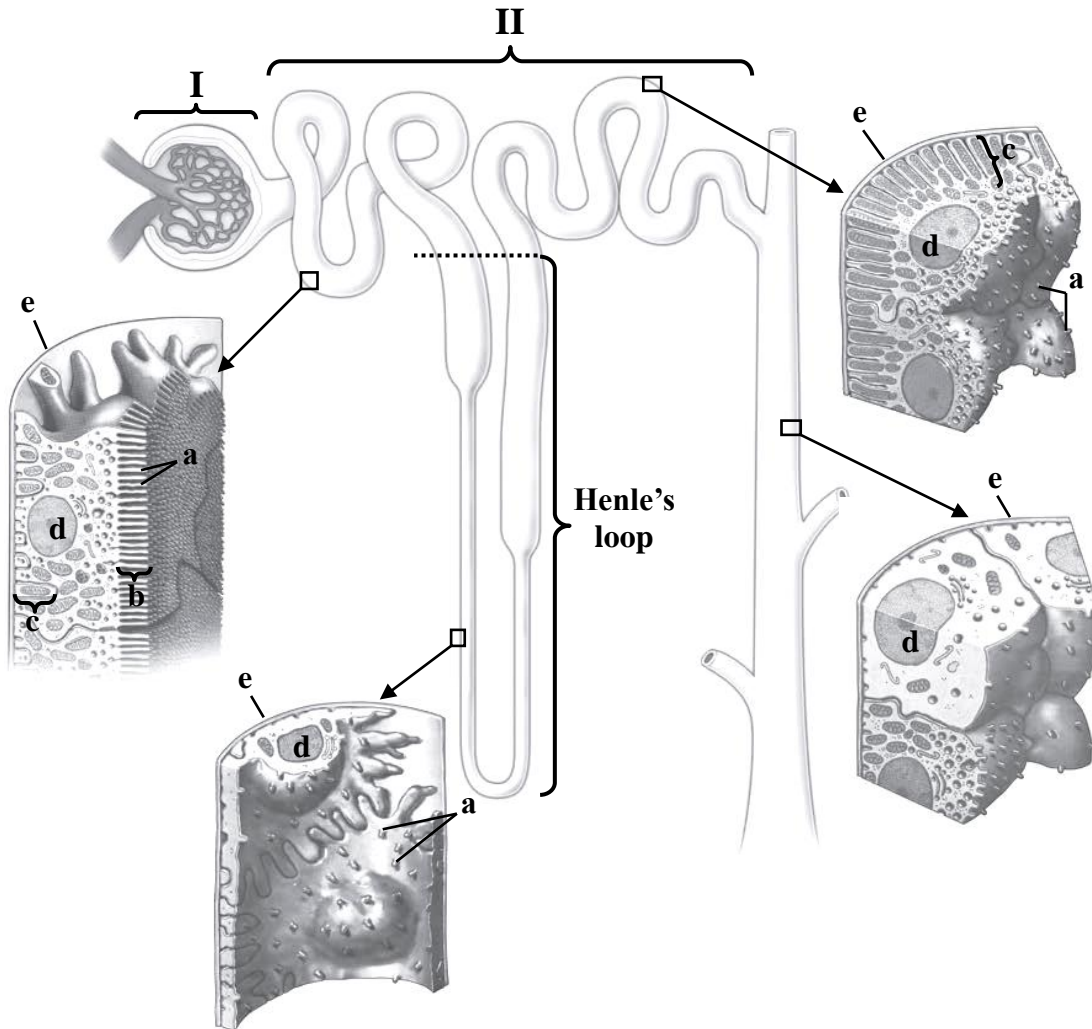


acula densa



ndothelial cells

DIAGRAM OF THE NEPHRON



Name structures, indicated by the numbers and letters:

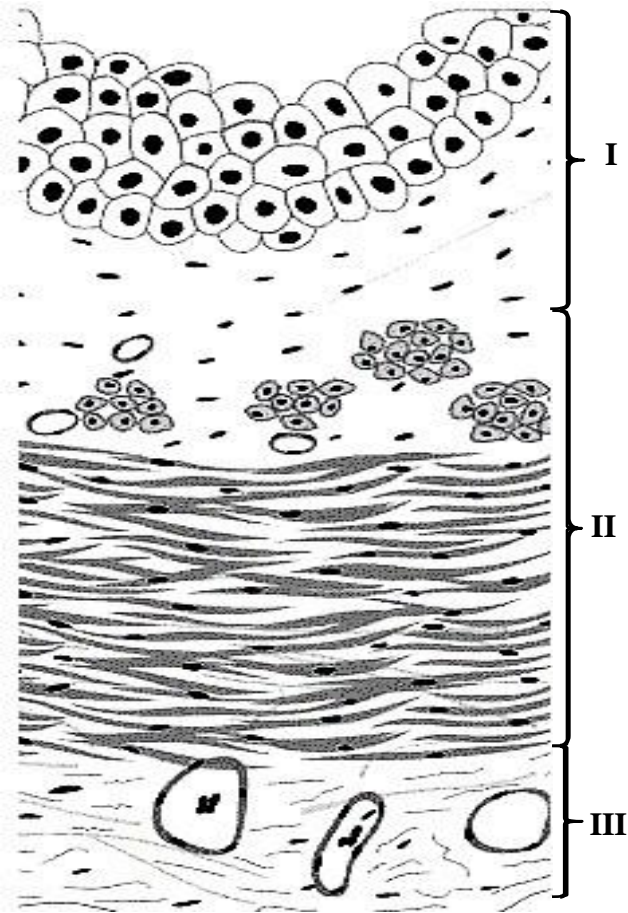
I. Renal _____
 II. Renal _____

a. _____
 b. brush border
 c. basal _____
 d. _____
 e. _____

Color the following structures,
 using a different color for each:

- Bowman's capsule
- glomerulus
- proximal convoluted tubule
- proximal straight tubule
- thin tubule
- distal straight tubule
- distal convoluted tubule
- collecting duct

URETER



Name and color the following structures:

I. _____

transitional epithelium

lamina propria

II. _____


inner longitudinal layer

outer circular layer

III. _____

Scheme of histological structure of the wall

URINARY BLADDER



Draw and indicate the following structures:

I. Mucosa:

1. Transitional epithelium

2. Lamina propria

II. Muscularis externa

III. Serosa

Histology slide

(H&E, low-power magnification)

THE LESSON IS COMPLETED

Teacher _____

« _____ »

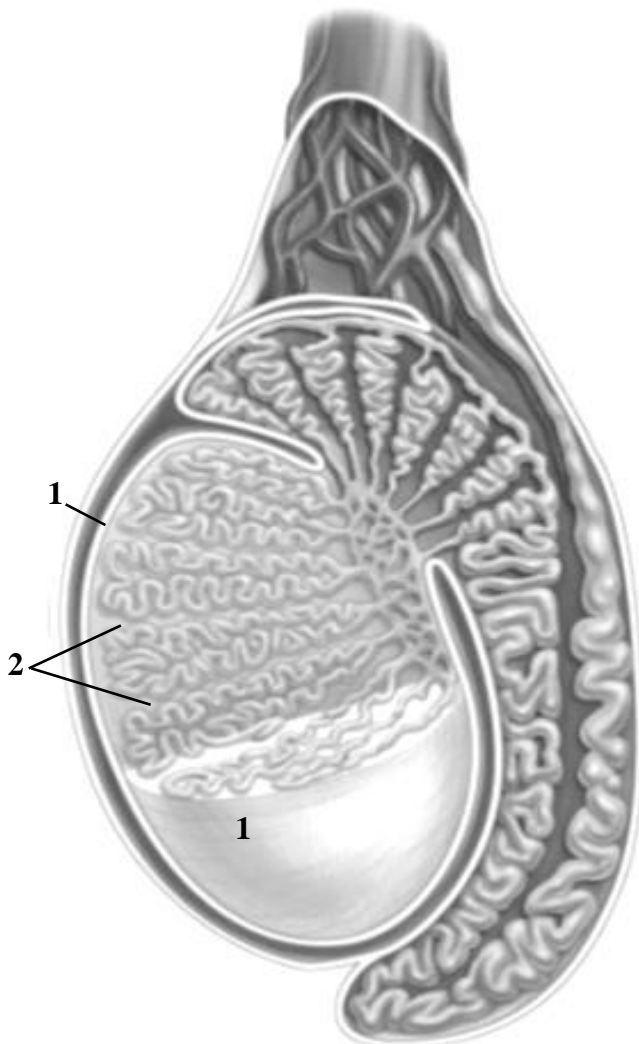
Topic 15. MICROSCOPIC STRUCTURE OF THE MALE REPRODUCTIVE SYSTEM ORGANS: TESTIS, GENITAL DUCTS, PROSTATE

Control questions:

1. Embryonic origins and general organization of the male reproductive system.
2. Histological structure of the testis.
3. Spermatogenesis: cellular stages of sperm cell development.
4. Testicular steroidogenesis (testosterone secretion). Age-related histological changes in the testis.
5. Histological structure of the epididymis, ductus deferens, ejaculatory duct.
6. Histological structure and secretory functions of the male accessory glands: seminal vesicles, prostate, and bulbourethral glands.

MATERIAL FOR INDEPENDENT WORK

TESTIS



Name structures, indicated by the numbers:

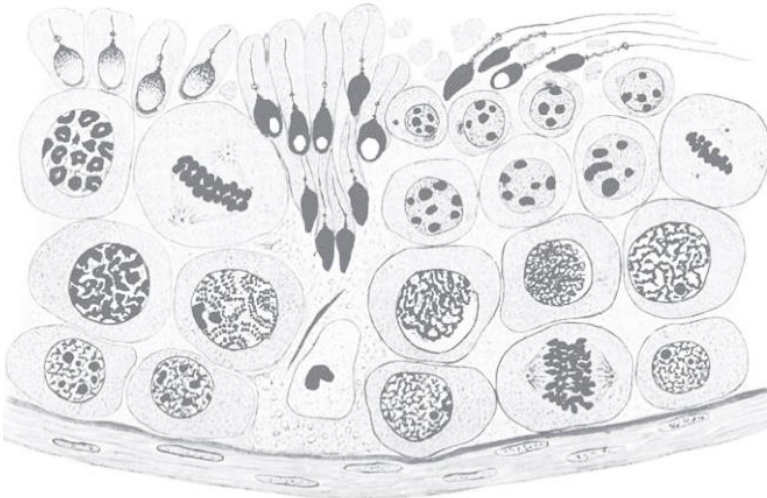
1. Tunica _____
2. _____

Color the following structures, using a different color for each:

- seminiferous tubules
- straight tubules
- rete testis
- efferent ductules
- duct of epididymis
- ductus (vas) deferens

Scheme of histological structure


SEMINIFEROUS TUBULE



Scheme of histological structure

Color the following structures, using a different color for each:

- Sertoli cells
- spermatogonia
- primary spermatocytes
- secondary spermatocytes
- spermatids
- spermatozoa



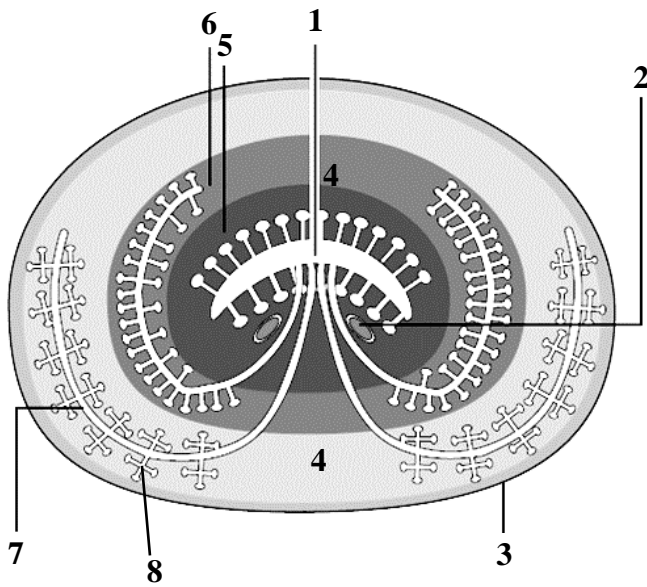
Draw and indicate the following structures:

1. Interstitial connective tissue
2. Interstitial endocrine cell (of Leydig)
3. Sustentocytes (Sertoli cell)
4. Myoid (contractile) cell
5. Spermatogonia
6. Spermatocytes
7. Spermatids

Histology slide

(H&E, high-power magnification)


PROSTATE



Scheme of structure

Name structures, indicated by the numbers:

1. _____
2. Ejaculatory ducts
3. _____
4. Fibromuscular stroma
5. _____ zone
6. _____ zone
7. _____ zone
8. _____ glands



Histology slide
(H&E, low-power magnification)

Draw and indicate the following structures:

1. Fibromuscular stroma
2. Main prostatic glands
3. Prostatic concretions

THE LESSON IS COMPLETED

Teacher _____

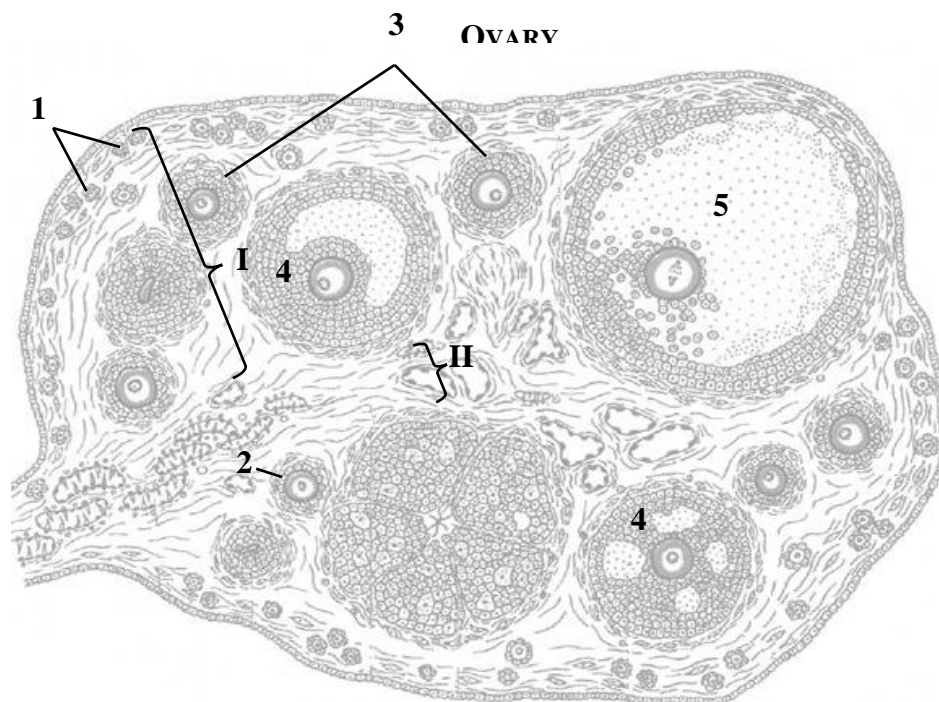
« _____ » _____

Topic 16. MICROSCOPIC STRUCTURE OF THE ORGANS OF THE FEMALE REPRODUCTIVE SYSTEM: OVARY, UTERUS

Control questions:

1. Embryonic origins and general organization of the female reproductive system.
2. Histological structure of the ovary: follicle development, atresia, and corpus luteum formation, function, and regression..
3. Oogenesis and comparative analysis with spermatogenesis.
4. Ovarian endocrine function, hormonal regulation, and age-related histological changes.
5. Histological structure of the fallopian tube wall.
6. Histological structure of the uterine tube, uterus, and vagina: wall organization and cyclical changes.
7. Phases of the menstrual cycle: endometrial transformation and hormonal control.

MATERIAL FOR INDEPENDENT WORK



Name structures, indicated by the numbers:

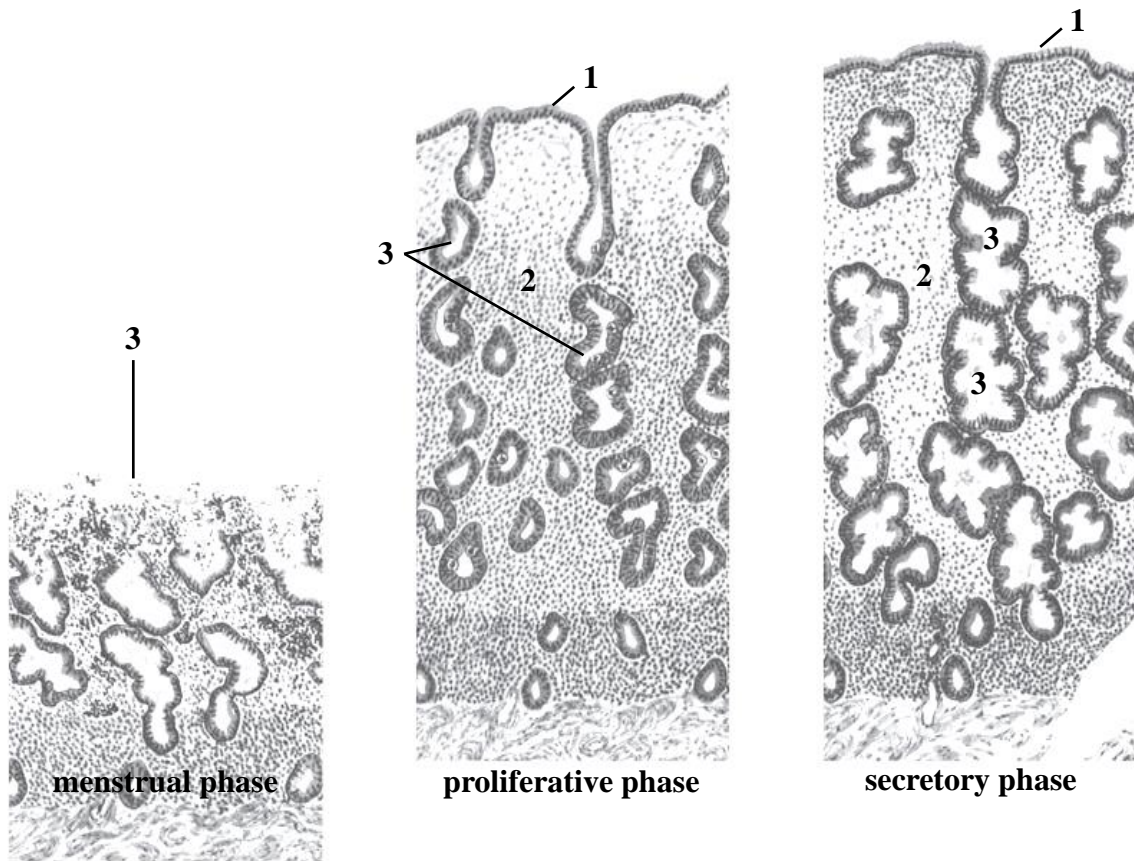
I. _____ II. _____

1. _____ follicles
2. _____ follicle
3. _____ follicles
4. _____ follicles
5. _____ follicle

Color the following structures in diagram, using a different color for each:

- | | |
|--|---|
| <input type="checkbox"/> germinal epithelium | <input type="checkbox"/> corpus albicans |
| <input type="checkbox"/> zona pellucida | <input type="checkbox"/> corpus luteum |
| <input type="checkbox"/> theca | <input type="checkbox"/> atretic follicle |
| <input type="checkbox"/> follicular antrum | |

UTERUS



Scheme of the histological structure of the endometrium in different phases of the menstrual cycle

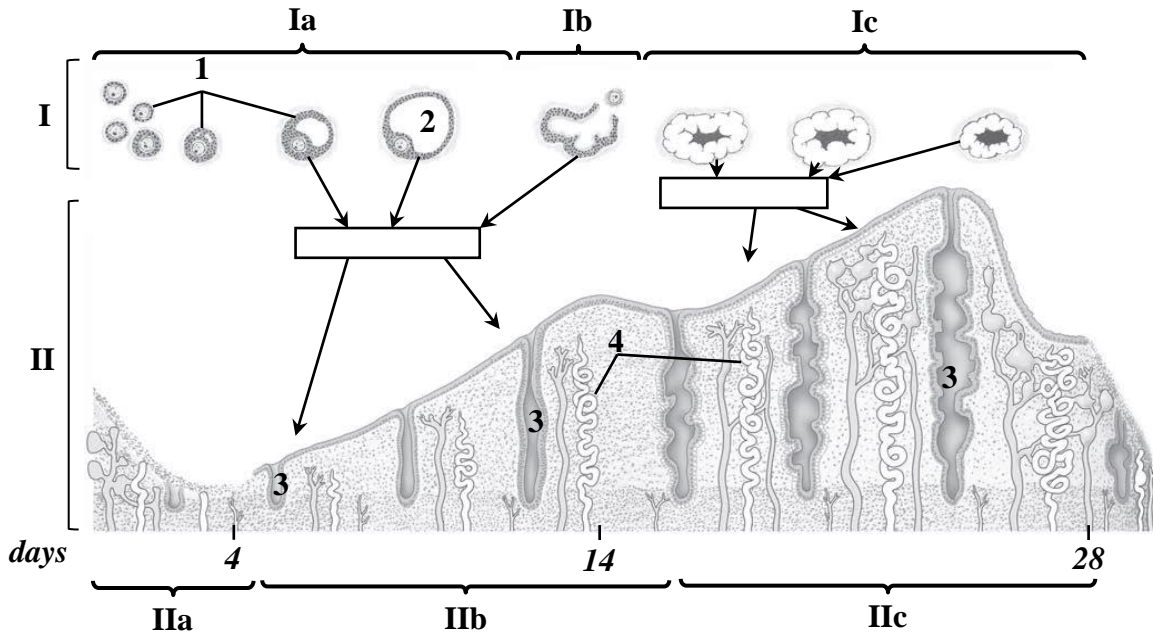
Name structures, indicated by the numbers:

- 1. _____ epithelium
- 2. _____ propria
- 3. Uterine _____

Color the following structures, using a different color for each:

stratum basalis
stratum functionalis

CYCLIC CHANGES IN OVARY AND ENDOMETRIUM ACROSS THE CYCLE



Name structures, indicated by the numbers.

Write the names of the hormones produced by the ovary on the diagram in rectangles:

I. Ovarian cycle

- a. _____ phase
- b. _____ phase
- c. _____ phase

Color the following structures, using a different color for each:

- corpora lutea
- stratum basalis
- stratum functionalis

II. Uterine cycle

- a. _____ phase
- b. _____ phase
- c. _____ phase

- 1. Growing follicles
- 2. Mature follicle
- 3. Uterine _____
- 4. _____ arteries

THE LESSON IS COMPLETED

Teacher _____

« _____ » _____

CONTENTS

Topic 1. Cardiovascular system. Microscopic structure of blood vessels and the heart wall.....	3
Topic 2. Primary lymphoid organs. Red bone marrow. Thymus.....	7
Topic 3. Secondary lymphoid organs. Lymph node. Spleen. Tonsil	10
Topic 4. Endocrine glands. Microscopic structure of the pituitary gland, epiphysis, thyroid and parathyroid glands, adrenal gland	13
Topic 5. Peripheral nervous system. Microscopic structure of the nerve, sensory and autonomic ganglia	16
Topic 6. Central nervous system. Microscopic structure of the spinal cord, cerebellar cortex and cerebral cortex	18
Topic 7. Sense organs. Microscopic structure of the eyeball and inner ear.....	21
Topic 8. Digestive system. Microscopic structure of the oral mucosa. Lip, gingiva, cheek, palate, tongue	25
Topic 9. Digestive system. Microscopic structure of the wall of the pharynx, esophagus, stomach	29
Topic 10. Digestive system. Microscopic structure of the wall of the small and large intestines.....	31
Topic 11. Digestive system. Microscopic structure of the liver and pancreas.....	33
Topic 12. Integumentary system. Microscopic structure of the skin and its derivatives.....	36
Topic 13. Respiratory system. microscopic structure of the conducting and respiratory portions	40
Topic 14. Urinary system. Microscopic structure of the kidney, ureter, bladder	43
Topic 15. Microscopic structure of the male reproductive system organs: testis, genital ducts, prostate.....	46
Topic 16. Microscopic structure of the organs of the female reproductive system: ovary, uterus.....	49