

МИНИСТЕРСТВО ЗДРАВООХРАНЕНИЯ РЕСПУБЛИКИ БЕЛАРУСЬ
БЕЛОРУССКИЙ ГОСУДАРСТВЕННЫЙ МЕДИЦИНСКИЙ УНИВЕРСИТЕТ
КАФЕДРА ХИРУРГИЧЕСКОЙ СТОМАТОЛОГИИ

**ХИРУРГИЧЕСКАЯ СТОМАТОЛОГИЯ
И ПРОПЕДЕВТИКА ХИРУРГИЧЕСКИХ ЗАБОЛЕВАНИЙ
ЧЕЛЮСТНО-ЛИЦЕВОЙ ОБЛАСТИ**

**ORAL SURGERY AND PROPAEDEUTIC
OF MAXILLOFACIAL SURGICAL DISEASES**

Практикум для студентов,
обучающихся по специальности «Стоматология»
в 6-м семестре

2-е издание



Минск БГМУ 2026

УДК [616.31+616.716.8]-089(076.5)(075.8)
ББК 56.6я73
Х50

Рекомендовано Научно-методическим советом университета
в качестве практикума 17.12.2025 г., протокол № 4

А в т о р ы: д-р мед. наук, проф., зав. каф. хирургической стоматологии И. О. Походенько-Чудакова; канд. мед. наук, доц. Е. В. Максимович; д-р мед. наук, доц. Т. Л. Шевела; канд. мед. наук, доц. Н. Н. Чешко; канд. мед. наук, доц. В. Л. Евтухов; ст. преп. Е. Ю. Слижикова

Р е ц е н з е н т ы: канд. мед. наук, доц., зав. каф. эндодонтии Белорусского государственного медицинского университета В. А. Андреева; каф. челюстно-лицевой хирургии и хирургической стоматологии с курсом ФПК и ПК Витебского государственного ордена Дружбы народов медицинского университета

Хирургическая стоматология и пропедевтика хирургических заболеваний
Х50 челюстно-лицевой области = Oral Surgery and Propaedeutic of Maxillofacial Surgical Diseases : практикум для студентов, обучающихся по специальности «Стоматология» в 6-м семестре / И. О. Походенько-Чудакова, Е. В. Максимович, Т. Л. Шевела [и др.]. – 2-е изд. – Минск : БГМУ, 2026. – 100 с.

ISBN 978-985-21-2140-8.

Представлены контрольные вопросы и задания для практических занятий согласно календарно-тематическому плану на 6-й семестр. Первое издание вышло в 2024 году.

Предназначен для студентов 3-го курса медицинского факультета иностранных учащихся, обучающихся по специальности 1-79 01 07 «Стоматология».

УДК [616.31+616.716.8]-089(076.5)(075.8)
ББК 56.6я73

ISBN 978-985-21-2140-8

© УО «Белорусский государственный
медицинский университет», 2026

LIST OF ABBREVIATIONS AND SYMBOLS

- ABT — antibacterial therapy
- HIV — Human Immunodeficiency Virus
- TD — temporary disability
- MS — maxillary sinus
- MSS — maxillary sinusitis
- IIP — infectious inflammatory process
- IIS — integral indicator of severity
- CBCT — cone beam computed tomography
- CT — computed tomography
- LII — leukocyte intoxication index
- LIIO — leukocyte intoxication index by Ostrovsky
- PhE — physiotherapy exercises
- ICD — International Classification of Diseases
- INR — international normalized attitude
- OPTG — orthopantomography
- PON — multiple organ failure
- PTI — prothrombin index
- PST — primary surgical treatment
- OF — oral fluid
- SIR — a systemic inflammatory response
- AIDS — Acquired Immunodeficiency Syndrome
- SIRS — systemic inflammatory response syndrome
- SERW — students' educational research work
- NII — nuclear intoxication index

TOPICS OF STUDENTS' EDUCATIONAL RESEARCH WORK (SERW)

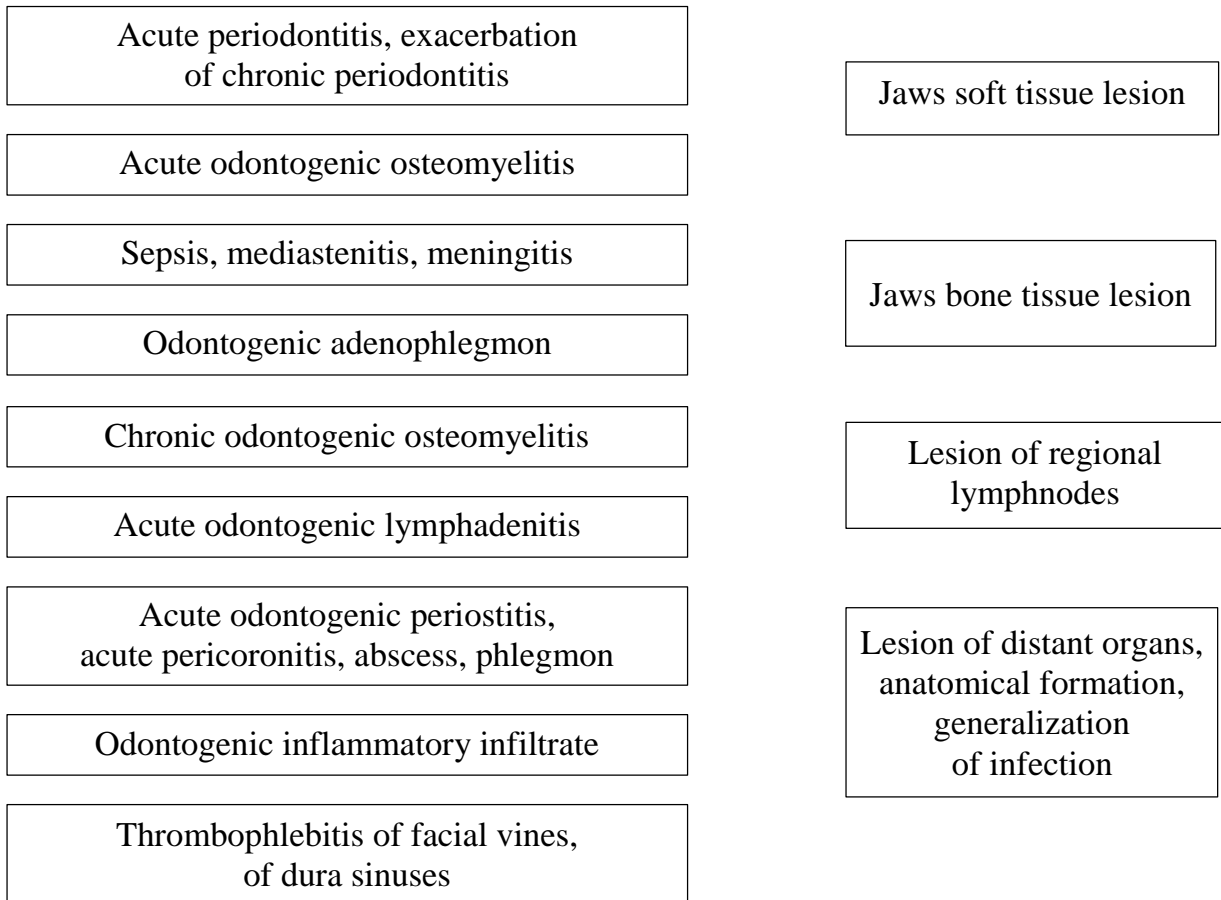
1. Techniques of tooth-saving operations in the treatment of chronic apical periodontitis.
2. Features of pericoronarotomy, pericoronarectomy operations.
3. Acute odontogenic osteomyelitis of the jaws. Etiology. Pathogenesis. Diagnostics. Treatment. Prevention of complications.
4. Chronic odontogenic osteomyelitis of the jaws. Etiology. Pathogenesis. Diagnostics. Treatment.
5. Chronic ossifying osteomyelitis Garre. Features of the clinical picture. Diagnostics. Treatment.
6. Differential diagnosis of acute odontogenic infectious inflammatory diseases in maxillofacial region and neck.
7. Features of thrombophlebitis of the facial veins. Contributing factors. M. A. Sreseli phenomenon.
8. Biofilms and their effect to the clinical picture, clinical course and treatment of infectious inflammatory diseases in the maxillofacial region.
9. The history of the odontogenic sepsis study.
10. Emergency and preventive tracheostomy. Anatomical and topographic landmarks. Tools. Methodology.
11. The principles of the primary surgical treatment of the infectious inflammatory focus in the maxillofacial region and neck.
12. Drainages, used in septic maxillofacial surgery.
13. Modern complex treatment of patients with anaerobic infection of the maxillofacial region and neck.
14. The principles of modern drug therapy of infectious inflammatory processes (IIP) of the maxillofacial region and neck.
15. Actinomycosis of the maxillofacial region and neck. Clinic. Diagnostics. Treatment. Prevention.
16. Manifestations of syphilis in the maxillofacial region. Features of the clinic, diagnosis, treatment, prevention.
17. Tuberculosis and its manifestations in the maxillofacial region and the neck. Features of the clinic, diagnosis, treatment, prevention.
18. The manifestation of the human immunodeficiency virus (HIV) in the maxillofacial region. Features of the clinic, diagnosis, treatment, prevention.
19. Odontogenic maxillary sinusitis. Modern theories of the etiology and diagnosis.
20. Modern treatment methods of odontogenic maxillary sinusitis.

Theme 1
ODONTOGENIC INFECTIOUS INFLAMMATORY DISEASES
OF MAXILLOFACIAL AREA AND NECK

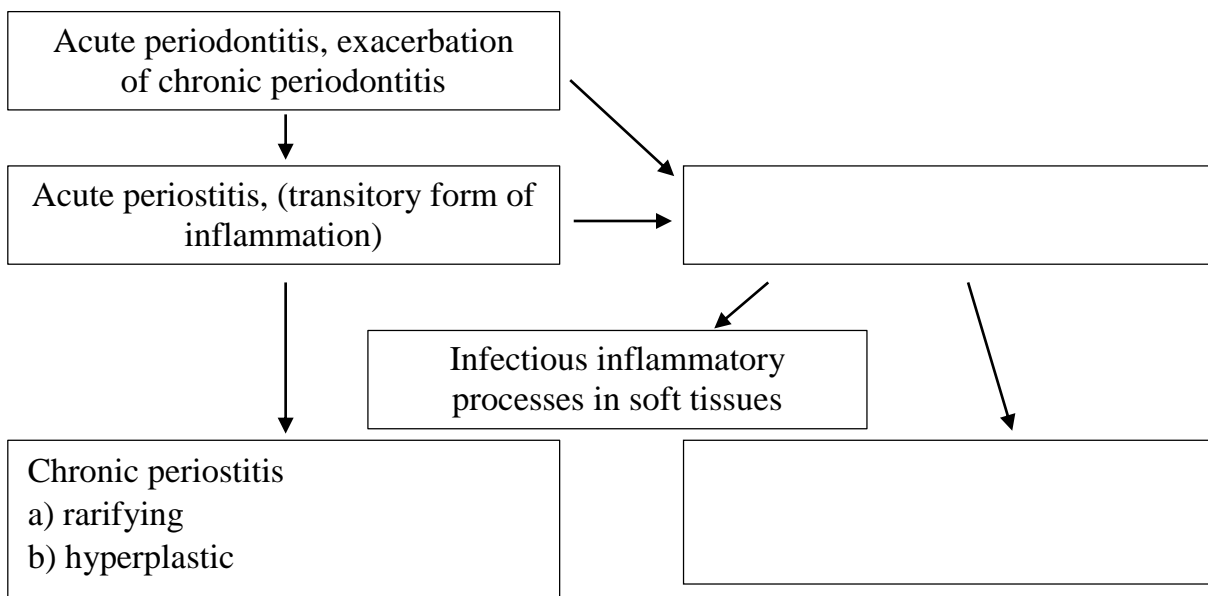
Control questions on the topic:

1. List the causative agents of odontogenic inflammatory diseases.
2. The role of micro- and macroorganisms in the occurrence, development and course of the disease.
3. What determines the clinical course of the infectious inflammatory process?
4. The evidence of the presence of anaerobes in the clinical course of the inflammatory process. Clinical signs of anaerobic infection.
5. Describe the representatives of obligate anaerobic flora (fusobacteria, bacteroids, peptostreptococci).
6. What are the pathways of acute odontogenic infection spreading?
7. Describe the role of specific and nonspecific immunity in the occurrence and development of the infectious inflammatory disease in the maxillofacial region and neck.
8. Modern classification of acute odontogenic inflammatory diseases in the maxillofacial region and neck.
9. List the factors that determine the amount of tissue lesion in the maxillofacial region.
10. What are the pathways of acute odontogenic infection spreading?
11. Describe the role of specific and nonspecific immunity in the occurrence and development of the infectious inflammatory process in the maxillofacial region and neck.
12. Relevant classification of acute odontogenic inflammatory diseases of the maxillofacial region and neck.
13. List the factors that determine the amount of tissue damage in the maxillofacial region.

1. Specify the classification of acute odontogenic infectious inflammatory diseases of the maxillofacial region and neck, connecting the classes of diseases and nosology with arrows.



2. Fill out the dynamics scheme of odontogenic infection according to N. A. Gruzdev.



3. What are the representatives of the microflora of the oral cavity?

- 1) Anaerobic sticks _____
- 2) Gram-negative anaerobic bacteria _____
- 3) Gram-positive anaerobic bacteria _____
- 4) Stabilizing resident microflora _____

4. Complete the missing.

After the invasion of infectious agent, the patient's organism general reaction severity, characterized by a violation of the homeostat, depends on:

- 1) cultural qualities _____ disease;
- 2) _____ microbial agent;
- 3) the ability of the microorganism to form _____;
- 4) _____ patient's organism.

5. Highlight the pathways of odontogenic infection that can be classified as retrograde:

- intracanalicular path (through the root canal of the «causal» tooth),
- periodontal (through a pathological gingival pocket in a case of marginal periodontitis),
- traumatic,
- hematogenous,
- lymphogenous,
- in length or contact (for example, in a case of violation of the integrity of the alveolar process mucous, the inflammatory process extends to the periosteum, bone, etc.).

6. Arrow the concepts and definitions.

serous, serous-purulent or purulent-necrotic inflammation of the gums above the erupting tooth

Odontogenic infection is

Odontogenic adenophlegmon is

the spread of the microbial agent from the cavity of the tooth affected by complicated caries through periodontium, and then through the system of Folkman and Haversian bone canals into the bone marrow channels of the alveolar ridge

diffuse purulent, purulent-necrotic inflammation of the regional lymph node with the spread to two, three or more anatomical spaces, areas of the cellular tissue, when lesions of the teeth hard tissues, lesions in the epithelium of the gum, and gingival attachment are the entrance gate for infection

Acute pericoronitis is

7. The reaction of one from three types develops because of the occurrence and development of an infectious inflammatory process in the patient's organism, depending on the individual level of the patient's resistance (add the missing type):

_____;

hyperergic;

anergic.

8. Connect with arrows nosology and its pathognomonic signs.

Acute odontogenic periostitis	Sharply painful on palpation infiltration on the surface of the alveolar ridge and jaw in the zone of projection of the «causal» tooth, which was the entrance gate of the infection
Odontogenic abscess	Sharply painful limited infiltration in the parajaws soft tissues located in one anatomical space
Periodontitis acute / chronic in exacerbation	Mild or moderate signs of intoxication
	Inflammatory truisms of jaws
	There are no inflammatory signs from para jaws soft tissues
	Appearance of pain in a case of pressing or percussion on «causative» tooth

9. There are several signs of the patient's organism hyperergic reaction like response to the invasion of an infectious agent which can be characterized (add the missing):

- the temperature increases over 38 °C, the difference between morning and evening temperatures is more than ____ °C;
- expressed _____ to the left of peripheral blood;
- appearance of anisocytosis and _____;
- appearance of mast and / or _____ cells in peripheral blood;
- appearance of C-reactive protein.

10. In parentheses, using the numbers indicate the correct sequence of the main symptoms of the inflammatory reaction, adding the name of the symptom in English next to it:

rubor – () – _____,

tumor – () – _____,

color – () – _____,

function lesae – () – _____,

dolor – () – _____.

11. Write in empty lines the name of the patient's response, developing as a reaction to the invasion of the infectious agent.

An increase in body temperature, a shift to the left in the leukocyte formula of peripheral blood, an accelerated erythrocyte sedimentation rate (ESR), are characteristic of _____ reaction.

_____ reaction develops in a case of reduced resistance of the macroorganism, because of decreasing in humoral and cellular immunity, when the patient's organism does not react or reacts very weakly to the invasion of an infectious agent.

12. Connect the class of diseases from the classification N. N. Bozhanova et al., (1990) of acute odontogenic inflammatory processes and the nosologies with the arrows.

1	Acute periodontitis	Odontogenic abscess periodontitis	
	Acute pericoronitis		Mediastinitis
	Acute odontogenic purulent lymphadenitis		Meningitis
2	Odontogenic adenophlegmon periodontitis		Meningoencephalitis
	Exacerbation of chronic periodontitis		Brain abscess
	3		Thrombophlebitis of facial veins
Acute odontogenic osteomyelitis			Thrombosis of the dura mater sinuses
4			Acute odontogenic periostitis
	Odontogenic inflammatory infiltrate		

Theme 2
APICAL PERIODONTITIS.
SURGICAL TREATMENT OF APICAL PERIODONTITIS

Control questions on the topic:

1. Indicate the anatomical structure of the tooth periodontium, specify the blood supply and innervation of the teeth in the upper and lower jaws.
2. List the pathways of infection in the tooth periodontium.
3. Indicate the predominantly microflora in the foci of inflammation in apical periodontitis.
4. Describe the classification of apical periodontitis (according to I. G. Lukomsky, according to A. I. Evdokimov, ICD-10).
5. Describe the clinical picture of acute apical periodontitis.
6. Describe the clinical picture of chronic apical periodontitis and chronic apical periodontitis in exacerbation.
7. What special examination methods are used for apical periodontitis?
8. Describe diagnosis and differential diagnosis of chronic forms of apical periodontitis.
9. Name the indications and contraindications for apex root resection operation.
10. Describe the technique of the apex root resection operation, name the necessary tools and materials for its performing.
11. Name the indications and contraindications for the hemisection operation.
12. Describe the technique of the hemisection operation, name the necessary tools and materials for its performing.
13. Name the indications and contraindications for the tooth root amputation operation.
14. Describe the technique of the tooth root amputation operation, list the necessary tools and materials for its performing.

1. Define apical periodontitis.

Apical periodontitis is _____

2. Define marginal periodontitis.

Marginal periodontitis is _____

3. Highlight the existing pathways for the spread of the infectious agent to the periodontal tissue:

- intracanalicular (through the root canal of the «causal» tooth);
- periodontal (through a pathological gingival pocket with marginal periodontitis);
- traumatic;
- hematogenous;
- airborne;
- lymphogenous;
- in extent (for example, in a case of violation of the integrity of the mucous membrane of the alveolar process, the inflammatory process extends to the periosteum, bone, etc.).

4. Fill in the table.

Clinical symptoms	Acute periodontitis	Acute pulpitis
Pain characteristics		Spontaneous, night
Pain irradiation		
Pain from chemical and temperature stimuli		
Tooth percussion	Sharply painful	
Probing of caries cavity		
Tooth statics(mobility)		
Swelling and hyperemia of the gums in the projection of the tooth root		

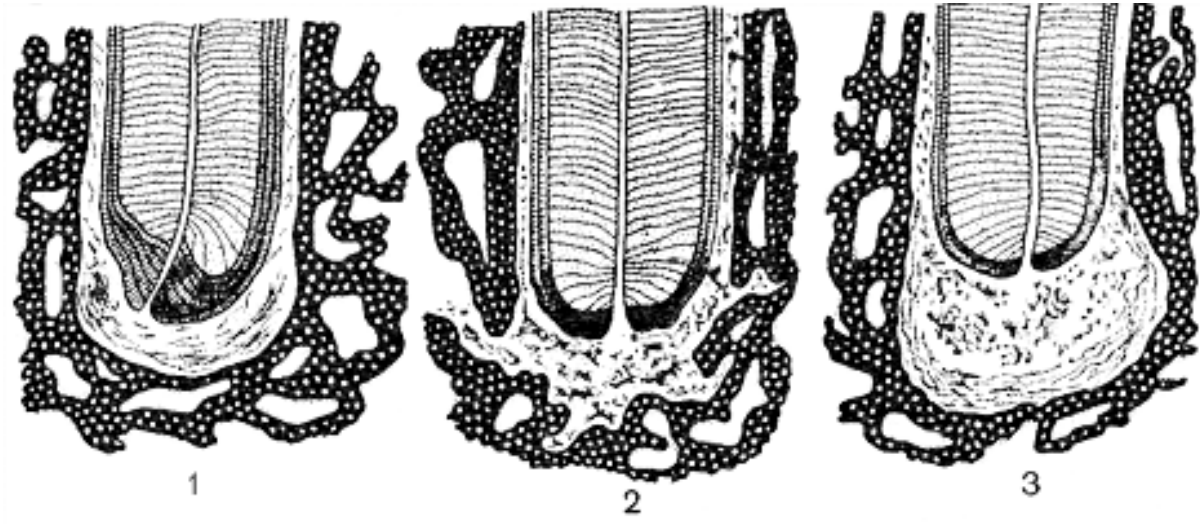
5. Classification of apical periodontitis according etiology:

1) _____ (most often develops after incorrect treatment of pulpitis, when potent drugs fall into the periodontium (for example, devitalizing paste), after root canal washing with antiseptics (sodium hypochloride), root canal filling with violation of the technologies of endodontic treatment methods (putting of filling material designed to fill the root canal over the root apex where they are capable of exerting a toxic effect on tissues, for example, pastes containing eugenol, phosphate cement);

2) _____ (arises as a result of a single traumatic impact on the tooth (for example, when it is struck or dropped), and also as a result of chronic injury (when the fillings are «overestimated» when overloaded, due to the absence of adjacent teeth));

3) _____ (more often it is a complication of caries, may be associated with the spreading of the inflammatory process from the pathological gingival pocket, by contact way in maxillary sinusitis, osteomyelitis).

6. Sign the types of chronic periodontitis and justify your choice.



1. _____

2. _____

3. _____

7. Highlight from the listed characteristics those that are included in the list of requirements for materials for retrograde root canal filling:

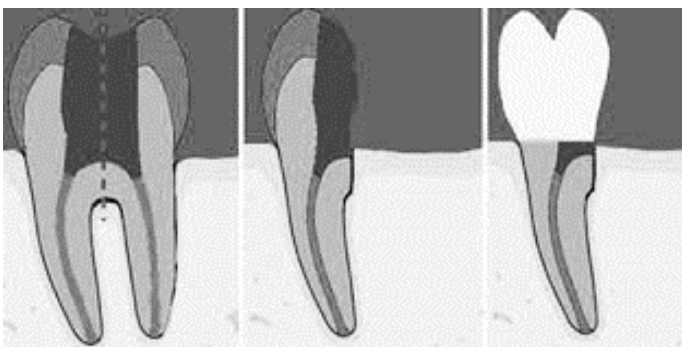
- radiopacity;
- biocompatibility;
- the need for mechanical retention;
- micro-leakage;
- multi-stage methodology;
- hydrophobicity;
- using in a humid environment;
- nonrestorable material.

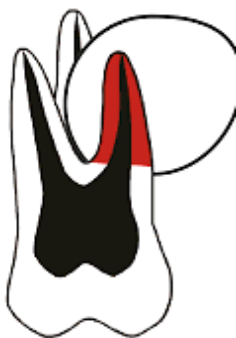8. It is necessary to connect the indications and contraindications for tooth-saving operations with arrows.

incomplete filling of the curved root canal	tooth apex root (not more than 1/3 of the length from the apex)	moving the filling material beyond the tooth root apex
INDICATIONS		CONTRINDICATIONS
the presence of tooth root apex granulomas, in a case of violation of tooth statics (II – III mobility degree)		the presence of acute or exacerbation of chronic periodontitis of the tooth, which is planned for surgery

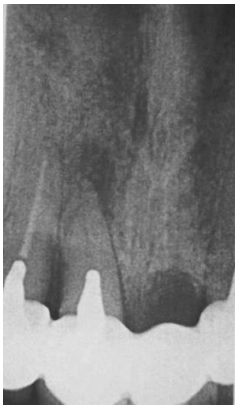9. Name the types of tooth-saving operations.



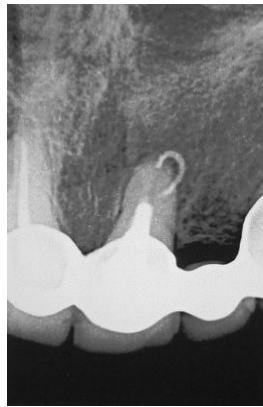



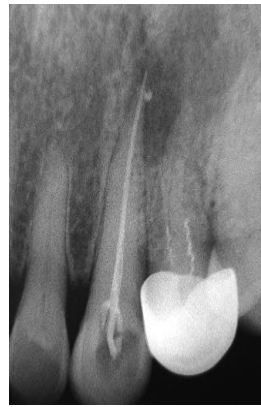10. Indicate the mistakes that were made during endodontic treatment of root canals.



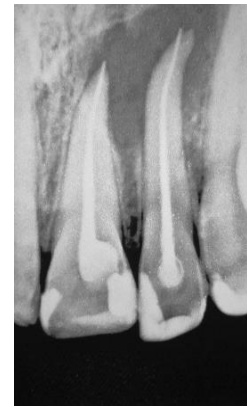1



2



3



4

1) _____;

2) _____;

3) _____;

4) _____;

11. Indicate, by connecting with arrows, the correspondence of the pathohistological picture and the type of periapical granulomas.

simple granuloma

fibrous capsule with granulation tissue penetrated by epithelial strands

epithelial granuloma

granulation tissue infiltrated by lymphocytes, macrophages, white blood cells

cystogranuloma

fibrous capsule with epithelial lining with the germination of blood vessels and histiocytic elements

Theme 3
DISEASES OF ERUPTION, RETENTION, DYSTOPIA

Control questions on the topic:

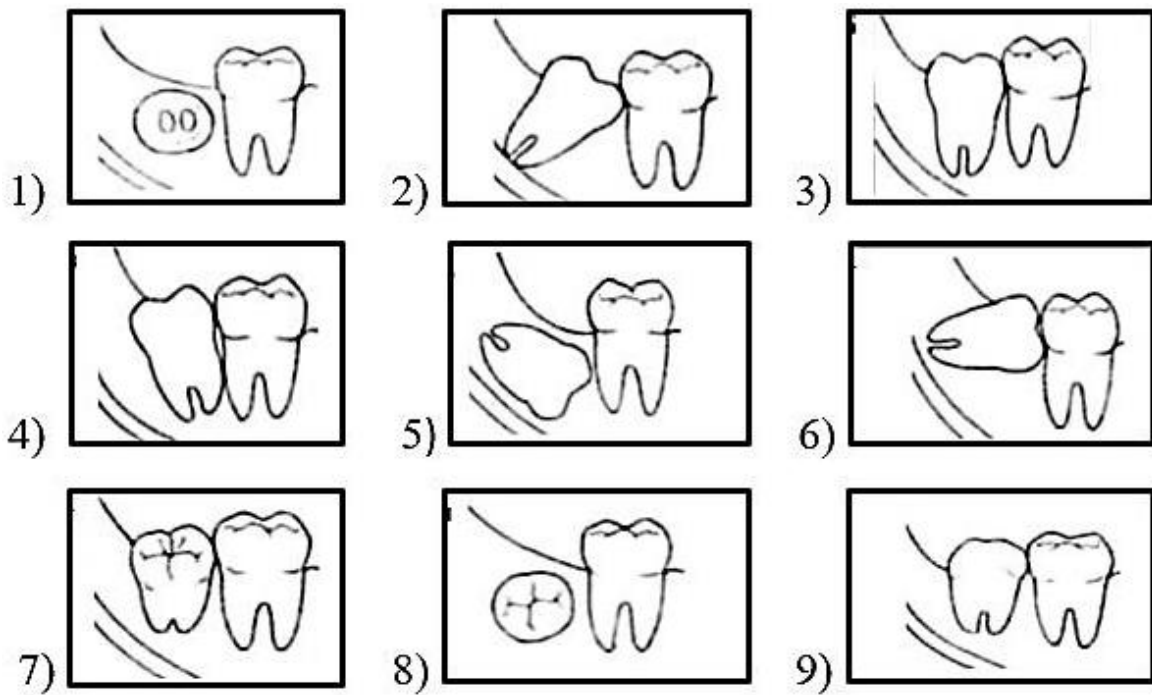
1. Name the diseases that are included in the «Eruption Diseases» section.
2. Indicate the etiology, pathogenesis of erupting diseases.
3. Name the definitions: dystopia, retention, partly erupting teeth, indicating which of them most often and in what situations lead to erupting diseases.
4. Name modern diagnostic methods that are used for erupting diseases.
5. Describe the clinical picture and possible complications of pericoronitis.
6. Describe the clinical and radiological picture of dystopia (retention and partly-eruption) of the teeth. Indicate possible complications.
7. Indicate the possible spread ways of the inflammatory process in a case of pericoronaritis of the third lower molar.
8. Name the indications for the removal of a dystopian (impacted and partly erupted) tooth in a case of pericoronitis.
9. What are the methods of surgical treatment in a case of pericoronaritis. List the technic stages. Perform a comparative assessment.
10. List the components of the complex treatment used for erupting diseases.
11. Indicate the list of absolute indications for the removal of dystopian (partly-erupted and impacted teeth) in the presence of an inflammatory process in adjacent tissues.

1. Indicate, by connecting with arrows, the correspondence of definitions.

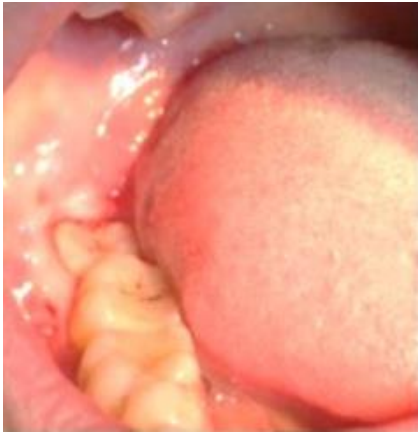Distopia	The location of the erupting tooth outside the dental
Retention	The location of the tooth outside the dental arch
Partial eruption	The location of the tooth inside the bone tissue
	Tooth that does not completely erupt through bone or mucous membranes

2. Indicate in parentheses the correspondence of the figure and the corresponding signature of the spatial arrangement of the third molars:

- medial slope / inclination (___);
- vertical position (___);
- distal slope (___);
- horizontal position (___);
- inversion (___);
- buccal slope (___);
- lingual slope (___);
- buccoverversion (___);
- lingueversion (___).

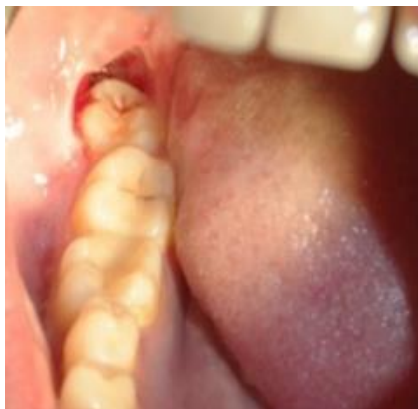

3. Describe the clinical picture and indicate the name of the surgical treatment of pericoronaritis.



Clinical picture _____

Operation _____



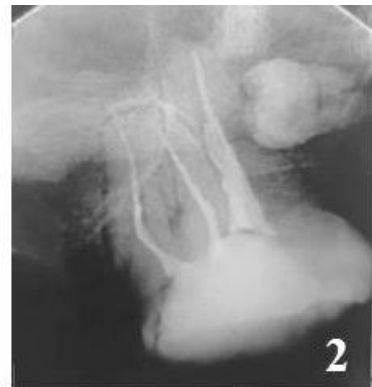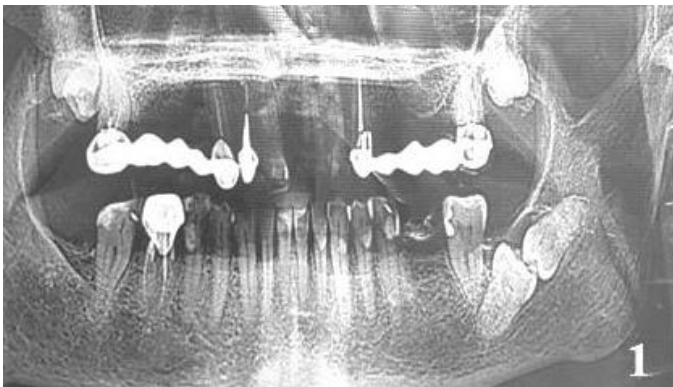Clinical picture _____

Operation _____

4. Choose and highlight possible pathways of infection in a case of pericoronaritis:

- | | |
|--|-----------------------------------|
| 1) to the floor of mouth / oral cavity bottom; | 5) temporal area; |
| 2) to buccal area; | 6) tonsillars; |
| 3) pterygomandible space; | 7) maxillary sinus; |
| 4) parapharyngeal space; | 8) the sinuses of the dura mater. |

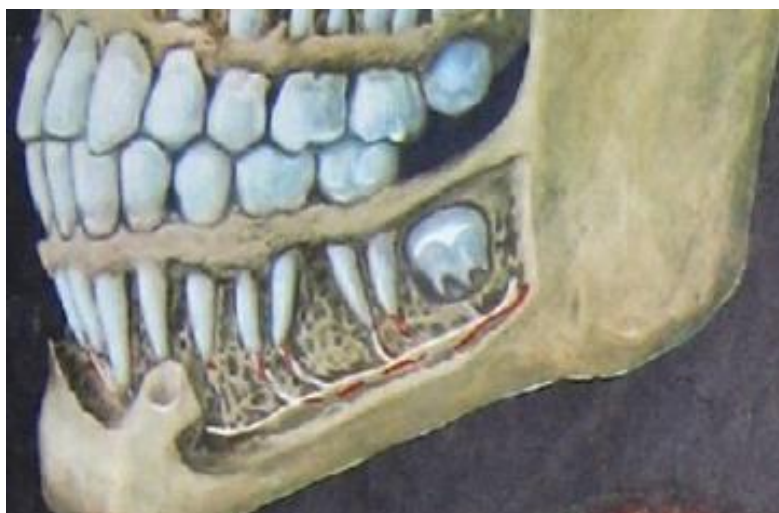5. Describe the Xray picture, write a diagnosis.



1) _____

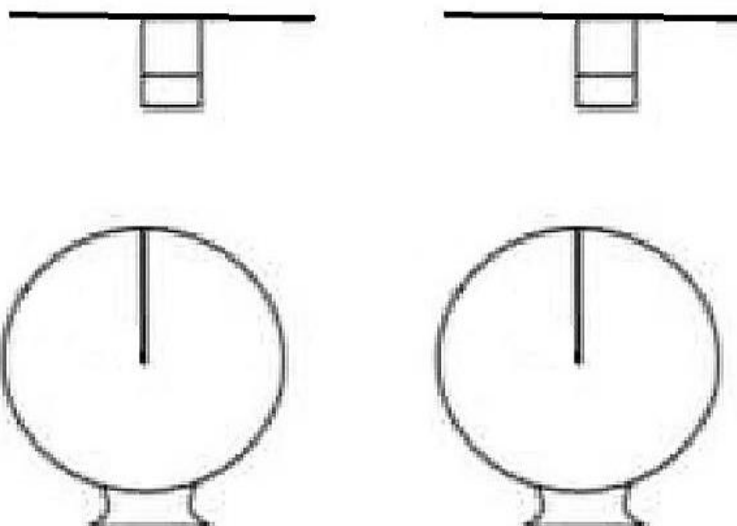
2) _____

6. Draw in the picture and underline from the following the correct features that determine the complexity of the operation of atypical removal of third molars.



- 1) length, shape and number of roots;
- 2) distance between the tooth and the mandibular canal;
- 3) the depth of the tooth in the jaw;
- 4) tooth slope angle;
- 5) distance to the first premolar;
- 6) distance from the distal surface of the second molar to the front border of the jaw branch.

7. Draw the correct position of the back of the chair (on the diagram of the head end) with a dotted line and around the circle — mark the dial with an arrow and indicate the position of the doctor during the operation of atypical tooth extraction.



- 1) right upper third molar (1.8);
- 2) left lower third molar (3.8).

8. Choose from the following the correct principles of ergonomics during the operation of atypical removal of third molars and highlight them:

- 1) fixation of soft tissues and mucoperiosteal flap;
- 2) protection of adjacent teeth;
- 3) fixation of the lower jaw by assistant;
- 4) stabilization of the patient's head;
- 5) fixation of the patient's lower jaw with the doctor's left hand;
- 6) tactile sensations.

9. Evaluate the list of characteristic symptoms, determine which of the diagnoses (acute pericoronitis, acute periodontitis, acute periostitis) it corresponds and sign.

Increase in body temperature 37–37,5 °C, intense pain in the retromolar region, irradiating pain, hyperemia of the overhanging mucous «hood» over the tooth, pain during swallowing, limited mouth opening

Increase in body temperature 37 °C, intense pain during biting, irradiating pain along the branches of the trigeminal nerve, hyperemia and edema of the mucous membrane of the alveolar process or alveolar part in the projection of the apex of the root

Increase in body temperature of 38 °C, tooth percussion is painful, the gum is hyperemic, swollen, the transitional fold is smoothed

10. Choose and highlight the correct etiological factors that determine the choice of removal of the third molar with pericoronitis:

- 1) the location of the tooth in the dental arch;
- 2) the buccal location of the tooth and the presence of a traumatic ulcer of the mucous membrane of the cheek in the projection of its crown;
- 3) an increase in the inflammatory process after pericoronarectomy;
- 4) the patient has a history of chronic diseases (diabetes, pyelonephritis, endocarditis);
- 5) constant biting of the lateral surface of the tongue with a third molar;
- 6) malocclusion and the need for orthodontic treatment.

11. Connect the arrows with the type of surgical intervention and the corresponding description.

Complete excision of the mucous membrane in the area of the erupting tooth crown	Periostotomy
Dissection of the mucous «hood» over the tooth crown, allowing to expose its chewing surface	Pericoronarectomy
Carrying out an incision along the transitional fold of the mucous with dissection of the periosteum	Pericoronarotomy
Carrying out an incision in the area of the tooth that has not been cut, with peeling of the muco-periosteal flap and skeletonization of the cortical plate in the area of the causative tooth	One of the stages of atypical tooth extraction

Theme 4

PERIOSTITIS OF THE JAWS

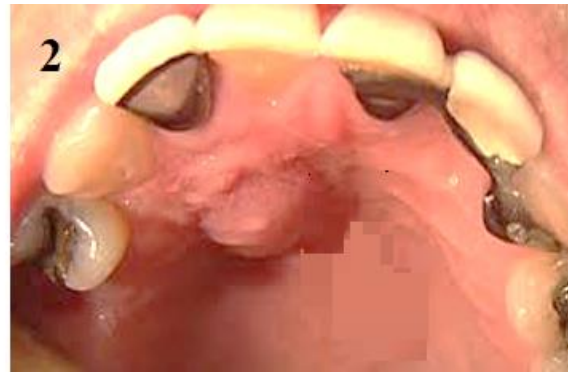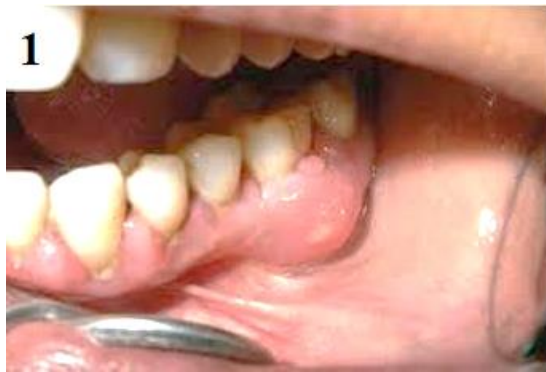Control questions on the topic:

1. What are the etiological factors for the development of acute odontogenic periostitis of the jaw?
2. Describe the pathogenesis, pathological anatomy of the jaw periostitis.
3. Indicate anamnestic data and patient complaints which characterize periostitis of the jaw.
4. Name the classifications of jaw periostitis known to you.
5. Specify the features of the clinical course of periostitis in the region of the upper and lower jaws.
6. What are the special methods for examining patients with periostitis of the jaw?
7. Name the examination management of a patient with acute purulent (serous) periostitis of the jaw.
8. Which of the X-ray research methods will differentiate acute purulent and acute serous jaw periostitis?
9. Indicate what the extent of the incision will depend on when performing a periostotomy in a patient with acute purulent periostitis.
10. Name the diseases that are most similar in development, clinical picture and course with periostitis of the jaw and should be differentiated with it.
11. What are the stages of the primary surgical treatment of the infectious inflammatory focus in periostitis of the jaw?
12. Determine the tactics according to the «causal» tooth in a patient with acute purulent periostitis of the jaw.
13. Write a complex treatment management for odontogenic acute purulent periostitis of the jaw.

1. Select and underline the diagnoses that may be complicated by acute serous or purulent periostitis:

- 1) acute and exacerbation of chronic periodontitis;
- 2) pericoronitis;
- 3) maxillary rhinogenic sinusitis;
- 4) radicular cyst;
- 5) acute pulpitis;
- 6) atypical tooth extraction;
- 7) alveolitis;
- 8) operation — dental implantation;
- 9) infiltration anesthesia.

2. In Figures 1 and 2, draw a section line that shows a correct length of an incision and indicate with the arrow the direction of periostotomy.



3. Name the antibacterial drugs and their daily dose that are used for treatment of acute purulent periostitis:

- 1) group of β -lactam antibiotics _____
_____ ;
- 2) macrolide group _____
_____ ;
- 3) fluoroquinolone group _____
_____ ;
- 4) cephalosporin group _____
_____ ;

4. Analyze and connect the clinical signs with arrows and the diagnoses of acute serous and purulent periostitis based on them.

Asymmetry of face because of soft tissue swelling	Acute serosal periostitis
Skin in maxilla-facial region is of physiological colour	
Skin hyperemia in the region of inflammatory process, local hypertermia	Acute purulent periostitis
Permanent aching pain	
Pains are throbbing, severe, radiating	
Mucous in the area of the «causal» tooth is hyperemic, edematous, the transitional fold is smoothed	
Mucous in the area of the «causal» tooth is hyperemic, edematous, the transitional fold is smoothed, the focus of fluctuation is determined	

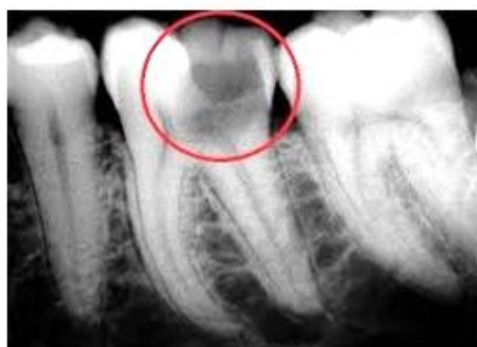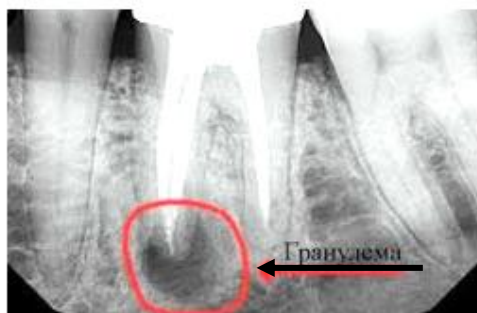
5. Select and write down the treatment tactics recommended in relation to the «causal» tooth (removal or endodontic treatment) based on the presented data of radiation research methods (dental radiographs).

I stage (_____) _____

II stage (surgical) _____

III stage (administration _____ therapy) _____

6. Select and write down the treatment tactics that is recommended to the «causal» tooth (extraction or endodontic treatment) based on the presented data of radiation research methods (dental radiographs).



7. Fill in the table adding the missing characteristic signs of the course of acute periostitis on the upper and lower jaw.

Clinical signs	Upper jaw	Lower jaw
Structure of bone tissue	Thin cortical plate, well developed spongy bone tissue.	
Blood supply	The vascular network is well developed.	
Muscle attachment, fascial spaces		A large number of muscles and fascial spaces attached to the jaw.
Proximity of anatomical formations	The presence of the maxillary sinus, good aeration of tissues	
Clinical course of inflammatory process		
Recovering time		
Complications development		

8. Distribute the sequence in the examination and treatment of patient with acute purulent periostitis, writing the correct number in brackets and crossing out the wrong positions.

1. Anamnesis, interviewing, examination (___);
2. Mandatory preservation and endodontic treatment of the root canal of the «causal» tooth (___);
3. Xray examination (___);
4. Nerve block anesthesia (___);
5. Extraction of «causal» tooth (___);
6. Administration of complex anti-inflammatory treatment (___);
7. Infiltrative anesthesia (___);
8. Aseptic dressing (___);
9. Periostotomia (___);
10. Instillation of inflammatory focus with antiseptic solution (___);
11. Filling in the list of temporary disability (___);
12. Putting inside the wound the drainage from glove rubber (___);

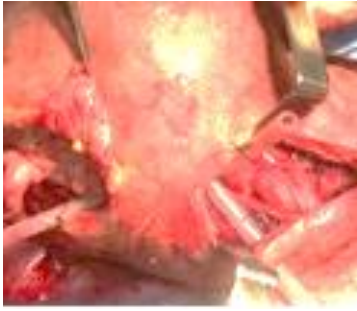9. Choose and highlight the possible complications of acute periostitis of the jaw:

- 1) lymphadenitis of regional lymph nodes;
- 2) meningitis;
- 3) abscess and phlegmon;
- 4) acute osteomyelitis;
- 5) acute purulent periodontitis;
- 6) chronic osteomyelitis;
- 7) maxillary sinusitis;
- 8) mediastinitis;
- 9) anaphylactic shock;
- 10) sepsis;
- 11) chronic periostitis.

10. Mark with the «+» or «-» signs the correct tactics according the «causal» tooth in a case of the development of acute purulent periostitis of the jaws.

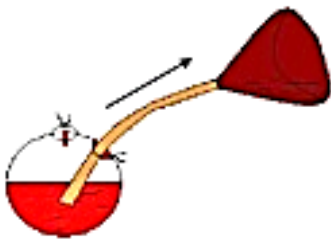Clinical signs	Extraction of the «causal» tooth	Endodontic treatment of the «causal» tooth
The presence of somatic pathology in decompensated stage		
Impassable and / or curved root canals of the tooth		
The presence of granulomas, cystogranulomas in the apex region of «causal» tooth of chewing teeth group		
The presence of granulomas, cystogranulomas in the apex region of «causal» tooth of frontal teeth group		
Tooth does not represent functional value		
The tooth is located out of the dental arch and / or injures the mucous of the oral cavity		
The progress of the inflammatory process cannot be stopped by conservative methods		

11. Analyze the illustrations and subscribe to what type of drainage (active or passive) each of the options depicted with the obligatory indication of the drainage method.



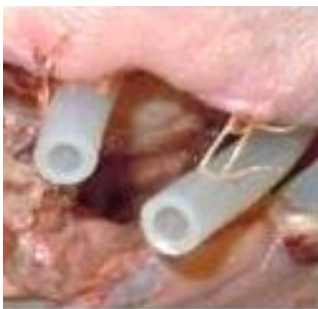Drainage _____

Method _____



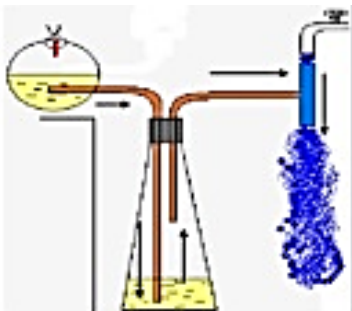
Drainage _____

Method _____



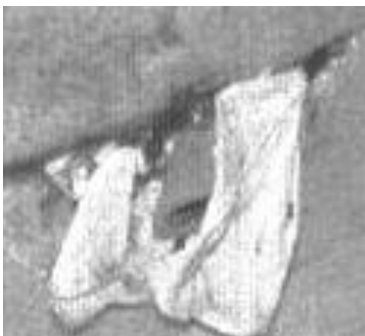Drainage _____

Method _____



Drainage _____

Method _____



Drainage _____

Method _____

12. Connect with the arrows to the appropriate drainage and methods determination.

loose wound tamponade

tight wound tamponade

plate drainage

cigar-shaped drainage

putting into the wound (for a while) a sterile wipe

represents a strip of thin rubber inserted into the wound to prevent adhesion of its edges and preserve the possibilities of its outflow

turunda stacked in layers tight (for a while)

tubular with the introduction inside of a narrow gauze swab, which can be easily changed

Theme 5
ACUTE ODONTOGENIC OSTEOMYELITIS OF THE JAWS

Control questions on the topic:

1. Name the clinical classification of acute odontogenic osteomyelitis.
2. Indicate the sources and ways of spreading infection in acute odontogenic osteomyelitis of the jaws.
3. List possible etiological factors contributing to development of acute odontogenic osteomyelitis of the jaws.
4. Name the known theories of the development of osteomyelitis of the jaws.
5. Describe the etiology and pathogenesis of acute odontogenic osteomyelitis of the jaws.
6. Describe the clinical picture of acute jaw osteomyelitis.
7. What does the term «endogenous intoxication» include and what indicators characterize it?
8. Describe the results of radiological research methods in acute odontogenic osteomyelitis of the jaws.
9. Make a plan for the examination of patients with acute odontogenic osteomyelitis of the lower jaw.
10. To analyze the possible complications of acute odontogenic osteomyelitis of the jaws.
11. Present the basic principles of prescribing antibiotic therapy (ABT).
12. Make a plan for the comprehensive treatment of patients with acute odontogenic osteomyelitis of the jaws.

1. Write a modern definition of acute odontogenic osteomyelitis.

Acute odontogenic osteomyelitis is _____

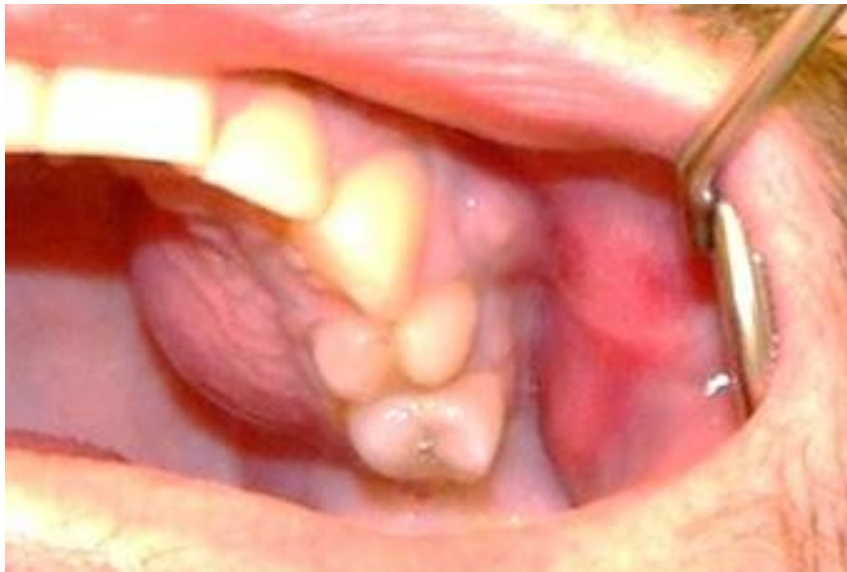2. Name the theories of osteomyelitis according to the authors who proposed them.

- 1) E. Lexer (1884), A.A. Bobrov (1889) _____
- 2) V. M. Uvarov (1951) _____
- 3) S. M. Derizhanov (1940) _____
- 4) G. I. Semenchenko (1958) _____
- 5) M. M. Solovyov (1971) _____

3. Define and mark the correct tactics to the «causal» tooth:

- 1) extraction of the «causal» tooth;
- 2) extraction of the «causal» tooth in the presence of destructive changes in the root area (granulomas, cystgranulomas, cysts);
- 3) endodontic treatment of the «causal» tooth.

4. Name and write down the clinical symptom of acute odontogenic osteomyelitis shown on the picture.



5. Analyze the clinical symptoms and underline those that correspond to the diagnosis of acute odontogenic osteomyelitis.

1. General condition: satisfactory, moderate, severe.
2. Local status:
 - muffed-shaped thickening of the jaw;
 - smoothness of the transitional fold only on the vestibular side;
 - collateral edema of soft tissues of the face;
 - edema and inflammatory infiltrate of the soft tissues of the face;
 - Vincent's symptom;
 - retrograde periodontitis;
 - inflammatory contracture of the chewing muscles;
 - displacement of the mimic muscles of the face to the affected side.

6. Select and underline from the presented list, the development of which pulpitis is typical for acute odontogenic osteomyelitis:

- 1) as a result of a complication of the carious process;
- 2) retrograde (as a result of a pathological dentogingival pocket with marginal periodontitis; with the spread of an infectious agent by the lymphogenous or hematogenous route);
- 3) traumatic etiology.

7. Name the stages of complex treatment of acute odontogenic osteomyelitis.

I stage _____

1) _____

2) _____

II stage _____

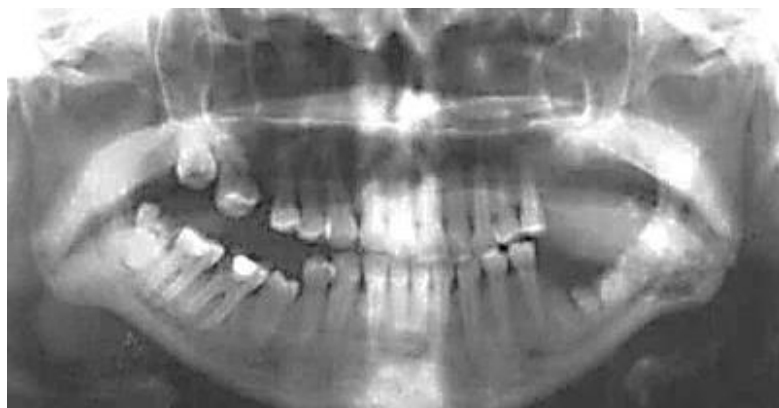Antimicrobial medicines:

Detoxification medicines:

Desensitizing medicines:

Immunocorrecting medicines:

8. Describe the orthopantomogram of a patient with acute odontogenic osteomyelitis.



9. Distribute in order of importance (based on the frequency of occurrence) the possible causes of acute odontogenic osteomyelitis of the lower jaw, putting the corresponding number in brackets.

1. Third molars (___);
2. First molars (___);
3. Second molars (___);
4. Frontal groups of teeth (incisors and canines) (___);
5. Premolars (___).

10. Distribute in order of importance (based on frequency of occurrence) the possible causes of acute odontogenic osteomyelitis of the upper jaw, putting the corresponding serial number in brackets.

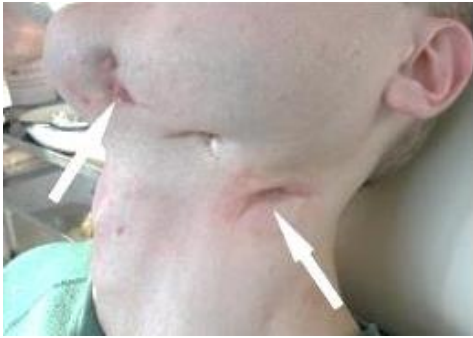1. Third molars (___);
2. First molars (___);
3. Second molars (___);
4. Frontal groups of teeth (incisors and canines) (___);
5. Premolars (___).

Theme 6
CHRONIC ODONTOGENIC OSTEOMYELITIS OF THE JAWS

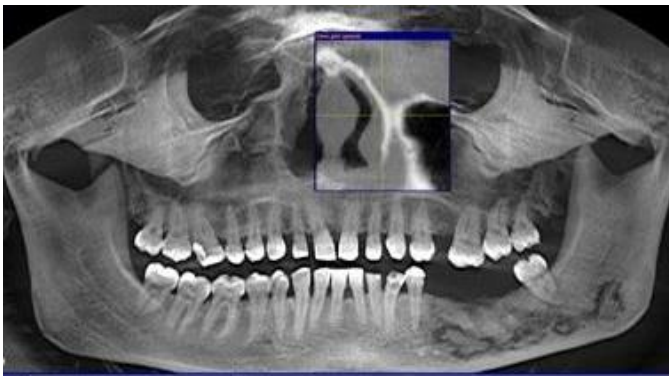Control questions on the topic:

1. Name the clinical and ICD-10 classification of chronic odontogenic osteomyelitis.
2. Name the sources and ways of introducing an infectious agent in chronic odontogenic osteomyelitis of the jaws.
3. Name the etiological factors contributing to the development of chronic odontogenic osteomyelitis of the jaws.
4. Name the reasons for the transition of the acute form of odontogenic osteomyelitis to the chronic form.
5. Describe the pathogenesis of chronic odontogenic osteomyelitis of the jaws.
6. Describe the clinical picture of chronic osteomyelitis of the jaw.
7. Conduct a comparative assessment of the development of acute odontogenic osteomyelitis in the upper and lower jaws, focusing on the anatomical and topographic features, pathogenesis and timing of development.
8. Make a plan for examining a patient with chronic odontogenic osteomyelitis of the jaw.
9. Describe the possible complications of the clinical course of chronic odontogenic osteomyelitis of the jaws. Specify the ways of their prevention.
10. Make a plan for the complex treatment of patients with chronic odontogenic osteomyelitis of the jaw.
11. List the radiological signs of chronic odontogenic osteomyelitis of the jaw.
12. Name the structure of the sequestral capsule.
13. Indicate the mechanisms of formation of sequestrers in chronic odontogenic osteomyelitis of the jaw.
14. Name the surgical intervention that is performed in chronic odontogenic osteomyelitis of the jaw.
15. List the stages of surgery — sequestrectomy in patients with chronic odontogenic osteomyelitis of the jaw.

1. Name and sign the distinctive clinical sign of chronic odontogenic osteomyelitis, indicated by arrows in the figure.



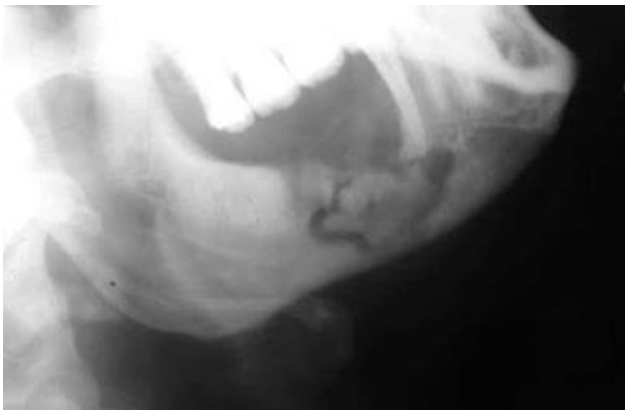2. List the main radiographic signs of chronic osteomyelitis, which can be identified on the presented panoramic zoonogram.



- 1) _____
- 2) _____
- 3) _____

3. Draw the structure of the sequestral capsule, indicate and label the zones with arrows.

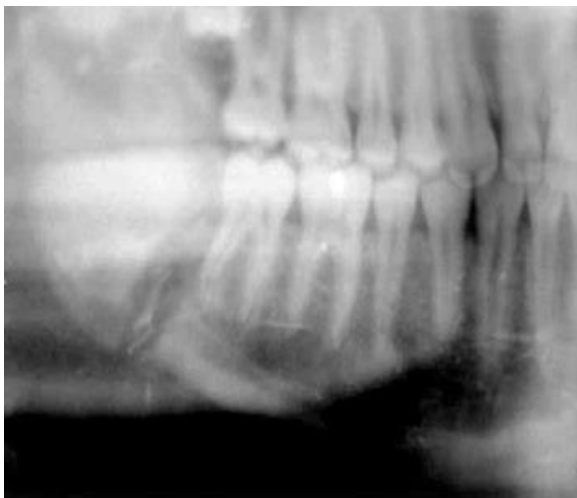4. Define and write what radiological sign of chronic osteomyelitis is visualized on the presented radiograph of the lower jaw in the lateral projection.



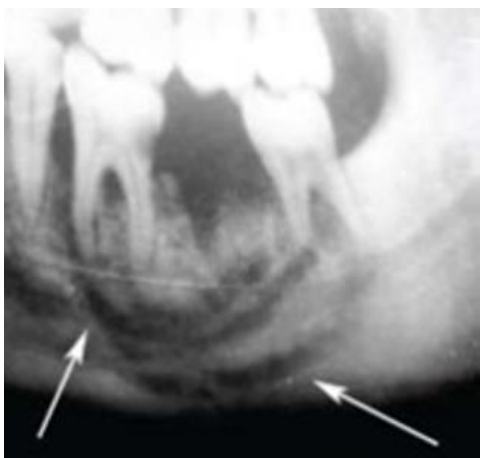5. Add the missing steps of the surgical intervention — sequestrectomy:

- 1) anesthesia;
- 2) _____;
- 3) _____;
- 4) removal of granulation tissue from a bone wound (curettage);
- 5) _____.

6. Determine and write down whether sequestrectomy is indicated in the clinical situation presented on the radiograph of the lower jaw in the lateral projection, substantiating the answer.



7. Identify and write which form of chronic odontogenic osteomyelitis in terms of the prevalence of the process is represented on this radiograph by signing the objects indicated by arrows.



8. Fill in the table, indicating the timing of the formation of sequesters in the upper and lower jaws.

Upper jaw anterior segment	Upper jaw lateral segment	Mandible anterior segment	Mandible lateral segment

9. Arrange in order the stages of preparation and conduct of surgical intervention - sequestrectomy by the intraoral method, adding the missing and putting the corresponding serial number in brackets.

1. Local anesthesia (___);
2. radiological research methods (___);
3. Incision of the mucous membrane of the alveolar process (___);
4. Sequester removal (___);
5. Exfoliation of the mucoperiosteal flap (___);
6. Sanitation of odontogenic infection foci— _____ (___);
7. Removal of granulation tissue (curettage) (___);
8. Suturing (___);
9. Control X-ray (___).

10. Fill in the table of comparative evaluation of clinical signs of chronic osteomyelitis of odontogenic and non-uniform genesis.

Clinical signs	Odontogenic chronic osteomyelitis	Nonodontogenic chronic osteomyelitis
Presence of a «causal» tooth		
In clinic history — jaw trauma		
In clinic history — dental implant placement		
Presence of disease caused by a specific infectious agent		
Radiation therapy for malignant tumors of the thyroid gland, pathology ENT organs		
Performing a cystectomy		
Incomplete root extraction		

Theme 7
ODONTOGENIC LYMPHADENITIS OF THE MAXILLOFACIAL AREA
AND NECK

Control questions on the topic:

1. Name the definition of lymphadenitis.
2. State the classification (clinical and ICD-10) of lymphadenitis of the maxillofacial region and neck.
3. Present the pathogenesis of odontogenic lymphadenitis of the maxillofacial region and neck.
4. Describe the clinical picture, diagnosis and treatment of acute serous and purulent odontogenic lymphadenitis.
5. Name the differential diagnosis of acute purulent and acute serous lymphadenitis of the maxillofacial region and neck. Specify the defining research method.
6. Features of the primary surgical treatment of the infectious and inflammatory focus in acute purulent lymphadenitis.
7. Describe the clinical picture, diagnosis and treatment of chronic lymphadenitis of the maxillofacial region and neck.
8. Present the differential diagnosis of chronic odontogenic lymphadenitis with acute odontogenic lymphadenitis and lymphadenopathy of the maxillofacial region and neck.
9. List the stages of primary surgical treatment (PSD) of an infectious-inflammatory focus in a patient with acute odontogenic lymphadenitis.

1. Write the classification of lymphadenitis of the maxillofacial region, adding the missing.

By etiology: _____

stomatogenic (inflammation of the oral mucosa, herpes).

By _____.

By _____.

2. Write down the groups of regional lymph nodes and the method of their palpation examination.

I group (submental _____);

II group (submandibular _____);

III group (buccal _____);

IV group (parotid _____);

V group (temporal _____);

VI group (occipital _____);

VII group (cervical _____).

3. Complete the description of the lymph node in acute serous lymphadenitis.

In the submandibular region on the right, a single _____ lymph node size _____, mobility _____, consistency _____, with skin and underlying tissues _____

4. List the stages of complex treatment of acute odontogenic purulent lymphadenitis, adding the missing items.

I stage _____:

- 1) _____;
- 2) _____.

II stage _____:

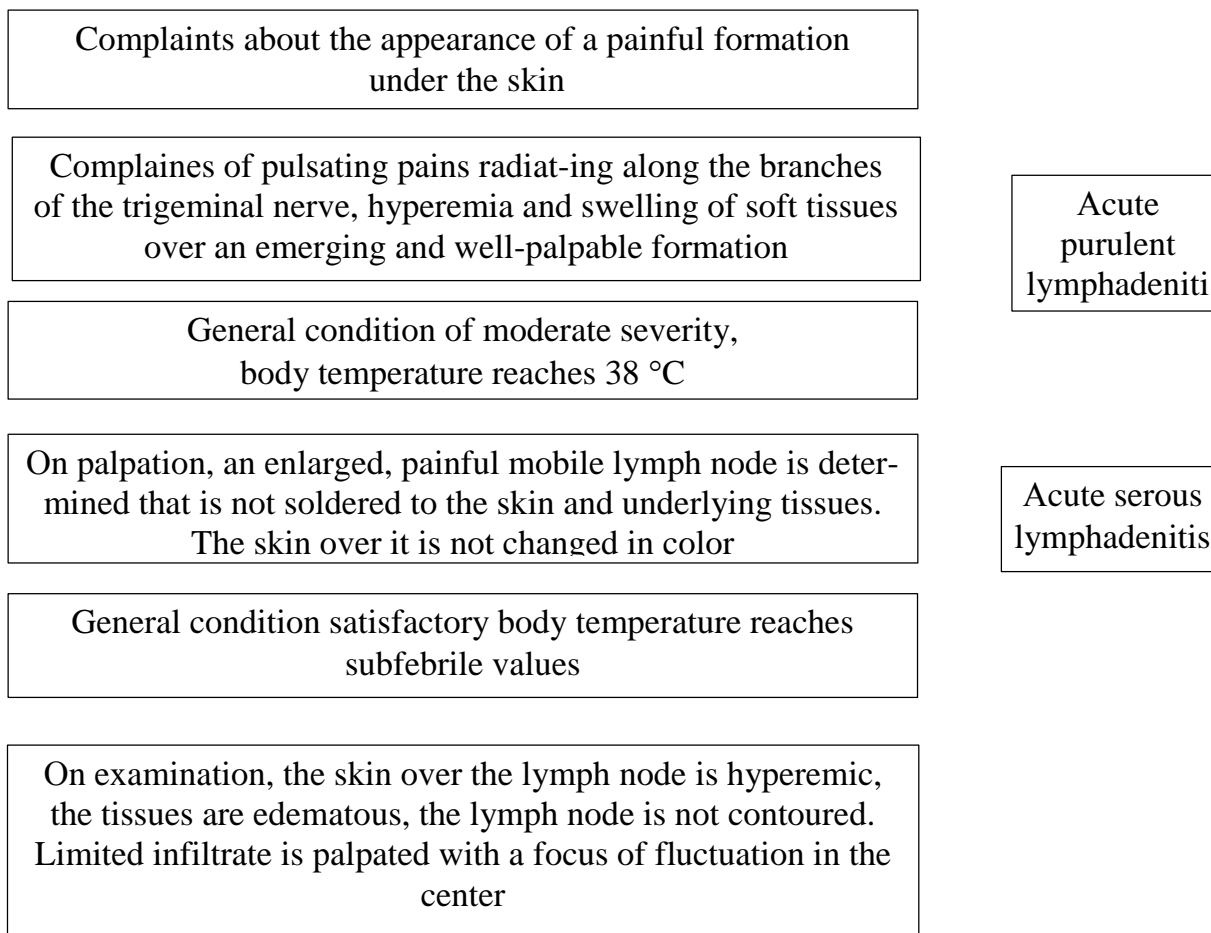
Antimicrobial medicines:

- 1) _____;
- 2) _____;
- 3) _____.

5. Fill in the table of hemogram indicators for acute and chronic lymphadenitis in comparison with the norm.

Hemogram indicators	Indicators in the norm	Indicators for acute serous lymphadenitis	Indicators for acute purulent lymphadenitis	Indicators for chronic lymphadenitis
Leukocytes	4,0–10,0 ($10^9/l$)			
ESR	3–8 mm/h			
Segmented	47–72%			
Monocytes	2–9%			
Stab neutrophils	1–6%			
Eosinophils	0–3%			
Lymphocytes	18–40%			
Shift towards youthful forms	none		The presence of young forms	none

6. Connect with arrows the diagnosis and the corresponding clinical signs characteristic of acute serous and acute purulent lymphadenitis.



7. Select and underline the basis of which following methods of research conduct differential diagnosis of chronic forms of specific and nonspecific lymphadenitis:

- 1) palpation of the lymph nodes;
- 2) ultrasound diagnostics;
- 3) cone beam computed tomography;
- 4) magnetic resonance computed tomography;
- 5) general blood test with a leukocyte formula;
- 6) diagnostic puncture of the lymph node;
- 7) histological examination of the lymph node;
- 8) serological diagnosis.

8. Write down the listed variants of lymphadenitis belong to the groups listed below.

Known lymphadenitis: tuberculous, syphilitic, viral, developed against the background of malignant neoplasms, developed after vaccination, occurring in autoimmune diseases, stomatogenic, tonsillogenic, infectious, traumatic, serous, productive, purulent, hyperplastic, odontogenic.

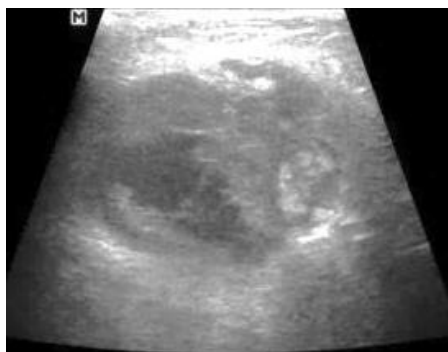Allocate groups of lymphadenitis:

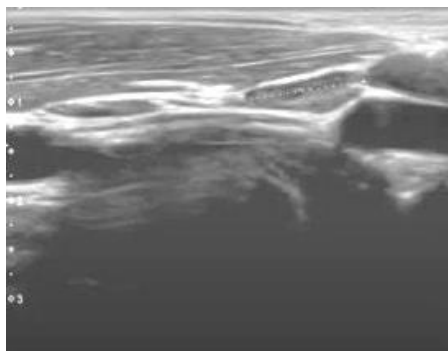
specific	<hr/> <hr/> <hr/> <hr/>
not specific	<hr/> <hr/> <hr/>
acute	<hr/> <hr/> <hr/>
chronic	<hr/> <hr/> <hr/>
reactive non-inflammatory hyperplasia	<hr/> <hr/> <hr/> <hr/>

9. Fill in the table diagnostic signs of odontogenic, specific lymphadenitis and metastatic lesions of the lymph nodes.

Diagnostic signs	Comparable nosologies		
	Odontogenic lymphadenitis	Specific lymphadenitis	Metastatic lymph nodes
History of the disease	Diseases of the hard or soft tissues of the tooth	Positive serological samples.	Against the background of malignant process
Localization of the lesion	One-sided		
Dynamics			
Results of a general blood test			
Clinical picture of the lymph node on palpation		Enlarged, dense, motionless	Enlarged, painless, defined as «packets»

10. Analyze the results of ultrasound examination of the cervical lymph nodes. Determine and sign where the image corresponds to the diagnosis of acute purulent lymphadenitis, and where is the acute serous process. In the illustration, mark with a colored rod the area of the focus in acute purulent lymphadenitis.





Theme 8

DIFFERENTIAL DIAGNOSIS OF PERIODONTITIS, PERIOSTITIS, ODONTOGENIC OSTEOMYELITIS OF JAWS, LYMPHADENITIS

Control questions on the topic:

1. On what basis is the disease diagnosed?
2. Indicate what the term «semiotics» includes.
3. What is meant by the concept of «methods of diagnostic examination»?
4. Define the methodological basis of diagnosis.
5. Define the differential diagnosis.
6. What is the logical outcome of the differential diagnosis?
7. What are the stages of examination of patients with IVP of the maxillofacial area and neck?
8. Indicate the general clinical manifestations of the diseases: acute odontogenic and chronic periodontitis, acute odontogenic periostitis and acute odontogenic osteomyelitis.
9. List the differences in the clinical picture of diseases of acute and chronic apical periodontitis, acute odontogenic periostitis and acute odontogenic osteomyelitis of the jaw.
10. Describe the differences according to the results of X-ray methods of chronic apical periodontitis (fibrous, granulating, granulomatous) with acute purulent periostitis, acute odontogenic osteomyelitis and chronic odontogenic osteomyelitis.
11. Indicate what can be the indicators in laboratory methods for examining blood, urine in patients with acute and chronic periodontitis, acute purulent odontogenic periostitis, acute and chronic odontogenic osteomyelitis.
12. Specify with what diseases it is necessary to differentiate chronic odontogenic osteomyelitis of the jaw.

1. Define the term «semiotics».

Semiotics is _____

2. Indicate what the concept of «methods of diagnostic examination» implies.

Methods of diagnostic examination include _____

3. Choose and underline the correct definition of the concept of «differential diagnosis» from among those presented below.

1. Differential diagnosis is a diagnostic method that excludes inappropriate diseases that are possible for a patient based on any signs or symptoms.

2. Differential diagnosis is the establishment of similarities and objective differences with other diseases that are closest in development, clinical picture, pathognomonic signs and course.

3. Differential diagnosis is the recognition of a disease by identifying and excluding similar pathognomonic symptoms of various diseases.

4. Differential diagnosis is a diagnosis taking into account the selection of the leading specific sign of this disease.

4. From the diseases listed below, select and underline those with which acute periodontitis should be differentiated:

- 1) acute odontogenic osteomyelitis;
- 2) acute purulent periostitis;
- 3) acute sinusitis of the maxillary sinus;
- 4) diffuse pulpitis;
- 5) acute lymphadenitis;
- 6) trigeminal neuralgia;
- 7) deep caries.

5. Make a differential diagnosis of acute serous periodontitis and acute purulent periodontitis by filling out the table and putting «+» or «-» in the empty columns.

Clinical signs and their characteristics	Differentiable diseases	
	Acute serous periodontitis	Acute purulent periodontitis
Pain		
Spontaneous pain, aggravated by vertical percussion of the «causal» tooth, biting on the «causal» tooth, while eating hot food		
Spontaneous throbbing pain radiating along the branches of the trigeminal nerve		
Swelling and hyperemia of the gums around the «principal» tooth		
The statics of the «causal» tooth is broken		
Mental and submandibular lymph nodes are enlarged, slightly painful on palpation, mobile, not soldered to the skin and underlying tissues		
Increase in body temperature to subfebrile values		
Changes in periapical tissues are determined on radiological research methods		

6. Analyze the differential diagnosis of acute purulent periodontitis and acute purulent periostitis in the table below and correct the mistakes in it.

Clinical signs and their characteristics	Differentiable diseases	
	Acute purulent periodontitis and exacerbation of chronic periodontitis	Acute purulent periostitis
Pain	+	+
It begins with the appearance of spontaneous pain in the area of the «causal» tooth	+	+
The pain intensifies when biting / pressing on the «causal» tooth, or when it is percussion	–	–
Percussion is painful	only one «causal» tooth	several teeth next to the «causal» tooth
Pain radiates along the branches of the trigeminal nerve	–	–
From the anamnesis, it is possible to find out that some time ago the pain was more severe, but with the appearance of edema and asymmetry of the face, the intensity of the pain attack significantly decreased	–	+
The statics of the «causal» tooth is broken	+	–
Swelling and hyperemia of the gums around the «principal» tooth	+ insignificant	+ pronounced
The presence of collateral soft tissue edema in the area of the «causative» tooth.	–	+
Palpation determines the infiltrate along the transitional fold.	–	+
Involvement in the process of regional lymph nodes (enlarged, mobile, with the skin and underlying tissues are not soldered).	+	+
Localization of the inflammatory focus	is within a few teeth	extends beyond one tooth and spreads under the periosteum
On radiation methods of research, changes in the periapical tissues are determined, including those indicating about bone destruction.	–	–
Violation the general condition of the patient (fever, increased heart rate, increased respiratory rate, changes in peripheral blood).	–	–

7. Make a differential diagnosis of acute purulent periostitis and acute odontogenic osteomyelitis by filling out the table and putting «+» or «-» in the empty columns.

Clinical signs and their characteristics	Differentiable diseases	
	Acute purulent periostitis	Acute odontogenic osteomyelitis
Pain		
Night pains in the area of the «causal» tooth		
Increased pain with a vertical load on the «causal» tooth or with vertical percussion		
Hyperemia and edema adjacent to the «causal» tooth of the gum		
Violation the statics of the «causal» tooth		
Isolation of purulent exudate from the periodontal pocket		
Presence of Vincent's symptom		
Hyperemia, collateral edema, infiltration of the maxillary soft tissues		
The presence of a «muff-like» thickening of the alveolar process		
Reaction from the regional lymph nodes (enlarged, painful, not soldered to the skin and underlying tissues)		
Changes in radiological research methods		
Violation the general condition of the patient (fever, increased heart rate, increased respiratory rate, changes in peripheral blood)		
Improvement of the general condition after the operation — primary surgical treatment of the infectious and inflammatory focus and removal of the «causal» tooth		
Cytological data		

8. Select and underline the common symptom in the diagnosis of acute pulpitis, acute periodontitis, trigeminal neuralgia, acute periostitis, acute maxillary sinusitis from the following list:

- 1) endogenous intoxication;
- 2) hyperthermia;
- 3) regional lymphadenitis;
- 4) violation of the statics of the «causal» tooth;
- 5) subperiosteal abscess;
- 6) local hyperemia and swelling of the oral mucosa;
- 7) shift of the peripheral blood leukocyte formula towards young forms of cells.

9. Analyze the differential diagnosis of acute purulent periodontitis and acute purulent periostitis in the table below and correct the mistakes in it.

Clinical signs and their characteristics	Acute odontogenic osteomyelitis	Acute purulent periostitis	Acute periodontitis and chronic periodontitis in the acute stage
Pain	+	+	+
Night pains in the area of the «causal» tooth	+	-	+
Increased pain with a vertical load on the «causal» tooth or with vertical percussion	-	+	+
Hyperemia and edema adjacent to the «causal» tooth of the gum	+ the entire alveolar process on the side of defeat	+ in the area of several adjacent teeth, one of which is «causal» and inflammatory infiltrate	+ only in the area of the «causal» tooth
Violation the statics of the «causal» tooth	+ groups of teeth that are close together with «causal»	+ pronounced mobility of two adjacent teeth, one of which is «causal»	-
Isolation of purulent exudate from the periodontal pocket			
Presence of Vincent's symptom		-	-
Hyperemia, collateral edema, infiltration of the maxillary soft tissues	+ significant edema, widespread infiltrate, infiltration present	+ swelling of the perimaxillary soft tissues in the area of interest	+ slight swelling of the perimaxillary soft tissues may be present in the zone of the corresponding localization of the «causal» tooth
The presence of a «muff-like» thickening of the alveolar process	+	+	-
Reaction from the regional lymph nodes (enlarged, painful, not soldered to the skin and underlying tissues)	+	+	+

End of the table

Clinical signs and their characteristics	Acute odontogenic osteomyelitis	Acute purulent periostitis	Acute periodontitis and chronic periodontitis in the acute stage
Changes in radiological research methods	–	–	–
Violation the general condition of the patient (fever, increased heart rate, increased respiratory rate, changes in peripheral blood)	+	+	+
Improvement of the general condition after the operation - primary surgical treatment of the infectious and inflammatory focus and removal of the «causal» tooth	–	–	–
Data of cytological examination	presence in purulent exudate of bone marrow cells	–	–

10. Connect with arrows the characteristics of the pain attack and the corresponding infectious and inflammatory disease of the maxillofacial region.

paroxysmal nocturnal pain, with short intervals, aggravated or provoked by temperature and chemical stimuli	acute odontogenic osteomyelitis
throbbing pain, aggravated by biting on the causative tooth during its percussion	acute purulent periostitis
throbbing pain, aggravated by biting on the causative tooth during its percussion	acute periodontitis
severe pain in the area of the entire jaw, irradiation along the branches of the trigeminal nerve, pain in all teeth, paresthesia of the skin of the chin and lower lip	acute pulpitis

Theme 9
FURUNCLES AND CARBUNCLES OF THE MAXILLOFACIAL AREA
AND NECK

Control questions on the topic:

1. Define the concepts of «furuncle» and «carbuncle».
2. Present the ICD-10 fragment for furuncles and carbuncles of the maxillofacial region and neck.
3. Name the etiological factors contributing to the development of furuncle and carbuncle.
4. Name the pathogenic microflora most often found in furuncles and carbuncles of the maxillofacial area and neck.
5. Make a plan for the complex treatment of a patient with furuncle and carbuncle of the maxillofacial region and neck.
6. Name antiaggregants known to you, indications for their use in furuncles and carbuncles of the maxillofacial region and neck, schemes and doses used for these purposes.
7. List anticoagulants of direct and indirect action, name the indications for their use in furuncles and carbuncles of the maxillofacial region, methods of administration, regimens and doses.
8. Indicate the features of conducting PST of an infectious and inflammatory focus in patients with furuncles and carbuncles of the maxillofacial region and neck. List the stages of surgery.
9. List the possible complications of furuncles and carbuncles of the maxillofacial region and neck, ways of spreading the infection, prognosis of the disease.
10. Outline a modern scheme for the rehabilitation of patients with furuncles and carbuncles of the maxillofacial region and neck.

1. Give the definition of a furuncle.

Furuncle is _____

2. Define a carbuncle.

Carbuncle is _____

3. Mark with a «tick» the representatives of the microbial flora that are most often detected in boils and carbuncles of the maxillofacial region and neck, underline those that are most often capable of forming biofilms:

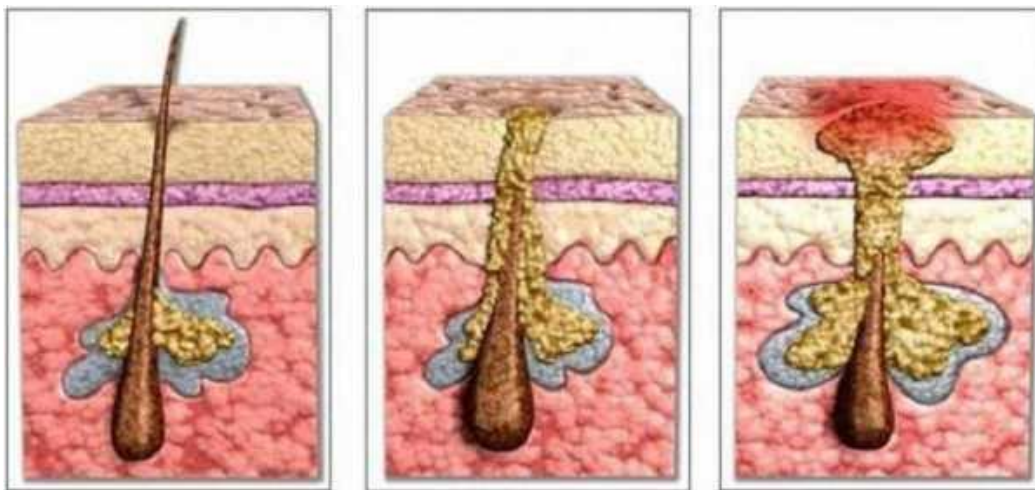
- | | |
|---|---------------------------------------|
| <input type="checkbox"/> Staphylococcus aureus; | <input type="checkbox"/> proteus; |
| <input type="checkbox"/> Streptococcus; | <input type="checkbox"/> Enterococcus |
| <input type="checkbox"/> Escherichia coli; | |

4. Specify (underline) what common factors are predisposing to the development of boils and carbuncles of the maxillofacial region and neck:

- 1) avitaminosis;
- 3) Diabetes;
- 2) diseases of the cardiovascular system;
- 4) obesity.

5. Add the missing stages in the development of the boil and the numbers corresponding to the serial number of the stage in the listing, mark them in the figures presented:

- 1) _____
- 2) stage of suppuration and necrosis;
- 3) _____

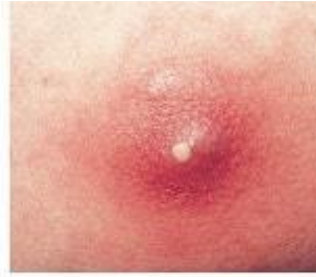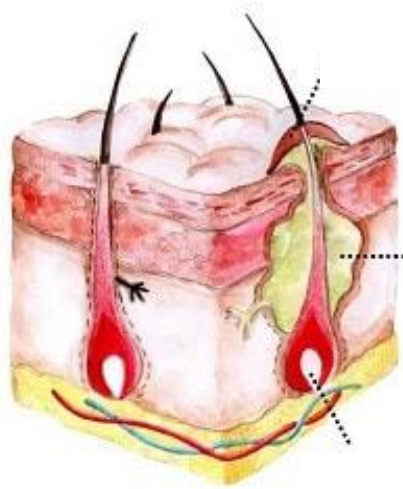


<http://feel-feed.ru/furunkul-prichiny-poyavleniya-chem-opasen-i-kak-lechit/>

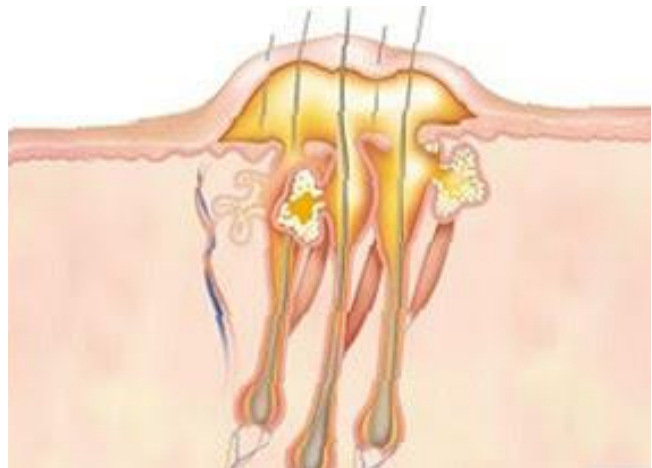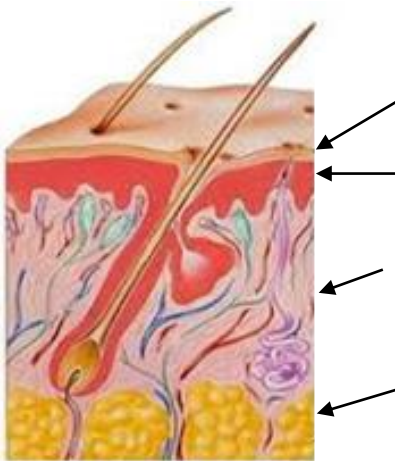
6. Complete the list of measures aimed at preventing the development of phlebitis of the facial veins by filling in the empty lines.

- 1) _____
- 2) _____
- 3) cancellation of anticoagulants;
- 4) _____

7. In the presented pictures, identify and sign the boil and carbuncle.



<http://feel-feed.ru/furunkul-prichiny-poyavleniya-chem-opasen-i-kak-lechit/>



<http://feel-feed.ru/furunkul-prichiny-poyavleniya-chem-opasen-i-kak-lechit/>

8. Mark where surgery is performed on patients — with furuncles and carbuncles of the maxillofacial region.

on an outpatient basis;

in a hospital setting.

9. List the most dangerous areas of localization of boils, carbuncles in the maxillofacial region and shade them in the figure, marking the areas with numbers corresponding to the serial number in the listing.



<https://www.pinterest.co.kr/pin/449234131567819152/?autologin=true>

10. List the complications of furuncles and carbuncles of the maxillofacial area.

local: _____

general: _____

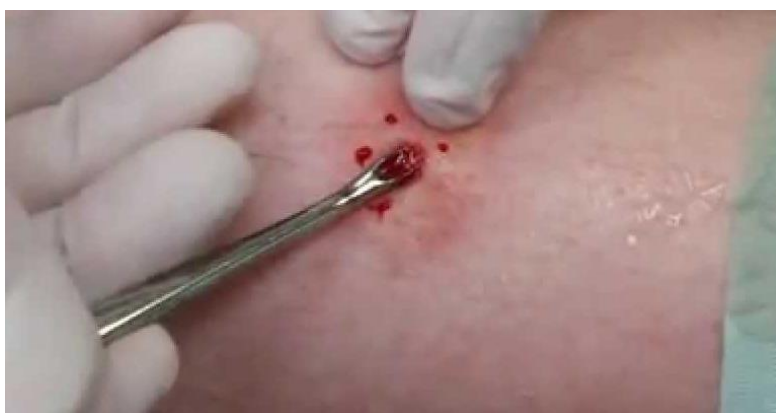11. List the indicators of the coagulogram, allowing to determine the state of the blood coagulation system and their norms.

International normalized ratio (INR), norm — _____;
_____ (normally 2–3 min);
Prothrombin index _____;
_____ (normal — 8–14 sec).

12. Fill in the missing steps of the operation - primary surgical treatment of the infectious and inflammatory focus in patients with furuncles and carbuncles of the maxillofacial region and neck:

- 1) anesthesia: indirect infiltration anesthesia _____ ;
- 2) _____ ;
- 3) _____ ;
- 4) _____ ;
- 5) _____ .

13. Name the stage of the operation — primary surgical treatment of the infectious and inflammatory focus in a patient with a furuncle of the parotid-masticatory region shown in the photo (write the name of the stage of the operation next to the photo).



<https://centr-hirurgii.ru/surgery/ambulatornaya-hirurgiya/vskrytie-furunkula/>

14. Complex conservative therapy of furuncles and carbuncles of the maxillofacial region and neck should include (fill in the missing).

1. _____ ;
2. Detoxification therapy _____ ;
3. _____ ;
4. _____ ;
5. _____ ;
6. Medicinal products of general strengthening action _____ .

15. Underline the group of drugs that is prescribed for furuncles of the maxillofacial region and neck in order to prevent phlebitis of the facial veins:

- 1) direct anticoagulants;
- 2) indirect anticoagulants;
- 3) antiaggregants;
- 4) corticosteroid hormones.

Theme 10
**SEVERE COMPLICATIONS OF INFECTIOUS-INFLAMMATORY
PROCESSES OF THE MAXILLO-FACIAL REGION (PHLEBIT
OF THE FACIAL VEINS, THROMBOSIS OF THE CAVERNOUS SINUS).
CLINIC, DIAGNOSIS, TREATMENT, PREVENTION**

Control questions on the topic:

1. Present the main etiological factors and pathogenesis of facial vein phlebitis, cavernous sinus thrombosis.
2. Present a fragment of the ICD-10 corresponding to thrombophlebitis of the facial veins, thrombosis of the cavernous sinus.
3. Indicate the ways of spreading the infectious agent during the development of thrombophlebitis of the veins of the face and the factors that contribute to this.
4. List the early clinical signs of facial vein thrombophlebitis.
5. Indicate the ways of spreading the infectious agent during the development of cavernous sinus thrombosis, and the factors that contribute to this.
6. List the early clinical signs of the development of cavernous sinus thrombosis.
7. Describe the clinical symptoms of thrombophlebitis of the veins of the face.
8. Describe the clinical symptoms of cavernous sinus thrombosis.
9. Specify the radiological research methods used for the diagnosis and verification of the diagnosis of cavernous sinus thrombosis.
10. Perform differential diagnostics of furuncle and furuncle complicated by facial vein phlebitis.
11. Perform a differential diagnosis of facial vein phlebitis and cavernous sinus thrombosis.
12. Outline the tactics of a dentist-surgeon in case of suspected development of thrombophlebitis of the veins of the face, thrombosis of the cavernous sinus.
13. Prescribe a complex treatment for a patient diagnosed with a furuncle of the maxillofacial region, complicated by thrombophlebitis of the veins of the face.
14. Prescribe complex treatment for a patient with a diagnosis of maxillary periostitis complicated by cavernous sinus thrombosis.
15. Specify the features of drug therapy in the treatment of patients with complications of infectious and inflammatory processes in the maxillofacial region (phlebitis of the facial veins, thrombosis of the cavernous sinus).
16. Indicate the period of temporary disability in patients with IIP(infectious inflammatory process) of the maxillofacial region, complicated by thrombophlebitis of the facial veins, thrombosis of the cavernous sinus.

1. Define thrombophlebitis of the veins of the face.

Thrombophlebitis of the veins of the face is _____

2. List the complication of which diseases is thrombophlebitis of the veins of the face:

1) _____ ;

2) _____ ;

3) carbuncle _____ ;

4) _____ .

3. Indicate on the diagram the paths of pathogenesis of thrombophlebitis of the veins of the face, add the missing.



4. In the development of thrombophlebitis, the Virchow triad is distinguished. Write down its components.

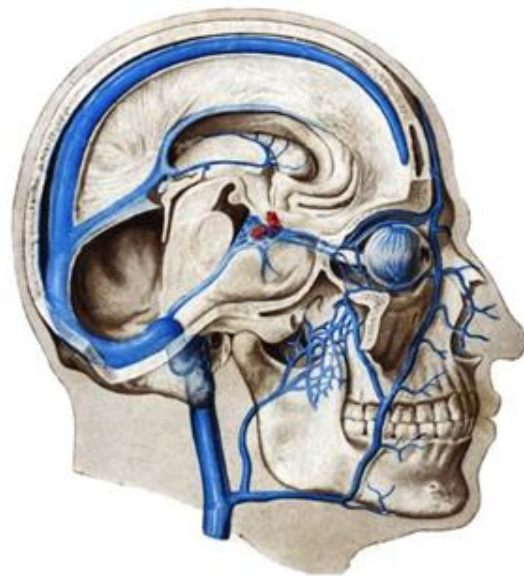
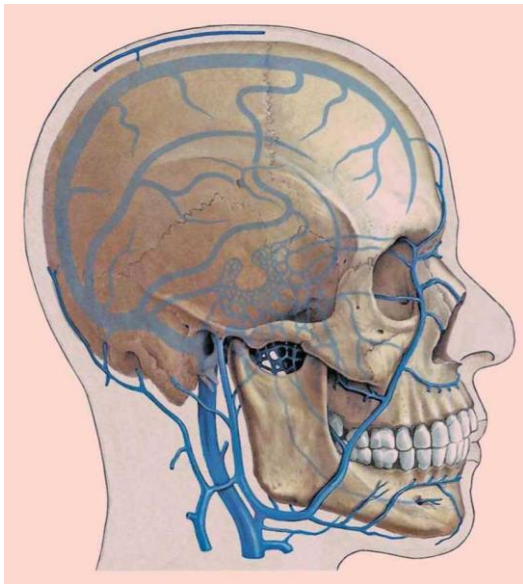
1) _____ ;

2) _____ ;

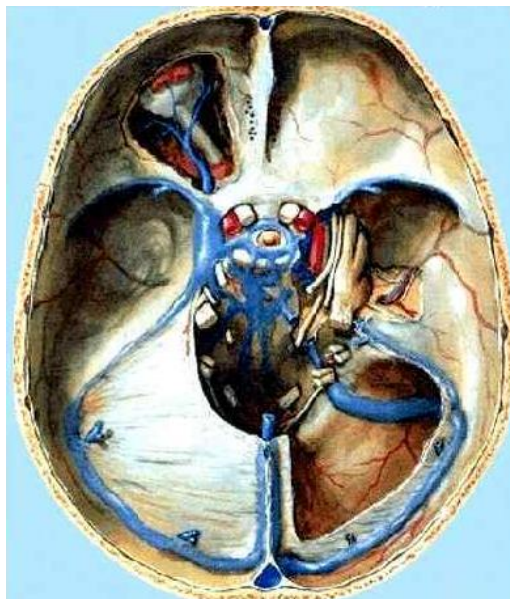
3) _____ ;

5. Write what is the essence of the anatomical and experimental studies conducted by M. A. Sreseli.

6. Point with arrows and sign on the figures below the facial vein, cavernous sinus.



<https://gkb79.ru/narushenie-venoznogo-ottoka.html>; <https://slide-share.ru/oslozhneniya-vospalitelnykh-zabolevanijchelyustno-licevoj-oblastiodontogennij-178409>



(<https://present5.com/zanyatie-2-veny-golovy-i-shei-ottok-venoznoj>)

7. Fill in the missing words in the sentence.

In anastomoses between the veins of the face and the sinuses of the dura mater
_____ practically none, so the direction of blood flow can
_____.

8. Write the missing words in the description of the *local* clinical symptoms of thrombophlebitis of the veins of the face:

- 1) severe _____ of tissues along the angular and facial veins;
- 2) on palpation, these veins are in the form of _____ without clear boundaries;
- 3) in the area of infiltration, a sharp soreness with a _____ tinge;
- 4) edema extends beyond _____

9. Write the missing words. With thrombophlebitis of the veins of the face, intravascular coagulation of the blood increases, as evidenced by the indicators of hemostasis:

- shortened blood clotting _____,
- the appearance _____ «fibrinogen» fraction, an indicator of thrombin in the bloodstream,
- increased activity _____ factor,
- oppressed _____,
- _____ the index can change, and sometimes remains within the normal range.

10. Treatment of thrombophlebitis of the veins of the face should be directed to (add):

- fight against _____,
- fight against _____,
- fight against the expansion of the boundaries of inflammation,
- fight against _____.

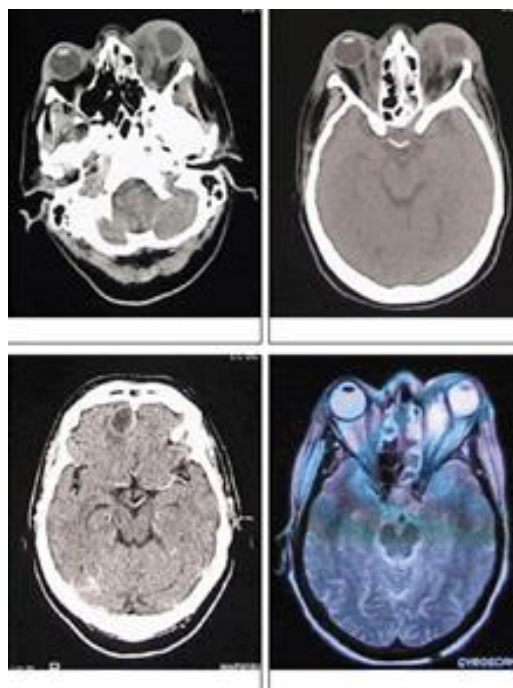
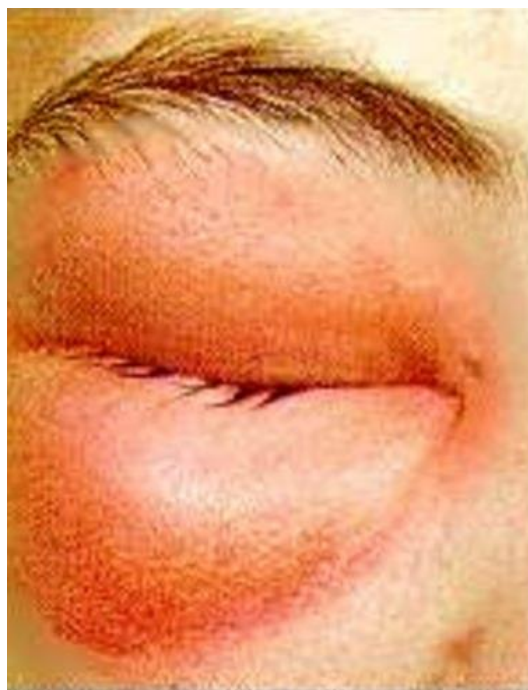11. Define cavernous sinus thrombosis.

Thrombosis of the cavernous sinus is _____

12. Explain what causes focal neurological symptoms that develop in cavernous sinus thrombosis?

13. Explain what causes the general neurological symptoms that develop in cavernous sinus thrombosis?

14. Write the names of the symptoms shown in Figures 1 and 2.



1. _____

2. _____

<https://medicine-live.ru/incident/2015/11/17/tromboz-kavernoznogo-sinusa.html>

15. Fill in the missing words in the sentences.

Pathogenetic treatment of thrombophlebitis of the veins of the maxillofacial region should include:

1) when the first signs of this disease appear, it is necessary to hospitalize patients and place them in a ward or department _____;

2) exudate is taken from the focus of inflammation (_____) and blood from a vein (to determine indicators _____ and bacteremia);

3) vein catheterization _____, when the inflammatory process is simultaneously involved _____, the catheter should be placed in the external carotid artery at the level of the vertebrae _____ or in _____ arteries;

4) perform early incision _____, which creates soft tissue decompression and prevents generalization of infection;

5) to reduce endogenous intoxication of the body, the patient is given detoxification therapy: _____;

6) to restore acid-base balance appoint _____;

7) intravenously or intra-arterially administered antibiotics _____;

8) in order to prevent intravascular coagulation, administered intravenously _____ (under the control of the blood coagulation system) at a dose _____ ED every 4-6 hours, and when «soft» hypocoagulation is reached, they switch to _____, the introduction of this drug is carried out in the same doses and at the same intervals;

9) prescribe non-specific _____ therapy.

Theme 11
**ANAEROBIC INFECTION IN THE MAXILLOFACIAL REGION,
ODONTOGENIC MEDIASTINITIS (SEVERE COMPLICATIONS
OF INFECTIOUS-INFLAMMATORY PROCESSES
OF THE MAXILLOFACIAL REGION)**

Control questions on the topic:

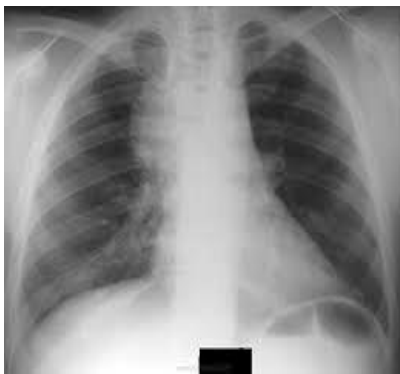1. Present the etiology and pathogenesis of acute odontogenic mediastinitis.
2. Outline the clinical classification of mediastinitis and the relevant fragments of the ICD-10.
3. Indicate the etiology and pathogenesis, ways of spreading anaerobic infection in the maxillofacial area and on the neck.
4. Specify the ways of spreading of acute odontogenic infection during the development of acute odontogenic mediastinitis in the anterior and posterior mediastinum.
5. List the clinical signs of anaerobic infection.
6. Describe the features of conducting anesthesia for anaerobic infections of the maxillofacial region and neck, and acute odontogenic mediastinitis.
7. List the special methods for examining patients with suspected anaerobic infection of the maxillofacial region and neck.
8. Indicate the features of conducting PST of infectious and inflammatory foci in the development of anaerobic infection in the maxillofacial region and on the neck.
9. Indicate the features of wound drainage during PST of infectious and inflammatory foci with anaerobic infection in the maxillofacial region and on the neck.
10. Describe the features of drug therapy in the development of anaerobic infection of the maxillofacial region and neck.
11. List the early clinical signs of the development of acute odontogenic mediastinitis.
12. List the mediastinal symptoms characteristic of anterior mediastinitis.
13. List the mediastinal symptoms characteristic of posterior mediastinitis.
14. Indicate what symptoms in radiological methods of research are characteristic of acute odontogenic mediastinitis.
15. List the types of surgical access for anterior and posterior acute odontogenic mediastinitis
16. What components should include complex treatment of patients with complications of IIP of the maxillofacial region (anaerobic infection, acute odontogenic mediastinitis).
17. Specify the main preventive measures aimed at preventing the development of anaerobic infection and acute odontogenic mediastinitis in patients with IIS of the maxillofacial region.

1. Define the mediastinitis.

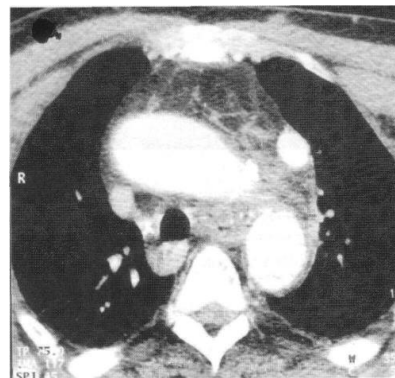
Mediastinitis is _____

2. Write which microorganisms and their communities are most often the cause of the infectious and inflammatory process of the maxillofacial region and neck, which can be complicated by mediastinitis.

3. Label (circle) the boundaries of the mediastinum in Figures 1 and 2 below.



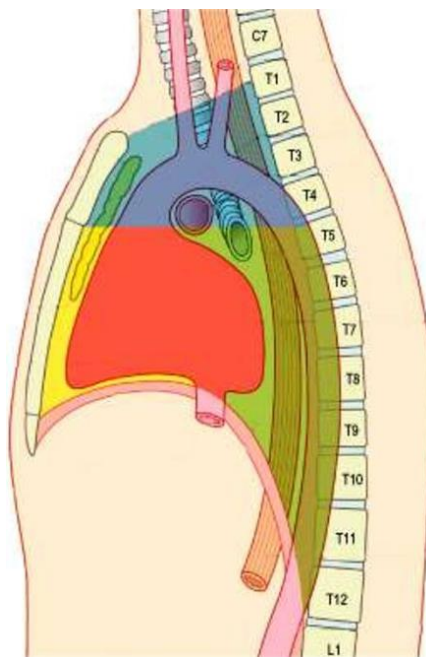
1



2

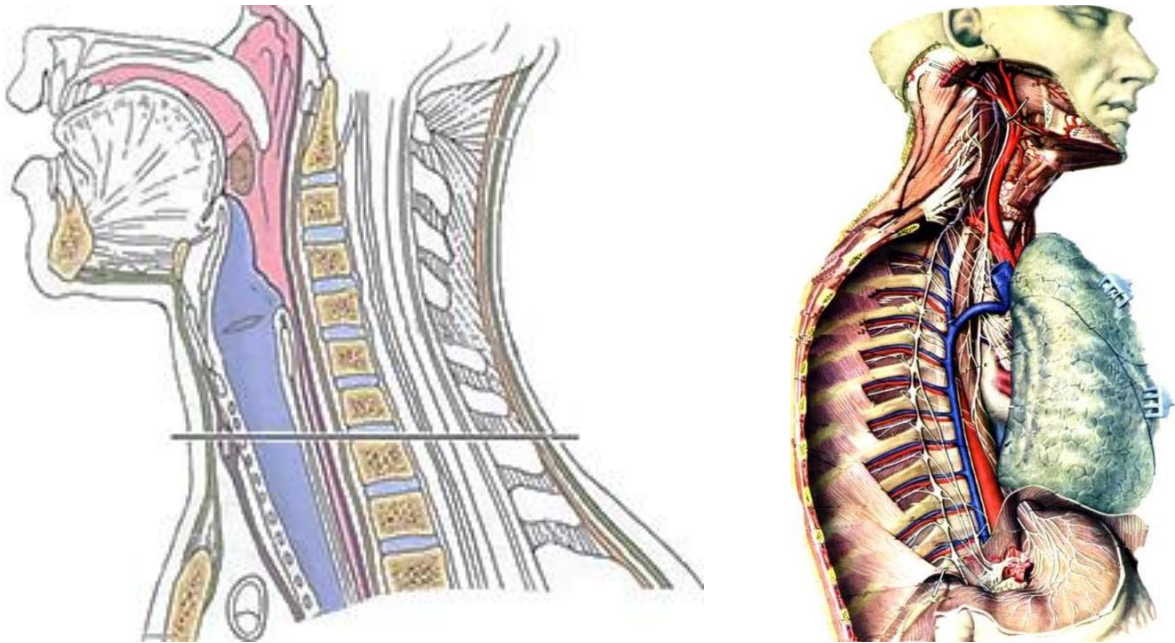
(<http://www.kievoncology.com/mediastinit-i-gemomediastinum.html>)

4. Mark the figure with arrows and sign the boundaries of the anterior, posterior, superior, inferior, central mediastinum.



<https://ppt-online.org/537920>

5. Indicate in the figure with arrows and sign the ways of spreading the exudate into the anterior and posterior mediastinum.



<https://slide-share.ru/funkcionalnaya-anatomiya-mishc-golovi-i-shei-166064;>
<https://osnimke.ru/mrt-grudnoj-kletki/mrt-sredosteniya.html>

Anterior mediastinum:

Posterior mediastinum:

6. Write and justify what causes the severity of acute odontogenic mediastinitis.

7. Fill the table. Complete the clinical description of the indicated symptoms of mediastinitis and indicate for the localization of the process in which mediastinum (anterior or posterior) they are characteristic.

Mediastinal symptoms	Clinical description of mediastinal symptoms	Process localization
	Pulsating pain in the chest, which radiates to the interscapular region and increases with pressure on the spinous processes of the thoracic vertebrae.	
Gercke's symptom		
Ivanov's symptom		
	Pain in the mediastinal region is aggravated by tapping on the heels of outstretched legs in the horizontal position of the patient.	
Symptom Ravich-Shcherbo		
Popov's symptom		
Symptom Ravich-Shcherbo-Steinberg		
Symptom of Rutenburg-Revutsky		
Symptom of unpaired and semi-unpaired vein		

8. Fill in the table. Write the clinical characteristics of the symptoms revealed during the physical examination of the patient.

Symptom	Description of the symptom
Skin of the face, neck, chest	
Number of breaths, breathing patterns	
The patient's position in bed	
Percussion is determined	
Body temperature	
Heart rate	
Arterial pressure	
Level of consciousness	
General condition of the patient	

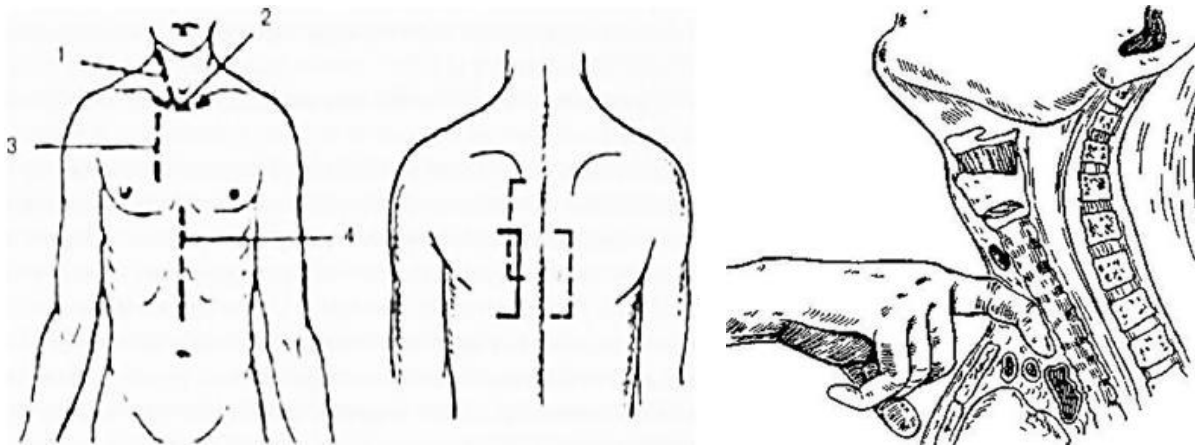
9. Indicate how often additional radiation methods of examination should be performed in a patient with odontogenic mediastinitis.

Radiation research methods are carried out every _____ days.

10. Fill in the missing.

Chest x-ray is performed in three projections: _____,
 _____ and _____ .

11. Indicate on the drawings in which anatomical region a maxillofacial surgeon can perform surgical procedures. Write the name of these surgeries.



(<http://www.med24info.com/books/diagnostika-i-lechenie-gnoynoy-stomatologicheskoy-infekcii-monografiya/glava-15kontaktn-y-odontogenn-y-mediastinit-12389.html>)

12. Fill in the classification table of anaerobic infection in surgery (A. P. Kolesov, A. V. Stolbovoy, V. I. Kocherovets, 1989).

By microbial etiology:	
By the nature of the microflora:	
On the affected part of the body:	
By prevalence:	
By source of infection:	
For reasons of occurrence:	

13. Indicate with arrows the corresponding pairs of clinical description and the name of the clinical form of anaerobic infection.

Clinical forms		Clinical Description
Mixed		A. There is a strong gas infiltration of tissues, rapidly spreading to the surrounding fascial-cellular spaces and muscle masses. The skin has a bronze tint. From the very beginning there is shortness of breath, frequent and intermittent pulse. Patient dies from stenotic asphyxia
Phlegmonous		B. The patient progresses edematous infiltration. The skin is pale, tense, superficial veins are dilated. Emphysema is either completely absent or not pronounced in the focus of inflammation. The general condition is severe. His face is pale, his features are pointed. The pulse is small, irregular. Death occurs quickly, before the pathogen enters the blood
Emphysematous, classic		C. When examining the patient, gas infiltration and edema are equally pronounced. This clinical form is defined as the most dangerous in terms of prognosis
edematous, toxic		D. The process of tissue necrosis prevails. They develop a putrid process associated with the development of spores of low pathogenic pathogens, which, by their action on tissues, contribute to the reproduction of the main agents of anaerobic infection and the spread of the pathological process. The causative agent in this form of anaerobic infection, as a rule, is <i>Cl. sporogenes</i> . The necrotic form of the disease is stated in 10% of cases. Its clinical course is more favorable than that of mixed, edematous and emphysematous forms. Mortality is 9.3%. Zhensul-Ludwig's angina should also be referred to this form
Necrotic (putrid)		E. Emphysema and tissue edema are mild, they do not tend to spread, they are often masked by suppuration caused by an odontogenic infection. Relatively favorable prognosis for recovery, responds well to surgical treatment. With untimely diagnosis and insufficient therapy, they are able to move on to real gas gangrene

14. Write what local clinical signs during the primary surgical treatment of an infectious-inflammatory focus can determine/suggest the presence of anaerobic infection:

- 1) the nature of the exudate _____;
- 2) the nature of the tissues in the wound: adipose tissue _____;
- 3) _____, muscles _____;
- 4) _____ .

15. Write down the antibacterial drugs that are used to treat anaerobic infections. Write the chemical name of the drug and commercial analogues.

« _____ » (_____)	« _____ » (_____)
Rp.:	Rp.:
D.t.d.	D.t.d.
S. _____ administration	S. _____ administration

16. Prescribe the solutions of antiseptics that are used for the local treatment of postoperative wounds with anaerobic infection.

Rp.:	Rp.:
D.t.d.	D.t.d.
S. For local treatment of postoperative wounds with anaerobic infection.	S. For local treatment of postoperative wounds with anaerobic infection.

Theme 12
**ODONTOGENIC SEPSIS IN PATIENTS WITH INFECTIOUS
INFLAMMATORY PROCESSES IN MAXILLOFACIAL AREA AND NECK**


Control questions on the topic:

1. List the criteria for diagnosing a systemic inflammatory response (SIRS).
2. List the criteria for diagnosing sepsis.
3. Name the clinical forms of sepsis.
4. List special investigation methods to be used in patients with suspected sepsis.
5. Tactics of a dentist-surgeon in case of suspected development of odontogenic sepsis in a patient.
6. Give a definition and indicate the clinical and laboratory signs indicating the syndrome of multiple organ failure (MOF).
7. Specify the criteria for MOF in sepsis.
8. List the preventive measures in patients with IIP of the maxillofacial region and neck, aimed at preventing the development of sepsis.
9. What is meant by the term «focal infection»?
10. What are the factors contributing to the development of focal infection.

1. Define sepsis.

Sepsis is _____

2. Complete the flowchart of the components of sepsis.



3. Define systemic inflammatory response syndrome (SIRS).

The systemic inflammatory response syndrome is _____

4. Fill in the table. Designate SIRS Criteria.

Clinical indicators of SIRS	Values of clinical indicators indicating the presence of SIRS
Temperature	
Heart rate	
Respiratory rate / CO ₂ partial pressure	
Leukocytes / % immature forms	

5. Write what are the causes of organ-systemic disorders in sepsis.

6. What is microcirculatory mitochondrial distress syndrome?

7. Give definitions according to the classification of sepsis. Fill the table.

Criteria	Defining features
Sepsis	
Severe sepsis	
Septic shock	
Additional definitions	
Syndrome of multiple organ dysfunction	
Refractory septic shock	

8. At the prehospital stage, when screening patients with suspected sepsis, use the scale _____.

9. To determine organ dysfunction in a hospital, a scale is used

10. The treatment of sepsis has three main components (please fill in the blanks):

1) _____

2) _____

3) _____

11. What is the principle of the «golden hour» in antibiotic therapy for sepsis?

Theme 13
PROGNOSIS OF INFECTIOUS INFLAMMATORY PROCESSES IN
MAXILLOFACIAL AREA AND NECK

Control questions on the topic:

1. Present the characteristic of the integral index of severity (ISI) according to M. M. Solovyov, T. M. Alekhova.
2. Present the characteristics of the leukocyte index of intoxication (LII) according to Ya. Ya. Kalf-Kalif.
3. Present the characteristics of the leukocyte index of intoxication by L. K. Ostrovsky (LIIO).
4. Present the characteristics of the nuclear intoxication index (NI).
5. Present the characteristics of predicting the course of the IIP of the maxillo-facial region and neck according to the microcrystallization of the oral fluid (OF).

1. Complete the formula for calculating the leukocyte index of intoxication Ya. Ya. Kalf-Kalifa.

$$LII = \frac{(4mi + 3y + 2p + c) \times (pl + 1)}{(L + m) \times (e + 1)}$$

2. Indicate the normal values of LII _____
3. Complete the formula for calculating the leukocyte index of intoxication by V. K. Ostrovsky.

LIIO	=	<table border="1" style="width: 100%; border-collapse: collapse;"> <tr> <td style="width: 50%; text-align: center;">Segmented neutrophils</td> <td style="width: 5%; text-align: center;">+</td> <td style="width: 40%;"></td> </tr> </table>	Segmented neutrophils	+		+	<table border="1" style="width: 100%; border-collapse: collapse;"> <tr> <td style="width: 50%; text-align: center;">the young form</td> <td style="width: 5%; text-align: center;">+</td> <td style="width: 40%;"></td> </tr> </table>	the young form	+		+	<table border="1" style="width: 100%; border-collapse: collapse;"> <tr> <td style="width: 50%; text-align: center;">plasma cells</td> <td style="width: 5%; text-align: center;">+</td> <td style="width: 40%;"></td> </tr> </table>	plasma cells	+	
Segmented neutrophils	+														
the young form	+														
plasma cells	+														
		<table border="1" style="width: 100%; border-collapse: collapse;"> <tr> <td style="width: 33%;"></td> <td style="width: 33%;"></td> <td style="width: 33%; text-align: center;">eosinophils</td> </tr> </table>			eosinophils										
		eosinophils													

4. Specify the normal values of LIIO _____
5. Complete the formula for calculating the nuclear index of intoxication by G. D. Dashtayants.

$$NII = \frac{\text{_____} + \text{_____} + \text{stab neutrophils}}{\text{_____}}$$

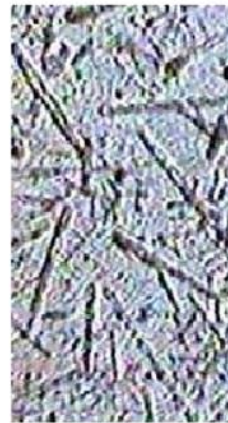

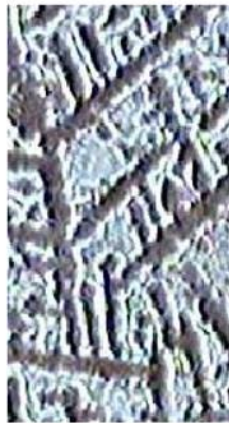
6. Fill in the table.

NI values	General condition of the patient
0,05–0,08	
0,3–1,0	
More 1,0	

7. Fill in the table. Fill in the missing.

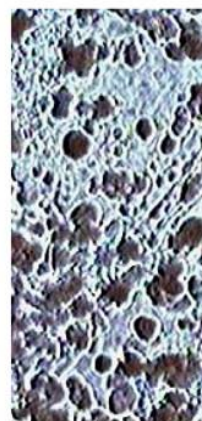
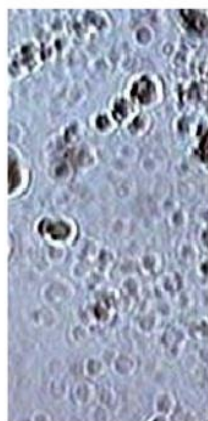
IPT values	The severity of the infectious and inflammatory process / prognosis
Up to 1.5 points	
	Medium /
	/ adverse

8. Assess the dynamics of the course of the IIP of the maxillofacial region and neck according to the micropreparation of microcrystallization of the stomach, when the type of microcrystallization is determined by the method modified by P. A. Leus (1977), write down the result, substantiating it.



[12]

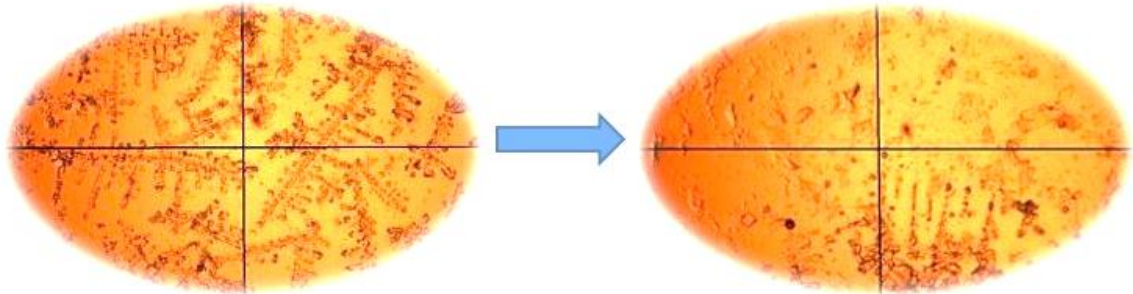
Dynamics _____



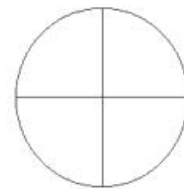
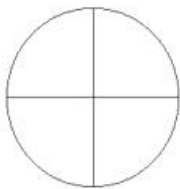
[12]

Dynamics _____


9. Determine the type of microcrystallization of RJ according to the method in the modification P. A. Leus (1977), writing the results obtained in the scheme of quadrants of the preparation under photographs, and then determine the index of microcrystallization of the RJ according to the method of I. O. Pohodenko-Chudakova, Yu. M. Kazakova, N. D. Pohodenko (2011) and evaluate the dynamics of the course of the IVP of the maxillofacial region and neck in accordance with a certain indicator, write down the result, substantiating your conclusion.



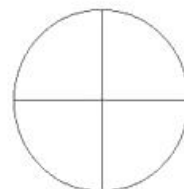
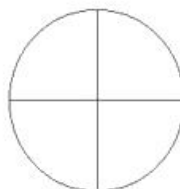
[18]



Dynamics _____



[18]



Dynamics _____

Theme 14
MODERN PRINCIPLES OF PURULENT WOUNDS TREATMENT
IN THE MAXILLOFACIAL AREA AND NECK.
MEDICAL REHABILITATION OF PATIENTS
WITH INFECTIOUS INFLAMMATORY DISEASES
OF MAXILLO-FACIAL AREA IN OUTPATIENT CLINICS

Control questions on the topic:

1. Define «primary» and «secondary» surgical treatment of an infectious-inflammatory focus.
2. Name the principles of primary healing of a purulent wound.
3. Name the principles of secondary healing of a purulent wound.
4. Explain the concept of «primary» purulent wound.
5. Explain the concept of «secondary» purulent wound.
6. What does the concept of «complex treatment of a purulent wound» include?
7. Name the optimal conditions necessary for the healing of a purulent wound.
8. Name the indications and requirements for surgical treatment of a purulent wound.
9. Specify the purpose of drainage of a purulent wound.
10. State the classification of drainages, indicating the indications for the use of each of their types.
11. Specify the mechanism of action of drainage.
12. Define the terms «primary-delayed» suture, «early secondary», «late secondary» sutures.
13. Name the indications for suturing a festering wound.
14. What are the contraindications for suturing a purulent wound.
15. Present a plan for local treatment of a purulent wound, depending on the phase of the course of the wound process.
16. Make a plan for the complex treatment of a patient with IIP of the maxillofacial region and neck.
17. Specify the main physiotherapeutic methods used in the treatment of IIP of the maxillofacial region and neck, the terms and conditions for their implementation.
18. What are the main methods of exercise therapy used in patients with IIP of the maxillofacial region and neck.

1. Define primary intention wound healing.

Wound healing by primary intention is _____


2. Define wound healing by second intention.

Wound healing by secondary intention is _____

3. Fill in the missing. Wound healing by secondary intention occurs when:

- 1) _____ damaged areas;
- 2) if present in the wound _____
- 3) with development _____ in the wound
- 4) presence of tissue defect _____

4. Complete the block diagram. The principle of secondary wound healing includes:



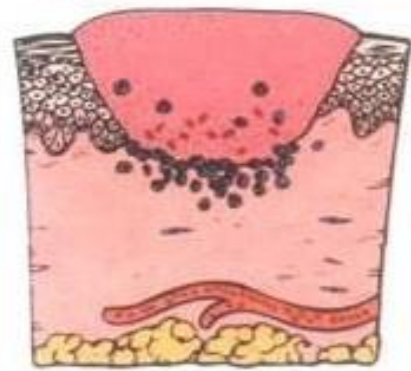
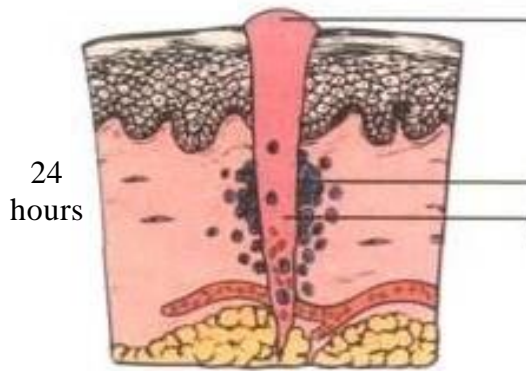
5. List the phases of healing of purulent wounds:

- 1) _____
- 2) _____
- 3) _____

6. Fill in the table. List the drugs used to treat purulent wounds depending on the phase of the wound process.

Local treatment of purulent wounds	
Phase of the wound process	Medicines
I	
II	
III	

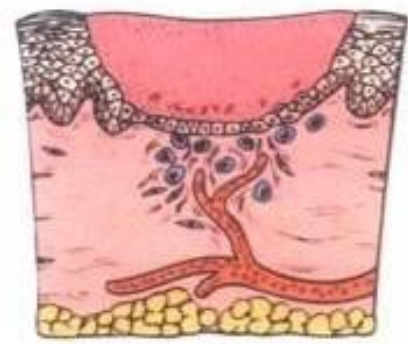
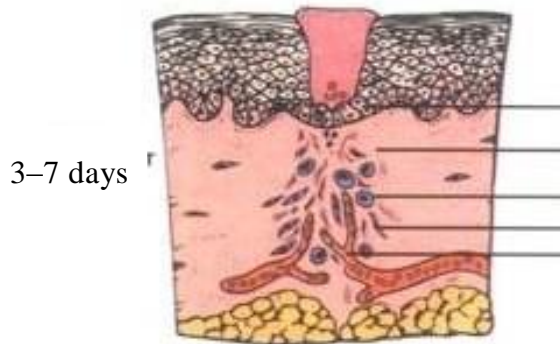
7. Sign the drawings: where healing is shown by *primary*, where by *secondary* intention.



(<https://presentacii.ru/presentation/zazhivlenie-ran>)

_____;

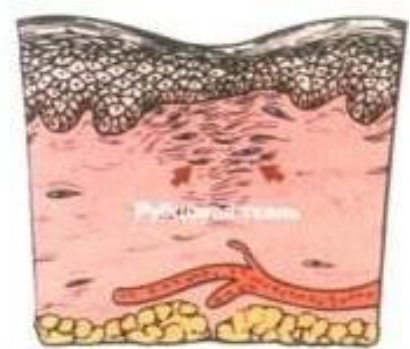
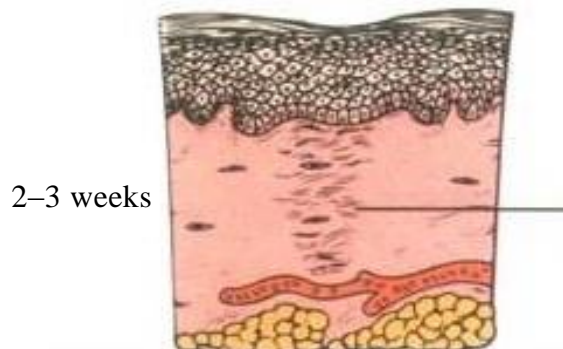
_____;



(<https://presentacii.ru/presentation/zazhivlenie-ran>)

_____;

_____;



(<https://presentacii.ru/presentation/zazhivlenie-ran>)

_____;

_____;

8. Give the definition of a primary purulent wound.

The primary purulent wound is _____

9. Define a secondary purulent wound.

Secondary purulent wound is _____

10. List the necessary conditions for optimal healing of purulent wounds:

1) _____

2) _____

3) _____

4) _____

5) _____

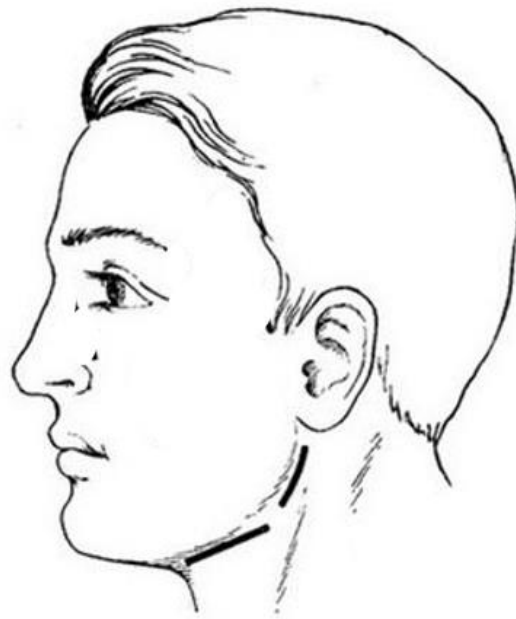
11. Write what is meant by surgical treatment of a purulent wound.

12. Write what does the complete treatment of a purulent wound include?

13. Write what does partial treatment of a purulent wound include?

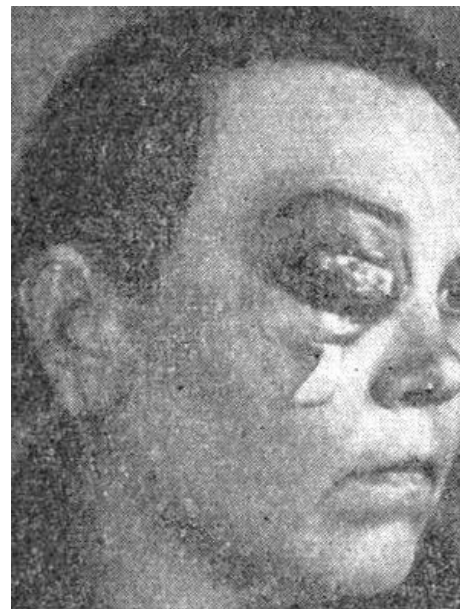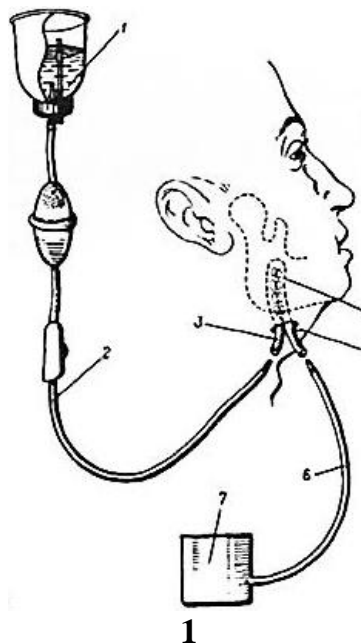
14. Write how the secondary surgical treatment of a purulent wound differs from the primary? _____

15. Indicate in the figure the lines of incisions that are made during the primary surgical treatment of purulent wounds (as it is shown in the submandibular region).



(<http://kursak.net/t-f-lavrova-v-n-gryaznov-n-v-archakov-xirurgicheskaya-anatomiya-kletchatochnyx-prostranstv-golovy-i-operacii-pri-odontogennyx-flegmonax/>)

16. Select and sign, which figure shows *active*, and which *passive* drainage of purulent wounds?



(<https://prezentacii.org/prezentacii/prezentacii-raznie/134918-abscessy-i-flegmony-chlo.html>)

17. Fill in the table. Specify the terms of applying different types of sutures in the treatment of purulent wounds.

Suturing a purulent wound	
Type of surgical suture	The timing of suturing

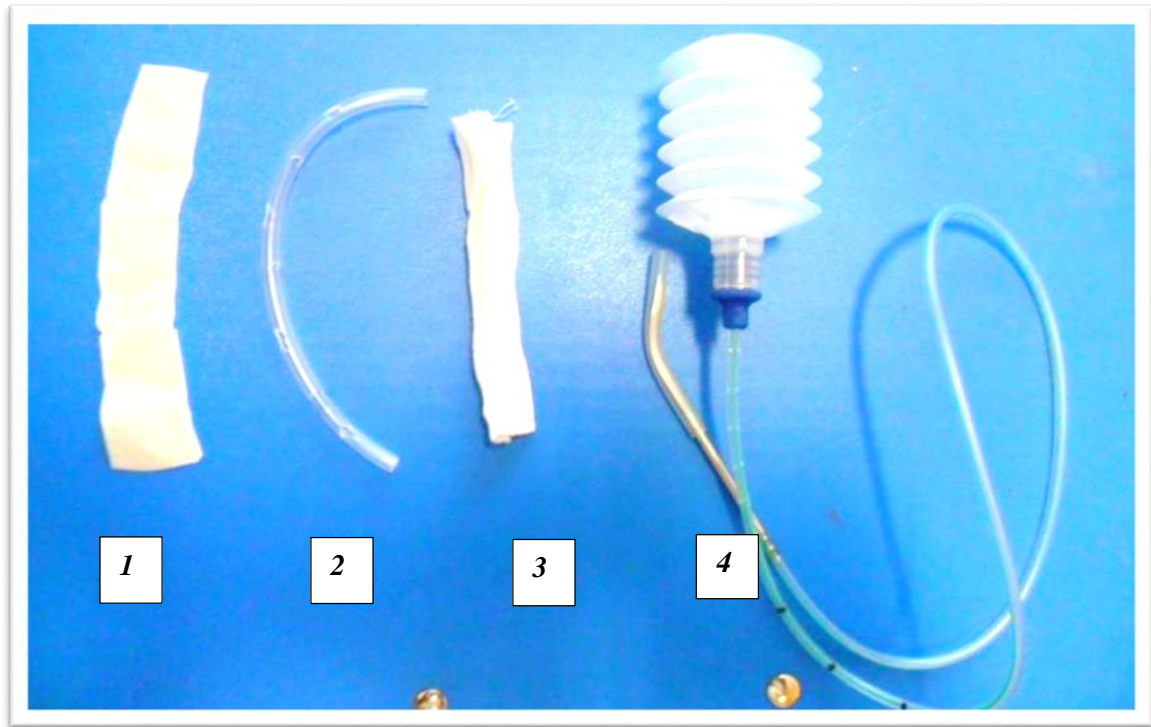
18. Fill in the table. Write indications and contraindications for suturing a purulent wound.

Suturing a purulent wound	
Indications	Contraindications

19. Fill in the table. Write indications and contraindications for physiotherapy in the treatment of purulent wounds.

Indications for prescribing	Contraindications for prescribing

20. Sign the types of drainage shown in the figure.



- 1) _____
- 2) _____
- 3) _____
- 4) _____

Theme 15

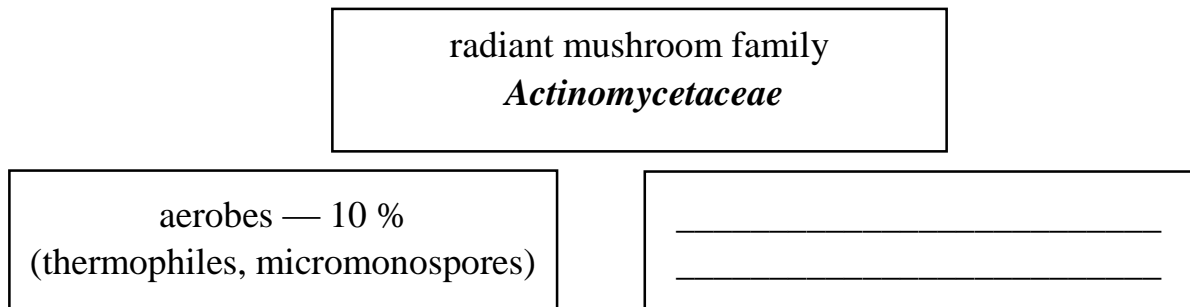
SPECIFIC INFLAMMATORY PROCESSES IN MAXILLOFACIAL AREA (ACTINOMYCOSIS OF THE MAXILLOFACIAL REGION. SYPHILIS, TUBERCULOSIS, HIV-INFECTION OF THE MAXILLOFACIAL REGION)

Control questions on the topic:

1. Present the etiology and pathogenesis of actinomycosis.
2. Describe the features of the pathological anatomy of actinomycosis.
3. Present the classification of actinomycosis of the maxillofacial region according to K. I. Berdygan.
4. Present the classification of actinomycosis of the maxillofacial region according to T. G. Robustova.
5. State the classification of actinomycosis of the maxillofacial region according to ICD-10.
6. Describe the features of the clinical manifestations of actinomycosis of the maxillofacial region, depending on its form.
7. Present the X-ray picture of actinomycosis of the jaw bones and justify the methods of radiation diagnostics recommended for examination.
8. Name modern methods for diagnosing actinomycosis.
9. What is called the specific diagnosis of actinomycosis?
10. Make a differential diagnosis of actinomycosis with other specific diseases.
11. Outline the basic principles of complex treatment of actinomycosis of the maxillofacial region.
12. Describe the features of the primary surgical treatment of actinomycosis foci.
13. Provide a list of preventive measures for actinomycosis.
14. Present the etiology, pathogenesis and ways of transmission of an infectious agent in syphilis.
15. Outline the clinical classification of syphilis and the classification of syphilitic lesions according to ICD-10.
16. Present the etiology, pathogenesis and ways of transmission of an infectious agent in tuberculosis.
17. Outline the classification of clinical forms of tuberculosis and the classification of tuberculosis according to ICD-10.
18. Present the etiology, pathogenesis and transmission of HIV infection.
19. Outline the clinical classification of HIV infection and the classification of HIV infection according to ICD-10.
20. List modern diagnostic methods and differential diagnosis of syphilis, tuberculosis, HIV infection.
21. Specify the clinical manifestations of syphilis in the maxillofacial region depending on the period of the disease.
22. List the radiographic signs of syphilis damage to the bones of the facial skeleton.
23. Name the clinical manifestations of tuberculosis in the maxillofacial region depending on the form of the disease.
24. List the radiographic signs of tuberculosis damage to the bones of the facial skeleton.

25. Name the clinical manifestations of HIV infection in the maxillofacial area.
26. Outline the tactics of a dentist-surgeon in relation to a patient with a suspected diagnosis of syphilis, tuberculosis, HIV infection.
27. Present the differential diagnosis of lesions of the bones of the facial skeleton with syphilis and tuberculosis.
28. Outline the modern principles of treatment of patients with manifestations of syphilis, tuberculosis, HIV infection in the maxillofacial region.

1. Draw using the arrows and fill in the diagram of the etiology of actinomycosis.



2. Define an actinomycotic granuloma.

Actinomycosis granuloma is _____

3. Cutaneous form of actinomycosis is divided into (fill in the missing forms):

- 1) _____ ;
- 2) tubercular;
- 3) _____ .

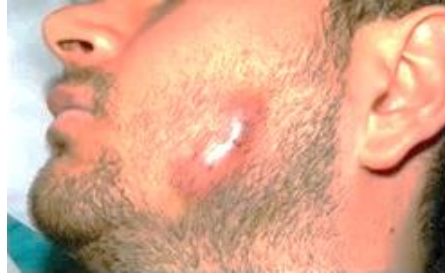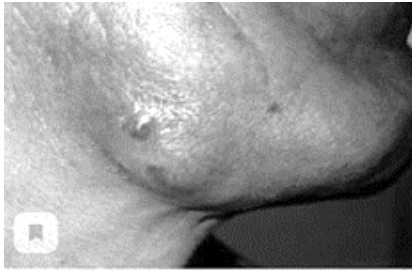
4. Subcutaneous form of actinomycosis is divided into (fill in the missing forms):

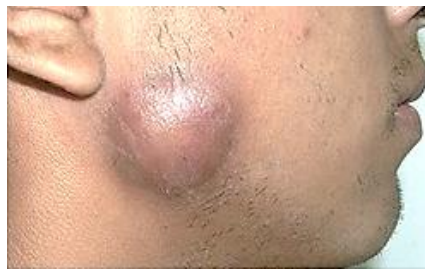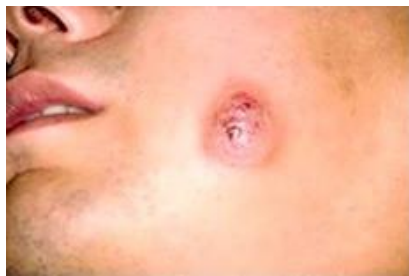- 1) absceding;
- 2) _____ ;
- 3) _____ ;

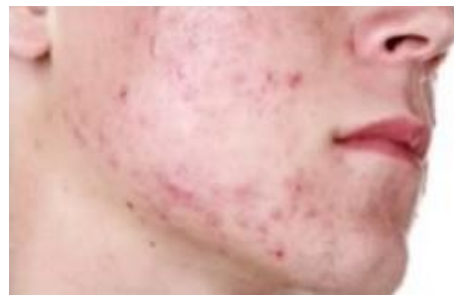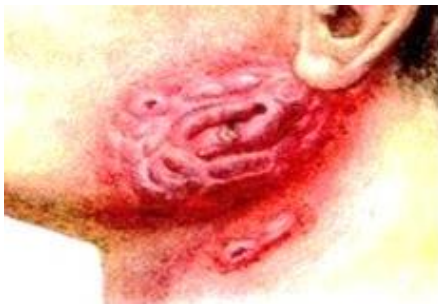5. Radiant mushrooms, penetrating through the mucous membrane of the oral cavity or skin, begin to assimilate into (complete the missing):

- 1) _____ ;
- 2) _____ ;
- 3) lymph nodes.

6. Sign under each of the figures the form of actinomycosis that it illustrates.



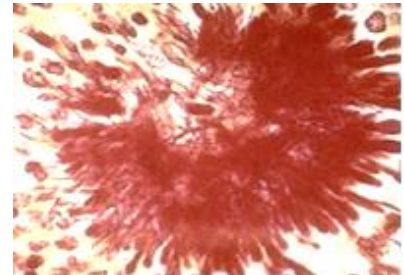
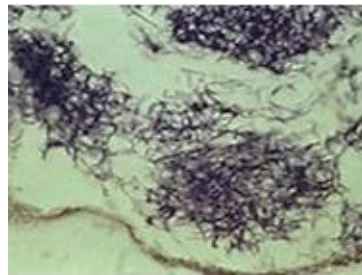
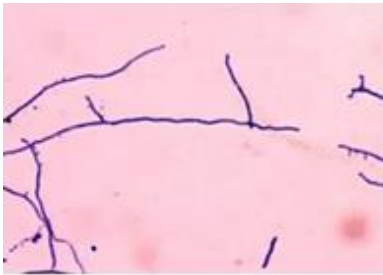



7. It is known that the tissue reaction to the introduction of the radiant fungus — actinomycete is manifested in the development of a specific granuloma — actiomycoma or actinomycosis granuloma. At the same time, the focus of specific inflammation is a complex of several actinomycosis granulomas, which are at different stages of development. In the center of the granuloma in the form of small whitish grains — drusen are actinomycetes. It is customary to distinguish four stages of such changes. Indicate the correct sequence of these stages by writing the corresponding number in brackets:

- lysis (___);
- deposition of calcium salts in the focus of inflammation (___);
- transformation of a part of the focus into an ameloid (___);
- absorption of foreign bodies by macrophages (___).

8. Connect the image and the corresponding caption with arrows.

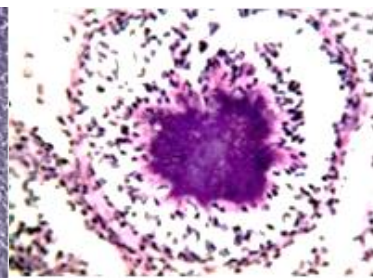
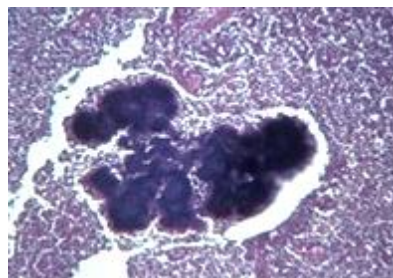


Actinomycosis granuloma

Druses of pathogenic actinomycetes

Mycelial filaments of actinomycetes

Clusters of Actinomyces Israelii in tissues



9. Provide a modern diagnosis of actinomycosis by filling in the missing columns in the table.

Diagnostic measures	Diagnostic results with actinomycosis
Bacterioscopy of native pus preparations with the search for actinomycete drusen	
Isolation of the radiant fungus culture by inoculation of the wound exudate on nutrient media	
Skin allergic reactions with diagnostic actinolysate	
Reaction of inhibition of migration of leukocytes of blood	
Biopsy of actinomycosis granuloma followed by microscopic examination of tissue	

10. Outline the main provisions of the modern complex treatment of actinomycosis of the maxillofacial region by filling out the table below.

Surgical treatment
Conservative treatment Creation of specific immunity
Anti-inflammatory therapy

Treatment of associated diseases
Increasing the overall reactivity of the body
Physiotherapy and exercise therapy

11. List and write down the possible complications of actinomycosis of the maxillofacial region:

- 1) _____;
- 2) _____;
- 3) _____.

12. Complete the sentences by adding the missing.

The incubation period for syphilis is _____.

Primary syphilis on the oral mucosa appears as _____.

Secondary syphilis on the oral mucosa manifests itself as:

- 1) _____;
- 2) _____.

Tertiary syphilis is characterized by the formation _____

_____ .

13. Outline the basic principles of dispensary observation of patients with actinoincosis of the maxillofacial region by a dentist by filling in the free fields in the table below.

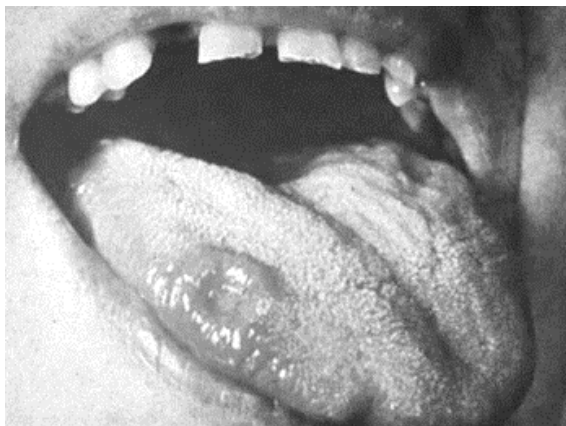
Nosological form	Frequency of observation at the dentist	Medical examinations by specialist doctors	Name and frequency of laboratory and other diagnostic studies	Basic therapeutic and preventive measures	Terms of observation and criteria for de-registration	Criteria for the effectiveness of clinical examination
Specific inflammatory processes of the maxillofacial region (actinomycosis B 37)	Group D (III) — sub-compensated course — 3 visits per year (3 months, 6 months, 12 months)					
	Group D (II) — compensated course — 2 visits per year					

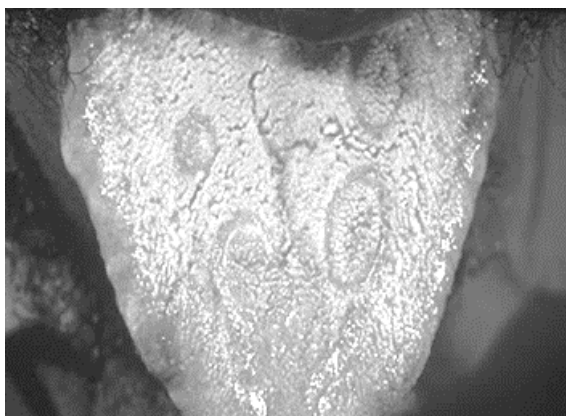14. Make a list of diseases and complete the phrase.

Differential diagnosis of syphilis should be carried out with diseases from the following list:

- 1) _____ ;
- 2) _____ ;
- 3) _____ ;
- 4) _____ ;
- 5) _____ ;
- 6) _____ ;
- 7) _____ ;
- 8) _____ ;
- 9) _____ .

15. Determine what type of specific inflammatory processes and what stage shown in the illustrations belong to and make the appropriate signatures.





16. Complete the fragments of the classification of tuberculosis by adding the missing items.

Tuberculosis is classified into:

- 1) primary;
- 2) _____.

It is customary to distinguish the following clinical forms of tuberculosis:

- 1) skin tuberculosis;
- 2) tuberculosis of the subcutaneous tissue;
- 3) tuberculosis of the lymph nodes;
- 4) _____;
- 5) _____;
- 6) _____;

Tuberculosis of the skin and subcutaneous tissue is classified into:

- 1) tuberculous chancre;
- 2) scrofuloderma;
- 3) _____.

Tuberculosis of the jaws is divided into:

- 1) bone damage with active pulmonary tuberculosis;
- 2) _____;

17. Complete the algorithm for diagnosing tuberculosis by adding the missing positions:

- 1) clarification of contact with a person who is affected by tuberculosis or tuberculosis is present in the patient's history;
- 2) detection of the presence of intoxication and respiratory syndromes;
- 3) analysis of the results of radiation research methods;
- 4) sputum bacterioscopy (if any);
- 5) bacterioscopy of discharge from the ulcer / fistula (if any);
- 6) _____;
- 7) _____;
- 8) _____.

18. Complete the sentences by adding the missing data from the pathogenesis of tuberculosis.

At the site of the introduction of an infectious agent, an infiltrate occurs without acute inflammatory phenomena, which ulcerates after _____ days.

The appearance of an ulcer, more often on the tongue, gums, lips, is accompanied by an increase in the submandibular lymph nodes. Ulcers increase to _____ cm in diameter, their bottom and edges are compacted, covered with a dirty gray coating.

The Mantoux test becomes positive at _____ week of illness.

19. Complete the sentence by adding the missing information.

The incubation period for HIV infection is _____.

20. Complete the sentence by adding the missing.

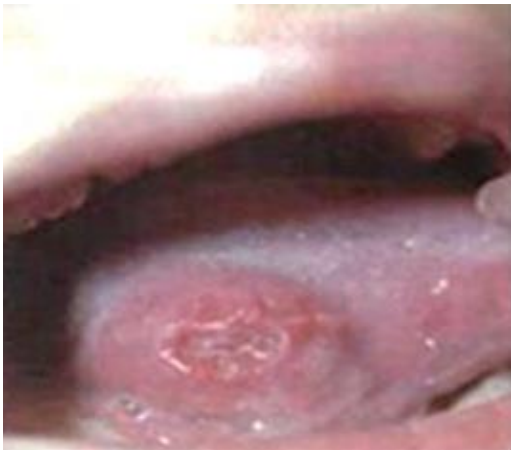Oral lesions less frequently associated with HIV infection include:

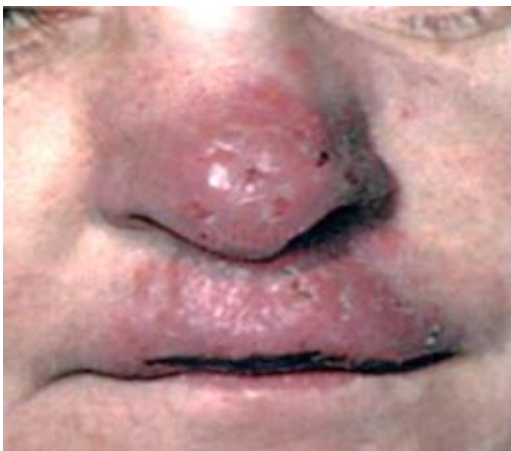- 1) _____ ;
- 2) _____ .

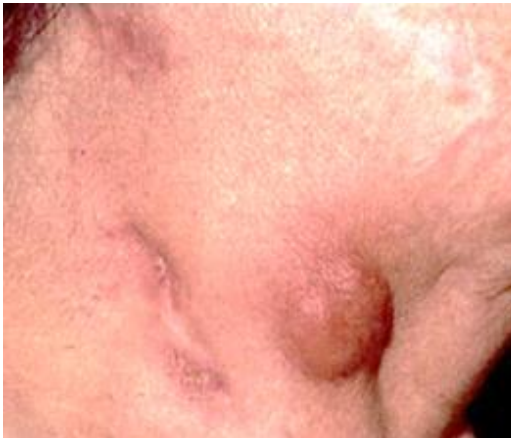21. Make and write down a list of oral lesions often associated with HIV infection:

- 1) _____ ;
- 2) _____ ;
- 3) _____ ;
- 4) _____ ;
- 5) _____ ;
- 6) _____ .

22. Determine what type of tuberculous lesions the clinical situations presented in the illustrations belong to and make the appropriate signatures.







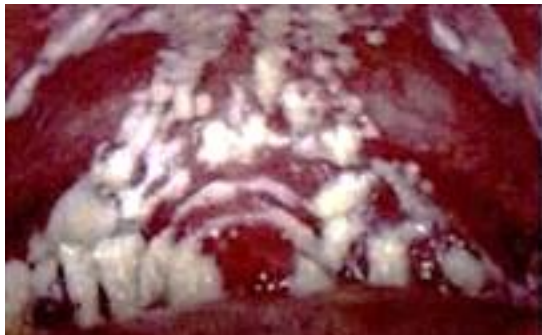
23. Fill in the table of lesions of the oral cavity in HIV infection, adding the missing characteristics to the types of lesions.

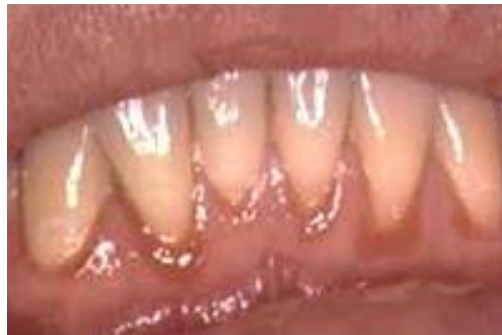Damage type	Type of defeat
Fungal infections	
Bacterial infections	
Viral infections	
Neoplasms	

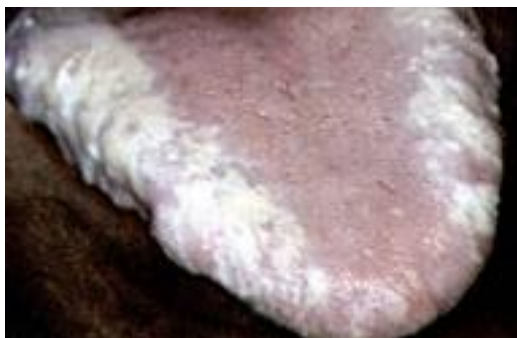24. Make a list of ways to protect dentists from HIV infection:

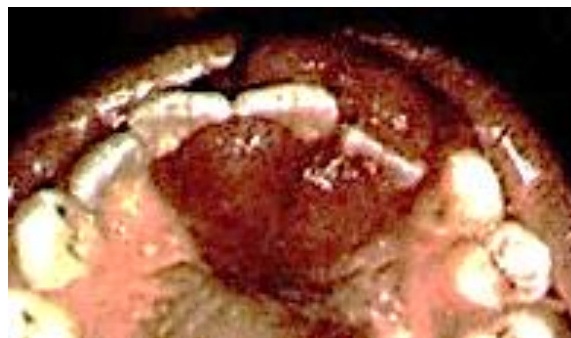- 1) _____ ;
- 2) _____ ;
- 3) _____ ;
- 4) _____ ;
- 5) _____ ;

25. Label the oral lesions often associated with HIV infection that are depicted in the illustrations.









26. Fill in the missing HIV target cells:

- 1) _____ (T- helper);
- 2) macrophages;
- 3) _____.

Theme 16

DISEASES OF THE MAXILLARY SINUS (ODONTOGENIC MAXILLARY SINUSITIS. PERFORATIONS AND FISTULAS OF THE MAXILLARY SINS)

Control questions on the topic:

1. Name the etiological factors in the development of acute and chronic odontogenic maxillary sinusitis.
2. Determine the pathogenesis of acute and chronic odontogenic maxillary sinusitis.
3. Give the clinical classification of odontogenic maxillary sinusitis and the corresponding fragment of the ICD-10 classification.
4. List the main clinical symptoms of acute and chronic odontogenic maxillary sinusitis.
5. List the modern methods for diagnosing inflammatory diseases of the maxillary sinus.
6. Make a differential diagnosis of acute and chronic odontogenic maxillary sinusitis.
7. Make a differential diagnosis of rhinogenic and odontogenic maxillary sinusitis.
8. Specify the features of preoperative preparation of patients with a diagnosis of chronic odontogenic hyperplastic maxillary sinusitis».
9. List the instruments and name the stages of performing a puncture of the maxillary sinus.
10. List the options for surgical access to perform a radical operation on the maxillary sinus.
11. List the stages of performing a radical operation on the maxillary sinus.
12. Describe the methods of surgical treatment of chronic odontogenic maxillary sinusitis.
13. Make a plan for examining a patient with a pathology of the maxillary sinus.
14. Determine the tactics of treating a patient with chronic odontogenic maxillary sinusitis.
15. Define indications and contraindications for surgical treatment of patients with chronic odontogenic maxillary sinusitis.
16. Determine indications for puncture of the maxillary sinus.

1. Present the classification of maxillary sinusitis, completing the missing.

I. According to the course of the disease:

- 1) _____;
- 2) _____.

II. According to the etiological factor:

- 1) viral (developing after an acute respiratory infection);
- 2) _____;
- 3) fungal (mycotic, often developing as chuperinfection);
- 4) _____;
- 5) allergic.

III. By _____ (the genesis of the disease):

- 1) rhinogenic;
- 2) 2) _____.

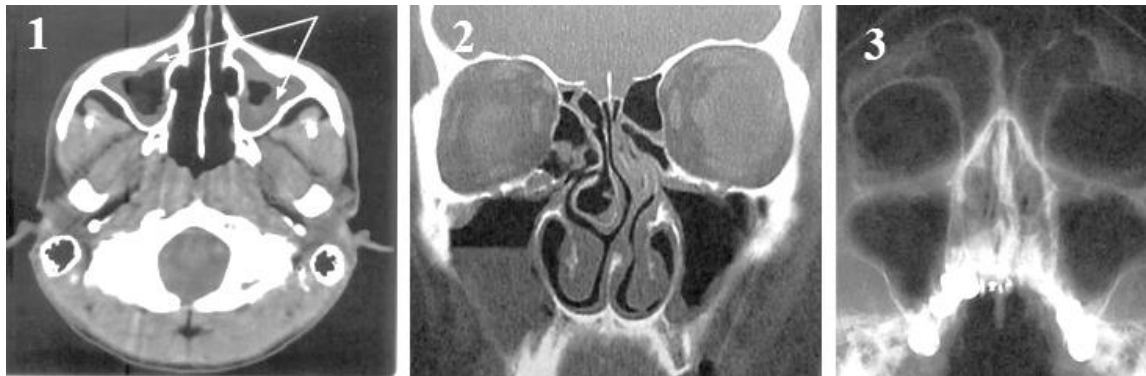
IV. Form:

- 1) exudative;
- 2) _____;
- 3) catarrhal;
- 4) _____;
- 5) productive;
- 6) _____;
- 7) polyposis.

V. According to the severity:

- 1) _____;
- 2) _____;
- 3) _____.

2. Make a diagnosis based on the results of the X-ray methods of examination presented below and write them down in accordance with the serial number of the illustrations.



1) _____;

2) _____;

3) _____.

3. The maxillary sinus contains several bays in its composition, fill in the missing:

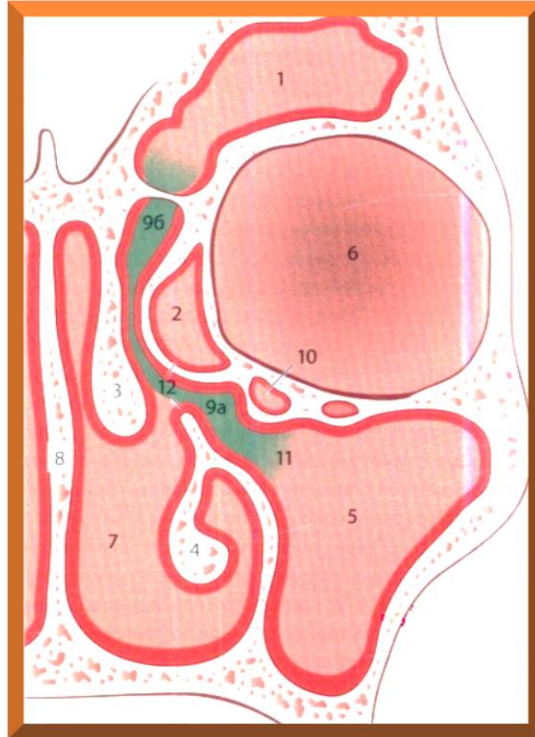1) alveolar;

3) spheroidal;

2) _____;

4) _____.

4. Analyze the scheme of the osteomeatal complex and adjacent anatomical structures and sign the missing:



1 — frontal sinus;

2 — lattice labyrinth;

3 — middle turbinate;

4 — inferior turbinate;

5 _____;

6 — eye socket;

7 — nasal cavity;

8 — nasal septum;

9a _____;

9b _____;

10. — orbital cell of the ethmoid labyrinth;

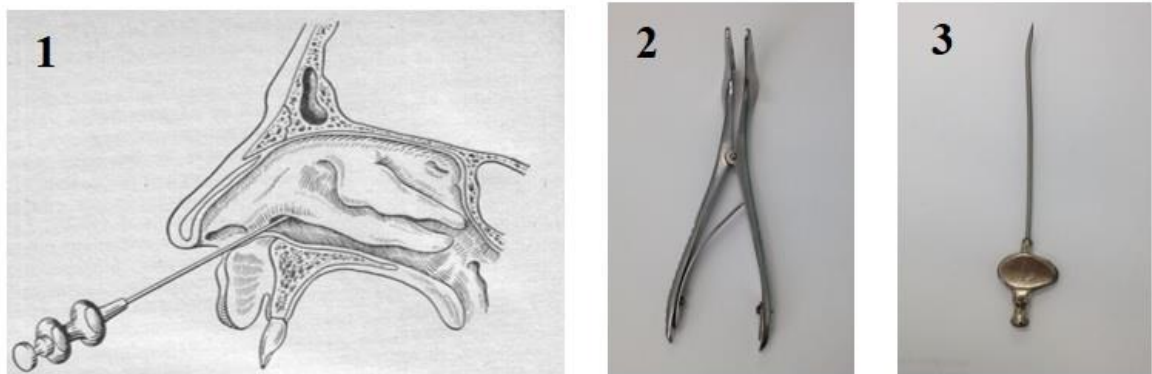
11. — _____;

12. — _____.

5. Analyze the functions of the maxillary sinus listed below and classify them into groups of external and internal, connecting the corresponding positions with arrows.

purification, heating and humidification of the air entering the nose when inhaling	external functions
ventilation	
drainage	
the formation of an individual timbre and the sound of a voice due to the formation of resonance	internal functions
olfactory	
structural	
protective: cilia of epithelial tissue contribute to the removal of mucus	

6. Name and write down the manipulation shown in the figure, as well as the depicted tools in accordance with the serial numbers shown in the illustrations.

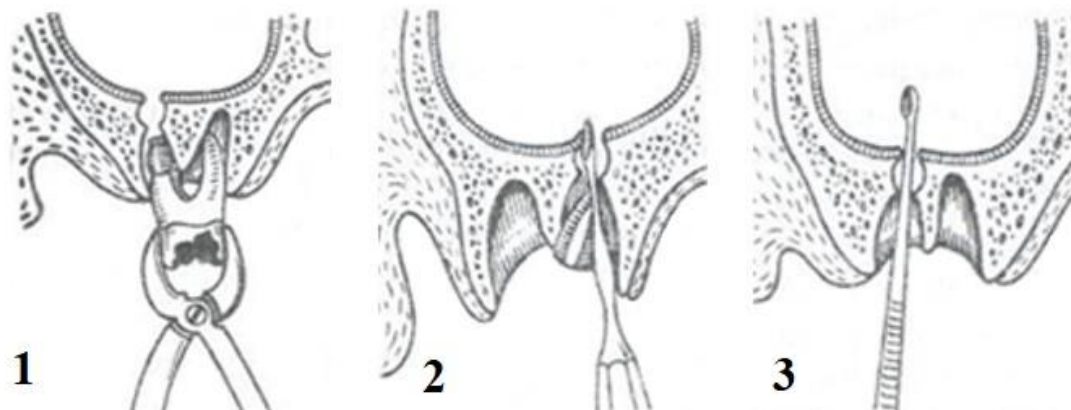


- 1) _____;
- 2) _____;
- 3) _____.

7. Choose and underline the correct answer to the question: «Through which nasal passage is the puncture of the maxillary sinus performed?»

- 1) through the upper nasal passage;
- 2) through the middle nasal passage;
- 3) through the lower nasal passage.

8. List the causes of maxillary sinus perforation shown below and write them down according to the sequence numbers shown in the illustrations.

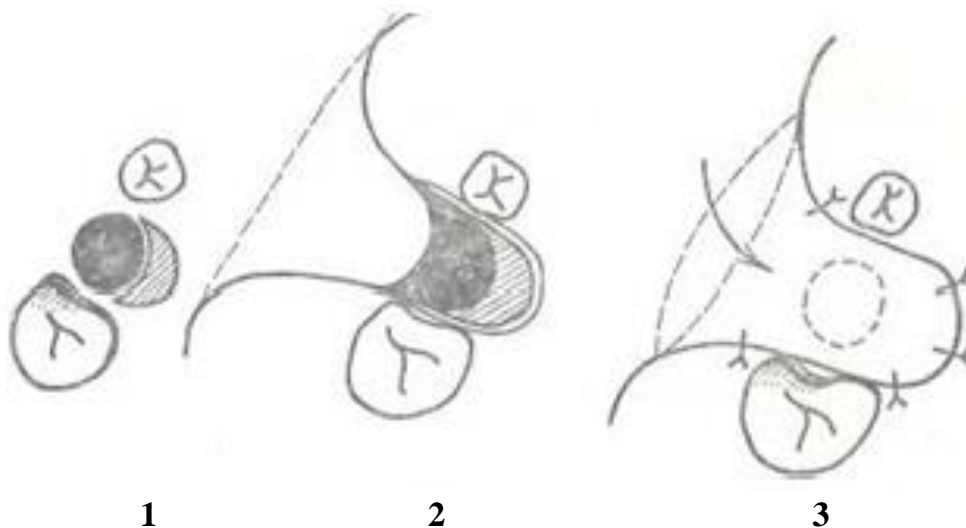


- 1) _____;
- 2) _____;
- 3) _____.

9. Choose from the list of symptoms and connect them with arrows to the corresponding diagnoses (odontogenic chronic maxillary sinusitis and perforation of the maxillary sinus)

Pain in the region of the maxillary sinus may occur at rest	purulent discharge from the nose on the affected side	bleeding with air bubbles from the socket of the extracted causative tooth
bleeding from the corresponding side of the affected half of the nose	occasional nasal congestion	the patient is unable to inflate the cheeks as air escapes through the perforation and nose
feeling of heaviness in the upper jaw area	smell disorder	the patient's feeling of a freely circulating air stream through the socket of the extracted causative tooth
nasality (pronouncing sounds through the nose)	foul odor from the mouth and airways	maxillary sinus perforation
chronic odontogenic maxillary sinusitis		

10. Sign the stages of the operation of plastic elimination of the perforation of the maxillary sinus with local tissues in accordance with the indicated serial numbers.



- 1) _____
 _____;
- 2) _____
 _____;
- 3) _____
 _____.

11. Select and underline from the proposed list the position in which the patient should be during radiography performed to determine the presence of exudate in the maxillary sinus:

- 1) lying on back;
- 2) lying on side;
- 3) standing;
- 4) lying on stomach.

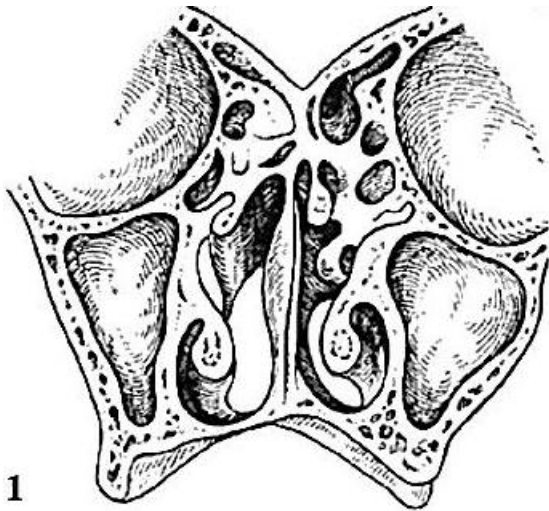
12. Choose and underline the correct answer to the question: «In the area of which walls of the maxillary sinus the mucous membrane is mainly affected in case of odontogenic sinusitis?»

1. Lower.
2. Upper.
3. Medial.
4. Posterior.
5. Lateral.
6. Anterior.

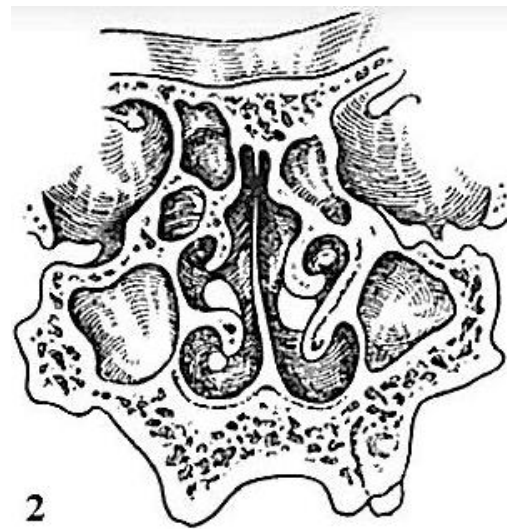
13. Make a differential diagnosis of rhinogenic and odontogenic maxillary sinusitis by filling in the table.

Clinical signs	Differentiable diseases	
	Rhinogenic sinusitis	Odontogenic sinusitis
Source of infection	_____ _____ _____	_____ _____ _____
Localization and distribution	_____ _____ _____	_____ _____ _____
Communication with the oral cavity	_____ _____ _____	_____ _____ _____
Clinical form	_____ _____ _____	_____ _____ _____

14. Sign the two types of structure of the maxillary sinus shown in the illustration in accordance with the indicated serial numbers.

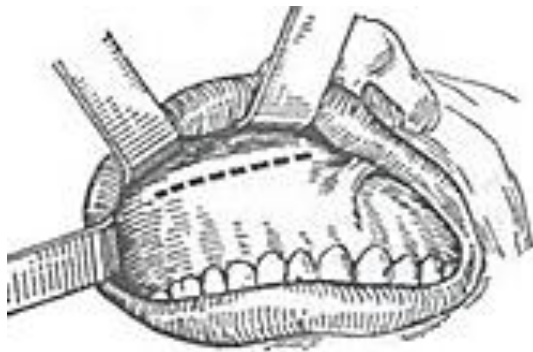


1) _____

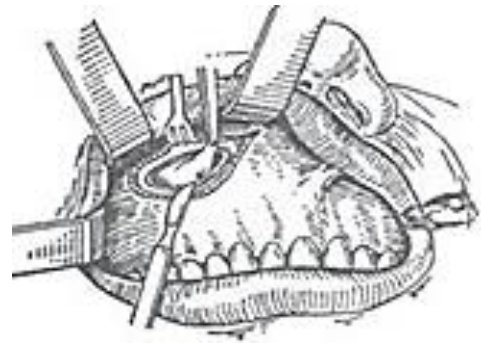


2) _____

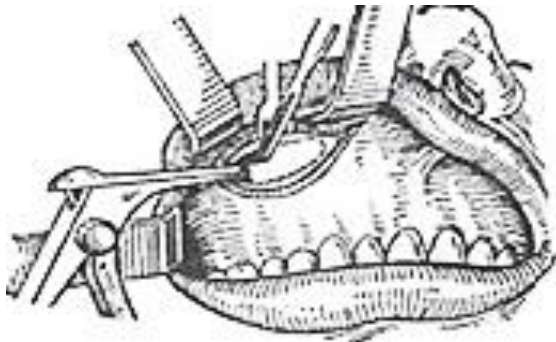
16. Sign the stages of surgical intervention shown in the illustration - radical surgery on the maxillary sinus in accordance with the indicated serial numbers.



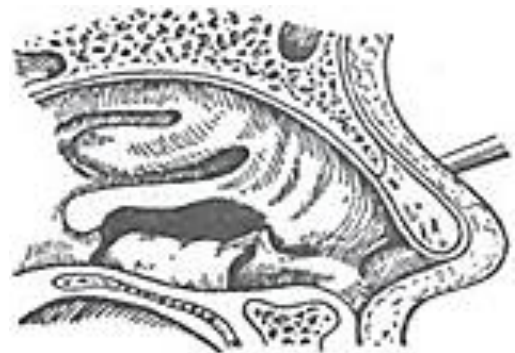
1



2



3



4

- 1) _____
_____;
- 2) _____
_____;
- 3) _____
_____;
- 4) _____
_____.

LITERATURE

1. *Oral and maxillofacial surgery* : textbook / ed. by prof. V. Malanchuk. 2nd ed. 2018. Part 1. 440 p.
2. *Oral and maxillofacial surgery* : textbook / ed. by prof. V. Malanchuk. 2nd ed., 2018. Part. 2. 440 p.
3. *Perioperative Assessment of the Maxillofacial Surgery Patient: Problem-based Patient Management* / Ferneini Elie M., Bennett Jeffrey D. (eds.). Springer, 2018. 702 p.
4. *Nahlieli, O. Minimally Invasive Oral and Maxillofacial Surgery* / O. Nahlieli. Springer, 2018. 203 p.
5. *Schmidt, G. New Insights into Oral and Maxillofacial Surgery* / G. Schmidt. HAYLE MEDICAL, 2019. 209 p.
6. *Contemporary Oral and Maxillofacial Surgery* / James R. Hupp DMD MD JD MBA, Myron R. Tucker DDS, Edward Ellis III DDS MS. 7th ed. Mosby, 2018. 721 p.
7. *Operative Oral and Maxillofacial Surgery* / John D. Langdon [et al.]. 3rd ed. CRC Press, 2017. 951 p.
8. *Rogers, N. Basic Guide to Oral and Maxillofacial Surgery* / N. Rogers, C. Pickett. Wiley-Blackwell, 2017. 160 p.
9. *Laskin, Daniel M. Clinician's Handbook of Oral and Maxillofacial Surgery* / Daniel M. Laskin, Eric R. Carlson. 2nd ed. Quintessence Pub Co, 2018. 624 p.

CONTENT

List of abbreviations and symbols.....	3
Topics of students' educational research work (SERW)	4
Theme 1. Odontogenic infectious inflammatory diseases of maxillofacial area and neck.....	5
Theme 2. Apical periodontitis. Surgical treatment of apical periodontitis	10
Theme 3. Diseases of eruption, retention, dystopia	15
Theme 4. Periostitis of the jaws	21
Theme 5. Acute odontogenic osteomyelitis of the jaws	28
Theme 6. Chronic odontogenic osteomyelitis of the jaws	32
Theme 7. Odontogenic lymphadenitis of the maxillofacial area and neck.....	36
Theme 8. Differential diagnosis of periodontitis, periostitis, odontogenic osteomyelitis of jaws, lymphadenitis	41
Theme 9. Furuncles and carbuncles of the maxillofacial area and neck.....	47
Theme 10. Severe complications of infectious-inflammatory processes of the maxillo-facial region (phlebit of the facial veins, thrombosis of the cavernous sinus). Clinic, diagnosis, treatment, prevention.....	52
Theme 11. Anaerobic infection in the maxillofacial region, odontogenic mediastinitis (severe complications of infectious-inflammatory processes of the maxillofaqarial region).....	57
Theme 12. Odontogenic sepsis in patients with infectious inflammatory processes in maxillofacial area and neck.....	65
Theme 13. Prognosis of infectious inflammatory processes in maxillofacial area and neck.....	68
Theme 14. Modern principles of purulent wounds treatment in the maxillofacial area and neck. Medical rehabilitation of patients with infectious inflammatory diseases of maxillo-facial area in outpatient clinics....	71
Theme 15. Specific inflammatory processes in maxillofacial area (actinomycosis of the maxillofacial region. Syphilis, tuberculosis, hiv-infection of the maxillofacial region).....	78
Theme 16. Diseases of the maxillary sinus (odontogenic maxillary sinusitis. Perforations and fistulas of the maxillary sins)	90
Literature	98

Учебное издание

Походенько-Чудакова Ирина Олеговна
Максимович Екатерина Викторовна
Шевела Татьяна Леонидовна и др.

**ХИРУРГИЧЕСКАЯ СТОМАТОЛОГИЯ
И ПРОПЕДЕВТИКА ХИРУРГИЧЕСКИХ ЗАБОЛЕВАНИЙ
ЧЕЛЮСТНО-ЛИЦЕВОЙ ОБЛАСТИ**

**ORAL SURGERY AND PROPAEDEUTIC
OF MAXILLOFACIAL SURGICAL DISEASES**

Практикум для студентов,
обучающихся по специальности «Стоматология»
в 6-м семестре

2-е издание

На английском языке

Ответственная за выпуск И. О. Походенько-Чудакова
Компьютерная вёрстка А. В. Янушкевич

Подписано в печать 16.01.26. Формат 60×84/16. Бумага «Снегурочка».
Ризография. Гарнитура «Times».
Усл. печ. л. 5,81. Уч.-изд. л. 4,1. Тираж 79 экз. Заказ 39.
Издатель и полиграфическое исполнение: учреждение образования
«Белорусский государственный медицинский университет».
Свидетельство о государственной регистрации издателя, изготовителя,
распространителя печатных изданий № 1/187 от 24.11.2023.
Ул. Ленинградская, 6, 220006, Минск.