

МИНИСТЕРСТВО ЗДРАВООХРАНЕНИЯ РЕСПУБЛИКИ БЕЛАРУСЬ
БЕЛОРУССКИЙ ГОСУДАРСТВЕННЫЙ МЕДИЦИНСКИЙ УНИВЕРСИТЕТ
КАФЕДРА МОРФОЛОГИИ ЧЕЛОВЕКА

С. Л. КАБАК

**КЛИНИЧЕСКАЯ АНАТОМИЯ
И ОПЕРАТИВНАЯ ХИРУРГИЯ
ГОЛОВЫ И ШЕИ**

**CLINICAL ANATOMY:
HEAD AND NECK**

Практикум для самостоятельной работы



Минск БГМУ 2015

УДК 611.91/.93:617.5(811.111)-054.6(076.5) (075.8)
ББК 28.70 (81.2 Англ-923)
К12

Рекомендовано Научно-методическим советом университета в качестве
практикума 17.12.2014 г., протокол № 4

Р е ц е н з е н т ы: канд. мед. наук, проф. С. Д. Денисов; канд. мед. наук, доц. О. Л. Жа-
рикова

Кабак, С. Л.

К12 Клиническая анатомия и оперативная хирургия головы и шеи = Clinical anatomy :
head and neck : практикум для самостоятельной работы / С. Л. Кабак. – Минск : БГМУ,
2015. – 88 с.

ISBN 978-985-567-267-9.

Содержит контрольные вопросы к лабораторным и итоговым занятиям, перечень практических навы-
ков по оперативной хирургии, глоссарий, материалы для самостоятельной работы, а также тесты для са-
моконтроля по изучаемым разделам оперативной хирургии и топографической анатомии.

Предназначен для иностранных студентов 2-го курса стоматологического факультета, обучающихся
на английском языке.

УДК 611.91/.93:617.5(811.111)-054.6(076.5) (075.8)
ББК 28.70 (81.2 Англ-923)

ISBN 978-985-567-267-9

© Кабак С. Л., 2015
© УО «Белорусский государственный
медицинский университет», 2015

INTRODUCTION

The workbook contains methodic materials for laboratory practicals included in the standard programs on «Human Anatomy» and «Topographic Anatomy, Operative Surgery» for Dentistry specialization, code 1-79 01 07.

Each practicals contains test questions; the list of practical skills, which students shall gain; bibliography and glossary with concise description of key terms and notions. The workbook contains questions of two final classes and topics for students' research activities.

The students are proposed to perform on their own the following training tasks during the laboratory practicals:

– to name the structures or surgical instruments displayed on the pictures. The clue shall be a part of a structure name, which shows its belonging to a certain organ system (e. g. «artery», «vein», «nerve», «muscle», etc.). The captions also contain full names of separate anatomic structures which could not be recognized from the image;

– to describe topographical landmarks of areas or projection lines of the head and neck main vessels;

– to specify indications and contraindications for a certain type of surgery; to enumerate the main stages of its performance and to identify a place of a cerebral nerve damage according to clinical signs (appearance of the patient shown in the picture).

Unassisted performance of class assignments helps the students to better understand and remember spatial relationship of the main head and neck anatomical structures and also to get acquainted with a prime surgical service. Moreover, graphical assignments could serve as a mean for the current control of students' knowledge.

OPERATIVE SURGERY: GENERAL ISSUES

LAB N 1: THE SUBJECT AND TASKS OF OPERATIVE SURGERY AND TOPOGRAPHICAL ANATOMY. BASIC SURGICAL INSTRUMENTS: CLASSIFICATION AND RULES OF USE. DISCONNECTION AND APPROXIMATION OF TISSUES. TYPES OF ANESTHESIA

Theoretical objectives (to know):

1. Determination of the value of main surgical terms: surgical access, operative procedure, and a way out of the operation.
2. Types of surgical interventions based on the purpose and timing of a procedure.
3. Types of anesthesia: local anesthesia, regional (block) anesthesia, and general anesthesia.
4. Techniques of local infiltration.
5. Classification of surgical instruments and principles of their use.
6. General description of cutting and dissecting instruments.
7. General description of instruments used for hemostasis.
8. General description of grasping instruments.
9. General description of tissue unifying instruments and materials.
10. Main characteristics of suture materials (catgut, silk, absorbables and non-absorbables modern surgical suture).
11. Main principles of soft tissues dissection and approximation (primary and secondary sutures).
12. Three basic surgical knots: simple (granny) knot, surgeon's knot, and square knot.
13. Types of sutures: interrupted and running (continuous) stitch.
14. Simple interrupted stitch: technique of suturing.
15. Simple continuous suture and Multanovsky's blanket suture: techniques of suturing.
16. Use of horizontal and vertical mattress stitches for wound closure.
17. Technique of the subcuticular (intra-dermal) suture.

Practical objectives (to be able to):

1. Interpret the significance of main operative surgery terms.
2. Recognize surgical instruments by their names and know the principles of use.
3. Use scalpel, scissors, hemostatic clamps, forceps, needle holder.
4. Approximate skin margins with simple interrupted stitch.
5. Tie simple, surgeon's, and square knots.

Glossary

Operative surgery is a medical science about techniques, types and principles of surgical interventions, and use of surgical instruments.

Operation [surgical procedure] is a diagnostic or therapeutic intervention, in which the body integrity is disrupted or the continuity of the tissues is reconstructed. Two types of operations exist: bloodless operations (e. g. reducing a joint dislocation, or treating a closed fracture) and bloody operations (e. g. abdominal, or thoracic operations).

Surgical [operative] access is a layer-by-layer tissues incision to reach the pathological focus. The decision to select a specific incision would depend on the several aspects e. g. surgical site, related anatomical structures, simplicity of an access, possible complications, time of healing and scarring.

Surgical [operative] procedure is an action taken on the pathological focus. The name of a surgical operation consists of the pathologically changed organ and surgical procedure: *-ectomy* — complete removal of an organ (such as *pulmonectomy*); *-resection* — removal of a part of an organ

(such as resection of the liver); *-tomy* — incision of a wall (such as tracheotomy); *-stomy* — creation of an artificial connection between organs or an organ and environment (such as enterostomy); *-rrhaphy* — stitching of a wall or tissues (such as myorrhaphy); *-sectio* — cutting of a tissue (such as venesection); *-plasty* — formation or plastic repair of an organ or a tissue (such as pyloroplasty); *-pexy* — surgical fixation of an organ to another one (such as nephropexy); *-anastomy* — creation of an artificial connection between lumens of two organs (such as gastroenteroanastomy); *amputation* — cutting off a body part, usually a limb or digit.

Finalizing (a way out) of the operation is the reconstruction of the cut tissues in layers and wound drainage.

Anesthesia is a pharmacologically induced reversible state of *amnesia* (deficit in memory), *analgesia* (relief from pain), loss of responsiveness, and loss of skeletal muscle reflexes. Types of anesthesia include local anesthesia, regional anesthesia, and general anesthesia.

Local anesthesia inhibits sensory perception within a specific location on the body, such as a tooth or the urinary bladder.

Regional anesthesia provides loss of sensation to a larger area of the body by blocking transmission of nerve impulses between a part of the body and the spinal cord or brain. Two frequently used types of regional anesthesia are spinal anesthesia and epidural anesthesia.

General anesthesia (общее обезболивание) refers to inhibition of sensory, motor and sympathetic nerve transmission at the level of the brain, resulting in unconsciousness and lack of sensation.

Primary suture is used for non-contaminated tissue approximation without tension.

Secondary suture is used for contaminated wounds and can be placed at a different time after injury. If no signs of infection present within 4–6 days after the initial management of wound *primary delayed sutures* are placed. Before then it takes anesthesia and refreshment of the wound edges. *Secondary wound sutures* are placed 2 weeks after an injury. Granulation tissue and scarring fragments should be removed prior to the suture placement.

Basic surgical instruments are used for routine interventions. Those instruments can be categorized into one of these five categories: *cutting and dissecting instruments* (scalpels, scissors, saws), *instruments used for hemostasis* (Kocher's and Billroth's clamps, hemostatic «mosquito» forceps, atraumatic hemostatic forceps, Deschamp's needle, Höpfner's hemostatic forceps), *grasping instruments* (smooth [anatomical] and toothed [surgical] forceps, towel clamps, vascular clamps, and organ holders), *retracting instruments* (Farabef's C-shaped laminar hook, blunt-toothed hook, sharp-toothed hook, grooved probe, tamp forceps), *tissue unifying instruments and materials* (needle holders, surgical needles, staplers, clips, adhesive tapes).

Special instruments are designed for a specific procedure or surgery.

Suture needle is a small, slender instrument used for sewing or surgical suturing. It has an «eye» at one end through which a length of thread is passed and held. Based on the cross-section there are two types of needles: circular («taper-point circular needle») and cutting.

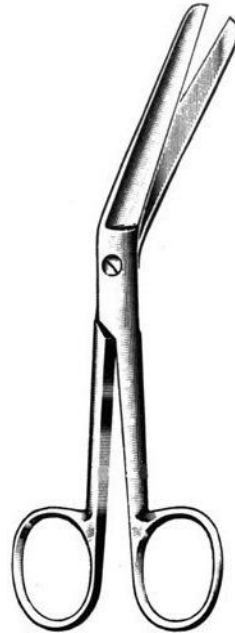
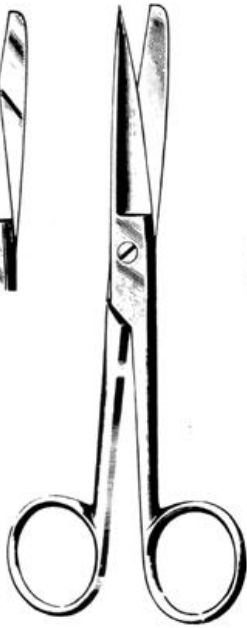Cutting needle has a very sharp tip and edges, which are needed to pass through the tissues. It is used primarily for suturing the skin.

Tapered («round-bodied») needle has a sharp tip with smooth edges and is less traumatic to the surrounding tissues. It is used primarily on the deeper, subcutaneous tissues, blood vessels, and intestinal anastomoses. A tapered needle is not convenient for simple skin suturing because it is difficult to the skin with the tapered needle.

Atraumatic needle is a round-bodied eyeless surgical needle with the suture permanently attached to the hollow end.

Self-instructional materials

Give the name of surgical instruments on pictures:

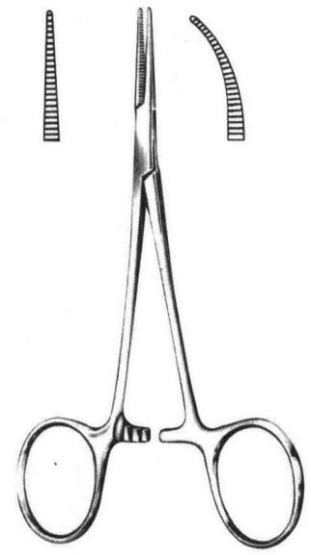
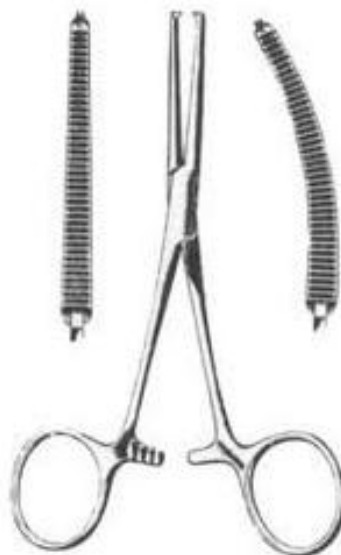
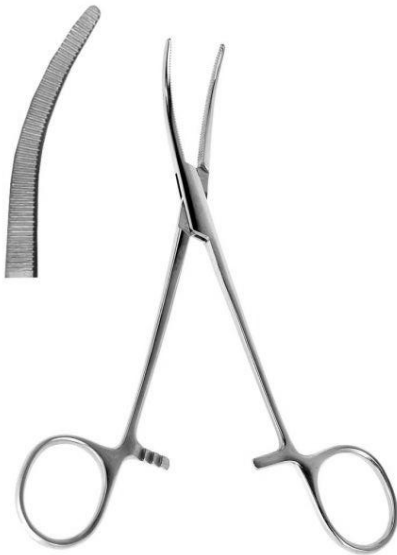
a

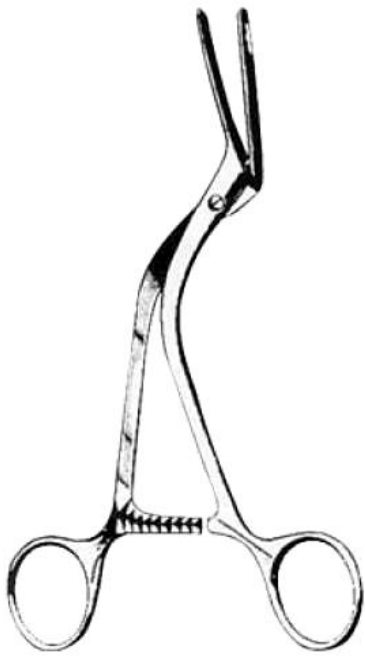b

c

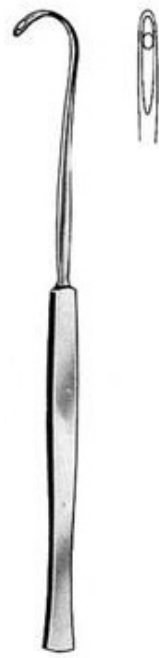a — _____; b — _____;
c — _____

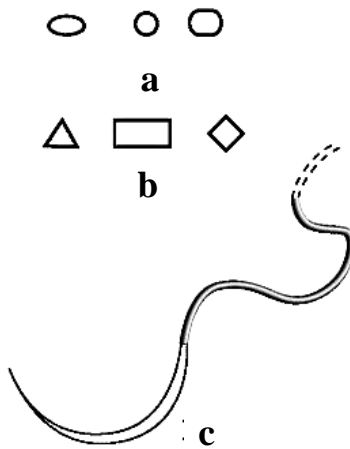



Entitle surgical instruments on pictures:







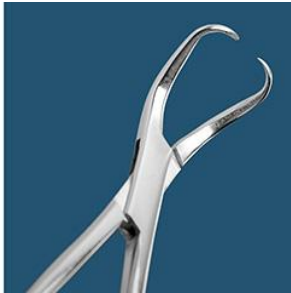
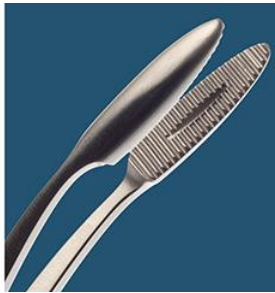

a — _____ ;
 b — _____ ;
 c — _____

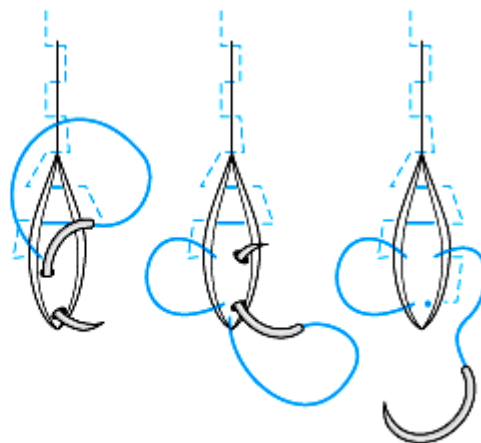
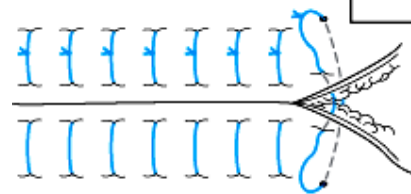
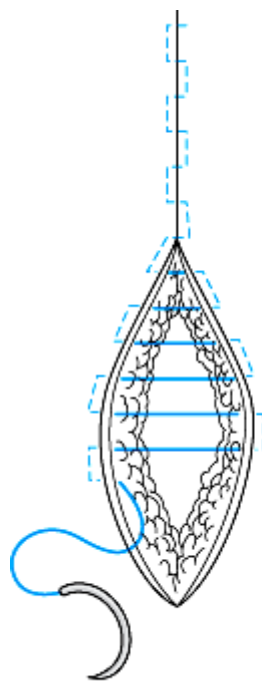
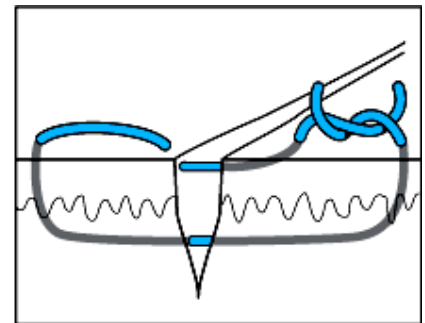
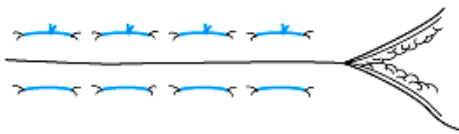
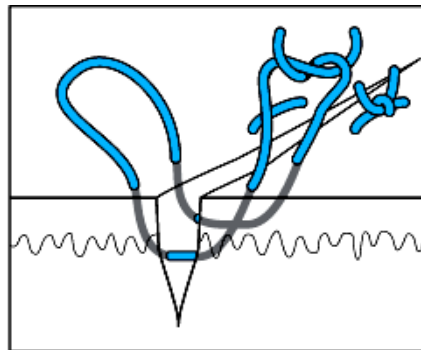
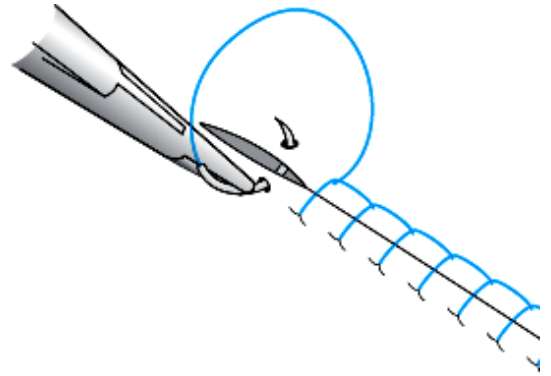
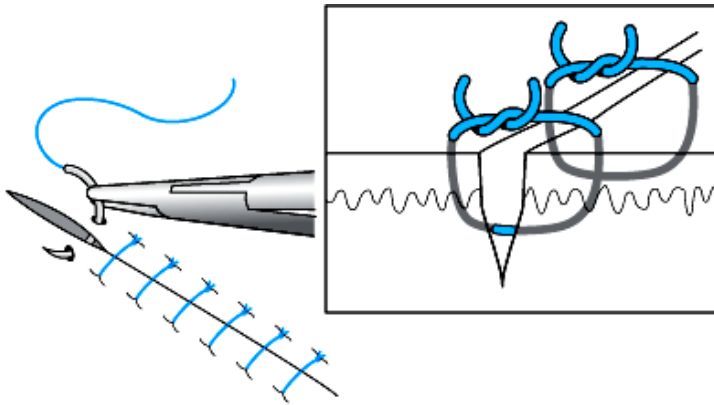




Entitle surgical instruments on pictures:



Entitle surgical sutures on pictures:



CLINICAL ANATOMY OF NECK REGIONS

LAB N 2: MUSCLES OF THE NECK: TOPOGRAPHY, BLOOD AND NERVE SUPPLY. ANATOMICAL REGIONS, TRIANGLES, FASCIAL LAYERS AND SPACES OF THE NECK

Theoretical objectives (to know):

1. Superior and inferior boundaries of the neck.
2. Surface projections of the following structures: common/internal/external carotid artery; subclavian artery; cutaneous branches of the cervical plexus; supraclavicular part of brachial plexus; phrenic nerve; submandibular gland; isthmus of the thyroid gland; external/internal/anterior jugular vein.
3. Boundaries of anatomical regions and triangles of the neck.
4. Superficial, medial (suprahyoid, infrahyoid), and deep muscles of the neck: topography, functions, blood and nerve supply.
5. Layers of the cervical fascia: interrelationships with muscles and organs of the neck.
6. Closed and open cervical fascial spaces.
7. Cervical plexus: location, and sources of the formation.
8. Topography of cutaneous branches of the cervical plexus.
9. Topographic relations of the phrenic nerve.
10. Ansa cervicalis: location, sources of the formation, and areas of distribution.

Practical objectives (to be able to):

1. Find sternocleidomastoid muscle, clavicle, acromion, jugular notch of the sternum, spinous process of vertebra VII, inferior margin of the mandible, external occipital protuberance, and thyroid cartilage in alive person by palpation.
2. Demonstrate muscles of the neck, cutaneous branches of cervical plexus, phrenic and hypoglossal nerves, ansa cervicalis and its roots in anatomical specimens and other visual sources.

Glossary

Neck (cervix) is a part of a body extending from the head down to the shoulders and thorax. Its superior boundary is demarcated by the inferior margin of the mandible; the imaginary line between external angle of the mandible and mastoid process; external occipital protuberance and superior nuchal line. The inferior boundary of the neck extends from the top of the sternum, along the clavicle, to the adjacent acromion. Posteriorly, the inferior limit can be approximated by the imaginary line between acromion and the spinous process of vertebra CVII. The side of the neck is subdivided into two large triangles by the sternocleidomastoid muscle. The triangular space in front of that muscle is called the *anterior triangle*; and the space behind it is called the *posterior triangle*.

Anterior triangle is an inverted triangle with the apex inferior to the base. The jugular notch in the manubrium of the sternum is the apex of the triangle; the midline of the neck from chin to the jugular notch is its anterior boundary; the anterior margin of the sternocleidomastoid muscle is its posterior boundary; the lower border of the body of the mandible and the line extending from the angle of the mandible to the mastoid process form its superior boundary (base). Two anterior triangles are the parts of the midline region of the neck. It is divided into the *suprahyoid* and *infrahyoid regions*. The suprahyoid region contains unpaired submental and bilateral submandibular triangles. The infrahyoid region contains bilateral carotid and muscular triangles.

Sternocleidomastoid region is the region of the neck overlying the sternocleidomastoid muscle. The two heads of the muscle are separated inferiorly by a space, visible superficially as a small triangular depression, the **lesser supraclavicular fossa**.

Posterior triangle as the following boundaries: the apex is the union of the sternocleidomastoid and the trapezius muscles at the superior nuchal line of the occipital bone; the anterior boundary is the posterior border of the sternocleidomastoid muscle; the posterior boundary is the anterior border of the trapezius muscle; the base is the middle one third of the clavicle. Approximately 2.5 cm above the clavicle the triangle is crossed by the inferior belly of the omohyoid muscle which divides the space into two compartments: the upper or omotrachezoid triangle and the lower or omoclavicular triangle (**greater supraclavicular fossa**).

Superficial cervical fascia is a thin layer of subcutaneous connective tissue that lies between the skin and the deep cervical fascia. It contains the platysma.

[Deep] cervical fascia is located deeper to the superficial fascia. It consists of several layers. The *investing layer* is the most superficial part. It wraps the trapezius and sternocleidomastoid muscles. The *pretracheal layer* of the fascia is situated anteriorly. It wraps trachea, oesophagus, thyroid gland and the infrahyoid muscles; than it flows from the hyoid bone down to the superior thorax, where it fuses with the pericardium. This layer can be functionally split into two parts: the *visceral part* which encloses the thyroid gland, trachea and oesophagus, and the *muscular part* which in turn encloses the infrahyoid muscles. The *prevertebral layer* of the deep cervical fascia surrounds the vertebral column and its associated muscles (scalene, pre-vertebral, and deep muscles of the back).

The carotid sheath is a paired structure, which encloses important cervical vessels and nerves. The fascial the sheath incorporates fragments of the pretracheal layer anteriorly, and the prevertebral layer of deep cervical fascia posteriorly.

Fascial spaces (also termed fascial tissue spaces), are potential gaps that exist between the fascia and underlying organs and other tissues. In health, these spaces do not exist, they are only created by pathology (e. g. the spread of pus or cellulitis in infection). Spaces of the neck can be divided into two types, which are the closed and open spaces. The *closed spaces* include: spatium suprasternale, spatium sternocleidomastoideus, and spatium submandibulare. The open spaces (distributed through the entire length of the neck) include: previsceral, retrovisceral, prevertebral, carotid, and posterior cervical spaces.

Suprasternal space is a slit-like gap between two sheets of the investing layer of cervical fascia, attached to the manubrium of sternum and to the interclavicular ligament. This space has two narrow lateral cul-de-sacs behind sternocleidomastoid muscles. Jugular venous arc, some areolar tissue and lymph nodes are located in this space.

Submandibular space is located below the mandible, inferiorly to the mylohyoid muscle. It is enclosed by the investing layer of the deep cervical fascia and contains the submandibular gland, submandibular lymph nodes; the facial artery and vein.

The pretracheal space is located between the visceral and muscular part of pretracheal layer of the deep cervical fascia. It extends from the hyoid bone and the attachments of the strap muscles and their fascia to the hyoid bone and thyroid cartilage to the superior mediastinum above the upper border of the aortic arch and great vessels. This space contains the trachea, thyroid gland, parathyroid glands, larynx, cervical part of esophagus, recurrent laryngeal nerves, and portions of the sympathetic trunk. The pretracheal space communicates freely with the retrovisceral space around the sides of the larynx, the lowermost pharynx, and the upper cervical esophagus between the levels of the thyroid cartilage and the inferior thyroid artery. Caudal to this level, the pretracheal space is separated from the retrovisceral space by dense connective tissue that extends from each lateral wall of the visceral compartment to the lateral margins of the esophagus.

Retrovisceral space is located between the visceral part of the pretracheal layer and the prevertebral layer of the deep cervical fascia behind the pharynx and upper esophagus. It extends from the skull base down to the mediastinum where its lowest part ends at about the level of the bifurca-

tion of the trachea (T1-T2). A part of this space located behind the pharynx is often referred to as the *retropharyngeal space*.

Prevertebral space is a potential space that is located between the prevertebral layer of the deep cervical fascia and the vertebrae, extending from the skull base to the coccyx. The prevertebral muscles are lying within this space. The vast majority of the pathology that affects this space arises from the adjacent vertebral bodies, discs, and neural elements.

The carotid space is outlined by the carotid sheath. It extends from the aortic arch to the skull base and contains the carotid artery, the internal jugular vein, CNs IX to XII in the suprahyoid region (with only CN X continuing in the infrahyoid neck), lymph nodes, and jugular trunk.

Posterior cervical space lies within the posterolateral neck between the investing and prevertebral layers of the deep cervical fascia just down and posteriorly to the sternocleidomastoid muscle. This space contains fat, CN XI, lymph nodes, brachial plexus, and the dorsal scapular nerve.

Self-evaluation questions:

1. What are the triangles of the anterior triangle of the neck? _____

2. Name borders of the anterior triangle. _____

3. What is the name of the 1st cervical fascia? _____

4. What muscles are enclosed by the investing layer of the deep cervical fascia? _____

5. The pretracheal layer of the deep cervical fascia is attached to _____

6. The pretracheal fascia splits to enclose: _____

7. What are the 2 parts of the pretracheal fascia? _____

8. From where to where the prevertebral fascia extends? _____

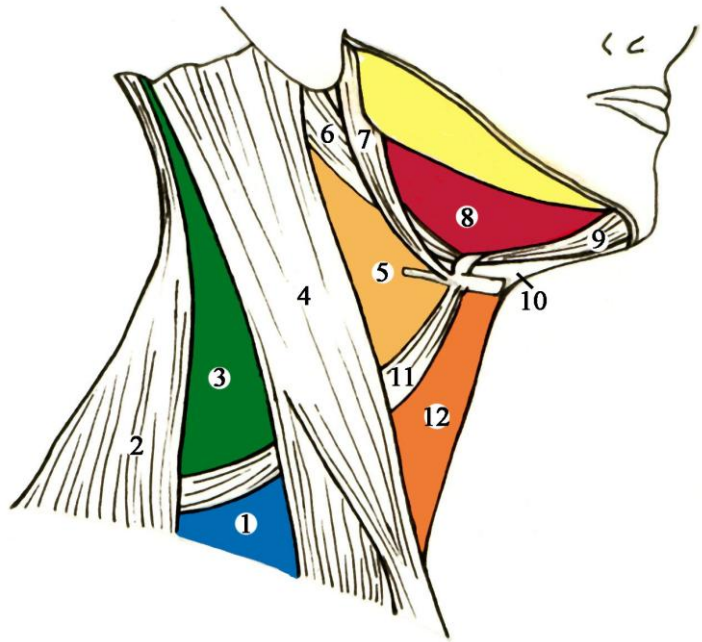
9. Deep to prevertebral fascia is. _____

10. What three fascia fuse behind sternocleidomastoid muscle? _____

Self-instructional materials

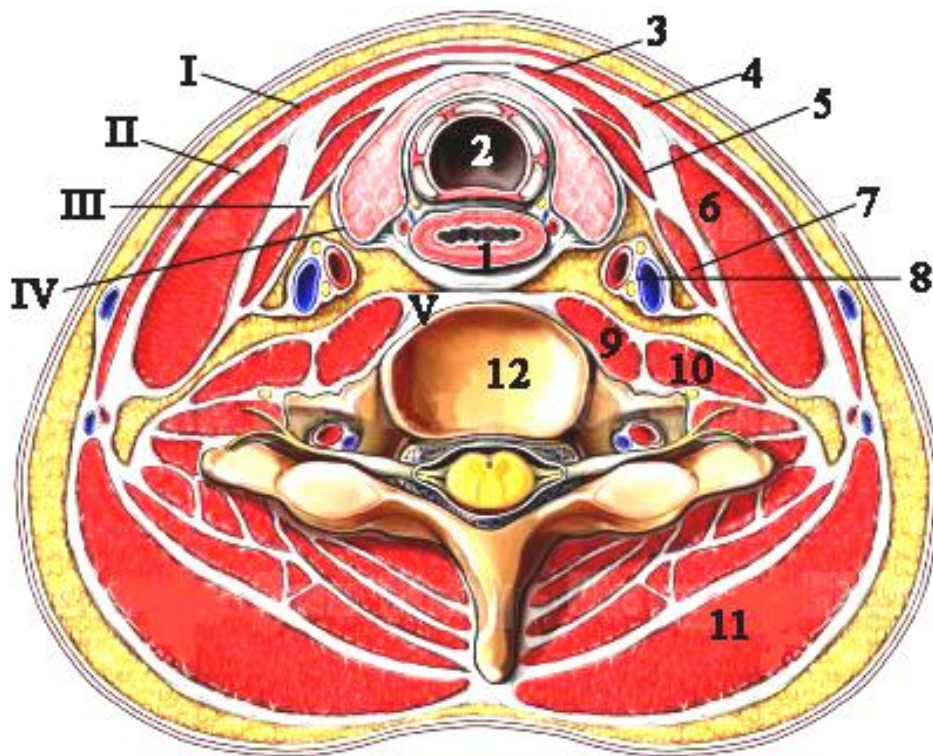
Triangles of the neck. Write the name of structures labeled on the diagram:

- 1 — _____ triangle
- 2 — _____ muscle
- 3 — _____ triangle
- 4 — _____ muscle
- 5 — _____ triangle
- 6 — _____ digastric
- 7 — _____ muscle
- 8 — _____ triangle
- 9 — _____
- 10 — _____ triangle
- 11 — _____
- 12 — _____ triangle



Characterize the outer surface landmarks of the neck structures listed below:

Carotid bifurcation	
Subclavian artery	
Cutaneous branches of the cervical plexus	
Phrenic nerve	
Submandibular gland	
Subclavicular part of the brachial plexus	



Fascia of the neck (on cross section). Write the name of structures labeled on the diagram:

1 — _____

2 — _____

3 — _____ muscle

4 — _____ muscle

5 — _____ muscle

6 — _____ muscle

7 — _____ muscle

8 — the main cervical neurovascular bundle with the carotid sheath

9 — _____ muscle

10 — _____ muscle

11 — _____ muscle

12 — _____

I — _____ fascia

II — _____ of the deep cervical fascia

III — _____ of the deep cervical fascia

IV — _____ of the deep cervical fascia

V — _____ of the deep cervical fascia

CLINICAL ANATOMY OF THE NECK

LAB N 3: SUPRAHYOID REGION OF THE NECK: BOUNDARIES, LAYERS AND CONTENTS OF THE SUBMANDIBULAR AND SUBMENTAL TRIANGLES

Theoretical objectives (to know):

1. Boundaries of the suprahyoid region of the neck.
2. Submandibular triangle: boundaries; layers; topography of the facial artery and vein, hypoglossal and lingual nerve.
3. Sublingual gland: two portions; submandibular (Warton's) duct topography; neural anatomy; arterial supply, venous and lymphatic drainage.
4. Pirogov's triangle: boundaries and contents.
5. Submental triangle: boundaries and layers.
6. Submental space: boundaries.
7. Sublingual space: boundaries, contents, and communication with submandibular space.
8. Sublingual gland: topography; neural anatomy; arterial supply, venous and lymphatic drainage.

Practical objectives (to be able to):

1. Show suprahyoid muscles; sublingual, submandibular glands, submandibular and major sublingual ducts; lingual and hypoglossal nerves; lingual artery and vein; sublingual caruncle and sublingual fold in anatomical specimens and other illustrative guides.
2. Apply the continuous and subcuticular (intra-dermal) sutures.

Glossary

Suprahyoid muscles are four muscles (digastric, stylohyoid, geniohyoid, and mylohyoid) running from the mandible and temporal bone to the hyoid bone. All suprahyoid muscles contribute to the floor of the mouth but the actual muscle plate which bridges between the two sides of the mandible is formed by the mylohyoid muscles (oral diaphragm). The floor of the mouth is reinforced by the geniohyoid muscles from above and by the anterior bellies of the digastric muscles from below. The oral diaphragm separates the sublingual and submandibular regions.

Submandibular (digastric) triangle is the region of the neck situated immediately beneath the mandible and has the following boundaries: the lower border of the body of the mandible, and a line drawn from its angle to the mastoid process on the top; the posterior belly of the digastric muscle at the bottom and the anterior belly of the digastric muscle as a front border. It is covered by the integument, superficial fascia, platysma, and deep cervical fascia. Its floor is formed by the mylohyoid and hyoglossus muscles. The Submandibular triangle is divided by the stylomandibular ligament into the anterior and posterior parts. The anterior part contains the submandibular gland, superficial to which the facial vein runs, while the facial artery is imbedded in the gland. The posterior part of this triangle contains the external carotid artery, ascending into the parotid gland following by the internal carotid artery, the internal jugular vein, and the vagus nerve in the deeper portion, separated from the external carotid by the styloglossus and stylopharyngeus muscles, and the glossopharyngeal nerve.

Submandibular space (see lab N 2).

Pirogov's (Pirogov–Belclard's) triangle is formed by the intermediate tendon of the digastric muscle, the posterior border of the mylohyoid muscle, and the hypoglossal nerve. The lingual artery lies in this triangle beneath the hyoglossus muscle and the muscle needs to be cut through in order to find it.

Submandibular gland is the second largest major salivary gland. It's located in the submandibular triangle. Wharton's duct, the main excretory duct of the gland, is approximately 4–5 cm long, running superiorly to the hypoglossal nerve and inferiorly to the lingual nerve. It opens laterally to the lingual frenulum through a papilla on the floor of the mouth behind the lower central incisor. The submandibular gland is supplied by the *submental* and *sublingual arteries*, branches of the lingual and facial arteries. The venous drainage parallels the corresponding arterial supply. The submandibular gland is innervated by the secretomotor fibers of the facial nerve (CN VII). Parasympathetic preganglionic fibers originating from the superior salivatory nucleus pass through the nervus intermedius, the lingual nerve (a branch of the mandibular division of the fifth cranial nerve) and terminate in the *submandibular ganglion*. The postganglionic fibers leave the ganglion to innervate the submandibular gland to secrete watery saliva. The sympathetic innervation from the superior cervical ganglion accompanies the lingual artery to the submandibular tissue and causes glandular production of mucous-rich saliva.

Submandibular nodes (cervical lymphatic nodes, level I) are three to six in number and located in the submandibular triangle. The afferents of the lymph nodes drain the cheek, the lateral side of the nose, the upper lip, the lateral part of the lower lip, the gums and teeth (except lower incisors), the anterior part of the margin of the tongue. Their efferent vessels pass to the superior deep cervical lymph nodes. Efferent vessels from the facial and submental nodes also enter the submandibular nodes.

Submental triangle is an unpaired division of the suprahyoid region of the neck. It is bounded laterally by anterior bellies of right and left digastric muscles and by the body of hyoid bone posteriorly. It contains submental lymph nodes and submental veins.

Submental space is a fascial space which coincides with the anatomic region called the submental triangle and located under the chin between the mylohyoid and platysma muscles. Its contents are submental lymph nodes, areolar connective tissue and the anterior jugular veins.

Submental nodes are located in the submental triangle. Those receive lymph from the following areas: the tip of the tongue; the floor of the mouth; mandibular incisor teeth and associated gingivae; the central part of the lower lip and skin of the chin. Lymph from the above mentioned structures drains into submandibular and deep cervical lymph nodes.

Sublingual space is located in the floor of the mouth and is outlined by the mandible anteriorly and laterally, the hyoid bone posteriorly, the oral mucosa superiorly, the mylohyoid muscle inferiorly. The sublingual space is divided at the midline by the geniohyoid and genioglossus muscles. Those muscles are demarcated in the middle by the low-density septum. Sublingual space contains: fat; the submandibular duct and the deep part of the submandibular gland; sublingual gland; the hyoglossus and styloglossus muscles; the lingual artery; the lingual, glossopharyngeal and hypoglossal nerves. The hyoglossus muscle is the surgical landmark separating superficially located submandibular duct and lingual vein from the lingual artery located deep to the muscle. Teeth apices anterior to the second molar lie superior to the mylohyoid line and thus involve the sublingual space. The sublingual space communicates posteriorly around the free border of the mylohyoid muscle with the submandibular space. Infections of the sublingual space may also penetrate through the mylohyoid muscle, or spread via the lymphatics to the submandibular and submental spaces.

Sublingual gland is the smallest of the major salivary glands. It lies as a flat structure in a submucosal plane within the anterior floor of the mouth, superior to the mylohyoid muscle and deeper to the sublingual folds opposite the lingual frenulum. Several minor sublingual ducts (*ducts of Rivinus*) from the superior portion of the gland either secrete saliva directly into the oral cavity, or collect it into the major sublingual duct (*duct of Bartholin*) which merges with the Wharton's duct. Blood is supplied to the sublingual gland by the *submental* and *sublingual arteries*, branches of the lingual and facial arteries, respectively. The venous drainage parallels the corresponding arterial supply. The lymph from the sublingual gland mainly drains into the submandibular lymph

nodes. The sublingual gland receives both sympathetic and parasympathetic innervation (see the nerve supply of the sublingual gland).

Self-evaluation questions:

1. Floor of the submandibular triangle is formed by _____
2. Roof of the submandibular triangle is formed by _____

3. Contents of the submandibular triangle are: _____ (1), _____ (2), _____ (3), and _____ (4)

4. What is the innervation of the submandibular gland? _____

5. Contents of the submental triangle are: _____ (1), _____ (2)

6. Boundaries of the submental triangle are: _____

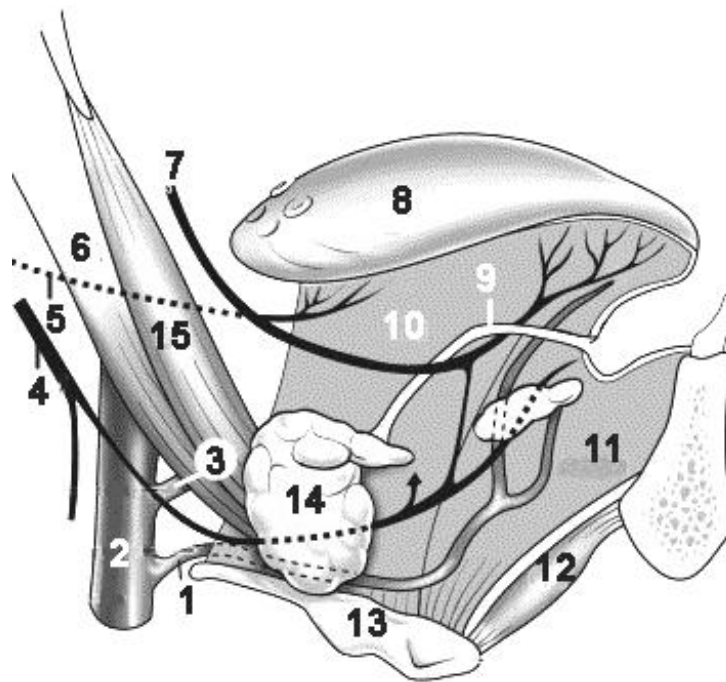
7. Floor of the submental triangle is formed by _____

8. With which space does the submandibular space communicate most directly? _____

9. What 3 things does the lingual artery supply? _____

10. What 5 structures are in the sublingual space? _____ (1) and _____ (2); _____ (3); _____ (4), and _____ (5)

Self-instructional materials

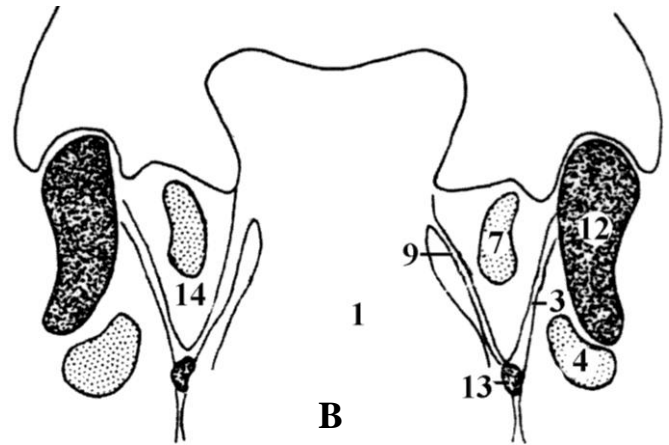
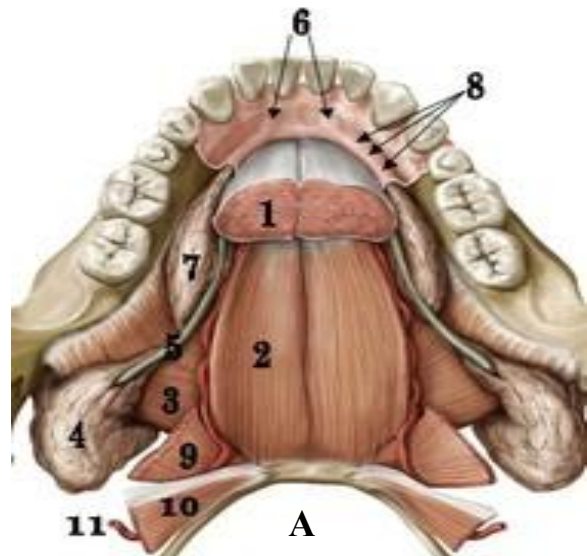


Submandibular trigon topography (lateral view; the part of the mandible in removed). Write the name of structures labeled on the diagram:

- 1 — _____ artery
- 2 — _____ artery
- 3 — _____ artery
- 4 — _____ nerve
- 5 — _____ nerve
- 6 — Posterior belly of the digastric muscle
- 7 — _____ nerve
- 8 — _____
- 9 — _____ duct
- 10 — Hyoglossus
- 11 — Mylohyoid
- 12 — Anterior belly of the digastric muscle
- 13 — Hyoid bone
- 14 — _____ gland
- 15 — _____ muscle

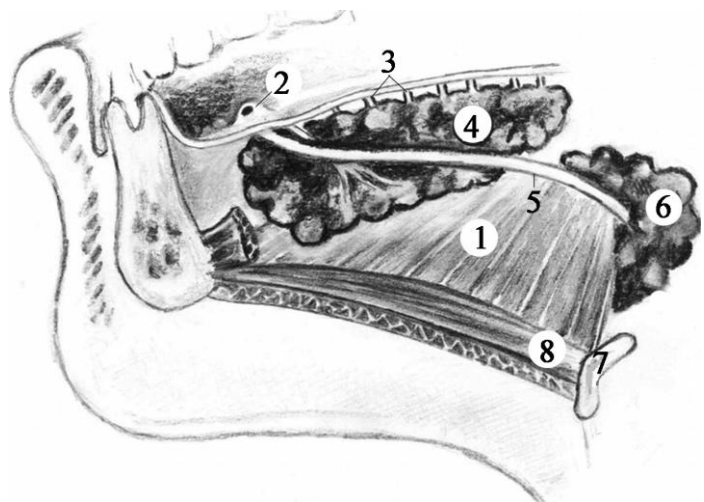
Sublingual space (A — cross-section, B — frontal section of the head). Write the name of structures labeled on the diagram:

- 1 — _____ muscle
- 2 — _____ muscle
- 3 — _____ muscle
- 4 — _____ gland
- 5 — _____ duct
- 6 — _____
- 7 — _____ gland
- 8 — _____
- 9 — _____ muscle
- 10 — _____ muscle
- 11 — _____ artery
(passing medial/deep to hyoglossus)
- 12 — Mandible
- 13 — Hyoid bone
- 14 — _____ space



Topography of the submandibular and sublingual gland (sagittal section). Write the name of structures labeled on the diagram:

- 1 — Mylohyoid muscle
- 2 — _____ caruncle
- 3 — _____ ducts
- 4 — _____ gland
- 5 — _____ duct
- 6 — _____ gland
- 7 — Hyoid bone
- 8 — _____ muscle



CLINICAL ANATOMY OF THE NECK

LAB N 4: STRUCTURAL AND FUNCTIONAL CHARACTERISTICS OF THE GLOSSOPHARYNGEAL (CN IX), VAGUS (CN X), ACCESSORIUS (CN XI), AND HYPOGLOSSAL (CN XII) NERVES

Theoretical objectives (to know):

1. Glossopharyngeal nerve: brainstem nuclei; topography; branches; regions of supply.
2. Overview of motor, sensory, and parasympathetic components of the glossopharyngeal nerve.
3. Brainstem nuclei of the vagus nerve.
4. Overview of motor, sensory, and parasympathetic components of the vagus nerve.
5. Cranial and cervical branches of the vagus nerve: topography; functional components; regions of supply.
6. Recurrent laryngeal nerve: topography; functional components; regions of supply.
7. Thoracic and abdominal branches of the vagus nerve. The influence of the parasympathetic fibers of the nerve on the function of internal organs.
8. Clinical findings related to the vagus nerve and its branches lesions.
9. Accessory nerve: brainstem nuclei; topography; regions of supply.
10. Hypoglossal nerve: the brainstem nucleus; topography; regions of supply.
11. Ansa cervicalis: superior and inferior roots; regions of supply.

Practical objectives (to be able to):

1. Demonstrate the glossopharyngeal (CN IX); vagus (CN X); accessory (CN XI); hypoglossal (CN XII) nerves; right and left recurrent laryngeal nerves and ansa cervicalis in anatomical specimens and other illustrative guides

Glossary

Glossopharyngeal nerve (CN IX) is a mixed nerve consisting of both sensory and motor fibers. It originates from the brainstem out from the sides of the medulla oblongata, just rostral to the vagus nerve and leaves the skull through the jugular foramen. Upon leaving the skull, it passes between the internal jugular vein and internal carotid artery. It descends in front of the latter vessel to the lower border of the stylopharyngeus muscle. It then curves forward, forming an arch on the side of the neck and lies superficially the stylopharyngeus and middle pharyngeal constrictor muscles. From there it passes under the cover of the hyoglossus muscle, and finally distributes to the palatine tonsil, mucous membrane of the fauces and base of the tongue, and the mucous glands of the mouth. The glossopharyngeal nerve receives general sensory fibers from the tonsils, pharynx, middle ear and posterior one third of the tongue; special sensory fibers (taste) from the posterior one-third of the tongue and visceral sensory fibers from the carotid bodies, carotid sinus. It supplies parasympathetic fibers to the parotid gland via the otic ganglion, and motor fibers to stylopharyngeus muscle.

Vagus nerve (CN X) is the longest and most complex of the cranial nerves. Upon leaving the medulla between the pyramid and the inferior cerebellar peduncle, it extends through the jugular foramen, then it passes into the carotid sheath between the internal carotid artery and the internal jugular vein down below the head, to the neck, chest and abdomen, where it contributes to the innervation of the viscera. The vagus nerve receives general sensory fibers from the dura mater of posterior cranial fossa, skin posterior to the ear, and external auditory canal, mucosa of the inferior pharynx at the esophageal junction, epiglottis, and ary-epiglottic folds, mucosa of larynx; special sensory fibers (taste) from the root of the tongue and the taste buds on the epiglottis. It supplies parasympathetic fibers to the thoracic and abdominal viscera; and motor fibers to pharyngeal muscles, muscles of the soft palate (except Tensor veli palatini), and all muscles of the larynx.

Recurrent laryngeal nerve is a thoracic branch of the vagus nerve. On the right side it arises in front of the subclavian artery; then winds backward around the vessel, and ascends to the side of the trachea behind the common carotid artery. On the left side, it travels inferior and then posterior to the aortic arch. The nerve on either side ascends into the groove between the trachea and esophagus, passes under the lower border of the inferior pharyngeal constrictor and enters the larynx behind the articulation of the inferior cornu of the thyroid cartilage with the cricoid. An injury to the recurrent laryngeal nerve tends to produce changes in the quality of the voice.

Accessory nerve is a motor nerve, which has an ambiguous nucleus (common with CN X) and nucleus of accessory nerve (lies in the upper five segments of the cervical spinal cord). Its trunk passes through the jugular foramen and divides into the internal and external branches. An internal branch joins vagus nerve, and an external branch reaches the sternocleidomastoid and trapezius muscles (innervating them).

Hypoglossal nerve is a motor nerve. Its fibers arise from the hypoglossal nucleus and emerges from the medulla oblongata in the sulcus separating the olive and pyramid. Upon emerging from the hypoglossal canal, the nerve spirals behind the vagus nerve and passes between the internal carotid artery and internal jugular vein lying on the carotid sheath. In the submandibular region it passes laterally to the hyoglossus, and inferiorly to the lingual nerve to reach and innervates muscles of the tongue.

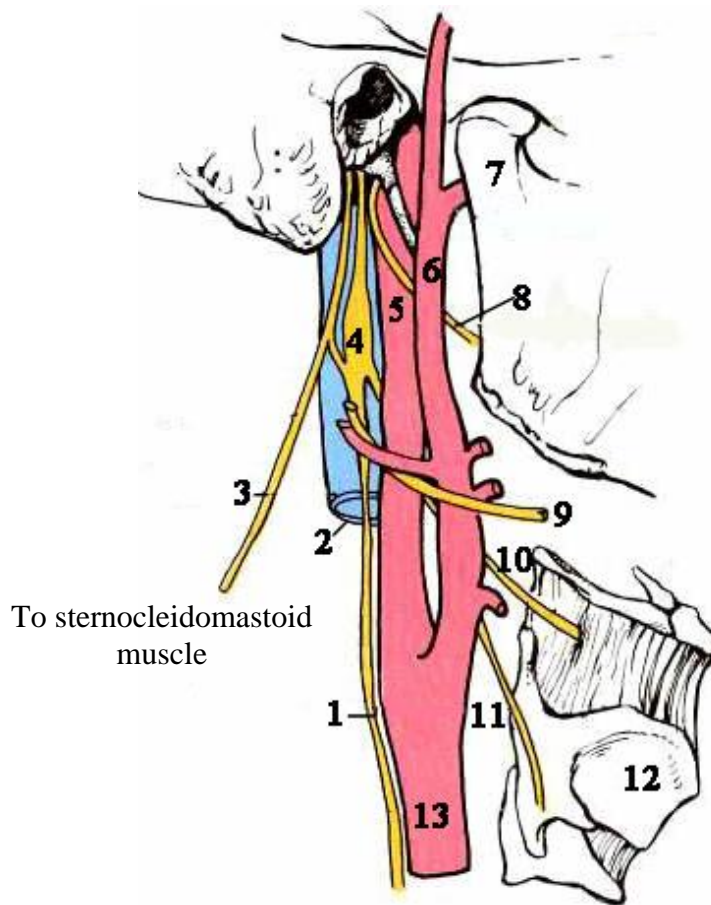
Ansa cervicalis is a loop of nerves that lies superficial to the internal jugular vein in the carotid triangle. It is formed by the union of two roots derived from the cervical plexus (the inferior root) and hypoglossal nerve (the superior root). Branches of ansa cervicalis innervate infrahyoid muscles, including the sternothyroid muscle, sternohyoid muscle, the omohyoid muscle, and the thyrohyoid muscle.

Self-evaluation questions:

1. CN 9 Glossopharyngeal: muscles innervated _____
2. Glossopharyngeal n. Innervation? _____
3. A cranial nerve with maximum branches in the body is _____
4. Vagus n. Function? (sensory, motor, both) _____
5. The recurrent laryngeal nerves are medial to the carotid sheath, in a groove between the trachea and the _____
6. Damage to CN XII causes _____
7. CN XII supplies _____

8. Damage to _____ cranial nerve results in inability to shrug and weak head movement.
9. Which CN (9–12) have parasympathetic innervation? _____

Self-instructional materials



The topography of the IX, X, XI, and XII cranial nerve. Write the name of structures labeled on the diagram:

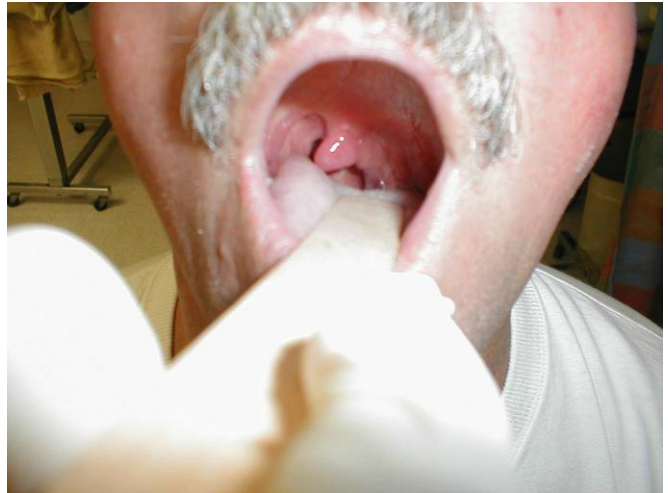- 1 — _____ nerve
- 2 — _____ vein
- 3 — _____ nerve
- 4 — Superior ganglion of vagus nerve
- 5 — _____ artery
- 6 — _____ artery
- 7 — Condylar process of mandible
- 8 — _____ nerve
- 9 — _____ nerve
- 10 — Internal branch _____ nerve
- 11 — External branch _____ nerve
- 12 — Cricoid cartilage
- 13 — _____ artery

Answer following questions:

1. What nerve lesion may cause deviation of the uvula away from the midline and failure of palate elevation?

2. On which side is the nerve damaged?

3. What muscle is denervated?

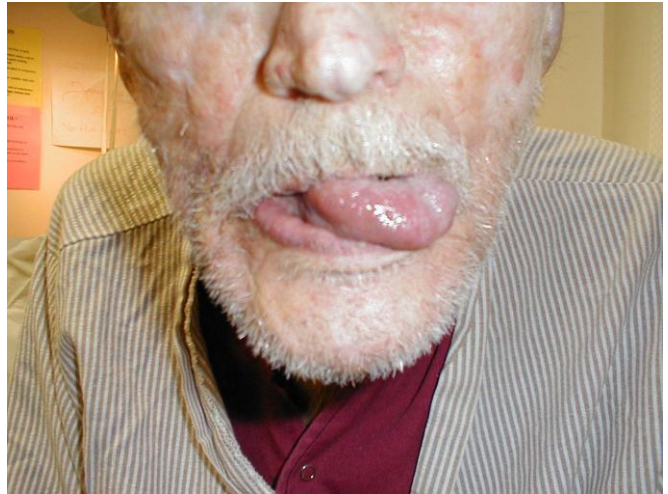


Answer following questions:

1. What nerve lesion may cause tongue deviation (a tendency of the tongue to turn away from the midline when extended or protruded)? _____

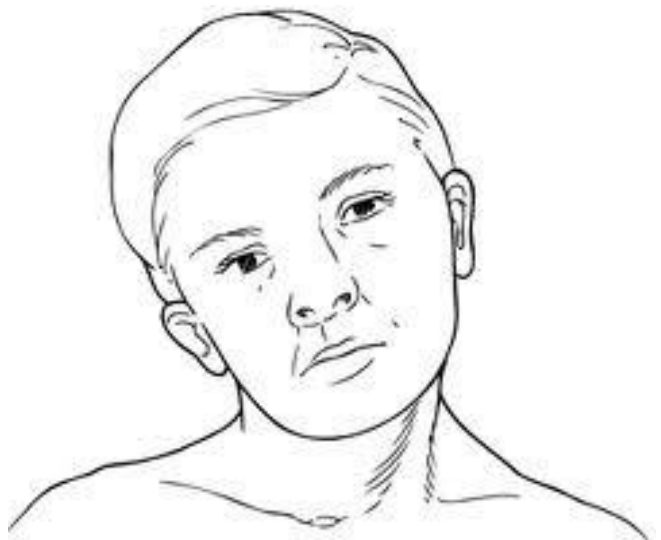
2. On which side is the nerve damaged?

3. What muscle is denervated?



What nerve excitation may cause spastic torticollis? _____

On which side is the nerve damaged?



CLINICAL ANATOMY OF THE NECK

LAB N 5: SUPRAHYOID REGION OF THE NECK: BOUNDARIES, LAYERS AND CONTENTS OF THE CAROTID TRIANGLE. THE MAIN NEUROVASCULAR BUNDLE AND REGIONAL LYMPHATIC NODES OF THE NECK

Theoretical objectives (to know):

1. Boundaries of the infrahyoid region of the neck.
2. Boundaries and layers of the carotid triangle.
3. Structural components of the neurovascular bundle located in the carotid triangle.
4. The level of the common carotid artery bifurcation. Distinctions between the internal and external carotid arteries.
5. Branches of the external carotid artery: classification.
6. Branches of the external carotid artery belonging to anterior group: regions of blood supply. The region (spot) of pulse evaluation on the facial artery.
7. Branches of the external carotid artery belonging to posterior group: regions of blood supply. The region (spot) of pulse evaluation on the occipital artery.
8. Branches of the external carotid artery belonging to medial group: regions of blood supply. The region (spot) of pulse evaluation on the superficial temporal artery.
9. Internal carotid artery: topography, branches. Arteries that supply the blood to the brain (cerebral arterial circle).
10. Arterial anastomoses between the external and internal carotid arteries.
11. Internal jugular vein: topography and tributaries (the facial, retromandibular, lingual, thyroïd, and pharyngeal veins).
12. External jugular veins: topography and tributaries.
13. Regional lymphatic nodes of the neck: classification, anatomical landmarks for identification.

Practical objectives (to be able to):

1. Demonstrate the external carotid artery and its branches; internal carotid artery, arteries of the cerebral arterial circle; internal, external and anterior jugular veins and their tributaries in anatomical specimens and other illustrative guides.
2. Palpate a pulse on the common carotid, superficial temporal, and facial arteries on a living person.

Glossary

Carotid triangle is a portion of the anterior triangle of the neck. It is bounded: posteriorly by the sternocleidomastoid muscle; inferiorly by the superior belly of the omohyoid muscle; superiorly by stylohyoid and the posterior belly of the digastric muscle. The triangle is covered by the integument, superficial fascia, platysma and deep cervical fascia (investing layer) which contains ramifications of the facial and cutaneous cervical nerves. Its floor is formed by parts of the thyrohyoid and hyoglossus muscles and inferior and middle pharyngeal constrictor muscles.

Main neurovascular bundle of the neck is situated in the boundaries of the carotid triangle. It contains: the common carotid artery, internal jugular vein, vagus nerve, jugular trunk, and lateral deep cervical lymphatic nodes surrounded by the carotid sheath.

Carotid bifurcation is the site of division of common carotid artery into the external and internal carotid arteries. This point is located approximately at the level of the fourth cervical vertebra (superior border of thyroid cartilage). While both branches travel upward, the internal carotid artery takes a deeper (more internal) path, eventually travelling up into the skull to supply the brain via

the carotid canal. The external carotid artery travels more closely to the surface, and sends off numerous branches that supply the neck and face.

Branches of the external carotid artery are:

- **anterior group:** superior thyroid, lingual and facial arteries;
- **medial group:** superficial temporal, maxillary, and ascending pharyngeal arteries;
- **posterior group:** sternocleidomastoid, occipital, and posterior auricular arteries.

The *superior thyroid artery* runs anteroinferiorly, the *lingual artery* — anteriorly with a characteristic upward loop, the facial artery — anterosuperiorly, the *occipital artery* runs posterosuperiorly and the ascending pharyngeal artery medial to the internal carotid artery. The *superficial temporal artery*, which is a continuation of external carotid artery, passes in front of the auricle. The *maxillary artery* is the largest branch of external carotid artery which supplies deep structures of the face.

Cerebral arterial circle (circle of Willis) is an anastomotic system of arteries that sits on the base of the brain. The circle is formed when the **internal carotid arteries** enter the cranial cavity bilaterally and divide into the *anterior cerebral arteries*. The anterior cerebral arteries are then united by the *anterior communicating artery*. These connections form the anterior half (anterior circulation) of the circle of Willis. Posteriorly, the **basilar artery**, derived from the left and right vertebral arteries, branches into the left and right *posterior cerebral arteries*, forming the posterior circulation. The posterior cerebral arteries complete the circle of Willis by joining the internal carotid system anteriorly via the *posterior communicating arteries*.

Internal jugular vein is a paired vein collecting the blood from the brain, superficial parts of the face, and neck. The vein originates from the *sigmoid sinus* at the level of the jugular foramen and runs down behind the internal carotid artery and vagus nerve. At the root of the neck, it unites with the *subclavian vein* to form the *brachiocephalic vein*. Internal jugular vein has the following extracranial tributaries: the *pharyngeal veins*; *lingual vein*; *superior thyroid vein*; *facial vein*, which receives the *retromandibular vein*.

External jugular vein receives the greater part of the blood from the exterior of the cranium and the deep parts of the face being formed by the junction of the posterior division of the retromandibular vein with the posterior auricular veins. The external jugular vein drains into the subclavian vein lateral to the junction of the subclavian and internal jugular veins.

Cervical lymphatic nodes (level II) include upper jugular nodes. They are located along the upper third of the jugular vein (between the skull base above, and level of hyoid bone or carotid bifurcation below). The upper group drains the oral cavity, pharynx, larynx, and parotid

Cervical lymphatic nodes (level III) include the middle jugular nodes. They are located along the middle third of jugular vein from the level of hyoid bone above to the upper border of the cricoid cartilage. The middle group drains the hypopharynx, larynx, oral cavity, oropharynx and thyroid.

Cervical lymphatic nodes (level IV) include lower jugular nodes. They are located along the lower third of the jugular vein from the upper border of the cricoid cartilage to the clavicle. The middle group drains the larynx, thyroid, and cervical oesophagus.

Self-evaluation questions:

1. The carotid triangle is formed by the posterior belly of the digastric, the sternocleidomastoid and the _____ of the omohyoid muscles.

2. What is situated within the carotid sheath and how is it oriented? _____

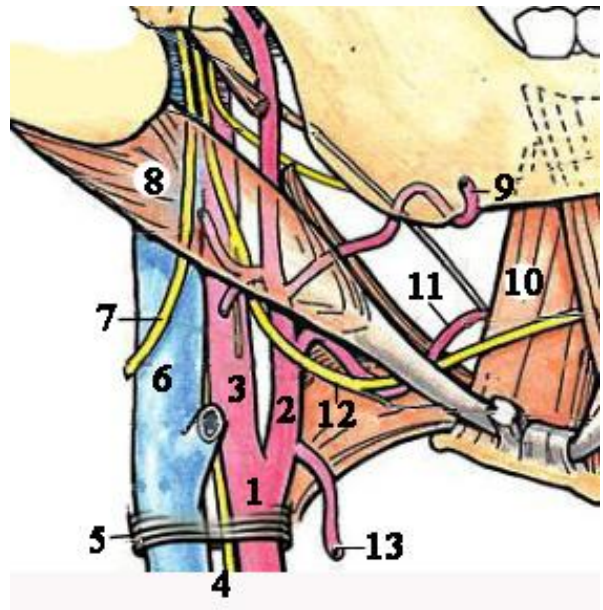
3. What spinal level does the carotid artery bifurcate at? _____
4. Which carotid artery is more anterior (internal or external)? _____
5. Name the branches of the external carotid artery in the neck. _____
6. This vessel gives the most important blood supply to superficial face. It starts deep to the mandible then runs inferiorly in front of the masseter muscle behind the corner of the mouth. It terminates at the medial corner of the eye. _____
7. What are the terminal branches of the external carotid artery? (Where does the external carotid end?). _____
8. Name the branches of the internal carotid artery in the neck? _____
9. What vessel is going through the cavernous sinus and surrounded by venous blood?

10. Which arteries form the cerebral circle? _____
11. Which arteries are formed from the bifurcation of the basilar artery to supply the occipital lobes? _____
12. What forms the ansa cervicalis? _____
13. Which muscles of the infrahyoid region would be affected by a damage to the ansa cervicalis? What movement of the hyoid bone would be primarily affected? _____
14. What are the motor and sensory nerves which originate from the vagus nerve in the carotid triangle? _____
15. What is the main route of blood drainage from the brain that leaves the sigmoid sinus through the jugular foramen. _____
16. What vein does the internal jugular drain to? _____
17. Posterior auricular and retromandibular veins drain to this vein that runs over the sternocleidomastoid. _____
18. What nerve runs along side the external jugular vein? _____
19. Name the node of deep cervical node group located near the junction of IJV with superior belly of omohyoid. _____
20. What is the largest lymphatic duct of the neck? _____

Self-instructional materials

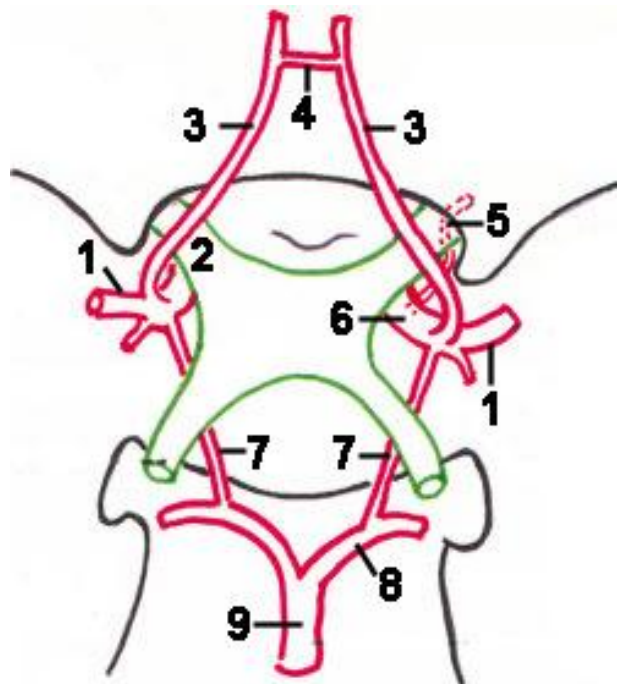
Right main neurovascular bundle of the neck. Write the name of structures labeled on the diagram:

- 1 — _____ artery
- 2 — _____ artery
- 3 — _____ artery
- 4 — _____ nerve
- 5 — _____
- 6 — _____ vein
- 7 — _____ nerve
- 8 — Posterior belly of digastric muscle
- 9 — _____ artery
- 10 — Mylohyoid muscle
- 11 — _____ artery
- 12 — _____ nerve
- 13 — _____ artery

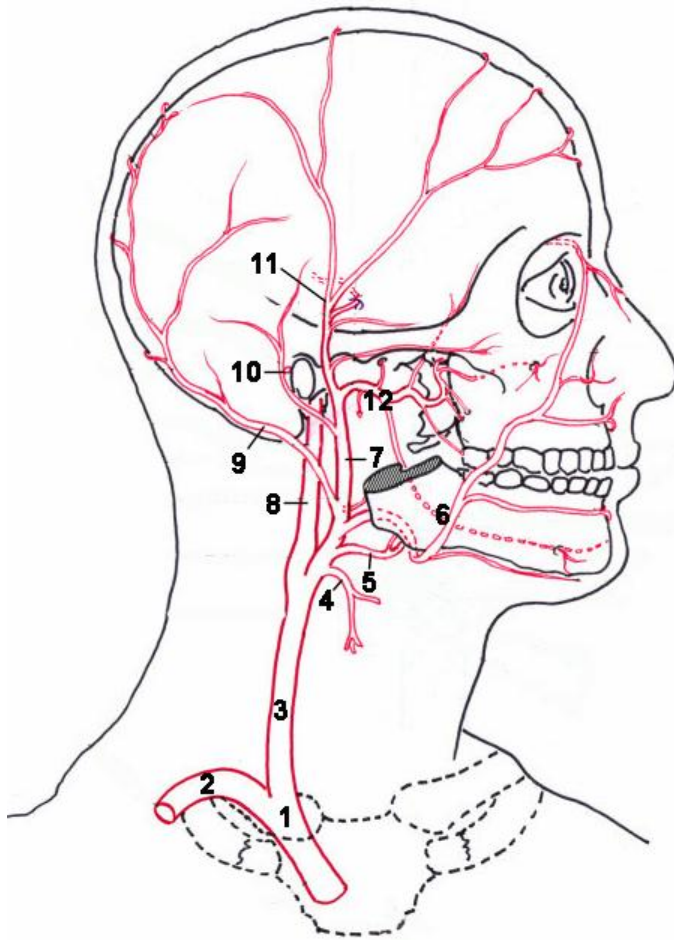


Branches of the internal carotid artery (circle of Willis). Write the name of structures labeled on the diagram:

- 1 — _____ artery
- 2 — _____ nerve
- 3 — _____ artery
- 4 — _____ artery
- 5 — _____ artery
- 6 — _____ artery
- 7 — _____ artery
- 8 — _____ artery
- 9 — _____ artery



Branches of the right external carotid artery. Write the name of structures labeled on the diagram:



- 1 — _____ trunk
- 2 — _____ artery
- 3 — _____ artery
- 4 — _____ artery
- 5 — _____ artery
- 6 — _____ artery
- 7 — _____ artery
- 8 — _____ artery
- 9 — _____ artery
- 10 — _____ artery
- 11 — _____ artery
- 12 — _____ artery

Name arteries forming circulatory anastomoses in the head:

Medial canthus — _____ artery (from a. facialis) and _____ artery (from a. ophthalmica).

Cranial dura mater — _____ branch (anterior ethmoidal artery from a. ophthalmica), _____ (from a. maxillaris) and _____ artery (branch of a. pharyngea ascendens).

Frontal region — _____ artery (from a. ophthalmica) and _____ artery (from a. carotis externa).

Basal brain surface — _____ artery (from a. basilaris) and _____ (from a. carotis interna).

CLINICAL ANATOMY OF THE NECK

LAB N 6: INFRAHYOID REGION OF THE NECK: BOUNDARIES, OMOTRACHEAL TRIANGLE. TOPOGRAPHICAL ANATOMY OF THE NECK ORGANS

Theoretical objectives (to know):

1. Omotracheal (muscular) triangle: boundaries and layers.
2. Anterior jugular veins: topography and influxes; jugular venous arc.
3. Larynx: topographical anatomy (surface landmarks, skeletotopic projection, relationship to another structures of the neck); cartilages, ligaments, joints, and muscles of the larynx; laryngeal cavity.
4. Nerves and vessels of the larynx.
5. Trachea: skeletopy, syntopy, innervation, blood supply, venous, and lymphatic drainage.
6. Thyroid and parathyroid glands: localization; innervation, blood supply, venous, and lymphatic drainage.
7. Pharynx: skeletopy, relationship to another structures of the neck, retropharyngeal and lateropharyngeal spaces; parts, communications, three layers of the pharyngeal wall; innervation, blood supply, venous, and lymphatic drainage.
8. Cervical part of the esophagus: skeletopy, syntopy, innervation, blood supply, venous, and lymphatic drainage.

Practical objectives (to be able to):

3. Sow the neck organs and their nerves and vessels in anatomical specimens and other illustrative guides.
4. Palpate the thyroid cartilage on a living person.
5. Apply the subcuticular (intra-dermal) cosmetic suture.

Glossary

Omotracheal (muscular) triangle is a portion of the infrahyoid region of the neck. It is bounded by the superior belly of omohyoid, anterior margin of the sternocleidomastoid and linea alba of the neck. The main content is the sternothyroid and sternohyoid muscles, thyroid & parathyroid glands.

Linea alba of the neck is the blending area of the fascial sheaths of the sternothyroid and sternohyoid muscles in the median plane of the neck.

Suprasternal space is the space in the inferior part of omoclavicular triangles (for details see lab N 2).

Anterior jugular vein begins near the hyoid bone by the confluence of several superficial veins from the submental region. The anterior jugular vein drains into the external jugular vein.

Jugular venous arch is the communication between the two anterior jugular veins just above the sternum. It lies in the suprasternal space.

Previsceral (pretracheal) space surrounds the trachea and lies against the anterior wall of the esophagus (for details see lab N 2). It can be infected directly by anterior perforations and rupture of the esophagus or indirectly by an infectious spread from the retrovisceral portion.

Retrovisceral (retroesophageal space) lies behind the esophagus and lower part of the pharynx (details see lab N 2). It is the important pathway by which infections originating from various locations in the head and the upper portion of the neck reach the mediastinum. The retrovisceral space may also be infected directly from posterior perforations of the esophagus or by infections of the deep cervical nodes lying adjacent to it.

Syntopy is the anatomical relationships of the organ (anatomical structure) to one another.

Holotopy is the projection of the organ on the surface of the body and corresponding region.

Skeletopy is the projection of the organ onto the skeleton.

Self-evaluation questions:

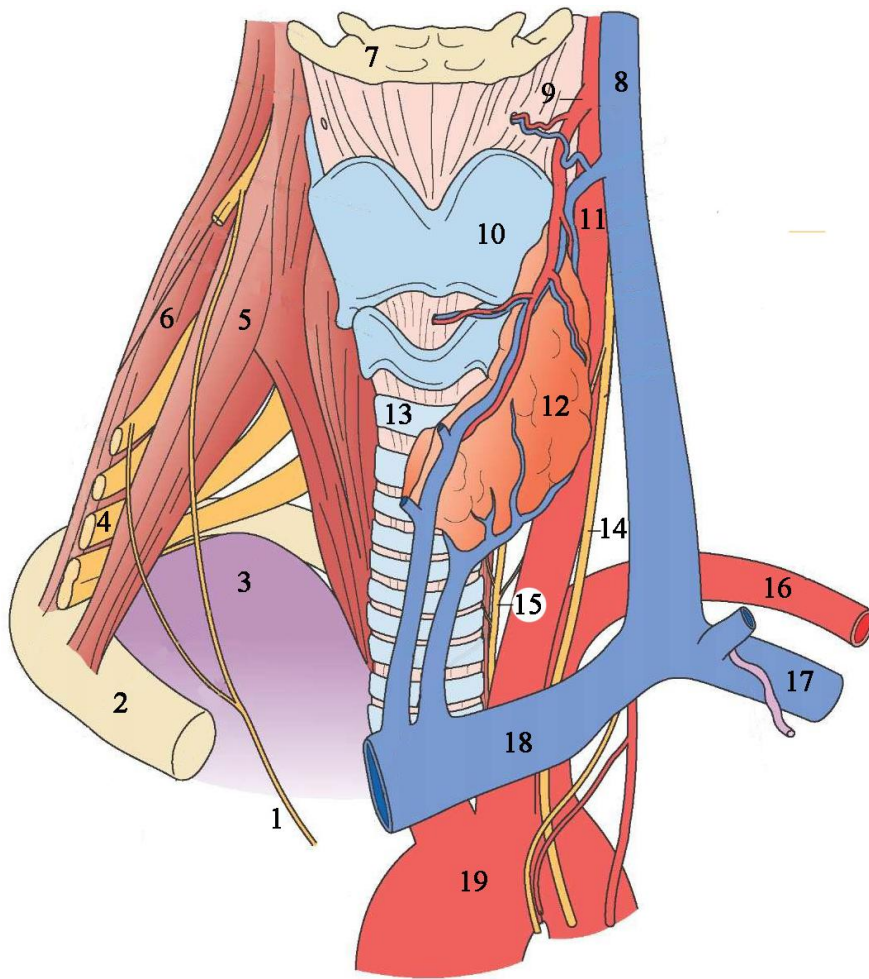
1. The _____ muscle covers the lateral lobe of the thyroid gland.
2. The thyroid gland extends from vertebral levels [1] to [2].
3. The portion of the thyroid gland linking the (two) lobes is called the _____
4. Approximately 50% of thyroid glands have a _____ lobe that extends superiorly from the isthmus.
5. The _____ potential space is located between the prevertebral and buccopharyngeal fasciae.
6. The _____ layer of the deep fascia surrounds (the) cervical viscera such as the trachea, esophagus and thyroid gland.
7. The _____ triangle is formed by the superior belly of the omohyoid, the sternocleidomastoid and the midline.
8. The parathyroid glands lie on the _____ surface of the thyroid gland.
9. Which arteries supply the parathyroid glands? _____
10. Would damage to the recurrent laryngeal nerve have a greater effect on phonation than damage to the external laryngeal nerve? _____

11. Which intrinsic muscle of the larynx would be affected by the damage to the superior laryngeal nerve? _____
12. What fibers is the pharyngeal plexus made of? What are their functions? _____

13. What are the five layers of the pharynx? _____

14. What is the name of the fascia on the posterior surface of the pharynx? Which space is directly posterior to this fascia? _____
15. What type of muscles does the lower 1/3 of the esophagus contain? _____

Self-instructional materials



Topographical anatomy of the neck organs. Write the name of structures labeled on the diagram.

- | | |
|----------------------|-------------------|
| 1 — _____ nerve | 11 — _____ artery |
| 2 — First rib | 12 — _____ gland |
| 3 — Dome of pleura | 13 — _____ |
| 4 — _____ | 14 — _____ nerve |
| 5 — Anterior scalene | 15 — _____ nerve |
| 6 — Middle scalene | 16 — _____ artery |
| 7 — Hyoid bone | 17 — _____ vein |
| 8 — _____ vein | 18 — _____ vein |
| 9 — _____ artery | 19 — _____ |
| 10 — _____ | |

TOPOGRAPHICAL ANATOMY OF THE NECK ORGANS

Complete the table.

Organ	Position	Syntopy	Blood supply	Innervation
Larynx	C__ - C__	<ul style="list-style-type: none"> • superior — _____ bone • anterior — _____ (1), _____ (2) and _____ (3) muscles • posterior — _____ • bilateral — _____ (1), _____ (2) 	_____ (1) and _____ (2) arteries	_____ (1) and _____ (2) nerves
Laryngeal part of the pharynx	_____ - C_	<ul style="list-style-type: none"> • anterior — _____ • posterior — _____ • bilateral — _____ 	_____ artery	_____ plexus
Trachea (cervical part)	C__ - _____	<ul style="list-style-type: none"> • anterior — _____ • posterior — _____ • bilateral — _____ (1), _____ (2), _____ (3) 	_____ artery	_____ nerves
Esophagus (cervical part)	C__ - _____	<ul style="list-style-type: none"> • anterior — _____ • posterior — _____ (1), _____ (2) • bilateral — _____ (1), _____ (2), _____ (3) 	_____ artery	_____ nerve; _____ branches
Thyroid gland	isthmus — _____ rings of the trachea; lobe: <i>superior</i> — _____; <i>inferior</i> — _____ rings of the trachea	<ul style="list-style-type: none"> • in front of the <i>lobe</i> — _____ and _____ muscles; of <i>isthmus</i> — _____ • posterior — _____ (1), _____ (2), _____ (3) • lateral — _____ • medial — _____ (1); _____ (2) 	_____ arteries	_____ nerves; _____ branches

CLINICAL ANATOMY OF THE NECK

LAB N 7: STERNOCLEIDOMASTOID REGION: BOUNDARIES, LAYERS AND CONTENTS OF THE SCALENOVERTEBRAL AND POSTERIOR TRIANGLES

Theoretical objectives (to know):

1. Boundaries and layers of the sternocleidomastoid region of the neck.
2. Boundaries and contents (artery, thoracic duct, phrenic nerve, cervicothoracic ganglion) of the scalenovertebral triangle.
3. Subclavian artery: divisions and branches.
4. Vertebral artery: pathway (vertebral canal), divisions and branches.
5. Internal thoracic artery: pathway and branches.
6. Thyrocervical trunk: pathway and branches.
7. Boundaries, floor, layers, and contents (vessels, nerve and lymphatic nodes) of the posterior (lateral) triangle of the neck.
8. Interscalenic space: boundaries and contents (second part of the subclavian and brachial plexus).
9. Topographical anatomy of the subclavian vein and jugular venous angle. Technique of central venous catheter placement via the subclavian vein.
10. Ganglions of the cervical part of the sympathetic trunk: localization and their branches.

Practical objectives (to be able to):

6. Demonstrate the subclavian and vertebral arteries, thyrocervical trunk, brachiocephalic and subclavian veins, the cervical part of the sympathetic trunk in anatomical specimens and other illustrative guides.
7. Palpate a pulse over the subclavian artery on a living person.

Glossary

Scalenovertebral triangle (triangle of vertebral artery) is bounded: medially by the longus colli muscle; laterally by the anterior scalene muscle; inferiorly by the dome of pleura. It contains the first part of the subclavian artery and its branches (including vertebral artery); inferior cervical ganglion of the sympathetic trunk; and the thoracic duct (on the left side). The prevertebral layer of the cervical fascia covers the triangle and its contents

Branches of the first part of the subclavian artery are:

- **Vertebral artery**, the largest branch of the subclavian artery, passes through foramina of transversal processes of cervical vertebrae, and gets into the skull cavity through occipital foramen magnum;
- **Internal thoracic artery** runs inferiorly along I–VII cartilages of ribs near sternum. Its two terminal branches are *musculophrenic artery* and *superior epigastric artery*. The artery gives off the anterior intercostal branches, which supply intercostal muscles;
- **Thyrocervical trunk** lies on the anterior scalene muscle and gives off the inferior thyroid, suprascapular and ascending cervical arteries.

Branches of the second part of the subclavian artery are the costocervical trunk, which ramifies into the *deep cervical artery*, and *supreme intercostal artery*.

The branch of the third part of the subclavian artery is the dorsal scapular artery.

Arch of the thoracic duct is its terminal portion that turns abruptly to the left, usually at the C7 vertebral level, to enter the superolateral aspect of the junction of the left subclavian and internal jugular veins.

Cervical portion of the sympathetic trunk consists of three ganglia, distinguished, according to their positions, as the *superior*, *middle*, and *inferior ganglia*, connected by intervening cords. Nerves emerging from cervical sympathetic ganglia contain postganglionic axons and contribute to the cardiac, common carotid (external/internal carotid), vertebral, and subclavian plexus, providing the innervation of all vessels and glands of the head, neck, upper limb and heart

Interscalenic space (interval) is a space between the anterior and middle scalene muscles, and the first rib. Here, pass superior, middle and inferior trunks of the brachial plexus and subclavian artery.

Anterscalenic space is located in front of the anterior scalene muscle and in the back of the sternocleidomastoid muscle. The subclavian vein passes here.

Jugular venous angle is the site where the subclavian vein joins with the internal jugular vein to form the brachiocephalic vein.

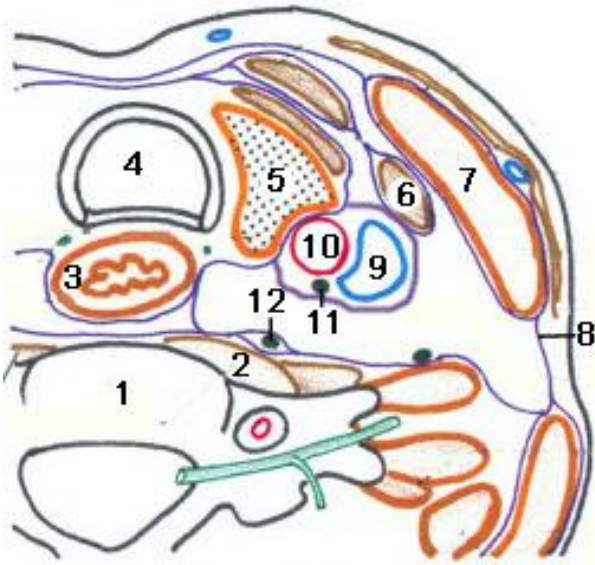
Self-evaluation questions:

1. List the branches of the subclavian artery. _____

2. _____, the first branch of the subclavian artery, runs vertically through the transverse foramina of the vertebrae to enter the skull through the foramen magnum and supply the brain and spinal cord.
3. _____, the branch of the thyrocervical trunk and important vessel in collateral circulation of the neck, runs just above the clavicle supplying Infraspinatus, and Supraspinatus.
4. The largest branch of the thyrocervical trunk, turns medially is _____
5. What nerve obliquely crosses the space from the sternocleidomastoid muscle which it pierces to the under surface of the trapezius muscle? _____
6. What lymph nodes lay in the posterior triangle of the neck? _____
7. Where is the sympathetic trunk located with respect to the carotid sheath? _____
8. The largest vein in the posterior triangle is the _____
9. In repairing a damaged right subclavian artery, the surgeon notices and protects a large nerve passing around to the posterior surface of the artery. This nerve, which does not encircle the subclavian on the left side, is the _____
10. A first year resident attempts to insert a central venous catheter into the heart by a subclavicular approach to the subclavian vein. Following the attempt, it is noted that the patient has difficulty breathing. What nervous structure lying immediately deep to the subclavian vein, as it crosses the anterior scalene muscle, may have been injured? _____

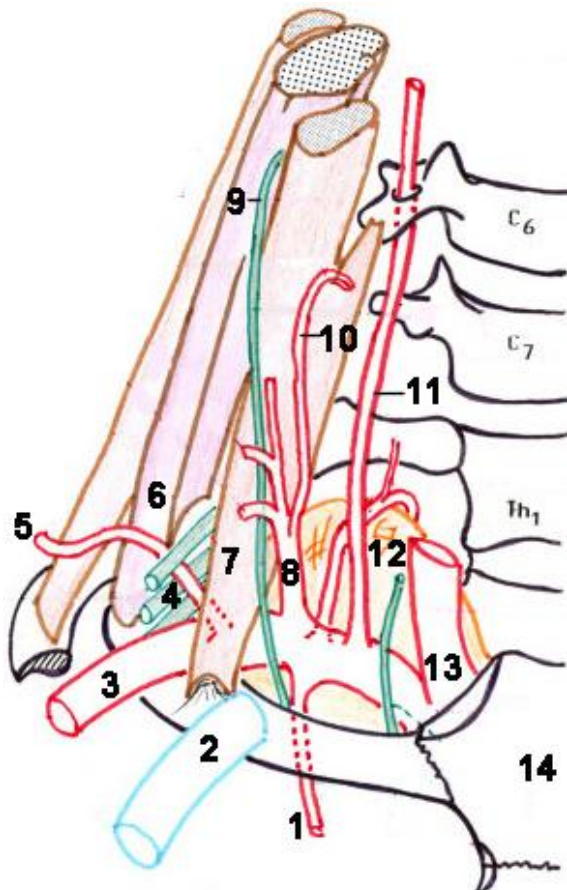
Self-instructional materials

Cross section of the head. Write the name of structures labeled on the diagram:



- 1 — Cervical vertebra
- 2 — Longus capitis
- 3 — _____
- 4 — _____
- 5 — Thyroid gland
- 6 — _____ muscle
- 7 — _____ muscle
- 8 — _____ layer
- 9 — _____ vein
- 10 — _____ artery
- 11 — _____ nerve
- 12 — _____ trunk

Scalenovertebral triangle. Write the name of structures labeled on the diagram:



- 1 — _____ artery
- 2 — _____ vein
- 3 — _____ artery
- 4 — Brachial plexus
- 5 — _____ trunk
- 6 — Middle scalene muscle
- 7 — Anterior scalene muscle
- 8 — _____ trunk
- 9 — _____ nerve
- 10 — _____ artery
- 11 — _____ artery
- 12 — Dome of pleura
- 13 — _____ artery
- 14 — Manubrium of sternum

NECK SURGERY

LAB N 8: EXTERNAL CAROTID ARTERY LIGATION. TRACHEOSTOMY. ABSCESS AND PHLEGMONS OF THE NECK: INCISION AND DRAINAGE. VAGOSYMPATHETIC NOVOCAIN BLOCKADE

Theoretical objectives (to know):

1. Techniques of external arterial bleeding control.
2. Difference between the direct and indirect surgical access for extensively injured arterial vessel.
3. Indications for the external carotid artery ligation.
4. Indications for the urgent and elective tracheostomy.
5. Surgical technique for tracheostomy. Difference between the superior and inferior tracheostomy.
6. Early and late complications of the tracheostomy and their prevention.
7. Standard approaches for the opening of the abscesses and phlegmons of the neck in suprasternal, pretracheal, and retrovisceral spaces; the posterior triangle of the neck, and around large vessels.
8. Incision and drainage for phlegmons in the submental, sublingual, and submandibular spaces.
9. Congenital malformations of the neck: the branchiogenous (lateral cervical) and thyroglossal duct (midline cervical) cysts.
10. Vagosympathetic Novocain blockade: indications, techniques, signs of the successful block.

Practical objectives (to be able to):

8. Use Deschamps' and Cooper' ligature needles.
9. Insert the tracheostomic tube into trachea.
10. Remove stitches.

Glossary

Abscess is a cavity containing pus and surrounded by inflamed tissue. It is an outcome of a localized infection. It requires surgical treatment.

Phlegmon is a diffuse inflammatory process with formation of suppurative/purulent exudate or pus which can spread to the surrounding tissues/spaces. The term mostly refers to a walled-off inflammatory mass without bacterial infection. It requires surgical treatment.

Cellulitis is a diffuse infection of the soft tissues with no localized area of pus amenable to drainage.

Pharyngeal (branchial) pouches form the lateral endodermal surface of the neck region to separate the arches.

Pharyngeal (branchial) groove or **pharyngeal cleft** is the counterpart of the branchial pouch on the ectodermal side. The first pharyngeal groove produces the external auditory meatus.

Thyroglossal duct is an embryological anatomical structure forming an open connection between the initial area of the thyroid gland development and its final position. It is located exactly at the midline, in front of the hyoid bone between the anterior 2/3rds and posterior 1/3rd of the tongue (foramen cecum) and the thyroid gland isthmus.

Lateral cervical (branchial cleft) cyst is a congenital epithelial cyst that arises on the lateral surface of the neck due to failure of obliteration of the second branchial cleft through embryonic development.

Branchial cleft fistula is a rare congenital abnormality that arises from the abnormal persistence of branchial apparatus remnants. A complete fistula is a tract that has the internal and external openings. The second branchial cleft fistulae extending from the anterior border of sternocleidomastoid muscle to the upper pole of the ipsilateral tonsil fossa.

Thyroglossal cyst (TGC) arises from the persistent epithelial and thyroglossal ducts, and is located on the front surface of the neck.

Vagosympathetic Novocain blockade is an effective method of prevention and treatment of the shock in pleuropulmonary penetrating wounds of the chest, especially in open pneumothorax.

Conicotomy or emergency airway puncture is an incision made through the skin and cricothyroid membrane to establish a airway during certain life-threatening situations, such as an airway obstruction by a foreign body, angioedema, or massive facial trauma.

Tracheotomy is a surgical procedure to create a communication through the neck into the trachea (windpipe).

External carotid artery ligation is indicated to control bleeding from the branches of the external carotid artery distal to the site of ligation; to diminish the blood supply of the tumor bed as an adjunctive procedure prior to a tumor resection and when major vessel or branches are involved in a tumor.

Bernard–Horner’s syndrome is the combination of drooping of the eyelid (ptosis) and constriction of the pupil (miosis) which is sometimes accompanied by decreased sweating (anhidrosis) of the face on the same side. Redness of the conjunctiva of the eye is usually present. It is also the sign of the successful vagosympathetic Novocain block.

Self-evaluation questions:

1. What are the indications for the urgent tracheostomy? (a) laryngeal obstruction by a foreign body; (b) acute asthmatic attack; (c) foreign body in trachea; (d) massive facial trauma.

2. A tracheotomy would precede which of the following surgical procedures? (a) laryngectomy; (b) parathyroidectomy; (c) labyrinthectomy; (d) turbinectomy. _____

3. The embryologic structure of the tongue/neck region that may remain open, form a cystic pouch, and become infected is the: (a) parathyroid duct; (b) parotid duct; (c) scalene node duct; (d) thyroglossal duct. _____

4. What is the standard approach in the treatment of abscesses and phlegmons?

5. Where is the line of skin incision carried out during the indirect surgical access for the carotid artery? _____

Self-instructional materials

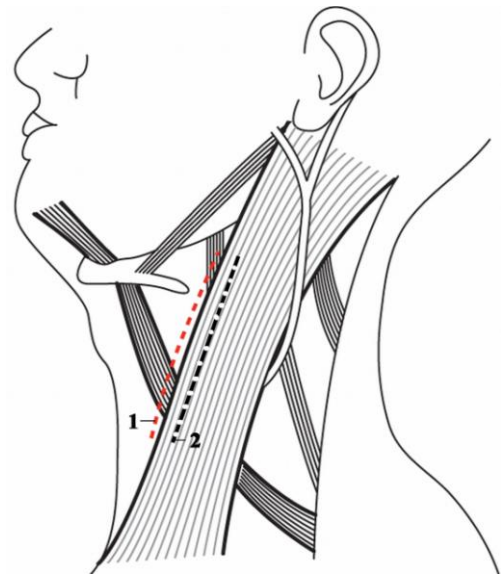
EXTERNAL CAROTID ARTERY LIGATION

The projection line of the carotid artery:

_____;

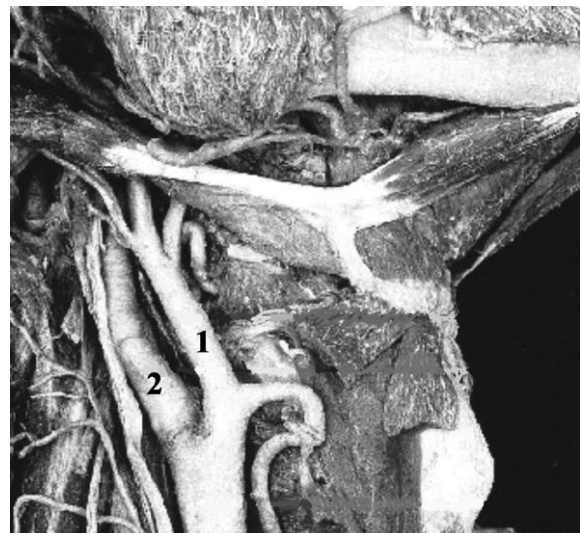
1 — the skin line of incision in the _____
surgical access for carotid artery;

2 — the skin line of incision in the _____
surgical access for carotid artery



External carotid artery (1) versus internal carotid artery (2):

- ECA _____
_____;
- ECA lies _____
and _____;
- after cross-clamping ECA the pulse
disappears on _____



Abscesses and phlegmons of the neck: incision and drainage

1 — phlegmon _____

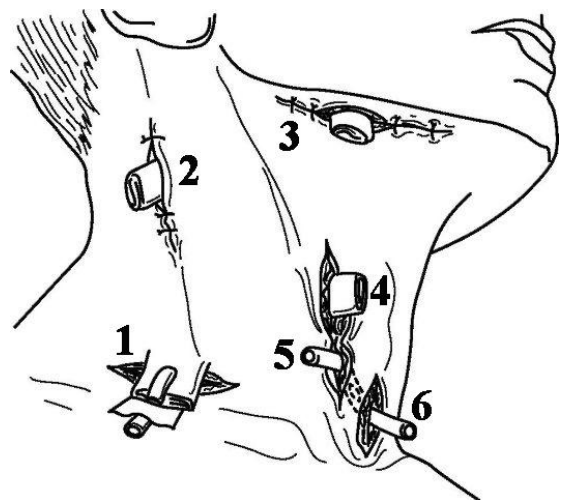
2 — Abscess _____

3 — _____ phlegmon

4 — phlegmon _____

5 — _____ phlegmon

6 — _____ abscess



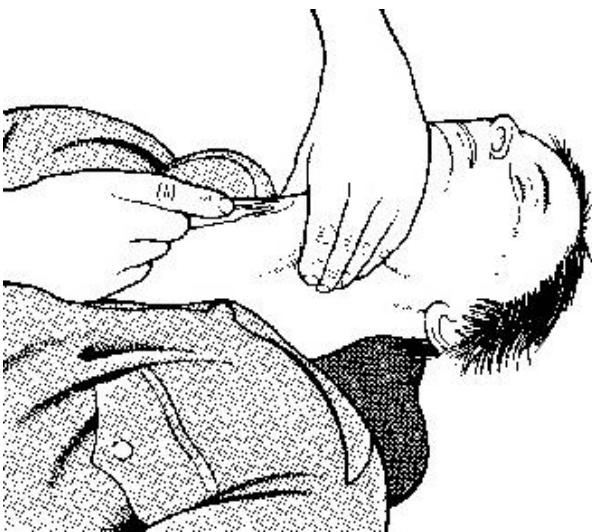
TRACHEOSTOMY

Indication for the urgent tracheostomy: _____,
_____ ; direct causes:

- _____ ;
- _____ ;
- _____

Indications for the elective tracheostomy:

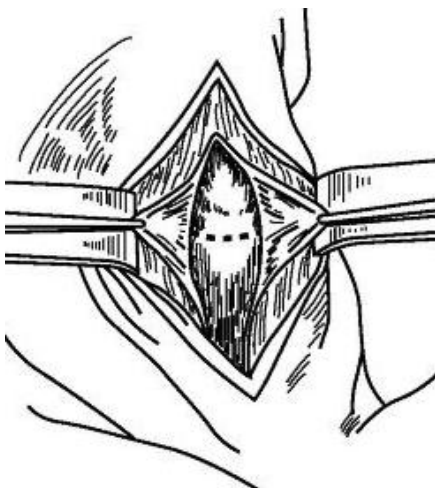
- _____ ;
- _____ ;
- _____ ;
- _____ ;
- _____



Procedures:

1. Vertical midline incision of:

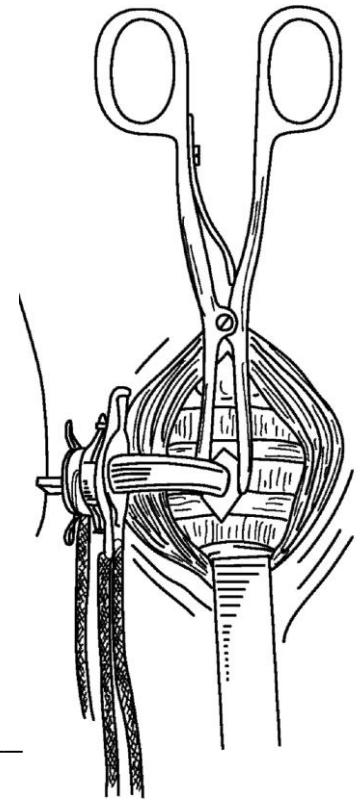
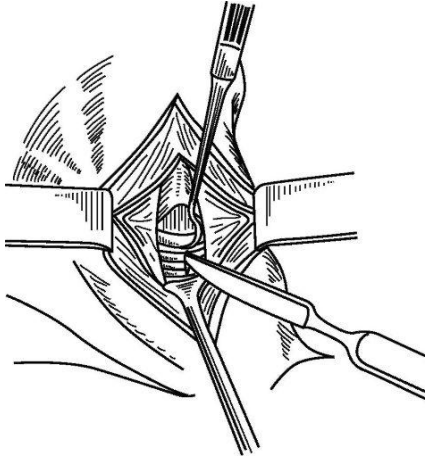
- _____ (1),
- _____ (2),
- _____ (3),
- _____ (4)



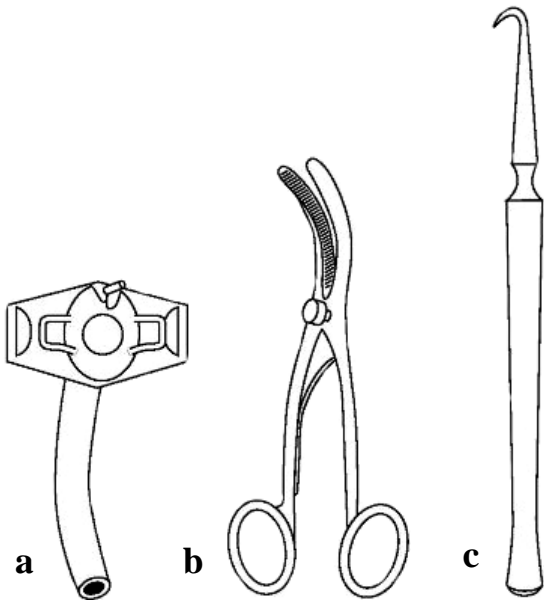
2. Mobilization of the thyroid gland isthmus by
the transversely incision of _____

3. Anchorage of the trachea by _____

and its dissection by _____



4. _____

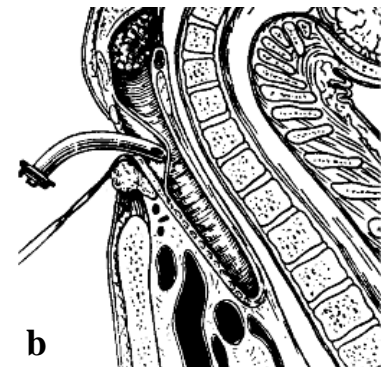
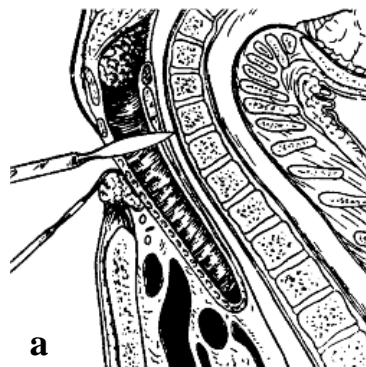


Instrument set for tracheostomy:

- a — _____;
- b — _____;
- c — _____

Complications:

- a — _____;
- b — _____;
- c — _____



CLINICAL ANATOMY OF THE NECK

LAB N 9: REVIEW OF THE NECK TOPOGRAPHICAL ANATOMY

QUESTIONS FOR DISCUSSION:

1. The superficial anatomy of the neck. Cervical fascia and fascial spaces.
2. Suprahyoid region: boundaries and layers of the submental and submandibular triangles.
3. Infrahyoid region: boundaries and triangles. Layers of the carotid triangle. Components of the main neurovascular bundle of the neck and their relationships.
4. Layers of omotracheal triangle of the neck.
5. Neck organs (pharynx, larynx, esophagus, thyroid and parathyroid glands) surface landmarks, the skeletotopic projection, syntopy, blood supply and innervation.
6. Sternocleidomastoid region: boundaries and layers.
7. Scalenovertebral triangle: boundaries and contents. Topographical anatomy of the subclavian artery first part branches.
8. Boundaries of the lateral triangle of the neck. Layers of the omoclavicular and omotracheal triangles. The interscalene triangle: boundaries and contents (topographical anatomy of the subclavian artery second part). Antescalenum space.
9. Main surgical terms: surgical access, operative procedure, and a way out of the operation. Types of surgical operations. The primary surgical wound debridement. Classification of surgical instruments and rules of use.
10. Types of anesthesia: local, regional, and general anesthesia. Special aspects of the anesthesia in head and neck surgery.
11. Methods of surgical haemostasis (application of the vessel clamp and ligation of a blood vessel into the wound; main peripheral arteries bleeding control; and vessel suture).
12. Typical approaches for the opening of the abscesses and phlegmons of the neck. Approaches in the surgery of neck organs.
13. Ligation of the external carotid artery in the carotid triangle.
14. Superior/inferior tracheostomy: indication; surgical technique; complications and their prevention.
15. Vagosympathetic Novocain blockade: indications, procedures, signs of the correct manipulation.

CLINICAL ANATOMY OF THE HEAD

LAB N 10: FACE: BOUNDARIES AND TOPOGRAPHIC REGIONS; INNERVATION AND BLOOD SUPPLY TO THE SKIN. MOTOR BRANCHES OF THE FACIAL NERVE (CN VII)

Theoretical objectives (to know):

1. Head: definition; borderline with the neck. Face: boundaries; surface landmarks; proportions, and horizontal facial thirds; regions.
2. Face: sensory innervation; skin projections of the trigeminal nerve branches (supraorbital, infraorbital, and mental nerves).
3. Blood supply to the face: surface makings, course, relations, and branches of the facial and temporal superficial arteries.
4. Venous drainage of the face: topographical anatomy of the facial vein; venous connections and their clinical significance.
5. Lymphatic drainage of the face.
6. Facial (mimetic) muscles: development; structure and actions; blood supply and innervation.
7. Facial nerve: the motor nucleus of the brainstem; parotid plexus and its branches; symptoms of the Bell's palsy.
8. Maxilla and mandible: anatomy; microstructure; the most common sites of fracture.

Practical objectives (to be able to):

1. Demonstrate branches of the facial and trigeminal nerves; facial, infraorbital, supraorbital, mental, temporal superficial arteries; facial and masticatory muscles on anatomical specimens and other illustrative guides.

Glossary

Head is the uppermost part of the body, containing the brain, and the eyes, ears, nose, mouth, and jaws (for the borderline with the neck see Lab N 2). The head includes the *frontal*, *parietal*, *occipital*, and *temporal* topographical regions in relation to the bones of the cranial vault. **Face** is the frontal surface of the head from the top of the forehead to the base of the chin and from ear to ear transversally. It also consists of some topographical divisions (*orbital*, *nasal*, *oral*, *mental*, *infraorbital*, *buccal*, and *zygomatic regions*).

Surface landmarks of the face. *Supra-orbital notch* represented at the junction of the medial one-third and lateral two-thirds of the supraorbital margin. Supra-orbital vessels and nerve curl upwards around the notch. *Nasion* — is a well-marked depression at the root of the nose where fronto-nasal and internasal sutures join. *Subnasale* is the point at which the nasal septum merges with the upper lip in the midsagittal plane. *Menton* is the most inferior point on the chin on the lateral cephalometric view. It is one of the cephalometric landmarks used in orthodontic treatment. *Gonion* (*angle of the mandible*) can be seen and palpated below and in front of ear lobe.

Horizontal thirds of the face: the *superior third* extends from the hairline to the glabella, the *middle third* — from the glabella to the subnasale, and the *lower third* — from the subnasale to the menton.

Supraorbital nerve is a terminal branch of the frontal nerve (from CN V₁). It supplies sensory innervation to the upper eyelid, the conjunctiva of the eye, the frontal sinus and the skin from the forehead extending back to the middle of the scalp.

Infraorbital nerve is the terminal branch of the maxillary nerve (CN V₂), occupying the infraorbital foramen located 6–7 mm down from the midpoint of the infraorbital margin. It supplies

sensory innervation to maxillary incisors, canine, and premolars, skin and conjunctiva of lower eyelid, cartilaginous septum and skin of side of nose, mucous membrane of the mouth, and skin of the upper lip.

Mental nerve is the terminal branch of the inferior alveolar nerve (from CN V₃). It emerges at the mental foramen in the mandible which is projected over the apex of the mandibular first or second premolars and innervates the skin of the chin and lower lip.

Facial nerve is the seventh pair of cranial nerves supplies motor innervation to the muscles of facial expression, Platysma, Stylohyoid, Posterior belly of digastric, and Stapedius; lacrimal, sublingual, and submandibular glands; glands of the palate and nose, and the taste buds of the anterior two-thirds of the tongue. The point where it leaves the skull projects just in front of the intertragic notch.

Pterygoid plexus is a venous plexus which is situated between the temporal and lateral pterygoid muscles, and partly between both pterygoid muscles. This plexus communicates freely with the facial vein and cavernous sinus.

Facial artery surface landmark is the imaginary wavy line joining three points: point A located on the mandible at the antero-inferior angle of the masseter where the pulsation of the artery can be felt; point B located about 1.25 cm laterally to the angle of the mouth and point C located at the medial angle of the eye.

Bell's palsy is the unilateral facial paralysis of a sudden onset due to a lesion of the facial nerve, resulting in characteristic facial distortion including eyebrow sagging; drooping of the eye and corner of the mouth. Moreover, it is not possible to close an eye completely on the affected side.

Self-evaluation questions:

1. Which nerve innervates the muscles of facial expression? _____

2. Name facial muscles of the orbital group. _____

3. Which nerves give sensory nerve supply to the face? _____

4. What is the terminal branch of the maxillary nerve? _____

5. Where is the cavernous sinus located? _____

6. Which artery supplies the upper lip tissues and muscles of facial expression? _____

7. Which artery arises within the parotid salivary gland and can be seen under the skin of the lateral portion of the forehead? _____

8. Which vein begins at the medial corner of the eye and drains into the internal jugular vein? _____

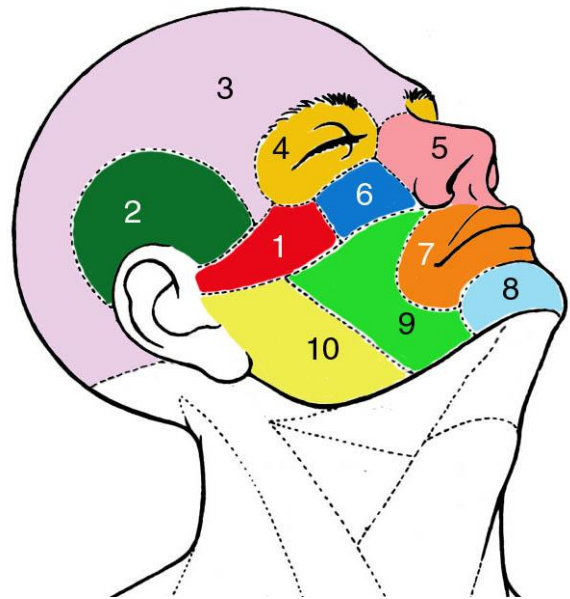
9. Which muscle protrudes the lips more forward, as for a kiss? _____

10. The facial muscle most responsible for moving the lips both upward and laterally to produce a smile is: _____

Self-instructional materials

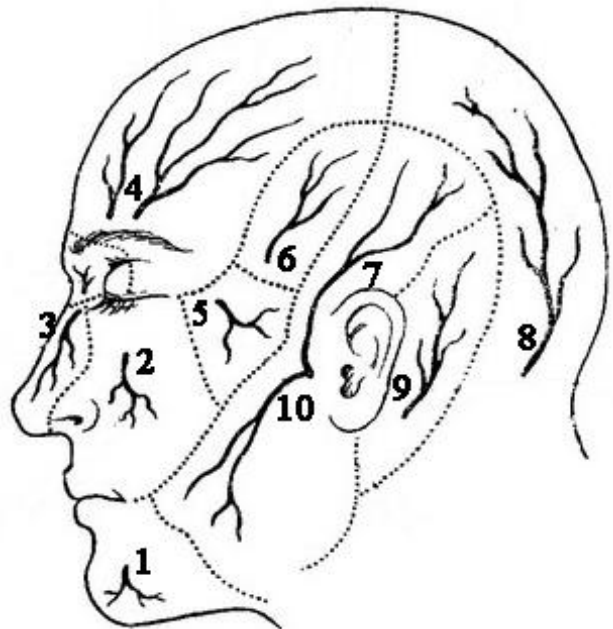
Regions of the head. Name the structures labeled on the diagram:

- 1 — _____
- 2 — _____
- 3 — _____
- 4 — _____
- 5 — _____
- 6 — _____
- 7 — _____
- 8 — _____
- 9 — _____
- 10 — _____

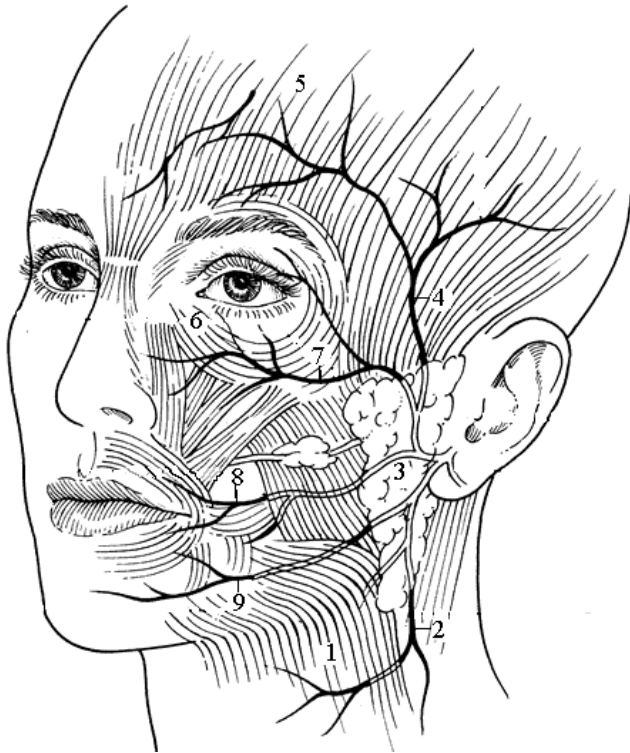


Sensory nerves of the face. Name the structures labeled on the diagram:

- 1 — _____ nerve
- 2 — _____ nerve
- 3 — _____ branches
(_____ nerve)
- 4 — Branches of _____
nerve
- 5 — _____ branch
- 6 — _____ branch
- 7 — _____ nerve
- 8 — _____ nerve
- 9 — _____ nerve
- 10 — _____ nerve

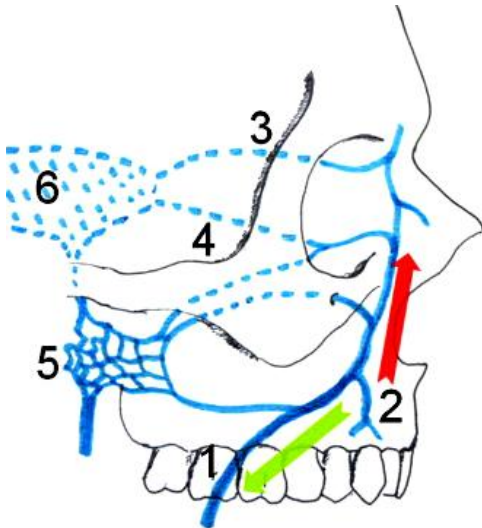


Facial nerve. Name the structures labeled on the diagram:



- 1 — Platysma
- 2 — _____ branch
- 3 — _____ gland
- 4 — _____ branches
- 5 — Epicranius
- 6 — Orbicularis oculi
- 7 — _____ branches
- 8 — _____ branches
- 9 — _____ branch

Venous anastomoses. Name the structures labeled on the diagram:



- 1 — _____ vein
- 2 — _____ vein
- 3 — _____ vein
- 4 — _____ vein
- 5 — _____ plexus
- 6 — _____ sinus

Name pathways of infection spread from the face to the intracranial compartment:

1. **Facial vein** → _____ vein → _____ vein → **cavernous sinus.**
2. **Facial vein** → _____ vein → _____ → **venous plexus of _____** → **cavernous sinus.**
3. **Pterygoid plexus** → _____ vein → _____ vein → _____ vein → **cavernous sinus.**

CLINICAL ANATOMY OF THE HEAD

LAB N 11: INFRAORBITAL AND BUCCAL REGION: BOUNDARIES, LAYERS, FASCIAL SPACES. PRIMARY SURGICAL MANAGEMENT OF FACIAL WOUNDS

Theoretical objectives (to know):

1. Infraorbital and buccal region: boundaries, layers, muscles, and neurovascular bundles.
2. Buccal space: anatomic boundaries; contents, communications; clinical relevance.
3. Canine space: anatomic boundaries; contents; communications.
4. Principles of wound management: assessment; haemostasis, analgesia; the skin preparation and wound toilet; closure.
5. The aim and techniques of the skin preparation and wound toilet (irrigation; debridement of ragged, nonviable skin edges; removal of foreign bodies).
6. General principles of the wound closure: types of wound healing; needles, suture materials, and suturing techniques.
7. Directions of skin incision on the face for the abscess and phlegmon drainage.
8. Reconstructive surgery of soft tissues of the face (flaps, skin grafts).

Practical objectives (to be able to):

1. Demonstrate the facial muscles; buccal fat pad; pterygomandibular raphe and buccopharyngeal fascia; infraorbital nerve and branches of facial nerve; angular artery in illustrative guides.
2. Apply the vertical and horizontal mattress stitches.

Glossary

Infraorbital and buccal region is bordered by the anterior margin of the masseter *posteriorly*; the nasolabial line *anteriorly*; the base of the mandible *inferiorly*; the infraorbital margin *superiorly*.

Buccal (buccinator) space is superficial to the buccinator muscle and deep to the platysma muscle and the skin. The boundaries of the buccal space are: the angle of the mouth anteriorly; the masseter muscle posteriorly; the zygomatic process of the maxilla and zygomaticus muscles superiorly; the depressor anguli oris muscle and attachment of the deep fascia to the mandible inferiorly. The space contains: the buccal fat pad; parotid duct; facial artery and vein; transverse facial artery and vein. Buccal space abscesses typically cause a facial swelling over the cheek that may extend from the zygomatic arch down to the inferior border of the mandible, and from the anterior border the masseter muscle posteriorly to the angle of the mouth anteriorly.

Buccopharyngeal fascia closely invests the constrictor muscles of the pharynx and progresses from the constrictor pharyngis superior onto the buccinator muscle.

Pterygomandibular raphe is a ligamentous band of the buccopharyngeal fascia, attached to the hamulus of the medial pterygoid plate superiorly, and to the posterior end of the mylohyoid line of the mandible inferiorly. It gives an attachment to the superior pharyngeal constrictor and buccinator muscles.

Buccal fat pad (Bichat's fat pad) is the encapsulated fat mass in the cheek. It is located on either side of the face between the buccinator muscle and several more superficial muscles (including the masseter, zygomaticus minor and major). The inferior portion of the buccal fat pad is a part of the buccal space.

Canine space (infraorbital space) is associated with the canine fossa and located between the levator anguli oris muscle inferiorly and the levator labii superioris muscle superiorly. It contains the angular artery and vein; infra-orbital nerve (a branch of the maxillary division of the trigeminal nerve). Canine space infections may occur due to bacterial spread from the buccal space.

Signs and symptoms of a canine space abscess may include a swelling that smoothes out the nasolabial fold. If left untreated, infections of this space are prone to drain spontaneously through the medial or lateral canthus of the eye, as this is the path of the least resistance.

Langer's lines refer to the structural orientation of the fibrous tissue of the skin. They form the natural cleavage lines that are present in all body areas parallel to dermal collagen bundles and perpendicular to muscle contraction. Incisions made parallel to these lines make a much smaller scar upon healing than those made at right angles to the lines.

Types of wound healing. *Primary healing* takes place when a wound is closed within a few hours (24 hours on the face) of its creation. *Delayed primary healing* occurs when a poorly delineated wound is left open for wound infection prophylaxis (an open wound allows the natural host defense debridement) and is closed in approximately 4 days. *Secondary healing* occurs when an open full thickness wound is left to be close by wound contraction and epithelialization.

Skin grafts involve the transfer of split thickness (most common) or full thickness sheets of skin from the donor site to the wound. A skin graft may be meshed to allow for drainage of exudate and expansion of the graft, or may be left as an intact sheet.

Flaps involve the partial or total isolation of a segment of a tissue with its blood supply that is then moved from the donor site to the wound. Flaps may contain a variety of tissues, including skin, subcutaneous fat, fascia, muscle, bone, and nerve. Types of flaps include rotational, free, and pedicle flaps.

Self-evaluation questions:

1. Which type of a suture material (??) should be used to close an infected wound? _____

2. What are the disadvantages of a braided (multifilaments) suture material? _____

3. What are the two types of suture materials? _____

4. A wound expected to heal by primary intention is a _____

5. What is the usual time for suture removal from the face? _____

6. The buccinator muscle forms the _____ wall of the mouth.

7. Which nerve provides motor innervation to the buccinator muscle? _____

8. Which nerve conveys primarily the pain elicited from an infected facial wound? _____

9. Two parts of facial subcutaneous fat are _____

10. Split-thickness skin graft (STSG) is a graft that contains _____

11. Full thickness skin graft (FTSG) is a graft that consists of _____

CLINICAL ANATOMY OF THE HEAD

LAB N 12: ORAL REGION: TOPOGRAPHY OF THE ORAL VESTIBULE AND ORAL CAVITY PROPER

Theoretical objectives (to know):

1. Boundaries of the oral vestibule. Lips: layers; blood vessels, sensory and motor nerve supply to the skin, muscles and mucous membrane; lymphatic drainage of the upper and lower lips.
2. Boundaries of the oral cavity proper: layers of the palate (hard and soft); blood vessels and nerve supply to the mucous membrane and muscles of the soft palate.
3. Structural components of the periodontium: gingiva (parts, gingival papilla, gingival groove), inserting periodontium; cementum; and alveolar bone.
4. Topography of the palatal tonsil: tonsillar capsule and fossa; paratonsillar space.
5. The floor of the oral cavity proper: sublingual caruncle and fold; frenulum of tongue.
6. Muscles of the floor of the oral cavity proper: overview of the structure and actions; blood supply and innervations.
7. Tongue: anterior and posterior part; midline and terminal sulcus; lingual tonsil.
8. Foramen caecum: location; relationship to the thyroglossal duct cyst and fistula.
9. Muscles of the tongue: intrinsic and extrinsic groups; origin, insertion, and action; innervation and blood supply.
10. Nerve and blood supply, venous and lymphatic drainage of the tongue.

Practical objectives (to be able to):

2. Demonstrate the soft palate, fauces, frenulum of upper/lower lip and frenulum of tongue, sublingual caruncle and fold, palatal tonsil in anatomical specimens and other illustrative guides and on living person.
3. Fabricate a clay model of muscles composing the floor of the mouth and sublingual space.

Glossary

Oral region includes the upper and lower lips, oral vestibule and oral cavity proper (mouth) with teeth, gingivae (gums), tongue, palate, and palatine tonsils.

Oral vestibule is a slit-like space between the lips or cheeks on one side and the teeth on the other side. When the teeth occlude, the vestibule is represented as a closed space communicating with the oral cavity proper only in the retromolar regions behind the last molar tooth on each side.

Oral cavity proper is bounded by the soft and hard palate superiorly; by the alveolar arches with teeth laterally and anteriorly; and by the tongue and reflection of the mucous membrane from the bottom surface of the tongue to the gum inferiorly. The lateral boundaries are the teeth. It communicates distally with the pharynx through a constricted aperture termed the isthmus faucium.

Tonsillar capsule is a thin fibrous layer covering the lateral surface of the tonsil only and is separated from the superior constrictor muscle by loose areolar tissue (peritonsillar space).

Peritonsillar space is located between the capsule of the palatine tonsils and constrictor muscles of the pharynx. The anterior and posterior pillars (the *palatoglossal* and *palatopharyngeal arches*), torus tubarius (superiorly), and pyriform recess (inferiorly) form the boundaries of this space. Accumulation of pus in the peritonsillar space is known as the *peritonsillar abscess*.

Periodontium refers to the specialized tissues that both surround and support the teeth. It consists of four principal components namely: *Gingiva*, *Periodontal ligament (PDL)*, *Cementum*, and *Alveolar bone*.

Gum (gingiva) consists of the connective tissue covered with mucous membrane which is attached to and surrounding the necks of the teeth (the *marginal gingiva*) and adjacent alveolar bone (*attached gingiva*). The marginal gingiva varies in width from 0.5 to 2.0 mm from the free gingival crest to the attached gingiva. The vestibular aspect of the attached gingiva extends to the relatively loose and movable alveolar mucosa, from which it is demarcated by the *mucogingival junction*.

Desmodontium (periodontal ligament) consists of the collagen fibers, running from the cementum to alveolar bone, that suspend teeth in their socket.

Gingival sulcus is an area of potential space between a tooth and surrounding gingival tissue. It is lined with the *sulcular epithelium*. It can turn into the gingival pouch.

Gingival (interdental) papilla is a part of the gingival margin. The interdental papillae fill in the areas between the teeth apically to their contact areas in order to prevent food impaction.

Alveolar bone is a thin layer of bone making up the wall of the dental alveolus, surrounding and containing the teeth. It is pierced by many small blood vessels, lymphatic vessels, and nerves.

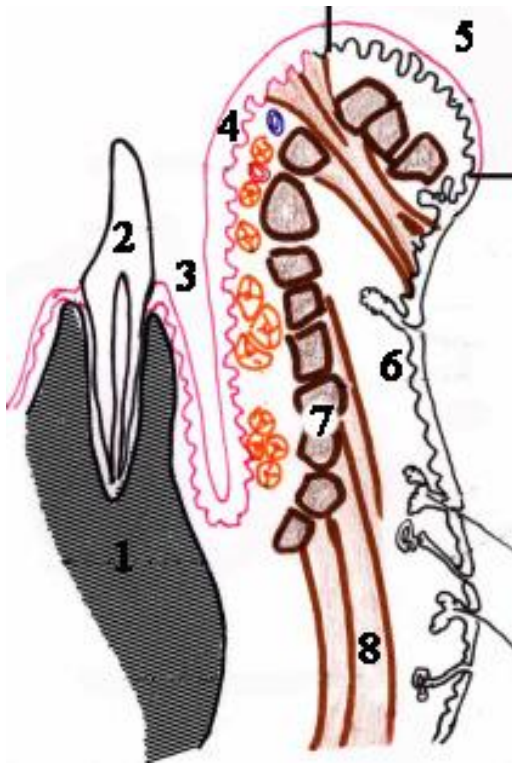
Cementum is a specialized calcified substance covering roots of the teeth. It is an area where the periodontal ligament is anchoring. The cementum is an avascular structure.

Self-evaluation questions:

1. The uvula, a structure of the posterior part of the oral cavity, is an extension of the _____.
 2. The lingual branch of the _____ nerve conveys general sensation from the posterior 1/3 of the tongue.
 3. The _____ papillae of the tongue contain no taste buds.
 4. The most anterior part of the oral cavity is the _____.
 5. Does the mucosa of the posterior third of the tongue contain papillae? _____
 6. The _____ muscles of the tongue change its shape. _____
 7. The _____ nerve conveys general sensation from the anterior 2/3 of the tongue.
-
8. The lingual artery is located _____ to the hyoglossus muscle.
 9. The _____ muscle protrudes the tongue.
 10. The posterior 1/3 of the palate is also known as the _____ palate.
 11. The _____ nerve passes through the incisive canal.
 12. The _____ conveys taste sensation from the anterior 2/3 of the tongue.

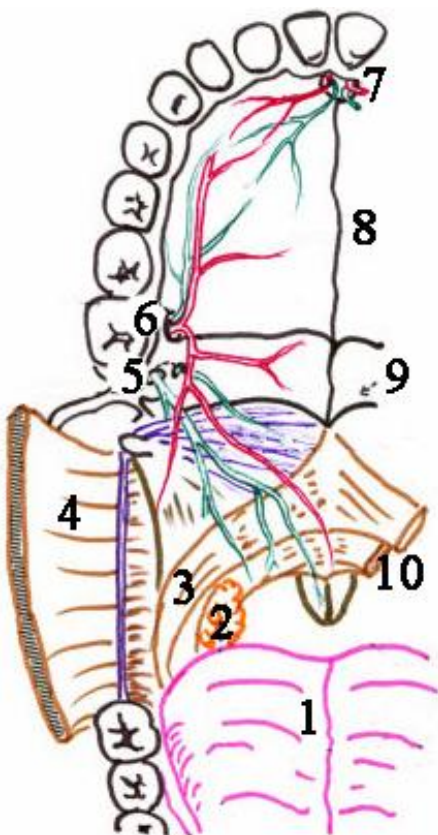
Self-instructional materials

Lower lip (sagittal section). Write the name of structures labeled on the diagram:

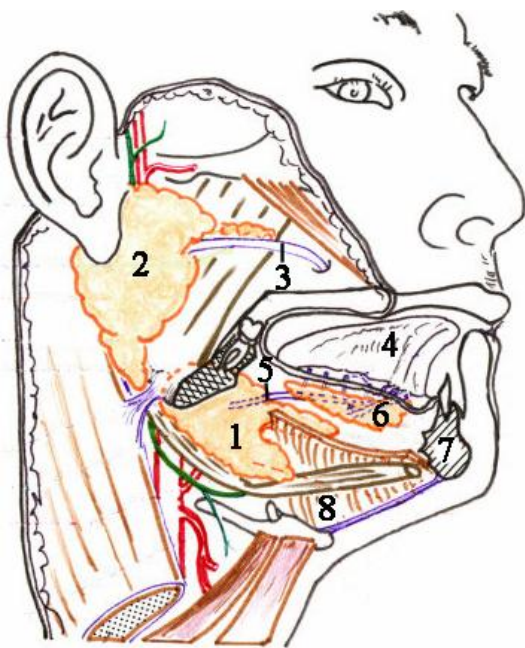


- 1 — Mandible
- 2 — Incisor tooth
- 3 — _____
- 4 — _____
- 5 — _____
- 6 — _____
- 7 — _____
- 8 — _____

Palatine nerves and blood vessels (underside view). Write the name of structures labeled on the diagram:

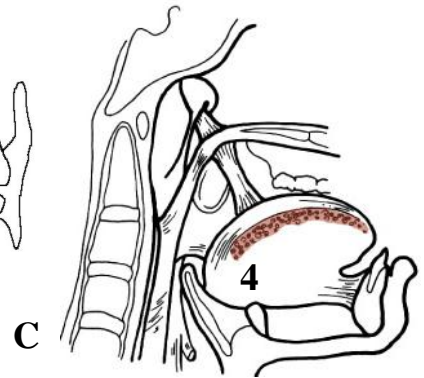
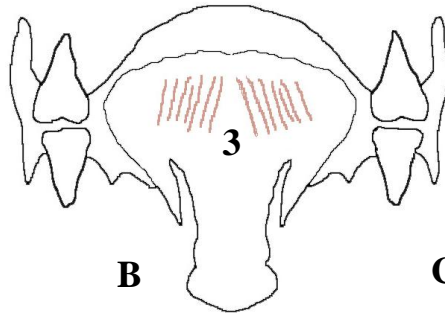
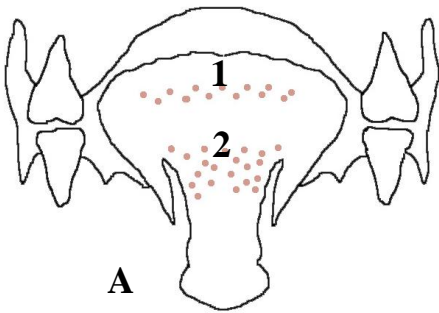


- 1 — _____
- 2 — _____
- 3 — _____ muscle
- 4 — _____ muscle
- 5 — _____ artery and nerve
- 6 — _____ artery and nerve
- 7 — _____ nerve in
_____ foramina
- 8 — _____
- 9 — _____
_____ bone
- 10 — _____



Major salivary glands topography. Write the name of structures labeled on the diagram:

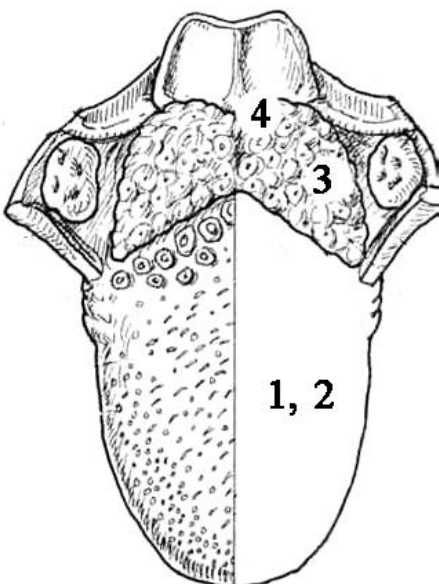
- 1 — _____ gland
- 2 — _____ gland
- 3 — _____ duct
- 4 — _____
- 5 — _____ duct
- 6 — _____ duct
- 7 — _____
- 8 — _____ muscle



Muscles of tongue (A, B — frontal; C — sagittal sections).

- 1 — _____ muscle
- 2 — _____ muscle
- 3 — _____ muscle
- 4 — _____ muscle

Muscles of tongue receive nerve supply from _____ nerve.



Write the name of structures labeled on the diagram:

- 1 — _____ (common sensation)
- 2 — _____ nerve (taste sensation)
- 3 — _____
(common and taste sensation)
- 4 — _____ nerve (common and taste sensation)

CLINICAL ANATOMY OF THE HEAD

LAB N 13: PERMANENT TEETH: GENERAL MORPHOLOGY; BLOOD SUPPLY AND INNERVATION; VENOUS AND LYMPHATIC DRAINAGE. ANATOMICAL CONSIDERATIONS FOR BLOCK ANESTHESIA

Theoretical objectives (to know):

1. Groups of permanent teeth. Reference systems commonly used to designate teeth during clinical examination and written report (FDI and Palmer numbering systems).
2. Parts of a tooth: crown, neck, and root. Definitions of the «clinical crown» and «clinical root». Life-long change in the clinical crown and the clinical root presentation.
3. Crown-to-root-ratio: clinical importance
4. Number of roots in different groups of teeth. Multi-rooted teeth: names and number of roots.
5. Root and root canal morphology.
6. Crown and root thirds.
7. Relationships between permanent teeth roots and the inferior wall of the maxillary sinus; nasal cavity and mandibular canal.
8. Anatomy of pulp chamber: dentine-pulp complex.
9. Tooth determination principles: crown and root signs.
10. Eruption schedule of permanent teeth.
11. Blood supply and lymphatic drainage of maxillary and mandibular teeth.
12. Nerve supply to teeth and gingivae of the upper jaw.
13. Nerve supply to teeth and gingivae of the lower jaw.
14. Anatomical landmarks for the block anaesthesia of maxillary teeth (infraorbital, posterior alveolar, and palatal nerve blocks).
15. Anatomical landmarks for the block anaesthesia of mandibular teeth (inferior alveolar and mental nerve blocks).

Practical objectives (to be able to):

4. Show different types of teeth and their parts in anatomical specimens and other illustrative material.
5. Determine to which side a tooth belongs by using the root, angle of a crown, and crown curvature characteristics.

Glossary

Dental arch is the parabolic curve formed by the cutting edges and masticating surfaces of the teeth. The upper dental arch is larger than the lower, so that under normal conditions maxillary teeth slightly overlap those of the mandible.

Alveolar arch is a curved free portion of the alveolar process of maxilla/mandible containing dental alveoli

Basal arch is the line joining root apices. During growth and development the values of alveolar and basal arches change, but the sizes of the teeth in the mesiodistal dimension remain the same

Dental alveoli are sockets in the alveolar process of the maxilla and mandible that house the roots of the teeth

Anatomical crown of a tooth is the part which is covered by the enamel (the area above the cemento-enamel junction). The crown has 5 surfaces: *lingual*, *vestibular (labial or buccal)*, *oc-*

clusal and 2 approximal, mesial and distal. In the anterior teeth, the occlusal surfaces are very narrow and referred as incisal edges.

Clinical crown of a tooth is the whole visible part projected above the gingiva.

Neck of a tooth is the constricted part of the tooth between the anatomical crown and the root at the enamel-cementum border.

Anatomical root is a part of the tooth covered with the cementum and retained in the alveolar socket by a fibrous periodontal ligament.

Clinical root is a portion of a tooth which is located apically from the gingival margin and not visible in the oral cavity.

Crown-to-root-ratio is the ratio of the length of the part of a tooth above the alveolar bone (unattached portion) versus the part which is surrounded with the alveolar bone (attached part). It is an important consideration in the diagnosis and restorative treatment planning. The minimal favorable crown-to-root ratio is 1:1. Any lesser support provided by the alveolar bone drastically impairs the individual tooth prognosis as well as limits restorative options.

Pulp chamber consists of a coronal portion (widest part) and a *root canal/canals* (narrow part). It is filled with *dental pulp* rich in vessels and nerves.

Root sign — the longitudinal root axis is inclined distally and forms a sharp angle with a line passing through the middle of the crown.

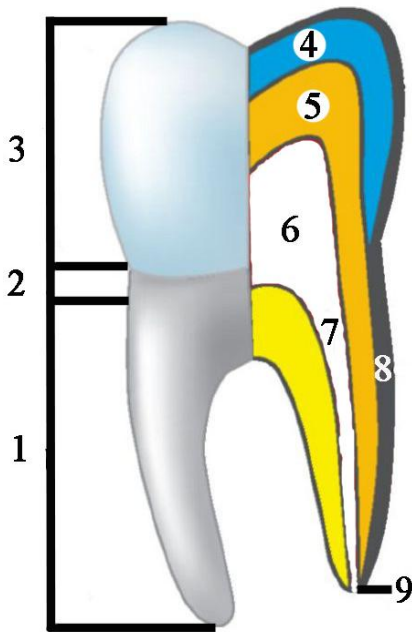
Crown angle sign (vestibular view) — an angle between an occlusal surface/incisal edge and mesial surface of a crown is sharper than an angle between occlusal surface/incisal edge and distal surface.

Crown curvature sign (occlusal view) — a vestibular surface of a crown joins the mesial more abruptly than the distal. Consequently, the mesial segment of the vestibular surface is more convex in the transverse direction than the distal.

Self-evaluation questions:

1. What is the name of the soft tissue that surrounds the roots of teeth? _____
2. The part of a tooth that anchors it to the gingiva and jawbone is called the _____
3. How many teeth are expected in the permanent dentition? _____
4. Which are the longest teeth? _____
5. Which part of a tooth is covered with enamel? _____
6. Name the areas where crowns of adjacent teeth touch each other. What are the main functions of those areas? _____
7. Name the anterior teeth. _____
8. Name the posterior teeth. _____
9. Which teeth usually have a bifurcation? _____
10. Which teeth usually have a trifurcation? _____

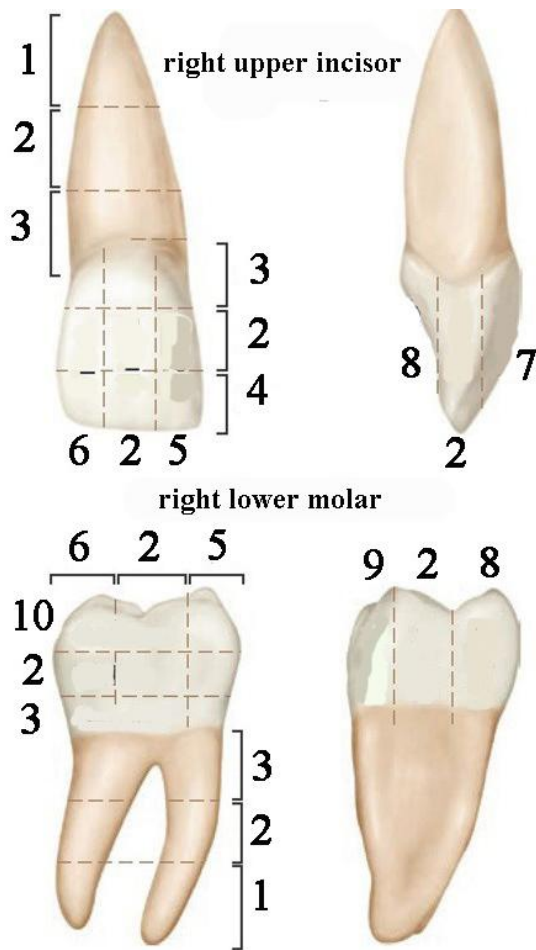
Self-instructional materials



Tooth morphology. Name the structures labeled on the diagram:

- 1 — _____
- 2 — _____
- 3 — _____
- 4 — _____
- 5 — _____
- 6 — _____
- 7 — _____
- 8 — _____
- 9 — _____

Name the thirds labeled on the diagram:



• root

- I — _____
- II — _____
- III — _____

• crown

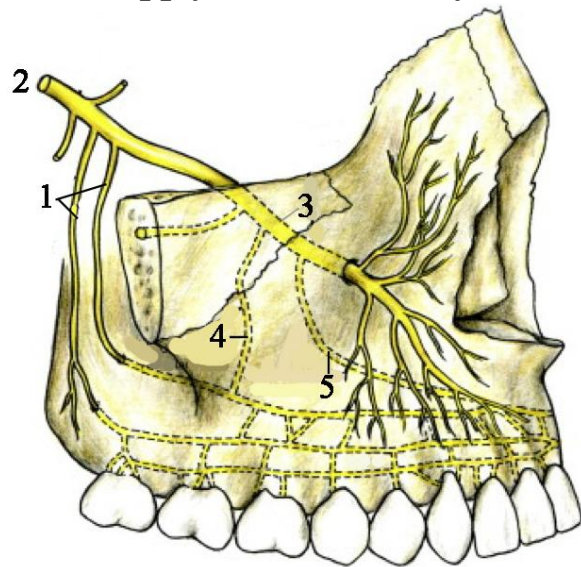
- 1 — _____
- 2 — _____
- 3 — _____
- 4 — _____
- 5 — _____
- 6 — _____
- 7 — _____
- 8 — _____
- 9 — _____

Nerve supply to the teeth and gingiva

MAXILLA	nerve								nerve	Palatal surface of the gingiva
	branches			branch		branches			TEETH	
	nerve		branches (1)			nerve (2)				
Tooth number	1	2	3	4	5	6	7	8	Buccal surface of the gingiva	
MANDIBLE				nerve		nerve (1)				Buccal surface of the gingiva
	nerve		nerve						nerve (2)	
	nerve(1)			nerve (2)						TEETH
									Lingual surface of the gum	

Nerve supply to the maxillary teeth. Name the structures labeled on the diagram:

57



- 1 — _____ branches
- 2 — _____ nerve
- 3 — _____ nerve
- 4 — _____ branch
- 5 — _____ branches

CLINICAL ANATOMY OF THE HEAD

LAB N 14: MORPHOLOGY OF THE PERMANENT DENTITION

Theoretical objectives (to know):

1. Surfaces of the anterior teeth.
2. Occlusal surface/incisal edge of a crown: cusps, a cingulum, tubercles, ridges, fissures, and fossa.
3. Equator of a tooth. Clinical significance.
4. Morphological features of the maxillary and mandibular incisors: crown shape and outline pulp chamber features.
5. Maxillary and mandibular canines: crown shape and outline; pulp chamber features.
6. Maxillary and mandibular premolars: crown shape and outline; pulp chamber features.
7. The Maxillary and mandibular first molars: crown shape and outline; the names and number of roots.
8. Maxillary and mandibular second molars: crown shape and outline, the names and number of roots.
9. Maxillary and mandibular third molars: crown shape and outline; the names and number of roots.

Practical objectives (to be able to):

1. Demonstrate elements of the crown outline (tubercles, ridges, fissures etc.) in anatomical specimens.
2. Identify different types of teeth by the crown morphology and root number on anatomical specimens.
3. Use FDI and Zsigomond tooth numbering systems.

Glossary

Permanent teeth are the second set of teeth. It normally contains 32 teeth: 8 incisors, 4 canines, 8 premolars, and 12 molars.

Cusp of a tooth is an elevation on the occlusal surface of tooth (with the exception of the incisors). The number varies from 1 to 5.

Cingulum is a bulbous prominence connecting both marginal crests close to the cervical margin on the oral surface of the incisors and canines.

Incisors are the 1st and 2nd teeth on each side from the midline of the dental arch having crowns shaped like a cutting chisel. The crowns of the upper incisors are twice as wide as of the lower. Each tooth has a single root, flattened from the sides in the lower incisors. The apex of the root deviates slightly laterally.

Canine teeth are the 3rd teeth on both sides from the midline of the dental arch. Each of them has a long single root flattened and grooved on the sides. The crown has two cutting edges which meet at an angle. There is a tubercle located on the lingual surface close to the neck. The crown is so flattened that the lingual and labial surfaces converge toward the cutting edge. The vestibular surface is convex transversely and longitudinally. The cutting edge of the crown consists of two segments, a smaller, mesial, and a larger, distal, which converge towards its apex.

Premolar teeth occupy the 4th and 5th positions in the dental arch on both sides from the midline. The characteristic feature is the presence of two occlusal cusps on the masticatory surface of the crown. That is why these teeth are also called bicuspid. One cusp is vestibular (buccal) and the other is lingual. The premolars have a single root, but that of the upper first premolar usually bifurcates; it is flattened anteroposteriorly.

Molar teeth located at the 6th, 7th and 8th positions in the dental arch on both sides from the midline. They decrease in size from the first to the third molar so the first is the largest and the third is the smallest. Third molars erupt late and are called the *wisdom teeth*. The crown is of cuboid shape with the square occlusal surface having three or more cusps. The upper molars have three roots, two buccal and one lingual; the lower molars have only two roots, *mesial* and *distal*. Roots of wisdom teeth may fuse to form a single conical root.

Cusp of Carabelli is the fifth cusp on the mesiopalatal surface of the maxillary first molar present in about 60 % of Caucasians (wites).

Self-evaluation questions:

1. How many roots does an anterior tooth usually have? _____
2. What is a cingulum? _____
3. Which surfaces of the anterior teeth have a greater curvature of the CEJ? _____
4. How many mamelons does an incisor have and where are they located? _____
5. Name the premolar with a bifurcated root. _____
6. Name the premolar with a buccal cusp being longer than lingual. _____
7. Which maxillary premolar has a longer root? _____
8. Which premolar is the largest from the facial view (aspect)? _____
9. Which is the smallest premolar from the facial view? _____
10. What tooth is considered to have a less plaque retentive occlusal table? (Not many supplementary grooves). _____
11. How many cusps does the first maxillary molar have? _____
12. How many roots does the second mandibular molar have? _____
13. How many roots does the second maxillary molar have? _____
14. A tooth that usually has 3 roots (either fused or very close to each other) and 3 to 5 cusps on the occlusal surface is the _____
15. What are the main differences between maxillary and mandibular molars? _____

Self-instructional materials

Morphology of the permanent teeth (right upper quadrant). Name the structures labeled on the diagram:

FDI system

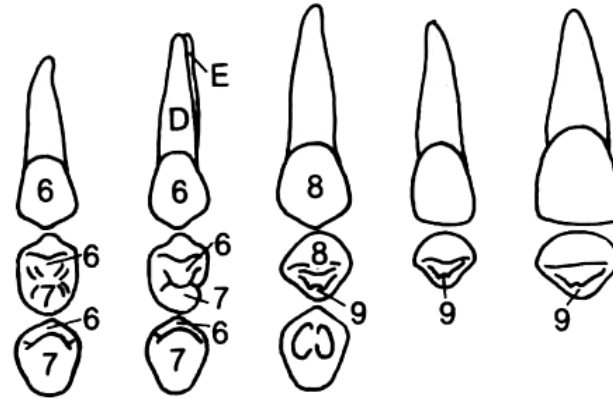
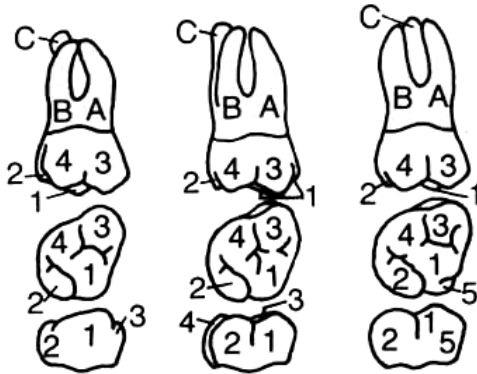
**Name
of the roots**

A. _____
B. _____
C. _____

D. _____
E. _____

**Surfaces
of the crown**

buccal
occlusal
palatal



Cusps name

1. _____
2. _____
3. _____
4. _____
5. _____

6. _____
7. _____

8. _____

9. _____

Self-instructional materials

Morphology of the permanent teeth (right lower quadrant). Name the structures labeled on the diagram:

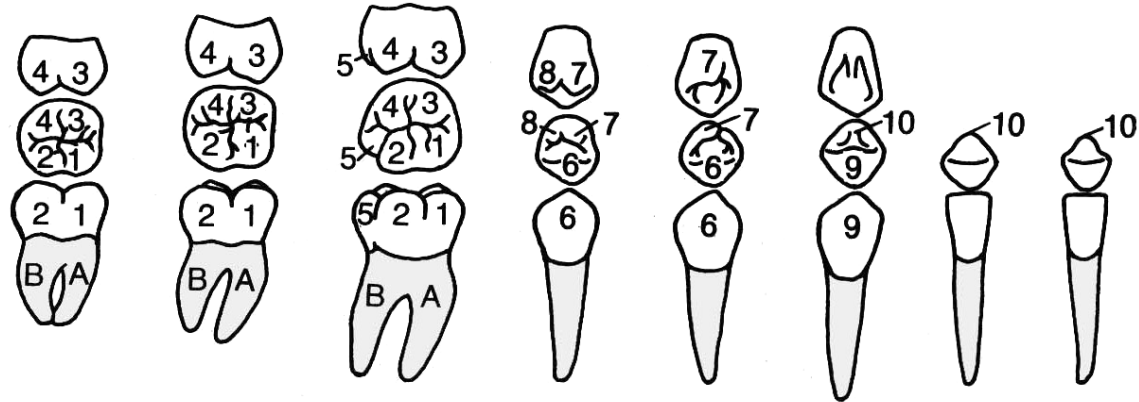
FDI system

Cusps name

- | | | |
|----------|----------|-----------|
| 1. _____ | 6. _____ | 9. _____ |
| 2. _____ | 7. _____ | 10. _____ |
| 3. _____ | | |
| 4. _____ | 8. _____ | |
| 5. _____ | | |

Surfaces
of the crown

lingual
occlusal
buccal



Names
of the roots

- A. _____
B. _____

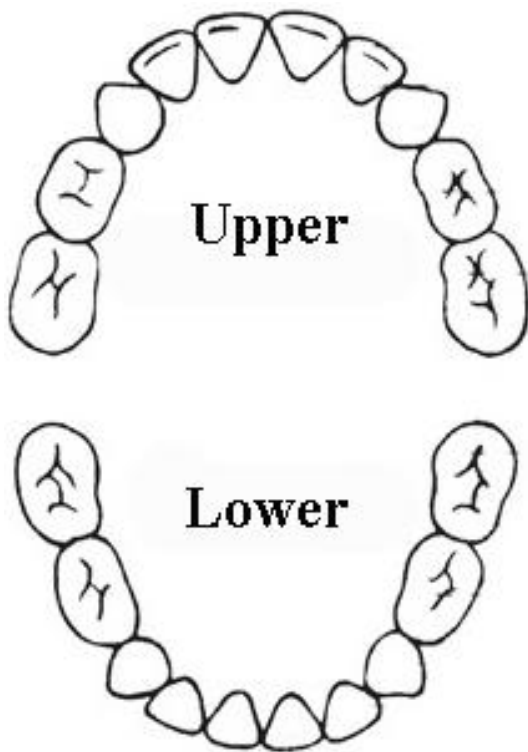
CLINICAL ANATOMY OF THE HEAD

LAB N 15: MORPHOLOGY OF DECIDUOUS DENTITION

Theoretical objectives (to know):

1. Numbering systems (dental formulas) used for deciduous teeth.
2. Eruption schedule of deciduous teeth.
3. Mixed dentition: time frames.
4. Primary (deciduous) incisors: crown, root and pulp chamber morphology.
5. Primary (deciduous) canines: crown, root and pulp chamber morphology.
6. Primary (deciduous) molars: crown, root and pulp chamber morphology surfaces.

Self-instructional materials




Indicate the age and the sequence of deciduous teeth eruption.

Number of primary teeth = $N - 4$,

where N — _____

Refer to deciduous teeth using FDI numbering system.



CLINICAL ANATOMY OF THE HEAD

LAB N 16: TOPOGRAPHY OF THE PAROTIDOMASSETERIC REGION

Theoretical objectives (to know):

11. Boundaries and layers of the parotidomasseteric region.
12. Parotid gland: topography; parts, parotid duct and accessory parotid gland.
13. Parotid fascia: border, location; parotid space. Life threatening complication of parotid space infections.
14. Relationships of the parotid gland with blood vessels and nerves including facial and auriculotemporal nerves, external carotid artery, retromandibular and internal jugular veins.
15. Parotid gland: blood and nerve supply; venous and lymphatic drainage.
16. Masseter muscle: anatomy; function; blood and nerve supply; submasseteric space.
17. Temporomandibular joint: articular surfaces, disk and capsule; capsular and intracapsular ligaments; blood and nerve supply.
18. Phlegmons and abscesses of the parotidomasseteric region: milestones of the surgical procedure; potential complications and their prevention.

Practical objectives (to be able to):

6. Show the temporal superficial and maxillary arteries; facial and auriculotemporal nerves; the parotid duct and masseter muscle on anatomical specimens and other illustrative guides.
7. Prepare a kit of instruments for the surgical management of purulent conditions of the face.

Glossary

Parotidomasseteric region is outlined by the anterior margin of the masseter muscle *anteriorly*; base of the mandible *inferiorly*; imaginary line drawn from the angle of the mandible to the apex of the mastoid process *posteriorly*; and zygomatic arch *superiorly*.

Parotid fascia is the investing layer of deep cervical fascia which splits to enclose the parotid gland. It is fused to zygoma superiorly and to the acoustic meatus and anterior border of the sternocleidomastoid muscle posteriorly. The parotid fascia gives numerous septae passing along the lobules of glandular tissue. The superficial facial layer is very thick and strong. Infections of parotid gland cannot pierce through that layer; they progress medially instead where the lateral pharyngeal space is easily accessible.

Masseteric fascia is a strong layer derived from the deep cervical fascia. It covers the masseter muscle, is firmly connected to it, and is attached to the lower border of the zygomatic arch.

Parotid gland is a salivary gland located behind (*deep part*) and on (*superficial part*) the mandibular ramus. Two parts of the gland are separated by the facial nerve branches

Parotid duct (also called Stensen Duct) is 5 cm long. It arises from the anterior part of the gland, runs finger thick over the masseter muscle below the zygomatic arch; pierces the buccinator muscle and opens at a crown level of the second upper molar tooth.

Masseter muscle arises in two parts. The superficial part starts from the anterior two-thirds of the zygomatic arch while the deep part starts from the zygomatic arch close to the temporomandibular joint and its discocapsular system. The muscle inserts into the angle of the mandible. It is innervated by the mandibular nerve.

Submasseteric space is situated between the masseter muscle and mandible. It contains the masseteric artery and nerve and continues superiorly to the zygomatic arch on the superficial surface of the temporal muscle (subaponeurotic space). The space also communicates around vessels with spaces of the deep facial region.

Temporomandibular joint is formed by the *condylar process* of the mandible and the *articular fossa* and *articular eminence* of the temporal bone. The articular surfaces are covered with fibrous (*not* hyaline) cartilage. The fibrocartilaginous *articular disc* divides the joint cavity into the upper and lower compartments. The capsule surrounding the joint is reinforced by a lateral *temporomandibular ligament* and by the *sphenomandibular ligament*. The mandible can be depressed, elevated, protruded, retracted and moved from side to side.

Retromandibular (posterior facial) vein is formed by the junction of the superficial temporal and maxillary veins. It joins with the facial vein and drains into the internal jugular vein.

External carotid plexus is an autonomic nerve plexus around the external carotid artery and its branches. It contains the postganglionic sympathetic fibers arising from the superior cervical ganglion and supplying the parotid, submandibular and sublingual glands.

Auriculotemporal nerve is a branch of the mandibular nerve (CN V₃). It begins by two rootlets that envelop a middle meningeal artery, and then unite into one trunk, which transfixes parotid gland, innervating it as well as the skin of temporal area and auricle. Postganglionic parasympathetic fibres from the *otic ganglion* pass along with of this nerve.

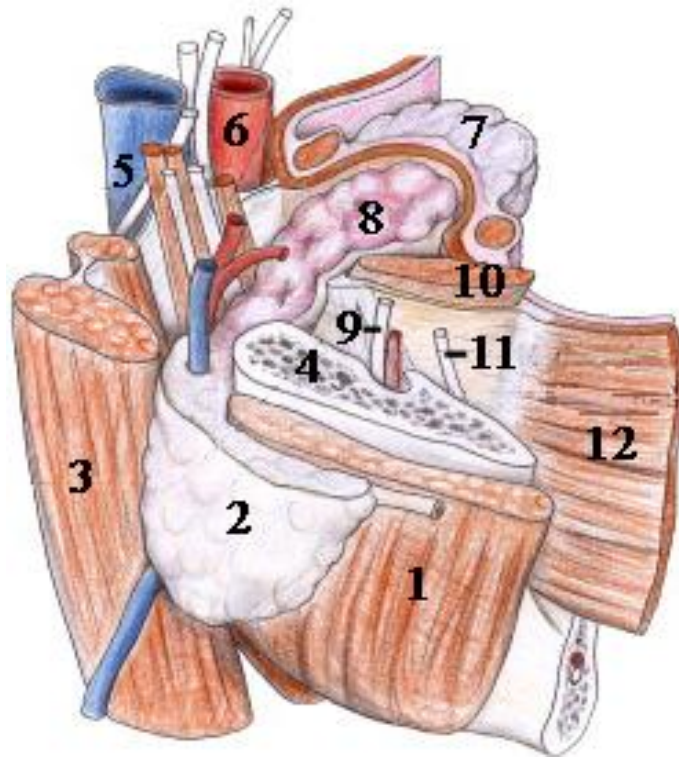
Otic ganglion is located medially to the mandibular nerve below the foramen ovale. It receives preganglionic parasympathetic fibres from the glossopharyngeal nerve via the lesser petrosal nerve. Its postganglionic, parasympathetic fibers are distributed to the parotid gland

Self-evaluation questions:

1. Which three important anatomical structures run through the parotid gland on each side (from superficial to deep)? _____
 2. Where is the parotid duct opening located? _____
 3. Which nerves innervate the parotid gland? _____
 4. Does the parotid duct pass superficially or deeper to the masseter muscle? _____
 5. Which anatomical structures separate the parotid gland from the ICA, IJV, and IX–XII?

 6. The retromandibular vein is formed by _____
 7. Which sensory nerve innervates the TMJ? _____
 8. The masseter muscle is innervated by the _____ branch of the trigeminal nerve.
 9. What muscle elevates the mandible and closes the mouth? _____
 10. Describe all possible movements of the mandible. _____
 11. How the temporomandibular joint range of motion is usually assessed? _____
-

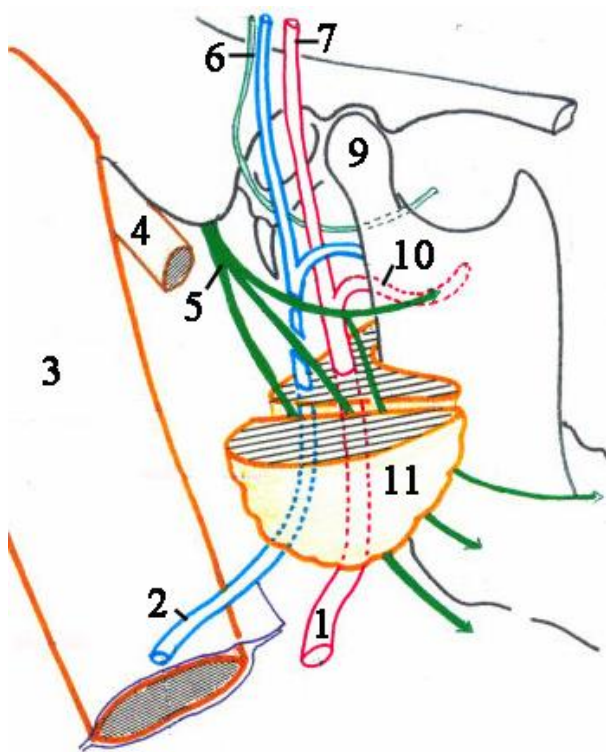
Self-instructional materials



Parotid gland topography (right side). Name the structures labeled on the diagram:

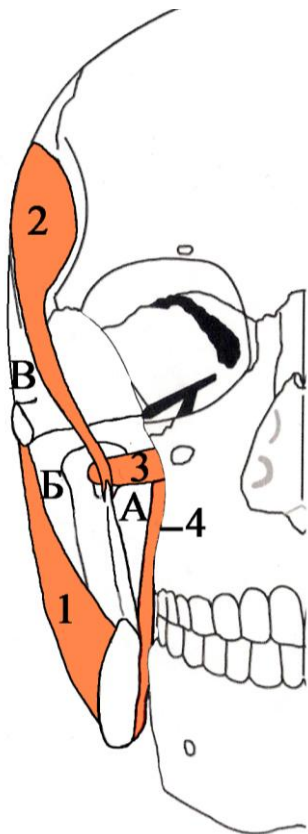
- 1 — _____ muscle
- 2 — _____ part of the _____ gland
- 3 — _____ muscle
- 4 — Mandible
- 5 — _____ vein
- 6 — _____ artery
- 7 — Palatine tonsil
- 8 — _____ part of the _____ gland
- 9 — _____ nerve and artery
- 10 — _____ muscle
- 11 — _____ nerve
- 12 — _____ muscle

Vessels and nerves that traverse the parotid gland (right side). Name the structures labeled on the diagram:



- 1 — _____ artery
- 2 — _____ vein
- 3 — Sternocleidomastoid muscle
- 4 — Venter posterior of digastric muscle
- 5 — _____ nerve
- 6 — _____ nerve
- 7 — _____ artery
- 8 — Condylar process of mandible
- 9 — _____ artery
- 10 — _____ part
of the _____ gland

Fascial spaces of the head. Name the structures labeled on the diagram:



- 1 — _____ muscle
- 2 — _____ muscle
- 3 — _____ muscle
- 4 — _____ muscle
- A — The deep facial region (_____ space)
- B — _____ space
- B — _____ space

CLINICAL ANATOMY OF THE HEAD

LAB N 17: TOPOGRAPHY OF THE DEEP FACIAL REGION

Theoretical objectives (to know):

1. Deep facial region: boundaries; location, contents, and communications of the deep temporal, infratemporal, and pterygomandibular spaces.
2. Pterygopalatine fossa: boundaries, passages, contents.
3. Anatomical structures of the deep facial region.
4. Lateral and medial pterygoid muscles: origin and insertion; actions; blood supply and innervation.
5. Maxillary artery: parts, and topography; branches and supplied anatomical structures.
6. Topography of the maxillary nerve and its branches. Superior dental plexus.
7. Topography of the mandibular nerve and its branches. Inferior dental plexus.
8. Lateral pharyngeal and retropharyngeal spaces: location and communication with another fascial spaces of the head and neck.
9. Most common sources of deep facial region spaces infections. Potential pathways of infection spread.

Practical objectives (to be able to):

1. Demonstrate the maxillary, inferior alveolar, and meningeal arteries; the inferior alveolar, buccal, lingual, and auriculotemporal nerves; the lateral and medial pterygoid muscles in anatomical specimens and other illustrative guides.
2. Fabricate a clay model of the deep facial region spaces.

Glossary

Deep facial region is bounded *superiorly* by the great wing of the sphenoid bone; *anteriorly* by the tuber maxillae; *laterally* by the ramus of mandible; *posteriorly* by the styloid process of the temporal bone; and *medially* by the lateral pterygoid plate of the sphenoid bone and the superior constrictor of the pharynx.

Deep temporal space has the inner surface of temporal muscle as its lateral boundary and the temporal bone as its medial boundary. The inferior portion of this space is called the *infratemporal space*. It is located posteriorly to the maxilla, between the lateral pterygoid plate of the sphenoid bone medially and the base of skull superiorly. The deep temporal space is separated from the pterygomandibular space by the lateral pterygoid muscle. The infratemporal space contains the second part of maxillary artery and mandibular nerve.

Pterygomandibular space is located between the medial pterygoid muscle and the medial surface of the mandibular ramus. In health, the space contains the inferior alveolar vessels; inferior alveolar and lingual nerves, chorda tympani; and sphenomandibular ligament.

Lateral pharyngeal space is shaped like an inverted pyramid, with the skull base superiorly, and the greater horns of the hyoid bone (the apex), inferiorly. The medial wall of this space is made of the pharynx and buccopharyngeal fascia. The lateral pharyngeal space is bordered *anteriorly* by the pterygomandibular raphe; *posteriorly* — by the paravertebral layer of the deep cervical fascia; *laterally* — by the parotid gland, medial pterygoid muscle fascia, and fascia of the posterior belly of digastric muscle. The parapharyngeal space is divided into 2 compartments. Prestyloid compartment contents the deep part of the parotid gland; CN V branch heading to the tensor veli palatini muscle, ascending pharyngeal artery and venous plexus. Poststyloid compartment contains the internal carotid artery; internal jugular vein; CN IX to XII; and cervical sympathetic chain.

Retropharyngeal space is bounded anteriorly by the buccopharyngeal fascia and posteriorly by the prevertebral fascia. Together with the lateral pharyngeal space, it forms the parapharyngeal spaces. Retropharyngeal space contains the retropharyngeal lymph nodes.

Pterygopalatine fossa is a cone-shaped depression deep to the infratemporal fossa. It has the following boundaries: *anterior* is the infratemporal surface of maxilla; *posterior* — the root of the pterygoid process of sphenoid bone; *medial* — the perpendicular plate of the palatine bone. It contains the pterygopalatine ganglion; terminal third of the maxillary artery; and maxillary nerve.

Lateral pterygoid is a muscle of mastication. It lies superiorly to the medial pterygoid and originates on the greater wing of the sphenoid bone, and the lateral surface of the lateral pterygoid plate. The muscle inserts onto the neck of condyloid process of the mandible; the articular disc and fibrous capsule of the temporomandibular joint.

Medial pterygoid muscle originates from the tuberosity of the maxilla, lateral pterygoid plate and pterygoid fossa. It inserts into the medial surface of the angle of the mandible.

Maxillary nerve is the second division of the trigeminal nerve. It enters pterygopalatine fossa through the oval foramen. The main branches are: the *infraorbital*, *zygomatic*, *greater* and *lesser palatine*, *superior alveolar nerves*; and *posterior superior lateral* and *medial nasal branches*.

Pterygopalatine ganglion is a parasympathetic ganglion located in the corresponding fossa close to the sphenopalatine foramen. Its postganglionic fibers innervate the lacrimal and nasal glands as well as minor salivary glands.

Mandibular nerve is the third division of the trigeminal nerve. The motor portion of the nerve supplies the masticatory muscles. The sensory portion supplies the salivary glands, anterior portions of the tongue, gingiva, mandibular teeth, and skin of the lower third of the face. The nerve contains the anterior and posterior trunks. The anterior trunk branches are: the buccal nerve, masseteric nerve, deep temporal nerves, and nerve to the lateral pterygoid. The posterior trunk branches are auriculotemporal, lingual, and inferior alveolar nerves. Other branches of the mandibular nerve are the meningeal nerve and nerve to the medial pterygoid muscle.

Self-evaluation questions:

1. What other spaces does the pterygomandibular space communicate with? _____

2. Where does an infection of the pterygomandibular space originate from? _____

3. Where does V3 enter the infratemporal fossa? _____

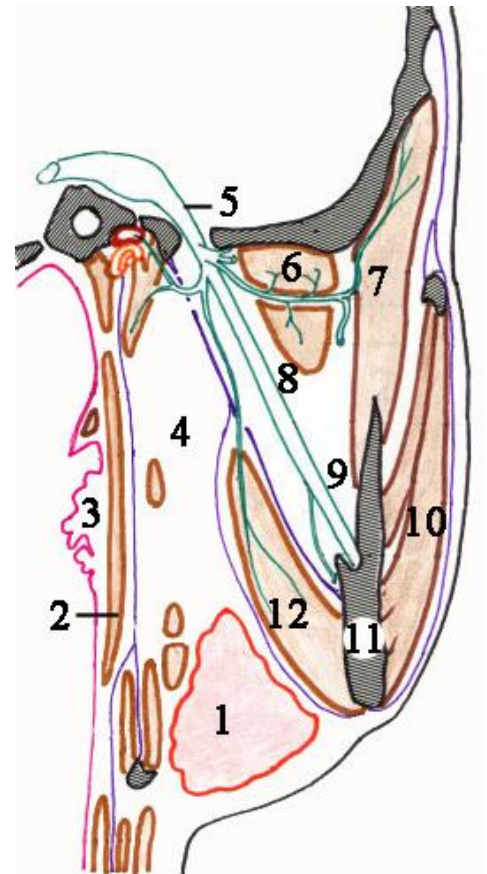
4. Where does the maxillary artery enter the infratemporal fossa? _____

5. Which fibers pass along the initial segment of the auriculotemporal nerve? _____

Self-instructional materials

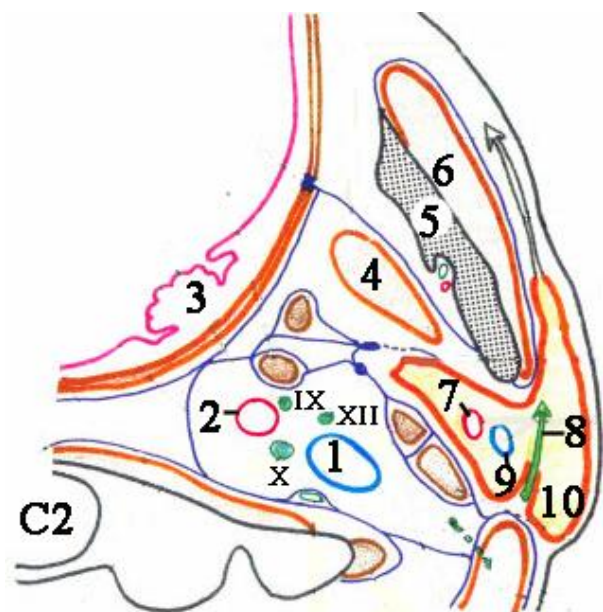
Topography of the deep facial region (frontal section of the head). Name the structures labeled on the diagram:

- 1 — Submandibular gland
- 2 — Superior constrictor of the pharynx
- 3 — _____ tonsile
- 4 — _____ space
- 5 — _____ nerve
- 6 — _____ muscle
- 7 — _____ muscle
- 8 — _____ space
- 9 — _____ space
- 10 — _____ muscle
- 11 — Mandible
- 12 — _____ muscle

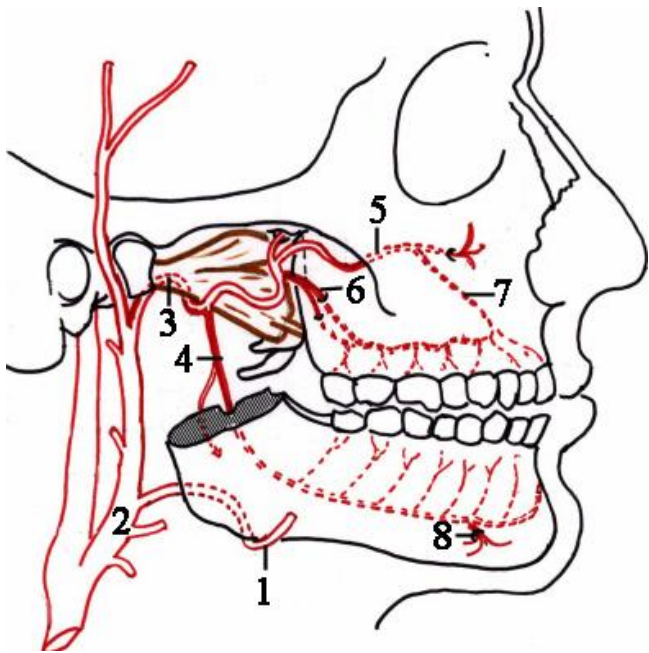


Topography of the deep facial region (horizontal section of the head). Name the structures labeled on the diagram:

- 1 — _____ vein
- 2 — _____ artery
- 3 — Pharynx
- 4 — _____ muscle
- 5 — Mandible
- 6 — _____ muscle
- 7 — _____ artery
- 8 — _____ nerve
- 9 — _____ vein
- 10 — Parotid gland

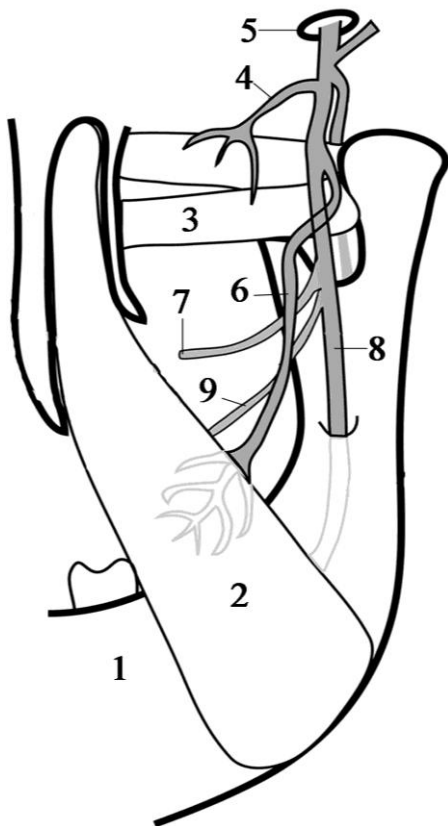


The deep facial region: the maxillary artery. Name the structures labeled on the diagram:



- 1 — _____ artery
- 2 — _____ artery
- 3 — _____ artery
- 4 — _____ artery
- 5 — _____ artery
- 6 — _____ artery
- 7 — _____ artery
- 8 — _____ of the inferior alveolar artery

Topography of the mandibular nerve (back view). Name the structures labeled on the diagram:



- 1 — Mandible
- 2 — _____ muscle
- 3 — _____ muscle
- 4 — _____ nerve
- 5 — Oval foramen
- 6 — _____ nerve
- 7 — Buccal nerve
- 8 — _____ nerve
- 9 — _____ nerve

CLINICAL ANATOMY OF THE HEAD

LAB N 18: ORBITAL REGION: EYEBALL; CRANIAL NERVES OF ORBIT; OPHTHALMIC ARTERY AND VEINS

Theoretical objectives (to know):

1. Anatomy of bony orbit.
2. Orbital foramina and openings; their contents.
3. Eyeball anatomy: fibrous, vascular and inner layers.
4. Optic nerve (CN II): anatomy, visual tract.
5. Refractory media of the eye: lens and vitreous body. Eyeball chambers. Aqueous humor production and drainage.
6. Extra-ocular muscles: origins and insertions; functions; blood supply and innervation.
7. Eyelid anatomy: layers; blood supply and innervation.
8. Lacrimal apparatus: anatomy of the lacrimal gland, lake, papilla, and sac; the nasolacrimal duct.
9. Ophthalmic nerve (CN V₁): path and branch distribution.
10. Ophthalmic artery: course, branches and supplied structures.
11. Ophthalmic veins: topography; anastomosis with the facial vein. Pterygoid venous plexus.
12. Accessory visual structures: fascial sheath of eyeball; episcleral space; retrobulbar fat and periorbita.
13. Cranial nerves of orbit: symptoms of nerve injuries.

Practical objectives (to be able to):

1. Demonstrate the optical (CN II), oculomotor (CN III), abducent (CN IV), ophthalmic (CN V₁), frontal, lacrimal, nasociliary, and abducent (CNVI) nerves in anatomical specimens and other illustrative guides.
2. Find layers and chambers of the eyeball; the lens; and extra-ocular muscles on the anatomical eye model.
3. Show orbital foramina and openings on the skull.

Glossary

Orbit is a conical or four-sided pyramidal cavity, which opens on the middle third of the face and points its apex back into the head. It consists of the base, apex and four walls. The *superior wall* separates the orbital cavity from the anterior cranial fossa; the *inferior wall* — from the maxillary sinus, the *medial wall* — from the nasal cavity, and the *lateral wall* — from the infratemporal fossa.

Eyelid is a thin fold of skin that covers and protects the eyeball. It is made of several layers. These are (from superficial to deep): the skin, subcutaneous tissue, orbicularis oculi muscle, orbital septum and tarsal plates, and palpebral conjunctiva.

Fascial sheath of an eyeball (capsule of Ténon) is a thin membrane which envelops the eyeball from the optic nerve to the corneoscleral junction, separating it from the orbital fat and forming a socket in which it moves.

Retrobulbar fat (orbital fat body) fills the space around the eye, extra-ocular muscles, nerves, blood vessels, and lacrimal gland.

Episcleral space is a gliding space between the fascial sheath of an eyeball and the eyeball. It is traversed by long, delicate connective tissue fibers.

Extraocular muscles are those seven (the rectus superior, inferior, lateral and medial muscles; the superior and inferior oblique muscles; the levator palpebrae superioris muscle) controlling movements of the eye and superior eyelid

Intrinsic muscles of eyeball are the dilatator, sphincter pupillae, and ciliary muscle. The sphincter pupillae muscle is located in the posterior part of the iris, near the pupil, and consists of smooth muscle cells. Its contraction results in the pupil constriction (miosis). The dilator pupillae muscle also consists of smooth muscle cells. Its contraction results in the pupil dilatation (mydriasis). The ciliary muscle is a ring of smooth muscle fibers in the vascular layer that controls the accommodation for viewing objects at varying distances.

Ophthalmic artery is the first branch of the internal carotid artery located distally to the cavernous sinus. Its branches supply all the structures in the orbit as well as some areas of the nose, face and meninges.

Ophthalmic nerve (V₁) is one of the three branches of the trigeminal nerve. It supplies sensory branches to the ciliary body, cornea, and iris; lacrimal gland and conjunctiva; portions of the mucous membrane of the nasal cavity, sphenoidal and frontal sinuses; skin of the eyebrow, eyelids, forehead, and nose; tentorium cerebelli, dura mater, and posterior area of the falx cerebri.

Ciliary ganglion is a parasympathetic ganglion located in the posterior orbit. *Preganglionic* fibres travel along with the oculomotor nerve and form synapses there. The *postganglionic* fibres run within the short ciliary nerves and innervate ciliaris and sphincter pupillae muscles

Self-evaluation questions:

1. The Superior wall of the orbit is formed by: _____

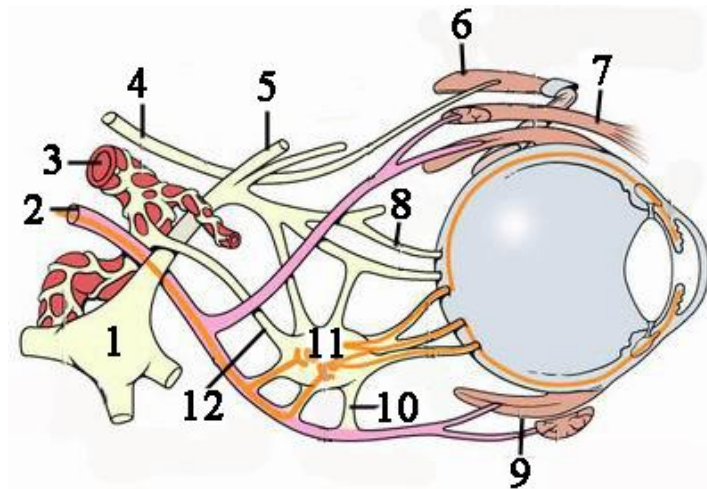
2. The lateral wall of orbit is formed by: _____

3. Connective tissue plates, forming the “skeleton” of the lids, are called _____
4. The lacrimal gland is stimulated by: _____
5. Which are the sources of extraocular muscles innervation other than CN III? _____

6. The largest branch of the ophthalmic division of CN V is _____
7. The ophthalmic artery enters the orbit through the _____
8. The nerve that carries preganglionic parasympathetic fibers to the smooth muscles of the eyeball inside the orbit is the _____ nerve
9. The venous drainage from the eye is maintained via _____

10. The actions of the inferior oblique muscle are _____

Self-instructional materials

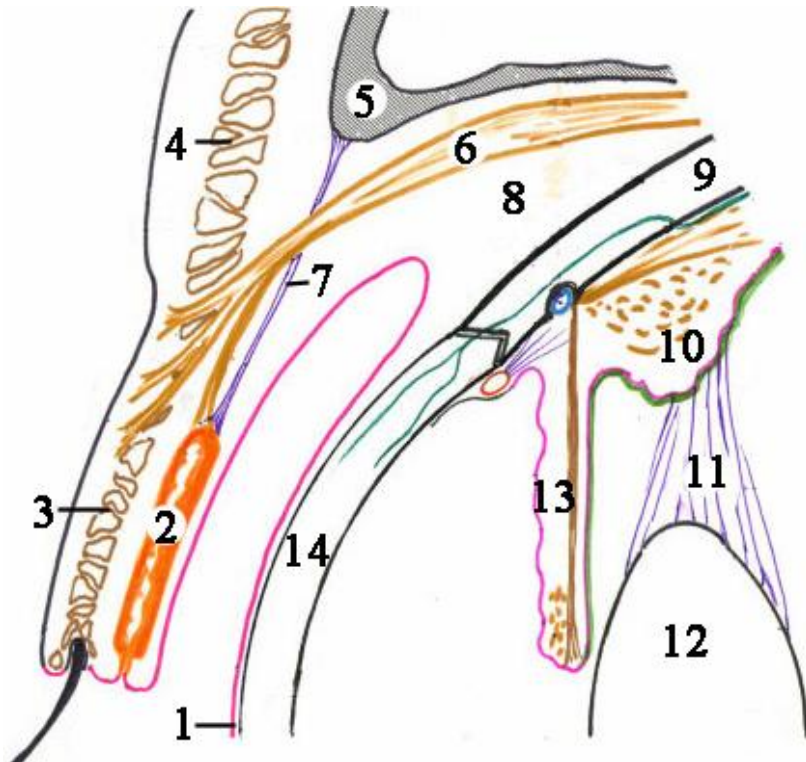


Cranial nerves of the orbit. Name the structures labeled on the diagram:

- | | |
|-----------------------------|----------------------------|
| 1 — Trigeminal ganglion | 7 — _____ muscle |
| 2 — _____ nerve | 8 — _____ nerves |
| 3 — _____ artery | 9 — Inferior rectus muscle |
| 4 — _____ nerve | 10 — _____ root |
| 5 — _____ nerve | 11 — _____ ganglion |
| 6 — Superior oblique muscle | 12 — _____ root |

Orbital foramina and openings

Foramens, canals, fissures	Connects to	Contents
Nasolacrimal canal Anterior and posterior ethmoidal foramina		
Infraorbital foramen		
Zygomatico-orbital foramen		
Superior orbital fissure Optic canal		
Inferior orbital fissure		



Layer-by-layer morphology of the superior eyelid. Name the structures labeled on the diagram:

- 1 — _____
- 2 — _____
- 3 — _____
- 4 — _____
- 5 — Frontal bone
- 6 — _____
- 7 — _____
- 8 — _____
- 9 — _____
- 10 — _____
- 11 — _____
- 12 — _____
- 13 — _____
- 14 — _____

CLINICAL ANATOMY OF THE HEAD

LAB N 19: NASAL REGION: ANATOMY OF THE NOSE AND NASAL CAVITY. TOPOGRAPHY OF THE PARANASAL SINUSES

Theoretical objectives (to know):

1. Boundaries of the nasal region and anatomy of the external part of the nose: bone and cartilage; soft tissues; blood supply and drainage; innervation.
2. Lateral, medial, superior and inferior walls of the nasal cavity: bony components.
3. Nasal conches and meatuses: location and communications. Nasolacrimal canal.
4. Nasal mucosa: blood supply and lymphatic drainage. Kiesselbach's plexus: anatomical localization and significance.
5. Nasal mucosa: general sensory, parasympathetic and sympathetic innervation. Nasal olfactory region: localization; smell pathway.
6. Paranasal sinuses: development; anatomical location; connections and clinical significance; neurovascular supply.
7. Relationship between the maxillary sinus floor and maxillary posterior teeth roots.
8. Anterior and posterior nasal packing.

Practical objectives (to be able to):

1. Find the olfactory (CN I), and nasociliary nerves; nasal conches and nasal meatuses; structural components of bony walls of the nasal cavity; paranasal sinuses in anatomical specimens and other illustrative guides.
2. Perform the nasal packing on the artificial skull.

Glossary

Nasal cavity is a large paired air filled space in the middle of the face. Each cavity is the continuation of the nostril and is separated from the contralateral one by the nasal septum. They blend via the choanae into the nasopharynx in the back. The floor of the nasal cavity forms the roof of the mouth; the superior wall separates it from the anterior cranial fossa; the lateral wall — from the orbit.

External nose consists of the root (between the eyes), the dorsum that run down to the middle, and the apex at the tip of the nose. Two openings called nares allows air in. The parts that surround the nostrils are called alae.

Angular artery is the terminal part of the facial artery. It ascends to the medial angle of the orbit, accompanied by the angular vein and ends by anastomosing with the dorsal nasal branch of the ophthalmic artery.

Nasal vestibule is the pear-shaped cavity that lies directly behind the nostrils. It is separated from the respiratory region by a curved ridge known as the limen nasi. The lumen of the nasal vestibule is lined with the skin and contains short brush-like hairs that act as filters to stop dust particles and pollutants passing into the respiratory system.

Nasal conchae are three curved shelves which are situated one above the other and project medially and inferiorly across the nasal cavity. The medial, anterior, and posterior margins of the conchae are free. The superior and middle nasal conchae are portions of the ethmoid bone and the inferior nasal concha is a separate bone of the facial skeleton.

Nasal meatus is any of four passages in the nasal cavity formed by the projection of the conchae. *Inferior nasal meatus* lies below the inferior concha; *middle nasal meatus* — between the middle and inferior conchae; *superior nasal meatus* — between the superior and middle conchae.

Innervation of the nasal cavities is given by three cranial nerves. *Olfaction* is carried by the olfactory nerve [CN I]; *general sensation* of the anterior region is carried by the ophthalmic nerve (CN V₁), and the posterior region is supplied by the maxillary nerve [V₂]. All glands are innervated by parasympathetic fibers passing along the facial nerve [VII] (greater petrosal nerve), which join with branches of the maxillary nerve [V₂] in the pterygopalatine fossa. Sympathetic fibers are derived from the T1 spinal cord level. They synapse mainly in the superior cervical sympathetic ganglion, and postganglionic fibers reach the nasal cavities along blood vessels, or by joining branches of the maxillary nerve [V₂] in the pterygopalatine fossa.

Blood supply to the nasal cavities is given by terminal branches of the *maxillary* and *facial arteries*, which originate from the external carotid artery; and from ethmoidal branches of the *ophthalmic artery*, which originates from the internal carotid artery.

Kiesselbach's plexus is a region in the anteroinferior part of the nasal septum where four arteries anastomose. These arteries are: the *anterior ethmoidal artery* (from the ophthalmic artery); *sphenopalatine artery* (terminal branch of the maxillary artery); *greater palatine artery* (from the maxillary artery); septal branch of the *superior labial artery* (from the facial artery). Ninety percent of nose bleedings (epistaxis) occur in this area.

Self-evaluation questions:

1. Where does the maxillary sinus drain into? _____

2. What are the two parts of the nasal mucosa? What parts of the nose do they cover?

3. The palatine process of maxilla and horizontal plate of palatine bone form the: _____

4. The superior and middle conchae are parts of the _____ bone.

5. The main arteries of the nose are: _____

6. Which two cranial nerves give nerve supply to the nasal cavity? _____

7. Which nerves supply to the maxillary sinus? _____

8. Why do you need to be careful in removing maxillary molar teeth? _____

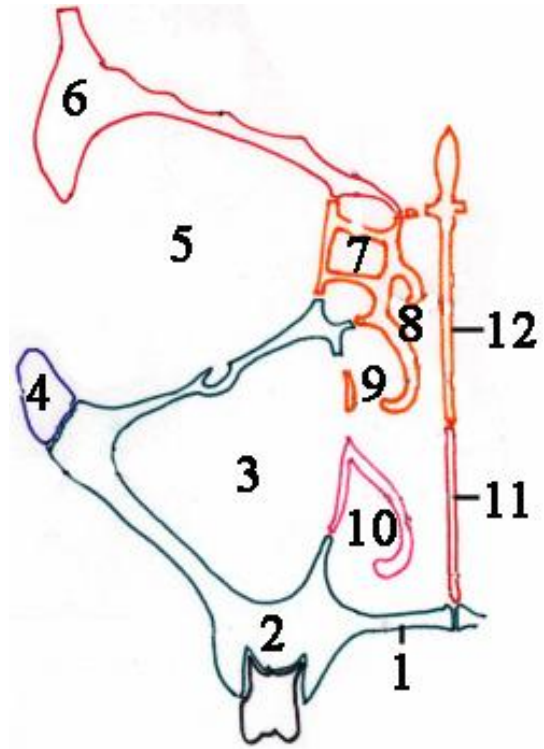
9. Why is it difficult to differentiate between a toothache and sinus infection? _____

10. Where does the nasolacrimal duct open into inside the nasal cavity? _____

Self-instructional materials

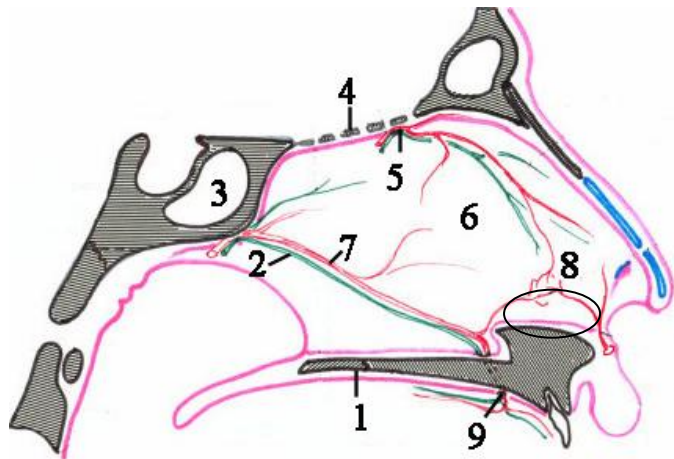
Nasal cavity (frontal section if the head). Name the structures labeled on the diagram:

- 1 — _____
- 2 — _____
- 3 — _____ sinus
- 4 — _____ bone
- 5 — _____
- 6 — _____ bone
- 7 — _____
- 8 — _____ meatus
- 9 — _____ meatus
- 10 — _____ meatus
- 11 — _____
- 12 — _____ plate
- _____ bone

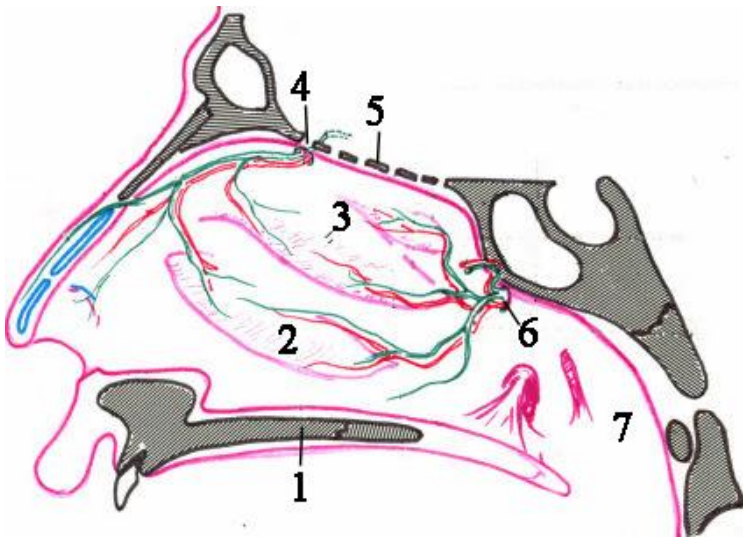


The medial wall of the nasal cavity: blood and nerve supply. Name the structures labeled on the diagram:

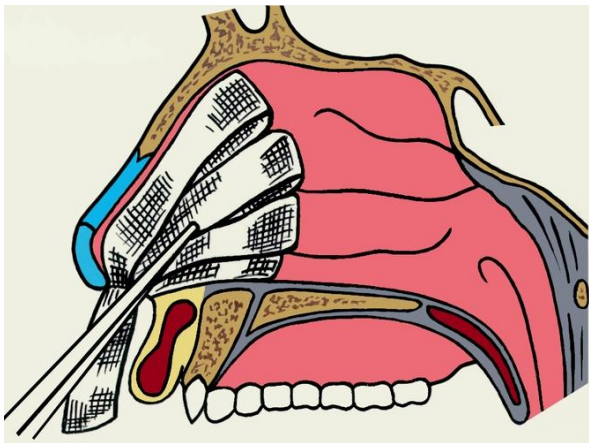
- 1 — _____
- 2 — _____ nerve
- 3 — _____ sinus
- 4 — _____
- 5 — _____ artery
- and nerve
- 6 — Nasal septum
- 7 — _____ branches
- of _____ artery
- 8 — Kisselbach's plexus area
- 9 — _____ canal



The lateral wall of the nasal cavity: blood and nerve supply. Name the structures labeled on the diagram:



- 1 — _____
- 2 — _____ concha
- 3 — _____ concha
- 4 — _____ artery
and nerve
- 5 — _____ plate
- 6 — _____ artery
and _____ branches
- 7 — Nasopharynx

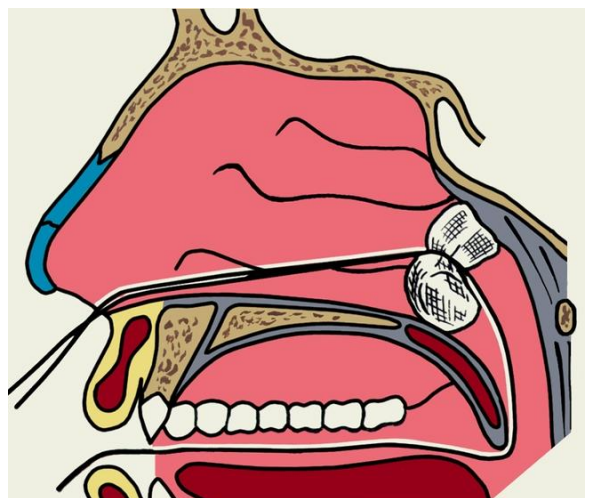


A

Management of a massive nasal bleeding:

A — _____

B — _____



B

CLINICAL ANATOMY OF THE HEAD

LAB N 20: TOPOGRAPHIC ANATOMY OF THE FRONTAL, PARIETAL AND OCIPITAL REGIONS OF THE HEAD

Theoretical objectives (to know):

1. Head divisions (compartments): cranium and face. Regions of the cranium.
2. Surface anatomy of the superficial temporal and occipital arteries; supraorbital, auriculotemporal, great and lesser occipital nerves.
3. Boundaries and layers of the scalp.
4. Blood and nerve supply to the scalp. Anatomical landmarks for the local anesthesia on the scalp.
5. Occipitofrontalis muscle: course and action; blood supply and innervation.
6. Scalp hematomas: locations, and types (subcutaneous, subgaleal, and subperiosteal hematoma).
7. Morphology of cranium flat bones: cortical plates (the outer and inner table) and diploe. Cranial sutures.
8. Meninges: pachymeninx and leptomeninx; subdural and subarachnoid space.
9. Cerebrospinal fluid: production and circulation. Hydrocephalus.
10. Communications between the dural venous sinuses and veins of the scalp: diploic and emissary veins.

Practical objectives (to be able to):

1. Demonstrate the supraorbital, auriculotemporal, greater and lesser occipital nerves; superficial temporal, occipital and middle meningeal arteries; dural venous sinuses in anatomical specimens and other illustrative guides.
2. Identify the zygomatic arch, external occipital protuberance and superior nuchal line in a living person.

Glossary

Scalp extends from the external occipital protuberance and superior nuchal line to the supra-orbital margins. The scalp consists of five layers: the skin, dense connective tissue, epicranial aponeurosis, loose areolar tissue, and pericranium. The first three layers are bound together as a single unit. This unit can move along the loose areolar tissue over the pericranium, which is adherent to the calvaria.

Occipitofrontalis covers the skull vault and consists of two bellies. The occipital belly originates from the superior nuchal line and mastoid process and fuses with the galea aponeurotica. The occipital belly originates from the aponeurosis and inserts in the skin above the eyes and nose.

Subaponeurotic space is the potential space beneath the epicranial aponeurosis. It is limited anteriorly and posteriorly by the origins of the occipitofrontalis muscle, and extends laterally as far as the attachment of the aponeurosis to the temporal fascia does.

Subperiosteal space is created when the periosteum of the outer table becomes detached from calvaria in the cephalohematoma. Hematoma is limited by the skull sutures, and generally it does not cross suture lines.

Diploic veins are found in the bones of the vault of the skull, and drain the diploic space — the marrow-containing area of cancellous bone between the inner and outer layers of compact bone. They communicate with the meningeal veins and sinuses of the dura mater, as well as veins of the pericranium.

Emissary veins are venous connections between a venous sinus, diploic veins and superficial cranial veins. They form an important route for an infection spread.

Subdural space is a potential space that can be opened by the separation of the arachnoid mater from the dura mater as the result of a trauma or pathological conditions.

Dural venous sinuses are devoid of valves. Venous channels are found between layers of the dura mater in the upper and distal part and at the base of the skull. They receive blood from internal and external veins of the brain, ophthalmic veins, and cerebrospinal fluid from the subarachnoid space, and eventually drain into the internal jugular vein.

Arachnoid granulations are small protrusions of the arachnoid through the dura mater. They protrude into the venous sinuses of the brain, and allow cerebrospinal fluid to leave the subarachnoid space and enter the blood stream.

Subarachnoid space is the anatomic space between the arachnoid membrane and pia mater. It is filled by a spongy tissue consisting of delicate connective tissue filaments which extend from the arachnoid mater and blend into the pia mater and intercommunicating channels with the cerebrospinal fluid inside.

Self-evaluation questions:

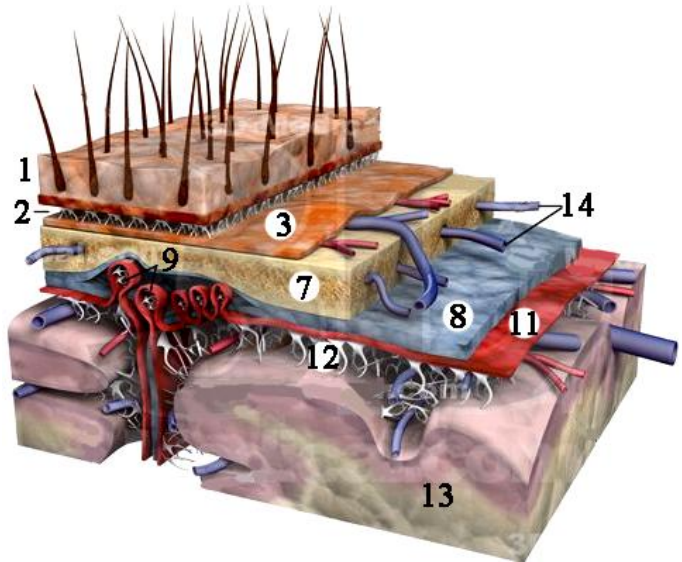
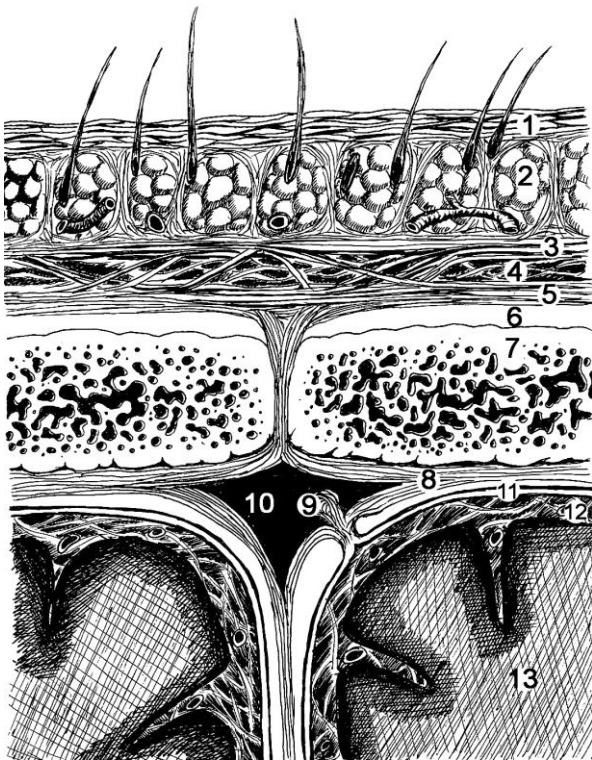
1. The anterior part of the scalp is supplied by branches of the supraorbital and _____ arteries.
2. What layer of the scalp allows infections to spread into the bone or inside cranial vault via the emissary veins? _____
3. Which layer of the scalp allows infections to spread through quickly? _____
4. What layer of the scalp is highly vascularized and keeps the blood vessels open if injured?

5. Name the vault bones. _____
6. What bones are joined by the lamboid suture join? _____
7. What is the only paired vault bone that doesn't contribute to the cranial base? _____

8. Where is the subarachnoid space located? What is this space filled with? _____

9. What is a subdural haematoma? _____
10. What «structures» do the venous sinuses of the cranial cavity drain blood from? (3)

Self-instructional materials



Layers of the scalp (diagrammatic coronal section of the head). Name the structures labeled on the diagram:

- 1 — _____
- 2 — _____
- 3 — _____
- 4 — _____ space
- 5 — _____
- 6 — _____ space
- 7 — Parietal bone
- 8 — Cranial _____
- 9 — _____
- 10 — _____ sinus
- 11 — _____
- 12 — _____ space
- 13 — _____
- 14 — _____ veins

CLINICAL AND SURGICAL ANATOMY OF THE HEAD

LAB N 21: TOPOGRAPHICAL ANATOMY OF THE TEMPORAL AND MASTOID REGIONS. HEAD SURGERY: MANAGEMENT OF SCALP LACERATIONS AND THE SURGICAL ACCESS FOR EPIDURAL AND SUBDURAL GEMATOMAS TREATMENT

Theoretical objectives (to know):

1. Temporal region: boundaries and layers.
2. Temporal muscle: course and action; blood supply and innervation.
3. Bony framework of the temporal fossa. Squamous part of the temporal bone: anatomical characteristics.
4. Fascial spaces of the temporal region.
5. Mastoid region: boundaries and layers.
6. Suprameatal triangle: boundaries. Relations of its anteroinferior, superior and posterior borders with the floor of the middle cranial fossa, facial nerve canal, and sigmoid sinus.
7. Scalp laceration: assessment, wound management, types of sutures.
8. Indications for the surgical craniotomy.
9. Epidural hematoma: causes; location and most common origin of bleeding.
10. Topography of the middle meningeal artery.
11. Osteoplastic craniotomy: surgical technique.
12. Bleeding control in dural sinus injuries.

Practical objectives (to be able to):

1. Use the surgical instruments for bones.
2. Legate around a hemostatic clamp.

Glossary

Temporal region is outlined by the temporal line, frontal process of the zygomatic bone, and zygomatic arch. Beyond the arch it communicates with the infratemporal fossa.

Temporal muscle is the fan-shaped muscle arising from the floor of the temporal fossa. Its tendon passes deep to the zygomatic arch to reach the coronoid process of the mandible. It is supplied by deep temporal branches of the mandibular nerve. The muscle elevates the mandible, and its posterior fibers pull the head of the mandible posteriorly into the mandibular fossa during the mouth closure.

Temporal fascia is a strong, fibrous investment covering the temporal muscle. The upper part is a single layer, attached to the entire extent of the superior temporal line. The lower part which is fixed to the zygomatic arch, consists of two layers: one is inserted into the lateral, and the other — into the medial edge of the arch.

Pterion is situated approximately 3 cm behind and slightly above the level of the zygomatic process of the frontal bone. It marks the junction of three bones: the parietal bone, squamous part of temporal bone, and greater wing of sphenoid bone. The pterion is known as the weakest part of the skull.

Mastoid process is the rounded bone projection behind the ear. It is pneumatized with the mastoid air cells. These hollow air cells form connections with the middle ear via the mastoid antrum. The external surface of the bone provides attachment to the posterior belly of the occipitofrontalis muscle, posterior auricular, longissimus capitis, splenius capitis, and sternocleidomastoid muscles.

Craniotomy is a surgical operation in which a bone flap is temporarily removed from the skull to access the brain and meninges. Craniotomy is distinguished from *craniectomy* in which the skull flap is not immediately replaced, allowing the brain to swell, thus reducing intracranial pressure and *trepation*, the creation of a burr hole through the cranium in to the dura mater.

Epidural hematoma is an accumulation of blood in the potential space between cranial dura mater and bone. The majority of bleedings originate from meningeal arteries, particularly in the temporal region (only 20 to 30% of epidural hematomas occur outside this region) Around ten percent of epidural bleedings are venous

Middle meningeal artery is the branch of the first part of the maxillary artery. It runs through the foramen spinosum to supply the cranial dura mater and the calvaria. An injured middle meningeal artery is usually a cause of an epidural hematoma.

Self-evaluation questions:

1. Middle meningeal artery goes to _____
2. All the muscles of mastication are supplied by the _____ division of the trigeminal nerve.
3. The _____, a surgical landmark of the mastoid antrum, is made of the _____ spine and _____ crest.
4. Mastoid air cells communicate with the middle ear through the _____
5. Because of the scalp's rich blood supply, one likely result of a scalp injury is _____

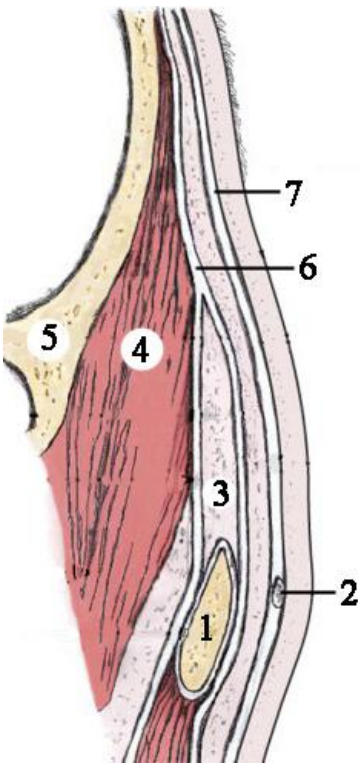
6. The most likely source of blood in a patient with an epidural hemorrhage is: _____

7. What is the optimal time between a scalp injury and laceration repair. _____

8. What is the timeframe to remove sutures from scalp wounds? _____

Self-instructional materials

Topography of the temporal region (coronal section of the head). Name the structures labeled on the diagram:



- 1 — _____ bone
- 2 — Zygomatic branch of the facial nerve
- 3 — _____ space
- 4 — _____ muscle
- 5 — Sphenoidal bone
- 6 — _____ fascia
- 7 — _____ fascia

The boundaries of the suprimeatal (Macewen's) triangle are:

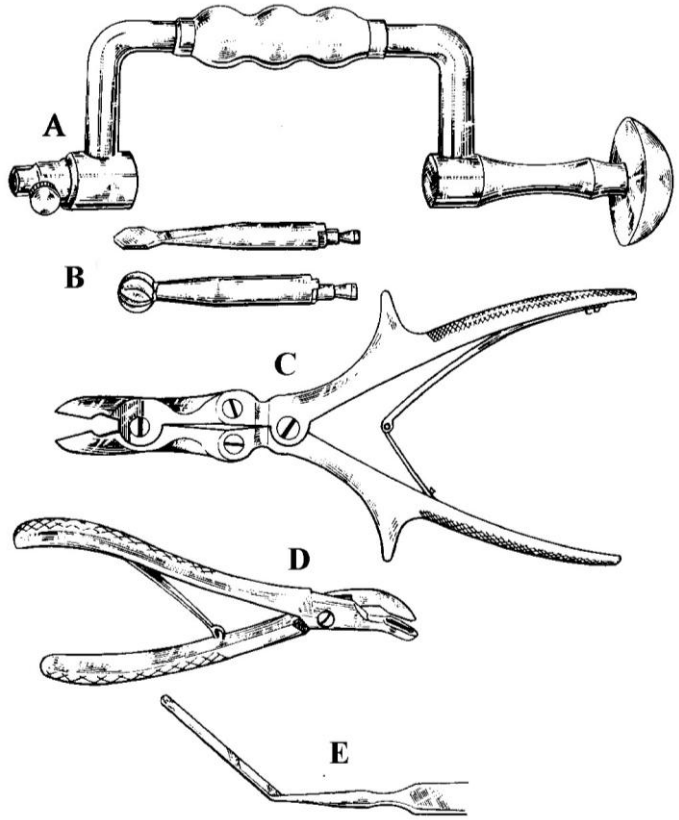
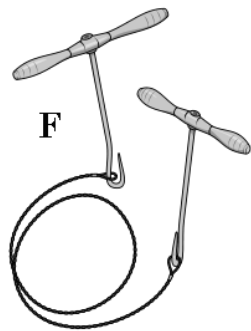
- *Anterior:* _____ along with the suprimeatal spine. This spine is a prominent landmark for the suprimeatal triangle.
- *Superior:* _____
- *Posterior:* a vertical line drawn _____

The management of head wounds includes:

- _____;
- _____;
- _____;
- _____;
- _____;

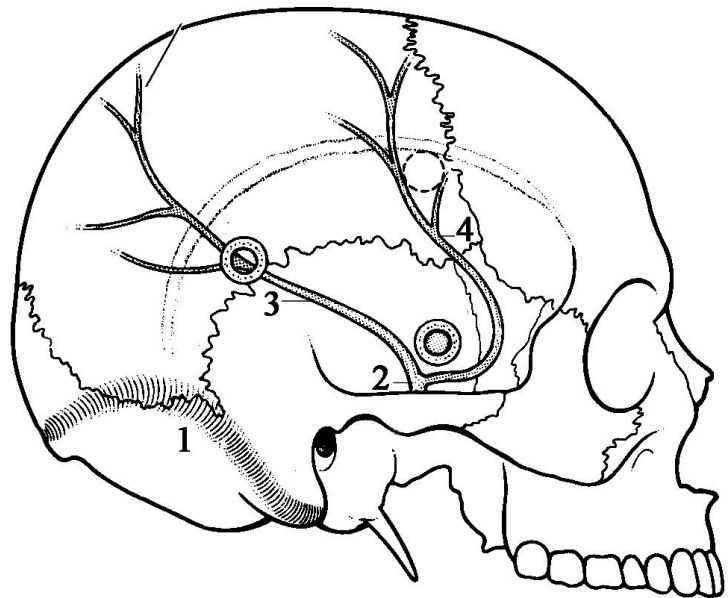
Name the surgical instruments for craniotomy:

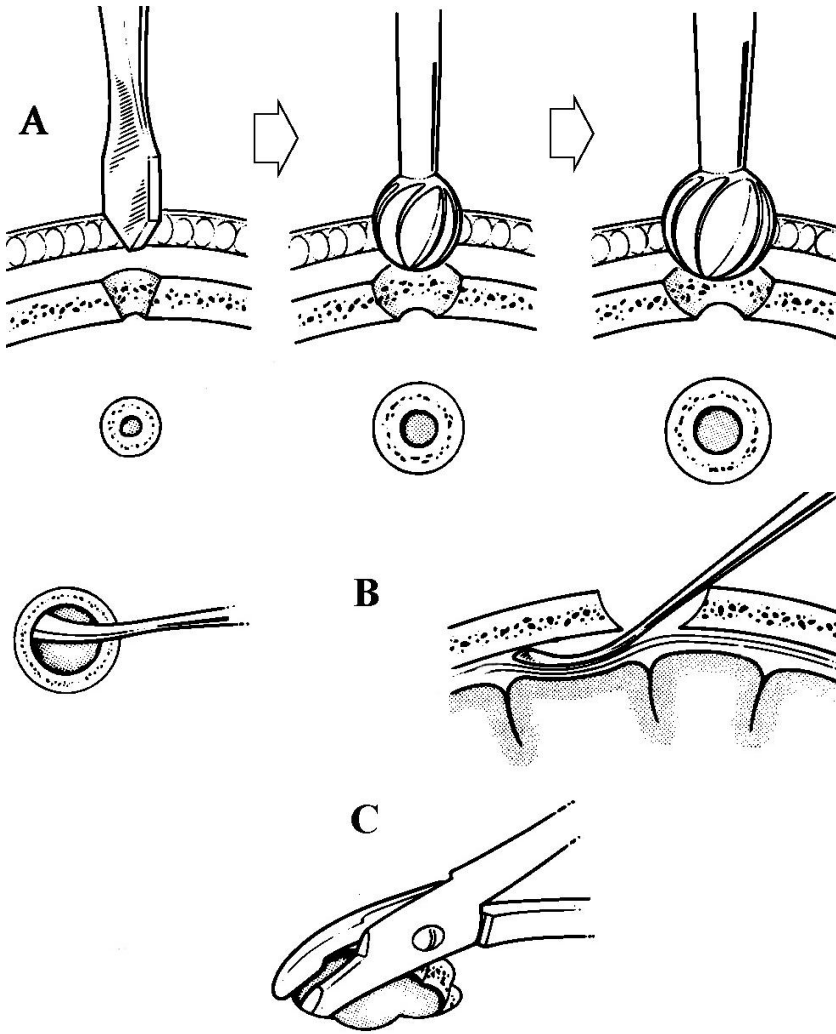
- A — _____
- B — _____
- C — _____
- D — _____
- E — _____
- F — _____



Burr holes for epidural hematoma. Name the structures labeled on the diagram:

- 1 — _____ sinus
- 2 — Trunk of the _____
_____ artery
- 3 — _____
branch
- 4 — _____
branch





Surgical craniectomy:

A — _____

_____ using

_____ and

_____ cutters

B — Using of _____

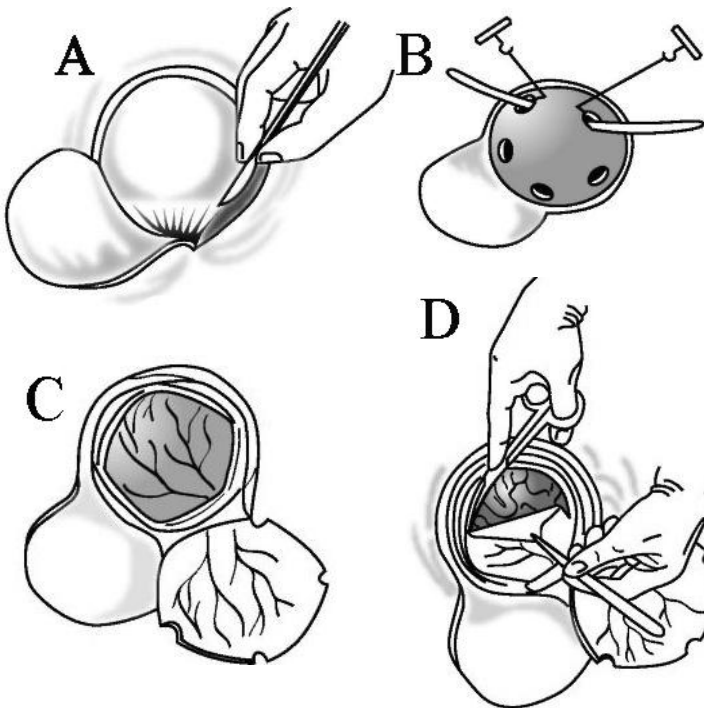
_____ separate

the _____

from the bone

C — widen the hole with

the _____



Osteoplastic craniotomy

A — elaborate the _____

_____ flap

B — cut _____

C — elaborate the _____

_____ flap

D — dissect the _____

CLINICAL ANATOMY OF THE HEAD

LAB N 22: REVIEW OF THE NECK TOPOGRAPHICAL ANATOMY

QUESTIONS FOR DISCUSSION

1. Face: boundaries; surface landmarks; blood and nerve supply to skin.
2. Lips: anatomy; layers; blood supply and innervation.
3. Boundaries of the oral vestibule. Lips: layers; blood vessels, sensory and motor nerves supply to the skin, muscles, and mucous membrane.
4. Boundaries of the oral cavity proper: layers of the hard and soft palates; blood vessels and nerves supply to the mucous membrane and muscles of the soft palate.
5. Tongue: anatomy; blood supply and innervation.
6. Orbital region: bony orbital walls; orbital foramina and openings and their contents; topography of the ophthalmic artery and veins; cranial nerve of orbit; ciliary ganglion.
7. Lacrimal apparatus: anatomy of the lacrimal gland, lake, papilla, and sac; the nasolacrimal duct. Anatomy of the eyelids: layers; blood supply and innervation. Location of the fascial sheath of eyeball and orbital fat body.
8. Boundaries of the nasal region and anatomy of the nasal cavity: bony walls; nasal conchae and meatuses; blood supply and innervation to nasal mucosa.
9. Paranasal sinuses: anatomical location; their connections and significance; neurovascular supply.
10. Buccal region: boundaries, layers, muscles; topography of the facial artery and vein. Buccal and canine spaces: boundaries; contents, communications; clinical relevance.
11. Boundaries and layers of the parotidomasseteric region. Parotid space: contents; communication with lateral pharyngeal space.
12. Infratemporal and pterygopalatine fossae: pterygoid muscles; maxillary artery; pterygoid plexus; mandibular nerve and its branches.
13. Deep facial region: boundaries; location, contents, and communications of the deep temporal, infratemporal, and pterygomandibular spaces.
14. Frontal, parietal and occipital regions: boundaries; layers and spaces; blood supply and innervation.
15. Temporal and mastoid region: boundaries; layers and spaces. Boundaries of the supra-mental triangle.
16. Regional nerve block in dentistry: technics of mandibular, mental, infraorbital, incisal, palatal, and tuberal anesthesia
17. Face and scalp wounds management: skin disinfection; hemostasis and anesthesia; wound assessment; wound closure. Surgical incisions for the drainage of the orofacial region abscess and phlegmon.
18. Cranial trauma: control bleeding in the soft tissues, middle meningeal artery and dural sinus injury.
19. Technique of the osteoplastic craniotomy and craniectomy.

Operative surgery critical skills

Each student should be able to:

1. Use general surgical instruments.
2. Tie simple, surgeon's, and square knots.
3. Make the tissue connection imposing simple interrupted; simple continuous and Multanovsky' blanket; vertical and horizontal mattress; intradermal stitches.
4. Take out skin stitches.
5. Use hemostatic clamps to stop bleeding from damaged vessel and make a vasoligation.
6. Use the Dechamp's needle for vasoligation.
7. Insert the tracheostomy tube.

Учебное издание

Кабак Сергей Львович

**КЛИНИЧЕСКАЯ АНАТОМИЯ
И ОПЕРАТИВНАЯ ХИРУРГИЯ
ГОЛОВЫ И ШЕИ**

**CLINICAL ANATOMY:
HEAD AND NECK**

Практикум для самостоятельной работы

Ответственная за выпуск Н. В. Синельникова
Компьютерная верстка Н. М. Федорцовой

Подписано в печать 18.12.14. Формат 60×84/8. Бумага писчая «Снегурочка».

Ризография. Гарнитура «Times».

Усл. печ. л. 10,23. Уч.-изд. л. 5,22. Тираж 60 экз. Заказ 425.

Издатель и полиграфическое исполнение: учреждение образования
«Белорусский государственный медицинский университет».

Свидетельство о государственной регистрации издателя, изготовителя,
распространителя печатных изданий № 1/187 от 18.02.2014.

Ул. Ленинградская, 6, 220006, Минск.