

**L. A. KAZEKO, E. L. KOLB**

**DIAGNOSTIC PROCEDURES  
IN THERAPEUTIC DENTISTRY**

Minsk BSMU 2016

МИНИСТЕРСТВО ЗДРАВООХРАНЕНИЯ РЕСПУБЛИКИ БЕЛАРУСЬ  
БЕЛОРУССКИЙ ГОСУДАРСТВЕННЫЙ МЕДИЦИНСКИЙ УНИВЕРСИТЕТ  
1-я КАФЕДРА ТЕРАПЕВТИЧЕСКОЙ СТОМАТОЛОГИИ

**Л. А. КАЗЕКО, Е. Л. КОЛЬ**

# **ДИАГНОСТИКА В ТЕРАПЕВТИЧЕСКОЙ СТОМАТОЛОГИИ**

## **DIAGNOSTIC PROCEDURES IN THERAPEUTIC DENTISTRY**

Учебно-методическое пособие



Минск БГМУ 2016

УДК 616.314.163-085.242 (811.111)-054.6 (075.8)  
ББК 56.6 (81.2 Англ-923)  
К60

Рекомендовано Научно-методическим советом университета в качестве  
учебно-методического пособия 20.01.2016 г., протокол № 5

Рецензенты: канд. мед. наук, доц. Н. М. Полонейчик; канд. мед. наук, доц.  
А. Г. Третьякович; ст. преп. Т. А. Проволоцкая

**Казеко, Л. А.**

К60 Диагностика в терапевтической стоматологии = Diagnostic procedures in therapeutic dentistry: учеб.-метод. пособие / Л. А. Казеко, Е. Л. Колб. – Минск : БГМУ, 2016. – 51 с.

ISBN 978-985-567-429-1.

Изложены современные взгляды на основные этапы и принципы диагностики в терапевтической стоматологии. Приведены критерии оценки стоматологического статуса пациента, алгоритмы обследования при основных стоматологических заболеваниях.

Предназначено для студентов 3-го курса медицинского факультета иностранных учащихся, обучающихся на английском языке.

УДК 616.314.163-085.242 (811.111)-054.6 (075.8)  
ББК 56.6 (81.2 Англ-923)

ISBN 978-985-567-429-1

© Казеко Л. А., Колб Е. Л., 2016  
© УО «Белорусский государственный  
медицинский университет», 2016

## INTRODUCTION

**Diagnosis** is the identification of the nature and cause of a certain phenomenon. Diagnosis is used in many different disciplines with variations in the use of logics, analytics, and experience to determine “cause and effect”.

**Medical diagnosis** (abbreviated Ds or Dx) is the process of determining which disease or condition explains a person’s symptoms and signs. The information required for diagnosis is typically collected from a history and physical examination of the person seeking medical care. Often, one or more diagnostic procedures, such as diagnostic tests, are also carried out during the process.

Diagnosis is a major component of the procedure of a doctor’s visit. A proper diagnosis of dental disease is an important stage of a competent and professional treatment. The basic principle of the diagnosis is assessment of the patient’s dental health on the whole, rather than a single disease (caries, periodontal disease, a disease of the oral mucosa).

**Diagnostics** is the science and practice of diagnosing disease.

General components, which are present in a diagnostic procedure in most of the various available methods include:

- 1) taking a history (subjective examination), during which the patient provides the doctor with all diagnostic information about himself or herself;
- 2) objective examination using basic (visual examination, palpation, percussion, probing) and additional (laboratory, instrumental) methods or diagnostic tests.

**A diagnostic test** is any kind of medical test performed to aid in the diagnosis or detection of disease. Diagnostic tests can also be used to provide prognostic information on people with established disease.

The method of **differential diagnosis** is based on finding as many candidate diseases or conditions as possible that can possibly cause the signs or symptoms, followed by eliminating or, at least, rendering the entries more or less probable by using further medical tests and other processing until, aiming to reach the point, when only one candidate disease or condition remains as probable.

A careful examination of the patient allows to establish the correct diagnosis, which is a prerequisite for successful treatment. The diagnostic methods should be very accurate, informative and have good reproducibility. Dental patient survey is carried out with strict observance of steps, adhering to a particular scheme and recommendations of the World Health Organization (WHO).

### DENTAL PATIENT’S EXAMINATION SCHEME

1. *Taking history (dialogue with the patient):*
  - 1.1. Complaints.
  - 1.2. Dental health history.
  - 1.3. General health history.
  - 1.4. Identification of bad habits and unhealthy lifestyle factors.

2. *Inspection (visual and instrumental determination of the oral cavity status):*
  - 2.1. External inspection (extraoral, perioral).
  - 2.2. Inspection of the oral cavity (intraoral).
3. *Index rating:*
  - 3.1. Status of the patient's oral hygiene (as a major risk factor of dental diseases) (OHI-S, PHP indices).
  - 3.2. Condition of the dental hard tissue (DMF).
  - 3.3. Gingival (gum) index (GI).
  - 3.4. Periodontal indices (CPI, CPITN).
  - 3.5. Other indicated indices.
4. *Additional diagnostic tests taking (these methods include physical (related to physical factors), laboratory and instrumental studies):*
  - 4.1. X-rays.
  - 4.2. Determination of the teeth vitality (Electric Pulp Test or EPT).
  - 4.4. Identification of allergy to dental materials.
  - 4.5. Laboratory tests (microbiological, immunological, biochemical and others).
  - 4.6. Morphological examination (histology, cytology).
  - 4.7. Laser-induced fluorescence (DIAGNOdent).
  - 4.8. Fibrooptical transillumination (FOTI).
  - 4.9. Yellow-orange fluorescence (QLF-method).
  - 4.10. Tests for other reasons (depending on the nosology group of disease).

## **TAKING A HISTORY**

Examination of the patient begins with taking his chief complaint, present illness history, dental and medical history (anamnesis).

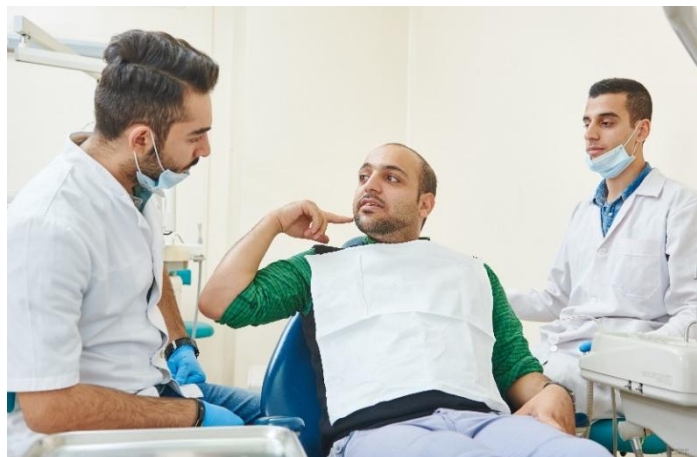The dentist typically asks questions to obtain the following information about the patient:

*Personal data:* name, age, address, social status, occupation and etc.

*The "chief complaint"* — the major health problem or concern, and its duration. Most patients visit the dentist complaining of toothache or gums bleeding. Frequent causes of visits to the dentist are broken fillings or loss of fillings, poorly functioning dentures, aesthetic defects. By asking targeted questions the dentist clarifies the information given by the patient and directs his complaints to the correct diagnosis (fig. 1).

*History of the present illness* — details about the complaints, enumerated in the chief complaint. (Also often called "History of presenting complaint"). The answer to the question about the beginning and duration of toothache allows to approximately divide it into acute and chronic. Throbbing pain indicates the spread of the purulent inflammation into the affected teeth, while the use of cold often reduces the intensity of pain. Dull pain and sensitivity to biting indicates the lesion of the periodontal ligament. Pain from cold and chemical

irritants (sweet irritants due to the change of osmotic pressure) indicates the presence of dental caries.



*Fig. 1. Medical interview*

*Past dental history* — the dentist takes data on hygienic care of the oral cavity, dietary habits and use of fluoride; he also finds out whether the patient has been treated for dental diseases before; he should know the treatment outcome, if there was any exacerbation.

*Medical history:*

– *allergic history:* the diseases restricting the implementation of anesthesia primarily recorded, such as: allergic reactions (food allergy, dust allergy); drug allergy; intolerance to local anesthetics;

– *history of general diseases* (a review of systems), also called a systems enquiry or systems review, is a technique used by healthcare providers for eliciting a medical history from a patient. It is often structured as a component of an admission note covering the organ systems, with a focus upon the subjective symptoms perceived by the patient (as opposed to the objective signs perceived by the clinician).

It is important to find out whether a patient has the following general diseases:

- endocrine disease (diseases of the thyroid gland, pancreas);
- diseases of the liver, lung, gastrointestinal tract;
- blood diseases;
- problems with the cardiovascular system: acute and chronic forms of coronary heart disease (myocardial infarction, unstable and stable angina), heart disorders in systemic connective tissue diseases, infective endocarditis, rheumatic and infectious-allergic myocarditis and others;
- the presence of arterial hypertension, blood pressure level, hypertensive crises in history;
- in-patient treatment within the last 10 years, the frequency and cause of hospitalization;
- inspection at the general practitioner (the therapist, the cardiologist, the endocrinologist, etc.) within the last 5 years;
- medication: groups of drugs, intake duration, and dosage.

It is necessary to identify the disease limiting the duration of treatment, such as a general state of the patient (6 months after myocardial infarction, hypertensive crisis), epilepsy difficulties in the opening of the mouth.

The dentist should also register the disease with a high risk of infective endocarditis developing:

- patients after prosthetic heart valves surgery;
- patients with acquired heart diseases of rheumatic etiology (usually aortic localization);
- patients with previously undergone infective endocarditis and congenital heart disease;
- with mitral valve prolapse and severe mitral insufficiency;
- with idiopathic hypertrophic subaortic stenosis;
- patients on chronic hemodialysis;
- patients with an implanted pacemaker;
- drug addicts.

*Risk factors identification:* smoking; using alcohol; genetic predisposition.

It is necessary to inquire about *pregnancy or lactation period* for women.

All data should be carefully recorded to the dental patient's card. Details of medical history are subsequently taken into account when planning preventive and therapeutic measures.

## **DETERMINATION OF THE DENTAL STATUS**

Dental examination as recommended by the WHO consists of *extraoral* and *intraoral examination*.

A patient is examined by various visual, tactile, manual, and instrumental methods. It should be noted that the methods of the dental status determination are also divided into *basic and additional clinical tests*.

*Basic tests:*

- probing;
- percussion;
- palpation;
- determination of tooth mobility.

*Additional tests:*

- drying;
- staining;
- temperature test;
- mechanical test (biting on a hard object);
- test on local anesthesia;
- cavity preparation test (diagnostic dissection of dental hard tissues).

**Basic tests.** *Probing* is an instrumental test with examination instruments, such as the explorer and probe. These instruments are used for specific examination of the teeth and periodontal tissues. The explorer provides the tactile information to the clinician's fingers and is used to determine calculus deposits,

tooth surface irregularities, defective margins on restorations, decalcified areas and carious lesions (fig. 2).

Use of explorer should be very gentle because:

- sharp tips physically damage small lesions with intact surfaces;
- probing with explorer can cause fracture and cavitation of incipient lesion;
- mechanical binding may be due to non-carious causes.

*The calibrated periodontal probe* (fig. 3) is a periodontal instrument that is marked in millimeter increments and used to evaluate the health of the periodontal tissues.

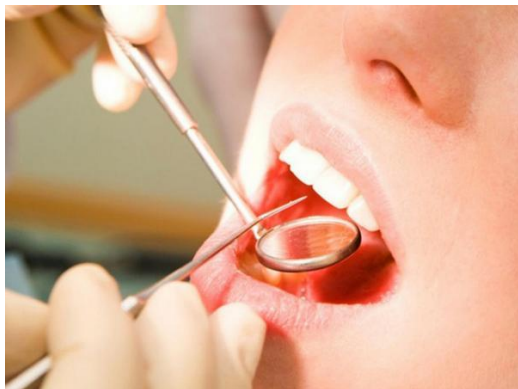

Fig. 2. Probing with explorer

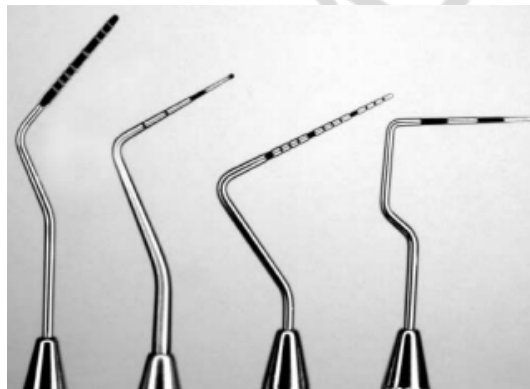


Fig. 3. Different types of calibrated periodontal probe

Calibrated probes have blunt, rod-shaped working-ends that may be circular or rectangular in cross section.

Function of Periodontal Probes includes:

a) findings from an examination with a calibrated probe are important in a comprehensive periodontal assessment to determine the health of the periodontal tissues;

b) the calibrated periodontal probe is used to measure sulcus and pocket depths, to measure clinical attachment levels, to determine the width of attached gingiva, to assess for the presence of bleeding and/or purulent exudate (pus), and to measure the size of oral lesions.

*Palpation* is examination using the sense of touch through tissue manipulation or pressure on an area with the fingers or hand. The method used depends on the area to be investigated.

Types of palpation include the following:

1. *Digital*. Use of a single finger. Example: index finger applied to the inner border of the mandible beneath the canine-premolar area to determine the presence of a torus mandibularis.

2. *Bidigital*. Use of finger and thumb of the same hand. Example: palpation of the lips (fig. 4).

3. *Bimanual*. Use of finger or fingers and thumb from each hand applied simultaneously in coordination. Example: index finger of one hand palpates on the floor of the mouth inside, while a finger or fingers from the other hand press on the same area from under the chin externally (fig. 5).



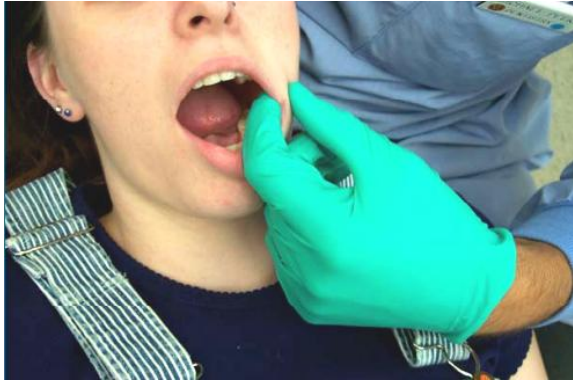

Fig. 4. Bidigital palpation

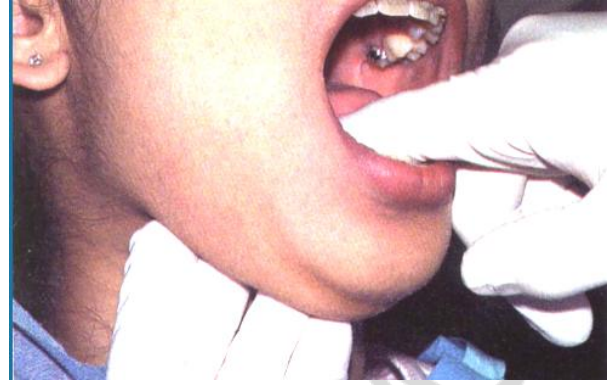

Fig. 5. Bimanual palpation

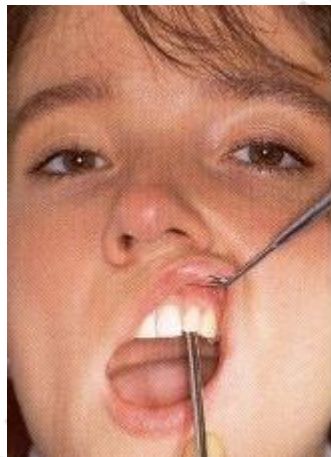
4. *Bilateral*. The two hands are used at the same time to examine corresponding structures on opposite sides of the body. Comparisons may be made. Example: fingers placed beneath the chin to palpate the submandibular lymph nodes.

*Percussion* is the act of tapping or striking a surface or tooth with the fingers or an instrument. Information about the status of health of the part is determined either by the response of the patient or by the sound. For example, a metal mirror handle may be used to tap each tooth successively. When a tooth is known to be painful to movement, percussion should be avoided.

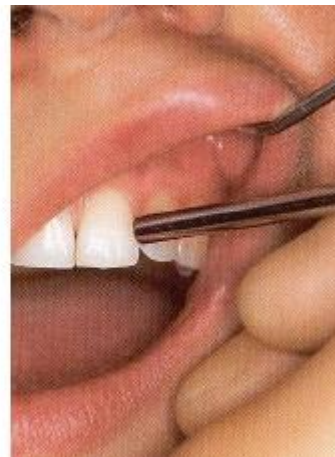Types of percussion:

Vertical percussion: occlusal percussion of the tooth helps to reveal the periapical inflammation (fig. 6, *a*).

Horizontal percussion — tapping a tooth buccally — helps to reveal the periodontal inflammation (fig. 6, *b*).



*a*



*b*

Fig. 6. Types of percussion:  
*a* — vertical; *b* — horizontal

#### *Determination of tooth mobility*

Mobility is the loosening of a tooth in its socket. Mobility may result from loss of bone support to the tooth. Types of tooth mobility:

*Horizontal tooth mobility* is the ability to move the tooth in a facial-lingual direction in its socket. Horizontal tooth mobility is assessed by putting the handles of two dental instruments on either side of the tooth and applying alternating moderate pressure in the facial-lingual direction against the tooth — first with one, then with the other instrument handle (fig. 7).

*Vertical tooth mobility*, the ability to depress the tooth in its socket, is assessed using the end of an instrument handle to exert pressure against the occlusal or incisal surface of the tooth (fig. 8).

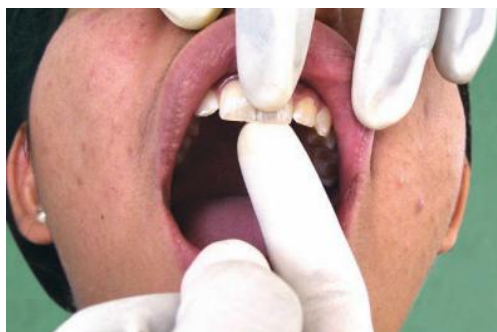

Fig. 7. Horizontal tooth mobility

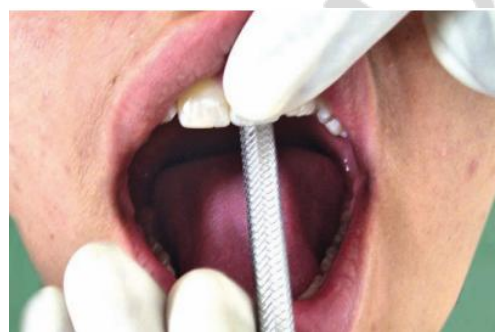

Fig. 8. Vertical tooth mobility

There are many mobility-rating scales for recording tooth mobility on a periodontal chart. Useful rating scales are indicated in tables 1 and 2.

Table 1

**Mobility scale (adapted from [http://www1.umn.edu/perio/dent5612-04/module\\_21.pdf](http://www1.umn.edu/perio/dent5612-04/module_21.pdf))**

<b>Class 1</b>	Slight mobility, up to 1 mm of horizontal displacement in a facial-lingual direction
<b>Class 2</b>	Moderate mobility, greater than 1 mm of horizontal displacement in a facial-lingual direction
<b>Class 3</b>	Severe mobility, greater than 1 mm of displacement in a facial-lingual direction combined with vertical displacement (tooth depressible in the socket)

Table 2

**Tooth mobility-rating scales according to A. I. Yevdokimov**

<b>1<sup>st</sup> degree</b>	The tooth is displaced in vestibular direction by 1 mm in relation to the adjacent tooth crown
<b>2<sup>nd</sup> degree</b>	The tooth is displaced in vestibular direction more than 1 mm, or there is mobility in the medial direction
<b>3<sup>rd</sup> degree</b>	The tooth is displaced both in horizontal and vertical directions

*Additional tests*

*Drying* the teeth surface with air is very useful in differential diagnostic of white spot enamel lesions. Enamel carious defects are more obvious when the teeth are dried (similar to other defect areas) since drying heightens the difference in refractive index between sound enamel and adjacent abnormal enamel.

*Staining* is carried out with a 2 % solution of methylene blue. Application time — 3 minutes. The color of the tooth surface changes in the presence of tooth decay and dental plaque (fig. 9).

Dying is carried out in order to:

- motivate the patient;
- determine hygienic index rating;
- make differential diagnosis of caries and non-carious lesions;
- determine the effectiveness of preventive measures.

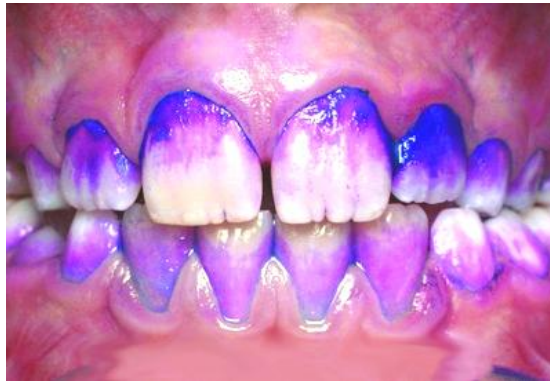

Fig. 9. Staining test

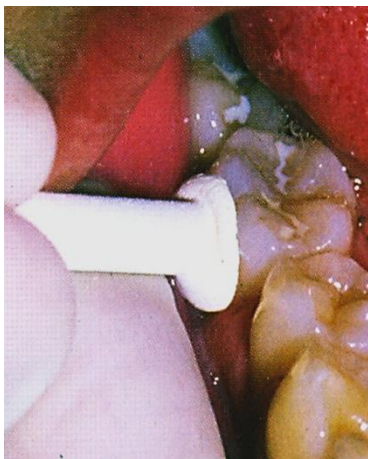


Fig. 10. Test with heating

#### *Temperature test*

*Test with heating.* Heat testing can be undertaken using a stick of heated gutta-percha or hot water. A gutta-percha stick is heated with a naked flame or an electric heater until it becomes soft and glistens. It is then applied to the vaseline-coated surface of the test tooth. It is supposed that a tooth surface temperature as high as 150 °C can be achieved with this technique: gutta-percha softens at 65 °C and may be heated in delivery devices up to 200 °C. This test may be difficult to use on posterior teeth because of limited access. A further disadvantage is that excessive heating may result in pulp damage (fig. 10).

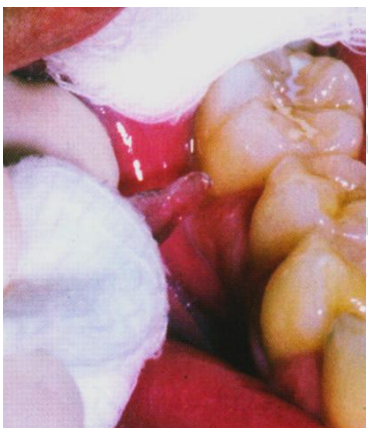

Fig. 11. Test with cooling

*Test with cooling.* A simple means of applying a cold stimulus to a tooth is to wrap a sliver of ice in wet gauze and place it against the buccal surface, comparing the reaction between the test tooth and a control tooth. Pencils of ice can be made by filling a plastic straw with water and freezing it in an upright position in a refrigerator. Ethyl chloride (boiling point — 41 °C) may be sprayed onto a cotton pledget, resulting in the formation of ice crystals, prior to application to the tooth (fig. 11).

There are 6 options for temperature response:

- the lack of response (necrosis of pulp, chronic apical periodontitis, or obliteration of the pulp cavity in the elderly);



- single transient response (healthy intact tooth, carious lesions, dental caries);
- transient reaction quickly passing (reversible pulpitis — hyperemia of the pulp);
- the pain reaction occurs quickly from cold, survive the termination of stimuli (acute pulpitis);
- the pain reaction occurs rapidly from the hot, survive the termination of stimuli, decreasing from the cold (acute purulent pulpitis);
- pain reaction appears slowly and increases after the temperature stimuli removing (chronic pulpitis).

*Mechanical test (biting on a hard object)* is the use of bit sticks to check for incipient fractures that are causing pain to a tooth when under function. By having a patient bite on each cusp and laterally move the lower jaw, each cusp is subjected to lateral stresses (fig. 12). If a section of the tooth under a cusp has an incipient fracture it will often hurt when pressure is applied. If a fracture does exist, the tooth may not need endodontics if the fracture does not extend into the pulp. The pain generally disappears if the fractured portion of the tooth can be cleaved off.

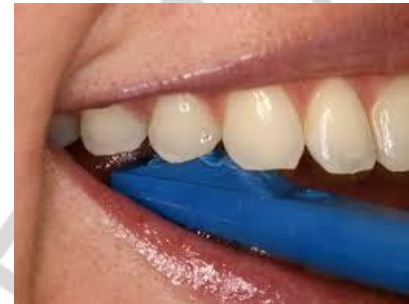

Fig. 12. Mechanical test

*Cavity preparation test.* This test may serve as a last resort in testing for pulp vitality. It is only considered when the results of all other tests have proved inconclusive. Its value in clinical practice has been largely anecdotal as there is no evidence base to support its effectiveness. The test cavity is made by drilling through the enamel – dentine junction of an unanesthetized tooth with good isolation. This may be achieved under rubber dam with a small round diamond bur in a high-speed handpiece with adequate coolant. The patient is asked to respond if any painful sensation is felt during the drilling procedure. If the patient feels pain once the bur contacts the sound dentin, the procedure is terminated and the cavity is restored.

*Local anesthetic test.* When dental symptoms are poorly localized or referred, an accurate diagnosis is extremely difficult. Sometimes, patients may not even be able to specify whether the symptoms are from the maxillary or mandibular arch. In such cases, and where pulp testing has proved inconclusive, an anesthetic test may be helpful. The technique is as follows: using either infiltration or an intraligamentary injection, the most posterior tooth in the area suspected of causing the pain is anesthetized. If pain persists once the tooth has been fully anesthetized, the tooth immediately mesial to it is then anesthetized, and so on, until the pain disappears. If the source of the pain cannot be even localized to the upper or lower jaw, an inferior alveolar nerve block injection is given; cessation of pain indicates involvement of a mandibular tooth. This approach has an advantage over a test cavity, which may incur iatrogenic damage.

## EXTRAORAL (EXTERNAL) INSPECTION

Extraoral examination includes inspection of the head and neck region for asymmetry or swelling. Palpate the submental, submandibular, cervical and supraclavicular regions

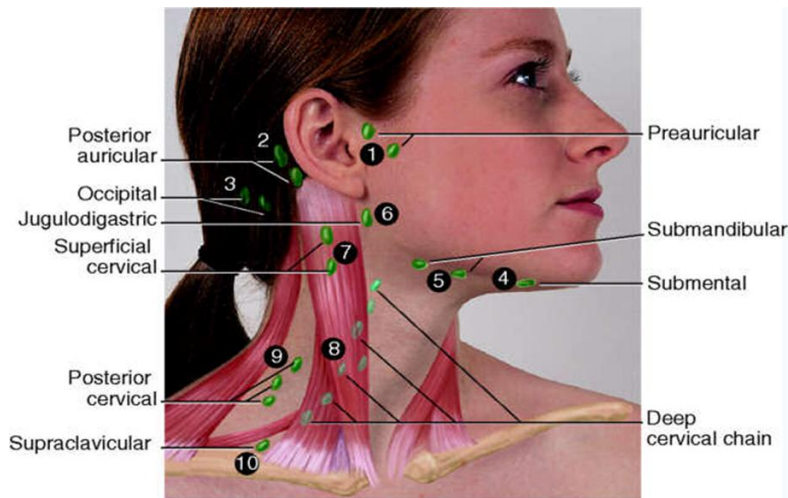


Fig. 13. Lymph nodes of the neck

paying particular attention to the size, number, tenderness and mobility of lymph nodes (fig. 13). A bimanual approach is recommended as it enhances the examiner's ability to appreciate the characteristics of any mass and to make comparisons with the contralateral side (fig. 14). This is of particular importance in the neck where some lymph nodes lie under the muscles. In patients who have had a prior dental infection or surgical procedure in the head and neck region, it is common to find small, painless, freely mobile residual lymph nodes. However, if a lymph node is enlarged (i. e. > 1 cm in diameter) and palpably firm or fixed to adjacent structures, referral or further investigation is indicated. To complete the extraoral examination, inspect and palpate the lips and perioral tissues for abnormalities.

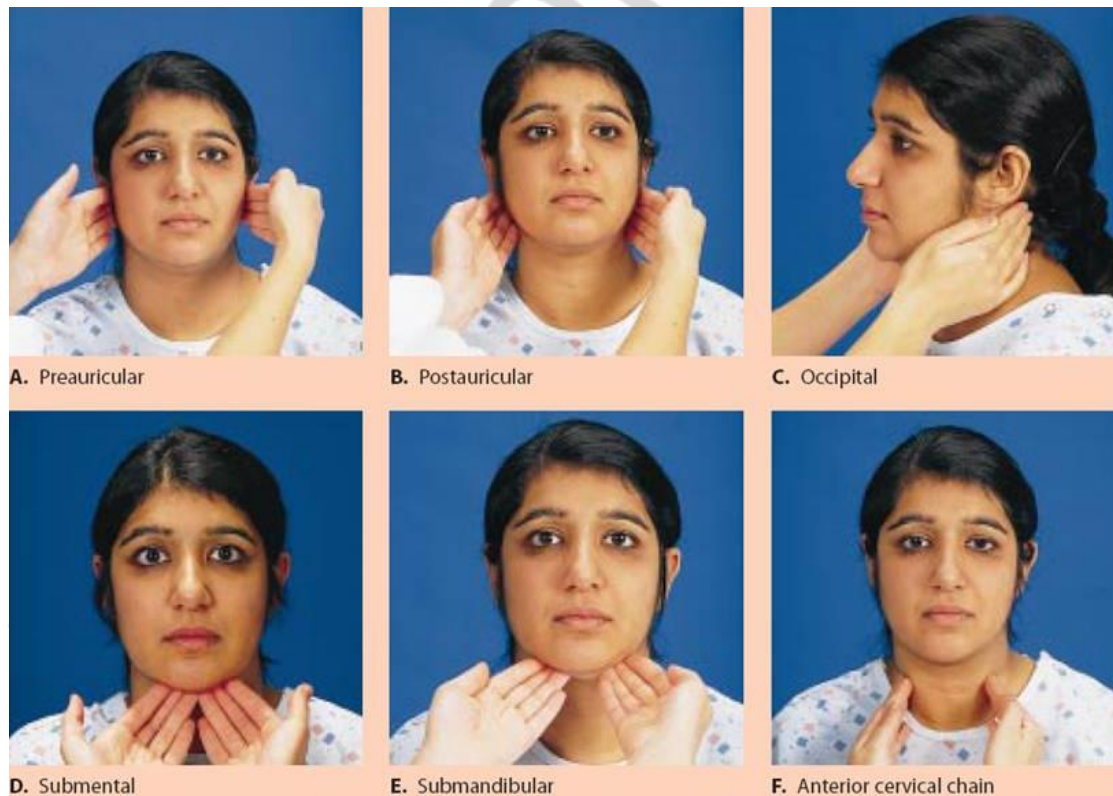

Fig. 14. Bimanual lymph nodes of the neck palpation

### *Symmetry and Profile*

Discreetly observe the patient for facial symmetry and profile type. Obvious asymmetry may be a sign for inflammation (fig. 15), neoplastic growths, muscle atrophy or hypertrophy, and neurological problems. Asymmetry is also associated with temporomandibular joint dysfunction and malocclusions (fig. 16).

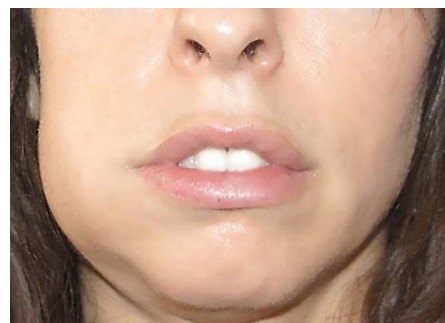

Fig. 15. Asymmetry of the patient's face due to acute periostitis



Fig. 16. Different types of facial profile

## **INTRAORAL INSPECTION**

*Intraoral inspection: a systemic examination of the oral cavity.*

*Inspection of the oral mucosa.*

Inspection of the oral cavity begins with a visual assessment of the color and the relief of the oral mucous membrane. The dentist should determine a violation of the integrity and the presence of elements of lesions. Inspection is carried out with the help of 2 dental mirrors (fig. 17) on the anatomical and topographical areas of the oral cavity with natural light. WHO (1997) recommends the following sequence of the oral mucosa examination:

- commissure and the mucous membrane of the lips;
- vestibule of the mouth;
- buccal mucosa on the left and right side (fig. 17);
- mucosa of the hard and soft palate;
- the back and lateral sides of the tongue (fig. 18);
- the lower surface of the tongue and the floor of the mouth.

Systematically inspect and palpate all oral soft tissues, as oral cancer can develop at any anatomical site. Particular attention should be given to high-risk sites, which include the lateral and ventral aspects of the tongue, floor of the mouth and the soft palate complex.



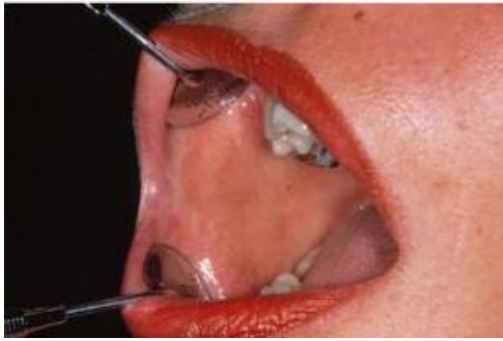


Fig. 17. Inspection of the oral mucosa

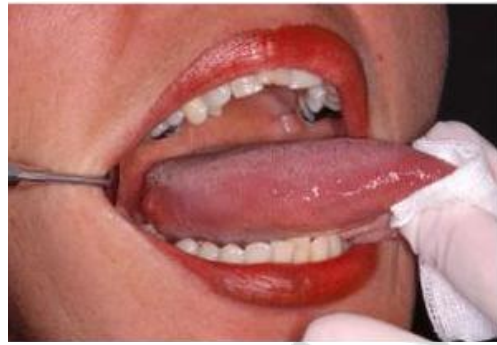

Fig. 18. Inspection of the tongue

*Determination of the patient's oral hygiene status* is crucial. The presence of supragingival plaque and calculus deposits should be noted in terms of distribution within the mouth and the quantity present. However, whilst plaque and calculus deposits give some indication of the patient's level of oral hygiene (fig. 19), the presence of gingival inflammation (gingivitis) provides a better indication of the patient's long-term plaque control.

*Plaque.* When present in small amounts, plaque is not always apparent solely by visual examination, and it is necessary to run a probe around the gingival margin to enable trace amounts to be visualized. Use of a probe is also required to detect plaque in interproximal spaces.

*Calculus* formed by mineralization of plaque, this is described according to its relation to the gingival margin.

*Supragingival calculus* is formed above the gingival margin; it accumulates most readily adjacent to the orifices of the major salivary glands: on the lingual aspects of the lower incisor teeth, and the buccal aspect of maxillary molars. It is light yellow in color and is best visualized by drying the teeth (fig. 20). It is composed of calcium phosphate crystals — brushite, whitlockite, octacalcium phosphate and hydroxyapatite. It is relatively easily removed by scaling.

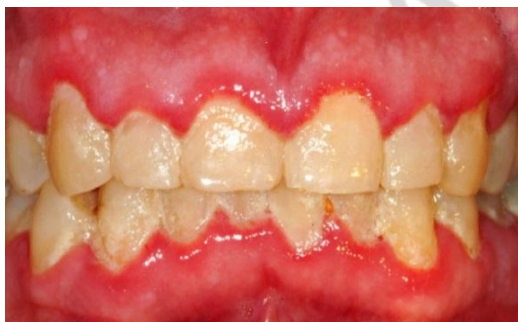

Fig. 19. Poor level of oral hygiene

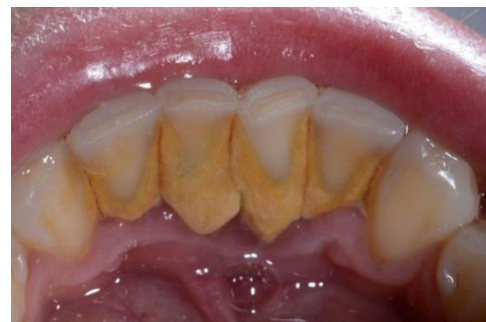

Fig. 20. Supragingival calculus

*Subgingival calculus* is dark brown or green in color. Subgingival calculus is located beneath the gingival margin. Present either in sheets covering the entire root surface or in discrete clumps, it is detectable only by tactile means or by using an air syringe to deflect the gingivae. The ball end of the CPITN probe, used with light touch, is the most effective means of determining the location of subgingival calculus, which appears as a rough area caught on the root surface. A sound

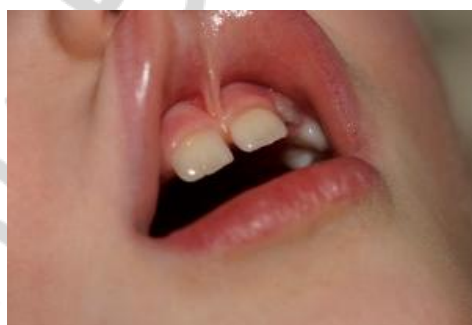knowledge of root surface anatomy is required to enable accurate probing. Subgingival calculus may come to lie supragingivally following gingival recession. It is firmly adherent to the root surface and its removal requires careful scaling technique.

For digital assessment of the oral hygiene level hygienic indexes (OHI-S, PHP) described below are used.

*A detailed investigation of periodontal tissue includes:*

- evaluation of oral architectonic;
- index assessment of the periodontal tissues using complex periodontal index (CPI) or periodontal index CPITN, periodontal attachment loss;
- the identification of the attached gingiva width;
- the identification of the gingival margin level;
- the presence and magnitude of gingival recession;
- furcation involvement;
- determination of tooth mobility.

*Evaluation of oral architectonic:* the shape and location of the lips and tongue frenulum attachment are determined (frenulum normally triangular in shape, has a broad base; lip frenulum attached to the lip and end in the midline of the alveolar ridge at a distance of 0.5 cm from the gingival margin). The test “tension” assesses the state of lip frenulum. Pulling down lip causes displacement of the gingival margin of the gum and interdental whitening means short frenulum (fig. 21).



*Fig. 21. Evaluation of oral architectonic; test “tension” assesses the state of lip frenulum*

*Index assessment of the periodontal tissues using complex periodontal index (CPI) or periodontal index CPITN, periodontal attachment loss*

The periodontal attachment system is a group of structures that work together to attach the teeth to the skull. To remain in the oral cavity, each tooth must be attached by the following:

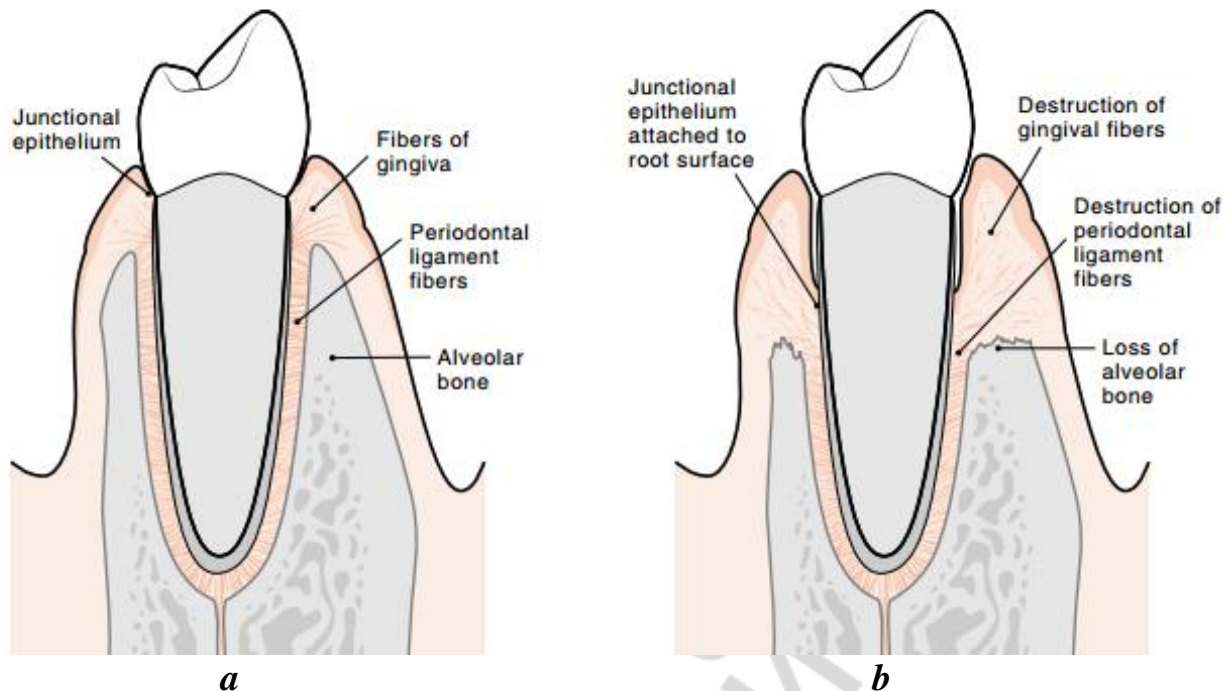
1. Junctional epithelium — the epithelium that attaches the gingiva to the tooth.
2. Fibers of the gingiva — a network of fibers that brace the free gingiva against the tooth and unite the free gingiva with the tooth root and alveolar bone.
3. Periodontal ligament fibers — the fibers that surround the root of the tooth. These fibers attach to the bone of the socket on one side and to the cementum of the root on the other side.
4. Alveolar bone — the bone that surrounds the roots of the teeth. It forms the bony sockets that support and protect the roots of the teeth (fig. 22, a).

Loss of attachment (LOA) is damage to the structures that support the tooth. LOA occurs in periodontitis and is characterized by:

- relocation of the junctional epithelium to the tooth root;
- destruction of the fibers of the gingiva;



- destruction of the periodontal ligament fibers, and
- loss of alveolar bone support from around the tooth (fig. 22, *b*).



*a*

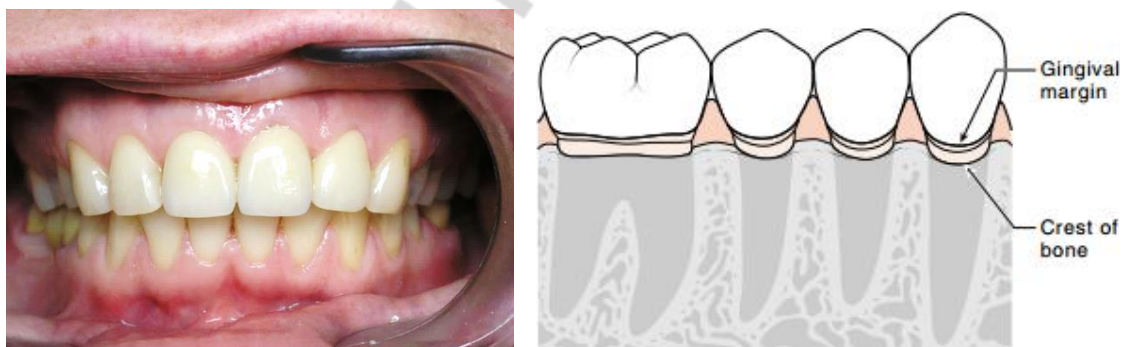
*b*

*Fig. 22.* Cross Section of the Periodontal Attachment System:

*a* — the periodontal attachment system in health; *b* — destruction of the periodontal attachment system in disease

The changes that occur in the alveolar bone in periodontal disease are significant because loss of bone height can eventually result in tooth loss.

In health, most of the tooth root is surrounded with bone. The crest of the alveolar bone is located very close to the crowns, only 1 to 2 mm apical to (below) the cemento-enamel junctions of the teeth (fig. 23).



*Fig. 23.* Bone Support in Health

In gingival disease, there is no loss of alveolar bone and the crest of the alveolar bone remains only 1 to 2 mm apical to (below) the cemento-enamel junctions of the teeth (fig. 24).

In periodontitis, bone is destroyed and the teeth are not well supported in the arch. In this example of bone loss, the gingival margin has remained near the cemento-enamel junction, creating deep periodontal pockets (fig. 25).

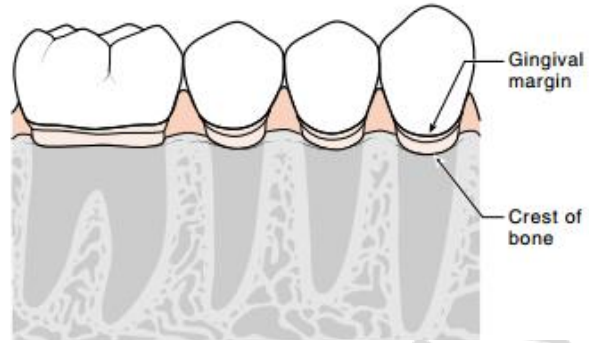
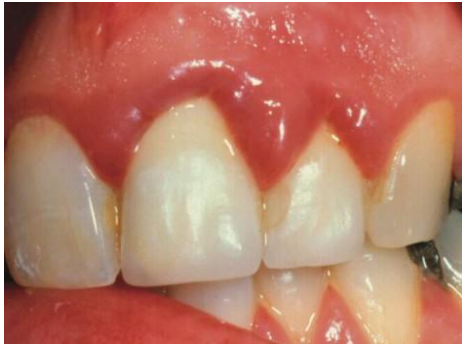

Fig. 24. Bone Support in Gingivitis

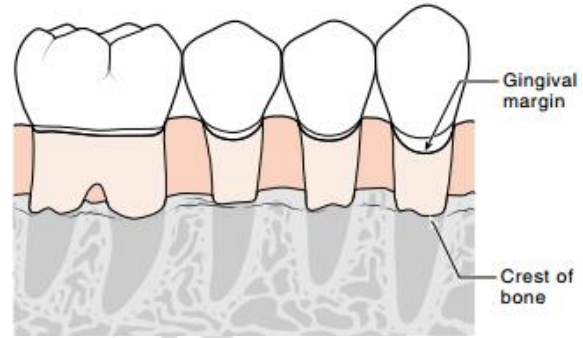
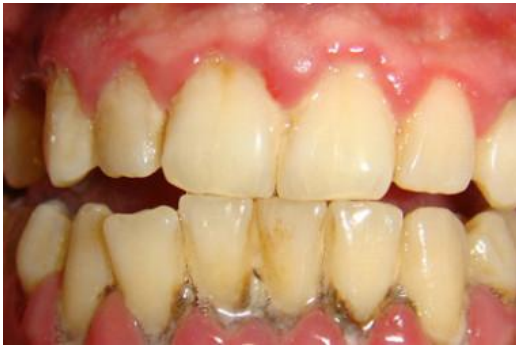

Fig. 25. Bone Loss and Pocket Formation in Periodontitis

In the next example of periodontitis, the gingival margin has receded, and the tooth roots are visible in the mouth. Note that the alveolar bone is at the same level in this example and the one before — only the level of the gingival margin differs in these two examples (fig. 26).

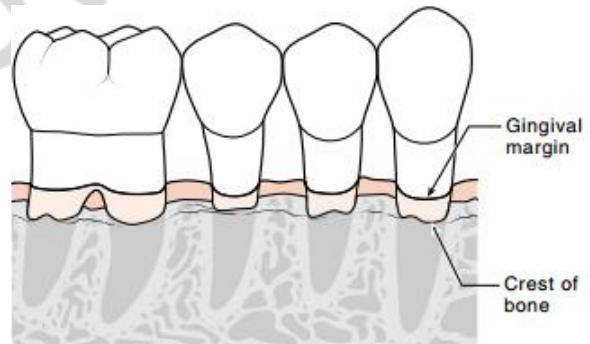
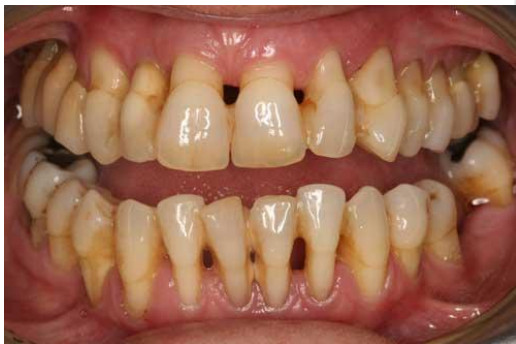

Fig. 26. Loss of Bone and Gingival Recession in Periodontitis

It is also necessary to pay attention to the following signs of disease during the inspection of periodontal tissue:

*Color of the gum.* Healthy gum has a pale pink color (“coral pink” by Caranza), acute inflammatory gum becomes bright red in color, chronic inflammatory gum — cyanotic.

*Shape of the gum.* Normally, the gingival papillae in the incisors and canines are pointed shape, in the premolars and molars they are trapezoidal in shape. When pathological processes form can be smoothed, acquire a spherical, scalloped or crater shape (fig. 27).

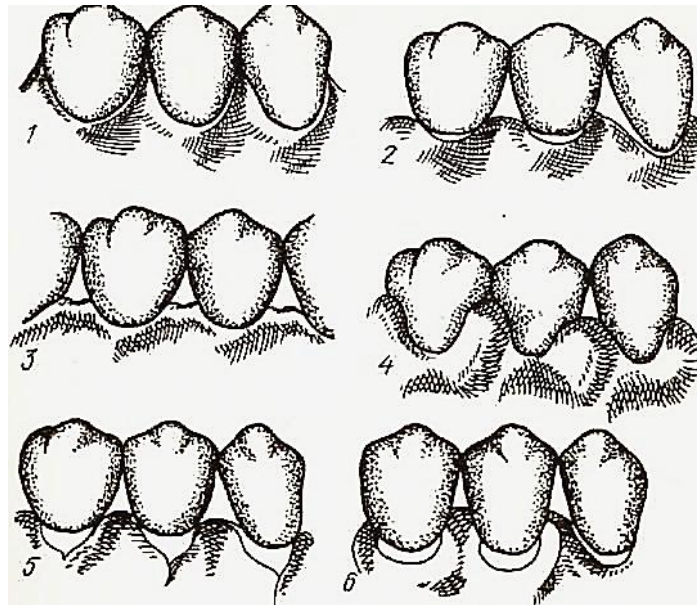


Fig. 27. Changes of the gingival contour in periodontal diseases:  
 1 — normal; 2 — atrophic; 3 — crateriform; 4 — spherical; 5 — dissected; 6 — scalloped

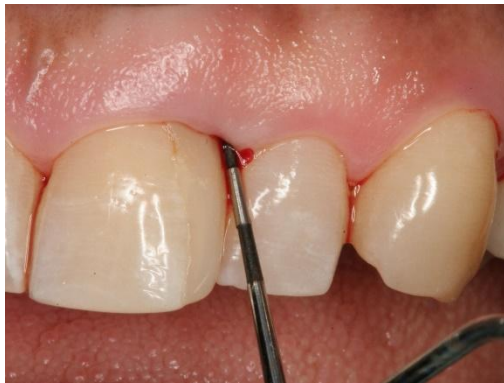

Fig. 28. Bleeding of the gum

*Surface of the gum.* Healthy gum has drip depressions, reminiscent of an orange or lemon crust. In inflammatory process, it becomes smooth and shiny.

*Consistency of the gum* (determined by palpation), Healthy gum has elastic consistency, in the pathology it is loose and pastose.

*Bleeding of the gum* is not observed normally, in pathological processes it appears within 30–40 seconds after gum palpation or touching with periodontal probe (fig. 28).

### **Identification of the gingival margin position with the index assessment of the periodontal tissues. The Community Periodontal Index of Treatment Needs (CPITN) and Comprehensive Periodontal Index (CPI)**

#### ***The Community Periodontal Index of Treatment Needs (WHO, 1982)***

A report by the World Health Organization in 1978 led to the creation of the *Community Periodontal Index of Treatment Needs (CPITN)* and a periodontal probe termed WHO 621 (“Trinity”). The CPITN was intended to provide a global standard for clinical practice and research. This index was designed to assess the treatment needs of specific groups. It can be used as a screening or monitoring tool to determine the periodontal treatment needs of either a community or an individual. Only six measurements per a person are recorded, so it is time efficient when assessing a large group.

*Category of CPITN:* Oral Hygiene & Periodontal. This index is reversible (oral hygiene) and irreversible (periodontal).



The periodontal probe WHO 621 has a ball end 0.5 mm in diameter and a first colored band at 3.5–5.5 mm. Another colored band at 8.5–11.5 mm may be present (fig. 29). The ball at the end of the probe functions to aid in detection and reduce the risk of over-measurement. The probe is used to determine probing depth, bleeding response, and presence of calculus. Pressure of the probing no greater than 15–25g.

*Procedure of CPITN:*

The teeth are first divided into sextants, with each box representing a sextant. Teeth selection is determined by the age of the patient. If the patient is 20 years old, or older, then begin distal to canines. A sextant with no teeth or one tooth is marked with an X. If only one functional tooth is present, assess with adjacent sextant. Third molars are assessed only if they function in place of second molars. For children and adolescents, one tooth per sextant is evaluated: all first molars, maxillary right central incisor, and mandibular left central incisor. If designated tooth missing, mark the sextant with an X.

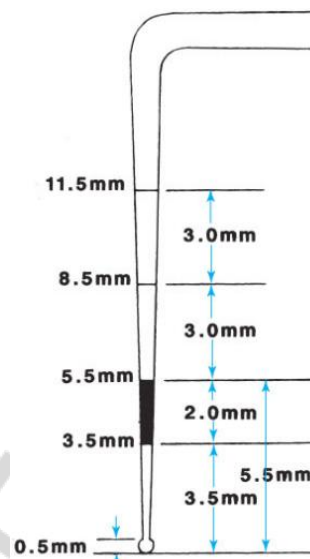


Fig. 29. Periodontal probe

Codes of CPITN are represented in table 3.

Table 3

**Codes of CPITN**

CODE	
0	Healthy periodontal tissues
1	Bleeding after gentle probing
2	Supragingival or subgingival calculus or defective margin of filling or crown
3	4mm or 5mm pocket
4	6mm or deeper pathologic pocket

*Recording:* use the 2 × 3 box chart. An X is marked for all missing sextants. Record only the highest code (most severe) for the designated sextant. Once a Code 4 has been assessed, there is no need to continue assessing the remaining teeth of the sextant.

*Scoring:* the patient are classified into treatment needs based on the highest code recorded (table 4).

Table 4

**Scoring of CPITN**

SCORE	
0	No need for treatment (Code 0)
I	Oral hygiene instruction (Code 1)
II	OHI + scaling and root planing, including elimination of plaque-retentive margins (Codes 2 & 3)
III	I + II + complex periodontal therapy that may include surgical intervention and/or deep scaling and root planing with local anesthetic (Code 4)

### ***Comprehensive Periodontal Index (CPI) (P. A. Leus, 1988)***

*Category of CPI:* Oral Hygiene & Periodontal. This index is reversible (oral hygiene) and irreversible (periodontal).

It determines the state of periodontal tissue using a conventional dental probe and dental mirror, to determine the mobility of the teeth, dental forceps can be used. In adults one should explore 1.7/1.6; 1.1; 2.6/2.7; 3.7/3.6; 3.1; and 4.6/4.7 teeth. If there are several signs of periodontal disease, more serious condition is registered (higher score).

Criteria of CPI are represented in the table 5:

Table 5

#### **Criteria of CPI**

<b>CODE</b>		
<b>0</b>	healthy	plaque and signs of periodontal lesions are not detected
<b>1</b>	plaque	any amount of plaque
<b>2</b>	bleeding	bleeding visible to the naked eye with gentle probing of periodontal groove
<b>3</b>	calculus	any amount of plaque in the gingival area of the tooth
<b>4</b>	pathological pocket	pathological tooth-gingival pocket defined by the probe
<b>5</b>	tooth mobility	mobility of degree 2–3

CPI individual is calculated using the next formula:

$$\text{CPI} = \frac{\text{the amount of codes}}{\text{number of sextants (usually 6)}}$$

Interpretation of the CPI gives the individual risk factors presence and intensity level of the periodontal disease (table 6).

Table 6

#### **Interpretation of the CPI**

<b>CPI Value</b>	
<b>0.1–1.0</b>	Risk of periodontal disease
<b>1.1–2.0</b>	Light level of periodontal disease
<b>2.1–3.5</b>	Average level of periodontal disease
<b>3.6–5.0</b>	Severe level of periodontal disease

#### ***Identification of the attached gingiva width***

The attached gingiva is the part of the gingiva that is tightly connected to the cementum on the cervical-third of the root and to the periosteum (connective tissue cover) of the alveolar bone. The function of the attached gingiva is to keep the free gingiva from being pulled away from the tooth. The width of the attached gingiva is an important clinical feature for the dentist to keep in mind when planning restorative procedures. If there is no attached gingiva on a tooth surface, the dentist is limited in the types of restorations that can be placed on the tooth.

1. The attached gingiva extends from the base of the sulcus to the mucogingival junction. The alveolar mucosa can be detected visually by its deep red color and shiny appearance.

2. The width of the attached gingiva on the facial aspect varies in different areas of the mouth:

a) it is widest in the anterior teeth (3.5–4.5 mm in the maxilla and 3.3–3.9 mm in the mandible);

b) it is narrowest in premolar and molar regions (1.8 mm in the mandible and 1.9 mm in the maxilla);

c) the width of the attached gingiva is not measured on the palate because clinically it is not possible to determine where the attached gingiva ends and the palatal mucosa begins.

3. The formula for calculating the width of attached gingiva is shown in figure 30.

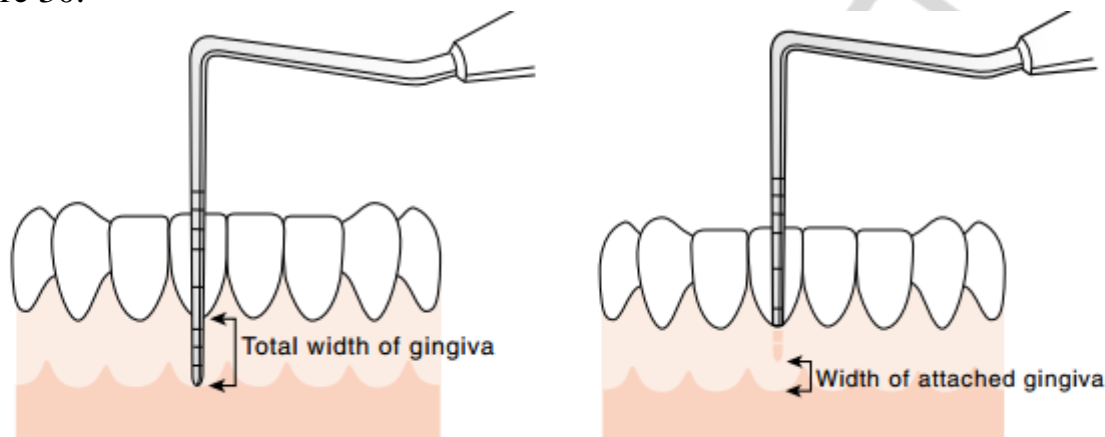


Fig. 30. Calculating the Width of Attached Gingiva

Formula: calculate the width of the attached gingiva by subtracting the probing depth from the total width of the gingiva.

STEP 1: Measure the total width of the gingiva from the gingival margin to the mucogingival junction.

STEP 2: Measure the probing depth (from the gingival margin to the base of the pocket).

STEP 3: Calculate the width of the attached gingiva by subtracting the probing depth from the total width of the gingiva.

#### *Identification of the gingival margin level*

The level of the gingival margin can change over time in response to trauma, medications, or disease. Three possible relationships exist between the gingival margin and the cemento-enamel junction (CEJ) of the tooth.

1. *Gingival margin is at the CEJ.* This is the natural position of the gingival margin (fig. 31).

2. *Gingival margin significantly covers the CEJ.* In this instance, the gingiva covers

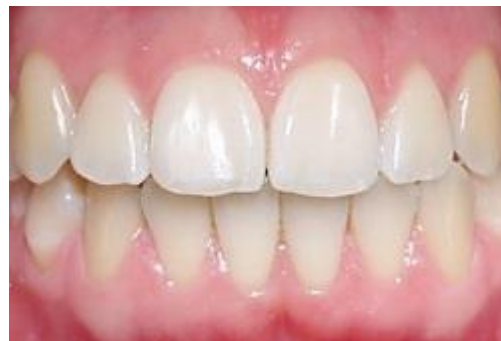

Fig. 31. Natural position of the gingival margin

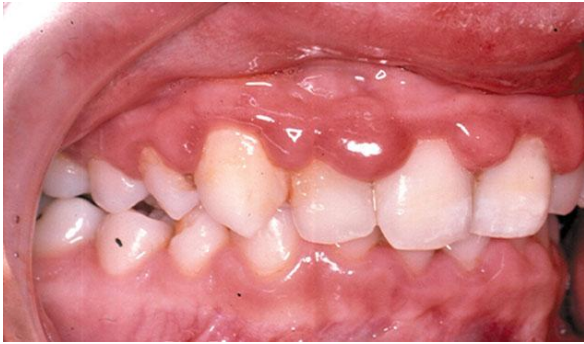

Fig. 32. Gingival margin significantly covers the CEJ

a significant portion of the tooth crown. The position of the gingival margin may be coronal to the CEJ owing to (1) swelling (edema) (fig. 32), (2) an overgrowth of the gingival tissues caused by certain medications that a patient takes to treat a medical condition, and/or (3) an increase in the fibrous connective tissue of the gingiva caused by a long-standing inflammation of the tissue.

3. *Gingival margin is significantly apical to the CEJ.* When the gingival margin is significantly apical to the CEJ, a portion of the root surface is exposed in the mouth. This relationship is known as gingival recession. Gingival recession is the movement of the gingival margin from its normal position — usually with underlying loss of bone — resulting in the exposure of a portion of the root surface.

*Technique to determine the gingival margin level*

When tissue swelling or recession is present, a periodontal probe is used to measure the distance that the gingival margin is apical or coronal to the CEJ.

If gingival recession is present, the distance between the CEJ and the gingival margin is measured using a calibrated periodontal probe. This distance is recorded as the gingival margin level. If the gingival margin covers the CEJ, the distance between the margin and the CEJ is estimated using the following technique:

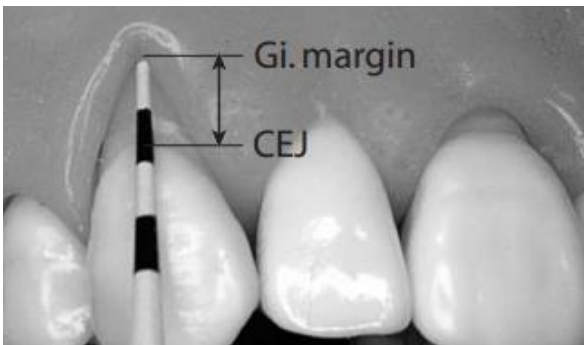


Fig. 33. Gingival margin is significantly apical to the CEJ; Technique to determine the gingival margin level

STEP 1: position the tip of the probe at a 45-degree angle to the tooth;

STEP 2: slowly move the probe beneath the gingival margin until the junction between the enamel and cementum is detected;

STEP 3: measure the distance between the gingival margin and the CEJ. This distance is recorded as the gingival margin level (fig. 33).

*Presence and magnitude of gingival recession*

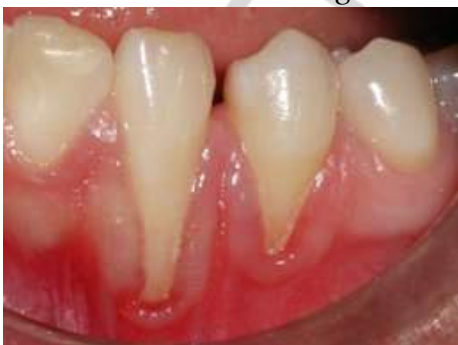

Fig. 34. Gingival recession

*Gingival recession* refers to the progressive loss of gum and bone tissue, which can eventually result in tooth root exposure if left untreated (fig. 34). Gum recession is most common in adults over the age of 40, but the process can begin as young as seven, when a tooth begins to erupt in the mouth.

Typical causes of recession are trauma, periodontitis, tooth position or local inflammation

(Wennstrom and Prato 2003). Periodontitis associated recession defects are caused because the alveolar bone supports the gingiva. When the bone is lost, the gingiva becomes unsupported.

*Classification of recession*

Several classification schemes have been used to help diagnose gingival recession. The most commonly used is the Miller's classification (1985). According to Miller's classification, gingival recession can be divided into 4 categories (table 7):

Table 7

**Gingival recession classification (Miller's, 1985)**

<p><i>Class I</i> Marginal tissue recession which does not extend to the mucogingival junction (MGJ). There is no alveolar bone loss or soft tissue loss in the inter-dental area. Complete root coverage obtainable (fig. 35)</p>	<p><i>Class III</i> Marginal tissue recession which extends to/or beyond the MGJ. Bone or soft tissue loss in the interdental area is present. Partial root coverage related to level of papilla height (fig. 37)</p>
<p><i>Class II</i> Marginal tissue recession which extends to/or beyond the MGJ. There is no alveolar bone loss or soft tissue loss in the interdental area. Complete root coverage obtainable (fig. 36)</p>	<p><i>Class IV</i> Marginal tissue recession which extends to/or beyond the MGJ. The bone or soft tissue loss in the interdental area is present with gross flattening. No root coverage (fig. 38)</p>

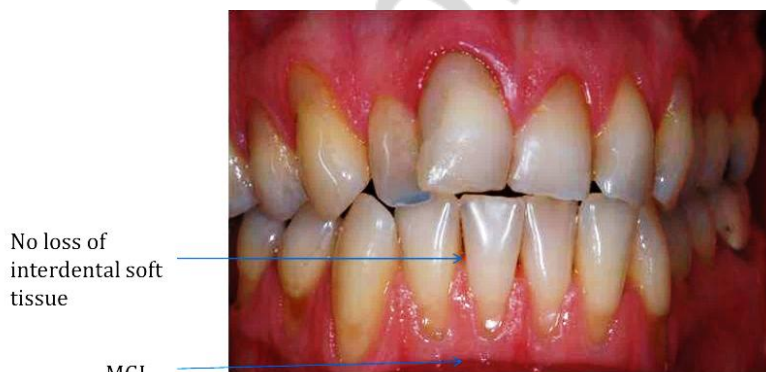

Fig. 35. Gingival recession, Class I

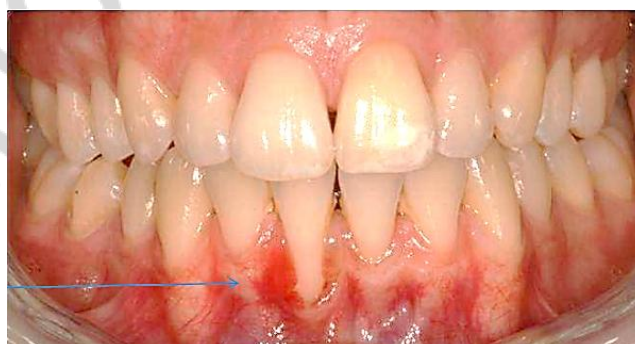

Fig. 36. Gingival recession, Class II



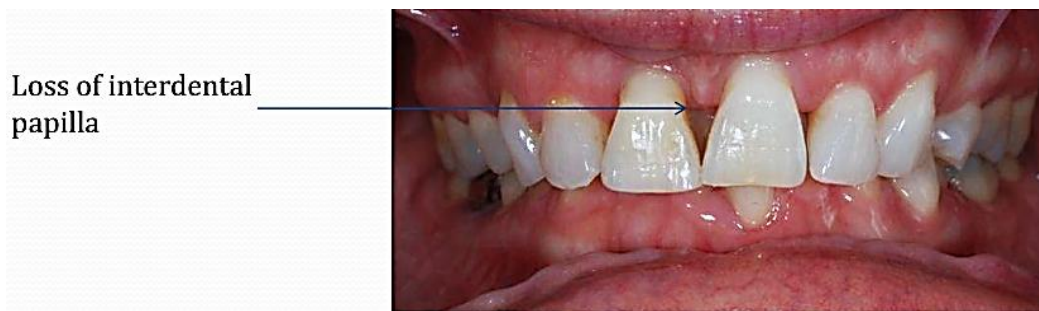

Fig. 37. Gingival recession, class III

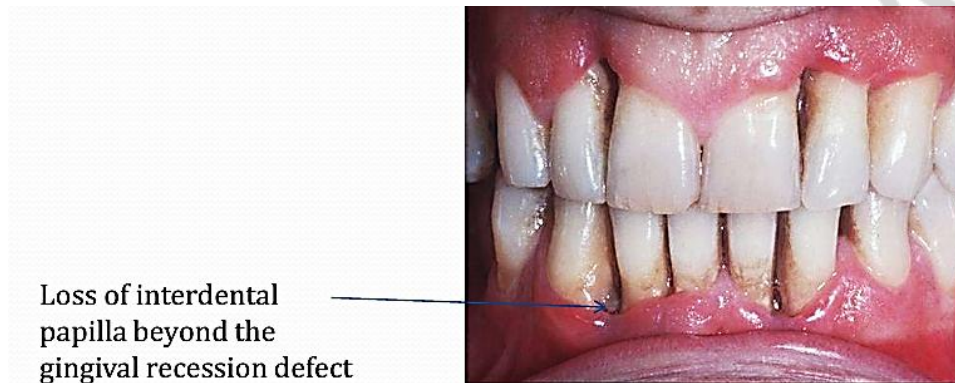


Fig. 38. Gingival recession, Class IV

There are also 2 types of gingival recession in terms of prevalence — localized and generalized — and severity: (1) light (up to 1 mm); (2) moderate severity (3–5 mm); (3) severe (6 mm, or more).

The following symptoms may be indicative of gum recession:

- *Sensitive teeth* — when the gums recede enough to expose the cementum protecting the tooth root, the dentin tubules beneath will become more susceptible to external stimuli;

- *Visible roots* — this is one of the main characteristics of a more severe case of gum recession;

- *Longer-looking teeth* — individuals experiencing gingival recession often have a “toothy” smile. The length of the teeth is perfectly normal, but the gum tissue has been lost, making the teeth appear longer;

- *Halitosis, inflammation and bleeding* — these symptoms are characteristic of gingivitis or periodontal disease. A bacterial infection causes the gums to recede from the teeth and may cause tooth loss if not treated promptly.

#### *Furcation involvement*

A furcation is the place on a multirooted tooth where the root trunk divides into separate roots. The furcation is termed a bifurcation on a two-rooted tooth and a trifurcation on a three-rooted tooth.

In health, the furcation area cannot be probed because it is filled with alveolar bone and periodontal ligament fibers. *Furcation involvement* is loss of alveolar bone and periodontal ligament fibers in the space between the roots of a multirooted tooth. Furcation involvement results when periodontal infection

invades the area between/and around the roots. It frequently signals a need for periodontal surgery after completion of periodontal debridement. Therefore, detection and documentation of furcation involvement is a critical component of the comprehensive periodontal assessment.

A furcation probe is a type of periodontal probe used to evaluate the bone support in the furcation areas of bifurcated and trifurcated teeth. Furcation probes have curved, blunt-tipped working-ends that allow easy access to the furcation areas (Naber's probe) (fig. 39).

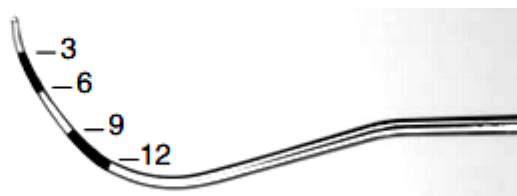

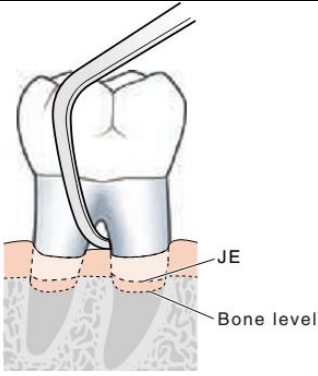
Fig. 39. Example of furcation probe

Table 8 shows a common furcation-rating scale and charting symbols.

Table 8

### Furcation Involvement Classification

Class	Description	
<b>I</b>		<p>The concavity — just above the furcation entrance — on the root trunk can be felt with the probe tip; however, the furcation probe cannot enter the furcation area</p>
<b>II</b>		<p>The probe is able to partially enter the furcation — extending approximately one third of the width of the tooth — but it is not able to pass completely through the furcation</p>
<b>III</b>		<p><i>In mandibular molars</i>, the probe passes completely through the furcation between the mesial and distal roots. <i>In maxillary molars</i>, the probe passes between the mesiobuccal and distobuccal roots and touches the palatal root</p>

IV		Same as a Class III furcation involvement except that the entrance to the furcation is visible clinically owing to tissue recession
----	---	---

#### *Determination of tooth mobility*

The method of tooth mobility determination and different types of tooth mobility are described on page 8–9.

#### *Assessment of dental hard tissues*

For dental hard tissues assessment dentist should be familiar with the tooth numbering systems. The three tooth designations systems in general use are the *Universal or Continuous Numbers 1 through 32*, adopted by the American Dental Association; the *FDI Two-Digit tooth numbering systems*, adopted by the World Dental Federation; and the *Palmer or Quadrant Numbers 1 through 8*. Because different systems are used in dental offices and clinics, it is necessary to be familiar with all of them.

#### *Universal, or ADA system*

This tooth numbering method is referred to as *the universal, or ADA system* (fig. 40).

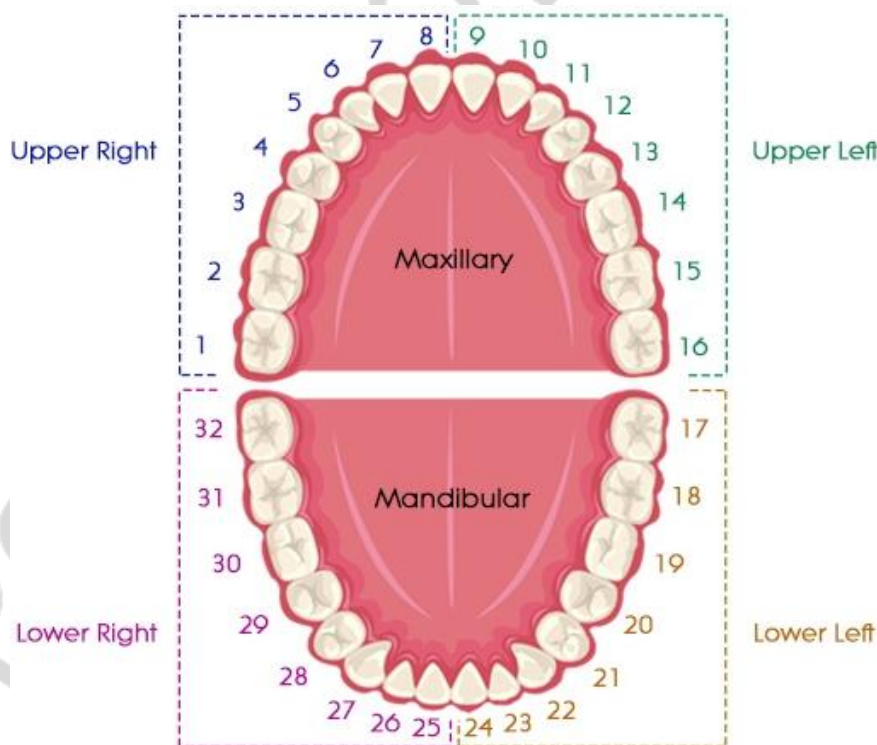


Fig. 40. Universal, or ADA system for permanent teeth

*Permanent Teeth* start with the right maxillary third molar (number 1) and follow around the arch to the left maxillary third molar (number 16); descend to the left mandibular third molar (number 17); and follow around to the right mandibular third molar (number 32). For *Primary or Deciduous Teeth* dentists use continuous upper case letters (fig. 41). A through T in the same order as described for the permanent teeth: right maxillary second molar (A) around to left maxillary second molar (J); descend to the left mandibular second molar (K); and around to the right mandibular second molar (T).

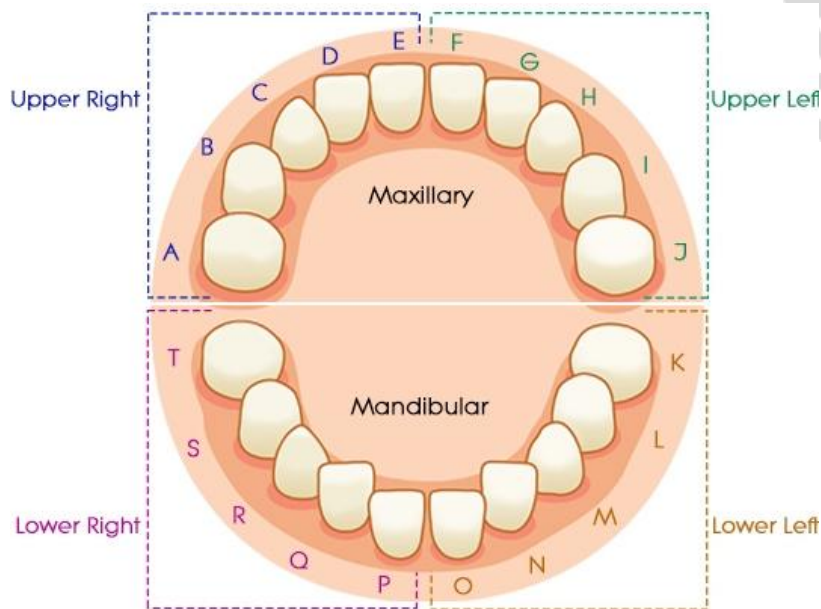


Fig. 41. Universal, or ADA system for primary teeth

*The Palmer Notation Numbering System* is used by some orthodontists, pedodontists, and oral surgeons. The mouth is divided into four sections called quadrants. The numbers 1 through 8 and a unique symbol is used to identify the teeth in each quadrant. The numbering runs from the center of the mouth to the back. In the upper right quadrant tooth, number 1 is the incisor. The numbers continue to the right and back to tooth number 8, which is the third molar. The numbers sit inside an L-shaped symbol used to identify the quadrant. The L is right side up for the teeth in the upper right quadrant. The teeth in the upper left use a backwards L. For the bottom quadrants, the L is upside down following the same pattern from the uppers. In children, the Palmer Notation System uses uppercase letters instead of numbers. Following the same order as for adult's teeth, children's 20 primary teeth are lettered "A" through "E" in each quadrant. The same symbol is used to identify the quadrants (fig. 42).

*The Federation Dentaire Internationale Numbering System (FDI)*. Internationally the two-digit system is used worldwide. Every branch of dentistry uses this system. Each quadrant is assigned a number. The maxillary right quadrant is assigned the number 1, the maxillary left quadrant is assigned the number 2, the mandibular left quadrant is assigned the number 3, and the mandibular right quadrant is assigned the number 4 (fig. 43).



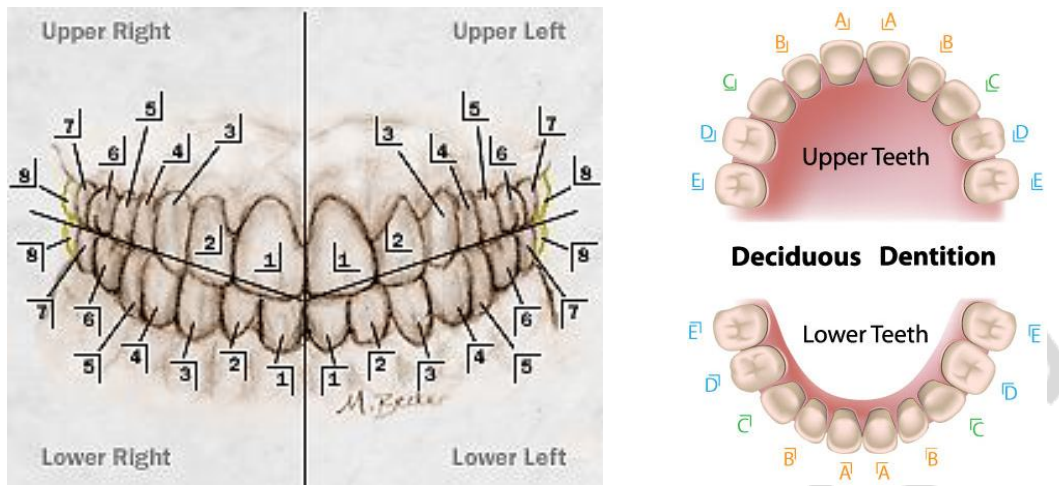


Fig. 42. The Palmer Notation Numbering System

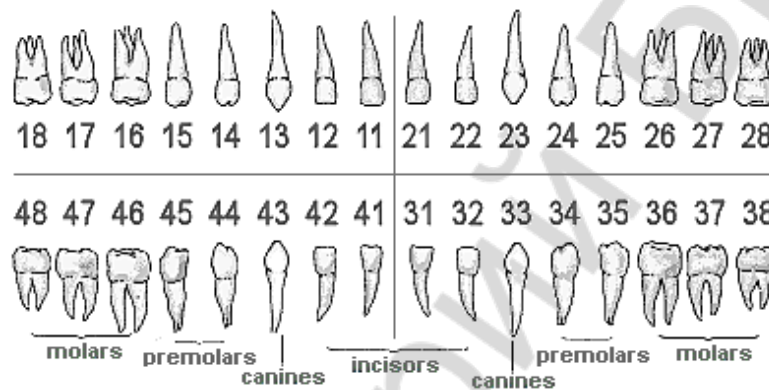


Fig. 43. Federation Dentaire Internationale Numbering System for Permanent Teeth

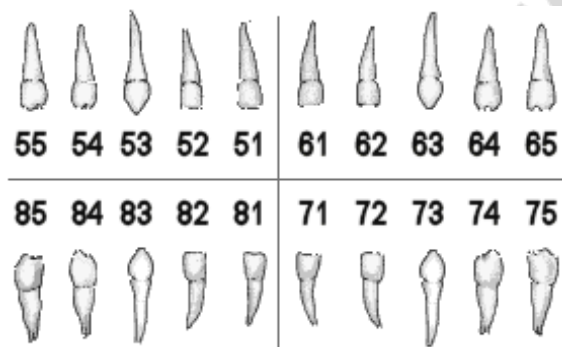


Fig. 44. Federation Dentaire Internationale Numbering System for Primary Teeth

In the primary dentition, the numbers 5–8 are used for the corresponding quadrants (fig. 44). The teeth within each quadrant are assigned a number from 1 through 8 or 1 through 5 with 1 being the central incisor and 8 being the third molar in permanent dentition and 1 being the central incisor and 5 being the second molar in primary dentition. In using the FDI system, the quadrant number is recorded first followed by the tooth number.

For example, the mandibular right first molar in the permanent dentition is noted as 46 and in the primary dentition as 84. When verbally reading the two-digit notation, each number is read separately; 23 would be read as “two, three”.

Examination of teeth is performed in a specific order, starting with 18 and ending with a tooth 48 according to FDI system. In this case, you should pay attention to proper lighting and proper position of the dentist.

*Characteristic of the early stages of carious disease (criteria of visual diagnostics)*

Spots on the teeth are estimated after preliminary drying. The estimation is made on the following criteria:

- color: white, white-yellow, light brown, brown;
- gloss: matt, shiny, matt fragmentary;
- localization: In the cervical area, closer to the equator.

Active carious process is characterized by a homogeneous white opaque spots localized in the cervical area of the tooth. Change in color to yellow or brown and the appearance of gloss in the spot area are the evidence of carious process stabilization.

### **Determining the intensity of caries using the Decayed-Missing-Filled Index (DMF) which was introduced by Klein, Palmer and Knutson in 1938 and modified by WHO**

The DMF components are:

**D component:** used to describe (Decayed teeth) which include:

1. Carious tooth.
2. Filled tooth with recurrent decay.
3. Only the roots are left.
4. Defect filling with caries.
5. Temporary filling.
6. Filled tooth surface with other surface decayed.

**M component:** is used to describe missing teeth due to caries; other cases should be excluded. These are:

1. Teeth extracted for reasons other than caries should be excluded; it includes:

- a) orthodontic treatment;
- b) impaction;
- c) periodontal disease.

2. Unerupted teeth.
3. Congenitally missing.
4. Avulsion teeth due to trauma or accident.

**F component:** used to describe (filled teeth due to caries). Teeth were considered filled without decay when one or more permanent restorations were present, and there was no secondary (recurrent) caries or other area of the tooth with primary caries. A tooth with a crown placed because of previous decay was recorded in this category. Teeth stored for reason other than dental caries should be excluded; it includes:

1. Trauma (fracture).
2. Hypoplasia (cosmetic purposes).
3. Bridge abutment (retention).
4. Seal a root canal due to trauma.
5. Fissure sealant.
6. Preventive filling.

A tooth is considered to be erupted when just the cusp tip of the occlusal surface or incisor edge is exposed. The excluded teeth in the DMF index are:

1 — Supernumerary teeth.

2 — The third molar (according to Klein, Palmer and Knutson only).

Limitations for DMF index: it can be invalid in older adults or in children because DMF index can overestimate caries record by cases other than dental caries.

A tooth may have several restorations but is counted as one tooth, F. A tooth may have restoration on one surface and caries on the other; it should be counted as decayed D. No tooth must be counted more than once, D M F or sound.

Calculation of DMFT:

For individual:  $DMF = D + M + F$ .

For population:  $Mean\ DMF = \frac{Total\ DMF}{Total\ No.\ of\ the\ subjects\ examined}$

Maximum score:  $DMF = 32$  or  $28$ .

Minimum score:  $DMF = Zero$ .

After visual inspection the dentist initiates clinical tests described on pages 9–11.

## INDEX RATING

Indices and scoring methods are used in clinical practice and community programs to determine and record the state of health of individuals and groups. In clinical practice, an index, biofilm record, or scoring system for an individual patient can be used for education, motivation, and evaluation. The effects of personal disease control efforts, the progress of healing between professional treatments, and the maintenance of health over time can be monitored.

Index assessment of dental health:

- provides individual assessment to help a patient recognize an oral problem;
- reveals the degree of effectiveness of present oral hygiene practices;
- motivates the person in preventive and professional care for the elimination and control of oral disease;
- evaluates the success of individual and professional treatment over a period of time by comparing index scores.

*OHI-S, PHP indices — patient's oral hygiene status determining (as a major risk factor of dental diseases).*

**SIMPLIFIED ORAL HYGIENE INDEX (OHI-S)** (Greene and Vermillion, 1964)

I. *Purpose.* To assess oral cleanliness by estimating the tooth surface covered with debris and/or calculus.

II. *Components.* The OHI-S has two components, the Simplified Debris Index (DI-S) and the Simplified Calculus Index (CI-S). The two scores may be used separately or may be combined for the OHI-S.

### III. Selection of teeth and surfaces.

#### A. Identify the Six Specific Teeth.

1. Posterior. The first fully erupted tooth distal to each second premolar is examined. The facial surfaces of the maxillary molars and the lingual surfaces of the mandibular molars are used. Although usually the first molars are used, the second or third molars also may be used.

2. Anterior. The facial surfaces of the maxillary right and the mandibular left central incisors are used. When either is missing, the adjacent central incisor is scored.

#### B. Extent.

A score represents half the circumference of the selected tooth; it includes proximal surfaces to the contact areas.

*IV. Method.* Visually examine with a dental probe (tip of the probe gently sliding from the edge of the crown of the tooth toward the gingiva) six key teeth: buccal surface of teeth 16 and 26; lip surface of teeth 11 and 31; lingual surface of teeth 36 and 46 (fig. 45). Determine the plaque and dental calculus.

At least two of the six possible surfaces must have been examined for an individual score to be calculated.

*OHI-S Debris (dental biofilm, materia alba, and food debris) Criteria (fig. 46):*

0 — No debris or stain present.

1 — Soft debris covering not more than one third of the tooth surface being examined, or the presence of extrinsic stains without debris, regardless of surface area covered.

2 — Soft debris covering more than one third but not more than two thirds of the exposed tooth surface.

3 — Soft debris covering more than two thirds of the exposed tooth surface.

*OHI-S Calculus Criteria (fig. 47):*

0 — No calculus present.

1 — Supragingival calculus covering not more than one third of the exposed tooth surface being examined.

2 — Supragingival calculus covering more than one third but not more than two thirds of the exposed tooth surface, or the presence of individual flecks of subgingival calculus around the cervical portion of the tooth.

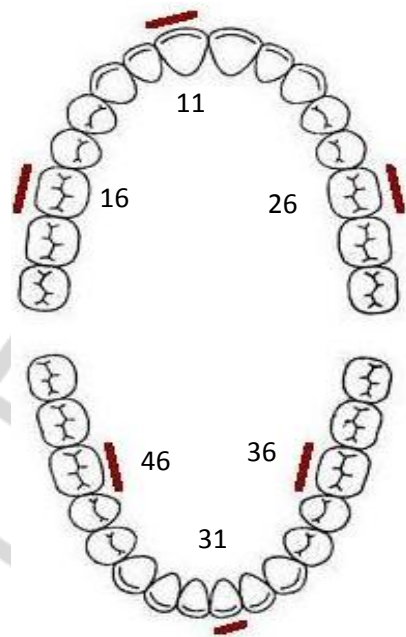


Fig. 45. Key Teeth Surfaces in OHI-S Index

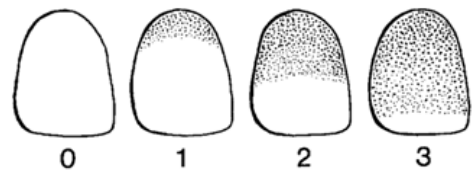


Fig. 46. OHI-S Debris Criteria

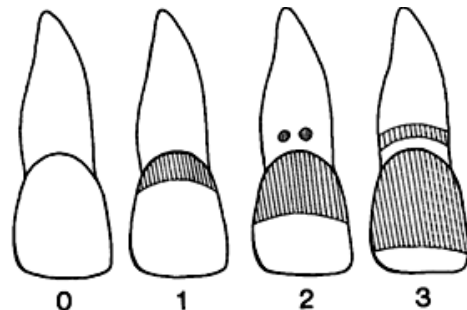


Fig. 47. OHI-S Calculus Criteria



3 — Supragingival calculus covering more than two thirds of the exposed tooth surface or a continuous heavy band of subgingival calculus around the cervical portion of the tooth.

*OHI-S Scoring:* Combine the DI-S and CI-S and divide total scores by the number of sextants. OHI-S value ranges from 0 to 6.

*OHI-S interpretation* is presented in table 9.

Table 9

OHI-S interpretation		
Meaning of OHI-S	Evaluation OHI-S	Evaluation of oral hygiene
< 0.6	low	excellent
0.7 - 1.6	average	good
1.7 - 2.5	high	fair
> 2.6	very high	poor

*OHI-S example*

2 2	0 2	1 2
2 2	2 2	2 2

$$DI-S = \frac{\text{Total debris scores}}{\text{Number of teeth scored}} = \frac{8}{6} = 1.3$$

$$CI-S = \frac{\text{Total calculus scores}}{\text{Number of teeth scored}} = \frac{12}{6} = 2$$

$$OHI-S = DI-S + CI-S = 1.3 + 2 = 3.3.$$

Interpretation: According to the suggested range of scores, the score for this individual (3.3) indicates a poor oral hygiene status.

*PATIENT'S HYGIENE PERFORMANCE (PHP)* (Podshadley and Haley, 1968)

I. *Purpose.* To assess the extent of biofilm and debris over a tooth surface Debris is defined for the PHP as the soft foreign material consisting of dental biofilm, materia alba, and food debris that is loosely attached to tooth surfaces.

II. *Selection of teeth and surfaces.* Examined teeth and surfaces are the same as those used for the Simplified Oral Hygiene Index (fig. 45).

III. *Procedure.* Apply disclosing agent.

Examination is made using a mouth mirror. Each tooth surface to be evaluated is subdivided (mentally) into five sections as follows: vertically: three divisions — mesial, middle, and distal; horizontally: the middle third is subdivided into gingival, middle, and occlusal or incisal thirds (fig. 48).

Each of the five subdivisions is scored for the presence of stained debris as follows: 0 — No debris (or questionable); 1 — Debris definitely present.

*Debris Score for Individual Tooth:* add the scores for each of the five subdivisions. The scores range from 0 to 5.

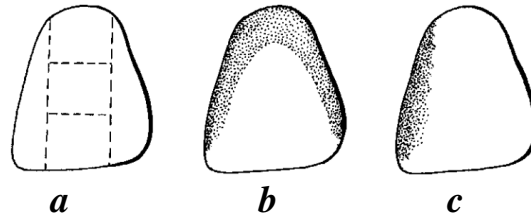


Fig. 48. *a* — oral debris is assessed by dividing a tooth into 5 subdivisions, each of which is scored 1 when debris is shown to be present after use of a disclosing agent; *b* — example of debris score of 3; *c* — example of debris score of 1

*PHP for the Individual:* Summarize the scores for the individual teeth and divide by the number of teeth examined. The PHP ranges from 0 to 5.

*PHP interpretation* is presented in table 10.

Table 10

**PHP interpretation**

Rating Scores	
Excellent	0 (no debris)
Good	0.1–1.7
Fair	1.8–3.4
Poor	3.5–5.0

*DMF index for determining hard dental tissues status* is described on pages 29–30.

*Gingival and Periodontal indices*

*Gingival (gum) index (GI)*

The Gingival Index (Löe and Silness, 1963) was created for the assessment of the gingival condition and records qualitative changes in the gingiva. Key teeth, gums which are examined: 16, 21, 24, 36, 41, 44. Each tooth is examined in four areas: vestibular-distal papilla, vestibular marginal gingiva, vestibular-medial papilla, lingual (or palatal) marginal gingiva. GI scores the marginal and interproximal tissues separately on the basis of 0 to 3. The criteria are:

0 = Normal gingiva;

1 = Mild inflammation — slight change in color and slight edema but no bleeding on probing;

2 = Moderate inflammation — redness, edema and glazing, bleeding on probing;

3 = Severe inflammation — marked redness and edema, ulceration with tendency to spontaneous bleeding.

The bleeding is assessed by probing gently along the wall of soft tissue of the gingival sulcus. The scores of the four areas of the tooth can be summed and divided by four to give the GI for the tooth. The GI of the individual can be obtained by adding the values of each tooth and dividing by the number of teeth examined. The Gingival Index may be scored for all surfaces of all/or selected teeth or for selected areas of all/or selected teeth. The GI may be used for the assessment of prevalence and severity of gingivitis in populations, groups and individuals.

GI score 0.1–1.0 = mild inflammation;  
 1.1–2.0 = moderate inflammation;  
 2.1–3.0 signifies severe inflammation.

The GI has been used frequently in clinical trials of therapeutic agents.

*GI Example*

2	1	2	1	1	2	1	2
	1		1	1		1	
1	1	1	1	1	1	1	1
	1		1	1		1	

$$= 28/4/6 = 1.2 \text{ (moderate inflammation)}$$

*The Community Periodontal Index of Treatment Needs (CPITN) and Comprehensive Periodontal Index (CPI) are described on pages 18–20.*

#### ***Additional diagnostic tests***

These methods include physical (related to physical factors), laboratory and instrumental studies.

## **DENTAL RADIOGRAPHIC EXAMINATIONS**

Radiographs and other imaging modalities are used to diagnose and monitor oral diseases, as well as to monitor dentofacial development and the progress or prognosis of therapy. Radiographic examinations can be performed using digital imaging or conventional film.

*Indications for the X-ray examination:*

– To identify hidden cavities: on the contact surfaces of teeth; under artificial crowns; identification of other inaccessible for inspection foci which contribute to the development of pulp inflammation (periodontal pocket, etc.).

– To determine: the depth of caries; the proximity of the cavity bottom to the pulp; the proximity of the filling material to the pulp, etc.

– For differential diagnosis of caries, pulpitis and different types of apical periodontitis.

– In case of teeth or jaws injury, which can lead to the pulp inflammation.

Types of X-ray:

– film.

– digital.

Digital imaging uses standard radiology technique with film to record the image, and then subjects the finished image to digital processing to produce the final result. Digital radiography has the following advantages: the amount of information available from these radiographs is greater than from the radiographs that have not been digitized; the storage of radiographs and quality of image is better; photographs of radiographs can be produced. But the radiation dose to the patient while using digital radiography is the same as that used for conventional radiographs.

Types of X-ray:

1) *intraoral*:

- bisecting angle technique (isometric);
- paralleling technique;
- bitewing radiography;
- occlusal radiography;

2) *extraoral*:

- orthopantomography;
- computed tomography.

*Intraoral Periapical Radiographs (IOPA)* are used to record the crowns, roots and surrounding bone. Size of IOPA films:

- size 0: for small children ( $22 \times 35$  mm);
- size 1: anterior teeth ( $24 \times 40$  mm);
- size 2: adults ( $31 \times 41$  mm);
- size 3: bitewings of adults ( $27 \times 54$  mm).

In *bisecting angle technique* the X-ray beam is directed perpendicular to an imaginary plane which bisects the angle formed by recording plane of X-ray film and the long axis of the tooth (fig. 49). This technique can be performed without the use of film holders, it is quick and comfortable for the patient when rubber dam is in place. But it also has certain disadvantages such as incidences of cone cutting, image distortion, superimposition of anatomical structures and difficulty to reproduce the periapical films.

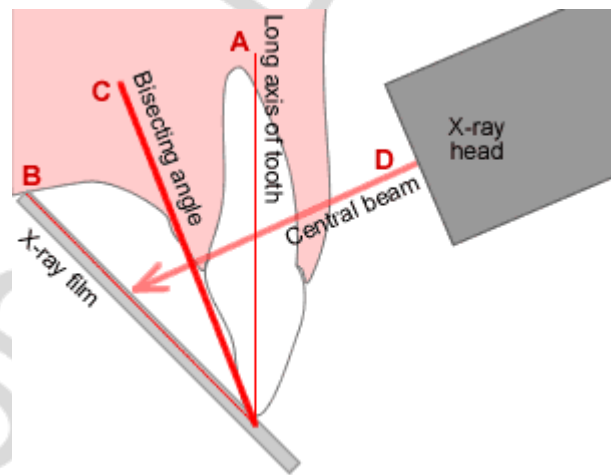


Fig. 49. Bisecting Angle Technique

*Advantages of the bisected angle technique:*

- positioning of the film packet is reasonably comfortable for the patient in all areas of the mouth;
- positioning is relatively simple and quick.
- if all angulations are assessed correctly, the image of the tooth will be the same length as the tooth itself and should be adequate (but not ideal) for most diagnostic purposes.

*Disadvantages of the bisected angle technique:*

- The many variables involved in the technique often result in the image being badly distorted.
- Incorrect vertical angulation will result in foreshortening or elongation of the image.
- The periodontal bone levels are poorly shown.
- The shadow of the zygomatic buttress frequently overlies the roots of the upper molars.

- The horizontal and vertical angles have to be assessed for every patient and considerable skill is required.
- It is not possible to obtain reproducible views.
- Coning off or cone cutting may result if the central ray is not aimed at the centre of the film, particularly if using rectangular collimation.
- Incorrect horizontal angulation will result in overlapping of the crowns and roots.
- The crowns of the teeth are often distorted, thus preventing the detection of approximal caries.
- The buccal roots of the maxillary premolars and molars are foreshortened.

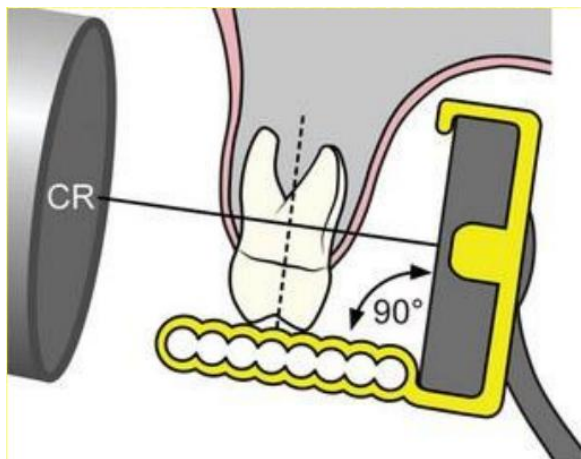


Fig. 50. Paralleling Technique

*In paralleling technique* the X-ray film is placed parallel to the long axis of the tooth to be exposed and the X-ray beam is directed perpendicular to the film (fig. 50). This technique has advantages such as better accuracy of image; reduced dose of radiation; reproducibility; better images of bone margins, interproximal regions and maxillary molar region. Paralleling technique has also certain disadvantages: e. g. it is difficult to use in patients with shallow vault; gag reflex, when rubber dam is in place; extremely long roots; uncooperative patients; tori.

*Advantages of the paralleling technique:*

- Geometrically accurate images are produced with little magnification. The shadow of the zygomatic buttress appears above the apices of the molar teeth.
- The periodontal bone levels are well represented.
- The periapical tissues are accurately shown with minimal foreshortening or elongation.
- The crowns of the teeth are well shown enabling the detection of approximal caries.
- The horizontal and vertical angulations of the X-ray tube head are automatically determined by the positioning devices if placed correctly.
- The X-ray beam is aimed accurately at the centre of the film — all areas of the film are irradiated and there is no coning off or cone cutting.
- Reproducible radiographs are possible at different visits and with different operators.
- The relative positions of the film packet, teeth and X-ray beam are always maintained, irrespective of the position of the patient's head. This is useful for some patients with disabilities.

*Disadvantages of the paralleling technique:*

- Positioning of the film packet can be very uncomfortable for the patient, particularly for posterior teeth, often causing gagging.
- Positioning the holders within the mouth can be difficult for inexperienced operators.
- The anatomy of the mouth sometimes makes the technique impossible, e. g. a shallow, flat palate.
- The apices of the teeth can sometimes appear very near the edge of the film.
- Positioning the holders in the lower third molar regions can be very difficult.
- The technique cannot be performed satisfactorily using a short focal spot to skin distance (i. e. a short spacer cone) because of the resultant magnification.
- The holders need to be autoclavable or disposable.

*Bitewing radiographs* include the crowns of maxillary and mandibular teeth and alveolar crest in the same film (fig. 51). It is a reliable method for estimation of the proximal tooth surfaces before they are detected clinically, because these areas usually are not readily assessed visually or tactilely. It is especially important to detect incipient lesions at the contact points. In bitewing films, we can also note the height of the alveolar crest, cervical margins of the restoration, lamina dura and pulp cavity.

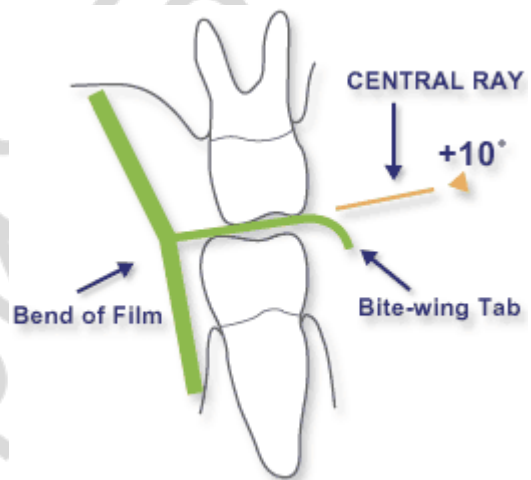


Fig. 51. Bitewing Radiographs Technique

Bitewing radiographs are divided into two types:

1. Horizontal bitewing films. In this technique, beam is aligned between the teeth parallel to occlusal plane.
2. Vertical bitewing film. In this technique, the film is oriented vertically so as to record more of root area. It is done in cases of extensive bone loss.

Bitewing radiographs help in detecting interproximal caries (fig. 52); evaluating periodontal conditions and secondary caries under restorations; assessing alveolar bone crest and changes in bone height by comparing it with adjacent teeth.

*Occlusal Radiographs* are used in the evaluation of entire maxillary arch or mandibular arch (fig. 53). Size: 57 × 76 mm. It is useful to view the maxilla for anterior alveolar fractures, cysts, supernumerary teeth and impacted canines, and to view pathology at the apices of the incisors. It is not used to diagnose periodontal conditions, to view the anterior portion of the mandible for fractures, cysts, root tip and periapical pathology. It provides a very good view of the symphysis region of the mandible.



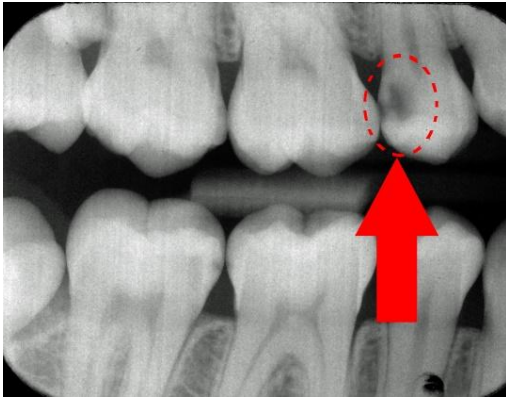


Fig. 52. Caries Approximal Decay on Bitewing Radiograph

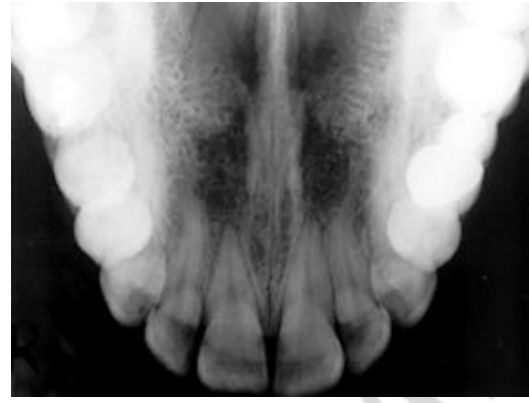
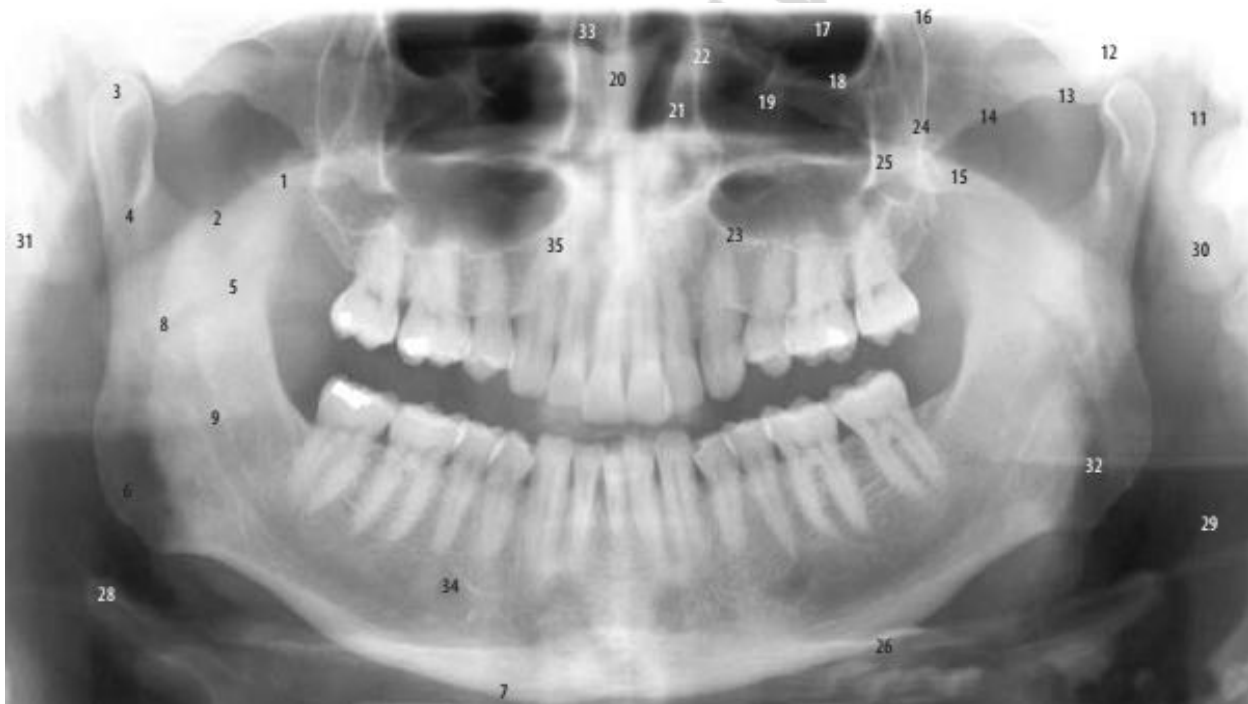

Fig. 53. Occlusal Radiograph

### Extraoral Radiographs Orthopantomography

Records a single image of facial structures including both maxillary and mandibular arches and their supporting structure (fig. 54). Panoramic radiography is a modified type of tomography or image layer radiography. It's also known as "pantomography" or "Rotational panoramic radiography". Size: 6 × 12 inch and 5 × 12 inch.



- |                                |                               |                                       |                             |
|--------------------------------|-------------------------------|---------------------------------------|-----------------------------|
| 1. Coronoid Process            | 12. Glenoid Fossa             | 23. Inferior Border of Max. Sinus     | 32. Oropharyngeal Air Space |
| 2. Sigmoid Notch               | 13. Articular Eminence        | 24. Posterolateral Wall of Max. Sinus | 33. Nasal Air Space         |
| 3. Mandibular Condyle          | 14. Zygomatic Arch            | 25. Malar Process                     | 34. Mental Foramen          |
| 4. Condylar Neck               | 15. Pterygoid Plates          | 26. Hyoid Bone                        | 35. Hard Palate             |
| 5. Mandibular Ramus            | 16. Pterygomaxillary Fissure  | 27. Cervical Vertebrae 1-4            |                             |
| 6. Angle of Mandible           | 17. Orbit                     | 28. Epiglottis                        |                             |
| 7. Inferior Border of Mandible | 18. Inferior Orbital Rim      | 29. Soft Tissues of Neck              |                             |
| 8. Lingula                     | 19. Infraorbital Canal        | (Look Vertically For Carotid          |                             |
| 9. Mandibular Canal            | 20. Nasal Septum              | Artery Calcifications Here)           |                             |
| 10. Mastoid Process            | 21. Inferior Turbinate        | 30. Auricle                           |                             |
| 11. External Auditory Meatus   | 22. Medial Wall of Max. Sinus | 31. Styloid Process                   |                             |

Fig. 54. Anatomical Structures Can Be Determined by a Panoramic Radiograph

The panoramic radiograph continues to offer today's dentist a unique patient view covering the entire dentition and surrounding structures, the facial bones and condyles, and parts of the maxillary sinus and nasal complexes.

Indications of OPG:

- evaluation of trauma;
- location of third molars;
- extensive disease;
- known or suspected large lesions;
- tooth development;
- retained teeth or root tips;
- developmental anomalies.

Panoramic films are not as defined or sharp as the images seen on intraoral films, consequently a panoramic film should not be used to evaluate and diagnose caries, periodontal disease, or periapical lesions.

*Cone beam-computed tomography imaging techniques.* It produces accurate 3-D images of the teeth and surrounding dentoalveolar structures (fig. 55). Computed tomography (CT) imaging, also referred to as a computed axial tomography (CAT) scan, involves the use of rotating X-ray equipment, combined with a digital computer, to obtain images of the body. Using CT imaging, cross sectional images of body organs and tissues can be produced. Though there are many other imaging techniques, CT imaging has the unique ability to offer clear images of different types of tissue. CT imaging can provide views of soft tissue, bone, muscle, and blood vessels, without sacrificing clarity. Other imaging techniques are much more limited in the types of images they can provide.

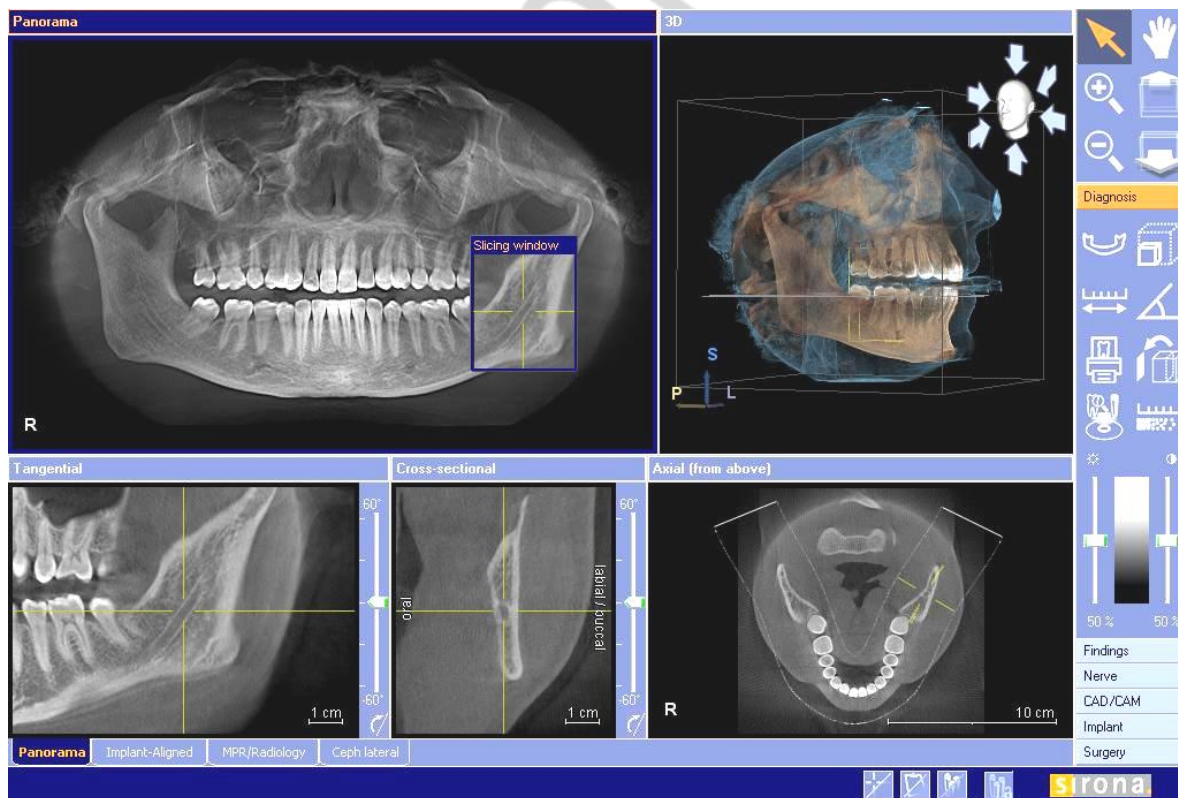


Fig. 55. Cone beam-computed tomography imaging techniques



CT imaging is commonly used for diagnostic purposes. In fact, it is a chief imaging method used in diagnosing a variety of diseases, including those affecting the lungs, pancreas, and liver. CT has been used for several years in medicine, and now the technology is being harnessed to provide better imaging for dentistry, allowing us to provide our patients the highest quality of care. Perhaps the most important advantage of CBCT in endodontics is that it demonstrates anatomic features in three dimensions that intraoral and panoramic images cannot. CBCT units reconstruct the projection data to provide interrelational images in three orthogonal planes (axial, sagittal and coronal). In addition, because reconstruction of CBCT data is performed natively using a personal computer, data can be reoriented in its true spatial relationships.

CBCT in Endodontics:

- anatomy of root canals.
- periapical lesions.
- root canal relationship with other anatomical structures.
- identification of errors and complications of endodontic treatment.

*CT — the gold standard for the determination of additional root canals!*

## **PRINCIPLES OF RADIOGRAPHIC INTERPRETATION**

Only a licensed dentist is permitted to prescribe radiographs. Radiographs are taken for a patient only after a thorough clinical examination has been completed and a clinical decision has been made that radiographs are indicated; that is, that the probable benefits to the patient at that stage outweigh the possible potential hazards. A clinical evaluation is essential even for asymptomatic patients undergoing routine dental examinations. A clinical assessment also determines the most appropriate view(s) that should be taken as well as the frequency. Radiographs are never taken “routinely”. It is ethically unsound to do so.

It is important to bear in mind that when one views a radiograph, one is looking at the image (shadow) of the object, and a radiograph is a two dimensional image of a three dimensional object. Thus, there must be sufficient density on a radiograph to be able to examine the radiograph(s). Areas that permit more rays to pass through, appear dark and are known as radiolucent areas. Areas that absorb more ionizing radiation are known as radiopaque areas and appear white or clear. Areas that have both radiopaque and radiolucent areas are known as mixed lesions.

It is very seldom that an area is made up completely of one shade. A combination of the black, mainly gray and white areas constitute the image. There are many shades of gray and the human eye is capable of detecting very subtle differences. There should be minimal or no distortion of the images as this can result in incorrect interpretation.

A radiograph is only one part of the diagnostic process. Usually one does NOT make a diagnosis solely from a radiograph. A diagnosis is made by the clinician once all the diagnostic information has been collected and analyzed

collectively. An interpretation or a differential diagnosis is made from the radiograph. The interpretation of a radiograph is accomplished in three steps, visualization, perception and integration of information received from the radiograph with that from other sources.

Also, one never makes use of a radiograph in cases where one can make use of other diagnostic tools; e. g. one never takes a radiograph to check the vitality or mobility of a tooth. The vitality of a tooth is checked with a pulp tester.

It is important always to use the correct terminology when discussing radiographs.

1. One examines a radiograph and NOT an X-ray. Bear in mind that an X-ray cannot be seen. An X-ray is a photon/beam of energy.

2. One does not see infection at the apex of a tooth. What one does see is the well/poorly demarcated radiolucency/opacity, X mm by Y mms in size at the apex of tooth number X.

3. For the same reason one does not speak about a periapical pathology in radiology.

4. Periodontal bone loss is not periodontitis per se.

5. Stay away from brand names. We do not have a panorex machine here. Use the word PANORAMIC radiograph or PAN.

6. In radiologic terminology, a PA is a postero-anterior view.

For optimal interpretive yield from a radiograph, it is important to observe the following guidelines.

1. Examine radiographs in a logical, systematic manner. Develop a routine of examining every radiograph from corner to corner.

- 1.1. Observe the difference between perception and visualization.

Perceptual inaccuracies include misinterpretation of size, content, or length [e. g. short gutta percha endo fill].

- 1.2. You only observe what you know or look for. It is important to know [radiographic] anatomy and pathology to be able to read a radiograph.

- 1.3. You must learn to think in terms of the third dimension.

2. Examine radiographs in a distraction-free environment.

3. Use uniform illumination of greater than 200 foot candles.

- 3.1. Reduce room illumination. [back ground].

- 3.2. and cover unused portions of the viewing box to be able to see subtle changes in gray.

4. Use a magnifying glass and a millimeter ruler to maximize the perception of image detail.

5. When an abnormality is found, do not neglect to examine the rest of the radiograph.

Never fall into the trap of seeing one problem and not carefully examining the rest of the radiograph.

6. Radiographs must be mounted in an opaque mount to mask out extraneous light.

7. Eye movement. Subtle differences in densities will not be observed by staring at one spot.

8. Viewing distance. Each person sees best at a certain distance.

9. All relevant findings must be recorded.

**When describing a lesion**, it is essential to discuss the

1. *Location / site*, e. g. left mandibular third molar region.

2. *Lesion* itself [e. g. radiolucent/opaque/mixed: unilocular/multilocular].

3. *Shape* round, oval, linear, saucer-shaped is a lesion that starts at the periphery of the bone.

4. *Borders*, poorly / well defined with regular/irregular borders.

5. *Size* in inches or mms, or cannot be estimated.

6. *Symmetry* usually indicates a variant of normal or an inherited condition.

7. *Relationship to other anatomy* [pushing into sinus / destroying the mandibular canal, causing root resorption, etc.].

Radiographically, examine bone, teeth and soft tissue separately.

**Bone.** If bone is abnormal, the radiograph can reveal 4 types of changes — increased radiolucency, [less trabeculations] increased radiopacity, a mixed lesion or a change in the alveolar trabecular pattern or outline of the bone.

**Teeth.** Always count the teeth [and roots] to observe missing or additional teeth or roots. Check for abnormal location of teeth, shape of teeth.

Then check the individual teeth, checking the

– enamel, [amelogenesis imperfecta, mulberry molar, etc.];

– dentin, [dens invaginatus or evaginatus, denticles etc.];

– pulp chamber [dentinogenesis imperfecta, odontogenesis imperfecta, odontodysplasia, taurodontism, individual obliteration of nerve canals, etc.];

– and nerve canal, [dentinogenesis imperfecta, individual obliteration of nerve canal etc.];

– apical area of the tooth, [root resorption, lucencies or opacities];

– periodontal ligament space [widened in early osteosarcoma (localized), scleroderma (generalized) [absent in hyperparathyroidism] and the amount of bone support.

In young people, check that the eruption pattern is normal and on schedule. Check periodontal ligament space.

**Soft tissue.** The examination of the radiographic appearance of soft tissue is all too often overlooked. This is particularly true on panoramic radiographs. If the clinical examination determines that soft tissue requires radiographic examination, request that the kVp be reduced when the patient is exposed. Soft tissue structures in the maxillofacial region are often seen; some examples are the tongue, soft palate, tip and ala of the nose, earlobe, etc.

**Existing diagnostic radiographs.** An effective way to reduce unnecessary radiation to the patient is to avoid retaking [recent] radiographs that already exist. It is the clinician's responsibility to obtain these records from earlier health providers where possible.

**Attaching significance to observations.** One only sees on a radiograph what one already knows and has seen on a radiograph previously. It is basic that one can recognize “normal” radiographic anatomy, otherwise one will not be able to recognize the pathology (abnormal). Certain features are highly suggestive or pathopneumonic of certain disease processes. As already stated, the interpretation of the changed radiographic pattern(s) require(s) a thorough background knowledge of both Anatomy and Pathology.

The diagnostic process is far from infallible. In any diagnostic procedure there are four possible outcomes:

1. True positive. The disease is present and correctly identified.
2. False positive. The disease was absent but something on the radiograph convinced the clinician that it was present.
3. True negative. No disease present and correctly determined.
4. False negative. Disease is present but not detected. Occurs much too often.

**Radiographic records.** The value of radiographs as a part of the integral records of a patient cannot be overstated. The information contained in a good radiograph is difficult to match with written records and the radiograph is usually more indisputable than a written statement in a court of law provided the name of the patient is indicated as well as the date. However, this is not a call to expose the patient to ionizing radiation merely for the sake of documentation.

One may not retake radiographs for the sake of improving one’s grades. Radiographs legally must be kept for at least 5 years; some authorities state 7 years.

**Documentation.** There is a clear medico-legal requirement for documentation of interpretation. For this reason a signed and dated radiographic report must be written and included in the patient’s record. It is also clinically useful in treatment planning and case presentation.

**Radiographic prescription.** Only a licensed dentist may prescribe radiographs and then only after an examination has been performed to determine which are the most appropriate radiographic views that will give the maximum amount of information, while exposing the patient to the minimum amount of ionizing radiation.

## **ELECTRIC PULP TESTING (EPT)**

Electric pulp tester is used for evaluation of condition of the pulp by electrical excitations of neural elements within the pulp (fig. 56, 57). The pulp tester is an instrument, which uses the gradations of electrical current to excite a response from the pulpal tissue. A positive response indicates the vitality of pulp. No response indicates nonvital pulp or pulpal necrosis.

Devices:

- EOM-1 (Russia);
- PULPOTESTER PT-1 (Lithuania);
- Digitest (USA).

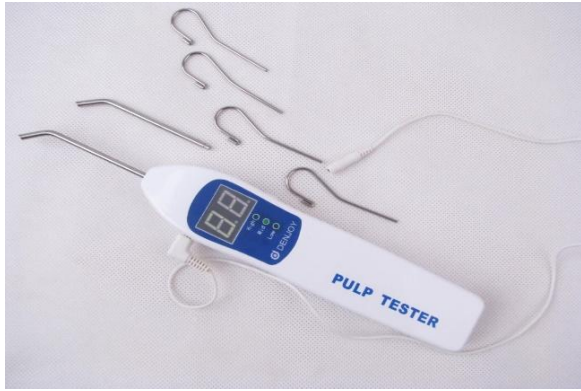


Fig. 56. Electric pulp tester

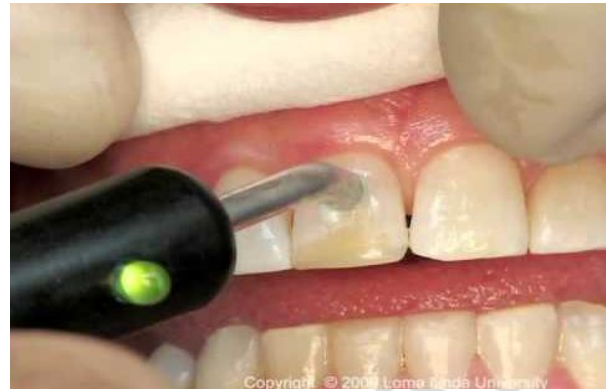

Fig. 58. Electric pulp test procedure

Table 11

**Correlation of EPT values to possible diagnosis**

Nosological form	Threshold values of amperage
Intact tooth	2–6 uA
Caries	2–10 uA
Hyperemia	12–18 uA
Acute pulpitis	20–30 uA
Suppurative pulpitis [pulpal abscess]	30–60 uA
Chronic pulpitis	40–60 uA
Chronic ulcerative pulpitis	60–90 uA
Chronic hyperplastic pulpitis [pulpal polyp]	50–70 uA
Necrosis of pulp (coagulation necrosis)	60–80 uA
Necrosis of pulp (Lique faction necrosis)	100 uA
Chronic apical periodontitis	More than 100 uA

*Disadvantages of electric pulp testing*

Following conditions can give rise to wrong results:

1. Electrode may contact gingival tissue thus giving the false positive response.
2. In multirooted teeth, pulp may be vital in one or more root canals and necrosed in others, thus eliciting a false positive response.
3. In teeth with acute alveolar abscess.
4. In certain conditions, it can give false negative response, for example:
  - Recently erupted teeth with immature apex.
  - Recently traumatized tooth.
  - Calcified canals.
  - Poor battery or electrical deficiency in plug of pulp testers.
  - Patients with high pain threshold.
  - Patients premedicated with analgesics or tranquilizers.
  - Teeth with extensive restorations or pulp protecting bases under restorations.



## DETERMINATION OF ALLERGY TO DENTAL MATERIALS

Dental products are widely used by patients and dental personnel as well, and may cause problems for both. Dental materials could cause contact allergy with varying manifestations such as burning, pain, stomatitis, cheilitis, ulcers, lichenoid reactions localized to the oral mucosa in patients, and hand dermatitis in dental personnel. Different allergic tests (blood test, skin test, patch testing with the dental series) comprising commonly used materials can be used to detect contact allergies to dental materials.

### LABORATORY TESTS

Laboratory tests (microbiological, immunological, biochemical and others) performed to detect pathogens of the periodontal diseases and oral mucosa. According to laboratory tests, the composition of plaque, the contents of periodontal pockets can be analyzed. There are the following methods of laboratory research:

*Bacteriological examination* followed by bacteriological differentiation and typing of microorganisms: determination of pathogens and their antibiotic sensitivity.

*Microscopic (morphological) examination* (histology, cytology) using light microscopy. In case of oral mucosa diseases researching material is taken from the tongue, buccal mucosa, from elements of destruction and other sites.

*Molecular biological research methods* (Polymerase Chain Reaction (PCR) and hybridization). Not live bacteria studied but the molecules of the bacteria. They are very accurate but expensive methods.

### LASER-INDUCED FLUORESCENCE (LF)

Diagnostic fluorescent methods are promising technologies that can be used for detection of dental caries, plaque, calculus and oral tumors.



Fig. 59. DIAGNOdent Device

Fluorescence is the process of absorption of light of a short wave length which results in emission of radiation at a longer wavelength. This emitted radiation is called fluorescence, as certain molecules (fluorophores) de-excite electronically from higher energy level to a lower energy level. This finding led to the development of the first dental chair side LF device by KaVo (Biberach, Germany) in 1999, called the DIAGNOdent (fig. 59). The DIAGNOdent is intended for use as an aid in detecting caries. It provides information to supplement the clinician's visual observations, consideration of patient's histories, and

information from other diagnostic modalities, resulting in an overall risk assessment and a treatment determination. It is not a stand alone diagnostic tool. DIAGNOdent may also be used as an aid in monitoring progression or arrestment of caries by comparing a patient's readings from visit to visit. All DIAGNOdent readings must be evaluated in the context of other diagnostic information.

Only caries on occlusal or flat surfaces of teeth, which are accessible to the probes, can be examined for caries. The DIAGNOdent does not detect interproximal caries, subgingival caries, or secondary caries under crowns, inlays, or composite/amalgam restorations.

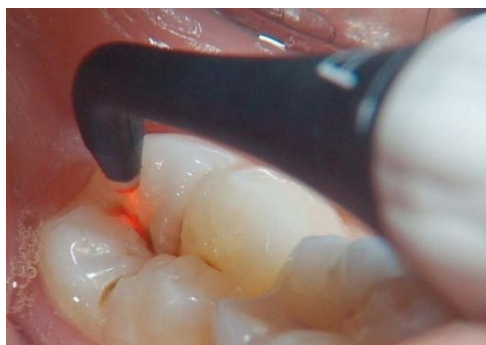


Fig. 60. DIAGNOdent Procedure

During examination of suspicious sites, the tip of the handpiece should be in light contact with the surface of the tooth and should be slowly rotated or rocked in a pendulum-like manner when contacting fissures or areas of concern, e. g., discoloration, enamel defects or areas that produce a sharp change in the audible signal (fig. 60). The higher the reading the greater the fluorescence of the site. The highest reading obtained can be referenced in the context of treatment considerations.

Table 12

**Correlation of DIAGNOdent values to possible course of action**

<b>Possible Course of Action*</b>					
<b>DIAGNOdent Values</b>	<b>No Action</b>	<b>Preventive Therapy</b>	<b>Record &amp; Monitor</b>	<b>Sealant</b>	<b>Preparation</b>
0-5	•				
5-10	•	•			
10-15	•	•	•	•	
15-20		•	•	•	
20-25		•***	•	•	•**
25-30		•***	•	•	•**
30+		•***			•

\* Taken from Lussi; See "Research Supporting DIAGNOdent Scale Readings". \*\* In unusual cases of virulent disease, preparation may be a course of action when a value between 20 and 30 is recorded. \*\*\* Regardless of course of action taken to treat a specific lesion, preventive therapy may be indicated based upon caries risk.

## **FIBROPTICAL TRANSILLUMINATION (FOTI)**

Optical transillumination was used extensively before the discovery of X-rays for detecting dental caries. More recently, the dental community has expressed renewed interest in this method, since high-intensity fiber-optic-based illumination systems have become available for detecting lesions located in-

between teeth near the proximal contact points — one of the common locations for caries in today's population. During fiber-optic transillumination (FOTI), a carious lesion appears dark upon transillumination because of decreased transmission due to increased scattering and absorption by the lesion.

Radiographs are the standard method for diagnosing approximal lesions. Unfortunately, as much as 25 percent of the interproximal areas of radiographs are unresolved due to the overlap with healthy tooth structure on adjoining teeth.

Figure 61 on the right shows a visible light image of two teeth placed in contact along with a transillumination image of the contact point taken using a 1.310-nm light source. The enamel is transparent in the transillumination image, and the lesion and dentin appear dark due to the higher light scattering. The lesion is clearly visible with high contrast. The internal incremental growth lines of the enamel are also visible within the transparent enamel.

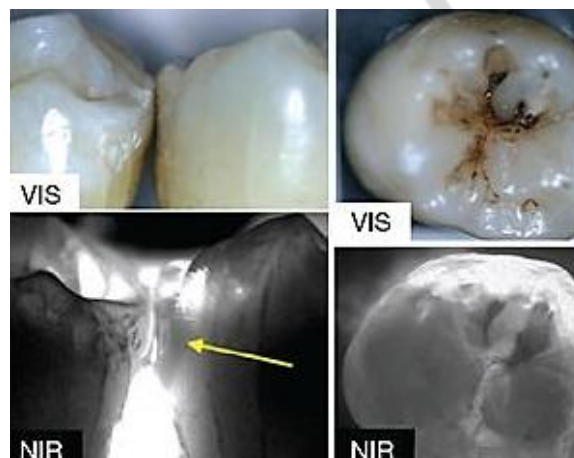


Fig. 61. Fiberoptical Transillumination Procedure

### YELLOW-ORANGE FLUORESCENCE (QLF-METHOD)

Quantitative light-induced fluorescence (QLF) was developed for use in caries detection and it is available commercially for clinical use. This device consists of a handheld intraoral color microvideo CCD camera, interfaced with a personal computer and custom software (fig. 62).

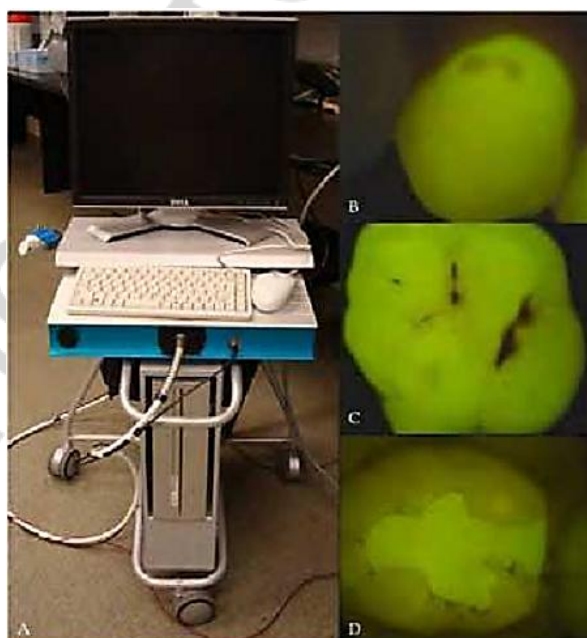


Fig. 62. A — QLF system; B — fluorescence image of an enamel caries lesion on the buccal surface; C — fluorescence image of an occlusal caries lesion; D — fluorescence image of a secondary caries lesion around a composite restoration

The software enables to capture and to analyze in vivo images of the tooth during clinical examination. QLF uses a 50-watt xenon arc-lamp and an optical filter in order to produce a blue light with a 290- to 450-nm wavelength, which is carried to the tooth through a light guide fitted with a dental mirror. The fluorescence images are filtered by a yellow high-pass filter ( $\lambda \geq 540$  nm) and then captured by a color CCD camera. When the tooth surface is illuminated by this high-intensity blue light, autofluorescence of the enamel is obtained by the intraoral camera, since all excitation light reflected or diffused is filtered. When a lesion is present on the surface, an increase in light scattering is observed relative to the surrounding enamel. The result of this is that the contrast between sound enamel and a carious lesion is improved with the lesion seen as being dark on a light green background.

## **DIAGNOSTIC METHODS IN RELATION TO NOSOLOGICAL FORM**

### **Caries**

Basic: visual inspection, probing.

Additional: staining, fluorescent techniques, X-ray diagnostics, temperature test, EPT, laser diagnostics.

### **Pulpitis, apical periodontitis**

Basic: visual inspection, probing, percussion, palpation.

Additional: x-ray diagnostics, temperature test, EPT.

### **Periodontal disease**

Basic: visual inspection, probing, percussion, palpation (estimation mobility of the tooth).

Additional: index score, X-ray diagnostics, microbiological and biochemical studies.

### **Oral mucosa disease**

Basic: visual inspection.

Additional: cytological, histological, microbiological, immunological studies, allergological tests, biochemical tests.

## REFERENCES

1. *Александрова, Л. Л.* Диагностика в терапевтической стоматологии : учеб.-метод. пособие / Л. Л. Александрова, Н. Н. Пустовойтова, Е. Н. Юрчук. Минск : БГМУ, 2007. 56 с.
2. *Юдина Н. А.* Основные и дополнительные методы обследования пациента на приеме врача-стоматолога : учеб.-метод. пособие / Н. А. Юдина, В.И. Азаренко. Минск : БелМАПО, 2006. 24 с.
3. *Application of Optical Methods for Diagnostics and Therapy of Dentine Caries / S. K. Dick [et al.] // 2nd Int. Conf. Nanotechnologies and Biomedical Engineering, Chişinău, Republic of Moldova, April 18–20. 2013. P. 429–432.*
4. *Gopikrishna, V.* Assessment of pulp vitality : a review / V. Gopikrishna, G. Pradeep, N. Venkateshbabu // *Chen. India Int. J. Paediatr. Dent.* 2009. Vol. 19. P. 3–15.
5. *Ashraf, A.-E.* Dental Pulp Neurophysiology. Part 2. Current Diagnostic Tests to Assess Pulp Vitality / A.-E. Ashraf, C. Yu. Donald // *JCDA.* 2009. Vol. 75, № 2. P. 139–143.
6. *Evaluation of a suspicious oral mucosal lesion / P. M. Williams [et al.] // J. Can. Dent. Assoc.* 2008. Vol. 74, № 3. P. 275–280.
7. *Rebelo, M. A. B.* Gingival Indices: State of Art [Electronic resource] / M. A. B. Rebelo, A. C. de Queiroz // *Gingival Diseases — Their Aetiology, Prevention and Treatment / eds : F. S. Panagakos, R. M. Davies. Ch. 3. Mode of access: <http://www.intechopen.com/books/gingival-diseases-their-aetiology-prevention-and-treatment>. doi: 10.5772/26236.*
8. *Nicolucci, M.* Gingival Recession — Etiology and Treatment / M. Nicolucci, M. Arlin // *Prev. Dent. Canada.* 2011. Vol. 2, № 2. P. 6–11.
9. *Dental Numbering Systems : Permanent Teeth [Electronic resource]. Mode of access: [http://www.americantooth.com/downloads/instructions/Dental\\_Sys\\_Permanent\\_Teeth.pdf](http://www.americantooth.com/downloads/instructions/Dental_Sys_Permanent_Teeth.pdf).*
10. *Indices used for dental caries assessment [Electronic resource]. Mode of access: <http://www.codental.uobaghdad.edu.iq/uploads/lectures/3rd%20class%20community%20dentistry/2%20DC%20Indices.pdf>.*
11. *The Business of Dentistry: Patient Records and Records Management [Electronic resource] / N. Kaweckyj [et al.]. Mode of access: <http://www.dentalcare.com/media/en-US/education/ce390/ce390.pdf>.*
12. *Tooth Numbering [Electronic resource]. Mode of access: <http://www.simplesteps-dental.com/SS/ihtSS/r.==/st.31843/t.31882/pr.3.html>.*
13. *Investigation of contact allergy to dental materials by patch testing / R. R. [et al.] // Indian Dermatol Online J.* 2014. Vol. 5, № 3. P. 282–286.
14. *Traditional and novel methods for occlusal caries detection: performance on primary teeth / J. F. Souza [et al.] // Lasers Med. Sci.* 2013. Vol. 28, № 1. P. 287–295. doi: 10.1007/s10103-012-1154-8.



## CONTENTS

Introduction .....	3
Dental patient examination scheme .....	3
Taking a history .....	4
Determination of the dental status .....	6
Extraoral (external) inspection.....	12
Intraoral inspection .....	13
Index rating .....	30
Dental radiographic examinations .....	34
Principles of radiographic interpretation .....	40
Electric pulp testing .....	43
Determination of allergy to dental materials .....	45
Laboratory tests.....	45
Laser-induced fluorescence .....	45
Fibroptical transillumination.....	46
Yellow-orange fluorescence .....	47
Diagnostic methods in relation to nosological form.....	48
References .....	49

Учебное издание

**Казеко Людмила Анатольевна**  
**Колб Екатерина Леонидовна**

**ДИАГНОСТИКА  
В ТЕРАПЕВТИЧЕСКОЙ СТОМАТОЛОГИИ**

**DIAGNOSTIC PROCEDURES  
IN THERAPEUTIC DENTISTRY**

Учебно-методическое пособие

На английском языке

Ответственная за выпуск Л. А. Казеко  
Переводчик Е. Л. Колб  
Компьютерная верстка Н. М. Федорцовой

Подписано в печать 21.01.16. Формат 60×84/16. Бумага писчая «Снегурочка».  
Ризография. Гарнитура «Times».  
Усл. печ. л. 3,02. Уч.-изд. л. 2,84. Тираж 40 экз. Заказ 138.

Издатель и полиграфическое исполнение: учреждение образования  
«Белорусский государственный медицинский университет».  
Свидетельство о государственной регистрации издателя, изготовителя,  
распространителя печатных изданий № 1/187 от 18.02.2014.  
Ул. Ленинградская, 6, 220006, Минск.