

MUSCULO-SKELETAL SYSTEM

Human anatomy manual

РЕПОЗИТОРИЙ БГМУ

Minsk BSMU 2016

МИНИСТЕРСТВО ЗДРАВООХРАНЕНИЯ РЕСПУБЛИКИ БЕЛАРУСЬ
БЕЛОРУССКИЙ ГОСУДАРСТВЕННЫЙ МЕДИЦИНСКИЙ УНИВЕРСИТЕТ
КАФЕДРА МОРФОЛОГИИ ЧЕЛОВЕКА

ОПОРНО-ДВИГАТЕЛЬНЫЙ АППАРАТ

MUSCULO-SKELETAL SYSTEM

Практикум по анатомии человека

4-е издание



Минск БГМУ 2016

УДК 611.7(811.111)-054.6(076.5) (075.8)
ББК 28.706 (81.2 Англ-923)
О-61

Рекомендовано Научно-методическим советом университета
в качестве практикума 18.05.2016 г., протокол № 9

Авторы: д-р мед. наук, проф. С. Л. Кабак (лаб. занятия 8, 9); канд. мед. наук, доц. В. А. Манулик (лаб. занятия 1, 2); канд. мед. наук, доц. Н. В. Синельникова (лаб. занятия 3, 6); канд. мед. наук, доц. С. Л. Анищенко (лаб. занятия 4, 5); канд. биол. наук, ст. преп. Е. В. Юшкевич (лаб. занятия 7)

Рецензенты: канд. мед. наук, доц. Л. Д. Чайка; канд. мед. наук, доц. О. Л. Жарикова

Опорно-двигательный аппарат = Musculo-skeletal system : практикум по анатомии
О-61 человека / С. Л. Кабак [и др.]. – 4-е изд. – Минск : БГМУ, 2016. – 39 с.

ISBN 978-985-567-495-6.

Содержит контрольные вопросы, учебные задания и перечень основной и дополнительной литературы по разделам «Остеология», «Артрология» и «Миология». Первое издание вышло в 2013 году.

Предназначен для студентов 1-го курса медицинского факультета иностранных учащихся, обучающихся на английском языке по специальности «Стоматология».

УДК 611.7(811.111)-054.6(076.5) (075.8)
ББК 28.706 (81.2 Англ-923)

ISBN 978-985-567-495-6

© УО «Белорусский государственный
медицинский университет», 2016

HUMAN ANATOMY MANUAL

First-year student _____ group
Of dental faculty
Belarusian state medical university

(name, surname)

Teacher _____
(name, surname)

№	Compliance	Score	Signature
1.	THE LESSON IS COMPLETED		
2.	THE LESSON IS COMPLETED		
3.	THE LESSON IS COMPLETED		
4.	THE LESSON IS COMPLETED		
5.	THE LESSON IS COMPLETED		
6.	THE LESSON IS COMPLETED		
7.	THE LESSON IS COMPLETED		
8.	THE LESSON IS COMPLETED		
9.	THE LESSON IS COMPLETED		

2014–2015

PART I. Lab № 1

Topic: THE OBJECT OF STUDY OF ANATOMY. AXIAL SKELETON. VERTEBRAL COLUMN

Control questions:

1. Subjects and methods of human body structure study.
2. Planes and axes used to describe the position of organs and parts of human body in space.
3. Anatomical terminology.
4. Classification of bones.
5. Axial skeleton. Vertebral column: parts, functions. The formation of spine curves.

The structure of "typical" vertebra.

6. The structure of cervical vertebrae (C₃–C₆). Structural features of the first (C₁), the second (C₂) and the seventh (C₇) cervical vertebra.
7. Structural features of the thoracic vertebrae.
8. Spine congenital anomalies.
9. The bones forming the chest skeleton. Borders of the upper and lower apertures.
10. Sternum: position, structure.
11. The structure of ribs. Classification of ribs. Structure features of the first rib.

Student should know:

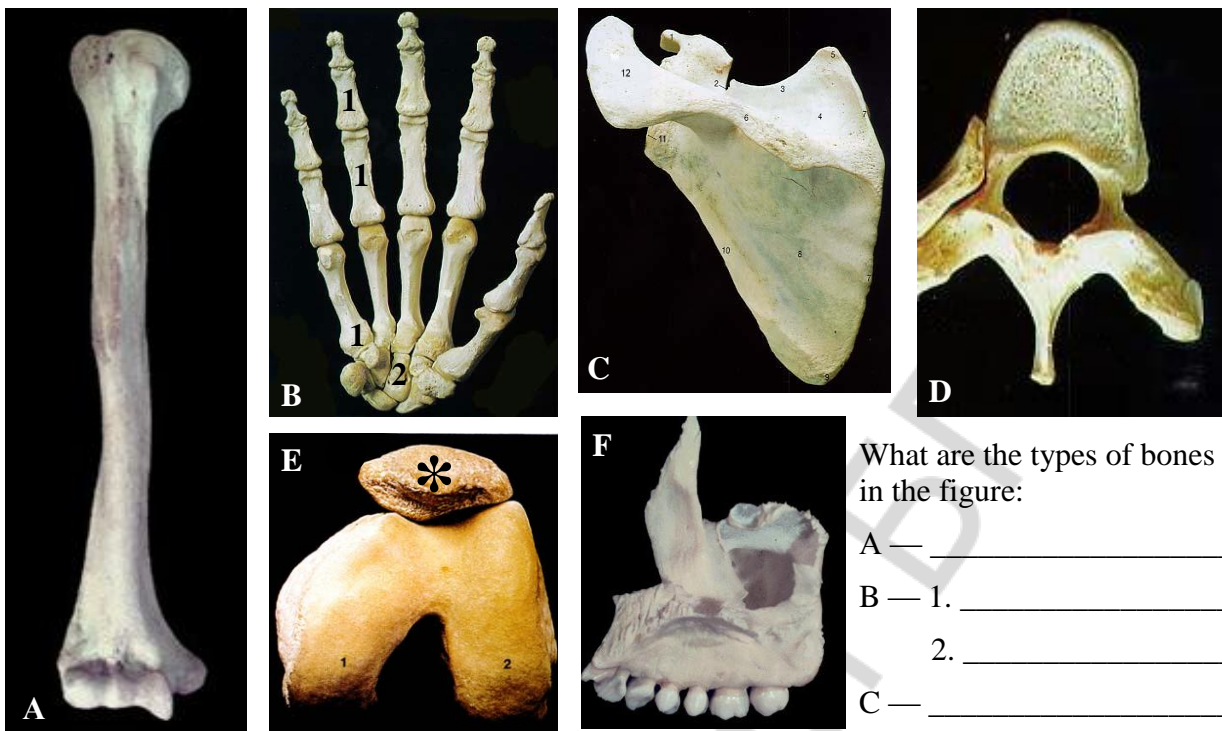
1) *Latin equivalent of following terms and understand its meaning:* 1. Vertical. 2. Horizontal. 3. Frontal. 4. Sagittal. 5. Right. 6. Left. 7. Transversal. 8. Medial. 9. Lateral. 10. Median. 11. Intermediate. 12. Posterior. 13. Anterior. 14. Ventral. 15. Dorsal. 16. Superior. 17. Inferior. 18. Cranial. 19. Caudal. 20. Median. 21. Longitudinal. 22. External. 23. Internal. 24. Superficial. 25. Deep. 26. Proximal. 27. Distal.

2) *To be able to find anatomical structures and know its Latin names on anatomical preparation and illustrated study guide:*

I. Vertebral column. 1. Spinal canal. 2. Cervical vertebrae. 3. Thoracic vertebrae. 4. Lumbar vertebrae. 5. Sacrum. 6. Sacral vertebrae. 7. Coccyx. 8. The vertebral body. 9. Arc of vertebra. 10. Intervertebral foramen. 11. Upper vertebral notch. 12. Lower vertebral notch. 13. Superior articular process. 14. Lower articular process. 15. Spinous process. 16. Transverse foramen. 17. Atlas. 18. Lateral mass (Atlas). 19. The upper articular surface (Atlas). 20. The lower articular surface (atlas). 21. Anterior arch of atlas. 22. Posterior arch of atlas. 23. Dens (odontoid process) of the second vertebrae.

II. Chest skeleton. 1. Thorax. 2. Apertura thoracis inferior and superior. 3. Costal arch. 4. Intercostal space. 5. Infrasternal angle of thorax. 6. Sternum. 7. Manubrium of sternum. 8. Jugular notch. 9. Clavicular notch. 10. Sternum angle. 11. Sternum corpus. 12. Rib incisures. 13. Xiphoid. 14. Rib. 15. Costal caput. 16. Costal column. 17. Corpus costae. 18. Tubercle of rib. 19. Rib angle. 20. Costal sulcus.

OSTEOLOGY. Types of bones

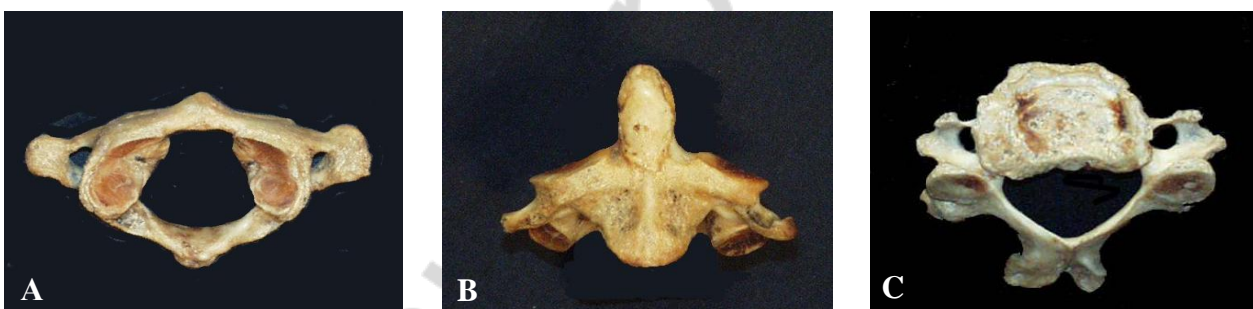

What are the types of bones in the figure:

- A — _____
- B — 1. _____
2. _____
- C — _____
- D — _____

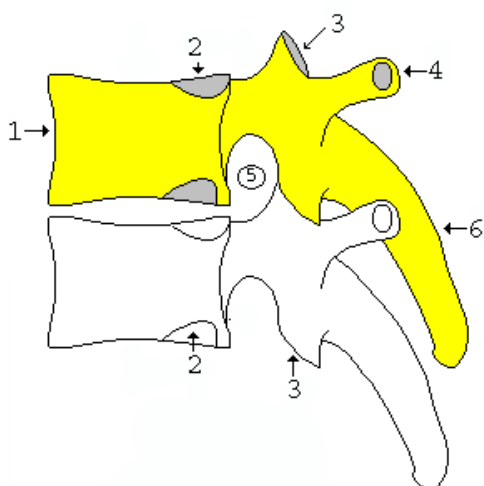
Cervical vertebrae

What are the vertebrae in the figure:



Thoracic vertebrae (lateral view)

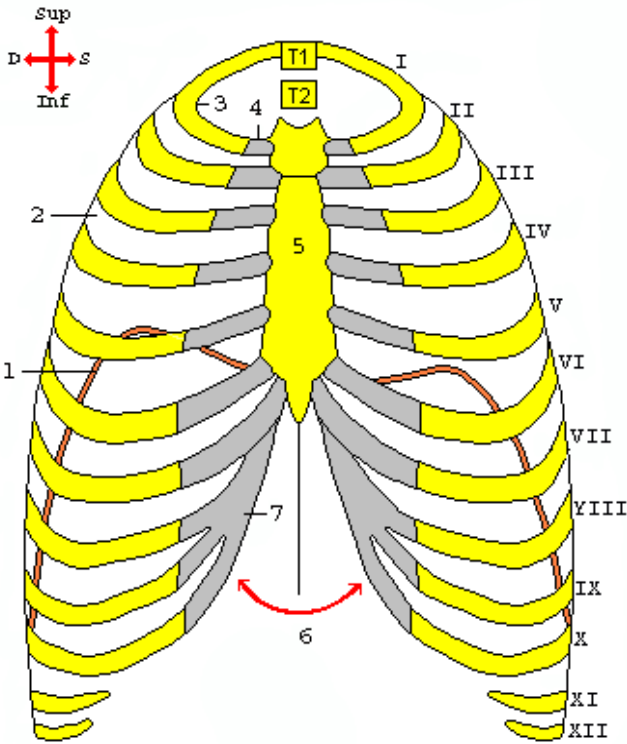
Ventr. ← → Dors.



What are the names of the anatomical structures indicated in the figure:

- 1. _____
- 2. _____
- 3. _____
- 4. _____
- 5. _____
- 6. _____

CHEST SKELETON (frontal view)



What are the names of anatomical structures indicated in the figure?

I-VII — _____

VIII-X — _____

XI-XII — _____

1. _____

2. _____

3. _____

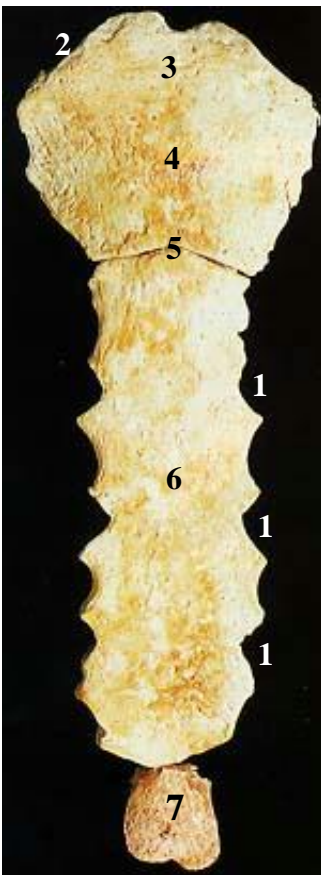
4. _____

5. _____

6. _____

7. _____

STERNUM



What are the names of anatomical structures indicated in the figure:

1. _____

2. _____

3. _____

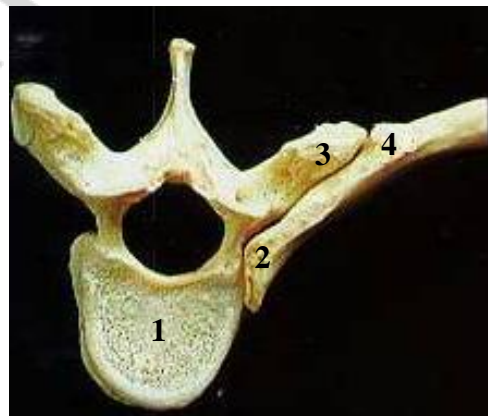
4. _____

5. _____

6. _____

7. _____

Connection rib with vertebra



What are the names of anatomical structures indicated in the figure?

1. _____

2. _____

3. _____

4. _____

Lab № 2

Topic: CRANIUM. THE CONSTRUCTION OF OCCIPITAL, FRONTAL, PARIETAL, SPHENOID, ETHMOID, TEMPORAL BONES

Control questions:

1. Name bones of cranium and viscerocranium and specify its location.
2. The construction of occipital bone. Parts, relief of external and internal surfaces. Canals, foramina and sulci of occipital bone.
3. Parietal bone: margins, angles, relief external and internal surfaces.
4. Frontal bone: parts, the construction.
5. Frontal sinus, its location, communication with the nasal cavity, its formation in ontogenesis.
6. The construction of sphenoid bone: parts, canals, foramina.
7. Sphenoid sinus: its location, communication with the nasal cavity, its formation in ontogenesis.
8. The construction of ethmoid bone. Ethmoid labyrinth, its communication with the nasal cavity, its formation in ontogenesis.
9. The structure of temporal bone: parts, its relative positions. The relief of internal and external surfaces.
10. Tympanic cavity. The structure of mastoid process.
11. Channels (facial, carotid, musculotubal canal,) and the tubules of the temporal bone. Foramina, its direction, bends, contents.

Student must be able to find listed structures on anatomical preparations and to know their Latin names:

I. Occipital bone. 1. Foramen magnum. 2. Occipital condyle. 3. Condylar canal. 4. Canal of hypoglossal nerve. 5. Jugular notch. 6. External occipital protuberance. 7. Internal occipital protuberance. 8. External occipital crest. 9. Internal occipital crest. 10. Upper nuchal line. 11. Lower nuchal line. 12. Cruciform elevation. 13. Groove of lower petrous sinus. 14. Groove of upper petrous sinus. 15. Groove of transverse sinus. 16. Groove of sigmoid sinus.

II. Parietal bone. 1. Groove of the middle meningeal artery. 2. Upper temporalis line. 3. Lower temporalis line. 4. Parietal tuber. 5. Parietal hole.

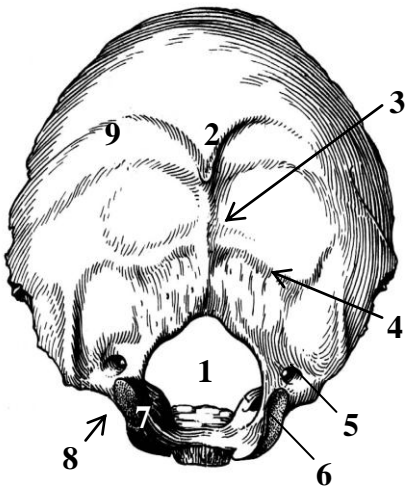
III. Frontal bone. 1. Frontal scales. 2. Nasal part. 3. Orbital part. 4. Frontal tuber. 5. Superciliary arch. 6. Glabella. 7. Supraorbital margin. 8. Supraorbital notch. 9. Supraorbital hole. 10. Zygomatic process. 11. Aperture of frontal sinus.

IV. Sphenoid bone. 1. Corpus. 2. Large wing. 3. Small wing. 4. Pterygoid process. 5. Pterygoid canal. 6. Pituitary fossa. 7. Tubercle of saddle. 8. Back of saddle. 9. Sulcus (pre)chiasmatis. 10. Optical canal. 11. Carotid groove. 12. Upper orbital fissure. 13. Round foramen. 14. Ovale foramen. 15. Spinos foramen. 16. Infratemporal crest. 17. Medial lamina. 18. Aperture of sphenoid sinus. 19. Infratemporal crest. 20. Medial lamina. 21. Lateral lamina.

V. Ethmoid bone. 1. Ethmoid lamella. 2. Cock's comb. 3. Perpendicular lamella. 4. Ethmoidal labyrinth. 5. Upper nasal conch. 6. Middle nasal conch. 7. Orbital plate of ethmoid bone.

VI. Temporal bone. 1. Pyramid. 2. Petrous part. 3. Tympanic part. 4. Squamosal part. 5. Zygomatic process. 6. Mandibular fossa. 7. Articular tubercle. 8. Petrosquamous fissure. 9. Tympanosquamous fissure. 10. Petrotympanic fissure. 11. External auditory foramen. 12. External auditory meatus. 13. Internal auditory foramen. 14. Arcuate eminence. 15. Sulcus of lesser petrosal nerve. 16. Sulcus of greater petrosal nerve. 17. Hiatus of canal for greater petrosal nerve. 18. Hiatus of canal for lesser petrosal nerve. 19. Roof of tympanum. 20. Trigeminal impression. 21. Sulcus of superior petrosal sinus. 22. Sulcus of inferior petrosal sinus. 23. Styloid process. 24. Stylomastoid foramen. 25. Jugular recess. 26. Mastoid process. 27. Sulcus of occipital artery. 28. Mastoid foramen. 29. Sulcus of sigmoid sinus. 30. Tympanum.

OCCIPITAL BONE



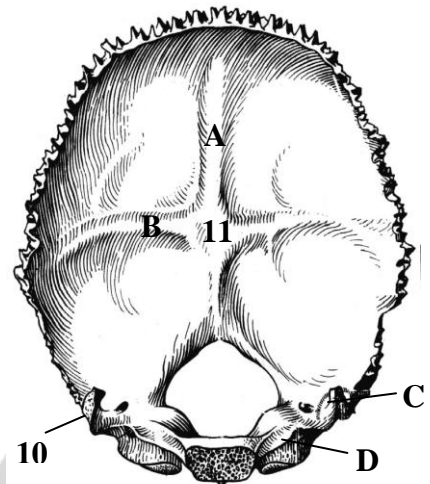
Color in blue and name sulcus of sinuses of hard meninges:

- A — _____

 B — _____

 C — _____

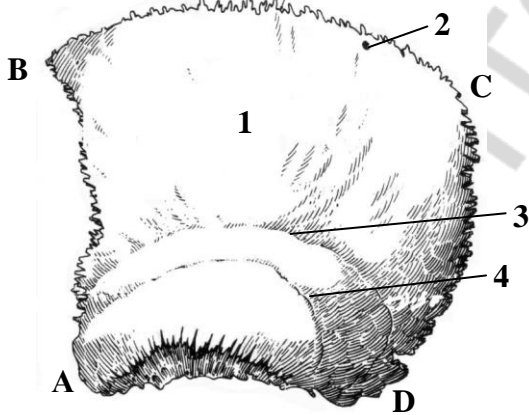
 D — _____



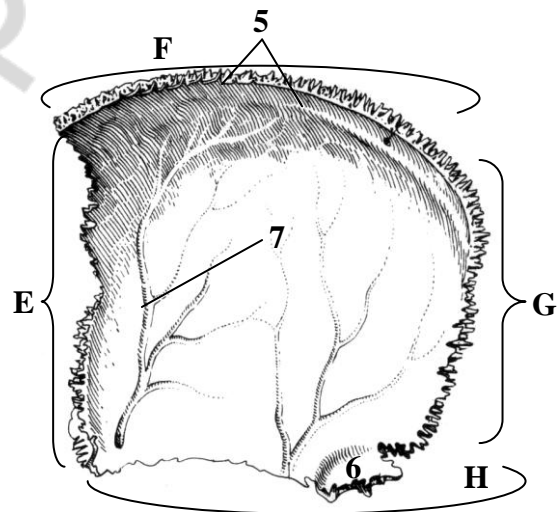
Name anatomical structures, designated in the figure:

- | | |
|----------|-----------|
| 1. _____ | 7. _____ |
| 2. _____ | 8. _____ |
| 3. _____ | 9. _____ |
| 4. _____ | 10. _____ |
| 5. _____ | 11. _____ |
| 6. _____ | |

PARIETAL BONE



External view of the left parietal bone

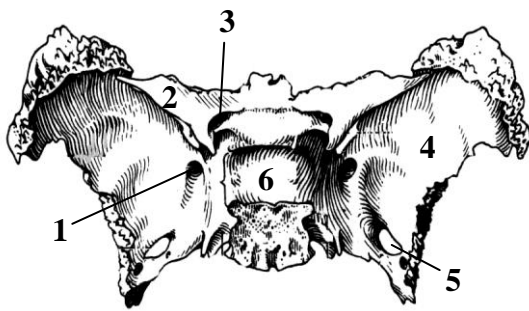


Internal view of the right parietal bone

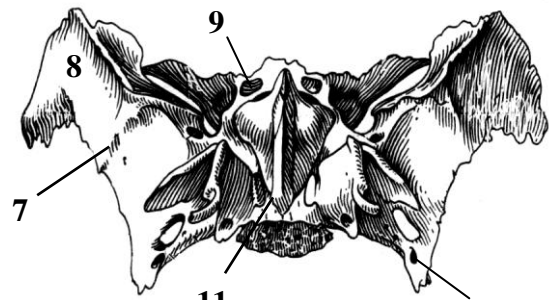
Name anatomical structures, designated in the figure:

- | | | |
|----------|-----------|-----------|
| 1. _____ | Angles: | Margins: |
| 2. _____ | A — _____ | E — _____ |
| 3. _____ | B — _____ | F — _____ |
| 4. _____ | C — _____ | G — _____ |
| 5. _____ | D — _____ | H — _____ |
| 6. _____ | | |
| 7. _____ | | |

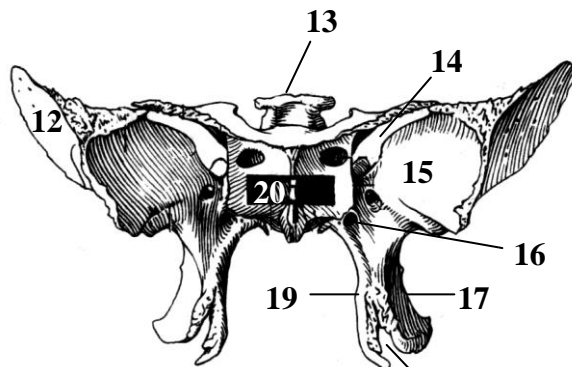
SPHENOID BONE



Top view



Bottom view



Front view

Write down in the table:

The structure	Latin name
Optical canal	
Pterygoid canal	
Round foramen	
Ovale foramen	
Spinos foramen	
Upper orbital fissure	

Name anatomical structures, designated in the pictures:

1. _____
2. _____
3. _____
4. _____
5. _____
6. _____
7. _____
8. _____
9. _____
10. _____

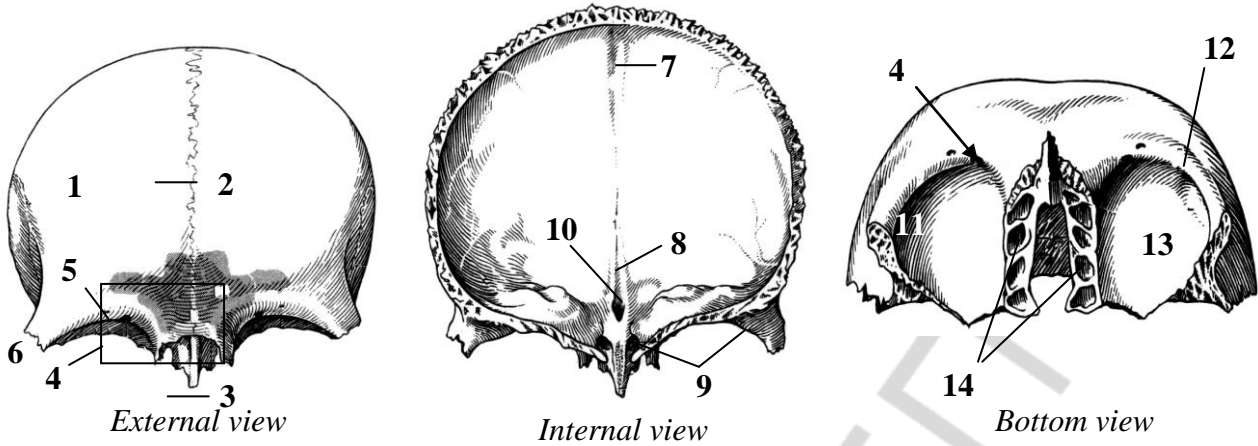
11. _____
12. _____
13. _____
14. _____
15. _____
16. _____
17. _____
18. _____
19. _____
20. _____

PNEUMATIC PARANASAL SINUSES

Complete the table:

The name of sinus	The time of cavity occurrence
Sphenoid sinus	
Frontal sinus	
Ethmoidal labyrinth	

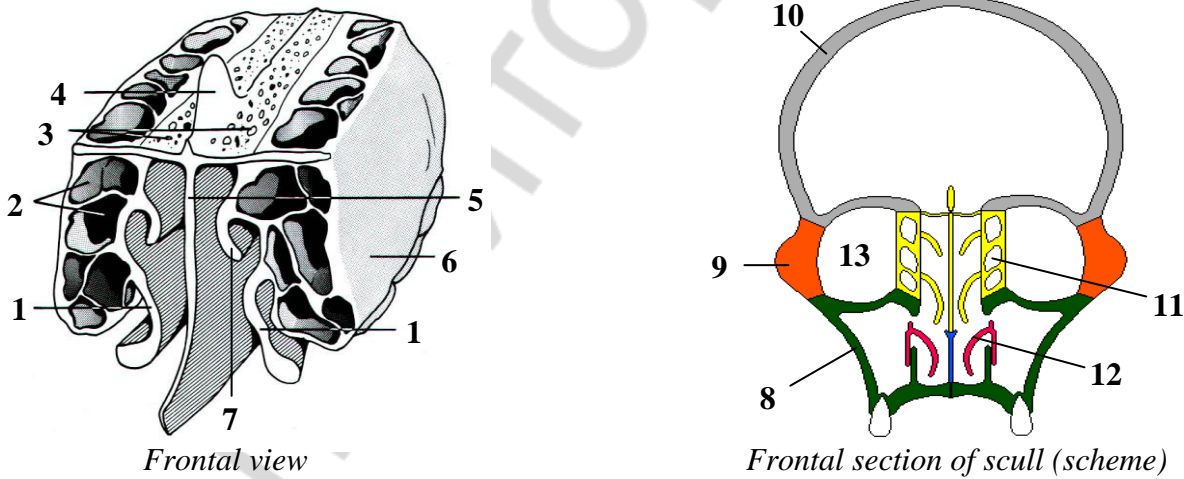
FRONTAL BONE



Name anatomical structures numerated in the figure:

- | | |
|----------|-----------|
| 1. _____ | 8. _____ |
| 2. _____ | 9. _____ |
| 3. _____ | 10. _____ |
| 4. _____ | 11. _____ |
| 5. _____ | 12. _____ |
| 6. _____ | 13. _____ |
| 7. _____ | 14. _____ |

ETHMOID BONE

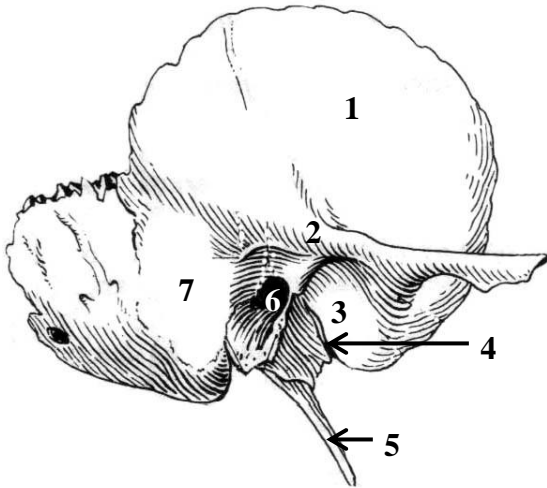


Color the ethmoid bone.

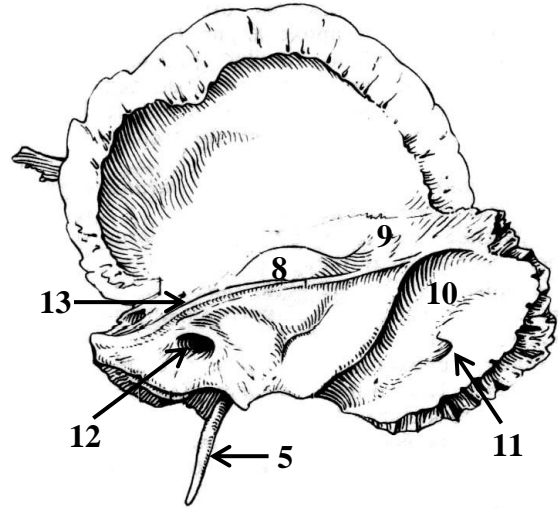
Name anatomical structures, numerated in the figure:

- | | |
|----------|-----------|
| 1. _____ | 8. _____ |
| 2. _____ | 9. _____ |
| 3. _____ | 10. _____ |
| 4. _____ | 11. _____ |
| 5. _____ | 12. _____ |
| 6. _____ | 13. _____ |
| 7. _____ | |

TEMPORAL BONE (right)



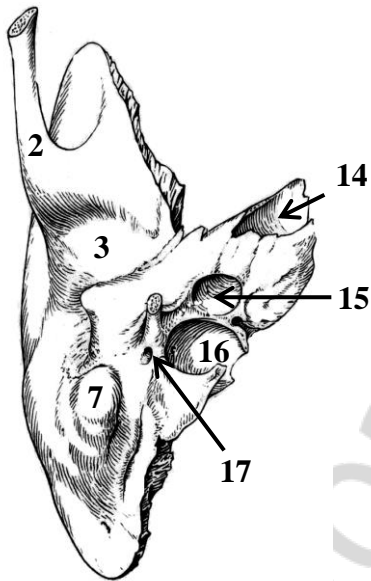
A. External view



B. Internal view

Color the next parts of the temporal bone in the figure:

- Squamosal part —
- Petrous part —
- Tympanic part —



C. Bottom view

Name anatomical structures, numerated in the figure:

- | | |
|----------|-----------|
| 1. _____ | 10. _____ |
| 2. _____ | 11. _____ |
| 3. _____ | 12. _____ |
| 4. _____ | 13. _____ |
| 5. _____ | 14. _____ |
| 6. _____ | 15. _____ |
| 7. _____ | 16. _____ |
| 8. _____ | 17. _____ |
| 9. _____ | _____ |

Complete the table:

№	Canals names (canaliculuses)	Contents
1.	Carotical canal	
2.	Facial canal	
3.	Musculotubal canal	
4.	Caroticotympanic canaliculuses	
5.	Small canal of chorda tympani	
6.	Tympanic canaliculus	
7.	Mastoid canaliculus	

Lab № 3

Topic: FACIAL BONES: MAXILLA, PALATINE BONE, MANDIBLE. SMALL BONES OF THE FACIAL SKELETON. HYOID BONE

Control questions:

1. The structure of maxilla: parts, its relative positions. The relief of surfaces of corpus and processes of maxilla.
2. Maxillary sinus: localization, structure, communication with the nasal cavity, dental root and sinus floor ratio.
3. Palatine bone: part, their relative positions and relief.
4. Mandible: the relative positions of parts, the relief of corpus and processes. Mandibular canal: holes, contents.
5. Small bones of the facial skeleton: zygomatic, lacrimal, nasal, inferior nasal concha, vomer: its location and structure.
6. Hyoid bone: location, structure.

To be able to find anatomical structures and know its Latin names on anatomical preparation and illustrated study guide:

I. Maxilla: 1. Infraorbital margin, foramen. 2. Fossa canina. 3. Tuber of maxilla. 4. Alveolar foramina. 5. Infraorbital sulcus, canalis. 6. Maxillary hiatus. 7. Lacrimal sulcus. 8. Greater palatine sulcus. 8. Frontal, zygomatic, palatine, alveolar process. 9. Anterior nasal spine. 10. Palatine torus. 11. Incisive foramen, canalis. 12. Dental alveolus. 13. Juga alveolaria. 14. Interpalveolaria, interdicularia septi.

II. Palatine bone: 1. Perpendicular, horizontal plate. 2. Greater palatine sulcus. 3. Lesser palatine foramina. 4. Pyramidal, orbital, sphenoidal processes. 5. Sphenopalatine notch.

III. Mandible: 1. The corpus, the base of mandible. 2. Mental foramen. 3. Mental tubercle, protuberance. 4. Oblique line. 5. Digastric fossa. 6. Mental spine. 7. Mylohyoid line, sulcus. 8. Sublingual, submandibular fovea. 9. Alveolar part. 10. Ramus of mandible. 11. Angle of mandible. 12. Masseteric, pterygoid tuberosity. 13. Mandibular foramen. 14. Lingula of mandible. 15. Mandibular canal. 16. Condylar process. 17. Mandibular notch. 18. Coronoid process. 19. Caput, collum of mandible. 20. Pterygoid fovea.

IV. Zygomatic bone: zygomaticoorbital, zygomaticofacial, zygomaticofacial foramina.

V. Lacrimal bone.

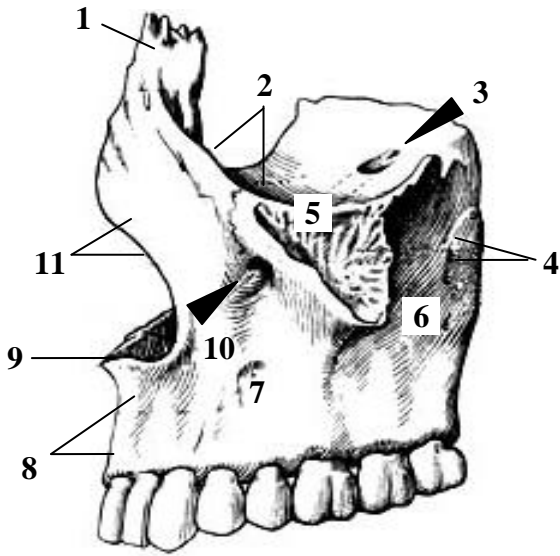
VI. Nasal bone.

VII. Inferior nasal concha.

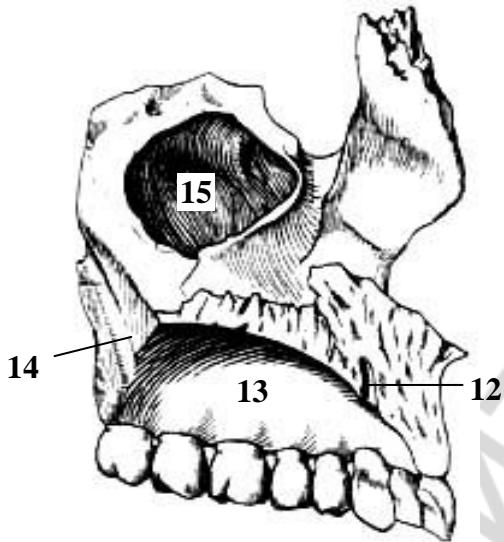
VIII. Vomer.

IX. Hyoid bone.

LEFT MAXILLA



Lateral view



Medial view

Color the surface of maxilla corpus:

Anterior

Infratemporal



Orbital

Nasal



Give the Latin names of anatomical structures marked in figures:

1. _____

2. _____

3. _____

4. _____

5. _____

6. _____

7. _____

8. _____

9. _____

10. _____

11. _____

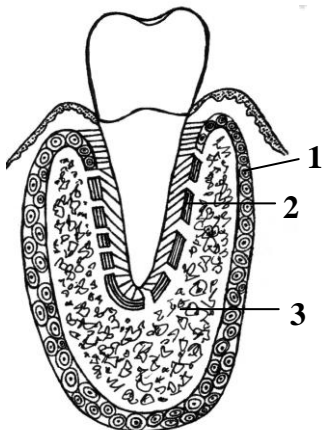
12. _____

13. _____

14. _____

15. _____

Microscopic structure of mandible



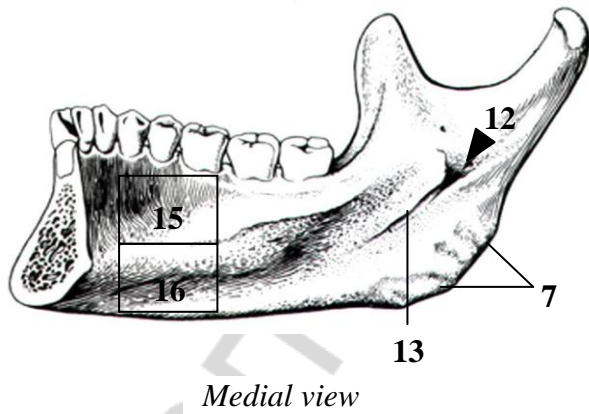
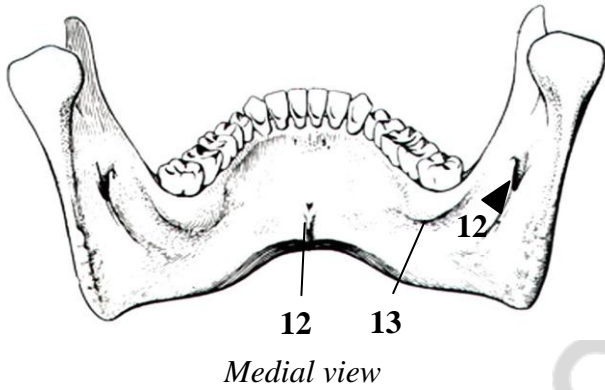
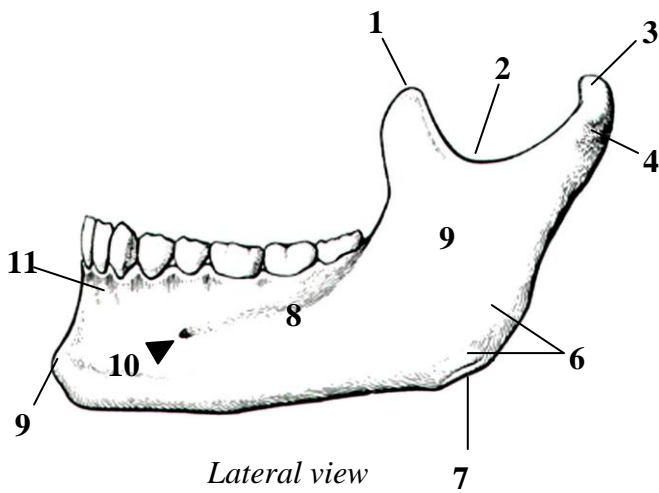
Name the structures marked in the figure:

1. _____

2. _____

3. _____

MANDIBLE

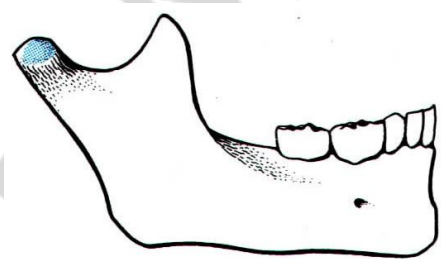
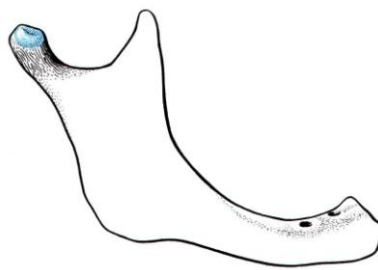
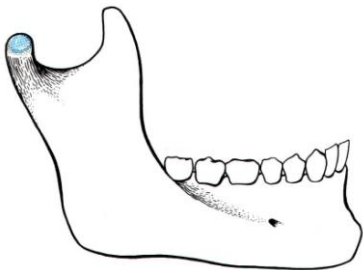


Give the Latin names of anatomical structures marked in figures:

1. _____
2. _____
3. _____
4. _____
5. _____
6. _____
7. _____
8. _____
9. _____
10. _____
11. _____
12. _____
13. _____
14. _____
15. _____
16. _____

MANDIBLE. Age features of structure

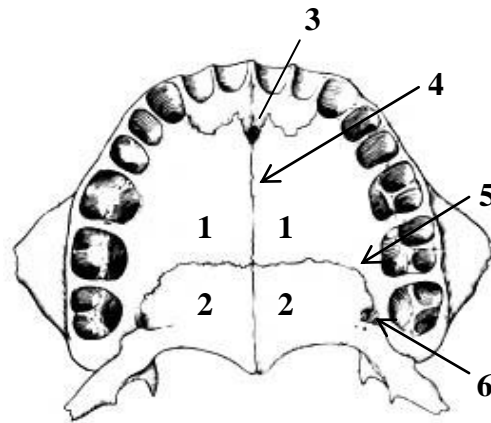
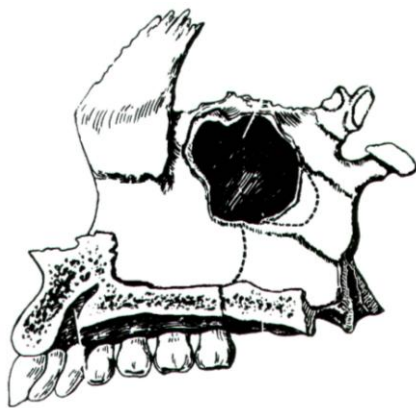
	Structure	Newborn	Adult	Elderly
1	Angulus mandibule	140–150°	110–130°	140–150°
2	Foramen mentale	Closer to the base	In the middle of corpus height	Closer to the upper edge
3	Pars alveolaris	Not developed	Presented	Atrophy
4	Mental symphysis	It is ossification on the 2-year of life	–	–



Indicate the person's age according to the mandible presented in the figure:

- A — 3-year-old child
- B — 30-year-old male
- C — 80 year-old male

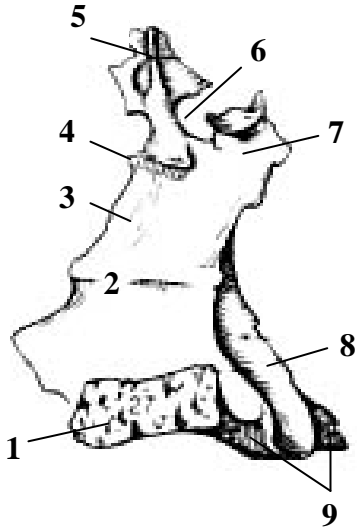
PALATINE BONE



Color the palatine bone and name the palatum osseum anatomical structures:

- 1. _____
- 2. _____
- 3. _____
- 4. _____
- 5. _____
- 6. _____

PALATINE BONE

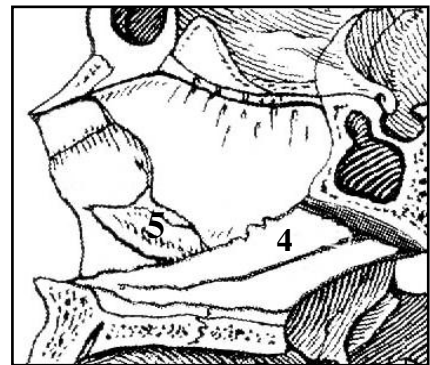
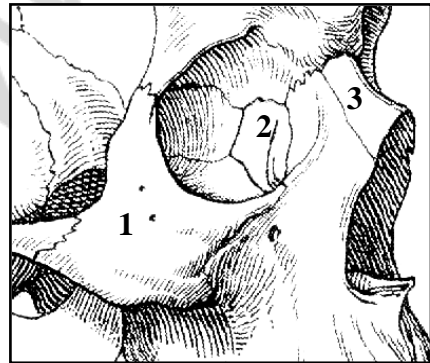
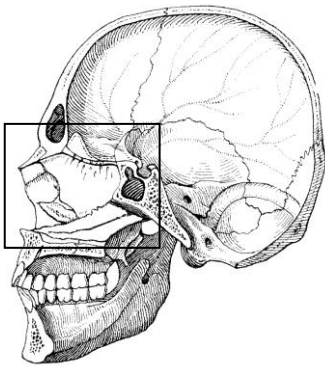
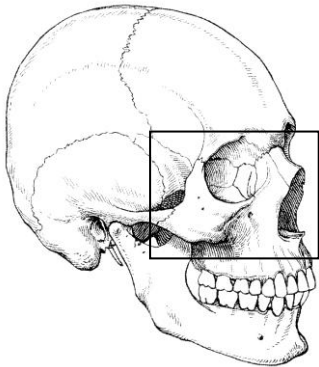


Medial view

Name anatomical structures indicated in the figure:

1. _____
2. _____
3. _____
4. _____
5. _____
6. _____
7. _____
8. _____
9. _____

SMALL BONES OF FACIAL SKELETON



Color in the small bones of facial skeleton:

Nº	Color	The name of the bone
1.		Zygomatic bone
2.		Lacrimal bone
3.		Nasal bone
4.		Vomer
5.		Inferior nasal concha

Lab № 4

Topic: CRANIUM. FACIAL, LATERAL, BASIAL, VERTICAL NORMS. EXTERNAL AND INTERNAL CRANIAL BASE. AGE-SPECIFIC CRANIAL ANATOMY. CRANIOMETRY

Control questions:

1. Orbit: walls, holes, fissures and canals. The communication of orbit with another cranial regions.
2. Nasal osseous cavity: borders, holes. The structure of walls (lateral, medial, superior, inferior).
3. Nasal meatus: borders, communication with another cranial cavities.
4. Fossas of lateral cranial norm. Borders and names of bones, forming the bone basis of temporal and infratemporal fossa. Fissures of infratemporal fossa and regions of head, in which they are opened.
5. Pterygopalatine fossa: walls, communication with the middle cranial fossa, nasal cavity, orbit, oral cavity, external cranial basis.
6. External cranial basis. Pattern, foramina, canals.
7. The structure of bone palate.
8. Internal cranial basis: names and borders of fosses, bones, forming it. The pattern of surface; foramina, canals, fissures.
9. Sulci of sinuses of pachymeninx, disposed on the external cranial base.
10. Calvarium; features of bone construction and development. Cranial sutures.
11. Facial and cranium age-specific anatomy.
12. Craniometry. The name and localization of craniometric points.

Student must be able to find the listed structures on anatomical preparations and to know their Latin names:

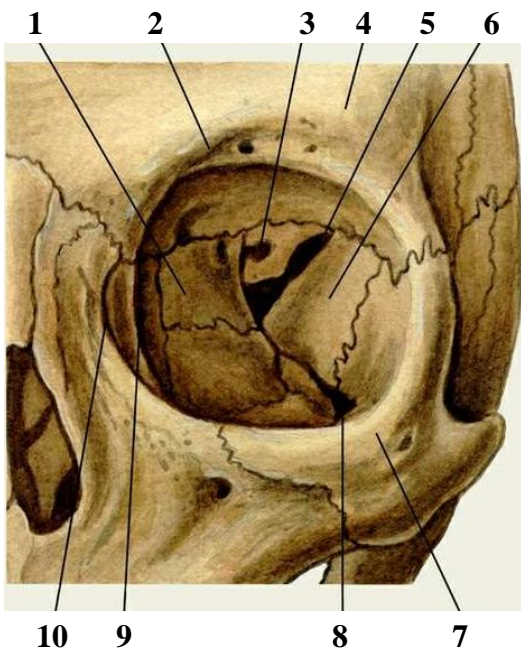
I. Orbit. 1. Anterior ethmoidal foramina. 2. Posterior ethmoidal foramina. 3. Superior orbital fissure. 4. Inferior orbital fissure. 5. Nasolacrimal canal. 6. Fossa of the lacrimal pouch. 7. Supraorbital edge. 8. Infraorbital edge.

II. Bone nasal cavity. 1. Pear-shaped aperture. 2. Choana. 3. Superior nasal meatus. 4. Middle nasal meatus. 5. Inferior nasal meatus. 6. Sphenopalatine foramen. 7. Nasolacrimal canal.

III. Lateral norm. 1. Malar arch. 2. Temporal fossa. 3. Infratemporal fossa. 4. Pterygopalatine fossa. 5. Pterygomaxillar fissure.

IV. Cranial basis. 1. Bony palate. 2. Middle suture of the palate. 3. Transverse suture of the palate. 4. Greater palate canal. 5. Greater palatine foramen. 6. Ragged (lacerum) foramen. 7. Jugular foramen. 7. Anterior cranial fossa. 7. Middle cranial fossa. 8. Posterior cranial fossa. 9. Clivus. 10. Sulcus of superior petrosal sinus. 11. Sulcus of inferior petrosal sinus. 12. Sulcus of sigmoid sinus. 13. Sulcus of transversal sinus. 14. Sulcus of superior saggital sinus.

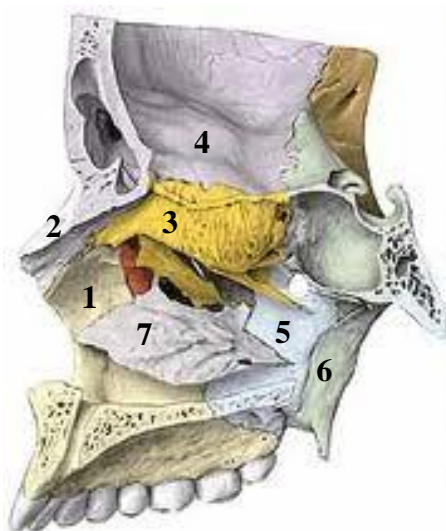
V. Calvarium. 1. Coronal suture. 2. Sagittal suture. 3. Lambdoid suture. 4. Frontal (metopic) suture. 5. Squamosal suture.



Name anatomical structures, indicated in the pictures:

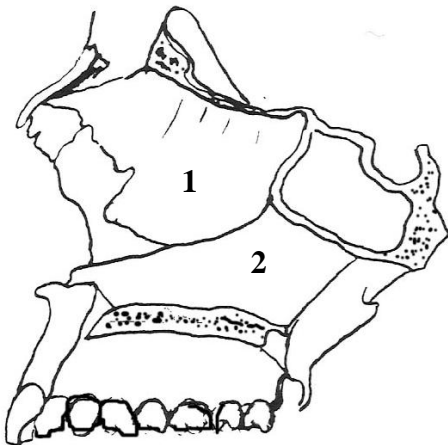
1. _____
2. _____
3. _____
4. _____
5. _____
6. _____
7. _____
8. _____
9. _____
10. _____

NAZAL CAVITY (LATERAL WALL)



Name anatomical structures, indicated in the pictures:

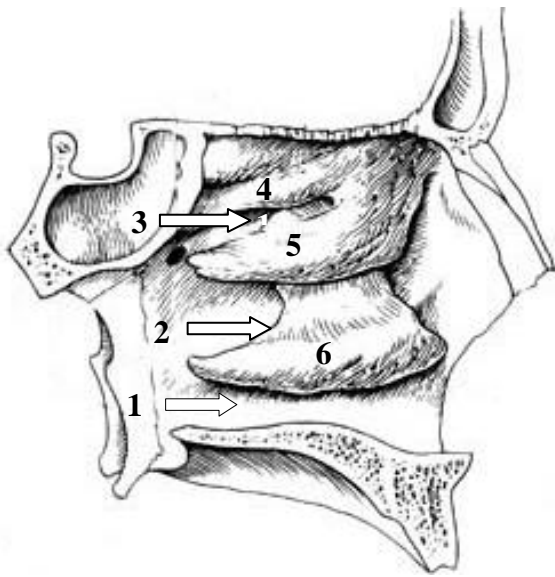
1. _____
2. _____
3. _____
4. _____
5. _____
6. _____
7. _____



Color and name the bones, forming the nasal septum:

1. _____
2. _____

Nasal passages and nasal conchas



Name nasal concha and nasal passages marked in the figure:

1. _____
2. _____
3. _____
4. _____
5. _____
6. _____

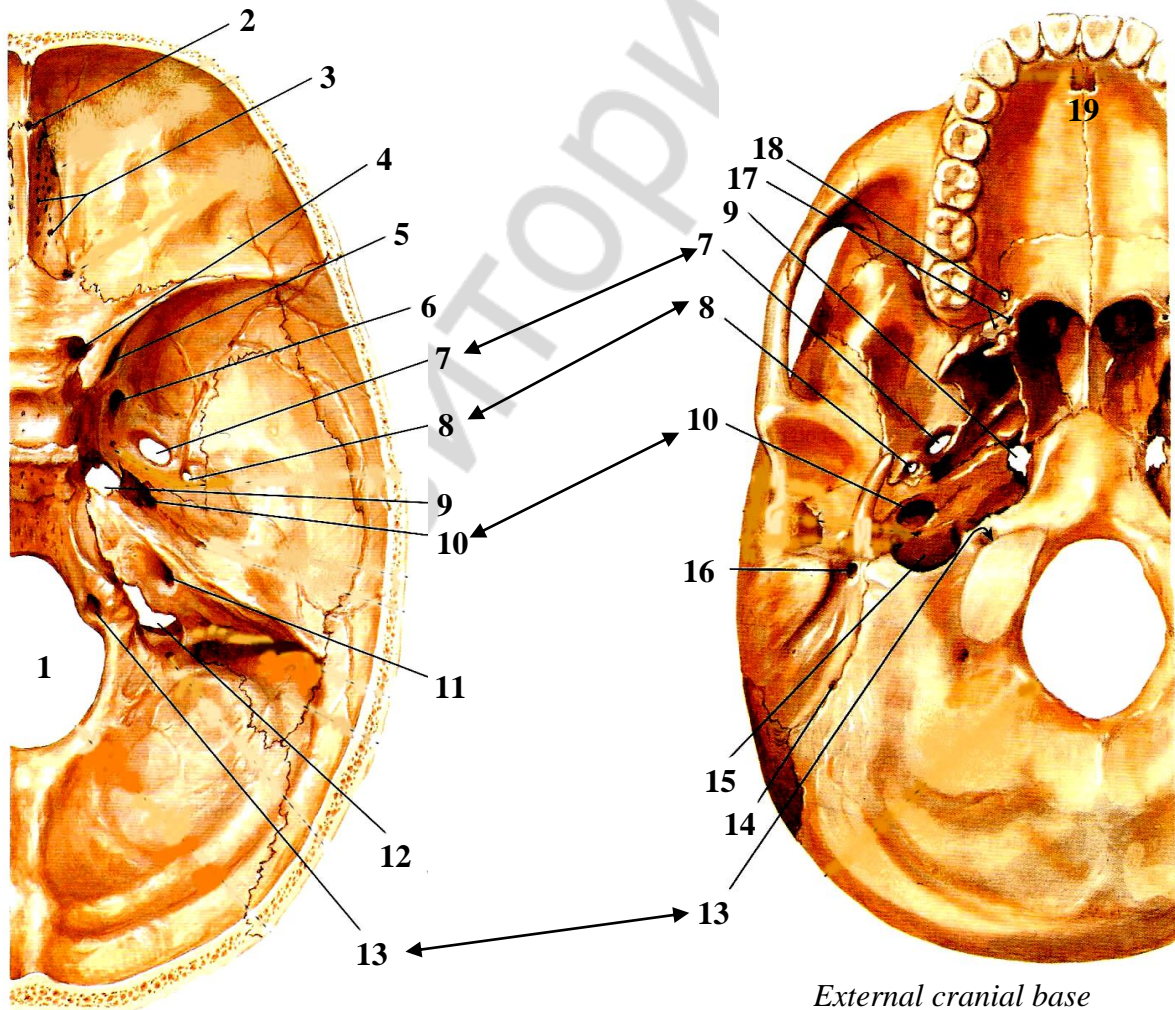
With which paranasal sinuses are nasal passages connect?

Upper _____

Middle _____

Lower _____

CRANIAL BASE



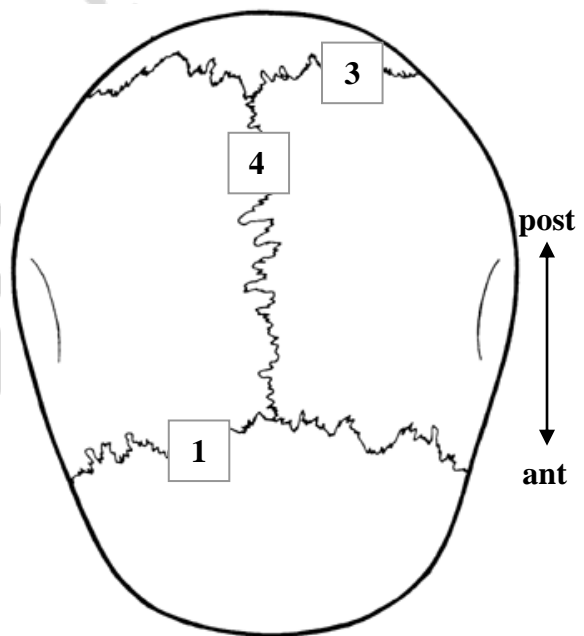
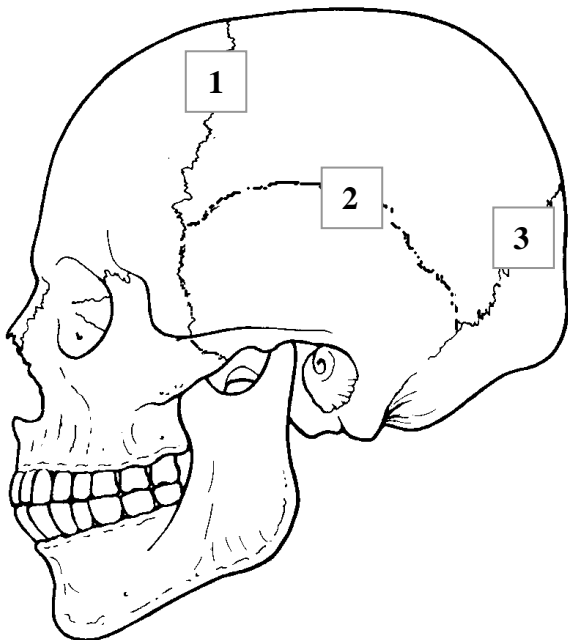
Internal cranial base

External cranial base

Name anatomical structures, designated in the pictures:

- | | |
|-----------|-----------|
| 1. _____ | 11. _____ |
| 2. _____ | 12. _____ |
| 3. _____ | 13. _____ |
| 4. _____ | 14. _____ |
| 5. _____ | 15. _____ |
| 6. _____ | 16. _____ |
| 7. _____ | 17. _____ |
| 8. _____ | 18. _____ |
| 9. _____ | 19. _____ |
| 10. _____ | |

CALVARIUM



Color and name the bones forming the calvarium:

Color	Name of bone

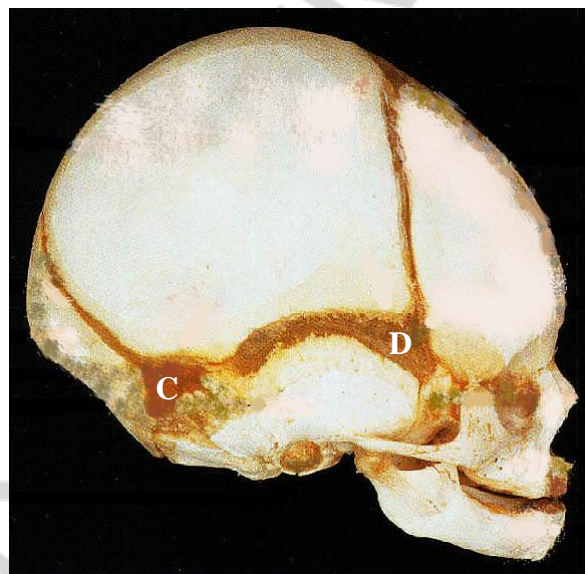
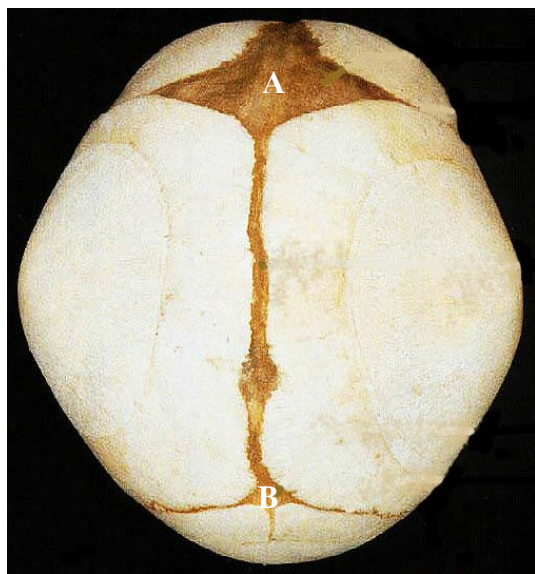Name the sutures, indicated in the picture:

1. _____
2. _____
3. _____
4. _____

NEONATAL CRANIUM

Construction features of a neonatal cranium:

1. Volume of cerebral cranium is 8 times bigger than facial cranium.
2. Frontal bone consists of two parts.
3. Tubercle of frontal and parietal bone is good-visible.
4. Ethmoidal, sphenoidal, frontal paranasal sinuses are absent.
5. Mandibles are underdeveloped, it consists of two parts, jointed with mandibular symphysis.
6. Bones are jointed with synchondrosis in the cranial basis.
7. There are fontanelles over the calvarium (regions of membranous) cranium)



Name the fontanelle and mark (using sign +) its overgrowing terms:

№	Name	Prenatal	2–3 month	1 year
A				
B				
C				
D				

Topics of students scientific and research work:

1. Development and age-specific features of certain cerebral and facial bones.
2. Versions and abnormalities of cranial bones development.
3. Construction and growth features of maxilla and mandible.
4. Maxilla and mandible abutments.
5. Development, construction and variational anatomy of auriferous sinuses.
6. Craniometry.
7. Cranium of a newborns.
8. Cerebral and facial cranial bones fractures.

Lab № 5

Topic: COMPARATIVE CHARACTERISTICS OF THE BONES OF THE UPPER AND LOWER EXTREMITIES. PART II. BONE JUNCTIONS

Control questions:

1. The overall plan of structure of skeleton of the upper and lower extremities. Similarities and differences between the skeletal upper and lower extremities.
2. Bones of shoulder girdle.
3. The skeleton of the upper extremity free part. The palpation-place of supracondyl of humerus, olecranon ulna, styloid process of radius and ulna, metacarpal bones, phalanges.
4. Pelvic girdle; structure of hip bone.
5. The skeleton of the lower extremity free part. The palpation-place of patella, tuberosity of tibia, lateral and medial ankle.
6. What is the most frequent location of fractures of long bones of the upper and lower extremities?
7. Classification of bone junctions.
8. Morphological and functional characteristics of both continuous and discontinuous (synovial) junctions of bones. Compounds of vertebral column: syndesmosis, structure of the intervertebral symphysis.
9. Joints of vertebral column: the structure of median and lateral atlantoaxial joints. Zhygapophysial joints. What is the danger of dislocation of tooth in the median atlanto-occipital joint?
10. The joints of chest: the joint head of rib and costotransverse joint, structure, types of movements.
11. Temporomandibular joint: morphological and functional characteristics.
12. The names and general morphological and functional characteristic joints of the upper and lower extremities.

Student must be able to find on anatomical preparation and visual aids anatomical structures and know their Latin name:

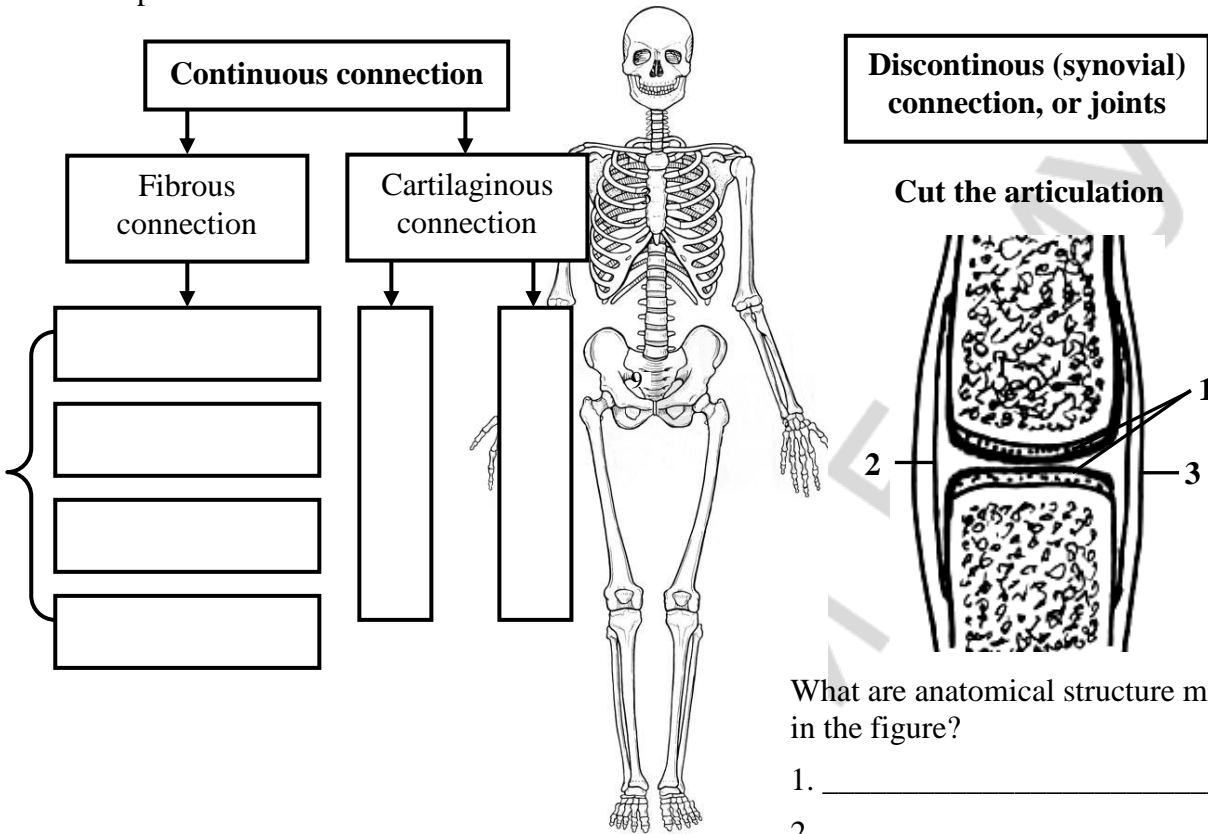
I. Bones of the upper and lower extremities. 1. Scapula. 2. Clavicle. 3. Humerus. 4. Radius. 5. Ulna. 6. Carpal bones. 7. Metacarpal bones. 8. Phalanges. 9. Hip bone. 10. Ilium. 11. Ischium. 12. Pubis. 13. Femur. 14. Tibia. 15. Fibula. 16. Tarsal bones. 17. Metatarsals.

II. Union of bones. 1. Intervertebral disc. 2. Zygapophysial joints. 3. Atlantooccipital joint. 4. Medial atlantoaxial articulation. 5. Lateral atlantoaxial articulation. 6. Shoulder joint. 7. Elbow joints. 8. Proximal radioulnar articulation. 9. Distal radioulnar articulation. 10. Radiocarpal articulation. 11. Hip joint. 12. Knee joint. 13. Ankle joint.

III. Temporomandibular joint. 1. The articular disc. 2. The lateral ligament. 3. Sphenomandibular ligament. 4. Stylomandibular ligament.

CLASSIFICATION OF BONE JUNCTIONS

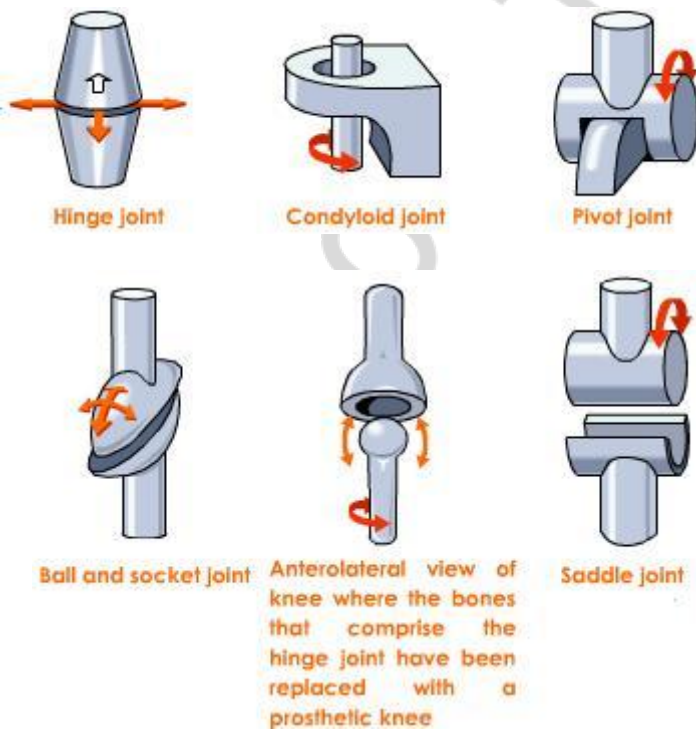
Complete the table:



What are anatomical structure marked in the figure?

1. _____
2. _____
3. _____

BONE JUNCTIONS: JOINTS

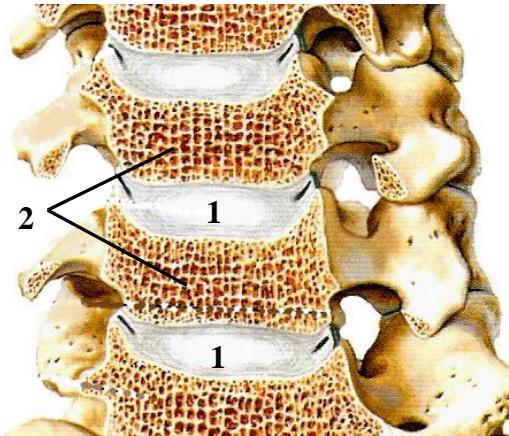


What are examples of joints with different shape of the articular surfaces?

- Hing _____
- Condyloid _____
- Pivot _____
- Saddle _____
- Ball _____
- Trochlea _____

BONE JOINTS. Vertebral column

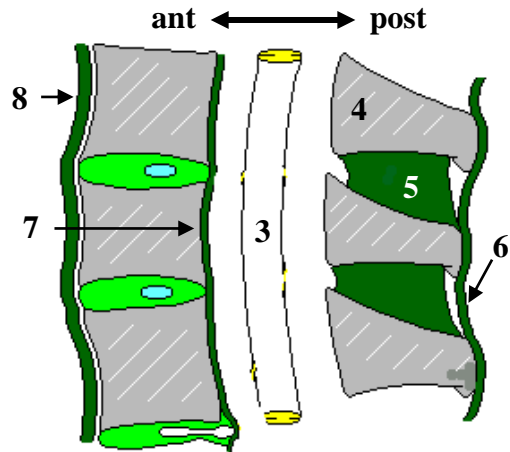
Intervertebral symphysis



What are the name of anatomical structures indicated in the figure?

1. _____
2. _____
3. _____
4. _____
5. _____
6. _____
7. _____
8. _____

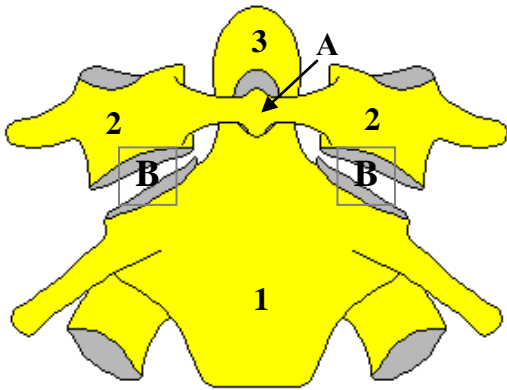
Ligaments vertebral column (ripping)



What is the type of compounds of the intervertebral symphysis?

- _____
- _____

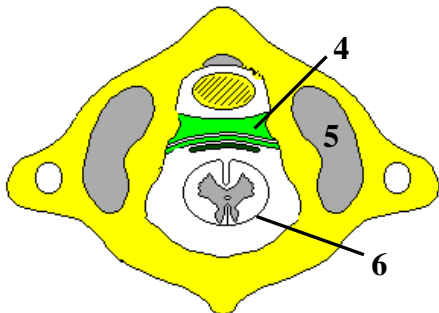
Atlantoaxial articulations



Which joints are shown in the figure?

- A — _____
- B — _____

1 and 2 cervical vertebrae (front)

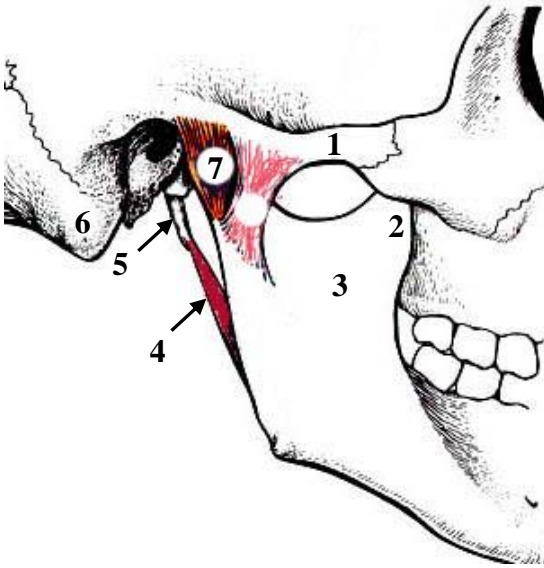


Atlas (top view)

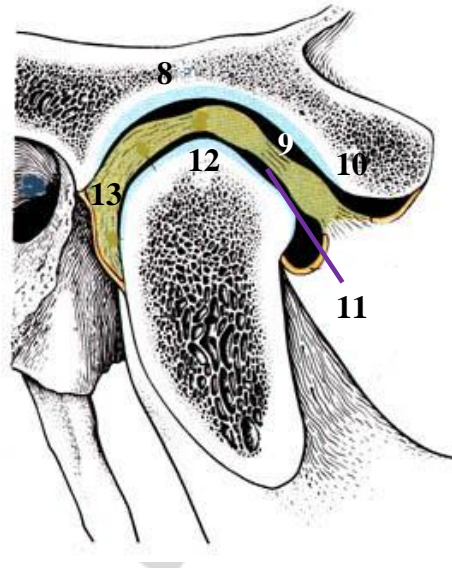
What are the name of anatomical structures indicated in figure?

1. _____
2. _____
3. _____
4. _____
5. _____
6. _____

TEMPOROMANDIBULAR JOINT



Lateral view



Sagittal view

Name the anatomical structures marked in the figure:

1. _____
2. _____
3. _____
4. _____
5. _____
6. _____
7. _____

8. _____
9. _____
10. _____
11. _____
12. _____
13. _____

Describe the temporomandibular joint:

1. The shape of articular surfaces:

- Plane
- Ellipsoid
- Hinge
- Spheroid

3. The number of movement axes:

- Uniaxial
- Biaxial
- Multiaxial

2. The number of joint surfaces:

- Simple joint
- Articular meniscus
- Mixed joint
- Articular disc

4. The presence of intra-articular structures:

- Composite joint
- Intra-capsular ligament
- Articular lip

Lab № 6

Topic: FINAL CLASS ON OSTEOLOGY AND ARTROSYNDESMOLOGY

Control questions:

1. Classification of bones.
2. The structure of cervical vertebrae. Structural features of atlas and axis.
3. The structure of thoracic vertebrae.
4. Vertebral column, complete overview. Congenital abnormalities.
5. The ribs and sternum: structure, classification. Thorax, complete overview.
6. The skeleton of the upper extremity: parts, the relative positions of bones, general plan of construction.
7. The skeleton of the lower extremity: parts, the relative positions of bones and general plan of construction.
8. Classification of joints.
9. Compounds of spine: ligaments, intervertebral symphysis, zygapophysial joints.
10. Atlantooccipital and atlantoaxial joints: articular surface, ligaments, movement.
11. The compounds of chest.
12. Thorax, complete overview.
13. The names and general morphological and functional characteristics of joints of the upper and lower extremities.
14. Skull: the name of the bones, division into the front and cranial sections.
15. The structure of the cranial bones: frontal, occipital, parietal, sphenoid, ethmoid, temporal bones.
16. The structure of maxilla.
17. The structure of mandible.
18. Nasal cavity: bony wall, nasal meatus and its connection with paranasal sinuses and eye socket (orbit).
19. Orbit: bony walls, foramina, fissures and channels.
20. The bones of calvaria, characteristic of structure and development. Calvaria sutures.
21. External and internal base of skull, the surface relief.
22. Structure of palatum osseum.
23. Lateral normal of skull: bony wall of temporal and infra-temporal fossae.
24. Bony wall of pterygopalatine fossa. Connections with other cavities of skull.
25. Craniometry, basic craniometric points and measurements of cerebral and visceral cranium.
26. Structural features of newborn's skull.
27. Temporomandibular joint: characteristics, structure, types of movement.

LAB № 7

Topic: MUSCLE: GENERAL AND MORPHOFUNCTIONAL CHARACTERISTICS. MUSCLE OF HEAD AND NECK

Control questions:

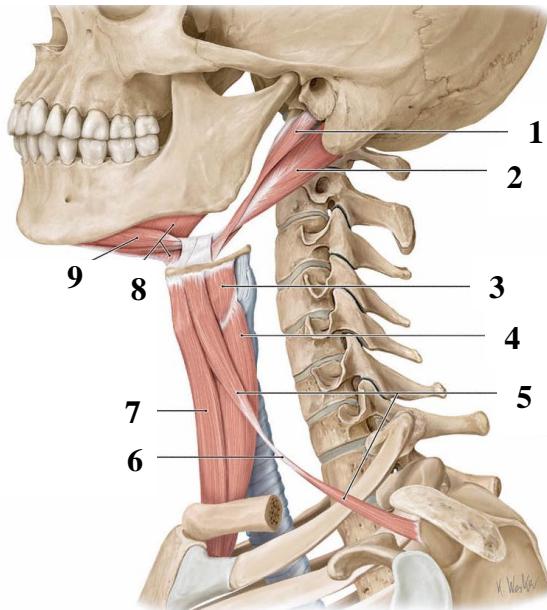
1. Skeletal muscle: classification and functions.
2. The structure of muscle as an organ. The size and strength of skeletal muscle: anatomically and physiological diameter of the muscle. Types of the skeletal muscles.
3. Accessory apparatus of muscle: fascia, synovial vagina and bags, bones and fibrous channels, sesamoid bone.
4. Classification of neck muscles
5. Superficial muscles of the neck: origin and insertion, functions.
6. Middle group of neck muscles: origin and insertion, functions.
7. Deep muscles of neck: origin and insertion, functions.
8. The structure of the cervical fascia and the topography of its plates.
9. Spaces of the neck: open and closed.
10. The division of neck into the regions. Anterior and lateral regions of the neck: borders, triangles.
11. Sources of development and general characteristics of masticatory muscles. Origin and insertion, direction of the fibers, functions.
12. Sources of development and general characteristics of facial muscles.
13. Sources of development and general characteristics of facial muscles.
14. Origin and insertion and fiber orientation, function of facial muscles.
15. The fascia of head: temporal, masseteric fascia, bucco-pharyngeal. The localization of pterygomandibular raphe.

Student must be able to find out the above structures on anatomical preparations and to know their Latin names:

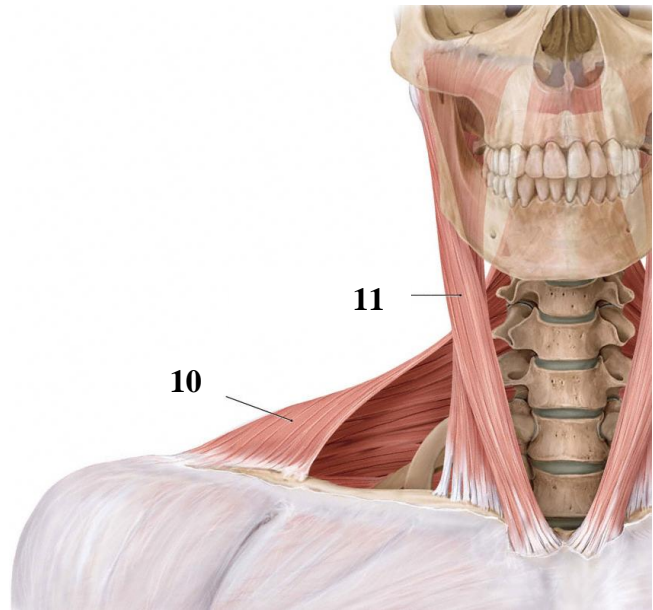
I. The neck muscles. 1. Platysma. 2. Sternocleidomastoid muscle. 3. Digastric muscle. 4. Stylohyoid. 5. Mylohyoid muscle. 6. Geniohyoid muscle. 7. Sternohyoid muscle. 8. Omohyoid muscle. 9. Sternothyroid muscle. 10. Thyrohyoid muscle. 11. The anterior, middle, posterior scalene muscles. 12. Muscles longus coli. 13. Muscles longus capiti. 14. Spatium suprasternale. 15. Previscerale space. 16. Retroviscerale space. 17. Interscalene interspace. 18. Anterior triangle of neck. 19. The lateral triangle of neck. 20. Omotrapezoidem triangle. 21. Omoclavicular triangle. 22. Carotic triangle. 23. Omotracheal triangle. 24. Submandibular triangle. 25. Submental triangle.

II. Muscles and fascia of the head. 1. Masseter. 2. Temporalis muscle. 3. Lateral pterygoid muscle. 4. The medial pterygoid muscle. 5. Occipital-frontal muscle. 6. The nasal muscle. 7. Muscles orbicularis oculi. 8. Muscles orbicularis oris. 9. Muscle levator labia superior. 10. Muscle depressor labia inferior. 11. Muscle levator anguli oris. 12. Mentalis. 13. Buccinator. 14. Temporal lobe, masseter, buccopharyngeal fascia. 15. Pterygomandibular raphe.

NECK MUSCLE



Lateral view

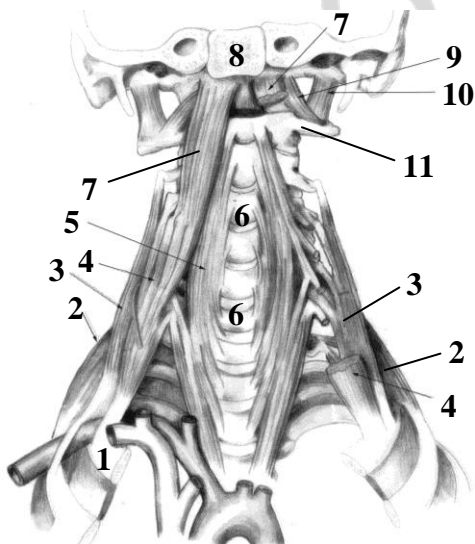


Anterior view

Name the anatomical structures marked in the figure:

1. _____
2. _____
3. _____
4. _____
5. _____
6. _____
7. _____
8. _____
9. _____
10. _____
11. _____

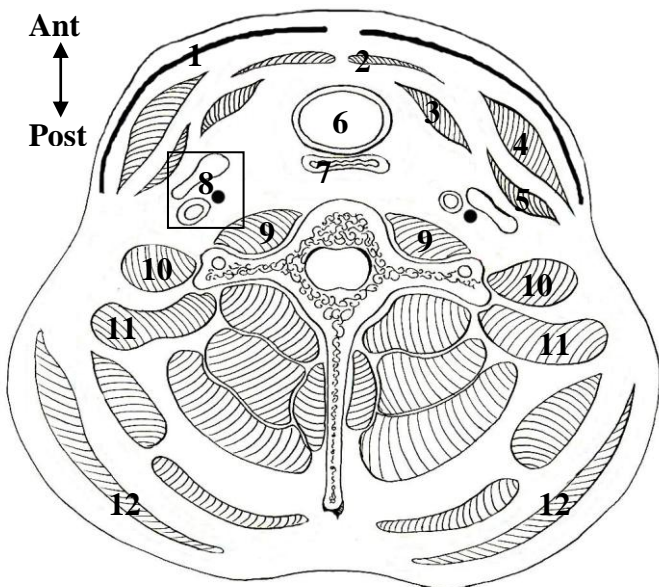
DEEP MUSCLE OF NECK



Name the anatomical structures marked in the figure:

1. _____
2. _____
3. _____
4. _____
5. _____
6. _____
7. _____
8. _____
9. _____
10. _____
11. _____

FASCI OF NECK



Color in different colors:

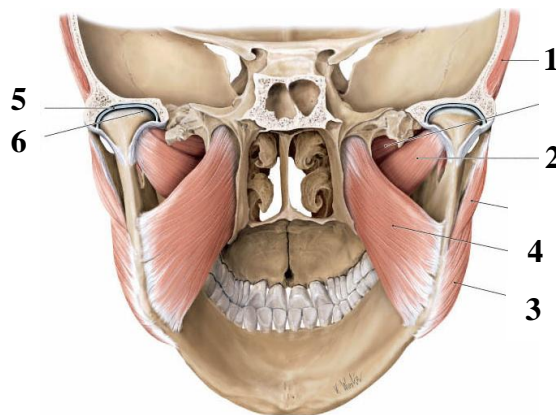
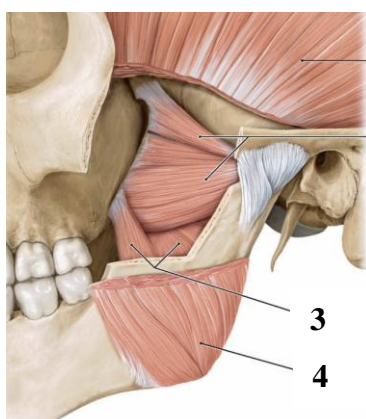
- superficial (subcutaneous) fascia of neck
- superficial plate of neck fascia
- pretracheal plate of neck fascia
- prevertebral plate of neck fascia
- carotid sheath

Crosscut of the neck

Name the anatomical structures marked in the figure:

- | | |
|----------|-----------|
| 1. _____ | 7. _____ |
| 2. _____ | 8. _____ |
| 3. _____ | 9. _____ |
| 4. _____ | 10. _____ |
| 5. _____ | 11. _____ |
| 6. _____ | 12. _____ |

MASTICATORY MUSCLES



Name anatomical structures marked in the figure:

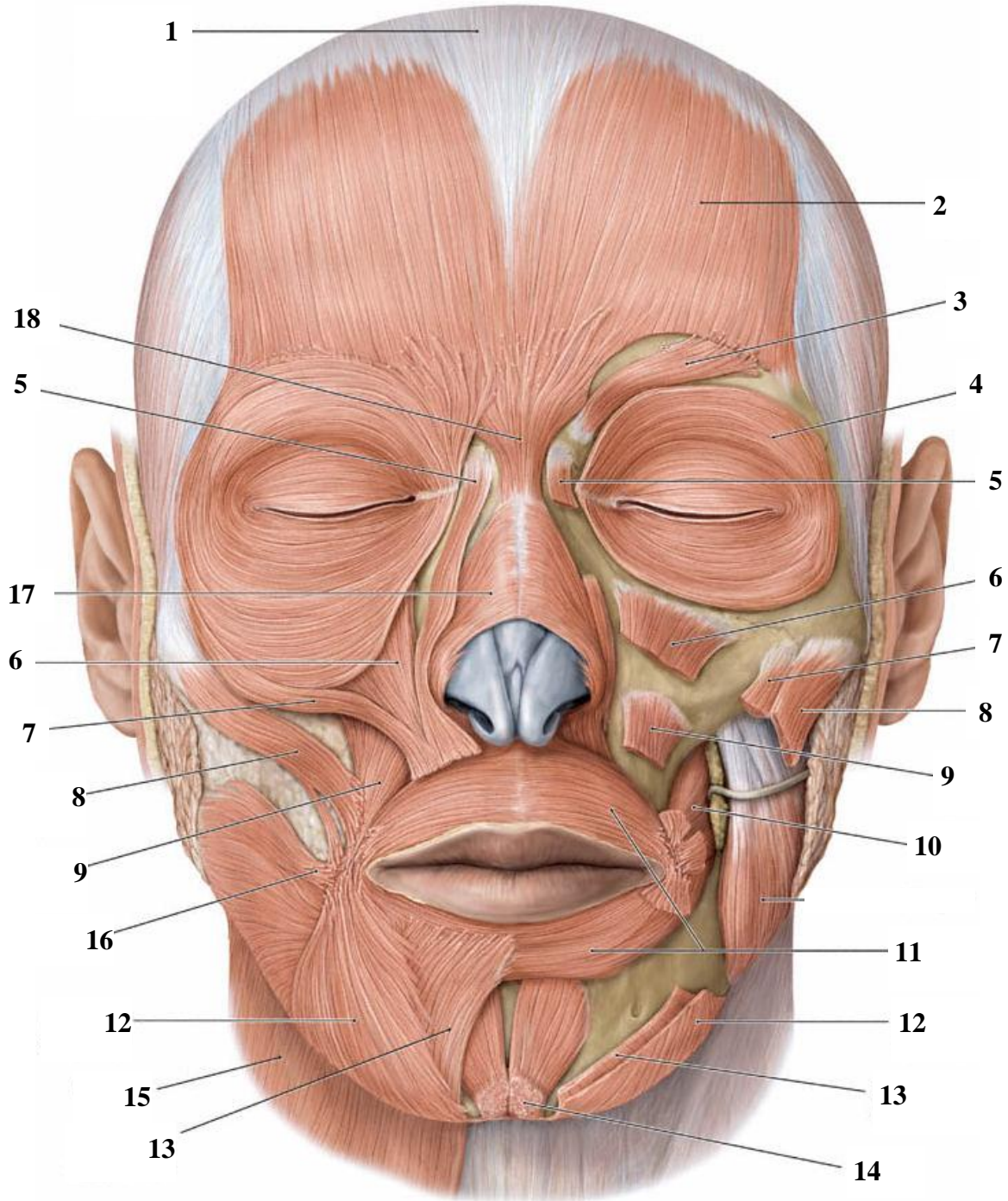
- | | |
|----------|----------|
| 1. _____ | 4. _____ |
| 2. _____ | 5. _____ |
| 3. _____ | 6. _____ |

Name the source of origin of masticatory muscles: _____

Masticatory muscles are innervate by _____

Masticatory muscles are supply by _____

FACIAL MUSCLES



Name the anatomical structures marked in the figure:

1. _____
2. _____
3. _____
4. _____
5. _____
6. _____
7. _____
8. _____
9. _____
10. _____
11. _____
12. _____
13. _____
14. _____
15. _____
16. _____
17. _____
18. _____

Peculiarities of structure and function of facial muscles:

- All the facial muscles (46) are occurred from the mesenchyme of the second visceral arch.
- Located around the orifices of skull (circular or angular).
- One end attaches to the skin or mucosa.
- It is without fascia.
- Gives a certain expression (mimicry) to a face, are involved in chewing, speech articulation, breathing.
- There are individual differences in the shape and size of facial muscles (the muscles surrounding the merger or dividing into separate muscle bundles, the lack of individual muscles, and additional facial muscles).

Age features of the structure and function of facial muscles:

- The mimicry is more expressive in children, but emotional connotation is poor. Muscles are around the mouth are well developed.
- Expressive of mimicry is richer at the age of 15.
- The configuration of the lips and oral fissure change in elderly.
- In the corners of the mouth and eyes are formed grooves and folds.

Lab № 8

Topic: STRUCTURE AND FUNCTION OF MUSCLES OF THE TRUNK, UPPER AND LOWER LIMBS

Control questions:

1. Muscles of trunk. Back muscles: the division into superficial and deep, functions.
2. Chest muscles that attach to the upper extremity and own chest muscles, general characteristics.
3. Diaphragm: topography, structure, and function.
4. Abdominal muscles: general morphological and functional characteristics. Topography of anterior abdominal wall: white line, umbilical ring, inguinal canal.
5. Muscles of shoulder [thoracic] girdle: general morphological and functional characteristics.
6. Muscles of girdle of lower extremity: general morphological and functional characteristics.

Student must be able to find listed structures on anatomical preparations and to know their Latin names:

I. Back muscles. 1. Trapezius muscle. 2. The latissimus dorsi muscle. 3. Rhomboid muscle. 4. Serratus posterior superior muscle. 5. Serratus posterior inferior muscle.

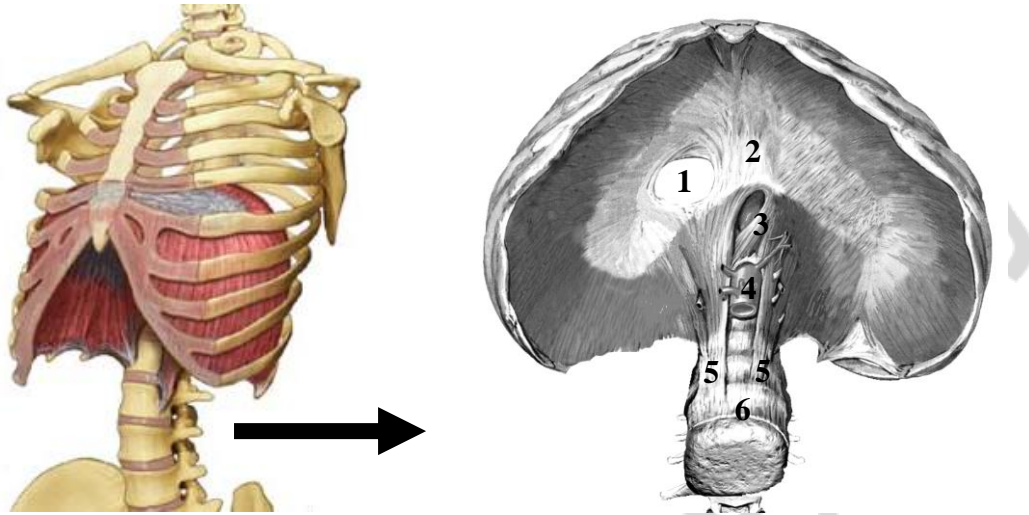
II. Chest muscles. 1. Greater pectoral muscle. 2. Lesser pectoralis minor. 3. The serratus anterior muscle. 4. External intercostal muscle. 5. Internal intercostal muscles. 6. Diaphragm.

III. The abdominal muscles. 1. External oblique muscle. 2. Internal oblique muscle. 3. Transverse muscle of abdomen. 4. The rectus muscle of abdomen. 5. White line. 6. Umbilical ring. 7. The inguinal canal.

IV. The muscles of the upper extremity. 1. Girdle of superior extremity. 2. Shoulder muscles. 3. Forearm muscles. 4. Muscles of the hand.

V. The muscles of the lower extremity. 1. The muscles of the lower extremity. 2. The thigh muscles. 3. The calf muscles. 4. The muscles of the foot.

MUSCLES OF THORAX



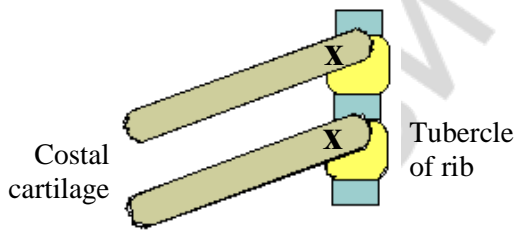
View from the side of the abdomen

What are the muscles lie on the border of the thoracic and abdominal cavities _____

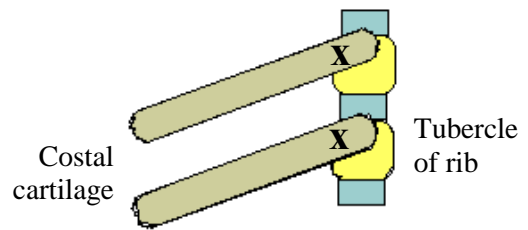
and indicate in figure the anatomical structures:

1. _____
2. _____
3. _____
4. _____
5. _____
6. _____

Draw the direction of movement of muscle fibers:



External intercostal muscle

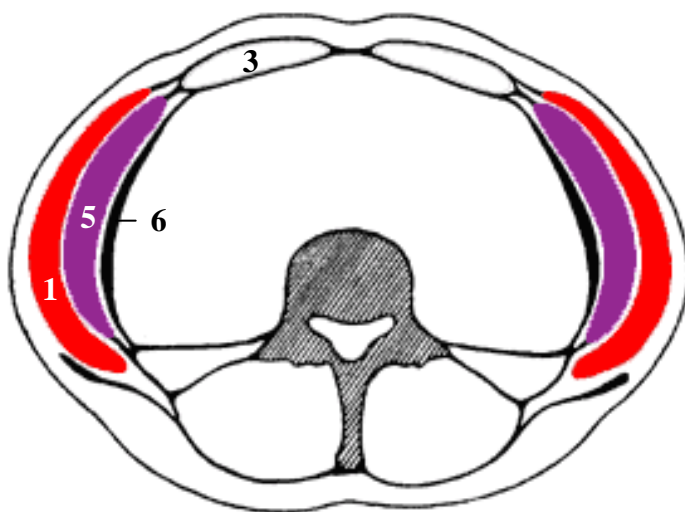
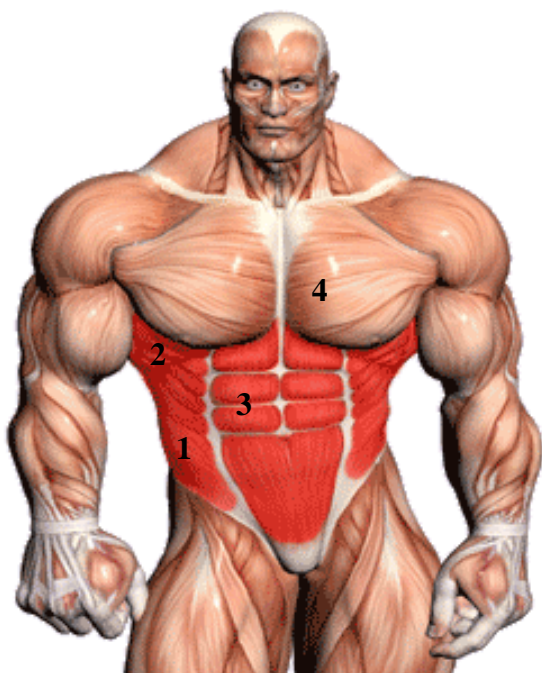

Internal intercostal muscle

Point by the "+" sign in the phases of respiratory cycle, in which the listed below muscles are involved:

Name of muscle	Inspiration	Expiration
Diaphragm		
External intercostal muscle		
Internal intercostal muscle		
Abdominal muscles		

MUSCLES OF ABDOMEN



Crosscut of tht abdomen

Name the muscle indicated in the figure:

- | | |
|----------|----------|
| 1. _____ | 4. _____ |
| 2. _____ | 5. _____ |
| 3. _____ | 6. _____ |

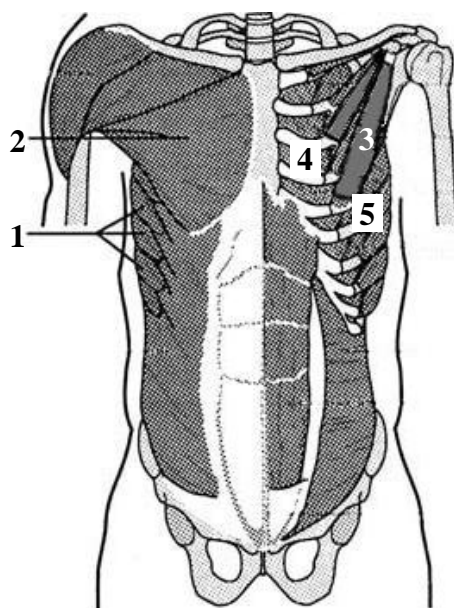
List the "weak" places of anterior wall of abdomen — the exit site of hernia sac:

1. _____
2. _____
3. _____
4. _____

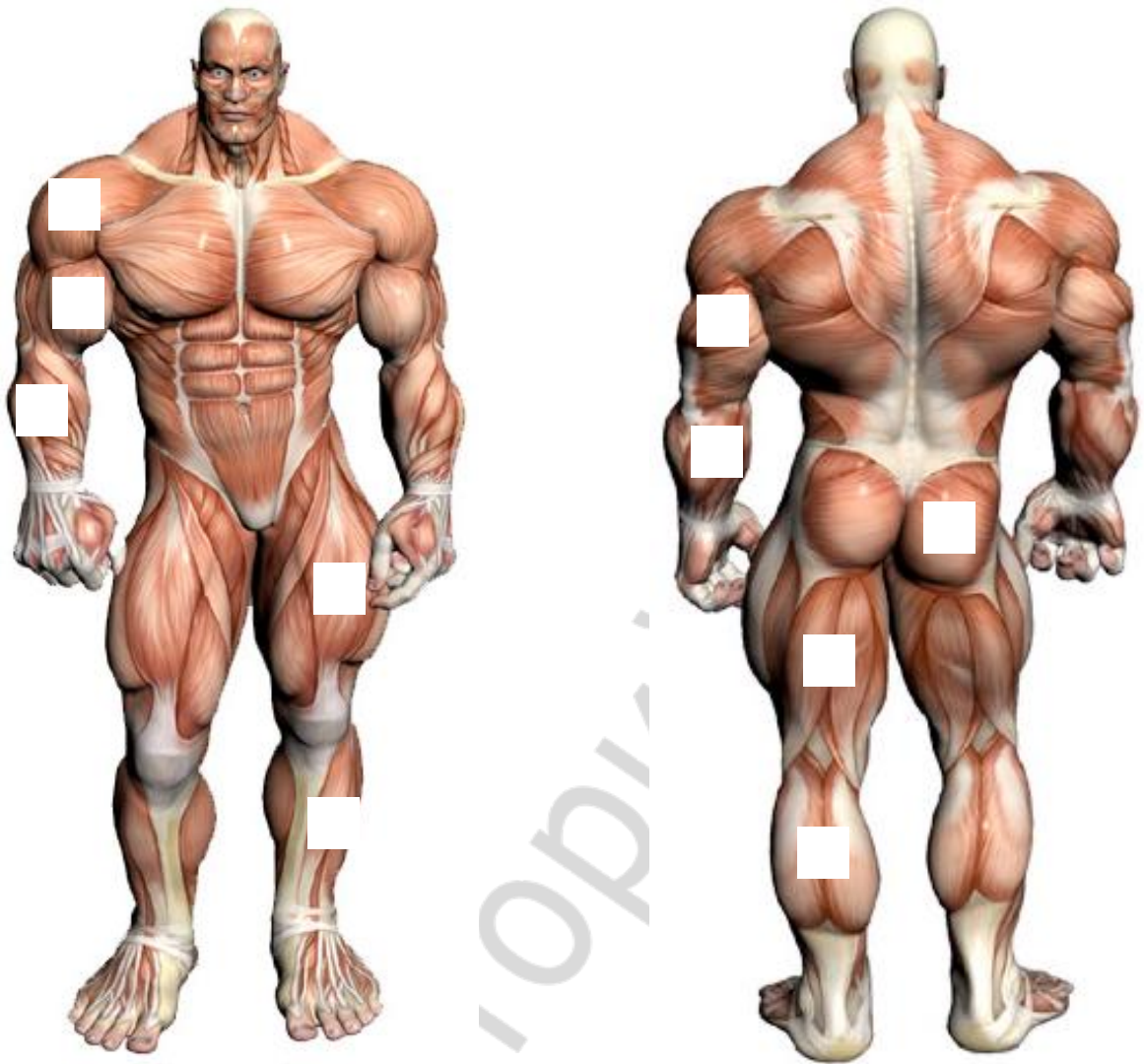
CHEST MUSCLES

What muscles are located in the anteriolateral wall of thoracic cavity:

1. _____
2. _____
3. _____
4. _____
5. _____



MUSCLES OF EXTREMITY



Complete the table:

№	Name the group of muscles	Functions
1.	Girdle of superior extremity	
2.	Anterior group of shoulder muscles	
3.	Posterior group of shoulder muscles	
4.	Anterior group of forearm muscles	
5.	Posterior group of forearm muscles	
6.	The muscles of the girdle of superior extremity	
7.	Anterior group of thigh muscles	
8.	Posterior group of thigh muscles	
9.	Anterior group of the Calf	
10.	Posterior group of the Calf	

Lab № 9

Topic: FINAL LESSON ON MYOLOGY

Control questions:

1. General Myology: structure and classification of skeletal muscles. Accessory apparatus of muscles
2. Classification of neck muscles.
3. Superficial muscles of the neck: origin and insertion, functions.
4. Suprahyoid muscles of the neck: origin and insertion, functions.
5. Infrahyoid neck muscles: origin and insertion, functions.
6. Deep muscles of neck: origin and insertion, functions.
7. The structure of the cervical fascia and the topography of its plates.
8. The spaces of neck.
9. The anterior region of neck: borders, triangles.
10. Lateral region of neck: borders, triangles.
11. Masticatory muscles: origins of development, its structure and function.
12. Facial muscles: classification, sources of development, structure and function.
13. Muscles of trunk; classification. General features of the back muscles.
14. Chest muscles: classification, general characteristics.
15. The structure of diaphragm.
16. The abdominal muscles, general characteristics.
17. Topography of anterior abdominal wall: white line, umbilical ring, inguinal canal.
18. Muscles of the shoulder girdle and the upper extremity: general morphological and functional characteristics.
19. Muscles of the pelvic girdle and the lower extremity: general morphological and functional characteristics.

LITERATURE

1. *Sapin, M. R.* Textbook of Human anatomy : for medical students / M. R. Sapin, L. L. Kolesnicov ; transl. from Russian. Moscow, 2007. Vol. 1.
2. *Drake, R.* Gray's anatomy for students / R. Drake, A. Wayne Vogl. Elsevier, 2010.
3. *Feneis, H.* Pocket atlas of human anatomy / H. Feneis, W. Dauber. Stuttgart, New York : Thieme, 2000. 501 p.
4. *Prives, M.* Human anatomy. Vol. 1. The weight-bearing and locomotor system; The science of the viscera; The science of the organs of internal secretion / M. Prives, N. Lysenkov, V. Bushkovich. Moscow : Mir Publishers, 1985. 608 p.
5. *Netter, F. H.* Atlas of human anatomy / F. H. Netter. Saunders/Elsevier, 2006. 595 p.

CONTENTS LIST

Lab № 1.....	4
Lab № 2.....	7
Lab № 3.....	12
Lab № 4.....	17
Lab № 5.....	22
Lab № 6.....	26
Lab № 7.....	27
Lab № 8.....	32
Lab № 9.....	36
Literature.....	37

РЕПОЗИТОРИЙ БГМУ

Учебное издание

Кабак Сергей Львович
Манулик Владимир Александрович
Синельникова Наталья Владимировна и др.

ОПОРНО-ДВИГАТЕЛЬНЫЙ АППАРАТ

MUSCULO-SKELETAL SYSTEM

Практикум по анатомии человека

На английском языке

4-е издание

Ответственная за выпуск Н. В. Синельникова
Переводчики: Е. Л. Колб, Н. В. Журавлева
Компьютерная верстка Н. М. Федорцовой

Подписано в печать 18.05.16. Формат 60×84/8. Бумага писчая «Снегурочка».

Ризография. Гарнитура «Times».

Усл. печ. л. 4,65. Уч.-изд. л. 2,53. Тираж 122 экз. Заказ 394.

Издатель и полиграфическое исполнение: учреждение образования
«Белорусский государственный медицинский университет».
Свидетельство о государственной регистрации издателя, изготовителя,
распространителя печатных изданий № 1/187 от 18.02.2014.
Ул. Ленинградская, 6, 220006, Минск.