

E. L. KOLB, T.I. GUNKO, I.S. KARMALKOVA

AMALGAM IN CLINICAL DENTISTRY

Minsk BSMU 2016

МИНИСТЕРСТВО ЗДРАВООХРАНЕНИЯ РЕСПУБЛИКИ БЕЛАРУСЬ
БЕЛОРУССКИЙ ГОСУДАРСТВЕННЫЙ МЕДИЦИНСКИЙ УНИВЕРСИТЕТ
1-я КАФЕДРА ТЕРАПЕВТИЧЕСКОЙ СТОМАТОЛОГИИ

Е. Л. КОЛЬ, Т. И. ГУНЬКО, И. С. КАРМАЛЬКОВА

АМАЛЬГАМА В ТЕРАПЕВТИЧЕСКОЙ СТОМАТОЛОГИИ

AMALGAM IN CLINICAL DENTISTRY

Учебно-методическое пособие



Минск БГМУ 2016

УДК 616.314-085.242-74(811.111)-054.6(075.8)
ББК 56.6 (81.2 Англ-923)
К60

Рекомендовано Научно-методическим советом университета в качестве
учебно-методического пособия 15.06.2016 г., протокол № 10

Рецензенты: канд. мед. наук, доц. Н. М. Полонейчик; канд. мед. наук, доц.
А. Г. Третьякович; ст. преп. Т. А. Проволоцкая

Колб, Е. Л.
К60 Амальгама в терапевтической стоматологии = Amalgam in clinical dentistry: учеб.-
метод. пособие / Е. Л. Колб, Т. И. Гунько, И. С. Кармалькова. – Минск : БГМУ,
2016. – 28 с.

ISBN 978-985-567-562-5.

Рассматриваются классификация, преимущества и недостатки, показания к применению и
методики работы с традиционными и современными амальгамами в терапевтической стоматологии.

Предназначено для студентов 3-го курса медицинского факультета иностранных учащихся,
обучающихся на английском языке.

УДК 616.314-085.242-74(811.111)-054.6(075.8)
ББК 56.6 (81.2 Англ-923)

ISBN 978-985-567-562-5

© Колб Е. Л., Кармалькова И. С., Гунько Т. И., 2016
© УО «Белорусский государственный
медицинский университет», 2016

INTRODUCTION

Amalgam is one of the oldest filling materials in dentistry; it is the standard for comparison with modern filling materials.

Dental amalgam is a metal-like restorative material composed of a mixture of silver/tin/copper alloy and mercury.

Dental amalgam is one of the most universal restorative materials used in dentistry. It constitutes approximately 75% of all restorative materials used by dentists. It has served as a dental restoration for more than 165 years. There is still no adequate economic alternative for dental amalgam. The combination of reliable long-term performance in load bearing situations, and low cost is unmatched by other dental restorative material. It has a myriad of uses: rather low technique sensitivity, self-sealing property and its longevity.

ADVANTAGES OF DENTAL AMALGAM

1. It is durable, long lasting if placed under ideal conditions.
2. Least technique sensitive of all restorative materials.
3. Applicable to a broad range of clinical situations.
4. It has good long-term clinical performance.
5. Ease of manipulation by dentist.
6. Minimal placement time compared to other materials.
7. Self-sealing properties. Corrosion products seal the tooth restoration interface and prevent bacterial leakage.
8. It is a one-appointment placement (direct material).
9. Very economical.
10. Biocompatible.

DISADVANTAGES OF DENTAL AMALGAM

1. Some destruction of sound tooth tissue.
2. Poor esthetic qualities.
3. Long-term corrosion at tooth-restoration interface may result in «ditching» leading to replacement.
4. Galvanic response potential exists.
5. Local allergic potential.
6. Concern about possible mercury toxicity that affects the CNS, kidneys and stomach.
7. Marginal breakdown.
8. Bulk fracture.
9. Secondary caries.
10. Sometimes excess Hg within the restoration may seep through the dentinal tubules, discolor dentin and result in blackish or grayish staining of teeth. Since enamel is semi-translucent, this discoloration is not inconspicuous.

INDICATIONS FOR DENTAL AMALGAM USING

1. In individuals of all ages.
2. In stress-bearing areas and in small-to-moderate sized cavities in the posterior teeth.
3. Especially used in large MOD cavities.
4. When there is severe destruction of tooth structure
5. As a foundation for cost-metal, metal-ceramic and ceramic restorations.
6. When the patient's commitment to personal oral hygiene is poor.
7. When moisture control is problematic with patients.
8. When cost is an overriding patient's concern.

DENTAL AMALGAM IS NOT USED WHEN:

1. Esthetics is important, both in the anterior teeth and in lingual endodontic- access restorations of the anterior teeth.
2. Patients have a history of allergy to mercury or other amalgam components.
3. A large restoration is needed and the cost of other restorative materials is not a significant factor in the treatment decision.
4. When a woman is breast feeding because mercury can be passed to the baby through breast milk.

CLASSIFICATION OF DENTAL AMALGAM

1. According to alloyed metals (fig. 1):

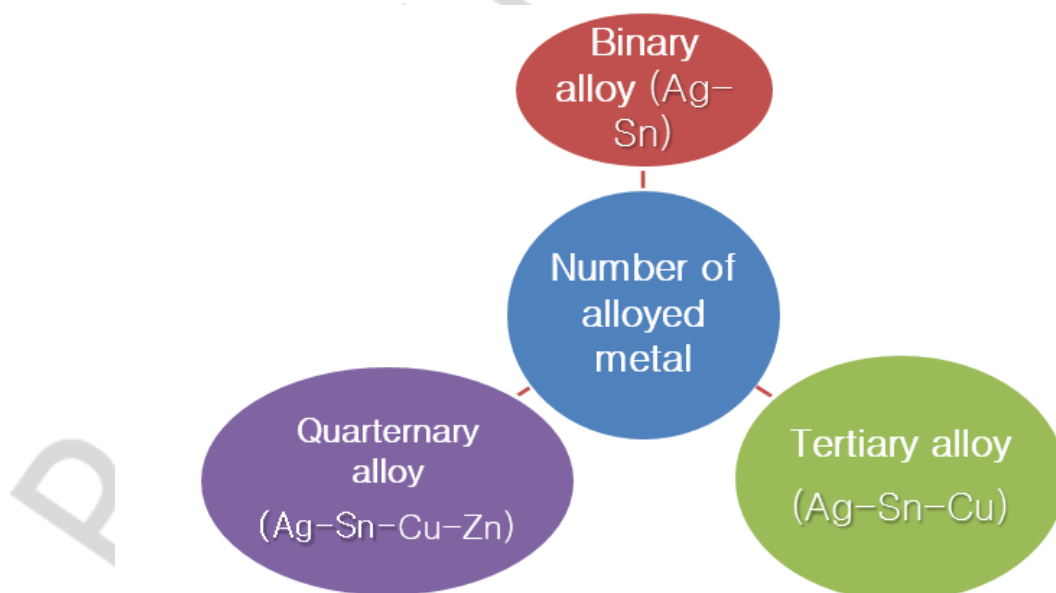


Fig. 1. Classification of dental amalgam according to alloyed metals

2. According to the shape of powdered particle:

- Lathe-cut;
- Spherical;
- Admixed.

Lathe-cut alloys are irregular in shape; they may be fine-grain or coarse-grain. They are heat-treated to produce a uniform composition and regulate properties. The alloy may be dispensed in the form of preweighed tablets or pellets.

Spherical alloys cure alloy particles made in the form of small spheres. One method of preparing this is known as atomizing procedure. Spherical alloys amalgamate very readily. Amalgamation can be accomplished with smaller amount of mercury than that required for lathe-cut alloys (tabl. 1).

Table 1

Differences between Lathe-cut and Spherical alloys

Lathe – cut	Spherical
1. Require more mercury (50 %)	1. Require less mercury (42 %)
2. Require more condensation force	2. Require less condensation force
3. Require smaller condenser points	3. Require broader condenser points
4. Less ease in carving and burnishing	4. Smooth surface during carving & burnishing
5. Less overhangs and strong proximal contacts	5. Overhangs and weak proximal contacts

3. According to zink content:

- Zinc containing alloy (> 0.01 – 2 %);
- Non zinc containing alloy (< 0 – 0.01 %).

4. According to copper content:

- Low copper amalgam(< 0 – 6 %);
- High copper amalgam(> 6 – 13 %).

Generations of dental amalgam:

Class – I Silver and tin in ratio (8 : 1).

Class – II Silver, tin, copper (4 %), zinc.

Class – III Silver eutectic alloy added to original alloy.

Class – IV Copper content increased to 29 %.

Class – V Indium added to mixture of silver, tin and copper.

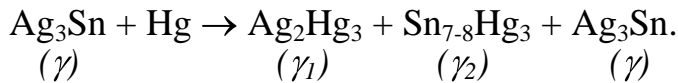
Class – VI Noble metals added such as palladium.

LOW-COPPER AMALGAM

These are also known as «traditional», «conventional» amalgam. Now low-copper amalgam has been replaced by high-copper amalgams. (*JF McCabe, AG Walls: 1998*).

The composition of low-copper, «traditional», «conventional» amalgam alloy is based on G. V. Black's composition of approximately 65 % silver, 25 % tin, less than 6 % copper and sometimes 1 % zinc.

Setting reaction:



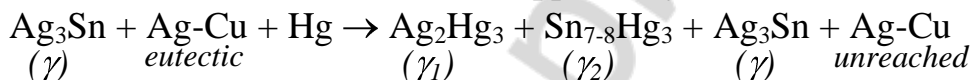
When liquid mercury is mixed with the amalgam alloy, the mercury is both absorbed by the particles and dissolves the surface of the particles. Silver and tin continue to dissolve in the liquid mercury which becomes saturated with silver and tin. The γ_1 (Ag-Hg) and γ_2 (Sn-Hg) phases begin to precipitate. Precipitation is a process in which a solid is formed from material dissolved in a liquid. Precipitation of the γ_1 and γ_2 phases continues until the mercury is consumed and a solid mass results. The setting reaction may take as long as 24 hours to complete, when strength reaches a maximum.

HIGH-COPPER DENTAL AMALGAMS

High-copper amalgam contains 40–60 % silver, 27–30 % tin, 13–30 % copper and 1 % zinc. Sometimes it also contains indium and palladium.

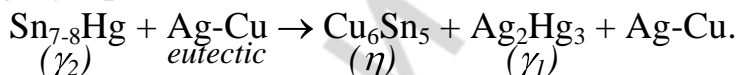
The setting reaction of high-copper amalgams is a little more complex than in low-copper amalgams. Its notable feature is the lack of a γ_2 (Sn-Hg) product. Silver reacts in the same manner as a low-copper amalgam, forming a γ_1 .

For high copper alloys, the reaction is different. It occurs in two phases. The initial reaction is similar in that of low copper alloys, i. e.



The second phase of the reaction involves the silver copper phase (Ag-Cu).

It reacts with γ (Ag_3Sn) and mercury to form Ag_2Hg_3 , Sn_{7-8}Hg and Cu_6Sn_5 phase. The mercury released from Sn_{7-8}Hg (γ_2 phase) reacts with silver to form Ag_2Hg_3 (γ_1) phase.



This reaction goes on. After one week, the γ_2 phase reacts completely with eutectic and replaces all the γ_2 phase by γ and γ_1 phase.

High-copper alloys exhibit the following properties:

- greater strength;
- less tarnish and corrosion;
- less creep;
- less sensitive to handling variables, and produce better long-term clinical results.

There are 2 basic types of high-copper alloys: admixed and single-composition.

More information about composition of dental amalgams and features of dental amalgams components is presented in the table 2 and 3.

Table 2

Composition of different components (in weight percent) in dental amalgam

Type	Ag	Sn	Cu	Zn	Other
Low copper	63–72	26–28	2–7	0–2	—
High-Cu admixed lathe-cut	40–70	26–30	12–30	0–2	—
High-Cu admixed spherical	40–65	0–30	20–40	0	0–1 Pd
High-Cu single spherical	40–60	22–30	13–30	0	0–5 In, 0–1 Pd

Table 3

Features of different components in dental amalgam

Silver(Ag): Decreases creep and setting time Decreases corrosion Increases hardness and edge strength Increases tarnishing	Copper (Cu): Decreases plasticity Increases hardness strength of alloy Reduces creep Reduces tarnish and corrosion
Tin (Sn): Low strength Larger contraction Decreases expansion Increases corrosion Increases plasticity Increases setting time	Indium(In): Decreases surface tension Reduces amount of mercury necessary Reduces emitted mercury vapor Increases strength Reduces creep and marginal breakdown
Zinc (Zn): Decreases brittleness Acts as a deoxidizer Less marginal breakdown	Palladium (Pd): Reduced corrosion Greater luster

PROPERTIES OF DENTAL AMALGAM

Strength. The strength of amalgam depends on the phases that are present. Dental amalgam has high compressive strength (380MPa for low-copper amalgams and 414MPa for high-copper amalgams). However, the tensile and shear strengths are comparatively low. Therefore, amalgam should be supported by tooth structures for clinical success in the long term.

Spherical particle alloys and copper-enriched alloys develop strength more rapidly than conventional lathe-cut materials.

Fine-grain, lathe-cut products develop strength more rapidly than coarse-grain products.

If the amalgam restoration is subjected to chewing or other oral forces before sufficient strength develops, it is at risk for fracture.

Creep. Creep is a slow change in shape caused by compression due to dynamic intra-oral stresses. Creep causes amalgam to flow, so that unsupported amalgam protrudes from the margin of the cavity. These unsupported edges are weak and may be further weakened by corrosion. Fracture causes the formation of

a «ditch» around the margins of the amalgam restoration. Creep also creates overhangs on fillings leading to food trapping and secondary decay (fig. 2).

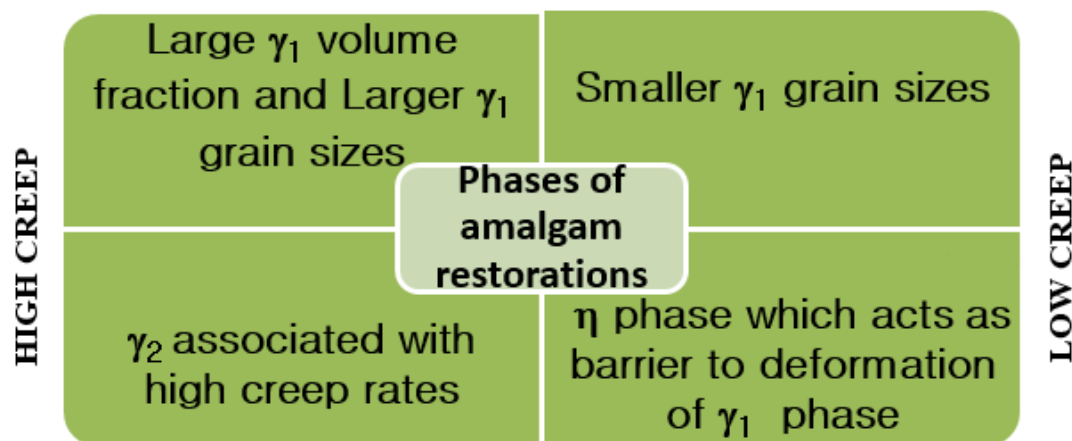


Fig. 2. Factors influencing creep in dental amalgam

Dimensional Change. The contraction or expansion of an amalgam causes its dimensional change. Dimensional change is negative if the amalgam contracts, and positive if it expands during setting. Dimensional change is affected by many factors, such as the mercury/alloy ratio as well as trituration and condensation techniques. During amalgamation reaction, expansion and contraction occur simultaneously. The dissolution of gamma particles generally leads to contraction, whereas the formation of gamma-1 causes expansion. The overall dimensional change is therefore the sum of these two processes. Improper manipulation that alters the ratio of gamma to gamma-1 and η in the set amalgam therefore also will alter its dimensional change.

Chemical Corrosion (Tarnish). Tarnishing simply involves the loss of luster from the surface of a metal or alloy due to formation of a surface coating. The integrity of the alloy is not affected and so no change in mechanical properties is expected. Amalgam readily tarnishes due to the formation of a sulphide layer on the surface.

Electro-chemical Corrosion. Galvanic corrosion occurs when two dissimilar metals exist in a wet environment. Electrical current flows between the two metals, corrosion (oxidation) of one of the metals occurs. The likelihood of galvanic corrosion increases if two metallic phases are present in a metal. Corrosion occurs both on the surface and in the interior of the restoration. Surface corrosion discolors an amalgam restoration and may even lead to pitting. Surface corrosion also fills the tooth/amalgam interface with corrosion products, reducing microleakage. Internal corrosion will lead to marginal breakdown and fracture. An acidic environment promotes galvanic corrosion.

Thermal Diffusivity. Amalgam has a relatively high value of thermal diffusivity. Thus, an amalgam restoration is a good thermal conductor. *In large cavities it is necessary to line the base of the cavity with an insulating, cavity lining material prior to condensing the amalgam. This reduces the harmful effects of thermal stimuli on the pulp.*

Coefficient of Thermal Expansion. This value for amalgam is about three times higher than that for dentin. This coupled with higher diffusivity of amalgam, results in considerably more expansion and contraction in the restoration than in the surrounding teeth when a patient takes hot or cold food or drink. Such a behavior may cause microleakage around the filling since there is no adhesion between amalgam and tooth substance.

MANIPULATION WITH DENTAL AMALGAM

Cavity Preparation.

1. Steps in cavity preparation:
 - Initial cavity preparation;
 - Outline form & initial depth;
 - Primary resistance form;
 - Primary retention form;
 - Convenience form.
2. Final cavity preparation:
 - Removal of any remaining defective enamel or dentin on pulpal floor;
 - Pulp protection;
 - Finishing external walls;
 - Final cleaning & inspection.

Outline Form. The outline form means extending the preparation margins to the place they will occupy in the final preparation. The following facts must be kept in mind while making outline form:

- to remove of all carious and defective pits and fissures to healthy tooth structure;
- to remove of all unsupported enamel rods;
- to avoid ending preparation margins in high stress areas like cusp tip and crest of the ridges;
- to place margins on sound tooth structure.

Steps. With the help of a round dimond bur, establish the external outline form to extend all margins into sound tooth tissue.

The bur should be kept parallel to the long axis of the tooth to make a ditch in the carious portion of the tooth and it should be rotating when applied to the tooth and should not stop rotating until removed.

Maintain the initial depth of 1.5 mm, which is approximately one-half of the length of the cutting bur. This should be, at least 0.2 to 0.5 mm in dentin to provide adequate strength to resist fracture due to occlusal forces (fig. 3). While maintaining the same depth and bur orientation, move the bur to extend the outline to include the central fissure. The margins of preparation not only extend into the sound tooth tissue but also involve adjacent deep pits and fissures in the preparation.

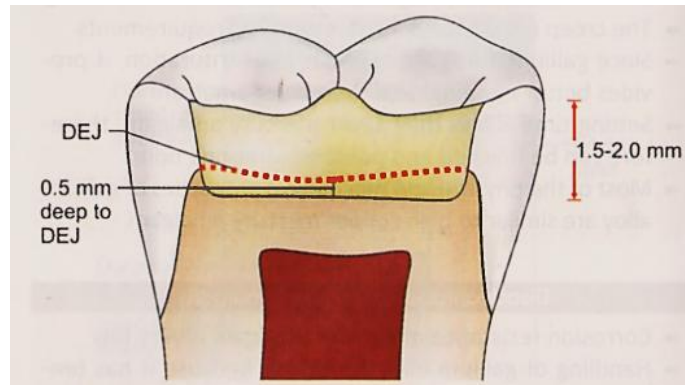


Fig. 3. Initial depth of 1.5 mm should be maintained while preparing outline form

Extend the margin mesially and distally but do not involve marginal ridges. These walls should have dovetail shape to provide retention to the restoration (fig. 4).

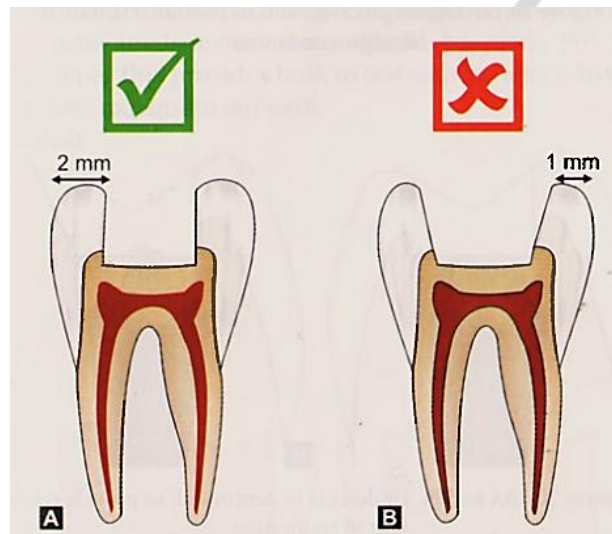


Fig. 4. a — Sufficient marginal ridge; b — Overcutting of marginal ridge causes thinning

While working towards mesial and distal surface, orient the bur towards respective marginal ridge. This will result in slight divergence of mesial and distal walls, which helps to provide dentinal support for marginal ridges (fig. 5).

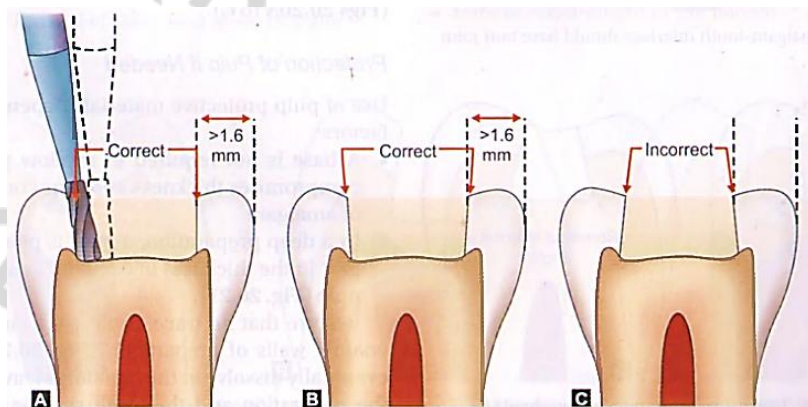


Fig. 5. Sometimes slight divergence of mesial and distal wall is done so as to have dentinal support of marginal ridges

The isthmus width should be as narrow as possible, it should not be wider than the intercusp distance.

The deep pit and fissure defects less than 0.5 mm apart should be included within the outline form.

The external outline form should have smooth curves, straight lines and rounded angles. All unsupported and demineralized enamel should be removed.

Enameloplasty is a careful removal of sharp and irregular enamel margins by «rounding» or «saucering» it and forming an easily cleansable area. The enameloplasty should not extend the outline form. The use of enameloplasty should be done in ends of fissures whenever needed.

Primary Resistance Form. Resistance form is that shape given to a preparation planned to afford such a seat for the restoration so as to best enable it to withstand the occlusal stresses. Primary resistance form should have following features:

- Shape of the preparation should be like a box with flat floor (fig. 6). This helps the tooth to resist occlusal masticatory forces without any displacement. Though it should be flat, at the same time it should follow the contour of occlusal surface (fig. 7).
- To provide adequate thickness of amalgam, keep the minimum occlusal depth of 1.5 mm.
- Provide the cavosurface angle of 90° (fig. 8).
- Restrict the extension of external walls to have strong marginal ridge areas with sufficient dentin support.

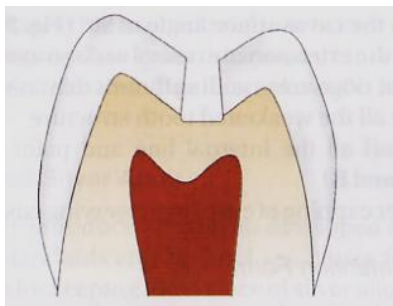


Fig. 6. Box shaped preparation to provide resistance form

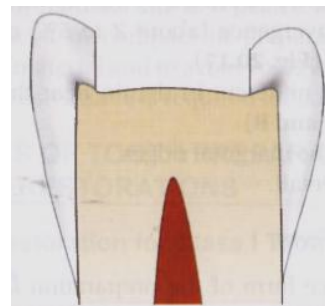


Fig. 7. Though pulpal floor is flat, it should follow the contour of occlusal surface

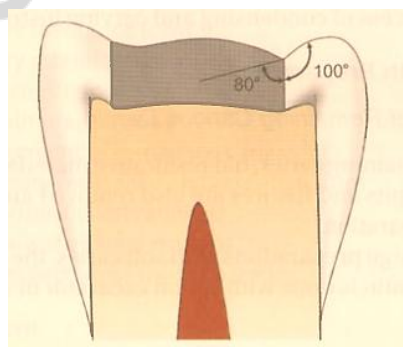


Fig. 8. Amalgam-tooth interface should have butt joint

- Include all the weakened tooth structure.
- Round off all the internal line and point angles (fig. 9).
- Consider capping of cusp for preserving cuspal strength.

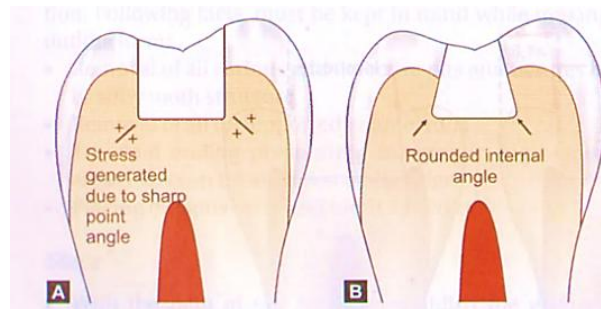


Fig. 9. Internal angles of preparation should be round
a — Sharp angles lead to stress concentration; b — Rounded internal angle

Primary Retention Form. Primary retention form prevents the restoration from being displaced.

Retention can be increased by the following:

- Occlusal convergence (about 2 to 5 %) of buccal and lingual walls (fig. 10).
- Giving slight undercut in dentin near the pulpal wall (fig. 11).
- Conserving the marginal ridges.
- Occlusal dovetail.

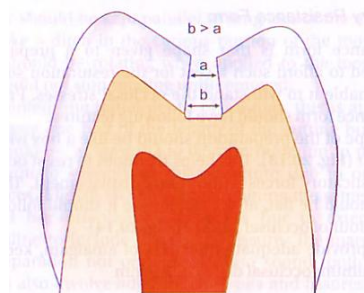


Fig. 10. Convergence of walls to provide retention to amalgam restoration

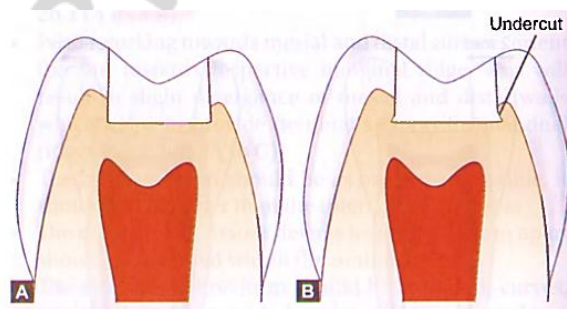


Fig. 11. Undercuts in dentin wall to provide retention of restoration

Convenience Form. The convenience form of the preparation facilitates and provides sufficient visibility, accessibility and ease of operation in preparation and restoration of the tooth. For amalgam restoration, it is the form or shape that also permits access of condensing and carving instruments.

FINAL TOOTH PREPARATION

Removal of Remaining Carious Dentin. In this, remaining caries, old restorative material and adjacent deep pits and fissures are also removed and involved in the preparation. In the large preparations with soft caries, the removal of carious dentin is done with spoon excavator or slow speed round bur. In this, two-step pulpal floor is made, i. e. only portion of tooth which is affected by caries is removed, leaving the remaining floor untouched.

Protection of Pulp if Needed. Use of pulp protective materials depends upon the following factors:

- a base is not required in shallow preparations, as it compromises thickness and thus compressive strength of amalgam
- in a deep preparation, a base is placed in the deepest part in the thickness of 0.5 to 0.75 mm to protect pulp (fig. 12).

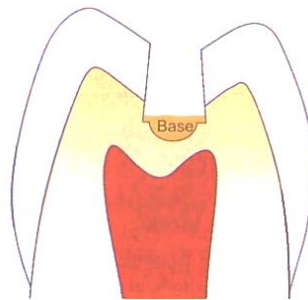


Fig. 12. In deep preparations, base is applied on pulpal floor to protect pulp

Be sure that no trace of the base material remains on enamel walls of preparation (fig. 13), as this would eventually dissolve in the oral fluids leaving a gap between the restoration and the tooth resulting in microleakage and recurrent caries.

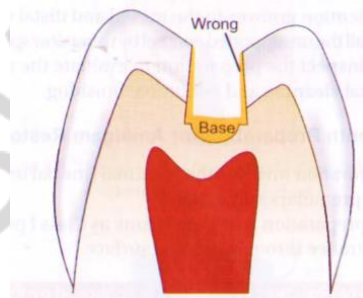


Fig. 13. Do not place base on walls as it would ultimately dissolve in oral fluids, leaving a gap between tooth and restoration

The selection of base for amalgam restorations is based on two factors:

1. It should have sufficient strength to support the forces of amalgam condensation.
2. It should be able to strengthen the restoration under masticatory stresses.

The strength of the bases depends upon the size, thickness and mechanical properties of base along with preparation design, position and amount of occlusal load.

Finishing of the Enamel Walls and Margins. Finishing of walls and margins is guided by the knowledge of dental histology. At this stage all unsupported enamel is removed. Cavo-surface angle, i. e. angle between enamel wall and amalgam interface should be made 90° butt joint type. This provides bulk to restoration, which in turn provides maximum strength.

Final Cleaning and Inspection of the Preparation. The final stage of tooth preparation is to clean the preparation thoroughly with water and air spray. Then dry it with moist air and inspect it for final approval.

AMALGAM APPLICATION

There are five major steps in amalgam application procedure:

1. Proportioning and dispensing.
2. Trituration.
3. Condensation.
4. Carving.
5. Polishing.

1. Proportioning and dispensing. Alloy/mercury ratios vary between 5 : 8 and 10 : 8. For any given alloy/mercury ratio, the nature of the mix may vary depending upon the size and shape of the alloy particles

Various methods of dispensation are available. The most accurate method to weigh the mercury and alloy components is using a balance. Volume dispensers are also common. Another method of dispensation for the alloy is preproportioned as a powder in a small sachet or envelope or as a tablet in which the powder particles are compressed together.

Another convenient method involves the use of encapsulated materials (fig. 14). Each capsule contains both alloy and mercury in proportions that have been determined by the manufacturer. The two components are separated by an impermeable membrane that is shattered using a purpose-built capsule press or starting to vibrate the capsule in a mechanical mixer. Capsules which do not require the use of a press are called self-activating capsules.

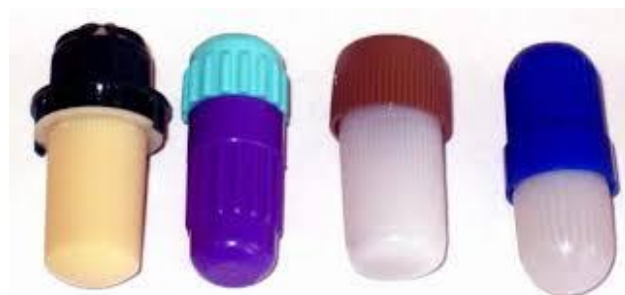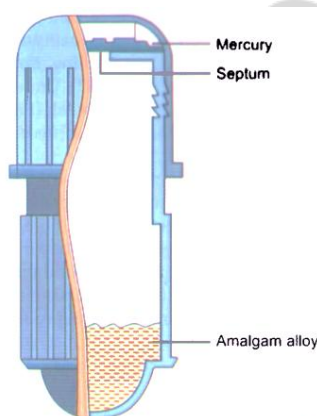


Fig. 14. Encapsulated dental amalgam

2. Trituration. The objective of trituration is to provide proper amalgamation of the mercury and the alloy. The alloy particles are coated with a film of oxide which is removed by abrasion when alloy particles and mercury are triturated. There are two main methods of amalgam trituration (fig. 15).

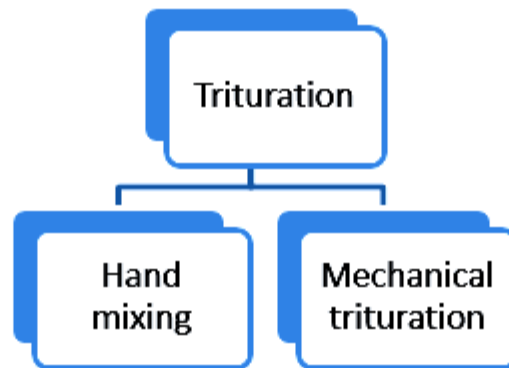


Fig. 15. Ways of amalgam trituration

Hand mixing. A glass mortar and a pestle are used. The mortar has its inner surface roughened to increase the friction. Usually a period of 25 to 45 second is sufficient for hand mixing (fig. 16).



Fig. 16. Hand mixing of dental amalgam

Mechanical trituration. The disposable capsule serves as a mortar and the cylindrical metal placed in the capsule serves as a pestle. The alloy and mercury are dispensed into the capsule; it is secured in the machine, and the machine is turned on. There is an automatic timer for controlling the mixing time.

Modern amalgamator has two or more operating speeds (fig. 17):

- speeds vary upward from 3000 rpm;
- times vary from 5–20 seconds;
- mix powder and liquid components to achieve a pliable mass;
- reaction begins after the components are mixed.

The mulling process generally causes the mix to cohere so that it can be readily removed from the capsule. Spherical alloy requires less amalgamation time than lathe-cut alloys; amalgamation time also depends on the quantity.

For a given alloy/mercury ratio increased trituration time and speed shortens the working and setting time.



Fig. 17. Amalgamator

Test for trituration (Fig. 18).

Normal trituration:

- Good shiny mix;
- Homogeneous mass, adheres together.

Over trituration:

- Mix is «warm»;
- Difficult to remove from capsule;
- Shiny wet and soft.

Under trituration:

- Dry mix;
- Crumbled mix that is very weak.

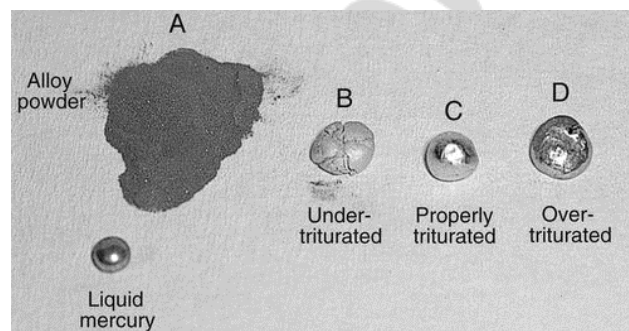


Fig. 18. Test for amalgam trituration

3. Condensation. The goal of condensation is to compact the alloy into the prepared cavity so amalgam sufficient mercury present to ensure complete continuity of the matrix phase between the remaining alloy particles. After the mix is made condensation of the amalgam should be promptly initiated, condensation of partially set material probably fractures and breaks up the matrix that has already formed. Amalgam is placed into the cavity with a special carrier (fig. 19).



Fig. 19. Amalgam carrier

Amalgam is placed in hollow tubes and then transferred to the cavity preparation. Amalgam sticks in the carrier if it is not released immediately after the tubes are filled. Amalgam carrier is used exclusively on amalgam tray setups. Amalgam carrier must be cleaned, bagged individually or bagged/wrapped in a tray setup, and then sterilized. A chemical/steam indicator device should be included in the wrapping.

Condensation should be as rapid as possible and a fresh mix of amalgam should be made if condensation takes longer than 3–4 minutes. The field of operation should be dry before application.

Tips of hand condensation:

- Once the increment of amalgam is inserted into the cavity preparation, it should be condensed with pressure to avoid voids and to adapt the material to the walls, the condenser point is forced into the amalgam mass under hand pressure.
- Condensation is started at the center and then condenser point is stepped little by little towards the cavity wall.
- After condensation of each increment, excess mercury should be left over the first increment so that it can bond with the next increment.
- The procedure of adding an increment, condensing it, adding another increment and so forth is continued until the cavity is overfilled.
- In case the cavity is large, well condensed amalgam restoration can be achieved when the mix has proper consistency
- When a given force is applied, the smaller the condenser the greater the pressure exerted on the amalgam.
- Serrated condenser is preferred than round condenser in case of the corner of the cavity.
- The shape of condenser points should conform to the area under condensation (fig. 20).
- Sufficient condensation force should be used to force the alloy particles together and to reduce voids, and let mercury to work to the surface to achieve bonding between the increments.
- To pack and condense amalgam into interproximal areas of cavity preparation, interproximal condenser is used (fig. 21).

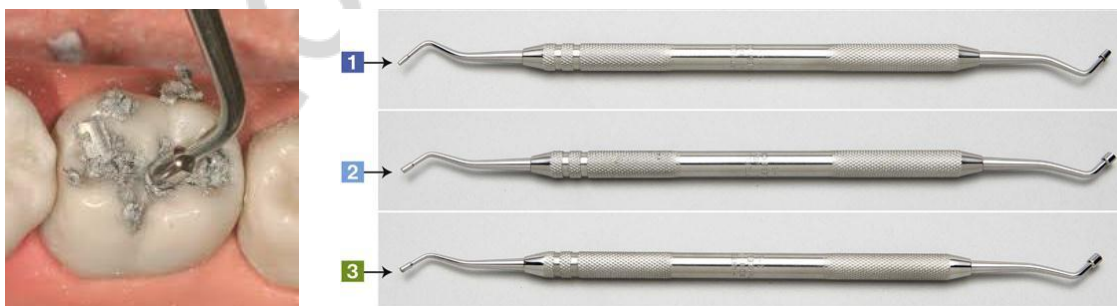

Fig. 20. Condensation of dental amalgam and Condenser (Plugger) – smooth and serrated

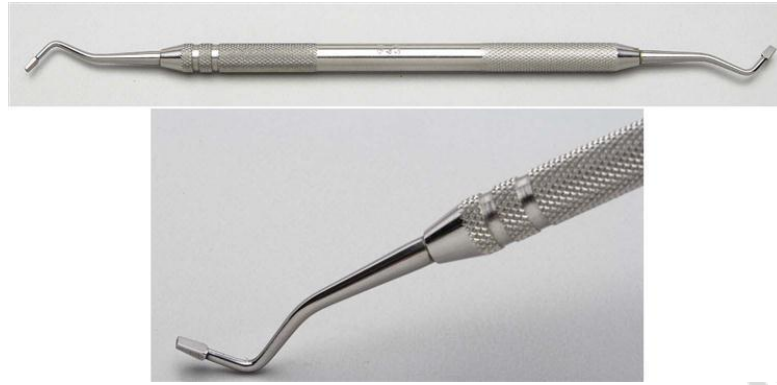

Fig. 21. Interproximal condenser

Mechanical condensation. It differs from hand condensation in such that it is performed by an automatic device. Various mechanics are employed for such instruments; some provide impact type of force, and some use rapid vibration.

Less energy is required than in case of hand condensation, and the dentist feels less fatigue.

4. Carving. After amalgam is condensed in the cavity, it is carved to reproduce the proper tooth anatomy. It should be started when the amalgam is hard enough to offer resistance to the carving.

Carving is performed by using various varieties of amalgam carvers available (like Hollenbeck's carver) (fig. 22). Carving is always directed from the tooth surface to the restoration surface. This is done to avoid removal of amalgam at the margins (fig. 23).

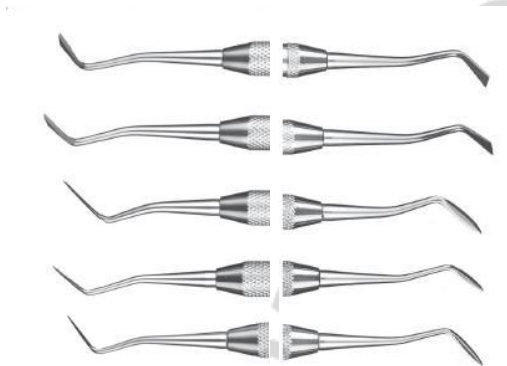

Fig. 22. Hollenbeck's carvers

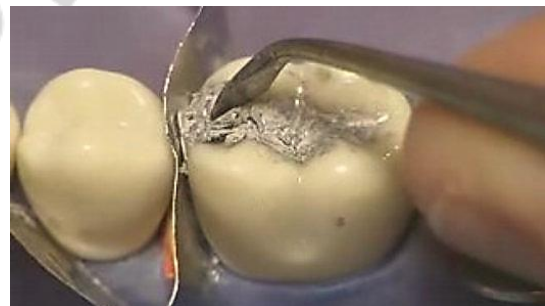

Fig. 23. Amalgam carving

Carving is done to produce a restoration with:

- Proper physiological contours.
- Minimal flash (no overhangs).
- Functional, non-interfering occlusal anatomy.
- Adequate, compatible marginal ridges.
- Proper size, location, extent and inter-relationship of contact areas.
- Physiologically compatible embrasures.
- No interference with integrity of periodontium.

5. Burnishing and finishing. It is done after carving with a suitable size of burnisher to improve smoothness with shiny appearance. It helps in reducing the surface roughness. Burnishing of the occlusal anatomy can be accomplished with the help of the ball burnisher (fig. 24). According to the purpose, burnishers with different forms of the working part can be used (fig. 25).

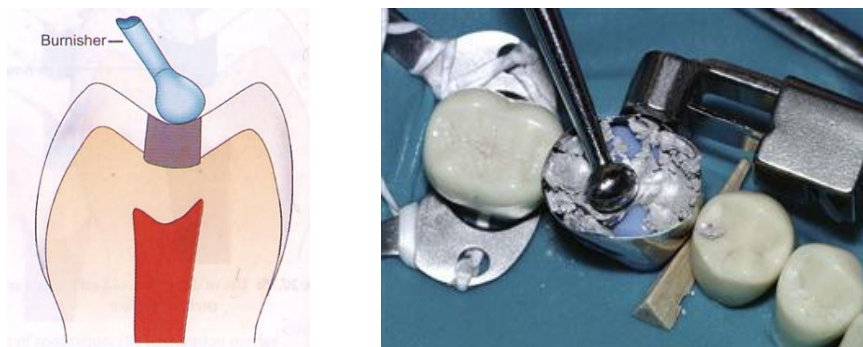


Fig. 24. Burnishing improves marginal adaptation of amalgam and removes excess mercury from amalgam



Fig. 25. 1 — Football Burnisher; 2 — Ball Burnisher; 3 — Acorn Burnisher

Final smoothing can be done with the help of moist cotton or with the help of polishing rubbers and prophylaxis paste (fig. 26). While polishing, temp should not exceed 60 degrees.

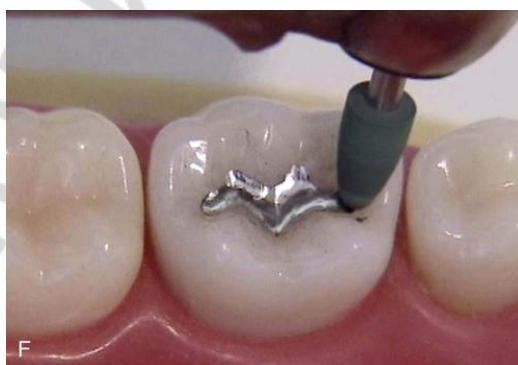

Fig. 26. Polishing of the amalgam restoration

Finishing amalgam restorations involves removal of marginal irregularities, defining anatomical contours, and smoothening the surface roughness of the restoration. Polishing is done to achieve a smooth, shiny luster on the surface of

the amalgam. Finishing is done before polishing by using abrasive agents that are coarse enough to remove the bulk from the surface. Polishing requires mildly abrasive materials for producing smooth and shiny surface of amalgam restoration.

Finishing and polishing of the restorations should be done at least 24 hours after the placement of the amalgam. Premature finishing and polishing will interfere with the crystalline structure of the hardening amalgam. The result will be a weakened restoration. Polishing may not be essential for restorations with high-copper alloys because they have a tendency of self-polishing.

The clinician should check the margins and proximal contacts of the restoration initially using a metal filling strip to remove any roughness or overhand of the restoration in the proximal area.

Advantages of finishing and polishing:

- improves marginal adaptation of restoration by removing flash;
- reduces tarnish and corrosion;
- polished surface is plaque resistant;
- polished surface is smoother and easier to clean;
- prevention of recurrent decay;
- prevention of amalgam deterioration;
- maintenance of periodontal health;
- prevention of occlusal problems.

One of the most important precautions to be taken while doing finishing and polishing is the minimization of heat production. Heat generated during the polishing procedure is potentially dangerous because:

- it can cause thermal damage to the pulp;
- heat brings the mercury to the surface of the restoration resulting in a dull, cloudy surface, and makes it more susceptible to corrosion.

To Minimize Heat Production:

- use light, intermittent pressure with rotary instruments;
- use slow speed with rotary instruments;
- use abrasive agents that are wet rather than dry.

Steps for Finishing and Polishing of Amalgam:

1. Using an explorer, evaluate the cavosurface margins for marginal integrity.
2. Determine the presence of any marginal discrepancies and evaluate the contour of the restoration.
3. Identify the occlusal pattern. Mark the occlusal contacts in centric occlusion and excursive movements. Areas that need to be reduced are identified by darker markings on the restoration. Establish proper occlusion by grinding.
4. Smoothen the margins by using a round bur moving it along all cavosurface margins. This procedure is done to blend the tooth structure to amalgam.
5. Use a large round finishing bur to eliminate scratches and graininess from the amalgam.

6. Using the side of the finishing bur, smoothen the occlusal surface and marginal ridges. Move the bur mesiodistally, overlapping each stroke, then do the same in a buccolingual direction.
7. Use a finishing strip for smoothening and polishing of the gingival cavosurface margins and interproximal space.
8. Smoothen the facial and lingual surfaces with finishing disks.
9. Finally polish the surface by using progressively finer abrasive agents.
10. Rinse and clean out all debris completely.
11. Evaluate all margins and surfaces of the restoration (fig. 27).

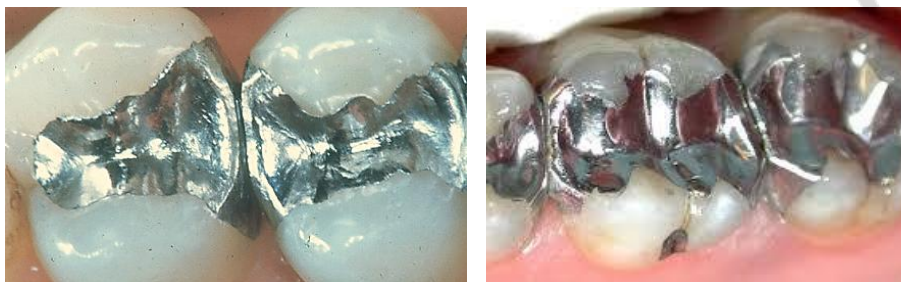

Fig. 27. Completed amalgam restoration

FLUORIDATED AMALGAM

Fluoride, being cariostatic, has been included in amalgam to deal with the problem of recurrent caries associated with amalgam restorations. The problem with this method is that the fluoride is not delivered long enough to provide maximum benefit.

A fluoride containing amalgam may release fluoride for several weeks after insertion of the material in the mouth. An anticariogenic action of fluoride amalgam could be explained by its ability to deposit fluoride in the hard tissues around the fillings and to increase the fluoride content of plaque and saliva, subsequently affecting remineralization. In this way, fluoride from amalgam could have a favorable effect not only on caries around the filling, but on any initial enamel demineralization. The fluoride amalgam thus serves as a «slow release device».

AMALGAM BONDING SYSTEM

Although amalgam has been a highly successful restorative material when used as an intracoronal restoration, it does not restore the strength of the clinical crown to its original strength. Additional features, such as pins, slots, holes and grooves to increase retention of the restoration, must be supplied with the preparations for large amalgam restorations, but they do not reinforce the amalgam or increase its strength.

With the development of adhesive systems for dental composites came the opportunity to attempt to bond amalgams to tooth structure. Adhesive plastics containing 4-META, an acronym for *4-methacryloxyethyl trimellitic anhydride* have been the most successful products. Shear bond strengths of amalgam to dentin as high as 10 MPa have been reported using these adhesives. Comparable values for the shear bond strength of microfilled composites to dentin using these same adhesives have been 20 to 22 MPa. The fracture resistance of teeth restored with amalgam-bonded MOD restorations was more than twice that of restorations containing unbonded amalgams. Also, in spite of the lower shear strength of amalgam-bonded-to-dentin test samples compared with composites, the fracture strength of MODS in teeth restored with bonded amalgams was as high as for composites, although neither were as high (45 % to 80 %) as values for the intact tooth. As expected, amalgam bonded MODS with narrow preparations had higher strengths than those with wide preparations. Other studies showed the retention of amalgam-bonded MODS with proximal boxes was as great as pin-retained amalgams. In addition, amalgam-bonded restorations decreased marginal leakage in Class 5 restorations compared with unbonded amalgams. Finally, the plastic bonding agents for amalgam have not been successful in increasing the amalgam-to-amalgam bond strength in the repair of amalgam restorations. Thus at this stage of development, adhesive bonding of amalgam restorations to tooth structures is improvement over non-bonded amalgams.

Potential advantages:

1. Improved retention.
2. Decreased microleakage.
3. Improved resistance form.
4. Decreased post-operative sensitivity.

Disadvantages:

1. It has not been in use long enough to allow a proper evaluation of its clinical performance.
2. It increases the cost of amalgam restoration.
3. It increases the time to perform a conventional amalgam and may be technique sensitive.

Bonding systems used:

- ALLBOND-2(Bisco);
- Amalgam bond plus (Parkell);
- Panavia (Kuraray);
- Scotch bond multi-purpose plus (3M-ESPE).

FAILURES IN AMALGAM RESTORATIONS

Studies have shown that the life of a properly manipulated and restored silver amalgam restoration is about 10 to 12 years. With time, the restoration may show some changes like tarnish, corrosion, recurrent marginal caries, discoloration of teeth, fracture of restoration or tooth and ultimately loss of restoration.

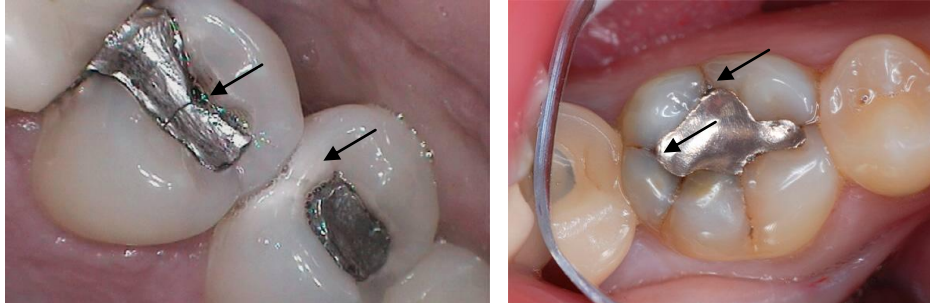


Fig. 28. Signs of failures in amalgam restorations

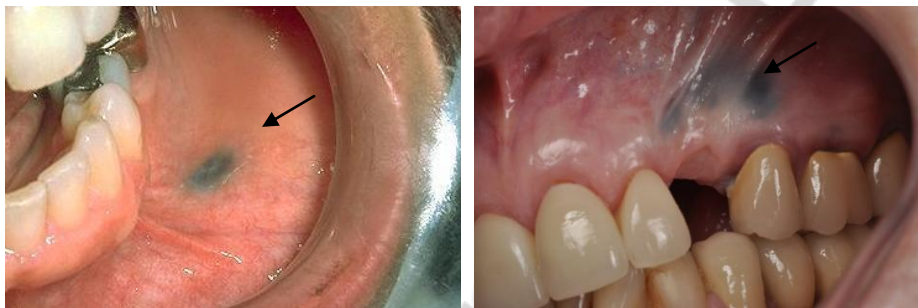

Fig. 29. Amalgam tattoo — is accidental implantation of silver containing compounds into oral mucosal tissue

Causes and sings of amalgam restorations failures are described in tabl. 4.

Table 4

Causes and sings of amalgam restorations failures

Reasons For Failures	Most common failures associated with dental amalgam restoration
1. Improper case selection 2. Improper cavity preparation <i>Inadequate occlusal extension</i> <i>Under extension of the proximal box</i> <i>Overextended tooth preparation</i> <i>Inadequate depth of preparation</i> 3. Faulty selection & manipulation of amalgam <i>Inappropriate condensation</i> <i>Incorrect mercury alloy ratio</i> <i>Contamination during manipulation</i> <i>Faulty finishing and polishing</i> 4. Defective matrix adaptation 5. Postoperative factors <i>Faulty finishing and polishing</i> <i>Premature fracture of restoration</i>	At microscopic level: <i>Pain after amalgam restoration</i> <i>Periodontal tissue injury due to proximal overhangs</i> <i>Pulpal involvement</i> <i>Tarnish and corrosion</i> <i>Internal stresses due to excessive masticatory forces</i> At macroscopic level: <i>Bulk fracture of restoration</i> <i>Tooth fracture</i> <i>Marginal fracture of amalgam</i> <i>Secondary or recurrent caries commonly takes place due to marginal leakage.</i> <i>Dimensional changes especially in zinc containing amalgam</i> <i>Discoloration of restoration</i> <i>Discoloration of tooth</i>

MERCURY HYGIENE

Mercury has been used in dentistry for a very long time. It is considered as the major component in amalgam restorations and is also used in medicines such as skin, antibacterial ointments and laxatives.

Mercury has been considered to be hazardous if not managed properly. Mercury vapors present in the dental office are toxic if they cross the threshold limit. So, management of free mercury is very important.

Mercury is present in the environment which is taken into the body through water, air and food, daily in one or another form.

Mercury usually enters the body everyday no matter what type of restorative filling is present in the oral cavity. A very low amount of mercury is usually released from the set amalgam as compared to daily intake.

It has been found that patients may have less health hazards from amalgam use than dental professionals because of a long-term contact with mercury in the dental office.

DENTAL MERCURY HYGIENE RECOMMENDATIONS:

1. *Ventilation:* Provide proper ventilation in the work place by having fresh air exchange and periodic replacement of filters, which may act as traps for mercury.

2. *Monitor office:* Monitor the mercury vapor level in the office periodically. This may be done by using dosimeter badges (Limit-50 μ g/m³ in 8hr shift over 40hr work week).

3. *Monitor personnel:* Monitor the office personnel periodically.

4. *Office design:* Use proper work area design to facilitate spill containment and cleanup.

5. *Pre-capsulated alloys:* Use pre-capsulated alloys to eliminate the possibility of a bulk mercury spill. Otherwise, store bulk mercury properly in unbreakable containers on stable surfaces.

6. *Amalgamator cover:* Use an amalgamator fitted with a cover.

7. *Handling care:* Use care in handling amalgam. Avoid skin contact with mercury or freshly mixed amalgam. Avoid dry polishing.

8. *Evacuation systems:* Use high volume evacuation when finishing or removing amalgam. Evacuation systems have traps or filters. Check, clean or replace traps and filters periodically.

9. *Masks:* Change the mask as necessary when removing amalgam restorations.

10. *Recycling:* Store amalgam scraps under radiographic fixer solution in a covered container. Recycle amalgam scraps through refiners.

11. *Contaminated items:* Dispose mercury contaminated items in sealed bags according to applicable regulations.

12. *Spills*: Clean up spilled mercury properly by using bottles, tapes or fresh mixes of amalgam to pick-up droplets or use commercial clean up kits. Do not use household vacuum cleaner.

13. *Clothing*: Wear professional clothing only in dental office.

14. *Select an appropriate alloy*: Proper mercury/alloy ratio to avoid the need to remove excess mercury before packing.

IS DENTAL AMALGAM SAFE?

Dental amalgams are still widely used by dental professionals in most parts of the world

Some countries, like Sweden, Canada and Germany, UK have either banned or imposed serious limitations on amalgam usage

In the 1990s, several governments evaluated the effects of dental amalgam and concluded that the most likely health effects would be due to hypersensitivity or allergy

In 2004, the Life Sciences Research Office analyzed studies related to dental amalgam. They took mean urinary mercury concentration (pg of Hg/L in urine, HgU) as the most reliable estimate of mercury exposure. 95 percent of study participants showed pg HgU below 4 to 5

Chewing gum, particularly for nicotine, along with more amalgam, seemed to pose the greatest risk of increasing exposure. However, the World Health Organization state mercury levels in biomarkers such as urine, blood, or hair do not correspond to its levels in critical organs and tissues

The American Dental Association Council on Scientific Affairs has concluded that both amalgam and composite materials are considered safe and effective for tooth restoration.

REFERENCES

1. *Operative dentistry* / H. W. Gilmore [et al.]. – 3d ed. – Saint Louis : Mosby, 1977. Vol. 380. P. 154–156.
2. *Robert, G. Powers. Restorative dental materials* / G. Robert, J. M. Craig. – 11th ed. / St. Louis [etc.] : Mosby, 2002. Vol. 704. P. 287–327.
3. *Van Noort, R. Introduction to Dental materials* / R. van Noort. – 2nd ed. – Mosby, 2002. Vol. 312. P. 81–96.
4. *Posterior Amalgam Restorations Usage, Regulation, and Longevity* / J. Richard [et al.] // Dent. Clin. N. Am. 2007. Vol. 51. P. 573–589.
5. *Applied dental materials* / eds. : J. F. McCabe, A. W. G. Walls. – 9th ed. – Wiley-Blackwell, 2008. Vol. 303. P. 181–194.
6. *Garg, N. Textbook of operative dentistry* / Garg N., Garg A. – 2nd ed. – New Delhi [etc.] : Jaypee Brothers Medical Publishers (P) LTD, 2013. 605 p.

CONTENTS

Introduction	4
Advantages of dental amalgam.....	4
Disadvantages of dental amalgam	4
Indications for dental amalgam using.....	5
Dental amalgam is not used when:	5
Classification of dental amalgam.....	5
Low-copper amalgam	6
High-copper dental amalgams	7
Properties of dental amalgam.....	8
Manipulation with dental amalgam	10
Amalgam application	15
Fluoridated amalgam	22
Amalgam bonding system.....	22
Failures in amalgam restorations	24
Mercury hygiene	25
Dental mercury hygiene recommendations:	25
Is dental amalgam safe?	26
References	26

Учебное издание

Колб Екатерина Леонидовна
Гулько Татьяна Ивановна
Кармалькова Ирина Сергеевна

АМАЛЬГАМА В ТЕРАПЕВТИЧЕСКОЙ СТОМАТОЛОГИИ

AMALGAM IN CLINICAL DENTISTRY

Учебно-методическое пособие

На английском языке

Ответственная за выпуск Л. А. Казеко
Переводчик Е. Л. Колб
Компьютерная верстка А. В. Янушкевич

Подписано в печать 15.06.16. Формат 60×84/16. Бумага писчая «Снегурочка».

Ризография. Гарнитура «Times».

Усл. печ. л. 1,63. Уч.-изд. л. 1,29. Тираж 40 экз. Заказ 634.

Издатель и полиграфическое исполнение: учреждение образования
«Белорусский государственный медицинский университет».

Свидетельство о государственной регистрации издателя, изготовителя,
распространителя печатных изданий № 1/187 от 18.02.2014.

Ул. Ленинградская, 6, 220006, Минск.