

МИНИСТЕРСТВО ЗДРАВООХРАНЕНИЯ РЕСПУБЛИКИ БЕЛАРУСЬ  
БЕЛОРУССКИЙ ГОСУДАРСТВЕННЫЙ МЕДИЦИНСКИЙ УНИВЕРСИТЕТ  
1-я КАФЕДРА ТЕРАПЕВТИЧЕСКОЙ СТОМАТОЛОГИИ

Л. А. КАЗЕКО, Е. Л. КОЛЬ, И. С. КАРМАЛЬКОВА

**ЗАБОЛЕВАНИЯ ТВЕРДЫХ ТКАНЕЙ  
ЗУБОВ, ВОЗНИКАЮЩИЕ  
ПОСЛЕ ПРОРЕЗЫВАНИЯ**

**DISEASES OF HARD  
TISSUES OF TEETH ARISING AFTER  
ERUPTION**

Рекомендовано Учебно-методическим объединением по высшему медицинскому, фармацевтическому образованию в качестве учебно-методического пособия для студентов учреждений высшего образования, обучающихся на английском языке по специальности 1-79 01 07 «Стоматология»

*2-е издание*



Минск БГМУ 2016

УДК 616.314.1-02(811.111)-054.6(075.8)

ББК 56.6(81.2Англ-923)

К14

Рецензенты: канд. мед. наук, доц., гл. внештат. специалист Министерства здравоохранения Республики Беларусь по стоматологии, гл. врач Республиканской клинической стоматологической поликлиники А. М. Матвеев; каф. терапевтической стоматологии Белорусской медицинской академии последипломного образования

**Казеко, Л. А.**

К14 Заболевания твердых тканей зубов, возникающие после прорезывания = Diseases of hard tissues of teeth arising after eruption : учебно-методическое пособие / Л. А. Казеко, Е. Л. Колб, И. С. Кармалькова. – 2-е изд. – Минск : БГМУ, 2017. – 34 с.

ISBN 978-985-567-843-5.

Изложены современные взгляды на этиологию, патогенез, диагностику некариозных заболеваний зуба, возникающих после прорезывания, описаны основные клинические формы патологии, подходы в лечении и профилактике. Первое издание вышло в 2016 году.

Предназначено для студентов 3-го курса медицинского факультета иностранных учащихся, обучающихся на английском языке.

УДК 616.314.1-02(811.111)-054.6(075.8)

ББК 56.6(81.2Англ-923)

ISBN 978-985-567-843-5

© Казеко Л. А., Колб Е. Л., Кармалькова И. С., 2017

© УО «Белорусский государственный

медицинский университет», 2017

## INTRODUCTION

There are many acquired noncarious diseases of hard tissues of the teeth with which all dentists should be familiar. They result in alterations to the tooth hard tissues and manifest as teeth wear. The International Classification of Diseases (ICD-10, WHO, 2014) defines these diseases as «Other diseases of dental hard tissues».

### ICD-10 CLASSIFICATION (WHO, 2014)

#### **K03. Other diseases of hard tissues of teeth**

*Excl.:* bruxism (F45.8)  
dental caries (K02.-)  
teeth-grinding NOS (F45.8)

#### **K03.0 Excessive attrition of teeth**

Wear: approximal | of teeth  
occlusal

#### **K03.1 Abrasion of teeth**

dentifrice  
habitual  
Abrasion: occupational | of teeth  
ritual  
traditional  
wedge defect NOS

#### **K03.2 Erosion of teeth**

NOS  
due to:  
Erosion of diet  
teeth: drugs and medicaments  
persistent vomiting  
idiopathic  
occupational

#### **K03.3 Pathological resorption of teeth**

Internal granuloma of pulp  
Resorption of teeth (external)

#### **K03.4 Hypercementosis**

Cementation hyperplasia

#### **K03.5 Ankylosis of teeth**

## DEFINITIONS OF CAUSES OF TOOTH SURFACE LESIONS

The causes of tooth surface lesions henceforth proposed are classified as *attrition*, *abrasion*, *erosion (corrosion)* and *abfraction*. Since the dawn of modern dentistry, the etiology of noncarious lesions has been ascribed by some dentists to toothbrush/dentifrice abrasion alone. Others have asserted that these lesions are mainly caused by acids and termed «erosion», more appropriately termed «biocorrosion», which embraces all forms of chemical, biochemical, and electrochemical degradation. Following the introduction of the term abfraction by Grippo in 1991 and amended in 2004, to represent the microfracture of tooth substance in areas of stress concentration, the term remains misconstrued and misused. The published studies have demonstrated the effects of stress combined with acids and enzymatic proteases as being factors in the genesis of teeth noncarious lesions. Piezoelectric effects on dentin have also been reported. Studies also suggest that stress may be a cofactor in the etiology of caries, especially of cervical or root caries. Unfortunately, the term abfraction has become a «buzzword», implying a single etiology, and is frequently used erroneously to designate all noncarious lesions of the teeth. Because of the complex interaction of these various mechanisms — erosion (corrosion) (causing chemical degradation), stress (manifested by abfraction), and friction (from toothbrush/dentifrice abrasion) — it is generally incorrect to designate all noncarious lesions of the teeth as being caused by only one mechanism (fig. 1). The clinician should consider all etiologic and modifying factors before completing the diagnosis or initiating treatment if indicated.

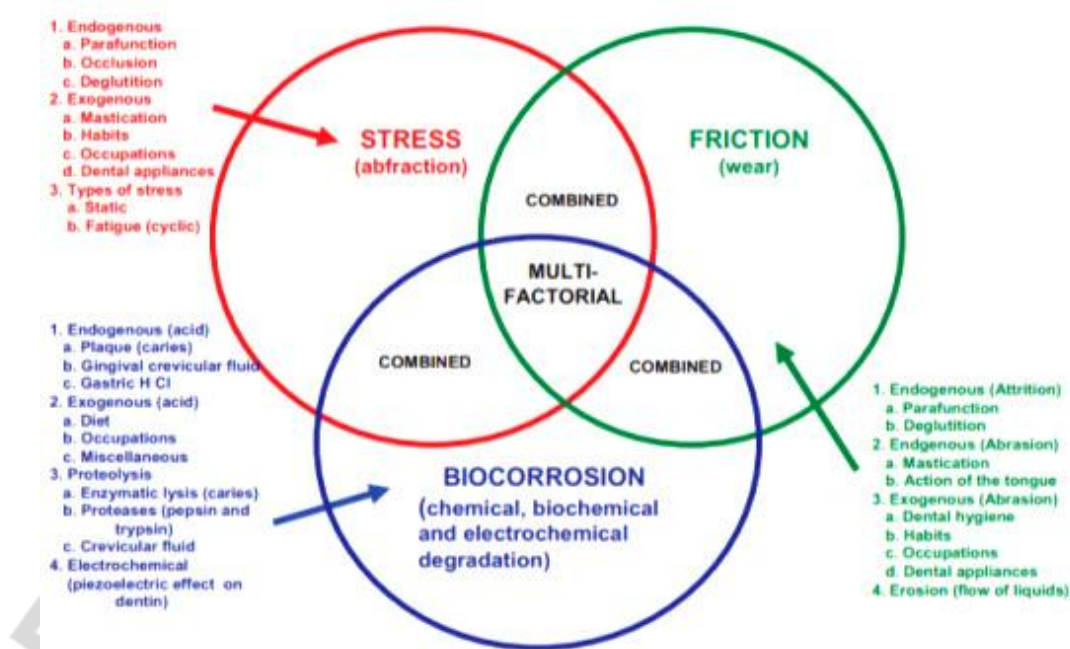


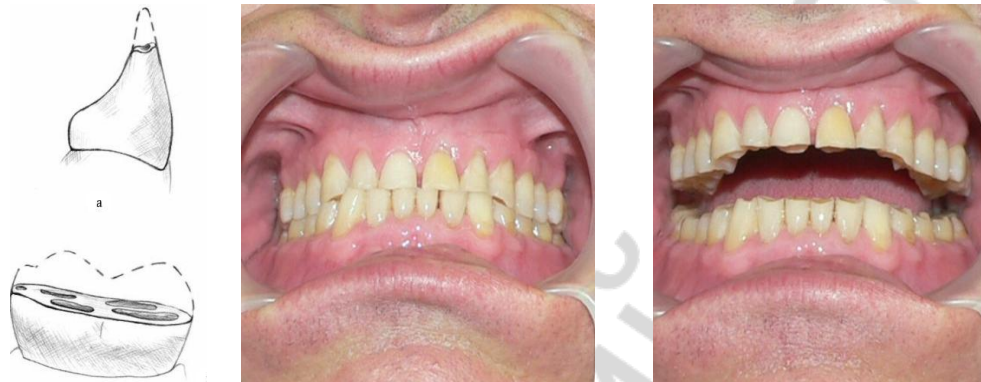Fig. 1 Revised schema of pathodynamic mechanisms. This schema indicates the initiating and perpetuating etiologic factors that produce tooth surface lesions

## ATTRITION

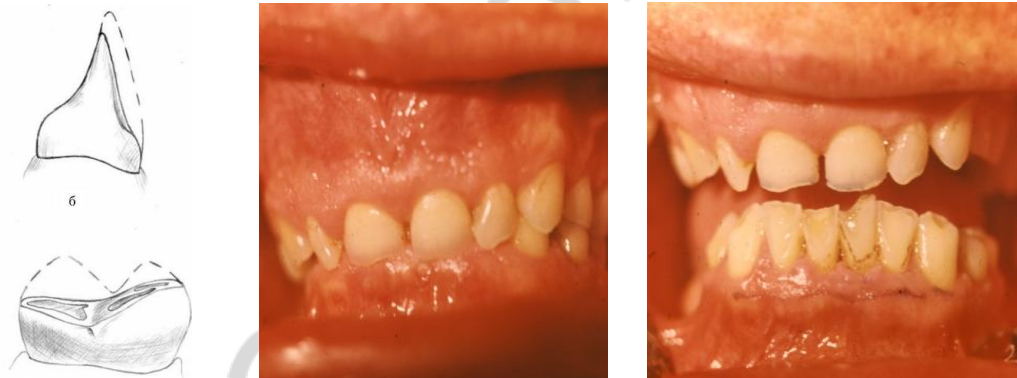Tooth-to-tooth friction causes the form of wear called «attrition». In other words attrition is a loss of tooth surface due to normal wear (with no foreign substance intervening). Some wearing is normal (physiologic) but accelerated wear beyond normal is pathologic.

There are few forms of excessive teeth attrition dentists can see in patients:

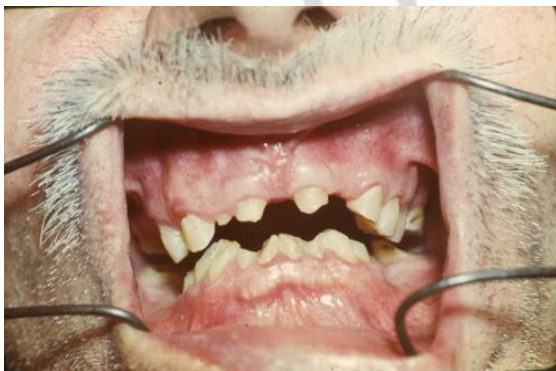1. Horizontal form (occlusal or incisal) — more often (fig. 2);
2. Vertical form (fig. 3);
3. Mixed form (fig. 4);
4. Proximal attrition (occurs at contact areas) (fig. 5).



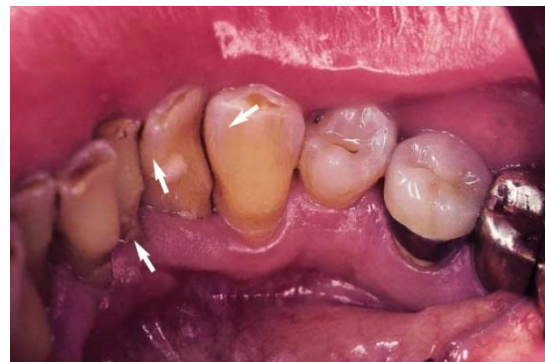*Fig. 2. Horizontal form of excessive attrition*



*Fig. 3. Vertical form of excessive attrition*



*Fig. 4. Mixed form of excessive attrition*



*Fig. 5. Proximal attrition*



Occlusal and incisal attrition can occur during deglutition and clenching; however, wear becomes most severe during bruxism, as evidenced by the advanced and often rapid wear of the teeth seen in that condition.

Proximal attrition (which occurs at contact areas) can cause a reduction of the dental arch.

### ABRASION

Friction between a tooth and an exogenous agent causes wear called «abrasion». So it is tooth wear beyond normal caused by mechanical forces. If teeth are worn on their occlusal surfaces, incisal surfaces or both by friction from the food bolus, this wear is termed «masticatory abrasion». The differential wear rate between dentin and enamel occurring in areas of exposed dentin may be a cofactor in the formation of some Class VI lesions. Masticatory abrasion also can occur on the facial and lingual aspects of teeth as coarse food is forced against these surfaces by the tongue, lips and cheeks during mastication.

Abrasion can occur as a result of overzealous toothbrushing (dentifrice abrasion or wedge-shape defect) (fig. 6), improper use of dental floss and toothpicks (fig. 7), or detrimental oral habits such as chewing tobacco, biting on hard objects such as pens, pencils or pipe stems, opening hair pins with teeth, and biting fingernails. Abrasion also can be produced by the clasps of partial dentures. Occupational abrasion may occur among tailors or seamstresses who sever thread with their teeth, shoemakers and upholsterers who hold nails between their teeth, glassblowers, and musicians who play wind instruments.

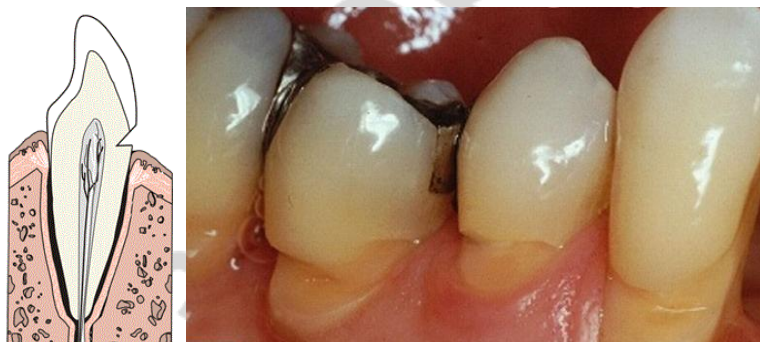

Fig. 6. Dentifrice abrasion or wedge-shape defect

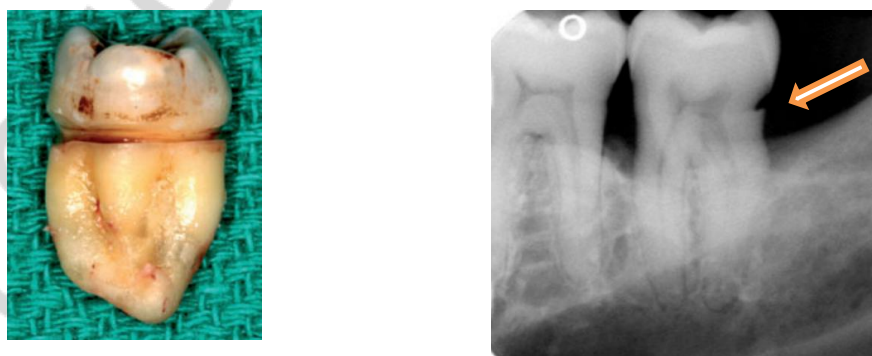


Fig. 7. Abrasion due to improper use of dental floss (habitual abrasion)

## EROSION OR CORROSION

Tooth surface loss caused by chemical or electrochemical action is termed «erosion». Erosion is the destruction of enamel and dentin by chemical substances without the presence of microorganisms. Erosions, mostly located to the vestibular surfaces of teeth, are commonly associated with the action of acids on the tooth surface. There are both endogenous and exogenous sources of erosion (tabl. 1).

Table 1

<b>Causes of exogenous and endogenous erosion</b>
<b>The more common causes of exogenous erosion;</b>
<b>Dietary</b> citrus fruits, fruit juices, carbonated beverages, vinegar and pickles
<b>Medicines</b> ascorbic acid, HCl replacement therapy, frequent acetylsalicylic acid use, some iron tonics, some cough suppressant syrups, some antiseptic mouthrinses.
<b>Occupational</b> wine assessment, acid vapours (battery workshops)
<b>Recreational</b> improperly chlorinated large swimming pools, heated spas (Zero DT, 1996).
<b>The more common causes of endogenous erosion are vomiting, regurgitation or reflux due to;</b>
<b>Anatomical defects</b> eg. hiatus hernia, deficient gastro-aesophageal spinctre, aesophageal diverticulosis
<b>Psychological problems</b> eg. anorexia nervosa/ bulimia, severe alcoholism, severe stress
<b>Medication</b> for some severe health problems chemotherapy, severe asthma, or other drugs severely irritating the gastric mucosa
<b>Side effect of some cytostatic drugs</b>
<b>Associated with peptic ulcer or uremia</b>
<b>Prolonged nausea during pregnancy</b>

Endogenous sources of erosion. Bulimia produces a unique pattern of enamel loss. The erosion called «perimolysis», is most marked on the palatal surfaces of maxillary anterior teeth and, in more severe cases, on the buccal surfaces of posterior teeth (fig. 8). This pattern is consistent with the head's position while vomiting. The forcefully directed movement of the vomitus, which has a mean pH of 3.8, determines the site and extent of dental erosion. As first reported by Howden, a special pattern of surface loss also is observed in patients with gastroesophageal reflux disease, or GERD. However, the movement of acidic gastric juice in GERD as compared with that in bulimia is slower, less forced, more prolonged, more pervasive and more likely to intermingle the acid with food, especially when the condition is «silent» and unknown to the patient. The enamel appears thin, and translucent; enamel is lost on the posterior occlusal and anterior palatal surfaces; depressions or concavities occur at the cervical areas of upper anterior teeth. «Cupped» or invaginated areas develop where dentin has been ex-

posed on the occlusal surfaces of posterior teeth because of wear. This dentinal cupping results from the joint digestive action of hydrochloric acid and the proteolytic enzyme pepsin that is contained in gastric juice. Atypical sites of corrosion may occur at locations where the gastric reflux fluid pools, especially while the patient is asleep. When the dentist finds evidence of gastric reflux, referral to a gastroenterologist for evaluation and control is indicated.

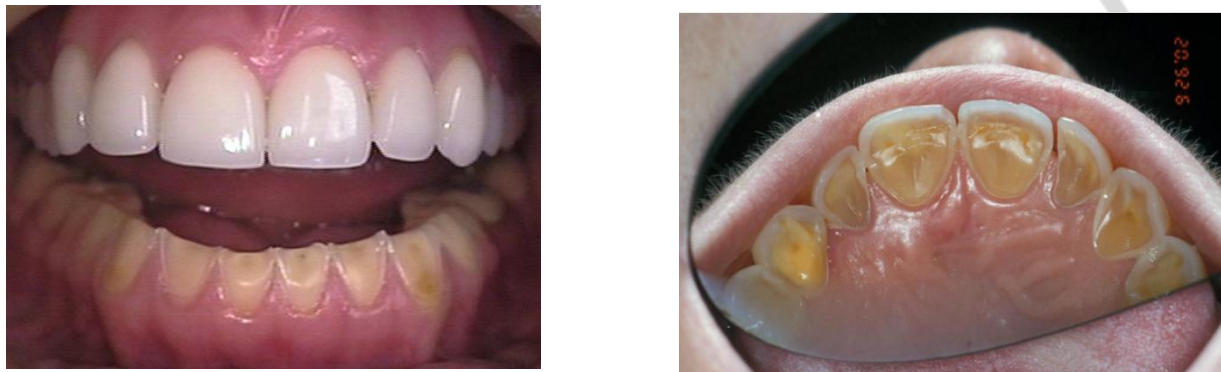

Fig. 8. Bulimic erosion

Gingival crevicular fluid has been shown to be acidic and may be corrosive when in contact with teeth in the cervical region.

*Exogenous sources of erosion.* It has been reported that any food substance with a critical pH value of less than 5.5 can become a corrodent and demineralize teeth. This may occur as a result of consuming and/or mulling highly acidic foods and beverages such as mangoes and other citrus fruits, drinking carbonated soft drinks and sucking sour candies. Acidic mouthwashes also may be implicated. Acidulated carbonated soft drinks have become a major component of many diets, particularly among adolescents and young children.

Acid vapours of hydrochloric, picric, formic, sulphuric and other acids, which are responsible for industrial erosion, may also be involved in dental erosion and then the incisal half of vestibular surfaces of incisors is affected most frequently; the other teeth are eroded less frequently.

Sometimes, when talking about idiopathic erosion, it is impossible to establish the cause of erosion (fig. 9).

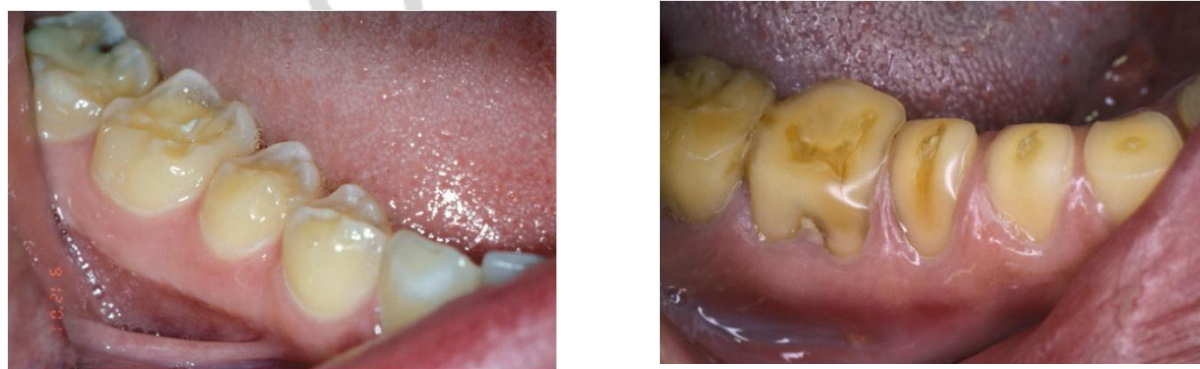
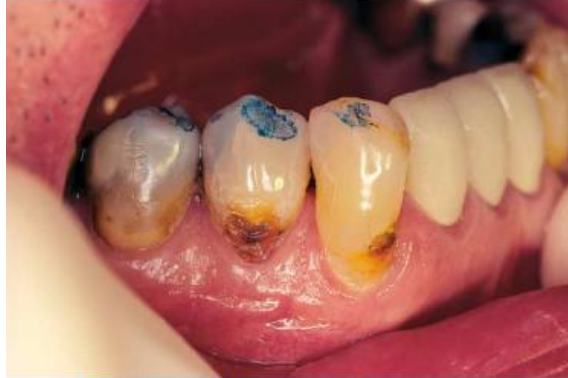
Fig. 9. Erosion of unknown cause (idiopathic erosion)



## ABFRACTION

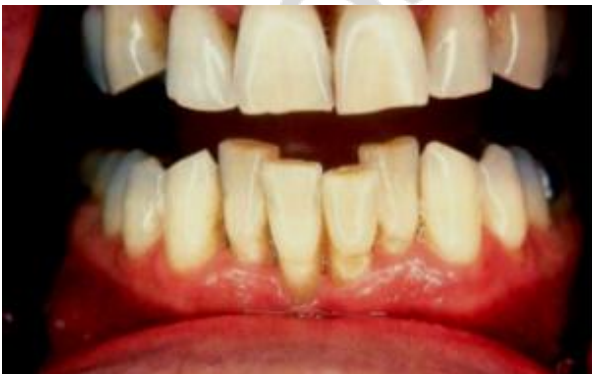Abfraction is the microstructural loss of tooth substance in areas of stress concentration. This occurs most commonly in the cervical region of teeth, where flexure may lead to a breaking away of the extremely thin layer of enamel rods, as well as microfracture of cementum and dentin. These lesions, which appear to result from occlusal loading forces, frequently have a crescent form along the cervical line, where this brittle and fragile enamel layer exists (fig. 10).



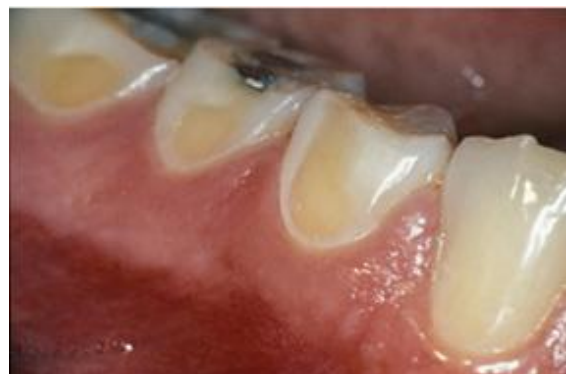*Fig. 10.* Caries and abfraction: articulating paper markings indicate eccentric loading, which induced stress concentration in the cervical region (abfraction) and may have exacerbated the caries

## COMBINED MECHANISMS OF TOOTH WEAR

Although some of the aforementioned individual mechanisms may act independently, combined mechanisms occur frequently during the dynamics of inter-occlusal activity. From a bioengineering perspective, many additive or synergistic combinations of mechanisms may occur simultaneously, sequentially or alternately, thus explaining the loss of dental hard tissue. For example, attrition-abfraction can be seen as the joint action of stress and friction when teeth are in tooth-to-tooth contact, as in bruxism or repetitive clenching (fig. 11). Frequently, more than two mechanisms may be involved in the etiology of tooth surface lesions (fig. 12). For example, a corrosive cervical lesion could be exacerbated by bruxism.



*Fig. 11.* Attrition-abfraction



*Fig. 12.* Erosion or abfractions, or both of them?

## DIFFERENTIAL DIAGNOSIS OF THE PATHOLOGICAL TOOTH WEAR

Summary of the clinical appearance of the forms of tooth wear shown in tabl. 2–3 and figs. 13, 14.

*Table 2*

**Summary of the clinical appearance of the forms of tooth wear**

Process	Clinical Appearance
<b>Abrasion</b>	<ol style="list-style-type: none"> <li>1. Usually located at cervical areas of teeth</li> <li>2. Lesions are more wide than deep</li> <li>3. Premolars and cuspids are more commonly affected</li> </ol>
<b>Attrition</b>	<ol style="list-style-type: none"> <li>1. Matching wear on occluding surfaces</li> <li>2. Shiny facets on amalgam contacts</li> <li>3. Enamel and dentin wear at the same rate</li> <li>4. Possible fracture of cusps or restorations</li> </ol>
<b>Abfraction</b>	<ol style="list-style-type: none"> <li>1. Affects buccal/labial cervical areas of teeth</li> <li>2. Deep, narrow, V-shaped notch</li> <li>3. Commonly affects single teeth with excursive interferences or eccentric occlusal loads</li> </ol>
<b>Erosion</b>	<ol style="list-style-type: none"> <li>1. Broad concavities within smooth surface enamel</li> <li>2. Cupping of occlusal surfaces (incisal grooving) with dentin exposure</li> <li>3. Increased incisal translucency</li> <li>4. Wear on non-occluding surfaces</li> <li>5. «Raised» amalgam restorations</li> <li>6. Clean, non-tarnished appearance of amalgams</li> <li>7. Loss of surface characteristics of enamel in young children</li> <li>8. Preservation of enamel “cuff” in gingival crevice is common</li> <li>9. Dentin hypersensitivity</li> <li>10. Pulp exposure in deciduous teeth</li> </ol>

*Table 3*

**Differential diagnosis of the pathological tooth wear**

Characteristics	Attrition	Abrasion	Erosion	Abfraction	Class V caries
<b>Tooth surface affected</b>	Predominantly matching wear on occluding surfaces	Predominantly cervical area of the vestibular surfaces of the canines and premolars	Predominantly smooth surfaces, rare on approximal surfaces	Affects buccal/labial cervical areas of teeth	Anywhere, but less frequent on self-cleaning surfaces (occlusal 2/3 of labial or palatal surfaces)
<b>Location in the mouth</b>	Usually it affects all teeth	In most cases cervical area of the vestibular surfaces of the canines and premolars	Anterior or posterior teeth, often bilateral in areas with low plaque levels	Commonly affects single teeth with excursive interferences or eccentric occlusal loads	Posterior or anterior teeth, not bilateral, associated with areas of plaque retention

Characteristics	Attrition	Abrasion	Erosion	Abfraction	Class V caries
<b>Appearance</b>	Reduced height of the tooth clinical crown, possible fracture of cusps or restorations	Tooth defect has typical dense walls and V-shape form	Surface is smooth and appears glazed, if oral hygiene is very good; the affected area may be yellowish (dentin showing through) and well polished	Deep, narrow, V-shaped notch	Matte surface (non-cavitated lesions), later may become cavitated
<b>Color of the lesion</b>	Similar to tooth color, it may become yellowish as enamel becomes thinner; if exposed, dentin becomes yellow and never stains, never colored by dyes	Similar to tooth color, it may become yellowish as enamel becomes thinner; if exposed, dentin becomes yellow and never stains, never colored by dyes	Similar to tooth color, it may become yellowish as enamel becomes thinner; if exposed, dentin becomes yellow and never stains, never colored by dyes	Similar to tooth color, it may become yellowish as enamel becomes thinner; if exposed, dentin becomes yellow and never stains, never colored by dyes	Varies from white through yellow to dark depending on the stage of the lesion development and staining, colored by dyes

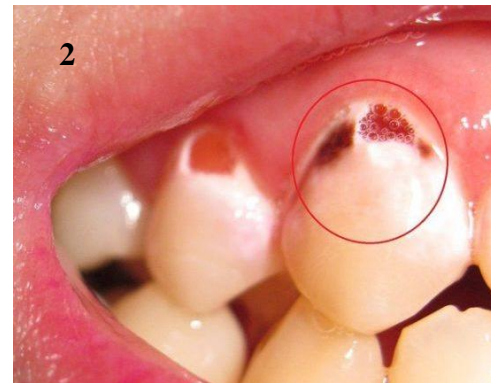
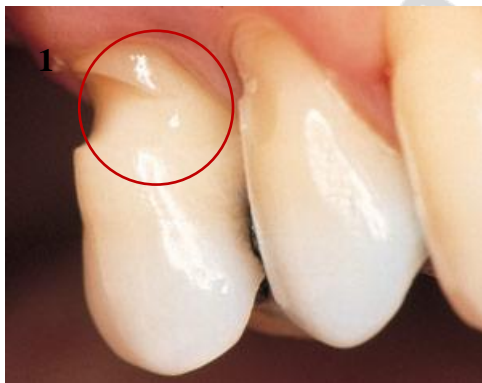

Fig. 13. Difference in clinical appearance between dental abrasion (1) and class V caries (2)

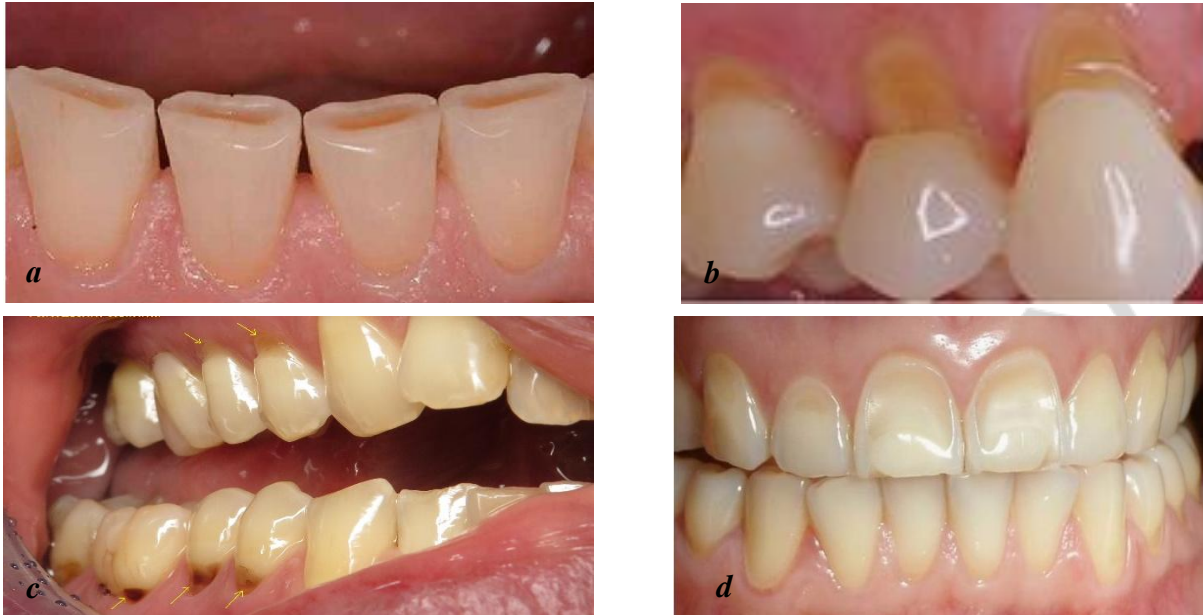

Fig. 14. Difference in clinical appearance between dental attrition (a), abrasion (b), abfraction (c) and erosion (d)

## CLINICAL MEASUREMENT OF TOOTH WEAR

The literature identifies different indices for use in clinical and laboratory situations and specific indices for attrition, abrasion, erosion and multifactorial tooth wear. There are common threads to all of the indices, such as descriptive diagnostic criteria and criteria for quantifying the amount of hard tissue loss. These generally consider the size of the affected area (as a proportion of a sound surface and/or the depth of tissue loss) often expressed as a degree of dentin exposure. To determine the severity of the pathological tooth wear some following clinical classifications and indices of excessive teeth wear can be used (tables 4–6, figs. 15, 16).

Table 4

**Tooth wear index (Smith and Knight, 1984)**

Score	Surface	Criteria
<b>0</b>	B/L/O/I	No loss of enamel surface characteristics
	C	No loss of contour
<b>1</b>	B/L/O/I	Loss of enamel surface characteristics
	C	Minimal loss of contour
<b>2</b>	B/L/O	Loss of enamel exposing dentine for less than one third of surface
	I	Loss of enamel just exposing dentine
	C	Defect less than 1 mm deep
<b>3</b>	B/L/O	Loss of enamel exposing dentine for more than one third of surface
	I	Loss of enamel and substantial loss of dentine
	C	Defect less than 1–2 mm deep
<b>4</b>	B/L/O	Complete enamel loss — pulp exposure — secondary dentin exposure

I	Pulp exposure or exposure of secondary dentine
C	Defect more than 2mm deep — pulp exposure — secondary dentine exposure
<b>B: buccal; L: lingual; O: occlusal; I: incisal; C: cervical</b>	

Table 5

**Index for dental erosion of non-industrial origin (Eccles, 1979)**

Class	Surface	Criteria
<b>Class I</b>		Early stages of erosion, absence of developmental ridges, smooth, surfaces of maxillary incisors and canines
<b>Class II</b>	<b>Facial</b>	Dentine involved for less than one third surface; two types Type 1 (commonest): ovoid-crescentic in outline, concave in cross differentiate from wedge shaped abrasion lesions Type 2: irregular lesion entirely within crown. Punched out
<b>Class IIIa</b>	<b>Facial</b>	More extensive destruction of dentin, affecting anterior teeth part of the surface, but some are localised and hollowed out
<b>Class IIIb</b>	<b>Lingual or palatal</b>	Dentin eroded for more than one third of the surface area. Gingival white, etched appearance. Incisal edges translucent due to loss of is flat or hollowed out, often extending into secondary dentin
<b>Class IIIc</b>	<b>Incisal or occlusal</b>	Surfaces involved into dentin, appearing flattened or with cupping. Undermined enamel; restorations are raised above surrounding
<b>Class IIId</b>	<b>All</b>	Severely affected teeth, where both labial and lingual surfaces may be affected; teeth are shortened

Table 6

**Simplified scoring criteria for tooth wear index (Bardsley et al. 2004)**

Score	Criteria
<b>0</b>	No wear into dentin
<b>1</b>	Dentin just visible (including cupping) or dentin exposed
<b>2</b>	Dentin exposure greater than 1/3 of surface
<b>3</b>	Exposure of pulp or secondary dentin



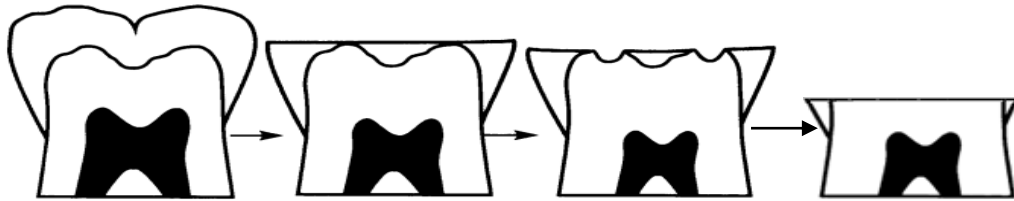


Fig. 15. Simplified scoring criteria for tooth wear index (Bardsley et al. 2004)

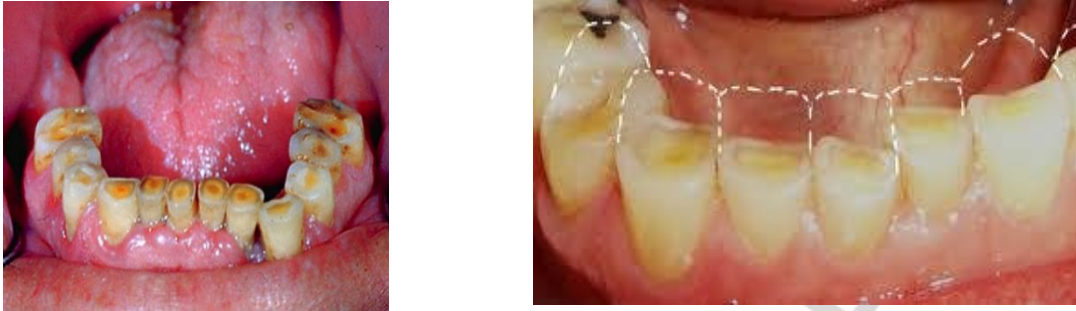

Fig. 16. Stage 3 of excessive teeth wear (attrition)

## OPTIONS FOR EXCESSIVE TOOTH WEAR TREATMENT

Treatment for pathological tooth wear depends on the severity of the damage. If the patient has a large defect that is very unsightly, he'll likely need to have the tooth restored. But if there is little damage, and he is not experiencing any problems with tooth sensitivity, he may not need any treatment.

### Indications for the treatment of worn teeth:

1. Patients' desire to improve their appearance.
2. Intractable sensitivity.
3. Loss of incisal edge.
4. Uncontrolled tooth wear.

**Monitoring.** The most convenient and accurate way to assess the activity of tooth wear is to take study models of the patient's teeth and compare them to the teeth over relatively long periods of time. This process can continue over many years. Tooth wear is phasic in nature, with short periods of activity separated by longer periods of relative inactivity. During the longer inactive phase, tooth wear probably continues, but slowly. Provided the patient's main concern is the prevention of further wear to the teeth rather than improvement in their appearance, mon-

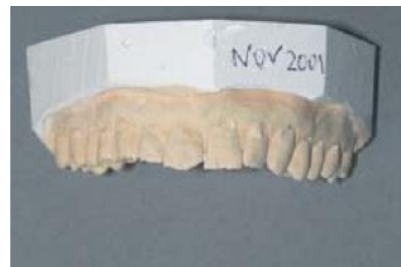
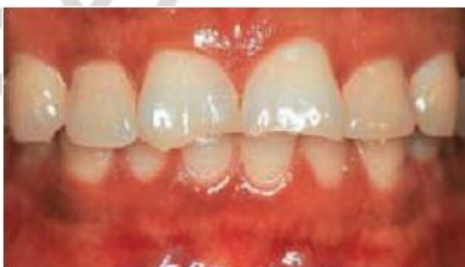
Fig. 17. The clinical photograph and the study model are of the same patient but taken about 8 years apart. There has been little tooth wear and, provided the patient is prepared to accept the appearance of the teeth, further monitoring would be indicated.

(Courtesy Professor B. G. N. Smith)

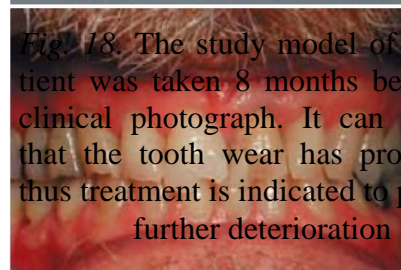


Fig. 18. The study model of this patient was taken 8 months before the clinical photograph. It can be seen that the tooth wear has progressed, thus treatment is indicated to prevent further deterioration

itoring is acceptable. However, it is imperative that the wear is monitored carefully rather than allowing the process to deteriorate to an extent where restorations become even more difficult (figs. 17, 18). The symptoms of regurgitation and the clean and unstained tooth surfaces indicate that the tooth wear is active; treatment is therefore indicated.

**Occlusal adjustment.** If the patient has a horizontal slide from the retruded contact position (RCP) to the intercuspal position (ICP), the adoption of RCP as the base position can be used to create space at the incisal edges of the upper anterior teeth. Adjustments to the occluding surfaces of the teeth are made until the RCP and ICP become coincident. A Michigan splint is helpful to determine the RCP, especially if manipulating the patient's mandible is difficult (fig. 19). Once established, the RCP should be recorded and transferred to a semi-adjustable articulator. The sequence of tooth adjustments can be planned on the articulator and recorded in a step-by-step process until the RCP is the same as the ICP so that the same sequence can subsequently be used in the mouth.

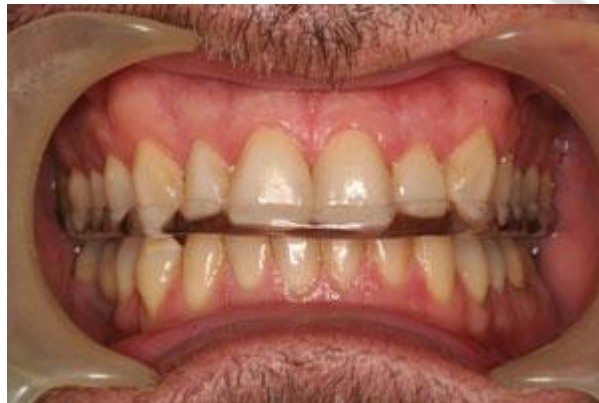

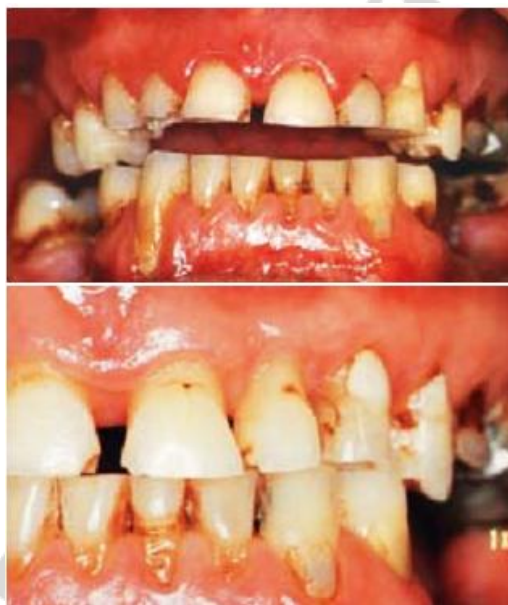Fig. 19. An example of a Michigan splint

**Full mouth rehabilitation.** Restoring the occlusal surfaces of all standing teeth and increasing the occlusal vertical dimension will provide sufficient space for anterior restorations. Whilst increasing the vertical dimension in an edentulous patient might not be successful, the opposite is true for dentate patients. Increases in vertical dimension have traditionally been achieved in stages by using a bite raising appliance to assess the patient's tolerance and thereafter restoring the teeth with crowns. However, the splints are often poorly tolerated and their use is questionable as they are often uncomfortable and delay the making of restorations at the new vertical dimension.

The recent improvement in bond strengths of dentin-bonding agents has allowed composites to be used as short- to medium-term restorations rather than traditional crowns. The composites can be overlaid onto the posterior teeth to increase the vertical dimension and also added to the anterior teeth to improve their appearance. These restorations should be considered for the short to medium term to allow the new vertical dimension to be assessed and thereafter conventional crowns made. It is a matter of judgement as to how much the vertical dimension

should be increased, although in this case the incisal edge of the existing porcelain crown provides a convenient reference point. In principle, the new vertical dimension should be estimated from the original crown height. This is most conveniently achieved with a diagnostic wax-up. Sometimes an existing tooth or restoration gives a clue to the original position of the incisal edge and the new restorations are made to this position. However, when it is not possible to estimate the level of the unworn incisors from existing teeth or restorations, it may be useful to manipulate the patient into the RCP. The more retruded position creates vertical space between the incisors, which might be sufficient for the new restorations. Most patients will accept increases in the occlusal vertical dimension in the order of 2–4 mm. An advantage of using composites is that, if the increase is too large, the occlusion can be adjusted until a comfortable position is achieved.

**Surgical crown lengthening.** The clinical crown height of teeth can be increased by surgically repositioning the gingival margin with alveolar bone recontouring (fig. 20). This procedure creates longer teeth but maintains the existing vertical dimension. The teeth can then be prepared for crowns using conventional techniques.



*Fig. 20.* Crown lengthening. The crown margin is surgically repositioned to a more apical position, so lengthening the crown height without changing the vertical dimension. This case shows crown lengthening and the results of successful periodontal treatment to control disease progression



**Elective devitalization and post crowns.** This procedure is not conservative and may reduce the prognosis of the teeth, but on occasions it is the only option available. Posts provide retention for the crowns but in doing so weaken the tooth and increase the potential for root fracture, which is further increased if the patient has a parafunctional habit.

**Restorative treatment of the noncarious cervical lesions (NCCLs).** Once the restorative treatment is indicated, the dentist has to know the different causes and aspects of each situation and choose the best strategy to employ. Unfortunately, although noncarious cervical lesions restorations are a very common occurrence in clinics, they also represent one of the less durable types of restorations and have a high index of loss of retention, marginal excess, and secondary caries. Despite the fact that these restorations are a continuing problem in restorative dentistry, the causes of the diminished longevity are still poorly understood. Failure of cervical adhesive restorations is often attributed to inadequate moisture control, adhesion to different opposite substrates (enamel and dentin), differences in dentin composition, and also cusp movement during occlusion. In order to help adopt the best restorative strategy, each step of the restorative procedure will be considered.

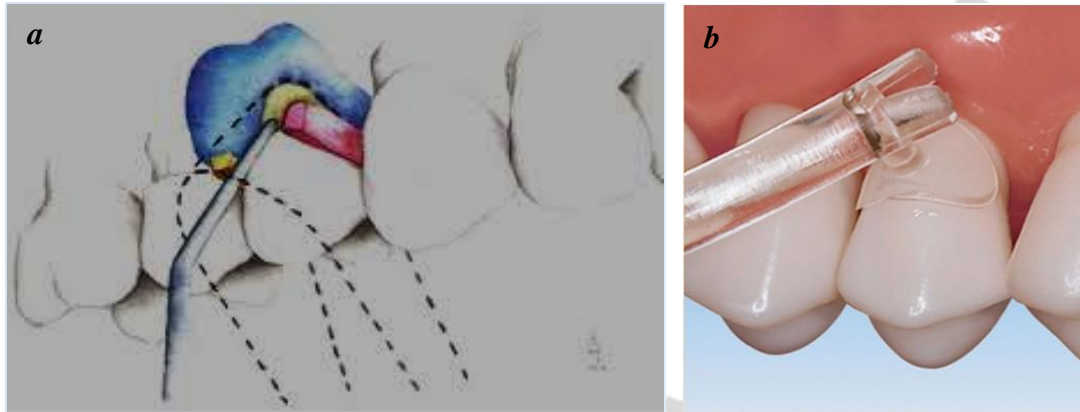
**Isolation.** Problems with restoring NCCLs include difficulty in obtaining moisture control and gaining access to subgingival margins. Rubber dam clamps, gingival retraction cord, and periodontal surgery are methods that can be used to retract and control the gingival tissues, and thus facilitate access and also control moisture. The exudation of gingival fluid is possibly one of the challenges to adhesion in cervical region, which is already impaired by other factors (such as the absence of enamel in the gingival wall of the cavity and the characteristics of the dentin in NCCLs). Rubber dam isolation should be used whenever possible. Intrinsic anatomical and morphological characteristics of the cervical region create limitations in the placement of the rubber dam and clamp. Proper isolation, is very difficult, sometimes impossible, when lesions extend proximally or under the gingiva. Sometimes part of the structure cannot be isolated and the dam promotes restorative material accumulation. Access is also limited, causing problems related to insertion of the restorative.

When adequate rubber dam isolation is not possible another isolation method has to be employed. The insertion of nonimpregnated retraction cords can help in moisture control (fig. 21). Another option is a proposed association of Mylar matrix with wood wedges and a photocured gingival barrier (figs. 22, 23). In any case, a proper isolation is the first step for the success in restoring NCCLs but, despite being the basis for the other subsequent steps, is probably the most underestimated one.

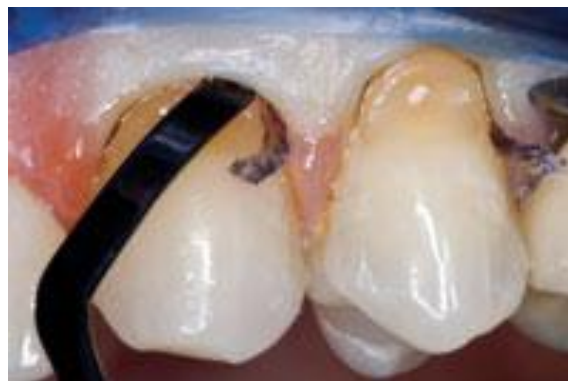

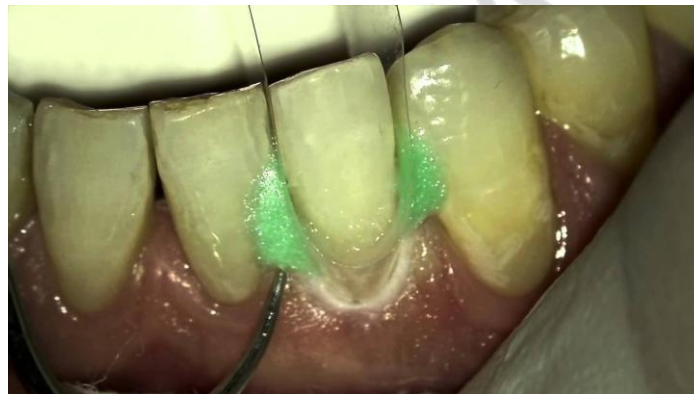Fig. 21. The insertion of the retraction cords

*Material Selection.* Even with advanced destruction, minimally invasive restorative intervention, such as sealing or covering with composite material, should be the therapy of choice. It is evident from the recent literature that there is no place for metallic materials such as amalgam and gold in the modern day restoration of NCCLs. Glassionomer cements (GICs), resin-modified GICs (RMGICs), a GIC/RMGIC liner base laminated with a resin composite, and resin composite in combination with a dentin bonding agent are all restorative options.



*Fig. 22.* The insertion of the of Mylar matrix with wood wedges and a photocured gingival barrier (a) Cure-Thru cervical matrices (b)



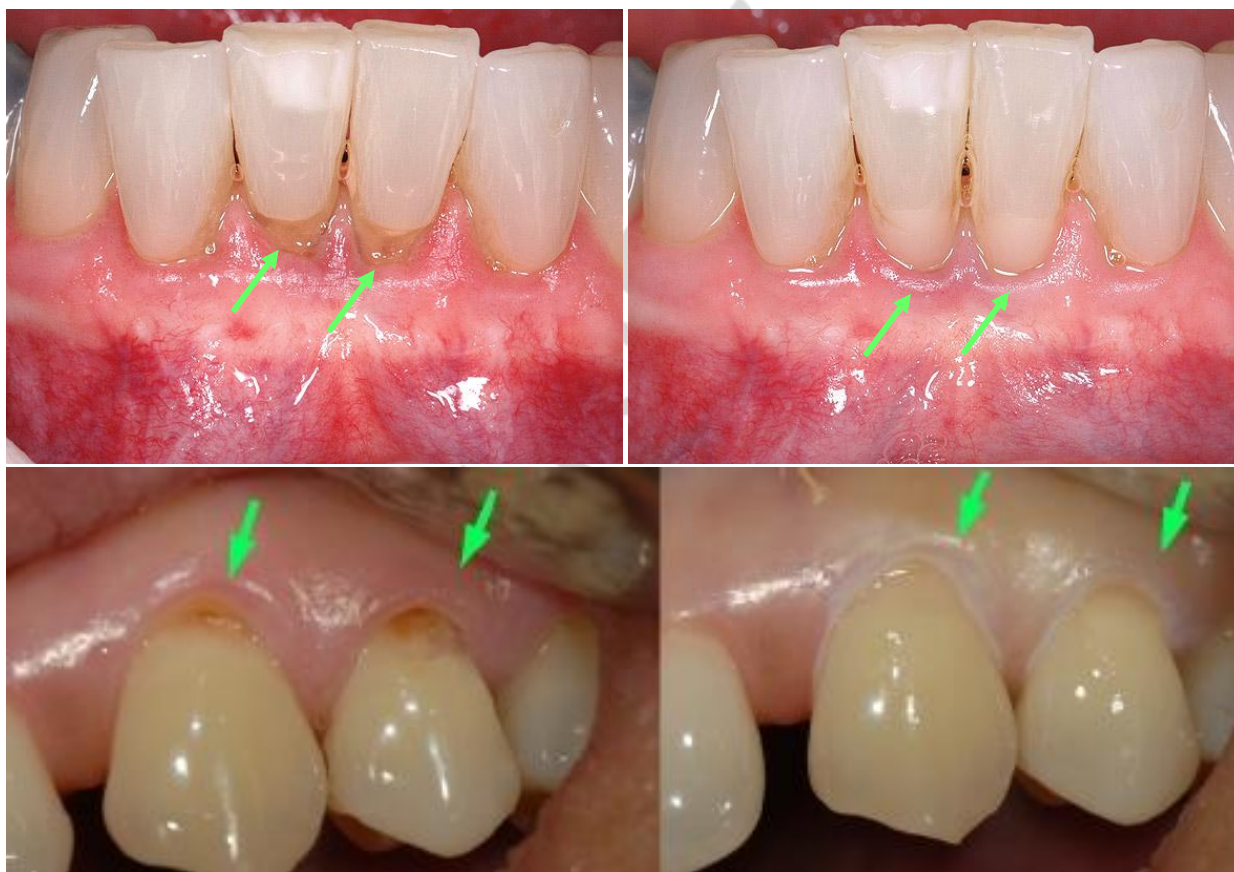*Fig. 23.* Cervical adaptation of the of Mylar matrix with a photocured gingival barrier

*Cavity Cleaning and Adhesion.* After the isolation another important, and commonly neglected, step should be performed: the prophylaxis of the cavity. Due to their nature, NCCLs are lined with a contaminated layer that resists adhesion. The gingival proximity (sometimes partially or totally covering the cavity) makes this procedure a more complex step. In some cases, rotary prophylactic brushes cannot be used in order to avoid mechanical aggression and bleeding. In nonsensitive cavities, the authors recommend rubbing the cavity and its periphery with a cotton pellet soaked with an anionic detergent, followed by rinsing with water, drying, and conventional total acid etching (37% phosphoric acid – 10 seconds on dentins and 20 seconds on enamel) with the aim of removing the sticky layer. Even when the roughening procedure is performed, the same sequence is recom-



mended. In the presence of sensitivity, rubbing with detergent is still indicated but the phosphoric acid should be applied only on enamel. Dentin will be conditioned by the self-etching primer/adhesive. When a conventional GIC is chosen, the previous conditioning with polyacrylic acid is indicated in order to provide a good surface wetting. If an RMGIC is chosen, pretreatment of dentin with self-etch adhesive systems, before filling, seems to be a good alternative to the conventional dentin conditioner provided by the manufacturer.

*Finishing and Polishing.* Any excess or roughness should be avoided in NCCLs' restorations. Plaque retention, gingival inflammation, and occurrence of caries lesions represent not only a failure of the restoration but also a creation of new problems to the patient. Poorly performed finishing and polishing procedures can lead to damage to the soft and hard tissues. Techniques with minimum need of finishing and polishing are ideal, but properly contoured restorations are seldom achieved without the need to remove excess material. When they are needed, a good option is the use of delicate diamond finishing points followed by application of a surface sealant or a liquid polisher (fig. 24).



*Fig. 24.* Results of teeth cervical lesions treatment in the mandibular incisors and premolars of the upper jaw with composite

*Clinical Control.* As emphasized before, treatment of NCCLs is not easy, and sometimes, new procedures or different approaches are needed. Semiannual appointments should be performed in order to observe the evolution of the lesions,

the conditions of the restorations, and other concerns of the patient. Also, the maintenance of the surface polish can be performed with a new surface sealant application.

РЕПОЗИТОРИЙ БГМУ

## EXCESSIVE TOOTH WEAR PREVENTION

In order to prevent or reduce non-carious destruction of tooth substance it is important to:

- Recognise that the problem is present
- Grade its severity
- Diagnose the likely cause or causes
- Monitor progress of the disease in order to assess the success, if any, of any preventative measures

The accuracy and importance of the chief complaint must be first evaluated. Common complaints associated with dentitions displaying tooth wear include concerns relating to:

- Aesthetic impairment (fractured, unattractive teeth/restorations or tooth discoloration)
- Difficulties with function, such as the efficiency of mastication or lip/cheek or tongue biting
- Less commonly, comfort (pain and sensitivity).

A detailed history of the chief complaint should be ascertained and documented. An accurate and up-to-date medical history must be obtained. The medical history may reveal underlying conditions which preclude the provision of complex treatment plans, and may also provide a valuable insight into the etiology of the wear pattern observed to be present.

**Implications for Home Care.** When performing oral hygiene, it is important to avoid tooth surface abrasion as well as mucosal abrasion and irritation. Patients should be advised to use a soft- or ultrasoftbristled toothbrush. If using a manual toothbrush, the patient must be taught how to use it correctly and without applying too much force. Patients have often been taught the Bass technique, which some may consider awkward and complicated. It is known that patients typically do not brush for an adequate length of time (considered to be two minutes of brushing). In addition, some patients are prone to brushing horizontally with force across the tooth surfaces in the belief that brushing hard is better and will remove more plaque. Manual toothbrushes currently available include models that are designed to gently remove plaque, and have handle designs that make brushing easier for patients (for example, Cross-Action®, Oral-B®). If using an electric toothbrush, care must also be taken to avoid applying too much pressure – some powered brushes will temporarily cut out (or «stall») if too much pressure is applied; this acts as a safety feature to help avoid the application of force that can result in tooth surface abrasion. In comparisons of the abrasivity of manual and powered brushes the results have varied depending on the study, with some finding manual brushes more abrasive and others finding powered brushes more abrasive.

With respect to interdental cleaning, the use of floss is unlikely to result in tooth surface abrasion, although care must be taken to avoid gingival abrasion and trauma as a result of using the floss carelessly or forcefully, or suddenly snapping it through tight contact points. Interdental brushes offer an alternative that may be easier to use and avoids the need to negotiate tight contact points — patients have been found to have fewer problems using interdental brushes than using floss.

Patients should be taught to use interdental brushes gently, and to use brushes that are soft and have adequate bristle coverage to avoid the underlying wire abrading the gingivae and teeth interdentally. Use of irrigating aids (fig. 25) and mechanical interdental cleaners have also been found to be effective.

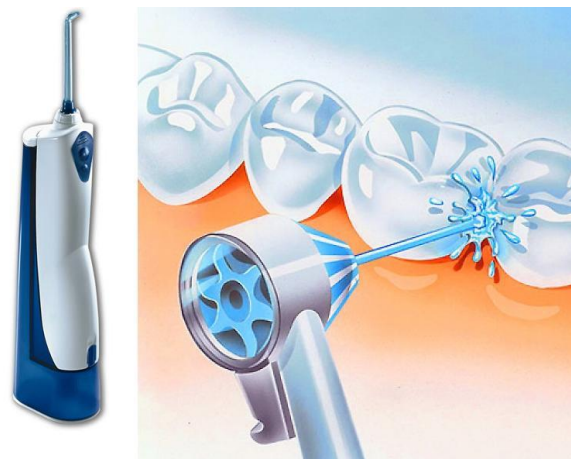

Fig. 25. Irrigator equipment and gentle cleaning of the teeth

**Desensitising therapy.** Where dentin hypersensitivity is a concern for the patient, the use of a 0.7% fluoride solution in the dental surgery followed by the home application of 0.4% stannous fluoride has been shown to be clinically beneficial.<sup>33</sup> Potassium containing toothpastes are also considered to be appropriate for the management of sensitive dentin. Such agents may be applied with the aid of a custom fabricated bleaching tray (containing reservoirs). Tooth Mousse ACP (GC), contains “Recaldent” which is an ingredient derived from casein (part of a protein found in bovine milk) that promotes remineralisation (fig. 26). This is a useful product for the passive management of tooth wear cases, when administered using a modified bleaching tray.

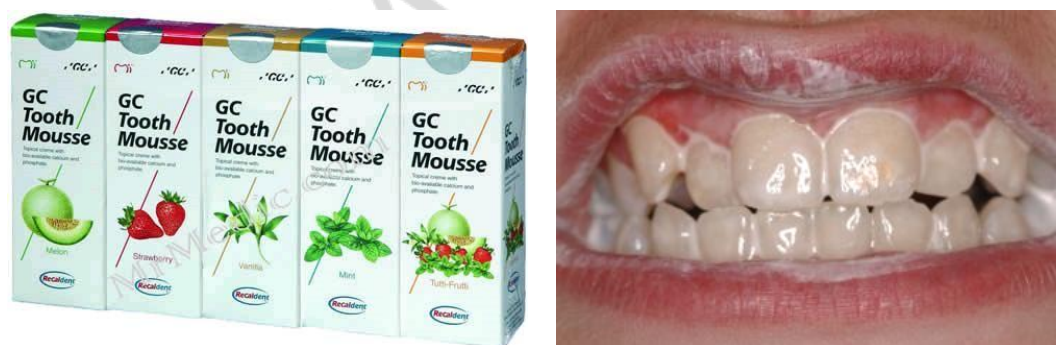

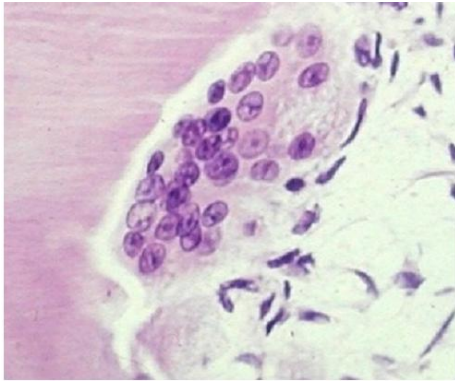
Fig. 26. Tooth Mousse application

**Habit changes.** A change of habit, such as drinking acidic beverages through a wide bore straw and the avoidance of swishing beverages in the mouth, will help to reduce the rate of dental erosion. The avoidance of overzealous tooth-brushing, the use of less abrasive toothpastes and refraining from habits such as that of pen/pencil biting will also help.

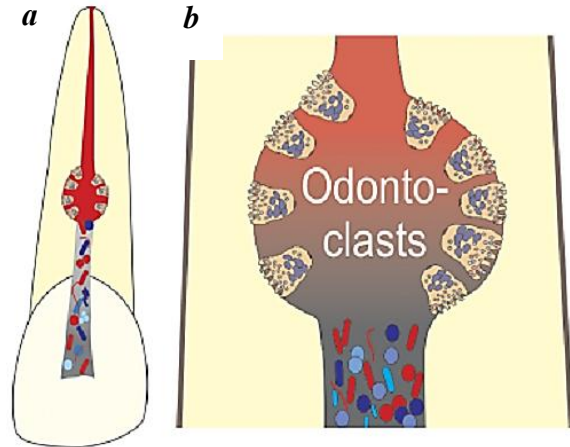


## PATHOLOGICAL RESORPTION OF TEETH

**Internal resorption** or **Internal granuloma of pulp** is an unusual condition of a tooth when the dentin and pulpal walls begin to resorb centrally within the root canal. Internal inflammatory root resorption is a relatively rare resorption that begins in the root canal and destroys surrounding dental hard tissues. Odontoclastic multinuclear cells are responsible for the resorption, which can grow to perforate the root if untreated (figs. 27, 28).



*Fig. 27. A histological specimen showing an odontoclast cell with a high number of nuclei next to a resorbed dentin surface Hematoxylin-eosin staining. Courtesy of Dr. P.-L. Lukinmaa*

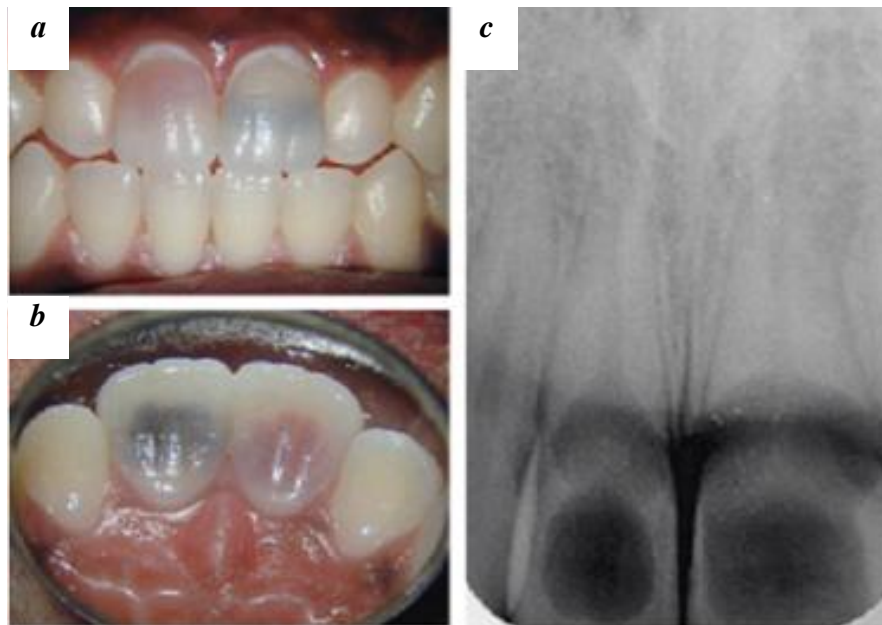


*Fig. 28. (a) A schematic drawing showing the pathogenesis of internal inflammatory root resorption. The canal coronal to the resorption is necrotic and invaded by microbes. The resorption cavity contains highly vascularized resorption tissue with multinuclear odontoclast cells. (b) A close-up image of the resorption*

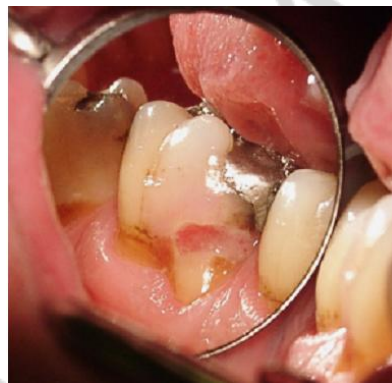The initiating factor in internal root resorption is thought to be trauma or chronic pulpal inflammation, but other etiological factors have also been suggested. The predisposing factors to internal root resorption as suggested in the literature include trauma, pulpitis, pulpotomy, cracked tooth, tooth transplantation, restorative procedures, invagination, orthodontic treatment and even a Herpes zoster viral infection. However, internal inflammatory root resorption is rare, its etiology and pathogenesis are only partially understood, and there is considerable confusion between internal and cervical invasive resorption, which is often incorrectly diagnosed as internal resorption.

In its classical form, internal root resorption is easy to diagnose. Internal root resorption is usually symptom-free; the first evidence of the lesion may be the appearance of a pink-hued area on the crown of the tooth (fig. 29, 30). However, when the resorption is actively progressing, the tooth is at least partially vital and may present symptoms typical of pulpitis, but in cases of perforation, a sinus tract usually forms.





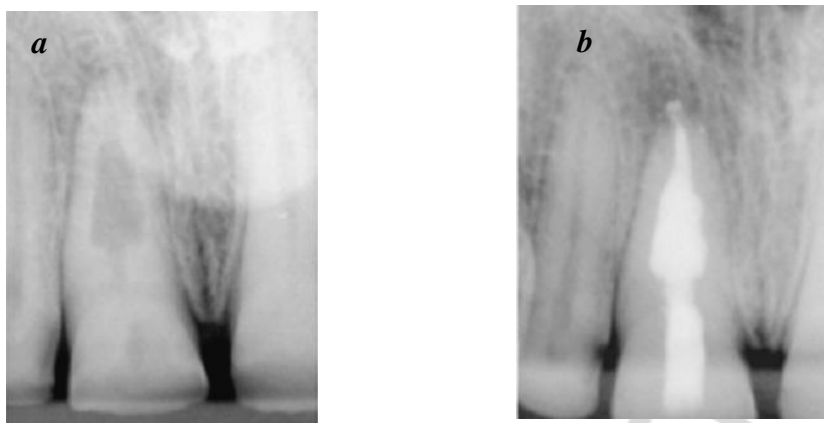
*Fig. 29.* (a) A patient with large internal inflammatory root resorptions in both maxillary central incisors. Tooth #11 has a pink discoloration indicating that the pulp is vital, whereas tooth #21 has a dark discoloration, an indication of pulp necrosis. (b) The teeth seen from the palatal side. Strong discolorations are clearly visible. (c) A radiograph of the teeth reveals wide destruction of dentin and enamel caused by internal inflammatory root resorption. *Courtesy of Dr. M. Ree*



*Fig. 30.* A photo of a lower first right molar with internal resorption which has perforated the crown in the distobuccal area at the cemento-enamel border. Highly vascularized granulation tissue can be seen through the perforation. A pink color through the enamel can be seen in a large area coronally and laterally to the perforation

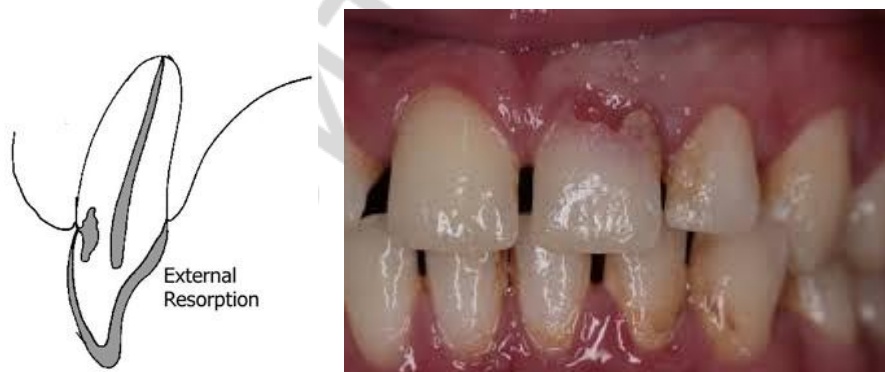The prognosis for treatment of small lesions of internal root resorption is very good. If, however, the tooth structure is greatly weakened and perforation has occurred, the prognosis is poor and tooth extraction must be considered. Sodium hypochlorite, ultrasonic instrumentation and calcium hydroxide are the cornerstones of treatment of internal inflammatory root resorption (fig. 31). Mineral trioxide aggregate is being increasingly used as a root canal filling material, particularly in cases of perforation.

**External resorption** is a condition of a tooth where the root surface is lost. This can be caused by chronic inflammation, cysts, tumors, trauma, reimplantation of a tooth, bleaching procedures, or sometimes the cause is unknown.



*Fig. 31.* Pre-operative (a) and post-operative (b) radiograph of the patient with the internal inflammatory root resorption in the middle root of the left upper central incisor. A final radiograph shows the root canal and the internal resorption filled with gutta-percha and sealer using warm vertical condensation

**External cervical resorption** is a clinical term used to describe a relatively uncommon and aggressive form of external tooth resorption which may occur in any tooth in the permanent dentition. Characterized by its cervical location and invasive nature, this resorptive process can lead to a severe loss of tooth structure (fig. 32). Resorption of coronal dentin and enamel often creates a clinically obvious pinkish color in the tooth crown as highly vascular resorptive tissue becomes visible through thin residual enamel. Frequently, cervical resorption lesions are confused with and misdiagnosed as caries or internal resorption. As a result, inappropriate treatment is often initiated.



*Fig. 32.* Cervical resorption

Cervical resorption can occur following injury to the root surface at or just below the epithelial cervical attachment apparatus. Clastic cells colonize the damaged area and begin resorbing the tooth. The damage can be caused by physical or chemical means. Physical injury to non-endodontically and endodontically treated teeth typically includes all forms of tooth trauma, surgical procedures, orthodontic treatment, bruxism, and periodontal root planning and scaling. Chemical injury

can occur from agents used within the root canal system, such as internal bleaching solutions. Research suggests that a combination of 30% H<sub>2</sub>O<sub>2</sub> and heat can damage the cementum layer through the dentinal tubules.

A classification system has been developed to provide a clinical guide in the assessment of cases of invasive resorption (fig. 33).

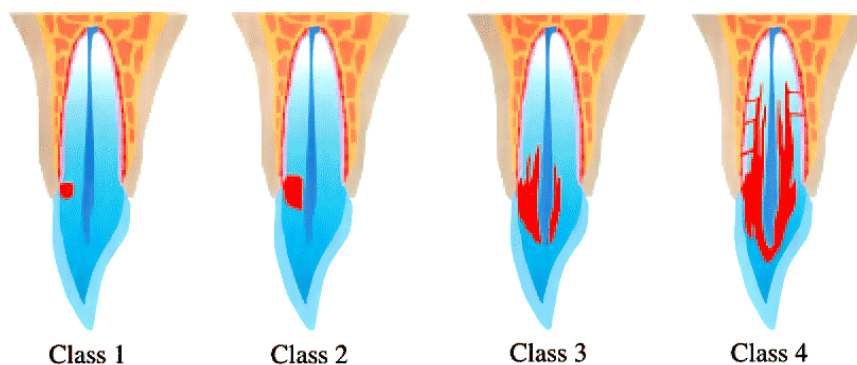


Fig. 33. Classification of the cervical resorption

*Class 1* — a small invasive resorptive lesion near the cervical area with shallow penetration into dentin.

*Class 2* — a well-defined invasive resorptive lesion that has penetrated close to the coronal pulp chamber but shows little or no extension into the radicular dentin.

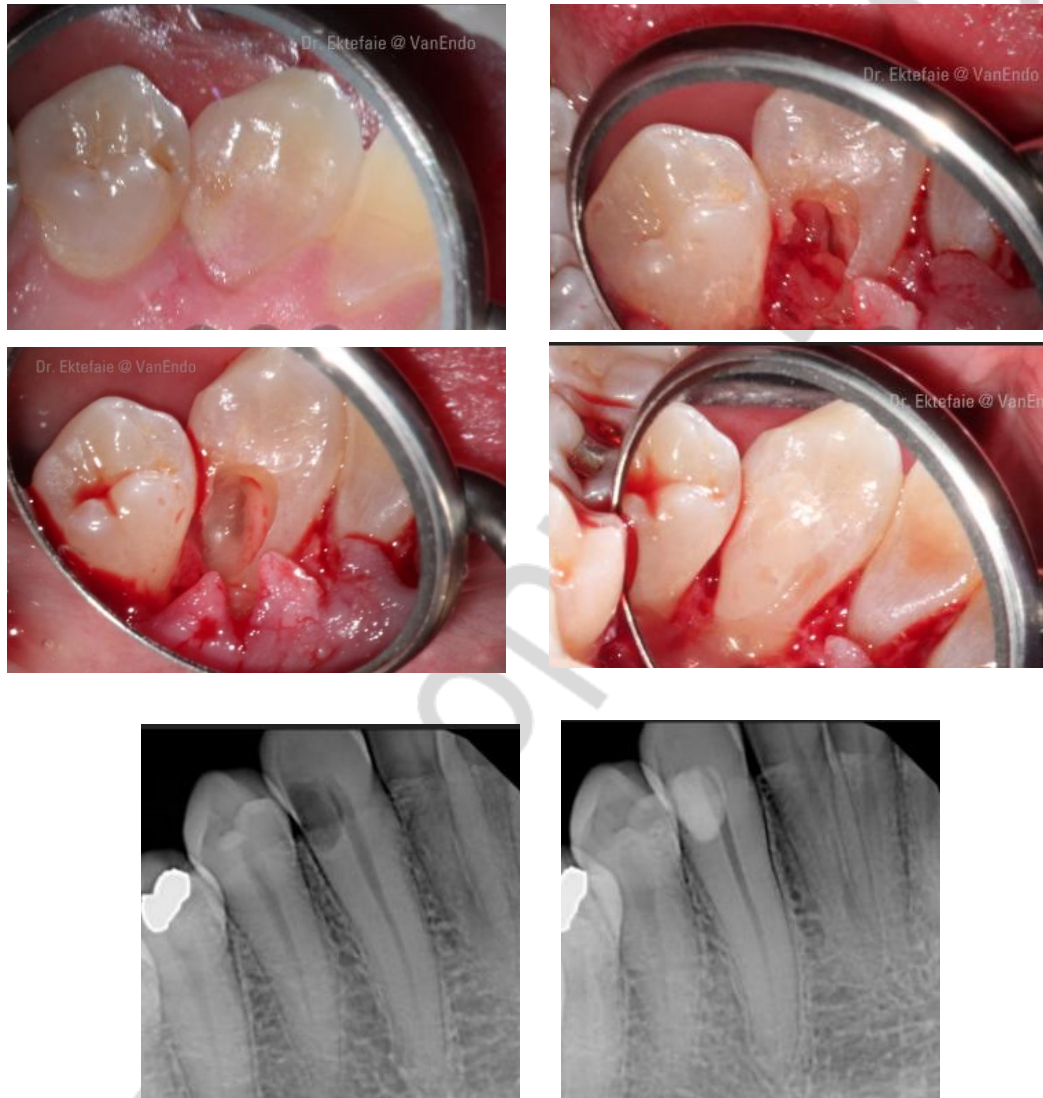
*Class 3* — a deeper invasion of dentin by resorbing tissue, not only involving the coronal dentin but also extending into the coronal third of the root.

*Class 4* — a large, invasive resorptive process that has extended beyond the coronal third of the root.

As in most cases of external resorption, cervical resorption is usually painless and goes unnoticed by the patient unless pulpal or periodontal infection is present. In some cases, a deep resorptive cavity can result in sensitivity to temperature changes because of proximity to the pulp. Tests for pulpal vitality are indicated to determine the pulpal status prior to initiating treatment. In most cases, cervical resorption is detected during routine radiographic or clinical examination, however there may also be a complete absence of clinical signs that would aid in diagnosis. If the lesion is located marginally, a pink coronal discoloration may be evident. The pink discoloration is caused by deep red, underlying granulomatous tissue showing through thin translucent enamel. This tissue bleeds freely on probing. By probing the resorption cavity walls with an explorer, hard, mineralized tissue will be felt accompanied by a sharp, scraping sound. This, and the appearance of knife-edge cavity borders are important in differentiating this resorption from root caries. A carious lesion presents with a yellowish or light brown color, and has a soft or leathery texture on probing with light pressure. The carious lesion may be covered by visible plaque, and cavitation may or may not be present. If the cervical resorptive lesion is more apically or proximally situated, it will not be visible, but may be detected by probing. When probing the area, copious bleeding and a spongy texture are commonly observed as the granulomatous tissue in the resorptive defect is disturbed. Resorptive process does not usually involve the pulp tissue and in most cases the tooth stays vital. Teeth with Class 3 or 4

resorption have poor prognosis. So, the key to saving these teeth is to catch the resorptive defects early on.

A resorptive defect harbouring a very touch-sensitive granulation tissue can be detected easily by running the sharp, curved end of the explorer below the level of cementum-enamel junction. The treatment of the resorptive defect is open-flap restoration. The tissue residing inside the defect is usually very easy to remove as it appears detached. As mentioned before, the pulp tissue is unaffected by this resorptive process and therefore, root canal therapy is not needed (fig. 34).



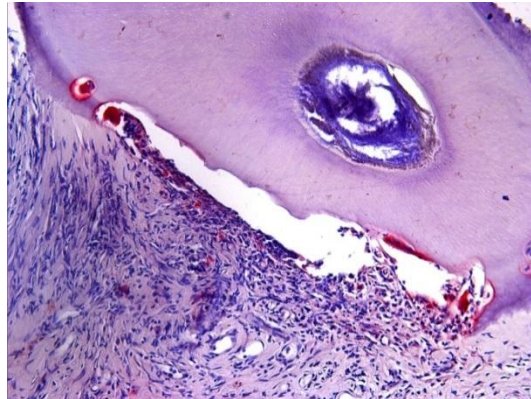
*Fig. 34. Treatment of the cervical resorption (Dr. Mahmoud Ektefaie, DMD)*

While the exact etiology of cervical resorption remains unknown, treatment is directed toward complete removal of the resorptive tissue. The use of a slow-speed handpiece is recommended to remove all resorptive tissue and to develop a sound dentinal margin. To prevent mechanical pulp exposure, bur contact with the pulpal wall must be avoided. The content of the defect, usually soft tissue with small hard tissue fragments, can easily be removed with spoon excavators.



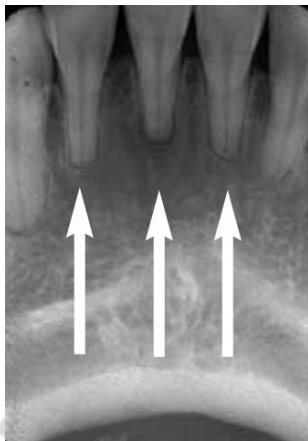A determination must be made if endodontic treatment is necessary and the defect restored with an appropriate restorative material, like a glass-ionomer resin. Adjunctive orthodontic extrusion can also be used with some advanced lesions.

**External root resorption** is a progressive and destructive loss of tooth structure, initiated by a mineralized or denuded area of the root surface. It is a surprising fact that a permanent tooth throughout life is placed in an environment of alveolar bone surrounded by very active osteoblasts and osteoclasts without being approached by any of these two cell lines under normal conditions. The process of tooth resorption involves an elaborate interaction among inflammatory cells, resorbing cells, and hard tissue structures (fig. 35). Frequently, this pathologic condition is difficult to predict, diagnose and treat.

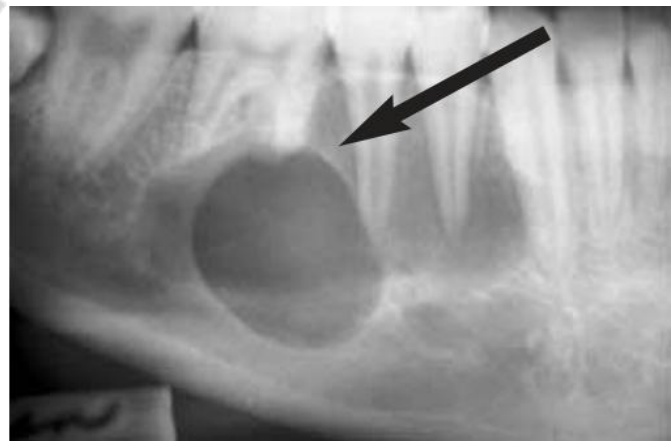

*Fig. 35. Experimental external root resorption in rats due to periapical inflammation Hematoxylin stained and TRAP-reaction. Odontoclast cells are red in color (Dr. E.L. Kolb)*

There are several types of external root resorption, external inflammatory root resorption being the most common. It may arise as a sequela of traumatic injury, orthodontic tooth movement (fig. 36), or chronic infection of the pulp or periodontal structures (fig. 37). External inflammatory root resorption is considered a major resorptive condition without symptoms.



*Fig. 36. External root resorption, secondary to orthodontic treatment*



*Fig. 37. External root resorption, secondary to radicular cyst*



The treatment goal in the external apical root resorption is to remove or destroy bacteria to allow healing to take place in the periradicular space (fig. 38). Nonsurgical pulp space therapy combined with a calcium hydroxide dressing is recommended. Mineral trioxide aggregate (MTA) also well known for its great biocompatibility, has demonstrated excellent sealing ability in studies of dye penetration and bacterial leakage even under blood contamination conditions. MTA is widely applied in root-end filling, perforation repair. It can induce regeneration of periradicular tissues, such as bone and cementum.

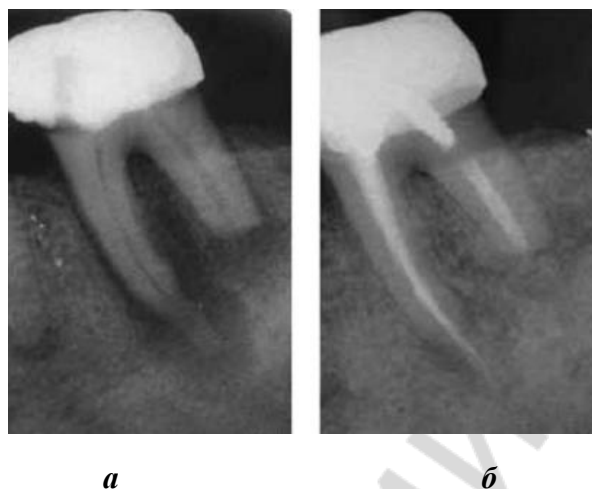


Fig. 38. Radiograph showing external inflammatory root resorption before treatment (a) and 6-month follow-up after root canal therapy (b)

## HYPERCEMENTOSIS

A very common dental change, which raises many questions on its etiology and meaning, is the hypercementosis. Hypercementosis is an idiopathic, non-neoplastic condition characterized by the excessive build-up of normal cementum on the roots of one or more teeth.

Thicker cementum — and, ultimately, hypercementosis — may be an adaptive response to an increased periodontal functional demand. This may result from an acceleration in the deposition, or an increase in the amount of cementum matrix. It requires more time and high functionality of the periodontal fibers. Hypercementosis can also occur as response to a chronic periapical lesion. Hypercementosis can also be present with none of the above causes. If multiple teeth are involved, we will need to rule out other conditions, such as Paget's disease and hyperpituitarism

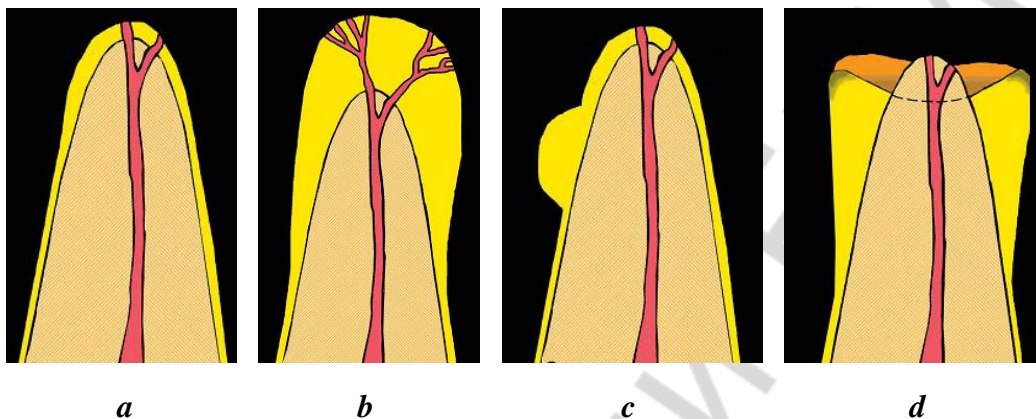
### **Possible causes of hypercementosis:**

- The extension of a tooth from its normal position due to the loss of the opposing tooth from the opposite arch.
- An abscess or low-grade inflammation at the tip of the root (most often caused by an infection of the pulp, or nerve, of a tooth).

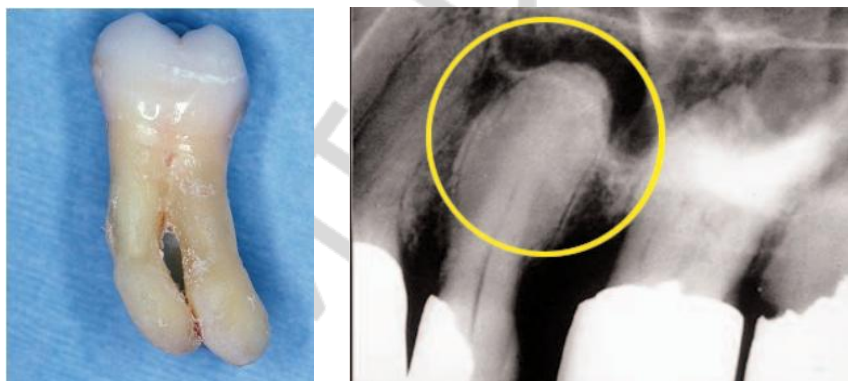
- A tooth that hits first when chewing (hyperocclusion).
- A broken or fractured root.

There can be identified three morphological types of hypercementosis (fig. 39):

- 1) club-shaped diffuse hypercementosis (fig. 40);
- 2) focal or localized hypercementosis;
- 3) hypercementosis in the shape of a «shirt sleeve cuff», does not involve the most apical portion, and occurs on the periphery as response to a chronic periapical lesion (fig. 41).

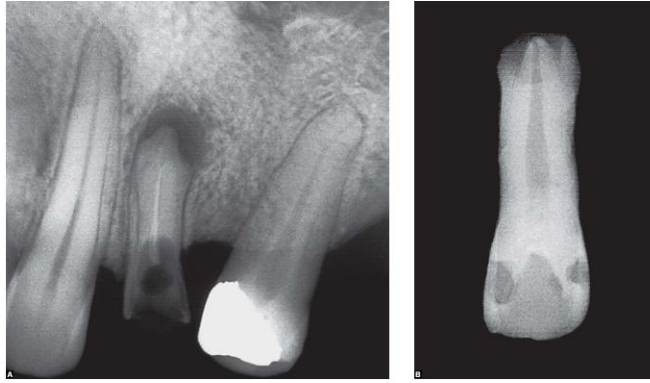


*Fig. 39. Morphological types of hypercementosis: (a) normal root; (b) club-shaped diffuse hypercementosis; (c) focal or localized hypercementosis; (d) hypercementosis in the shape of «shirt sleeve cuff» (Pinheiro BC)*



*Fig. 40. Club-shaped diffuse hypercementosis*

There are no special treatment options for hypercementosis. It is necessary to determine the cause of neoplastic cementum excessive build-up. Teeth with hypercementosis tend to have an accelerated aging of the pulp, reducing its reparatory capacity. In case of inflammatory-associated hypercementosis following root canal therapy is required.



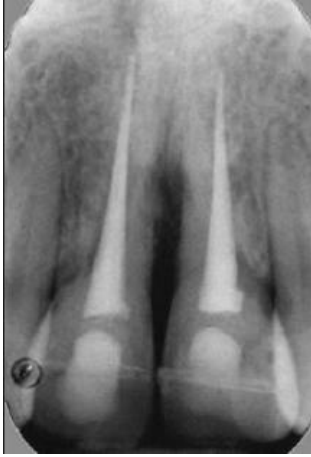*Fig. 41.* Upper premolar and incisor with hypercementosis in shape of a «shirt sleeve cuff». This aspect is provided by the presence of chronic periapical lesion and increased formation of reactive nature in the periodontal periphery of the lesion.

### **ANKYLOSIS OF TEETH**

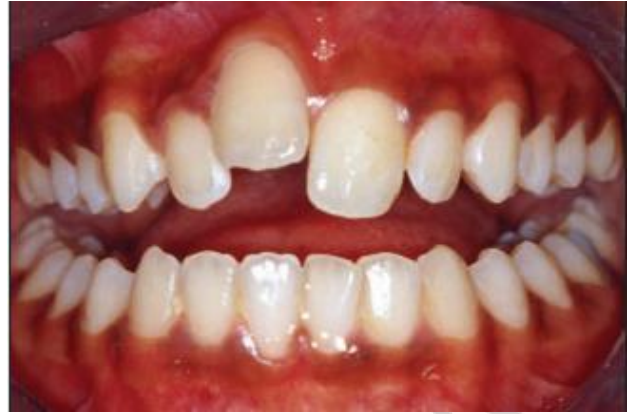Ankylosis is a pathologic fusion of the cementum or dentin of a tooth root to the alveolar bone. It is most likely to affect a replanted avulsed tooth or a severely intruded tooth (i.e., intrusion greater than 6 mm or half the clinical crown length) within weeks following trauma. Risk of ankylosis is highest in this subset of luxation injuries because of the nature and severity of damage to the root-side periodontal ligament.

Detection of ankylosis depends on clinical signs and radiographic interpretation (fig. 42). Clinical diagnosis of ankylosis is based on qualitative assessment of the sound produced on percussion and of mobility. Ankylosis of teeth in the pre-adolescent can dramatically alter local growth and development of the alveolus. The time at which these effects become clinically significant depends on the patient's age and stage of growth and development. Progressive infraocclusion and distortion of the gingiva and underlying bone produce both functional and esthetic deficits with jaw growth (fig. 43). It is accepted practice to assess mobility and percussion sound to detect ankylosis at an early stage. Tooth mobility can be evaluated by observing the extent of tooth movement during luxation in a labial-lingual direction. An ankylosed tooth produces a characteristic highpitched sound on percussion, compared with adjacent unaffected teeth.

Adults, with their slower rate of replacement resorption may retain an ankylosed tooth for many years with minimal treatment or minor cosmetic modifications. A number of increasingly invasive interventions have been advocated for growing individuals where ankylosis may produce significant local alveolar distortion. Early extraction followed by a series of transitional prostheses, intentional luxation and surgical repositioning, decoronation (crown amputation), alveolar distraction osteogenesis and ridge augmentation with placement of an endosseous implant retained prosthesis at skeletal maturity have all been described.



*Fig. 42.* Radiographic appearance of ankylosis in a 17-year-old female. Teeth 11 and 21 were replanted at the age of 15



*Fig. 43.* Tooth 11, which was avulsed and replanted when the patient was 7.5 years of age, developed subsequent ankylosis. Note the infraocclusion of tooth 11, space loss and distortion of the gingival architecture in the maxillary anterior segment

The choice of treatment depends on the severity of infraocclusion and replacement resorption, the preference and experience of the clinician and the patient's expectations.

## REFERENCES

1. *Cervical* external root resorption : 3-year follow-up of a case / D. Nikolidakis [et al.] // J. Oral Science. 2008. Vol. 50, № 4. P. 487–491.
2. *Comparison* of different approaches of interdental oral hygiene : interdental brushes versus dental floss / V. Christou [et al.] // J. Periodontol. 1998. Vol. 69, № 7. P. 759–764.
3. *Clinical* measurement of tooth wear : Tooth Wear Indices / F. J. López-Frías [et al.] // J. Clin. Exp. Dent. 2012. Vol. 4, № 1. P. e48–e53.
4. *Current* concepts on the management of tooth wear : part 1. Assessment, treatment planning and strategies for the prevention and the passive management of tooth wear / S. B. Mehta [et al.] // Br. Dent. J. 2012. Vol. 13, № 212(1). P. 17–27.
5. *Gordon, J. M.* A clinical study of the safety and efficacy of a novel electric interdental cleaning device / J. M. Gordon, J. A. Frascella, R. C. Reardon // J. Clin. Dent. 1996. Vol. 7(3). P. 70–73.
6. *Krejci, I.* Marginal adaptation of class V restorations using different restorative techniques / I. Krejci, F. Lutz // J. Dent. 1991. Vol. 19, № 1. P. 24–32.
7. *Restoration* of non-carious cervical lesions. Part I. Modelling of restorative fracture / P. Ichim [et al.] // Dent. Materials. 2007. Vol. 23, № 12. P. 1553–1561.
8. Haapasalo, M. Internal inflammatory root resorption: the unknown resorption of the tooth / M. Haapasalo, U. Endal // Endod. Topics 2006. Vol. 14, № 1. – P. 60–79.
9. *Tooth* morphology and characteristics of non-carious cervical lesions / J. E. A. Palamara [et al.] // J. Dent. 2006. Vol. 34, № 3. P. 185–194.
10. *Grippio, J. O.* Abfraction, abrasion, biocorrosion, and the enigma of noncarious cervical lesions: a 20-year perspective / J. O. Grippo, M. Simring, T. A. Coleman // J. Esthet. Restor. Dent. 2012. Vol. 24, № 1. P. 10–23.
11. *Tyas, M. J.* The Class V lesion — aetiology and restoration / M. J. Tyas // Austral. Dent. J. 1995. Vol. 40, № 3. P. 167–170.
12. *McLey, L.* Clinical and laboratory evaluation of powered electric toothbrushes: laboratory determination of relative abrasion of three powered toothbrushes / L. McLey, R. L. Boyd, S. Sarker // J. Clin. Dent. 1997. Vol. 8, № 3. P. 76–80.
13. *Newman, H. N.* Periodontal pocket irrigation as adjunctive treatment / H. N. Newman // Curr. Opin. Periodontol. 1997. Vol. 4. P. 41–50.
14. *Restoration* of Noncarious Cervical Lesions : When, Why, and How / dos R. P. Cesar [et al.] ; School Dent. Sate Un-y Rio de Janeiro (UERJ) // Int. J. Dent. 2012. Article ID 687058. P. 8.
15. *Schemehorn, B. R.* The dentin abrasivity potential of a new electric toothbrush / B. R. Schemehorn, A. C. Zwart // Am. J. Dent. 1996. Vol. 9, Spec No. P. 19–20.
16. *Ektefaie, M.* Tag Archives : heithersay classification The Pink Tooth September 19, 2012. [Electronic resource] / M. Ektefaie. – Mode of access : <https://endolounge.com/tag/heithersay-classification>.



## CONTENTS

Introduction .....	3
Icd-10 classification (who, 2014) .....	3
Definitions of causes of tooth surface lesions .....	4
Attrition.....	5
Abrasion.....	6
Erosion or corrosion.....	7
Abfraction .....	9
Combined mechanisms of tooth wear.....	9
Differential diagnosis of the pathological tooth wear.....	10
Clinical measurement of tooth wear .....	12
Options for excessive tooth wear treatment.....	14
Excessive tooth wear prevention .....	21
Pathological resorption of teeth .....	23
Hypercementosis .....	29
Ankylosis of teeth .....	31
References .....	33

Учебное издание

Казеко Людмила Анатольевна  
Колб Екатерина Леонидовна  
Кармалькова Ирина Сергеевна

**ЗАБОЛЕВАНИЯ ТВЕРДЫХ ТКАНЕЙ ЗУБОВ,  
ВОЗНИКАЮЩИЕ ПОСЛЕ ПРОРЕЗЫВАНИЯ**  
**DISEASES OF HARD TISSUES OF TEETH ARISING  
AFTER ERUPTION**

Учебно-методическое пособие

На английском языке

*2-е издание*

Ответственная за выпуск Л. А. Казеко  
Переводчик Е. Л. Колб  
Компьютерная верстка А. В. Янушкевич

Подписано в печать 04.09.17. Формат 60×84/16. Бумага писчая «Снегурочка».

Ризография. Гарнитура «Times».

Усл. печ. л. 2,09. Уч.-изд. л. 1,81. Тираж 40 экз. Заказ 700.

Издатель и полиграфическое исполнение: учреждение образования  
«Белорусский государственный медицинский университет».

Свидетельство о государственной регистрации издателя, изготовителя,  
распространителя печатных изданий № 1/187 от 18.02.2014.

Ул. Ленинградская, 6, 220006, Минск.