

Y. Bogdanov

CONGENITAL ANOMALIES OF THE HUMAN VERTEBRAL COLUMN

Scientific advisors: Professor Kabak S. L, MD

Senior lecturer Zatochnaya V. V.

Department of Human Morphology

Belarusian State Medical University, Minsk

Resume. Congenital spinal deformities are associated with an anomalous vertebral formation and segmentation. In most cases, such anomalies are detected only with an X-ray examination of scoliosis. Butterfly vertebra (BV), also known as a sagittal cleft vertebra, is a rare congenital malformation of the spine, which is usually reported in the literature as an isolated finding, this anomaly is usually asymptomatic and detected incidentally. A BV may be isolated or associated with other spinal anomalies such as kyphoscoliosis, hemivertebrae, or spina bifida; other congenital syndromes; or chromosomal defects.

Keywords: congenital anomaly, butterfly vertebra, hemivertebrae, spina bifida, scoliosis.

Aim. To evaluate the possibilities of computed tomography (CT) for the detection of congenital spinal anomalies.

Material and methods. CT scans of the 5 patients less than 20 years old were presenting to “Republican Scientific and Practical Centre for Traumatology and Orthopedics” from 2011–2017 with scoliosis. Axial, multiplanar and 3D reconstructions were analyzed using imaging software.

Results. All 5 patients had scoliotic deformations of the spine in the thoracic region. Butterfly vertebrae were revealed in the thoracic region with a median slit in the bodies of Th₆, Th₈, Th₉, Th₁₀ and Th₁₁. The total sagittal cleft was found out in 4 cases from 5 butterfly vertebrae (Figure 1A). In 1 case the cleft was incomplete (Figure 1B). Other congenital anomalies such as spina bifida posterior and hemivertebra were found together with the butterfly vertebrae. In some cases block vertebra, fusion of the transverse processes and ribs (intercostal block) were revealed (Figure 1A, C, D).

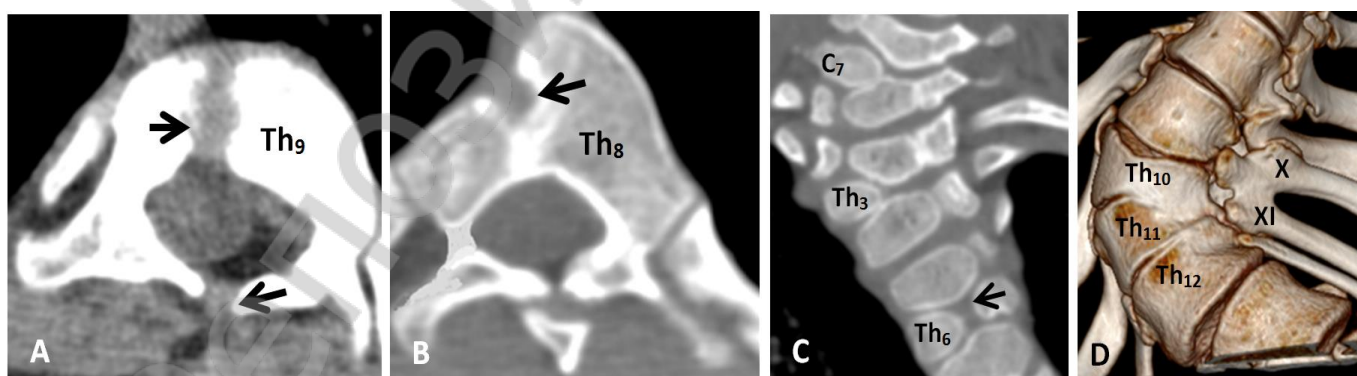


Figure 1 - CT scans of the vertebral column. A – thoracic vertebrae (Th₉), with complete sagittal cleft of the body and spina bifida posterior (axial projection); B – incomplete sagittal cleft of the body of the eighth thoracic vertebra (axial projection); C – cervical C₈ and thoracic Th₃ hemivertebrae, butterfly vertebra Th₆ (3D-reconstruction of the thoracic spine, frontal view). D – block of the lower thoracic vertebrae bodies and arcs (Th₁₀-Th₁₂), intercostal block (X-XI) (3D - reconstruction of the thoracic spine, view of the left side). Bone defects are indicated by arrows.

The vertebral column is the central structure in the human body, which provides stability, posture and initiates all the movements. The type of anomaly depends on which direction and where the abnormal vertebrae are positioned within the spinal column. The main factor causing the spine to curve is the asymmetric growth of the abnormally formed vertebrae. Formation of spine during embryogenesis is a highly complex and regulated process. Even small disruption (error) can lead to a variety of congenital anomalies such as hemivertebrae, block vertebrae, butterfly vertebrae, and in extreme cases, spina bifida. Dense structures within the body – such as bone – are easily imaged, that is why in most cases, such anomalies are detected only with an X-ray examination of scoliosis. CT scans can be used to identify disease or injury within various regions of the body.

Butterfly vertebra (also known as vertebral sagittal cleft) is an uncommon congenital anomaly of the spine [1]. It results from the failure of fusion of the lateral halves of the vertebral body because of persistent notochondal tissue between them forming a cleft in the center. Butterfly vertebrae often have no symptoms, and are only found when an x-ray is taken. This anomaly was first described in 1844 by Rokitansky, who examined the 12th thoracic vertebra of a 55-year-old man [2].

Spina bifida is a birth defect that occurs when the spine and spinal cord don't form properly. It falls under the broader category of neural tube defects. Spina bifida can range from mild to severe, depending on the type of defect, size, location and complications. The mild form is the most common. It usually doesn't cause problems or need treatment. You can't see the defect, but some people may have a dimple, birthmark, or hairy patch on their back. Most people with this form don't know they have it until they get a back X-ray for another reason [3].

The most rare and severe form is myelomeningocele. It's what most people mean when they say "spina bifida." Part of the spinal nerves push out of the spinal canal, and the nerves are often damaged. You may see a bulge in the skin. In some babies, the skin is open and the nerves are exposed. Typically, spina bifida is diagnosed before or right after birth.

Block vertebra is partial or complete fusion of adjacent vertebral bodies which, on radiographs, give the appearance of a more or less solid bony mass. Block vertebrae occur when there is improper segmentation (separation) of the vertebrae, leading to parts of or the entire vertebrae being fused. The fusion of thoracic vertebrae can present many clinical signs including formation of abnormal curvatures of the spine like scoliosis. Block vertebra is partial or complete fusion of adjacent vertebral bodies which, on radiographs, give the appearance of a more or less solid bony mass.

Hemivertebra is a developmental anomaly in which one side of a vertebra is incompletely developed. Hemivertebrae are usually wedge shaped vertebrae, in between other vertebrae. There are three main types of hemivertebrae. Unsegmented - this means that the hemivertebra is wedged between two bones without a growth plate. This is the least common type of hemivertebra. Semi-segmented - the hemivertebra is fused to either the upper or lower vertebra and only has one growth plate. Fully segmented - the hemivertebra has a full growth plate on either side and has full growth potential. This is the most common type of hemivertebra. The unsegmented and semi-segmented hemivertebrae has less growth potential, and tend to cause less issues and a less severe

curve. Fully segmented hemivertebra can cause larger curves, and sometimes, with a sharp curve, you run the risks of spinal cord compression or other nerve issues [4].

Conclusions:

1. Computed tomography is an informative method for detecting congenital anomalies of the spine.

2. The total sagittal cleft was found out in 4 cases from 5 butterfly vertebrae. In 1 case the cleft was incomplete.

3. Together with the butterfly vertebra the other congenital anomalies of the development of vertebral column were revealed.

References

1. Sifuentes Giraldo, W. A. Butterfly vertebra / W. A. Sifuentes Giraldo, J. Gallego Rivera // *Reumatología Clínica (English Edition)*. – 2015. – № 1. – P. 52-53.

2. Differential diagnosis of multiple vertebral compression: butterfly vertebrae / N. Ozaras et al. // *Journal of physical therapy science*. – 2015 – Vol. 27. – № 11. – P. 3601-3603.

3. Differentiating between traumatic pathology and congenital variant: a case report of butterfly vertebra. / O. Karagyris et al. // *Clinics in orthopedic surgery*. – 2015. – Vol. 7. – №. 3. – P. 406-409.

4. Congenital Butterfly Vertebra / M. Slouma et al. // *Acta medica portuguesa*. – 2016. – Vol. 29. – № 7-8. – P. 491.