

DOI: <https://doi.org/10.51922/2616-633X.2021.5.2.1307>

THE ROLE OF ENDOCARDIAL CATHETER ABLATION IN THE MANAGEMENT OF PAROXYSMAL VENTRICULAR TACHYCARDIA IN PATIENT WITH ARRHYTHMOGENIC CARDIOMYOPATHY

D. Goncharik, L. Plashchinskaya, V. Barsukevich, A. Chasnoit, Ye. Rebeko, M. Zakharevsky, O. Kovalenko

Republican Scientific and Practical Center «Cardiology», Minsk, Belarus
goncharikd@yahoo.com

УДК 161.124-008.311-008.318-089.819.1

Key words: arrhythmogenic cardiomyopathy, ventricular tachycardia, ablation, substrate mapping.**FOR REFERENCES.** D. Goncharik, L. Plashchinskaya, V. Barsukevich, A. Chasnoit, Ye. Rebeko, M. Zakharevsky, O. Kovalenko. The role of endocardial catheter ablation in the management of paroxysmal ventricular tachycardia in patient with arrhythmogenic cardiomyopathy. *Neotlozhnaya kardiologiya i kardiologicheskyye riski* [Emergency cardiology and cardiovascular risks], 2021, vol. 5, no. 2, pp. 1307–1314.

The article describes current approaches to the interventional treatment of patients with arrhythmogenic cardiomyopathy (ACM) complicated with paroxysmal sustained ventricular tachycardia (VT). The advantages and disadvantages of two competing methods for mapping and ablation – activation mapping vs substrate

mapping – are analyzed. The rationale for the proposed method of VT substrate mapping in ACM and the authors' own results are presented. The results obtained by the authors make it possible to recommend substrate ablation according to the proposed technique as an invasive first-line therapy for patients with persistent monomorphic VT and ACM.

Introduction

What is currently known:

To reduce the SCD risk in patients with ACM exercise restriction, some medication – beta-blockers, amiodarone, sotalol (class I recommendations), flecainide) and ICD implantation (class I-IIa-IIb recommendations) are recommended [2].

Recurrent monomorphic VT, often of several morphologies (predominantly from sources in the right ventricle (RV), is the most common cause of sudden cardiac arrest (SCA). Defibrillation or cardioversion are the methods of choice for VF, polymorphic VT, and monomorphic VT with hemodynamic disturbance, respectively [3].

Treatment of monomorphic VT with preserved hemodynamics: Due to the limited amount of data, there are no specific recommendations for patients with ACM for the treatment of monomorphic VT with conserved hemodynamics (including the recommendations of ESC 2015 [2], HRS 2019 3 [3], 2020 Canadian Cardiovascular Society 2020 [4]). Accordingly, for the treatment of monomorphic VT in this category of patients, apart from electrical cardioversion, intravenous antiarrhythmic drugs are used including procainamide (1st line) and amiodarone or lidocaine (2nd line); in the case of an electric storm, beta-blockers (preferably non-selective) + amiodarone, according to the standard criteria and doses for the termination of VT, as in other patients with VT and structural heart diseases [2, 4].

Recommendations for the subsequent management of patients with coronary artery disease (CAD) and ACM and recurrent VT pa-

roxysms have undergone a number of changes over the past 10 years, including indications for VT ablation. In light of the existing trends in the development of VT ablation, it is logical to assume that the presence of episodes of monomorphic VT from the RVOT (an area with high success of catheter ablation of idiopathic VT as well as in patients with ACM) preventive endocardial catheter ablation (ECA) before ICD implantation in patients with ACM, or in the early period after ICD implantation (without waiting for repeated ICD discharges), could be recommended. However, there is insufficient data on the effectiveness of preventive ablation of VT before implantation in patients with ACM, and there are no randomized trials in this category of patients.

What's new in this article:

The proposed method of substrate mapping and ECA in combination with the application of an ablation line to the annulus of the pulmonary artery valve (PA) could be recommended as a first-line preventive treatment before ICD implantation in all patients with ACM with monomorphic VT with morphology typical for RVOT. The second stage (if necessary) could be combined endo- / epicardial approach (if required). After stage 1, the need for epicardial ablation for this category of patients with VT is rare in the mid-term follow-up period.

Problem

Patients with ACM are at high risk of cardiac death, incl. sudden arrhythmic cardiac death. ACM is the cause of SCD in 11% of all SCD cases in young people, and in 22% – SCD cases among athletes [5, 6].

Data from meta-analyses indicate that the annual rate of cardiac and non-cardiac mortality was 0.9% and 0.8%, and the annual rate of heart transplantation was 0.9% [7].

Patients with a history of syncope, paroxysms of sustained monomorphic VT with impaired hemodynamics, or resuscitated after an episode of SCA are at the highest risk of SCD (up to 10% per year); for them ICD implantation has a class 1 indication [7].

Unclear and controversial issues

Despite the fact that beta-blockers and sotalol are recommended 1st-line therapy (class 1C recommendations, [2], neither beta-blockers nor sotalol significantly reduced the number of VT paroxysms in one of the large registries in patients with ACM [8]. There are also limited data on the role of ECA in new-onset monomorphic VT with a single morphology in patients with ACM.

Most of the data on the role of ECA in the treatment of patients with monomorphic VT and the ability of ECA to reduce SCD in patients with ACM come from nonrandomized studies. Therefore, ICD implantation is the mainstay of treatment to reduce SCD in groups at high risk of SCD [9, 10, 11, 12].

Secondary prevention of SCD with ICD

Earlier in the 2015 ESC recommendations, ICD implantation was recommended for all patients with VT and ACM, regardless of the hemodynamic significance of VT (class I recommendations) [13].

Taking into account the accumulated amount of data on the benefit / risk ratio, ICD implantation currently has class IIA indications for the treatment of monomorphic VT with stable hemodynamics in ACM patients, according to the recommendations of HRS 2019 [3]. Such changes in recommendations reflect the ambiguity of the accumulated data on the effec-

tiveness / safety (i.e. benefit / risk) ratio of ICD implantation in this category of patients (ACM). The role of ECA of monomorphic VT in patients with ACM has significantly increased over the past 10 years with the maturation of mapping technologies. In particular, ECA of paroxysmal monomorphic VT is one of the most effective methods for preventing recurrent VT paroxysms and ICD shocks.

Primary prevention of SCD using ICD in patients with ACM

The role of ICD in patients with ACM with preserved LVEF in primary prevention of SCD is less clear, and evidence for primary prevention with ICD is also obtained from a small number of non-randomized trials [14, 15]. The lack of sufficient data on the benefits of ICD implantation as strategy of primary prevention of SCD in patients with ACM with preserved LVEF (> 35%) is reflected in the new recommendations for the treatment of ACM (HRS 2019 [3]), i.e. class IIA-IIb recommendations, see Table 1.

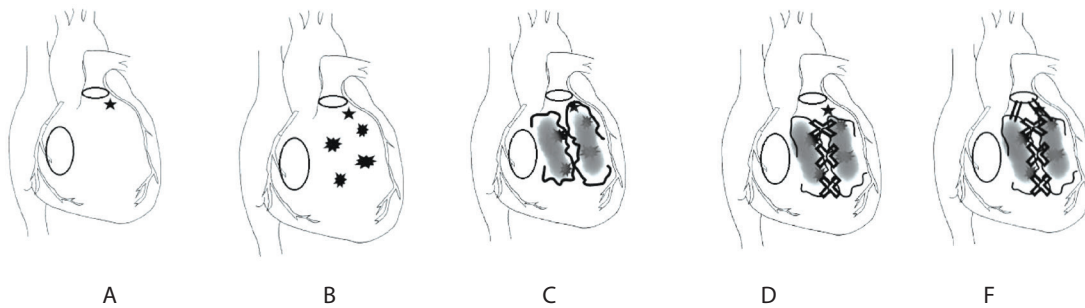
Recurrent ICD shocks reduce quality of life and increase hospitalization rate. Accordingly, catheter ablation of the VT is recommended for recurrent ICD shocks (recommendations ESC 2015, HRS 2019). The effectiveness of VT ablation in ACM is lower than in patients with monomorphic VT with CAD, which is in part caused by the presence of widespread arrhythmogenic substrate, often with the involvement of the epicardial layer of the RV / LV myocardium, and the presence of VT of several morphologies.

According to a prospective registry monomorphic VT is the main cause for appropriate ICD shocks in ACM patients [16]. The source of VT in such patients is usually localized in the RV, but in contrast to patients with idiopathic paroxysmal VT from RVOT, many patients with ACM have multiple VT (several morphologies of monomorphic VT, often with an epicardial location of the arrhythmogenic substrate) [17], see Figure 1.

Table 1. Indications for primary prevention of SCD using ICD in patients with ACM

	Class recommended	Level of evidence
Patients with ACM and LVEF > 35%		
ICD implantation is reasonable for patients with ACM and 3 major, 2 major and 2 minor, or 1 major and 4 minor risk factors of VA*.	Ia	B-NR
ICD implantation might be reasonable / considered for ACM-patients with 2 major, 1 major and 2 minor or 4 minor risk factors of VA*.	Ib	B-NR
Patients with ACM and LVEF ≤ 35%		
ICD implantation is recommended for ACM-patients with LVEF ≤ 35% and CHF symptoms of Class II-III according to NYHA and an expected survival of more than 1 year.	I	B-R
ICD implantation is reasonable for ACM-patients with LVEF ≤ 35% and CHF symptoms of Class I according to NYHA and an expected survival of more than 1 year.	Ia	B-R

Note: * Major criteria: unstable VT, inducibility of VT in intracardiac EPS, LVEF ≤ 49%. Minor criteria: male sex, > 1000 VES / 24 h, right ventricular dysfunction (according to the main criteria of the 2010 Working Group), proband status, two or more desmosomal variants. If there are also criteria for unstable VT and VES, in this case only the criterion of VT can be used; SCD – sudden cardiac death, ICD – implantable cardioverter-defibrillator, ACM – arrhythmogenic cardiomyopathy, LVEF – left ventricular ejection fraction, CHF – chronic heart failure, VA – ventricular arrhythmias, VT – ventricular tachycardia, VES – ventricular extrasystole, EPS – intracardiac electrophysiological study, NYHA – New York Heart Association classification of heart failure.



Note: VES – ventricular extrasystole, RVOT – right ventricular outflow tract, ACM – arrhythmogenic cardiomyopathy, VT – ventricular tachycardia, PA – pulmonary artery valve.

Rationale for choosing ECA as a 1st-line invasive strategy

ECA has demonstrated to have an acceptable success rate in patients with structural heart diseases (SHD). With the improvement of ECA techniques (the introduction of substrate mapping versus conventional activation mapping) and the expansion of approaches (endocardial, epicardial, or combined endo-epicardial), the incidence of VT recurrence and appropriate ICD-shocks after ablation has decreased. Complete long-term elimination of all VA after RFA by endocardial access could be achieved in about 1/3 of patients with ACM [18].

According to the literature, the intraoperative efficacy of ECA in ACM surpasses the efficacy of VT ablation in many other etiologies, including patients after myocarditis and non-ischemic DCM, especially when using a combined approach, including epicardial access. [19].

Some researchers believe that in patients with ACM with recurrent VT early ECA in experienced specialized centers is preferable to escalating drug therapy (including combination antiarrhythmic therapy) [9, 20].

In some patients, VT may recur over time and require repeated catheter ablation of VT, including epicardial ablation, due to the progression of the disease and localization of an arrhythmogenic substrate on the epicardial surface.

Difficulties in performing VT ablation in patients with ACM

Those are due to a number of factors:

1. The arrhythmogenic substrate in ACM is widespread, complex, often has three-dimensional structure, in contrast to idiopathic VT and PVCs, where the arrhythmogenic substrate usually has one limited focus, see Figure 1.

2. The existence of VT of several morphologies.

3. Localization of the arrhythmogenic substrate not only on the endocardial, but also on the epicardial surface of the ventricles, which requires ablation of VT from the epicardial approach in some patients, – see Figure 2.

4. The difficulty of performing standard activation mapping during continuing VT due to its high heart rate, hemodynamic instability and transformation into polymorphic VT and / or VF.

The propagation of the excitation wave in the RV myocardium occurs non-simultaneously, while the endo- and epicardial layers are (at least partly) electrically separated by the middle layer. The complete re-entry pathway can include both layers (through the “bridges” between the layers), but early in the onset of ACM could be localized within one of the layers.

The non-linear nature of the pulse propagation within and between the zones of fibrotic zones generates a fragmented potential, which reflects the propagation of the wave within isolated, protected channels of potential re-entry (see Figure 3).

This type of propagation of the activation wave can be observed not only during paroxysm of VT, but also in sinus rhythm, which makes it possible to map the VT substrate in patients with documented high-rate VT with hemodynamic compromise without need for VT induction for activation mapping. For some patients (including those with VT non-inducible during index EP-study), detection of such abnormal fragmented activity in sinus rhythm is the only way to identify and ablate the arrhythmogenic substrate (see Figure 4).

Rationale for the proposed ablation strategy

Thus, in many patients with ACM and paroxysmal VT in the area close to the RVOT, at least 2 potential re-entry circles can be expected.

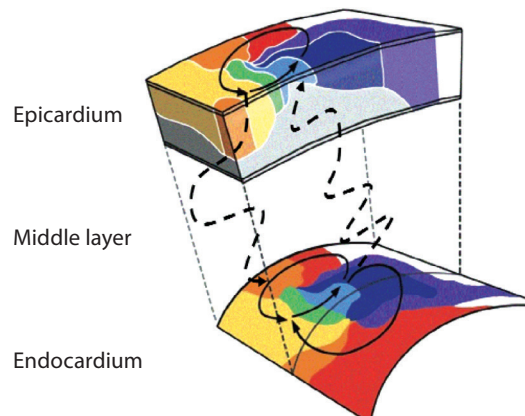
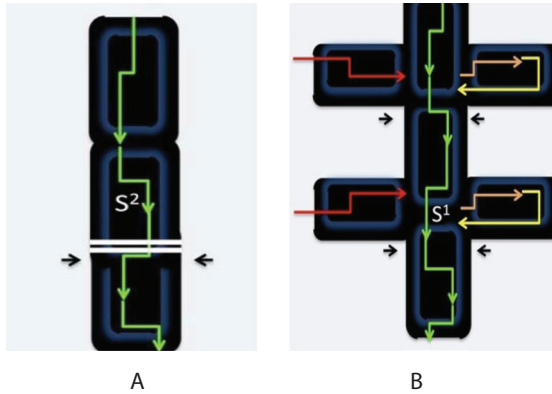
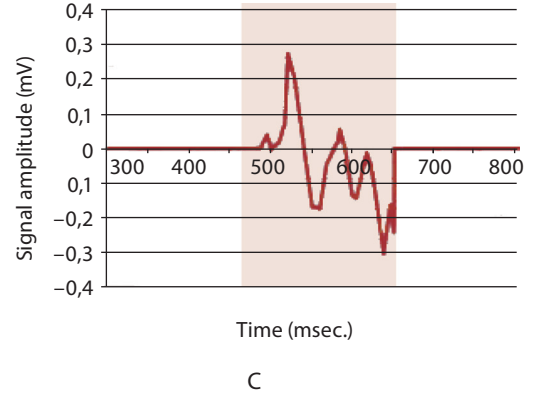


Figure 2. Propagation of the excitation wave along the epicardial and endocardial surfaces of the right ventricle occurs asynchronously. The endo- and epicardial layers are partially “isolated” electrically. Excitation in many zones does not occur simultaneously [21] with changes)

Figure 3. Propagation of the activation wave in the delayed conduction zone (A), through the zone of fibrous changes with numerous lateral "protected channels" (B), a fragmented (rapidly and repeatedly changing direction) signal is recorded at the tip of the mapping catheter



Note: mV – millivolts, msec. – milliseconds.



ted: 1-st re-entry canal(s) (often multiple), consisting of intact cardiomyocytes within zone and 2-nd re-entry channel between the PA valve (electrically non-conductive structure) and the zone of fibrosis / scar.

Since the arrhythmogenic substrate (areas of scar / fibrotic changes and VT re-entry channels) in ACM has a three-dimensional structure, it can be assumed that in a significant part of patients with a mixed arrhythmogenic substrate (both endo- and epicardial), substrate mapping and ablation throughout the area of these channels will be more effective than focal ablation of the early exit site of one clinically verified VT.

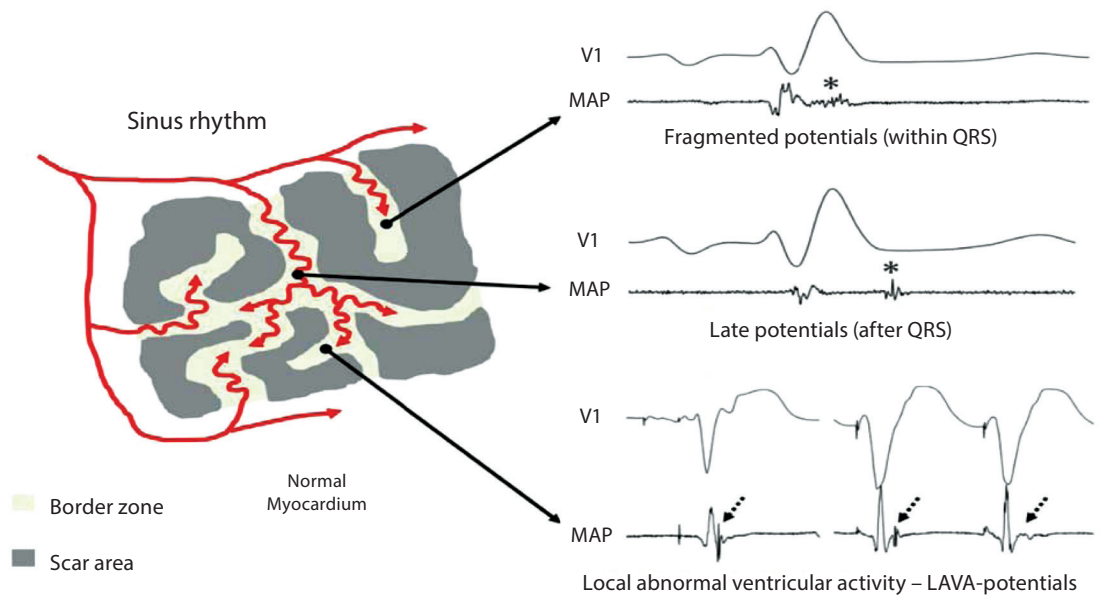
The hypothesis underlying the recommended approach

We have put forward a hypothesis that in some patients with ACM and documented VT, which has a morphology characteristic of RVOT, substrate mapping and ECA of the substrate in sinus rhythm in combination with an additional ablation line from the PA valve ring to the zone of the

documented arrhythmogenic substrate will be effective and sufficient in the prevention of recurrent paroxysms of monomorphic VT in patients with ACM. Prerequisites for this assumption are:

1. Monomorphic VT requires at least one fixed re-entry channel (i.e. zone between 2 electrically non-conductive structures (scars, etc.);
2. in patients with SHD such structures are most often 2 scars / areas of fibrosis, and / or an anatomical structure (valve ring, the place of entry of a large vessel etc.) and a scar area;
3. thus, a likely zone of vulnerable isthmus VT could be the area between the PA ring and the area of fibrosis, scar (caused by ACM) in the region of RVOT.
4. The thickness of the myocardium in the area of the RVOT (3–5 mm) will provide the possibility of applying transmural damage during ECA to that part of the vulnerable reentry loop, which is located endocardially.
5. Literature data on the efficacy of drawing an ablation line for VT arising after reconstructive heart surgery involving the RVOT (the line of ablation between the PA and the postopera-

Figure 4. The main types of abnormal ventricular activity of an arrhythmogenic substrate recorded during substrate mapping in sinus rhythm in patients with structural pathology



Note: LAVA – local abnormal ventricular activity

tive scar in the RVOT area in patients after correction of the congenital heart disease).

Thus, we have proposed to change the strategic endpoint of ablation:

1. The standard approach is to perform ECA based on activation mapping (VT earliest exit point) of the source of clinically documented VT, induced during intracardiac EPI.

2. We propose to change the strategic ultimate goal of ablation - not only ablation of the early exit site, but also extended ablation of the entire surface of the arrhythmogenic substrate (i.e., ablation of the maximum number of (multiple) potential re-entry channels in the area of fibrosis and fragmented signals in combination with application of an additional ablation line between the fibrosis / scar area and the 2nd non-conductive structure (valve ring; in this case, the PA valve)

It can be assumed, that:

1. Such ablation will lead to the elimination of those parts of the (multiple) reentry loops that have an endocardial part.

2. Combined ablation of an arrhythmogenic substrate (with ablation of the maximum number of identified potential channels for future VT) for the formation of new re-entry after the first ablation (see Figure 5).

Our experience suggests that this combined approach is effective, safe, and can be recommended as a first-line invasive therapy for VT from areas adjacent to the RVOT.

Materials and methods

We analyzed the results of ECA performed within the period from 2018 to 2021 (from the moment of introduction of substrate mapping/ablation in the Republican Scientific and Practical Center "Cardiology") in comparison with the results of VT ablation in patients with ACM during 2012–2017 (before the introduction of substrate ECA of VT in our Center).

During 2018–21 ECA of VT was performed in 7 patients with ACM, in whom an ICD was implanted before the ablation or immediately after VT ablation.

An intraoperative assessment of the effectiveness of activation mapping, substrate map-

ping, ECA using activation mapping, focal ablation (i.e. the earliest point of VT activation during activation mapping), substrate mapping, and substrate mapping with an additional ablation line to the PA ring was performed.

The inducibility of clinical VT, the total number of induced VT (the number VT of different morphologies), the effectiveness of ECA of clinical VT and all induced VTs intraoperatively and according to the results of ablation, and subsequently during long-term follow-up of patients with implanted ICD (according to the results of periodic programming within the period from 1 to 3 years).

The results of intracardiac EPI before and after ablation are presented in Table 1. As seen from the presented results, programmed ventricular stimulation (PVS) is the most effective way of induction of clinical VT (VT induced before ablation in 100% of cases) in comparison with frequent ventricular pacing, which allowed VT induction in only 57.1%.

In addition to clinical VT (documented before hospitalization, i.e. the reason for hospitalization of patients), PVS allowed the induction of VT with a different morphology in all 100% of patients with ACM (on average + 2 VT, which differed in the morphology of the QRS complex from clinical VT; maximum number = 3 "non-clinical VT").

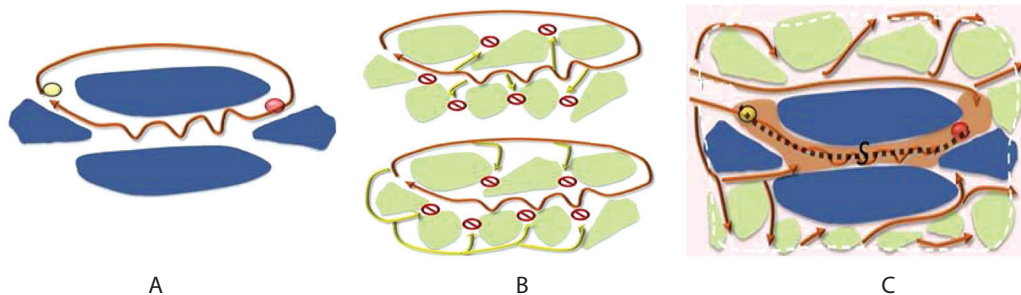
Catheter ablation of VT according to the proposed technique made it possible to reduce the number of induced VT during control PVS – both clinical VT and "non-clinical" VT.

Ablation protocol. Mapping was performed using the Carto 3 navigation system. For all VTs with stable hemodynamics (as well as in the presence of frequent monomorphic PVCs with the same morphology as clinical VT), activation mapping was performed, followed by substrate mapping in sinus rhythm.

VT ablation (power 30 W, temperature 38–42 °C, mean ablation time = 32 minutes [24–45 minutes]) was started from the earliest activation zone, identified during activation mapping.

Problems with this approach:

1. Only in 3 out of 7 patients the local PVCs / VT signal in the zone of early activation was ahead



A. Ventricular tachycardia (VT) with 1 channel re-entry within a dense scar (the place of the earliest exit from the zone of fibrosis is shown by the yellow dot).
 B. Propagation of the excitation wave of VT (often multiple) through the mixed area of viable cardiomyocytes and the area of nontransmural fibrosis with multiple channels (some of which dead-end), those being a substrate for the formation of fragmented activity associated with VT in this area.
 C. Propagation of a sinus rhythm impulse inside a dense scar and the mixed area of viable cardiomyocytes/area of nontransmural fibrosis. The central line shows the main protected re-entry channel. The lateral lines illustrate potential "non-main", often dead-end channels of delayed conduction, which are the substrate for the formation of fragmented activity in the sinus rhythm in this area (and possible alternative VT channels of re-entry) and the target of substrate ablation according to the proposed technique.

Figure 5. Differences between mono-re-entry in a patient with a "dense" transmural scar and a zone of multiple re-entry channels in the zone of "nontransmural" fibrosis

of the QRS complex by ≥ 30 msec., and the signal had a high-frequency pattern, and the zone was limited in size.

2. In 4 out of 7 patients with VT, the early activation zone was diffuse and had an early signal of a low-frequency pattern, and the local signal was in the range of 0–30 msec. before QRS of PVCs / VT. This indicates the localization of the source of PVC / VT outside the endocardial surface (intramural or epicardial location).

Accordingly, after focal ablation of VT at the site of the earliest activation, in 5 out of 7 patients, VT paroxysms continued to be induced. Thus, in patients with ACM, limited focal ablation of the earliest activation site has a low efficacy (only 28.6%).

After the 1st step of ablation (i.e. by activation mapping), we proceeded to substrate mapping and ablation of the substrate identified in the sinus rhythm. Zones of high-frequency and fragmented potentials in the RVOT area were identified in all 7 patients (100%). In addition, in 6 out of 7 patients diastolic potentials (early and late) were detected in the RVOT area, which were delayed in relation to the QRS complex in sinus rhythm by 20–90 msec. These were presumed as zones of delayed conduction, a potential substrate of identified VT.

Thus, the 2nd step of ECA was an extended ablation in the area of fragmented potentials, i.e. homogenization of the identified substrate (ablation with a power of 25–30 W, duration 15–45 minutes) over the entire area of the identified zones of fragmented potentials until they disappeared on control EPI (and repeated attempt of induction of VT).

3rd step of ablation – drawing the ablation line from the original ablation zone (homogenized substrate) to the PA ring.

After homogenization of the substrate (2nd step of ablation), clinical VT from RVOT continued to be induced in only 2 of 7 patients (the effectiveness of the approach in eliminating clinical VT = 71.4%). However, in 6 patients we could still continue to induce “non-clinical VT”) – 1–2 morphologies, in 2 patients VT with morphology similar to RVOT. After the 3-d step of ECA (line to the PA ring), only 1 of 7 patients VT with RVOT morphology could be induced, and the number of all induced VTs of all morphologies decreased to 0.71 per patient.

The result of the 3rd step of ablation was:

Impossibility of induction of clinical VT from RVOT in 6 out of 7 patients (the final intraoperative ablation efficiency is 85.7%). Non-inducibility of any VT – in 4 out of 7 patients (57.1%), a decrease in the total number of induced VT.

Long-term efficacy of catheter ablation of VT from VT-RV in patients with ACM

The long-term efficacy of ECA was assessed according to the protocols by ICD programming in patients during routine examinations (at least once / 6 months or more often, in the presence of ICD discharges / episodes of an electric storm) for 1–3 years.

Thus, during 1–3 years of follow-up, 71.4% of patients had no symptoms of VT / VF. Of 7 patients, 4 had non-sustained VT (4 patients) and sustained VT (1 patient) in the zone of the ICD monitor, which did not require ICD shocks and ATP therapy. ICD discharges were observed in 2 patients; 3 patients had paroxysms of VT, terminated by ATP therapy. None of the patients had episodes of electrical storms (see Table 3).

Discussion

The ECA effectiveness of monomorphic VT in patients with coronary artery disease has improved over the past 20 years, which is accompanied by a significant decrease in the number of appropriate ICD shocks from 30–31% to 9–10% [22]. Therefore, in order to prevent recurrent VT paroxysms and episodes of electrical storms, ECA is recommended as a first-line invasive therapy for patients with CAD and previously verified monomorphic VT.

The results of ablation of the 7 patients described above were compared with a cohort of patients with ACM, who underwent VT ablation using only activation mapping during the period 2010–2018. During this period, we operated on 6 patients with ACM. The indications for ECA were recurrent shocks of the previously implanted ICD. ECA using exclusively activation mapping and focal ablation of the earliest activation site reduced the number of shocks, but was effective in only 2 of 6 patients after

Table 2.
The effectiveness of ECA based on the results of intraoperative programmed stimulation*

	Inducibility of VT with frequent stimulation		Inducibility of clinical VT with programmed stimulation		Inducibility of other VT with programmed stimulation			
	Before	After ablation	Before	After ablation	Before		After ablation	
					All VTs	Nonclinical VTs	All VTs	Nonclinical VTs
Patient 1	1 VT	0	Yes	No	2	1	0	0
Patient 2	2 VT	0	Yes	No	2	1	0	0
Patient 3	1 VT	1 VT	Yes	No	4	3	1	1
Patient 4	0	0	Yes	Yes	1	0	0	0
Patient 5	0	0	Yes	No	1	0	0	0
Patient 6**	1 VT	1 VT	Yes	Yes	2	1	1	0
Patient 7	0	0	Yes	No	3	2	1	1

Note: * All 7 patients showed confirmed clinically stable or unstable VT from RVOT or frequent VES from RVOT, and the diagnosis of ACM verified using MRI and generally accepted criteria for ACM; ** Patient No.6 manifested continued inducement of VT after ECA procedure; VES – ventricular extrasystole, RVOT – right ventricular outflow tract, ACM – arrhythmogenic cardiomyopathy, VT – ventricular tachycardia, MRI – magnetic resonance imaging, ECA – endocardial catheter ablation.

the 1st ablation procedure (33.3%). The remaining 4 patients (66.7%) had recurrent ICD shocks, requiring repeated hospitalization and ECA: in 2 patients + 1 additional ECA, in 1 patient – 2 additional ECA, and in 1 patient + 3 additional ECA. In the last patient, the total number of VT ablation was 4 operations, which nevertheless did not lead to the elimination of VT paroxysms in this patient.

Thus, it can be concluded that substrate mapping and ECA of an arrhythmogenic substrate detected at sinus rhythm in patients with ACM is an effective, safe method in addition to standard activation mapping.

When using ECA of monomorphic stable VT with morphology corresponding to RVOT according to the proposed method (i.e. a combination of activation mapping in the presence of VT with preserved hemodynamics, with substrate mapping and ablation at sinus rhythm, and supplemented by an additional ablation line to the PA ring is much more effective in the elimination of recurrent paroxysms of VT (ICD discharges) than standard activation mapping and focal ablation in the zone of earliest activation.

The disadvantage of endocardial activation mapping of VT in patients with ACM is the frequent localization of the substrate on the epicardial surface of the RV. This is confirmed by the results of endocardial mapping: in all 4 patients in whom VT could not be eliminated according to the results of activation mapping, the zones of the earliest activation had a diffuse character, the signal at the site of the earliest activation had a low-frequency pattern (far-field signal), and a high-frequency signal in the site of early activation was only 0-10 msec. before QRS of clinical VT (or PVCs of the same morphology), which are the criteria for the epicardial localization of the VT origin.

While comparing the standard approach (only activation mapping) with the approach of substrate ablation and additional line to PA, the later strategy of ECA not only eliminate of the earliest VT's exit point, but also ablates the part of the re-entry loop, located on the endocardial surface.

Thus, ECA of an arrhythmogenic substrate in sinus rhythm (zones of abnormal LAVA potentials) can interrupt the re-entry loop in a significant proportion of patients in whom a part of the re-entry loop is located on the epicardial surface of the RV. This method is recommended by us as a 1st-line invasive therapy for patients with ACM and sustained monomorphic VT presumed from RVOT origin. If it is impossible to localize the arrhythmic substrate on the endocardial

surface and paroxysms of hemodynamically unstable VT persist, it is advisable to consider epicardial mapping and ablation.

In our opinion, the main reason for the high efficacy of ablation using the proposed technique in comparison with the standard approach (isolated activation mapping) is the following factors:

1. While performing substrate ablation of VT and adding a line to the PA ring, ablation is destroyed not only of the exit point of one clinically documented VT, but also a part(s) of the VT reentry loop(s) located partially on the endocardial surface (there may be several alternative potential reentry pathways, currently undocumented) or future VT.

2. The thickness of myocardium in the region of RVOT is up to 3–5 mm.

3. The proximity of the location of the arrhythmogenic focus to the PA valve (1.5–3.5 cm) makes it possible to apply a continuous, complete line of ablation.

Taking into account the progressive nature of the disease (ACM), the main question remains: “How long can the positive effect achieved after VT ablation in patients with ACM remains, i.e. non-inducibility of VT and the absence of recurrent VT paroxysms and ICD discharges during long-term follow-up?”

The most encouraging are the results of the two studies assessing the progression of VT substrate in ACM with the time. In both studies, substrate progression was assessed by repeated invasive endocardial myocardial mapping following previous VT ablation. In the first study, scar progression was observed in 2 of 11 patients (18.2%) during a median follow-up of about 6 years [23]. In the 2nd study – in 2 of 7 patients (28.6%) within 30 months of observation, and the source of recurrent VT was localized within the previously identified scar, which indicates incomplete elimination of the arrhythmogenic VT substrate during the initial ablation procedure [24].

This result allows us to hope for a low risk of VT recurrence in our patients with ACM when using an proposed integrated approach: substrate mapping and ablation in combination with activation mapping and adding an ablation line from the scar zone to the PA valve, resulting in non-inducibility of VT on control EPI.

In some patients with ACM, epicardial mapping has to be performed. However, according to our experience, if VT in patients with ACM has a typical pattern of RVOT (and such patients make up the majority among ACM) [25], then less invasive ECA approach with substrate

	Number of ICD shocks	Number of VT paroxysms terminated by ATP	Number of VT paroxysms in the range of VT monitor (HR < 150 bpm)	Number of any symptomatic VT/VF paroxysms
Patient 1	0	0	1	0
Patient 2	0	0	0	0
Patient 3	1 (2 shocks)	1 (4 ATP)	1 (11 paroxysms in ICD monitor)	yes
Patient 4	0	0	0	0
Patient 5	0	1	yes (2 episodes)	no
Patient 6	1 (shock)	yes (2 ATP)	yes (5 episodes)	yes
Patient 7	0	0	0	0

Note: RFA – radiofrequency ablation, ATP – antitachycardic pacing, ICD – implantable cardioverter defibrillator, VT – ventricular tachycardia, VF – ventricular fibrillation, HR – heart rate.

Table 3. Long-term ECA efficacy of VT based on the results of ICD programming and 24-hour ECG monitoring.

mapping and ECA according to the proposed technique is more preferred. At the time of this writing, none of the 7 operated patients with ACM required epicardial ablation. The use of this approach allows to reduce the number of patients with an implanted ICD for specialized care, the number of hospitalizations and health care costs by monitoring the parameters of the ICD using remote monitoring and counseling [26].

Conclusion:

1. ECA is a highly effective treatment for monomorphic VT in patients with ACM.
2. The use of the proposed combined approach increases the intraoperative efficacy of ECA (assessed by no-inducibility of VT using control intracardiac EPI after ECA).
3. The risk of repeated ICD shocks and electrical storm episodes after ablation is significantly lower than with an activation mapping approach.
4. The use of the combined approach is safe: there were no complications during the operation using this technique.
5. The question of whether it is possible to postpone ICD implantation after successful VT ablation using this combined approach in some high-risk patients with VT and ACM (for example, for patients who refuse ICD implantation, or when ICD implantation for technical reasons is not possible) – requires further study and long-term follow-up.

REFERENCES

1. Vaikhanskaya T.G. 1, Sivitskaya L.N. 2, Kurushko T.V. 1, Rusak T.V. 1, Levandisky O.D. 2, Danilenko N.G. 2, Davydenko O.G. 2 Change of concept arrhythmogenic cardiomyopathy: expansion of the clinical and genetic spectrum, new criteria for the diagnosis of left ventricular phenotypes. (<https://russjcardiol.elpub.ru> ISSN 1560-4071 (print) doi: 10.15829/1560-4071-2020-3863). Russian Journal of Cardiology 2020; 25 (10).
2. Priori S.G. et al. 2015 ESC Guidelines for the management of patients with ventricular arrhythmias and the prevention of sudden cardiac death. The Task Force for the Management of Patients with Ventricular Arrhythmias and the Prevention of Sudden Cardiac Death of the European Society of Cardiology (ESC) Endorsed by: Association for European Paediatric and Congenital Cardiology (AEPC). // *European Heart Journal* (2015) 36, 2793–2867
3. Towbin J.A. et al. 2019 HRS expert consensus statement on evaluation, risk stratification, and management of arrhythmogenic cardiomyopathy. // *Heart Rhythm*, Vol 16, No 11, November 2019, E301–372.
4. Deyell M.W. et al. 2020 Canadian Cardiovascular Society/Canadian Heart Rhythm Society Position Statement on the Management of Ventricular Tachycardia and Fibrillation in Patients With Structural Heart Disease. Society Position Statement. // *Canadian Journal of Cardiology* 2020, V. 36, p. E822–836.
5. Corrado D, Basso C, Schiavon M, Thiene G. Screening for hypertrophic cardiomyopathy in young athletes. // *NEJM*. 1998 Aug 6. 339(6):364–9.
6. Tabib A, Loire R, Chalabreysse L, et al. Circumstances of death and gross and microscopic observations in a series of 200 cases of sudden death associated with arrhythmogenic right ventricular cardiomyopathy and/or dysplasia. // *Circulation*. 2003 Dec 16. 108(24), p. 3000–5.
7. Schinkel AF. Implantable cardioverter defibrillators in arrhythmogenic right ventricular dysplasia/cardiomyopathy: patient outcomes, incidence of appropriate and inappropriate interventions, and complications. // *Circ Arrhythm Electrophysiol* 2013;6 p. 562–568.
8. Marcus GM, Glidden DV, Polonsky B, et al. Multidisciplinary Study of Right Ventricular Dysplasia Investigators. Efficacy of antiarrhythmic drugs in arrhythmogenic right ventricular cardiomyopathy: a report from the North American ARVC Registry. // *J Am Coll Cardiol* 2009;54, p. 609–615.
9. Orgeron GM, James CA, Te Riele A, et al. Implantable cardioverter-defibrillator therapy in arrhythmogenic right ventricular dysplasia/cardiomyopathy: predictors of appropriate therapy, outcomes, and complications. // *J Am Heart Assoc* 2017;6, p. 006242.
10. Link MS, Laidlaw D, Polonsky B, et al. Ventricular arrhythmias in the North American multidisciplinary study of ARVC: predictors, characteristics, and treatment. // *J Am Coll Cardiol* 2014;64, p. 119–125.
11. Corrado D, Leoni L, Link MS, et al. Implantable cardioverter-defibrillator therapy for prevention of sudden death in patients with arrhythmogenic right ventricular cardiomyopathy/dysplasia. *Circulation* 2003;108, p. 3084–3091.
12. Corrado D, Calkins H, Link MS, et al. Prophylactic implantable defibrillator in patients with arrhythmogenic right ventricular cardiomyopathy/dysplasia and no prior ventricular fibrillation or sustained ventricular tachycardia. // *Circulation* 2010;122, p. 1144–1152.
13. Corrado D, Wichter T, Link MS, et al. Treatment of Arrhythmogenic Right Ventricular Cardiomyopathy/Dysplasia: An International Task Force Consensus Statement. // *Circulation* 2015;132, p. 441–53.
14. Køber L, Thune JJ, Nielsen JC, et al. Defibrillator Implantation in Patients with Nonischemic Systolic Heart Failure. // *N Engl J Med* 2016;375:1221–30.
15. Zipse MM, Tzou WS. Sudden cardiac death in nonischemic cardiomyopathy: Refining risk assessment. // *J Cardiovasc Electrophysiol* 2017;286 p. 1361–6.
16. Link MS, Laidlaw D, Polonsky B, Zareba W, McNitt S, Gear K, Marcus F, Estes NA 3rd. Ventricular arrhythmias in the North American multidisciplinary study of ARVC: predictors, characteristics, and treatment. // *J Am Coll Cardiol* 2014;64, p. 119–125.
17. Hoffmayer KS, Machado ON, Marcus GM, Yang Y, Johnson CJ, Ermakov S, Vittinghoff E, Pandurangi U, Calkins H, Cannom D, Gear KC, Tichnell C, Park Y, Zareba W, Marcus FJ, Scheinman MM. Electrocardiographic comparison of ventricular arrhythmias in patients with arrhythmogenic right ventricular cardiomyopathy and right ventricular outflow tract tachycardia. // *J Am Coll Cardiol* 2011;58, p. 831–838.
18. Santangeli P, Zado ES, Supple GE, et al. Long-term outcome with catheter ablation of ventricular tachycardia in patients with arrhythmogenic right ventricular cardiomyopathy. // *Circ Arrhythm Electrophysiol* 2015;8, p. 1413–1421.
19. Jiang H, Zhang X, Yang Q, et al. Catheter ablation for ventricular tachycardia in patients with arrhythmogenic right ventricular dysplasia/cardiomyopathy: a systematic review and meta-analysis. // *Acta Cardiol* 2016;71, p. 639–649.
20. Cronin E.M. et al. Catheter Ablation of Ventricular Arrhythmias – 2019 HRS/EHRA/APHSR/LAHS expert consensus statement on catheter ablation of ventricular arrhythmias. // *Heart Rhythm*, Vol 17, No 1, January 2020, p. E1–E154.
21. Tung R et al. Simultaneous Endocardial and Epicardial Delineation of 3D Reentrant Ventricular Tachycardia. // *Journal of the American College of Cardiology - Volume 75, Issue 8, 3 March 2020, p. 884–897*(<https://doi.org/10.1016/j.jacc.2019.12.044>).
22. Reddy VY, Reynolds MR, Neuzil P, Richardson AW, Taborsky M, Jongnarangsin K, et al. Prophylactic catheter ablation for the prevention of defibrillator therapy. *N Engl J Med*. 2007;357, p. 2657–65. <https://doi.org/10.1056/NEJMoa0654571>.
23. Riley MP, Zado E, Bala R, et al. Lack of uniform progression of endocardial scar in patients with arrhythmogenic right ventricular dysplasia/cardiomyopathy and ventricular tachycardia. *Circ Arrhythm Electrophysiol*, 2010; 3, p. 332–338.
24. Berte B, Sacher F, Venlet J, et al. VT Recurrence after ablation: incomplete ablation or disease progression? A multicentric European study. // *J Cardiovasc Electrophysiol* 2016;27, p. 80–87.
25. Garcia FC, Bazan V, Zado ES, Ren JF, Marchlinski FE. Epicardial substrate and outcome with epicardial ablation of ventricular tachycardia in arrhythmogenic right ventricular cardiomyopathy/dysplasia. // *Circulation* 2009; 120, p. 366–375.
26. Zudin A.B. Praktika primeneniya distantsionnogo obsluzhivaniya pacientov v ramkah servisa telemeditsiny [The practice of using remote patient care within the telemedicine service]. *Vestnik Avicenny*, 2020, vol. 22, no. 4, pp. 553–557. (In Russian).

Conflicts of Interest, Relationships and Activities:

All authors declare that there is no potential conflict of interest on the topic of this study and do not require disclosure in this article.

Acknowledgments: The group of authors expresses gratitude to all employees of the Republican Scientific and Practical Center “Cardiology” who contributed to the selection, diagnosis, treatment and follow-up of patients with ACM.

Поступила 01.09.2021