

PHYSICAL EXAMINATION METHODS

Workbook

Surname, name _____

Group № _____

Minsk BSMU 2023

МИНИСТЕРСТВО ЗДРАВООХРАНЕНИЯ РЕСПУБЛИКИ БЕЛАРУСЬ
БЕЛОРУССКИЙ ГОСУДАРСТВЕННЫЙ МЕДИЦИНСКИЙ УНИВЕРСИТЕТ
КАФЕДРА ПРОПЕДВТИКИ ВНУТРЕННИХ БОЛЕЗНЕЙ

ФИЗИКАЛЬНЫЕ МЕТОДЫ ИССЛЕДОВАНИЯ

PHYSICAL EXAMINATION METHODS

Практикум

2-е издание, исправленное и дополненное



Минск БГМУ 2023

УДК 616-073(076.5)(075.8)-054.6

ББК 54.1я73

Ф48

Рекомендовано Научно-методическим советом университета в качестве практикума 27.06.2023 г., протокол № 6

А в т о р ы: Э. А. Доценко, М. Н. Антонович, Г. М. Хвощевская, И. И. Бураков, М. В. Шолкова, Е. О. Полякова, Т. П. Новикова, А. Г. Захарова, Ю. В. Репина

Р е ц е н з е н т ы: канд. мед. наук, доц. каф. терапии Белорусской медицинской академии последиplomного образования И. И. Семененков; 1-я каф. внутренних болезней Белорусского государственного медицинского университета

Физикальные методы исследования = Physical examination methods : практи-
Ф48 кум / Э. А. Доценко [и др.]. – 2-е изд., испр. и доп. – Минск : БГМУ, 2023. – 116 с.

ISBN 978-985-21-1375-5.

Содержит краткое описание, пошаговую технику исполнения наиболее диагностически значимых методов физикального исследования пациентов. Первое издание вышло в 2021 году.

Предназначен для студентов 2–6-го курсов медицинского факультета иностранных учащихся, обучающихся на английском языке.

УДК 616-073(076.5)(075.8)-054.6

ББК 54.1я73

Учебное издание

Доценко Эдуард Анатольевич
Антонович Мария Николаевна
Хвощевская Галина Михайловна и др.

ФИЗИКАЛЬНЫЕ МЕТОДЫ ИССЛЕДОВАНИЯ

PHYSICAL EXAMINATION METHODS

Практикум

На английском языке

2-е издание, исправленное и дополненное

Ответственный за выпуск Э. А. Доценко
Переводчик А. Г. Захарова
Компьютерная вёрстка Н. М. Федорцовой

Подписано в печать 07.08.23. Формат 60×84/16. Бумага писчая «Снегурочка».

Ризография. Гарнитура «Times».

Усл. печ. л. 6,74. Уч.-изд. л. 6,2. Тираж 235 экз. Заказ 432.

Издатель и полиграфическое исполнение: учреждение образования
«Белорусский государственный медицинский университет».

Свидетельство о государственной регистрации издателя, изготовителя,
распространителя печатных изданий № 1/187 от 18.02.2014.

Ул. Ленинградская, 6, 220006, Минск.

ISBN 978-985-21-1375-5

© УО «Белорусский государственный
медицинский университет», 2023

INTRODUCTION

Qui pillars bene diagnoscit — bene curat.

At all times, the physical examination of the patient was the basis for the diagnosis of diseases. With the development of laboratory and instrumental methods, the diagnostic paradigm has changed: if 100–200 years ago, apart from physical methods (questioning, examination, palpation, percussion, auscultation), the doctor had nothing at his disposal and the diagnosis of the disease was made on the basis of physical findings, today, in most cases, the results of physical examination allow us to formulate a diagnostic hypothesis, and then a preliminary diagnosis, which must be confirmed or refuted by laboratory and instrumental studies.

At the same time, each of the practicing doctors knows that there are often situations when we do not have any technical devices at hand and are forced to focus on our own skills when making a diagnosis.

On the other hand, there are diagnoses that do not require laboratory and instrumental verification in principle. Even in such a high-tech country as the United States, in recent years, there has been a clear trend towards increasing the role of physical examination in the diagnostic process, which actually means rethinking the place and role of physical methods in the diagnostic process and significantly reducing the economic component of the diagnostic process. Obviously, this applies primarily to physicians and general practitioners.

Do we need and to what extent additional (laboratory and instrumental) methods for acute respiratory viral infection? To diagnose tonsillitis, it is enough to examine the palatine tonsils and detect the enlarged submandibular lymph nodes. There are many similar examples.

There are several aspects here. First, we must trust what we have found in patients. If we heard moist rales over the lungs, we must be sure that they are the very ones; if we have found an increase in the size of the liver according to Kurlov on percussion — we must be sure that this is the case. And for this purpose, it is necessary to know the correct technique of examination (often, only the wrong location of the pleximeter finger on the chest leads to sound distortion and loss of information during comparative percussion). The second practical aspect of physical examination is the ability to interpret your findings: it is not enough to hear a systolic murmur at the apex of the heart, you need to understand the mechanisms of its formation in order to understand the causes for its formation. And here it is very appropriate to quote the statement of the outstanding cardiologist of our time, Professor E. Braunwald, the author of the most popular textbook on cardiology Braunwald's Heart Disease, the first edition of which was published in 1980, said: "the skill of physical diagnostics are not only the work of hands, but also to a greater extent the work of thought".

Finally, the third aspect of the physical examination is the diagnostic significance (value) of the revealed signs during the physical examination of the patient. An example from everyday life: we choose our shoes. The first “symptom” is shoes are “beautiful–ugly”. The second “symptom” is “comfortable–uncomfortable”. What is more important? What is the “diagnostic value” of these symptoms? I think it is obvious that the positive symptom “comfortable” is more likely to make us buy shoes than the symptom “beautiful”. Well, it is true that some people sacrifice comfort for beauty.

Similarly, each physical symptom, each physical finding has its own diagnostic value. It can be presented as the frequency of occurrence of a symptom in a specific pathology, for example, pneumonia (more precisely, you should take into account the frequency of occurrence of a symptom in pneumonia and other diseases similar to pneumonia; such calculations are made by science, called Evidence-Based Medicine. For example, shortness of breath occurs in thromboembolism in 50 % of cases, pleuritic chest pain in PE — 39 %. In acute cholecystitis, tension in the upper right quadrant of the abdomen with superficial palpation occurs in 77 % of patients, a positive Murphy’s symptom — in 65 % of cases. There are many similar examples; the diagnostic value of signs is the basis for the formation of diagnostic and prognostic scales, such as, for example, the risk scale of death from cardiovascular diseases, the Well’s scale — the risk of developing pulmonary embolism, etc. It should be remembered that symptoms with 100 % diagnostic value are extremely rare. English-language textbooks must include information on the diagnostic value of symptoms in various diseases (for example, the textbook edited by A. Leung and R. Padwal *Approach to Internal Medicine. A Resource Book for Clinical Practice*, 2011).

Objective examination of the patient is based on 4 “pillars”: inspection, palpation, percussion, auscultation. It has always been that way. And in 2018 one of the most prestigious journals in the world, JAMA (Journal American Medical Association), published an interesting article by American doctors J. Narula, Y. Chandrashekhar, E. Braunwald titled “Time to Add a Fifth Pillar to Bedside Physical Examination Inspection, Palpation, Percussion, Auscultation, and Insonation”, *JAMACardiol.* doi: 10.1001/jamacardio. 2018. 0001, which can be translated as “It’s time to add a fifth pillar to the patient’s physical examination: inspection, palpation, percussion, auscultation, and ultrasound”. In other words, the 5th pillar of the patient’s physical examination is a bedside examination using a pocket ultrasound sensor. Obviously, we will not have this today and not even tomorrow, but taking into account the rapid progress I want to believe that the time is not far away when there will be not only a pulse oximeter but also a portable ultrasonic sensor in the pockets of a medical gown (by the way, in some American medical schools they are already given to students along with the stethoscopes).

This manual presents specific techniques for examining a patient. We have pursued several goals when preparing it. First, to teach students a uniform

technique for conducting critical examinations. There are dozens, if not hundreds of books on propaedeutics of internal diseases, the descriptions of methods of physical examination are different, sometimes slightly, and sometimes significantly. Our teaching experience shows that it is difficult for a student who does not have his own clinical experience to choose the best method independently. A detailed description of a particular survey technique presented in this manual will help to unify them. When a young doctor acquires his clinical experience, he will be able to introduce certain modifications himself.

Secondly, the ground for conflict situations in exams disappears. Any teacher of propaedeutic disciplines can give many examples when a student responds to a remark about the incorrect technique of performing a practical skill: “And we were shown this way” or “And in such and such a book it is described this way”. We tried to divide each technique into the smallest steps and put them into so-called “checklist” (scorecard). Scorecards are used all over the world in the framework of the objective structured clinical exam; in fact, the checklist eliminates the subjective factor of the teacher as much as possible.

And finally, third, we selected the clinical skills that have the highest diagnostic value, in other words, practical skills that no one practitioner can work without.

The technique of performing the skills is summarized in checklists, which are a detailed description of the doctor’s actions. The use of scorecard in the process of teaching practical skills of physical examination is the first experience in Belarus, so there may be some shortcomings that will be corrected in future editions.

Physical examination methods:

1. Inspection of the skin and subcutaneous tissues.
2. Inspection and palpation of the lymph nodes of the head and neck.
3. Inspection and palpation of supra-, subclavian and axillary lymph nodes.
4. Inspection and palpation of inguinal and popliteal lymph nodes.
5. Inspection and palpation of the thyroid gland.
6. Chest shape estimation (inspection and palpation).
7. Palpation of the chest pain points.
8. Comparative percussion of the lung.
9. Assessment the inferior lung border.
10. Auscultation of the lungs.
11. Assessment the pulse on the radial, carotid arteries and dorsalis pedis arteries.
12. Palpation of the apical impulse.
13. Assessment of the relative heart dullness borders.
14. Auscultation of the heart.
15. Superficial palpation of the abdomen.
16. Palpation of the sigmoid colon.
17. Palpation of the cecum.

18. Palpation of the transverse colon.
19. Assessment of the liver size according to M. G. Kurlov's method.
20. Palpation of the liver.
21. Palpation of the kidneys in the horizontal position.
22. Palpation of the kidneys in the vertical position.
23. Palpation of the ureteral points, assessment of the kidney tenderness, auscultation of the renal arteries.
24. Palpation of the spleen.

GENERAL RULES AND PRINCIPLES OF OBJECTIVE EXAMINATION OF THE PATIENT

Physical examination of a patient consists of several consecutive stages (steps): 1) subjective, which includes evaluating the patient's perceptions of their illness; 2) objective — what the doctor finds; 3) additional, including laboratory and instrumental methods.

<p>1 Step. Subjective examination of the patient</p> <p>Passport data</p> <p>Complaints</p> <p>The history of the present illness (anamnesis morbi)</p> <p>The history of life (anamnesis vitae)</p>
<p>Step 2. Objective examination of the patient</p> <p>General examination, examination of body parts</p> <p>Examination of the respiratory system (inspection, palpation, percussion, auscultation)</p> <p>Examination of the cardiovascular system (inspection, palpation, percussion, auscultation)</p> <p>Examination of the digestive system (inspection, palpation, percussion, auscultation)</p> <p>Examination of the urinary organs (inspection, palpation, percussion, auscultation)</p> <p>Examination of the hematopoietic system (inspection, palpation, percussion, auscultation)</p> <p>Examination of the endocrine system (inspection, palpation, percussion, auscultation)</p> <p>Examination of the musculoskeletal system</p>
<p>Formulation of the diagnostic hypothesis (preliminary diagnosis)</p>
<p>Step 3. Additional methods (laboratory and instrumental methods)</p> <p>Laboratory methods — complete blood count, biochemical blood analysis, urinalysis, blood test for hormones, etc.</p> <p>Instrumental methods — electrocardiography, chest X-ray, ultrasonography, radioisotope method, magnetic resonance imaging, computed tomography, etc.</p>
<p>Formulation of the final clinical diagnosis</p>

Objective examination of the patient is based on 4 “pillars”: inspection, palpation, percussion, auscultation.

When we start an objective examination of a patient, we must have an appropriate appearance. It should be remembered that the patient's first impression of the doctor is the strongest. It is only in the movies that geniuses (like Dr. House) can afford to come in their outer clothing, sloppy, make a diagnosis, prescribe treatment, and leave. In real clinical practice, everything is more complicated.

Requirements for students at the Department of Propaedeutics of Internal Diseases of BSMU include:

I. Appearance of the student.

1. Indoor footwear that can be disinfected if it gets dirty with biological fluids (leather or rubber). Sneakers are not allowed.

2. A gown below the level of the knee joint or a surgical suit.

3. A white gown must be buttoned.

4. Hair must be under a medical cap.

5. Nails in length have not to be longer the pulp of the fingers.

6. Colorless nail polish is allowed.

II. The student must have.

- a centimeter tape;
- a stethoscope;
- a dermatograph or marker for the skin;
- a disposable mask;
- disposable gloves;
- light source (a pocket flashlight);
- wet alcohol wipes for hand hygiene;
- stopwatch or watch with a second hand;

When conducting an objective examination of a patient, certain requirements must be followed. The conditions in which the examination is performed should not aggravate the patient's suffering. The room where the examination is performed (doctor's office, ward) should be warm, without drafts, with natural light and isolation from possible external noise. The presence of strangers (other patients or relatives) is allowed only in certain cases (the patient is unconscious, the development of life-threatening conditions, etc.). The couch (bed) on which the patient is located and examined is covered with a clean white sheet. It should be flat, not too soft, with a low headboard, so that the patient does not feel uncomfortable during the examination. The results of the examination should be as complete as possible. A medical professional (doctor) conducts the examination in a clean, ironed white coat and cap. The hands of the researcher (doctor, medical professional) should be warm, clean, dry, with short-trimmed nails, without abrasions and pustules. Wash your hands with soap and water immediately before and after the examination. Latex gloves should be used when examining the patient. Before the examination, you should not use cologne, perfume or deodorant, eat acutely smelling food (onion, garlic), smoke, etc.

Inspection (inspectio). The inspection is begun with the so-called “general examination” (inspectio), which includes determining the level of consciousness, the position of the patient’s body, constitution, nutrition (degree of fatness), the condition of the skin, mucous membranes, hair and nails. In addition, this section includes the measurement of vital signs (temperature, heart rate, blood pressure, respiratory rate). You should pay attention to the patient’s speech (it reflects the level of intellectual development of the patient, possible disturbances of higher nervous activity), the state of the sensory organs (vision and hearing). During the examination, the patient’s clothes are evaluated (neat, clean or not), the presence of a specific smell (characterizes the level of personal hygiene and the presence of problems with urination — urinary incontinence).

To obtain reliable information during a general examination, the patient must be completely undressed (however, in some cases, sequential exposure of body parts is allowed). Therefore, there should be no unauthorized persons in the room. In some cases, the place of examination of the patient should be screened off. The air temperature should be 18–22 °C, so that the patient does not have any discomfort during the examination by a medical professional. The lighting should be sufficient, preferably natural. When using artificial light, you should use daylight lamps, since incandescent lamps can give the skin a jaundiced hue. The patient should be examined both in direct light (for example, with his face or back to the light source) and in side light (ask the patient to turn sideways), since some signs, such as changes in the configuration of a body part or pulsation of blood vessels, can only be clearly recognized in side light. The general examination and the chest examination should preferably be carried out in the patient’s vertical position, and the abdominal examination should be performed both in vertical and horizontal positions, since the configuration of the abdomen can change significantly when the body position changes.

Next, a study of organs and systems is carried out, sequentially studying the state of the respiratory system, cardiovascular system, abdominal organs and genitourinary system.

The first stage of such an examination is a “local examination”, in the process they examine those areas of the body that we are examining. For example, when examining the respiratory system, we examine the chest, when examining the digestive system—the stomach, etc. Experienced specialists include “local inspection” in the “general inspection” procedure, but while the researcher has minimal experience, in order not to miss important details, it is advisable to carry out an additional “local inspection”.

Palpation (palpatio) is the next stage after a local examination, in which, on the basis of the sensations obtained when feeling tissues and organs, we make a conclusion about their physical properties, relative position and individual functions (peristalsis, pulsation, etc.), and identify painful points, tumors and other pathological formations on the skin. Palpation is a physical method of

examining the skin, subcutaneous tissues, muscles, bones, joints, and also allows you to assess the condition of internal organs. Superficial palpation is used to examine the skin, subcutaneous fat, peripheral (subcutaneous) lymph nodes, thyroid and mammary glands, muscles, bones, joints, peripheral arteries, chest and anterior abdominal wall. The skin is palpated by stroking, slightly touching it with the palms, and the underlying tissues are felt by sliding along their surface with the fingers of the palpating hand along with the skin of the examined area, while lightly pressing on the investigated surface. To determine the thickness, density and elasticity of the skin, it is grasped in a fold between the thumb and forefinger. A similar technique is also used in the study of subcutaneous fat, skeletal muscles and enlarged lymph nodes. Deep palpation is used mainly for the study of the abdominal cavity and kidneys. Palpation involves mainly fingers that exert pressure on the anterior abdominal wall in order to penetrate into the depth of the abdominal cavity and feel the examined internal organs.

Percussion (percussio — pounding, tapping) is a method of studying internal organs, which makes it possible to assess their condition by the characteristics of sounds that arise from short blows on the body surface or by a pleximeter placed on the patient's body (studying the density of underlying tissues, gas content, borders of organs with different densities, etc.). Currently, the most common is the finger-finger method of percussion (mediocre percussion), in which the researcher's finger pressed to the body serves as a pleximeter (pleximeter finger), and the striking finger serves as a hammer (hammer finger).

When performing percussion, you must keep to the following conditions and rules.

1. The room where percussion is performed should be warm and quiet. The hands of the doctor (examiner) should be warm (in order to avoid unpleasant sensations in the patient and reflex muscle contraction), and the nails should be cut short.

2. During percussion, the position of the doctor (examiner) and the patient should be comfortable, the latter should not have muscle tension. Percussion of the lungs is best performed in the patient's "standing" or "sitting" position, in case of a serious condition of the patient — when the patient is in a horizontal position. Percussion is performed on the naked part of the body. When performing percussion from the front, the doctor (examiner) should be on the right of the patient or in front of him, when performing percussion from behind — on the left or directly behind.

The technique of percussion is as follows. The left hand is placed with the palm surface on the examined area of the patient's body free from clothing so that the middle finger (pleximeter finger) is tightly pressed to the skin with its entire surface and does not come into contact with other fingers. The right hand with the fingers slightly bent at the joints is placed over the left hand, so that the middle finger (or index finger) of the right hand (hammer finger) is slightly

lower than the other fingers, does not touch them and is located directly above the pleximeter finger of the left hand. Making swinging movements with the right hand (up and down) in the wrist joint, we apply two quickly successive short hits of the same strength and duration with the end of the terminal phalanx of the hammer finger on the bone base of the middle phalanx of the pleximeter finger. The direction of impact should be perpendicular to the back of the pleximeter finger. At the same time, both after the first and after the second blow, the hammer finger should bounce off the pleximeter finger. It is also necessary that each subsequent pair of percussion blows should have the same strength and interval between blows as the previous pair of blows.

Percussion sounds vary in volume, duration, and timbre. The volume of the percussion sound (with the same force of impact) depends on the air content in the examined organ. The duration of a percussion sound is directly proportional to the volume, since oscillations of a larger amplitude die down more slowly than oscillations of a smaller amplitude. Dense (airless) organs (liver, heart) and large masses of muscles give a quiet short sound, which is called dull, during percussion. It is detected above the heart, liver (“hepatic sound”), and other dense, air-free organs. Organs containing air (lungs) produce a loud, long-lasting, clear, percussion sound, called clear pulmonary. Percussion sounds contain a wide range of vibrations of different frequencies and amplitudes, which is associated with tissue heterogeneity. Therefore, their pitch is only conditionally estimated by the prevailing components. Tympanic sound (over the bowel): loud, long, high or low. It is detected over hollow, air-containing organs (stomach, intestines, trachea). The tympanic sound is similar in nature to the sound produced by hitting a drum (tympanon — drum). The tympanic sound is dominated by low frequencies, while the femoral (hepatic) sound is dominated by high frequencies.

It should be remembered that, depending on the force of the impact, the percussive vibrations of the underlying tissues do not penetrate deeper than 7 cm.

Auscultation is a method of listening to sounds arising within inner organs.

According to the method of listening, there are two types of auscultation: a) direct auscultation, which is performed by applying the ear to the surface of the patient’s body; b) indirect auscultation, which is performed using a stethoscope or phonendoscope.

A phonendoscope differs from a stethoscope by having a membrane (diaphragm), on the funnel that amplifies the sound. All steto- and phonendoscopes are closed acoustic systems in which the main conductor of sound is air. The ear tips of the stethoscope are placed in the auricles so that they fit snugly to the external auditory canal. The head of the stethoscope is tightly, but without pressure, set to the desired point on the patient’s body. The head should fit the entire circumference of the skin. The sound-conducting tubes should not touch the patient’s clothing and the doctor (examiner). It is advisable

to slightly moisten a very dry skin, as well as hair-coat covering with water or lubricate with vaseline, so that when using a stethoscope, additional sounds do not occur. It is especially important to make sure that when the patient is breathing, when the skin is stretched due to an increase in the volume of the chest or abdomen during inspiration, there would be no friction against the head of the stethoscope. Auscultation should be long enough to draw correct conclusions about the presence or absence of a pathological process. Each of the two methods of auscultation (direct, indirect) has its own advantages and disadvantages.

During auscultation, as well as during percussion, certain rules and conditions must be observed.

1. The room where the auscultation is performed should be quiet and warm, so that no extraneous noise deadens the sounds listened to by the doctor (medical profession), and fibrillar twitching of muscle fibers that occur from the cold does not simulate various pathological sounds.

2. During auscultation the patient is standing or sitting (on a chair or on the bed). Seriously ill patients are listened to in the “lying down” position, and if necessary, they are carefully turned on their side. During auscultation in the “standing” position, it is advisable to hold the patient with your free hand, placing it on the opposite surface of the body to the auscultation.

3. The patient’s chest should be free of clothing, which may cause additional sounds and murmurs when it comes into contact with the stethoscope head. Areas with pronounced hair should be slightly moistened with water or vaseline. This prevents the appearance of extraneous sounds that are not related to normal and pathological sounds heard in the lungs.

4. During auscultation, the head of the stethoscope or phonendoscope is held motionless by the end part with two fingers and is tightly applied to the patient’s body with the entire edge of the funnel, but does not squeeze the tissues. Excessive pressure on the underlying tissues causes inhibition of vibrations of the tissues lying under the bell and, thereby, weakens the sound conduction. When listening, do not hold the stethoscope tube with your hand, in order to avoid rubbing with your fingers and causing side murmurs as a result. Auscultation should always be performed with the same stethoscope for better perception of its features to transmit sounds.

5. Depending on the objective, the mitral valve is better listened to when listening to a patient on the left side, and the aortic valve — on the right side). The patient’s breathing should also be regulated; in some cases, for better perception or differentiation of existing auscultative phenomena, the patient is asked to cough or make a forced exhalation.

Thus, having prepared for the study of the patient, you can proceed to specific techniques.

1. INSPECTION OF THE SKIN AND SUBCUTANEOUS TISSUES

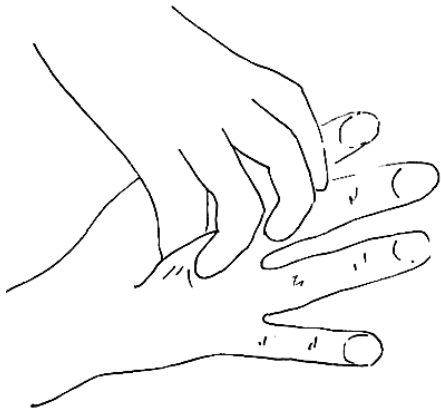

Fig. 1. Estimation of skin turgor (points 23–27)

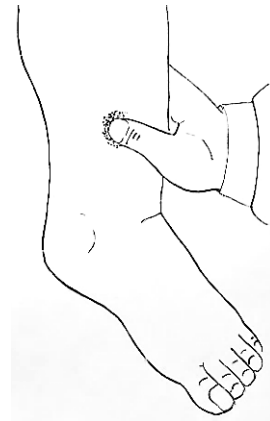


Fig. 2. Estimation of edema (points 28–34)

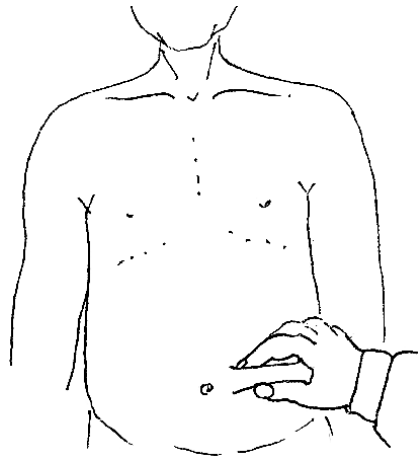


Fig. 3. Estimation subcutaneous fat at the navel level (points 45–46)

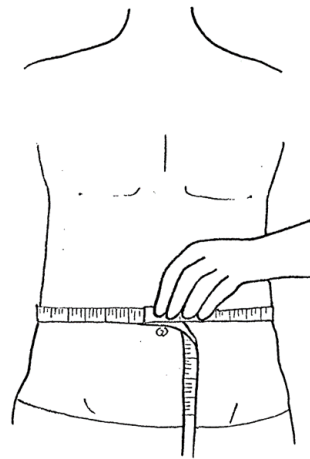


Fig. 4. Measure the waist circumference (points 48–50)

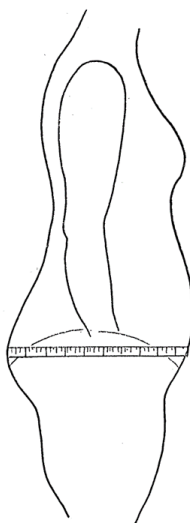


Fig. 5. Measure the circumference of the thighs (points 51–54)

PRACTICAL SKILL SCORECARD

Surname, Name _____ Group ____ Date _____

№	Compliance criteria	1 — done 0 — not done
Preparatory stage		
1	Greet the patient	
2	Introduce yourself to the patient	
3	Ask the patient's full name	
4	Ask the patient's age	
5	Ask about the patient's condition at the beginning of the examination	
6	Tell the patient the name of the examination method "Inspection of the skin and subcutaneous tissues"	
7	Get the patient's consent for the examination	
8	Ask the patient to take off his clothing from his upper part of body	
9	Position the patient in an upright position facing the daylight source	
10	Ask the patient to put his arms down	
11	Perform hand hygiene (gloves are optional)*	
12	Stand to the right of the patient, facing him	
Main stage		
<i>The color of the skin</i>		
13	Assess the color of the skin of the face, head and neck	
14	Announce the results of the examination: the skin color of the face, head and neck is pale pink (pale, cyanotic, jaundice, hyperemic, hyperpigmented, depigmentation foci)	
15	Pathological elements (roseola, erythema, urticaria, purpura, petechiae, herpes, shingles, xanthelasma, vascular "stars", scars, skin tightening, ulceration, bedsores, scratching, varicose veins) on the face, head and neck are present or absent	
16	Assess the color of the skin of the chest in front and behind, the skin of the hands	
17	Make a conclusion: the skin color of the chest and hands is pale (pink, pale, cyanotic, jaundice, hyperemic, hyperpigmented, depigmentation foci).	
18	Pathological elements (roseola, erythema, urticaria, purpura, petechiae, herpes, shingles, xanthelasma, vascular "stars", scars, skin tightening, ulceration, bedsores, scratching, varicose veins) on the chest and hands are present or absent	
19	Ask the patient to take off his clothing from the abdomen, legs and feet	
20	Assess the color of the skin of the abdomen, legs and feet	

21	Make a conclusion: the color of the skin of the abdomen and lower extremities is pale (pink, pale, cyanotic, jaundice, hyperemic, hyperpigmented, depigmentation foci).	
22	Pathological elements (roseola, erythema, urticaria, purpura, petechiae, herpes, shingles, xanthelasma, vascular “stars”, scars, skin tightening, ulceration, bedsores, scratching, varicose veins) on the abdomen, legs and feet are present or absent	
<i>Skin Turgor</i>		
23	With the thumb and forefinger of the right hand grasp the fold in the middle of the back of the patient’s hand (parallel to the axis of the middle finger)	
24	Squeeze the skin fold lightly for 1–2 seconds	
25	Pull the fold up a little	
26	Release the skin fold	
27	Make a conclusion: the skin turgor is normal or reduced	
<i>Edema</i>		
28	Examine the patient’s face, hands and lower limbs	
29	With the thumb of your right hand press on the skin of the back of the hand slowly (within 5 seconds)	
30	Remove the finger from the patient's skin	
31	With the thumb of your right hand press on the skin of the back of the foot slowly (within 5 seconds)	
32	With the thumb of your right hand press on the skin of the anterior surface of the leg in the middle third of the tibia slowly (within 5 seconds)	
33	Make a conclusion: edema is present or absent	
34	Localization of edema if present	
<i>Moisture</i>		
35	Examine the skin, paying attention to the moisture of the skin	
36	With the back of the fingers of both hands touch the skin shortly on the symmetrical areas of the patient's chest at the level of the 2 nd –3 rd ribs along the midclavicular lines	
37	With the back of the fingers of both hands touch the skin shortly on the symmetrical areas of the inner surface of the patient’s forearms	
38	With the back of the fingers of both hands touch the skin shortly on the symmetrical areas of the outer surface of the patient’s forearms	
39	Make a conclusion: the skin is dry or wet on palpation	
<i>Temperature</i>		
40	With the back of the fingers of both hands touch the skin shortly on the symmetrical areas of the patient's forehead	
41	With the back of the fingers of both hands touch the skin shortly on the symmetrical areas of inner surface of the patient’s forearms	
42	With the back of the fingers of both hands touch the skin shortly on the symmetrical areas of the anterior-lateral surface of the legs	

43	Make a conclusion: the skin temperature of the patient's forehead is normal, increased or decreased	
44	The temperature of the skin of the extremities is the same / not the same in symmetrical areas	
<i>Degree of development of subcutaneous fat</i>		
45	Grab the horizontal fat fold at the navel level (5 cm away from it) with the thumb and index fingers of the right hand so that it contains the skin and subcutaneous fat layer	
46	Measure the thickness of the skin fold with a ruler, and make a conclusion: the result (normally 2–3 cm)	
47	Suggest that the patient put their feet together, spread their arms out to the side, and distribute the weight evenly on both legs	
48	Measure the waist circumference with a centimeter tape at the midpoint of the distance between the lower edge of the costal arch and the iliac bones	
49	Measurement is performed in the exhalation phase with normal breathing	
50	Make a conclusion (cm)	
51	Measure the circumference of the thighs above the gluteal fold with a measure tape	
52	Measurement is taken at the widest point of the buttocks	
53	The measuring tape is held horizontally	
54	Make a conclusion (cm)	
55	Divide the waist circumference by the hip circumference	
56	Make a conclusion: the development of subcutaneous fat in the abdominal region is normal, excessive or reduced	
57	Waist circumference is normal (for women of the Caucasian race (Europid) less than 80 cm, for men less than 94 cm) or exceeds the norm	
58	Waist-to-hip ratio is normal (less than 0.85 for women; less than 0.9 cm for men) or exceeds the norm	
Completion of the procedure		
59	Thank the patient	
60	Ask the patient to get dressed	
61	Perform hand hygiene	
Total points _____ (minimum 43 points)		Mark

Full name of the teacher _____ Signature _____

*** Note: Wear gloves every time you touch broken skin, mucous membranes, blood or bodily fluids.**

2. INSPECTION AND PALPATION OF THE LYMPH NODES OF THE HEAD AND NECK

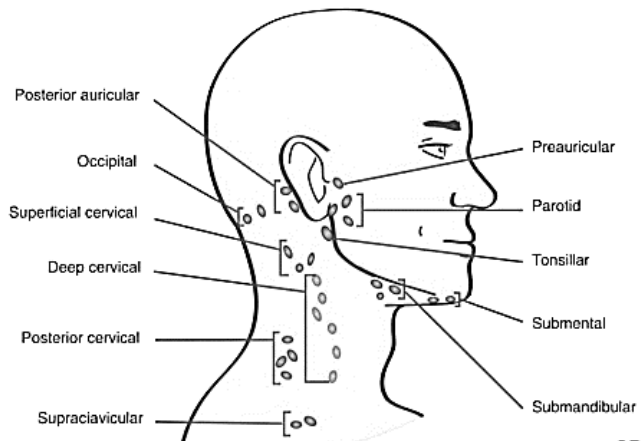


Fig. 6. Lymph nodes location on head and neck




Fig. 7. Palpation of posterior auricular lymph nodes (points 27–29)

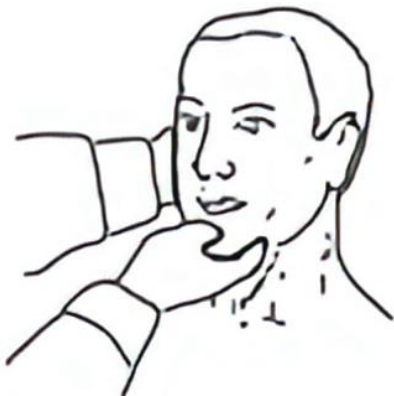

Fig. 8. Palpation of submental lymph nodes (points 68–79)

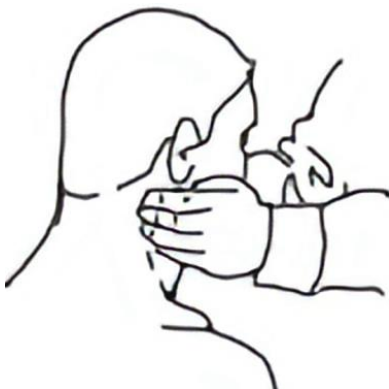

Fig. 9. Palpation of posterior cervical lymph nodes (points 80–82)

PRACTICAL SKILL SCORECARD

Surname, Name _____ Group ____ Date _____

№	Compliance criteria	1 — done 0 — not done
Preparatory stage		
1	Greet the patient	
2	Introduce yourself to the patient	
3	Ask the patient's full name	
4	Ask the patient's age	
5	Ask about the patient's condition at the beginning of the examination	
6	Tell the patient the name of the examination method "Inspection and palpation of the lymph nodes of the head and neck"	
7	Get the patient's consent for the examination	
8	Ask the patient to take off his clothing from his upper part of body	
9	Ask the patient to take an upright position, facing the source of daylight	
10	Ask the patient for pain in the area of head or neck	
11	Warn the patient to report about painful sensations on palpation	
12	Perform hand hygiene (gloves are optional)	
13	Stand in front of the patient, facing him	
Main stage		
<i>Inspection and palpation of the occipital lymph nodes</i>		
14	Ask the patient to turn his head first to the right, then to the left, so that the skin above the area of the lymph nodes on the left and right is accessible for examination	
15	Examine the skin of the head and neck	
16	Make a conclusion: the lymph nodes of the head and neck are visualized / not visualized	
17	Place the II–V fingers of the right and left hands on the tubercles of the patient's occipital bone	
18	Palpate the surface of the occipital bone in a circular motion moving from top to bottom.	
19	At the same time, gently press the occipital lymph nodes to the bone tissue with the pulp of the bent II–V fingers	
20	Ask the patient if there is pain on palpation	
21	Make a conclusion: occipital lymph nodes are palpable / not palpable	
22	The size of lymph nodes (cm)	
23	Lymph node consistency (dense or soft)	
24	Movable or fixed	
25	Joined to each other with surrounding tissues or not	
26	Painful / not painful	

<i>Inspection and palpation of posterior, anterior and parotid lymph nodes</i>		
27	Palpation is performed simultaneously on both sides	
28	Place the closed II–V fingers of the right and left hands symmetrically on both sides in the ear region	
29	Palpate the surface of the ear region from the base of the auricles and over the entire surface of the mastoid process in a circular motion, gently pressing the lymph nodes to the bone surface	
30	Place the tips of the bent II–V fingers of both hands at the base of the ear in the area of the tragus	
31	Palpate the parotid lymph nodes in a circular motion, gently pressing the lymph nodes to the bone surface	
32	Place the tips of the bent II–V fingers of both hands at the front edge of the ear in the region of the posterior edge of the zygomatic arch	
33	The fingertips are pointing up	
34	Palpate the anterior ear lymph nodes in a circular motion, gently pressing the lymph nodes to the bone surface	
35	Check the presence of pain on palpation	
36	Make a conclusion: the posterior, anterior, and parotid lymph nodes are palpable / not palpable	
37	The size of lymph nodes (cm)	
38	Lymph node consistency (dense or soft)	
39	Movable or fixed	
40	Joined to each other with surrounding tissues or not	
41	Painful / not painful	
<i>Inspection and palpation of the submandibular lymph nodes</i>		
42	Palpation of submandibular lymph nodes should be performed sequentially on one side and then on the other.	
43	Start with palpating the submandibular lymph nodes on the left side	
44	Ask the patient to tilt their head slightly forward and to the left	
45	Hold the patient's head in the right parietal region with the left hand	
46	Half-bent and closed tips of the II-V fingers of the right hand in the supination position should be brought to the corner of the lower jaw on the left from the front of the neck	
47	Place the index finger on the area of the angle of the lower jaw	
48	Immerse the tips of the II–V fingers into the soft tissues of the submandibular area	
49	Make a raking sliding motion to the corner of the lower jaw, while gently pressing the lymph nodes to the bone tissue	
50	Move your right hand towards the chin	
51	Repeat the raking movements, gently pressing the lymph nodes to the bone tissue	
52	Check the presence of pain on palpation	
53	Ask the patient to tilt their head slightly forward and to the right	
54	Hold the patient's head in the left parietal region with the right hand	

55	Half-bent and closed tips of the II–V fingers of the left hand in the supination position should be brought to the corner of the lower jaw on the right from the front of the neck	
56	Place the index finger on the area of the angle of the lower jaw	
57	Immerse the tips of the II–V fingers into the soft tissues of the submandibular area	
58	Make a raking sliding motion to the corner of the lower jaw, while gently pressing the lymph nodes to the bone tissue	
59	Move your left hand towards the chin	
60	Repeat the raking movements, gently pressing the lymph nodes to the bone tissue	
61	Check the presence of pain on palpation	
62	Make a conclusion: submandibular lymph nodes are palpable / not palpable	
63	The size of lymph nodes (cm)	
64	Lymph node consistency (dense or soft)	
65	Movable or fixed	
66	Joined to each other with surrounding tissues or not	
67	Painful / not painful	
<i>Inspection and palpation of the submental lymph nodes</i>		
68	Ask the patient to lower their head	
69	Hold the patient's head in the parietal region with the left hand	
70	Turn the half-bent right hand palm up	
71	Place the index finger of the right hand under the chin angle of the lower jaw	
72	With sliding finger movements from back to front and from top to bottom, palpate, while gently pressing the lymph nodes to the bone tissue	
73	Check the presence of pain on palpation	
74	Make a conclusion: the submental lymph nodes are palpable / not palpable	
75	The size of lymph nodes (cm)	
76	Lymph node consistency (dense or soft)	
77	Movable or fixed	
78	Joined to each other with surrounding tissues or not	
79	Painful / not painful	
<i>Inspection and palpation of the anterior and posterior cervical lymph nodes</i>		
80	Palpation is performed simultaneously on both sides	
81	Place the tips of the semi-bent II–V fingers of both hands along the back surface of the sternocleidomastoid (nodding) muscles symmetrically on both sides	
82	Perform palpation of the posterior cervical lymph nodes, moving the fingers in a circular motion from top to bottom along the muscle	

83	Place the tips of the semi-bent II–V fingers along the front edge of the medial leg of the nodding muscle simultaneously on the right and left. The index fingers are located below the angle of the lower jaw	
84	Palpate with your fingertips in a circular motion, moving from above (from the level of the angle of the lower jaw) down to the sternoclavicular joint	
85	Check the presence of pain on palpation	
86	Make a conclusion: the anterior and posterior cervical lymph nodes are palpable / not palpable	
87	The size of lymph nodes (cm)	
88	Lymph node consistency (dense or soft)	
89	Movable or fixed	
90	Joined to each other with surrounding tissues or not	
91	Painful / not painful	
Completion of the procedure		
92	Make a conclusion about the results of the examination of the lymph nodes	
93	Head and neck lymph nodes are visualized / not visualized	
94	Head and neck lymph nodes are palpable / not palpable	
95	Lymph nodes of which group are palpated — specify	
96	The size of lymph nodes (cm)	
97	Lymph node consistency (dense or soft)	
98	Movable or fixed	
99	Joined to each other with surrounding tissues or not	
100	Painful / not painful	
101	Thank the patient	
102	Ask the patient to get dressed	
103	Perform hand hygiene	
Total points _____ (minimum 72 points)		Mark

Full name of the teacher _____ Signature _____

3. INSPECTION AND PALPATION OF SUPRA-, SUBCLAVIAN AND AXILLARY LYMPH NODES

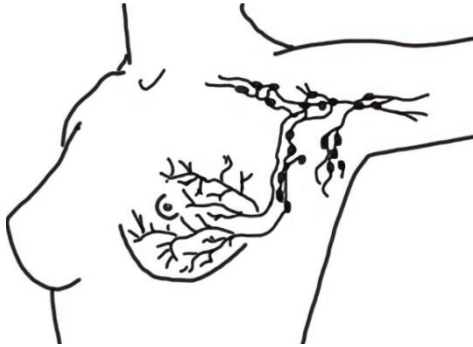

Fig. 10. Supra-, subclavian and axillary lymph nodes location

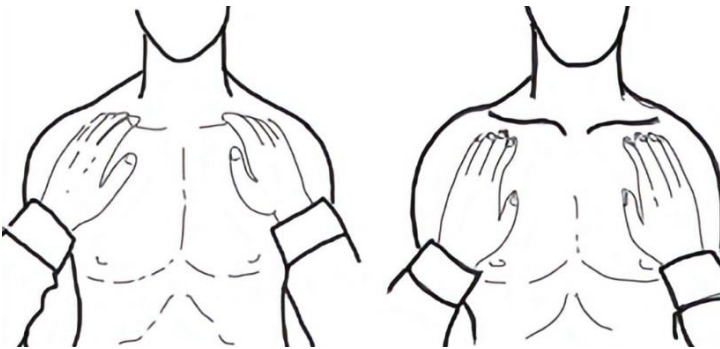


Fig. 11. Palpation of supraclavicular and subclavian lymph nodes (points 17–28)

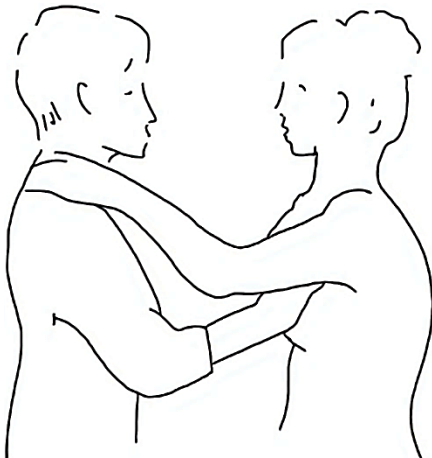


Fig. 12. Palpation of axillary lymph nodes (points 32–49)

PRACTICAL SKILL SCORECARD

Surname, Name _____ Group ____ Date _____

№	Compliance criteria	1 — done 0 — not done
Preparatory stage		
1	Greet the patient	
2	Introduce yourself to the patient	
3	Ask the patient's full name	

4	Ask the patient's age	
5	Ask about the patient's condition at the beginning of the examination	
6	Tell the patient the name of the examination method "Inspection and palpation of the supra-, subclavian and axillary lymph nodes"	
7	Get the patient's consent for the examination	
8	Ask the patient to take off his clothing from his upper part of body	
9	Position the patient in an upright position facing the daylight source	
10	Ask the patient for pain in the chest and armpits	
11	Warn the patient to report about painful sensations on palpation	
12	Perform hand hygiene (gloves are needed to axillary lymph nodes)	
13	Stand in front of the patient, facing him	
Main stage		
<i>Inspection and palpation of supraclavicular and subclavian lymph nodes</i>		
14	Examine the skin of the clavicle area	
15	Make a conclusion: supra-and subclavian lymph nodes are visualized / not visualized	
16	Ask the patient to lower their shoulders and slightly tilt their head down to achieve muscle relaxation	
17	Palpate simultaneously on both sides	
18	Place the closed and horizontally positioned II–V fingers of both hands symmetrically on both sides in the supraclavicular fossae	
19	With the tips of the bent II–V fingers of both hands, in a circular motion, palpate along the upper edge of the clavicle from the inside out, gently pressing the lymph nodes to the bone surface	
20	Place the closed and horizontally positioned II–V fingers of both hands symmetrically on both sides horizontally in the subclavian area	
21	With the tips of the II–V fingers of both hands, in a circular motion, palpate the subclavian region in a circular motion, pressing the lymph nodes to the bone surface	
22	Check the presence of pain on palpation	
23	Make a conclusion: supra-and subclavian lymph nodes are palpable / not palpable	
24	The size of lymph nodes (cm)	
25	Lymph node consistency (dense or soft)	
26	Movable or fixed	
27	Joined to each other with surrounding tissues or not	
28	Painful / not painful	
<i>Inspection and palpation of axillary lymph nodes</i>		
29	Ask the patient to move their hands to the sides	
30	Examine the skin in the armpit area	
31	Make the conclusion: axillary lymph nodes are visualized / not visualized	
32	Palpation of axillary lymph nodes is performed alternately on the right and then on the left side	
33	Put on gloves	

34	To palpate the right axillary lymph nodes, put the patient's right hand on the opposite shoulder of the researcher	
35	Put the palm of the left hand vertically deep into the right axillary fossa	
36	Move from top to bottom in circular sliding movements, gently pressing the lymph nodes to the lateral surface of the chest	
37	Check the presence of pain on palpation	
38	Proceed to palpation of the axillary lymph nodes on the left, remove the patient's right hand from the researcher's shoulder	
39	Place the patient's left hand on the researcher's opposite shoulder	
40	Put the palm of the right hand vertically deep into the left axillary fossa	
41	Move from top to bottom in circular motions, gently pressing against the lateral surface of the chest	
42	Check the presence of pain on palpation	
43	Remove the patient's hand from the researcher's shoulder	
44	Make a conclusion: axillary lymph nodes are palpable / not palpable	
45	The size of lymph nodes (cm)	
46	Lymph node consistency (dense or soft)	
47	Movable or fixed	
48	Joined to each other with surrounding tissues or not	
49	Painful / not painful	
Completion of the procedure		
50	Make a conclusion about the results of the examination of the lymph nodes	
51	Supra-, subclavian and axillary lymph nodes are visualized / not visualized	
52	Supra-, subclavian and axillary lymph nodes are palpable / not palpable	
53	Lymph nodes of which group are palpated — specify	
54	Which side (right / left)	
55	The size of lymph nodes (cm)	
56	Lymph node consistency (dense / soft)	
57	Movable / fixed	
58	Joined to each other with surrounding tissues or not	
59	Painful / not painful	
60	Thank the patient	
61	Ask the patient to get dressed	
62	Take off the gloves	
63	Perform hand hygiene	
Total points _____ (minimum 44 points)		Mark

Full name of the teacher _____ Signature _____

4. INSPECTION AND PALPATION OF INGUINAL AND POPLITEAL LYMPH NODES

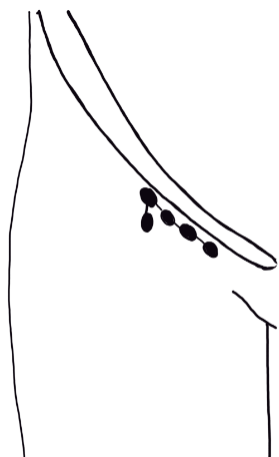


Fig. 13. Inguinal lymph nodes location

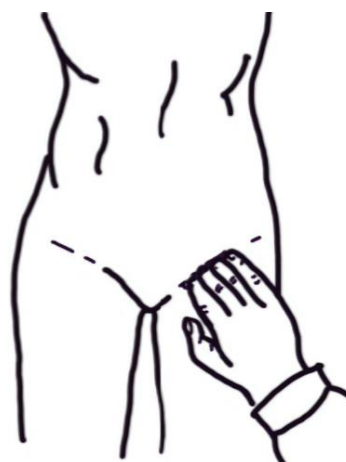

Fig. 14. Palpation of inguinal lymph nodes (points 17–32)

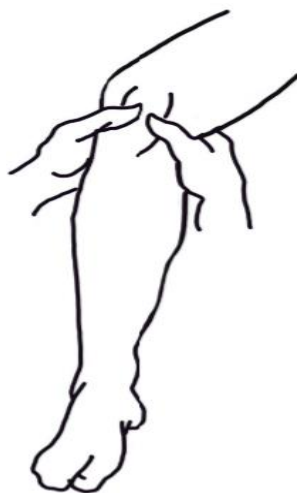

Fig. 15. Palpation of popliteal lymph nodes (points 36–49)

PRACTICAL SKILL SCORECARD

Surname, Name _____ Group ____ Date _____

№	Compliance criteria	1 — done 0 — not done
Preparatory stage		
1	Greet the patient	
2	Introduce yourself to the patient	
3	Ask the patient's full name	
4	Ask the patient's age	
5	Check the patient's condition at the beginning of the examination	

6	Tell the patient the name of the examination method “Inspection and palpation of inguinal and popliteal lymph nodes”	
7	Get the patient’s consent for the examination	
8	Ask the patient to take off his clothing from his lower half of the body	
9	Ask the patient to take a horizontal position (lying with straight legs)	
10	Ask the patient for pain in the inguinal, and popliteal areas	
11	Warn the patient to report painful sensations on palpation	
12	Perform hand hygiene, put on gloves	
13	Sit to the right of the patient, facing him	
Main stage		
<i>Inspection and palpation of inguinal lymph nodes</i>		
14	Examine the groin area	
15	Make a conclusion: the inguinal lymph nodes are visualized / not visualized	
16	Determine the location of the inguinal ligament on the right	
17	Place the tips of the II–V fingers of the right hand in the middle of the inguinal ligament on the right	
18	Palpate above the level of the inguinal ligament on the right in a sliding circular motion	
19	Palpate below the level of the inguinal ligament on the right in a sliding circular motion	
20	Specify the presence of pain on palpation	
21	Determine the location of the inguinal ligament on the left	
22	Place the tips of the II–V fingers of the right hand in the middle of the inguinal ligament on the left	
23	Palpate above the level of the inguinal ligament on the left in a sliding circular motion	
24	Palpate below the level of the inguinal ligament on the left in a sliding circular motion	
25	Specify the presence of pain on palpation	
26	Make a conclusion: the inguinal lymph nodes are palpable / not palpable	
27	The size of lymph nodes (cm)	
28	Lymph node consistency (dense or soft)	
30	Movable or fixed	
31	Joined to each other with surrounding tissues / not visualized	
32	Painful / not painful	
<i>Inspection and palpation of popliteal lymph nodes</i>		
33	Ask the patient to stand up and turn their back to the daylight source	
34	Examine the patient's popliteal regions	
35	Make a conclusion: popliteal lymph nodes are visualized / not visualized	
36	Ask the patient to sit so that the legs are at right angles to the patient’s thighs	

37	Sit opposite the patient	
38	Place both hands on the right knee joint of the patient so that the thumbs are located on the patella, and the tips of the II–V fingers are in the popliteal fossa	
39	With the pulp of the end phalanges of the bent II–V fingers of both hands, palpate the popliteal fossa of the bent joint in a circular motion, gently pressing the lymph nodes to the bone tissues	
40	Specify the presence of pain on palpation	
41	Place both hands on the left knee joint of the patient so that the thumbs are located on the patella, and the tips of the II–V fingers are in the popliteal fossa	
42	With the pulp of the end phalanges of the bent II–V fingers of both hands, palpate the popliteal fossa of the bent joint in a circular motion, gently pressing the lymph nodes to the bone tissues	
43	Specify the presence of pain on palpation	
44	Make a conclusion: popliteal lymph nodes are palpable / not palpable	
45	The size of lymph nodes (cm)	
46	Lymph node consistency (dense or soft)	
47	Movable or fixed	
48	Joined to each other with surrounding tissues or not	
49	Painful / not painful	
Completion of the procedure		
50	Make a conclusion about the results of the examination of the lymph nodes	
51	Inguinal and popliteal lymph nodes are visualized / not visualized	
52	Inguinal, popliteal lymph nodes are palpable / not palpable	
53	Lymph nodes of which group are palpated — specify	
54	Which side (right / left)	
55	The size of lymph nodes (cm)	
56	Lymph node consistency (dense or soft)	
57	Movable or fixed	
58	Joined to each other with surrounding tissues or not	
59	Painful / not painful	
60	Thank the patient	
61	Ask the patient to get dressed	
62	Perform hand hygiene, take off the gloves	
Total points _____ (minimum 43 points)		Mark

Full name of the teacher _____ Signature _____

5. INSPECTION AND PALPATION OF THE THYROID GLAND

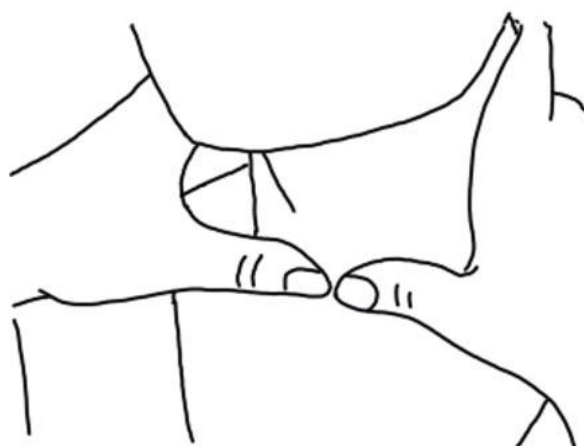


Fig. 16. Palpation of isthmus of thyroid gland (points 19–24)

PRACTICAL SKILL SCORECARD

Surname, Name _____ Group ____ Date _____

№	Compliance criteria	1 — done 0 — not done
Preparatory stage		
1	Greet the patient	
2	Introduce yourself to the patient	
3	Ask the patient's full name	
4	Ask the patient's age	
5	Ask about the patient's condition at the beginning of the examination	
6	Tell the patient the name of the examination method "Inspection and palpation of the thyroid gland"	
7	Get the patient's consent for the examination	
8	Ask the patient to take off his clothing from his neck and decollete area	
9	Ask the patient to take a vertical position facing the source of daylight	
10	Ask the patient for pain in the area of neck	
11	Perform hand hygiene (gloves are optional)	
Main stage		
<i>Inspection and palpation of thyroid gland</i>		
12	Stand in front of the patient, facing him	
13	Ask the patient to turn their head to the right	
14	Examine the anterior-left surface of the neck	
15	Ask the patient to turn their head to the left	
16	Examine the anterior-right surface of the neck	

17	Ask the patient to bend his head slightly forward	
18	With the tips of the thumbs palpate the location of the thyroid and cricoid cartilage on the front surface of the neck on both sides	
19	Place the thumbs of both hands below the cricoid cartilage on both sides of the anterior median line	
20	Place II–IV fingers of both hands on the back of the patient’s neck	
21	With the thumbs of both hands below the cricoid cartilage, perform a sliding motion from top to bottom, palpating isthmus of thyroid gland	
22	The movement is performed simultaneously from both sides	
23	Ask the patient to swallow saliva	
24	When swallowing, fix the thumbs of both hands on the isthmus of the thyroid gland	
25	With circular motions with the thumbs of both hands, palpate the lobes of the thyroid gland	
26	Palpation is carried out simultaneously from both sides	
27	The thumbs move laterally and upward to the upper edge of the thyroid cartilage	
28	Specify the presence of pain on palpation	
Completion of the procedure		
29	Make a conclusion about the results of the inspection: the thyroid gland is visualized / not visualized	
30	Make a conclusion about the results of palpation: the isthmus of the thyroid gland is palpable / not palpable	
31	Thyroid lobes are palpable / not palpable	
32	Localization of the thyroid gland (typical / not typical)	
33	Size (thyroid gland is enlarged / not enlarged)	
34	Consistency (soft / dense)	
35	Surface (smooth / nodular)	
36	Consolidations (palpable / not palpable)	
37	Mobility when swallowing (normally the isthmus is displaced by 1–2 cm)	
38	Painful / not painful	
39	Thank the patient	
40	Perform hand hygiene	
Total points _____ (minimum 29 points)		Mark

Full name of the teacher _____ Signature _____

6. CHEST SHAPE ESTIMATION (INSPECTION AND PALPATION)

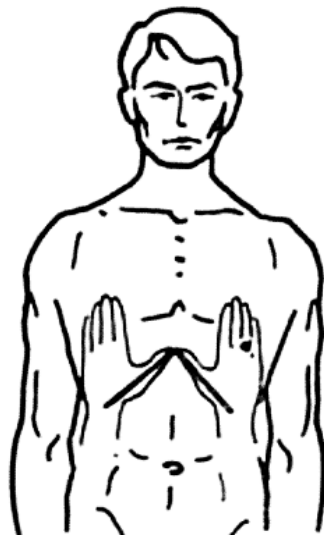

Fig. 17. Estimation of epigastric angle (points 26–29)

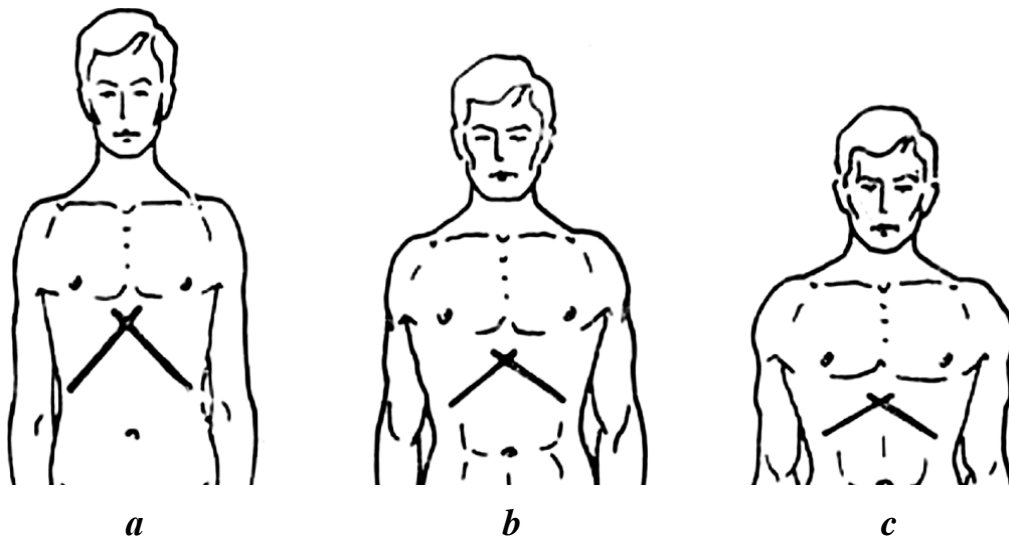


Fig. 18. Normal chest shapes:
a — asthenic (ectomorph); *b* — normosthenic (mesomorph); *c* — hypersthenic (endomorph)

PRACTICAL SKILL SCORECARD

Surname, Name _____ Group ____ Date _____

№	Compliance criteria	1 — done 0 — not done
Preparatory stage		
1	Greet the patient	
2	Introduce yourself to the patient	
3	Ask the patient's full name	
4	Ask about the patient's age	

5	Ask about the patient's condition at the beginning of the examination	
6	Tell the patient the name of the examination method "Chest shape estimation"	
7	Get the patient's informed consent for the examination	
8	Ask the patient to take off his clothing from his chest	
9	Ask the patient to take a vertical position facing the source of daylight	
10	Ask the patient to put his arms down and then spread them to the sides	
11	Ask the patient to breathe calmly and evenly	
12	Perform hand hygiene (gloves are optional)	
13	Stand in front of the patient, facing him	
Main stage		
<i>Static inspection of the chest</i>		
14	Assess the symmetry of the clavicles location	
15	Make the conclusion: the clavicles are at the same level / not at the same level	
16	Examine the supraclavicular fossae	
17	Make the conclusion: the supraclavicular fossae are visible / not visible	
18	Symmetrical/ not symmetrical	
19	Assess the direction of the ribs	
20	Make the conclusion: the direction of the ribs is oblique / horizontal / close to vertical	
21	Examine the intercostal spaces	
22	Make the conclusion: the intercostal spaces are narrow / normal / wide	
23	Assess the symmetry of the right and left halves of the chest. Make the conclusion: both halves of the chest are symmetrical / not symmetrical)	
24	Assess the symmetry of the shoulder joints	
25	Make the conclusion: the shoulder joints are symmetrical / not symmetrical	
26	Place the thumbs of the left and right hands on the costal right and left arches (palms are placed up and laterally)	
27	Join the nail phalanges of thumbs at the xiphoid process	
28	Assess the value of the epigastric angle by the angle between the thumbs	
29	Make a conclusion about epigastric angle: the epigastric angle is right / sharp / obtuse	
30	Ask the patient to turn his back to the daylight source	
31	Ask the patient to put his hands down	
32	Assess the symmetry of the scapulas	
33	Make a conclusion: the scapulas are located symmetrically / not symmetrically	

34	The scapulas are close / contoured (moderately close) / not close to the chest	
35	Assess the deviation of the spine from the vertical axis	
36	Make a conclusion: pathological abnormalities of the spine were identified / not identified	
37	Shape of the chest is normosthenic / asthenic / hypersthenic	
38	Chest deformation is detected / not detected	
<i>Dynamical inspection of the chest</i>		
39	Ask the patient to take an upright position, facing the source of daylight	
40	Determine the breathing pattern by visual observation of several breathing excursions of the patient's chest	
41	Make the conclusion: the type of chest breathing is chest / abdominal / mixed	
42	Determine respiratory rate by visual observation of the patient's chest breathing excursions	
43	Place fingers on the patient's wrist as in case of pulse checking	
44	Respiratory movements should be counted within one minute using a stopwatch or a clock with the second hand	
45	Make the conclusion: the frequency of respiratory movements is ... per minute (normally the respiratory rate is 14–20 per min)	
46	Determine the rhythm of breathing	
47	Make a conclusion: breathing is rhythmic / not rhythmic	
48	Pay attention to the intensity of the noise generated by the air flow in both phases of breathing	
49	Make a conclusion: additional sounds during breathing are heard / not heard	
50	Ask the patient to turn back to the daylight source	
51	Ask the patient to spread his arms to the sides	
52	Place the palms of both hands below the lower corner of the scapulas	
53	Place the thumbs of both hands vertically on the lower corners of the scapulas, II–IV fingers are directed to the axillary regions	
54	Ask the patient to respire using deep chest breathing	
55	The examiner should observe the angles of the scapulae and the movements of his hands during the act of the patient's breathing	
56	Make a conclusion: both halves of the chest are symmetrically / not symmetrically involved in the act of breathing	
Completion of the procedure		
57	Thank the patient	
58	Ask the patient to get dressed	
59	Perform hand hygiene	
Total points _____ (minimum 41 points)		Mark

Full name of the teacher _____ Signature _____

7.1. PALPATION OF THE CHEST PAIN POINTS AT ANTERIOR AND LATERAL CHEST SURFACE

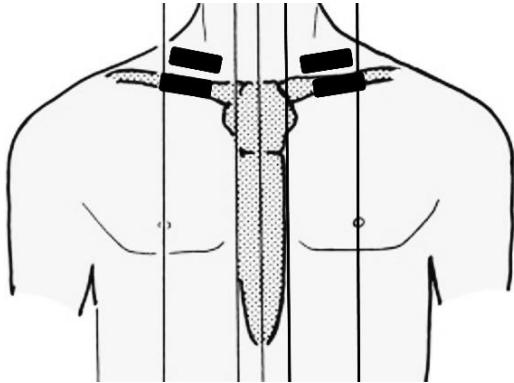


Fig. 19. Palpation of supraclavicular region and clavicle (points 19–24). Black lines indicate the area of palpation

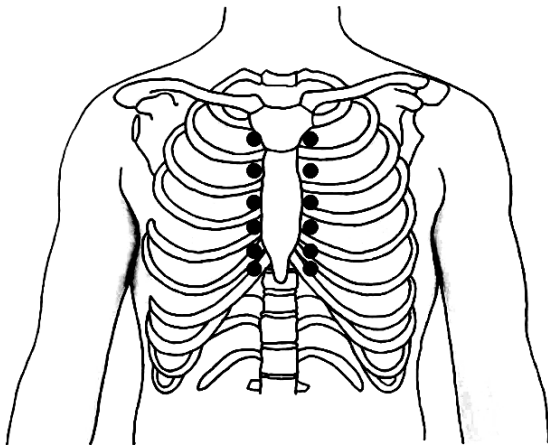


Fig. 20. Palpation of edge of sternum along the intercostal spaces (points 25–34). Black spots indicate the points of palpation

II and III fingers of right hand are raised and parted like “V” sign.

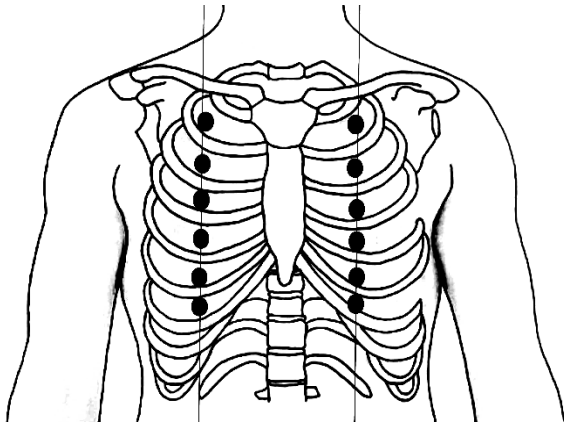


Fig. 21. Palpation along the midclavicular line in the intercostal space (with both hands simultaneously) (points 35–43). Black spots indicate the points of palpation

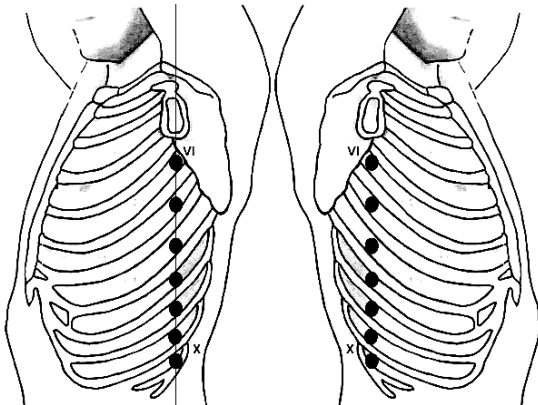


Fig. 22. Palpation of the chest lateral surface along the intercostal space (with both hands simultaneously) (points 45–54). Black spots indicate the points of palpation

PRACTICAL SKILL SCORECARD

Surname, Name _____ Group ____ Date _____

№	Compliance criteria	1 — done 0 — not done
Preparatory stage		
1	Greet the patient	
2	Introduce yourself to the patient	
3	Ask the patient's full name	
4	Ask the patient's age	
5	Ask about the patient's condition at the beginning of the examination	
6	Tell the patient the name of the examination method "Palpation of the chest pain points anterior and lateral chest surface"	
7	Get the patient's informed consent for the examination	
8	Ask the patient to take off his clothing from his chest	
9	Ask the patient to take a vertical position facing the source of daylight	
10	Ask the patient to put his arms down	
11	Ask the patient to relax the shoulder muscles	
12	Ask the patient to breathe calmly and evenly	
13	Ask the patient if he feels pain in the chest	
14	Ask the patient to inform you if he feels any pain on examination	
15	Perform hand hygiene (gloves are optional)	
Main stage		
16	Stand in front of the patient, facing him	
17	Ask the patient to turn his head to the side	
18	Place the left palm on the the patient's right shoulder joint	
<i>Palpation of supraclavicular region, clavicle</i>		
19	Palpate supraclavicular region on the right side with tips of II–V fingers of right hand	
20	Palpate supraclavicular region on the left side with with tips of II–V fingers of right hand	
21	Ask the patient if he feels pain	
22	Palpate the clavicle on the right side with with tips of II–V fingers of right hand	
23	Palpate the clavicle on the left side with with tips of II–V fingers of right hand	
24	Ask the patient if he feels pain on palpation	
<i>Palpation of edge of sternum along the intercostal space</i>		
25	Palpate simultaneously left and right sides of the sternum edge along first intercostalis space with tips of II and III fingers of right hand. Fingers are raised and parted like "V" sign	

26	Palpate simultaneously left and right sides of the sternum edge along second intercostalis space with tips of II and III fingers of right hand. Fingers are raised and parted like “V” sign	
27	Palpate simultaneously left and right sides of the sternum edge along third intercostalis space with tips of II and III fingers of right hand. Fingers are raised and parted like “V” sign	
28	Ask the patient if he feels pain	
29	Palpate simultaneously left and right sides of the sternum edge along fourth intercostalis space with tips of II and III fingers of right hand. Fingers are raised and parted like “V” sign	
30	Palpate simultaneously left and right sides of the sternum edge along fifth intercostalis space with tips of II and III fingers of right hand. Fingers are raised and parted like “V” sign	
31	Palpate simultaneously left and right sides of the sternum edge along fifth intercostalis space with tips of II and III fingers of right hand. Fingers are raised and parted like “V” sign	
32	Ask the patient if he feels pain	
33	With the tips of the II–III bent fingers in the form of the letter “V” of right hand, palpate simultaneously the left and right sides of the sternum edge along sixth intercostalis space	
34	Ask the patient if he feels pain	
<i>Palpation along midclavicular line in the intercostal space (with both hands simultaneously)</i>		
35	With the tips of the II–V bent fingers of both hands, palpate simultaneously from the left and right sides along the midclavicular line in the first intercostal space	
36	With the tips of the bent II–V fingers of both hands, palpate simultaneously from the left and right sides along the midclavicular line in the second intercostal space	
37	Ask the patient if he feels pain	
38	With the tips of the bent II–V fingers of both hands, palpate simultaneously from the left and right sides along the midclavicular line in the third intercostal space	
39	With the tips of the bent II–V fingers of both hands, palpate simultaneously from the left and right sides along the midclavicular line in the fourth intercostal space	
40	Ask the patient if he feels pain	
41	With the tips of the bent II–V fingers of both hands, palpate simultaneously from the left and right sides along the midclavicular line in the fifth intercostal space	
42	With the tips of the bent II–V fingers of both hands, palpate simultaneously from the left and right sides along the midclavicular line in the sixth intercostal space	
43	Ask the patient if he feels pain	

<i>Palpation of chest lateral surface along the intercostal space (with both hands simultaneously)</i>		
44	Ask the patient to place both hands behind the head	
45	With the tips of the both hands bent II–V fingers palpate along the mid-axillary line in the fourth intercostal space from the left and right sides	
46	With the tips of the both hands bent II–V fingers palpate along the mid-axillary line in the fifth intercostal space from the left and right sides	
47	Ask the patient if he feels pain	
48	With the tips of the both hands bent II–V fingers palpate along the mid-axillary line in the sixth intercostal space from the left and right sides	
49	With the tips of the both hands bent II–V fingers palpate along the mid-axillary line in the seventh intercostal space from the left and right sides	
50	Ask the patient if he feels pain	
51	With the tips of the both hands bent II–V fingers palpate along the mid-axillary line in the eighth intercostal space from the left and right sides	
52	With the tips of the both hands bent II–V fingers palpate along the mid-axillary line in the ninth intercostal space from the left and right sides	
53	With the tips of the both hands bent II–V fingers palpate along the mid-axillary line in the tenth intercostal space from the left and right sides	
54	Ask the patient if he feels pain	
Completion of the procedure		
55	Make the conclusion about the results of the examination: palpation of the chest pain points is painful / not painful	
56	Localization of pain, if any	
57	Thank the patient	
58	Ask the patient to get dressed	
60	Perform hand hygiene	
Total points _____ (minimum 42 points)		Mark

Full name of the teacher _____ Signature _____

7.2. PALPATION OF THE CHEST PAIN POINTS AT POSTERIOR CHEST SURFACE

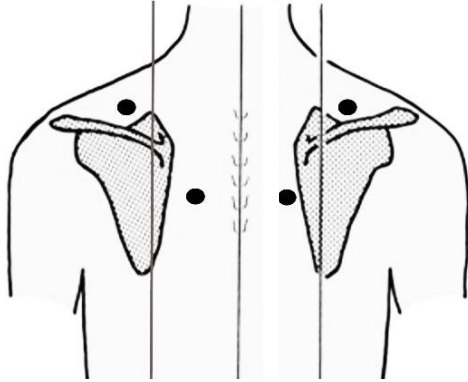


Fig. 23. Palpation of supraspinatus and interscapular regions (with both hands simultaneously) (points 15–17). Black spots indicate the area of palpation

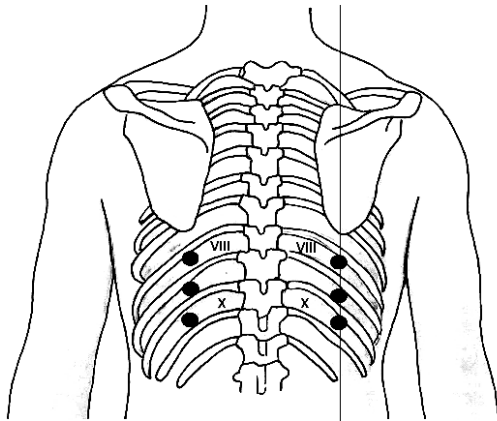


Fig. 24. Palpation along the scapular lines (with both hands simultaneously) (points 18–21). Black spots indicate the area of palpation

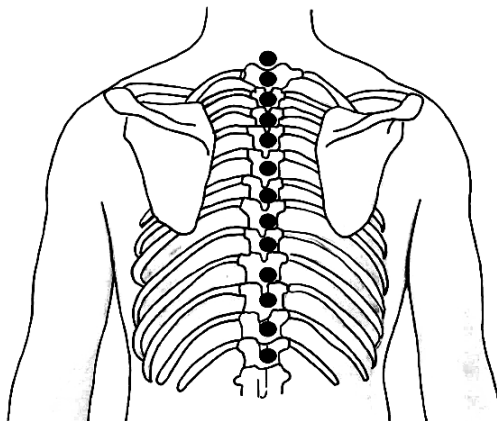


Fig. 25. Palpation of spinous processes of thoracic vertebrae (points 22–39) (with thumb of right hand). Black spots indicate the points of palpation

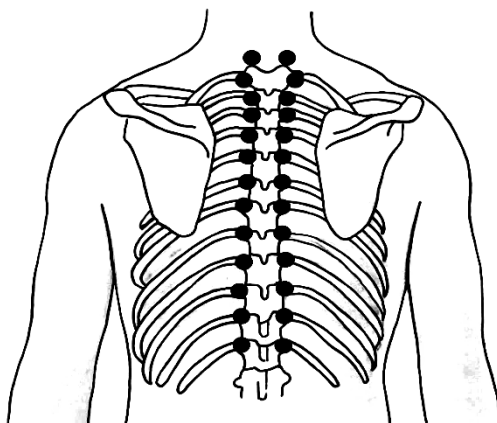
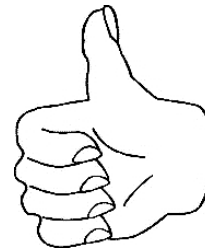


Fig. 26. Palpation of paravertebral points (points 40–55) (II and III fingers of right hand are raised and parted like “V” sign). Black spots indicate the points of palpation



PRACTICAL SKILL SCORECARD

Surname, Name _____ Group ____ Date _____

№	Compliance criteria	1 — done 0 — not done
Preparatory stage		
1	Greet the patient	
2	Introduce yourself to the patient	
3	Ask the patient's full name	
4	Ask the patient's age	
5	Ask about the patient's condition at the beginning of the examination	
6	Tell the patient the name of the examination method "Palpation of the chest pain points at posterior chest surface"	
7	Get the patient's informed consent for the examination	
8	Ask the patient to take off his clothing from his chest	
9	Ask the patient to take a vertical position facing the source of daylight	
10	Ask the patient to turn back to the examiner and cross his arms over his chest ("hug" himself)	
11	Ask the patient to breathe calmly and evenly	
12	Ask the patient if he feels pain in the chest	
13	Ask the patient to inform you if he feels any pain on examination	
14	Perform hand hygiene (gloves are optional)	
Main stage		
<i>Palpation of supraspinatus, interscapular and subscapular regions (with both hands simultaneously)</i>		
15	With the tips of the bent II–V fingers of both hands, palpate the right and left sides of the supraspinatus region	
16	With the tips of the bent II–V fingers of both hands, palpate the right and left sides of the interscapular region	
17	Ask the patient if he feels pain for pain	
18	With the tips of the bent II–V fingers of both hands, palpate along the scapular line right and left sides in the eighth intercostal space	
19	With the tips of bent II–V fingers of both hands, palpate along the scapular line right and left sides in the ninth intercostal space	
20	With the tips of bent fingers II–V fingers of both hands, palpate along the scapular line right and left sides in the tenth intercostal space	
21	Ask the patient if he feels pain	
<i>Palpation of the spinous processes of the thoracic vertebrae and paravertebral points</i>		
22	Place the left palm on the the patient's left shoulder joint	
23	With the tip of the right bent thumb palpate the spinous process of the VII cervical vertebra	

24	With the tip of the right bent thumb palpate the spinous process of the I thoracic vertebra	
25	With the tip of the right bent thumb palpate the spinous process of the II thoracic vertebra	
26	Ask the patient if he feels pain	
27	With the tip of the right bent thumb palpate the spinous process of the III thoracic vertebra	
28	With the tip of the right bent thumb palpate the spinous process of the VI thoracic vertebra	
29	With the tip of the right bent thumb palpate the spinous process of the V thoracic vertebra	
30	Ask the patient if he feels pain	
31	With the tip of the right bent thumb palpate the spinous process of the VI thoracic vertebra	
32	With the tip of the right bent thumb palpate the spinous process of the VII thoracic vertebra	
33	With the tip of the right bent thumb palpate the spinous process of the VIII thoracic vertebra	
34	Ask the patient if he feels pain	
35	With the tip of the right bent thumb palpate the spinous process of the IX thoracic vertebra	
36	With the tip of the right bent thumb palpate the spinous process of the X thoracic vertebra	
37	With the tip of the right bent thumb, palpate the spinous process of the XI thoracic vertebra	
38	With the tip of the right bent thumb palpate the spinous process of the XII thoracic vertebra	
39	Ask the patient if he feels pain	
40	With the tips of the II–III bent fingers in the form of the letter “V” of right hand, palpate simultaneously the right and left paravertebral points at the level of the spinous process of the VII cervical vertebra	
41	With the tips of the II–III bent fingers in the form of the letter “V” of right hand, palpate simultaneously the right and left paravertebral points at the level of the spinous process of the I thoracic vertebra	
42	With the tips of the II–III bent fingers in the form of the letter “V” of right hand, palpate simultaneously the right and left paravertebral points at the level of the spinous process of the II thoracic vertebra	
43	Ask the patient if he feels pain	
44	With the tips of the II–III bent fingers in the form of the letter “V” of right hand, palpate simultaneously the right and left paravertebral points at the level of the spinous process of the III thoracic vertebra	
45	With the tips of the II–III bent fingers in the form of the letter “V” of right hand, palpate simultaneously the right and left paravertebral points at the level of the spinous process of the IV thoracic vertebra	

46	With the tips of the II–III bent fingers in the form of the letter “V” of right hand, palpate simultaneously the right and left paravertebral points at the level of the spinous process of the V thoracic vertebra	
47	Ask the patient if he feels pain	
48	With the tips of the II–III bent fingers in the form of the letter “V” of right hand, palpate simultaneously the right and left paravertebral points at the level of the spinous process of the VI thoracic vertebra	
49	With the tips of the II–III bent fingers in the form of the letter “V” of right hand, palpate simultaneously the right and left paravertebral points at the level of the spinous process of the VII thoracic vertebra	
50	With the tips of the II–III bent fingers in the form of the letter “V” of right hand, palpate simultaneously the right and left paravertebral points at the level of the spinous process of the VIII thoracic vertebra	
51	With the tips of the II–III bent fingers in the form of the letter “V” of right hand, palpate simultaneously the right and left paravertebral points at the level of the spinous process of the IX thoracic vertebra	
52	With the tips of the II–III bent fingers in the form of the letter “V” of right hand, palpate simultaneously the right and left paravertebral points at the level of the spinous process of the X thoracic vertebra	
53	With the tips of the II–III bent fingers in the form of the letter “V” of right hand, palpate simultaneously the right and left paravertebral points at the level of the spinous process of the XI thoracic vertebra	
54	With the tips of the II–III bent fingers in the form of the letter “V” of right hand, palpate simultaneously the right and left paravertebral points at the level of the spinous process of the XII thoracic vertebra	
55	Ask the patient if he feels pain	
Completion of the procedure		
56	Make the conclusion about the results of the examination: palpation of the chest pain points is painful / not painful	
57	Localization of pain, if any	
58	Thank the patient	
59	Ask the patient to get dressed	
60	Perform hand hygiene	
Total points _____ (minimum 42 points)		Mark

Full name of the teacher _____ Signature _____

8.1. COMPARATIVE PERCUSSION OF THE LUNG AT ANTERIOR AND LATERAL CHEST SURFACE

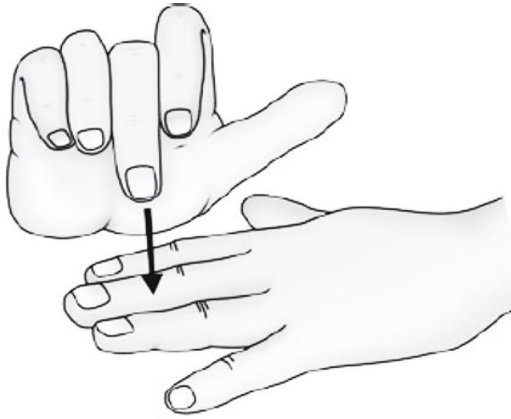


Fig. 27. Percussion technique

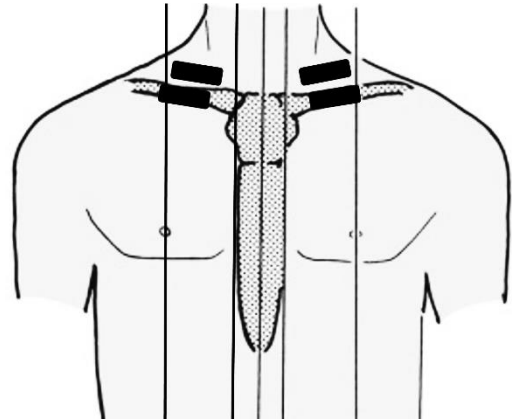


Fig. 28. Comparative percussion on supraclavicular regions and clavicles (points 17–49). Black lines indicate the location of pleximeter finger

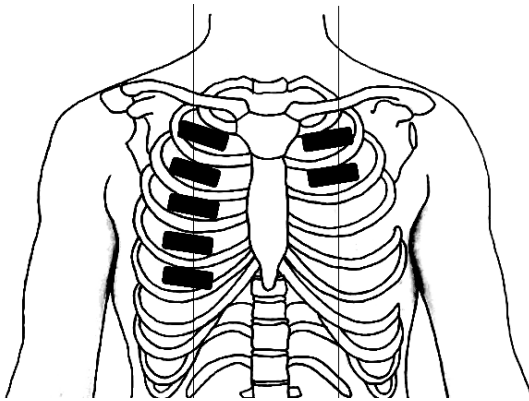


Fig. 29. Comparative percussion on intercostal spaces (points 50–118). Black lines indicate the location of pleximeter finger

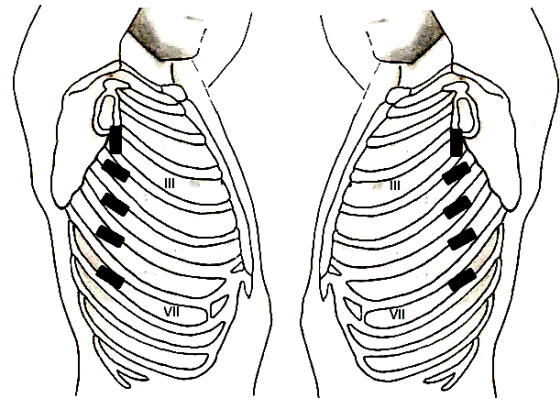


Fig. 30. Comparative percussion at lateral chest surface (points 122–201). Black lines indicate the location of pleximeter finger

PRACTICAL SKILL SCORECARD

Surname, Name _____ Group ____ Date _____

№	Compliance criteria	1 — done 0 — not done
Preparatory stage		
1	Greet the patient	
2	Introduce yourself to the patient	
3	Ask the patient's full name	
4	Ask the patient's age	
5	Ask about the patient's condition at the beginning of the examination	

6	Tell the patient the name of the examination method “Comparative percussion of the lung at anterior and lateral chest surface”	
7	Get the patient's informed consent for the examination	
8	Ask the patient to take off his clothing from his chest	
9	Ask the patient to take a vertical position facing the source of daylight	
10	Ask the patient to put his arms down	
11	Ask the patient to relax the shoulder muscles	
12	Ask the patient to breathe calmly and evenly	
13	Ask the patient about any pain in the chest	
14	Perform hand hygiene	
Main stage		
<i>Percussion of the anterior surface of the chest</i>		
15	Stand on the right opposite the right half of the patient’s chest, facing him	
16	Ask the patient to turn their head to the left	
<i>Comparative percussion on supraclavicular region</i>		
17	Place the palm of the left hand on the surface of the patient’s body so that the middle of the distal phalanx of the middle finger corresponds to the intended point of percussion	
18	Place the pleximeter finger on the right parallel to the clavicle in the supraclavicular fossa	
19	Press the pleximeter finger tightly to the skin along the right mid-clavicular line	
20	Place II and IV fingers apart, they do not touch the pleximeter finger	
21	Perform percussion using the loud percussion method in the supra-clavicular fossa along the distal phalanx of the pleximeter finger	
22	As a hammer, use the middle finger of the right hand bent in the proximal and distal interphalangeal joints so that its terminal phalanx is perpendicular to the surface of the distal phalanx of the middle finger of the left hand	
23	Percuss below the nail of the distal phalanx (between the nail and the distal interphalangeal joint)	
24	Short taps, equal strength, two at each point of percussion	
25	The interphalangeal joints of the middle finger, elbow and shoulder joints of the right hand remain motionless	
26	After the second tap, the hammer finger should not remain pressed against the pleximeter finger	
27	Place the palm of the left hand on the surface of the patient’s body so that the middle of the distal phalanx of the middle finger corresponds to the intended point of percussion	
28	Place the pleximeter finger on the left parallel to the clavicle in the supraclavicular fossa	
29	Press the pleximeter finger tightly to the skin along the left mid-clavicular line	
30	Place II and IV fingers apart, they do not touch the pleximeter finger	

31	Perform percussion using the loud percussion method in the supra-clavicular fossa along the distal phalanx of the pleximeter finger	
32	As a hammer, use the middle finger of the right hand bent in the proximal and distal interphalangeal joints so that its terminal phalanx is perpendicular to the surface of the distal phalanx of the middle finger of the left hand	
33	Percuss below the nail of the distal phalanx (between the nail and the distal interphalangeal joint)	
34	Short taps, equal strength, two at each point of percussion	
35	The interphalangeal joints of the middle finger, elbow and shoulder joints of the right hand remain motionless	
36	After the second tap, the hammer finger should not remain pressed against the pleximeter finger	
37	Compare the percussion sound, make the conclusion (if the percussion sound is the same on the right and left or not)	
<i>Comparative percussion on the clavicle</i>		
38	Perform percussion using loud percussion directly along the right clavicle along the mid-clavicular line	
39	As a hammer, use the middle finger of the right hand, bent at the proximal and distal interphalangeal joints so that its terminal phalanx is perpendicular to the surface of the middle of the clavicle	
40	Tap on the center of the clavicle, the movement of tapping should come from the right wrist	
41	Short taps, equal strength, two at each point of percussion	
42	The interphalangeal joints of the middle finger, elbow and shoulder joints of the right hand remain motionless	
43	After the second tap, the hammer finger should not remain pressed against the clavicle	
44	Perform percussion using the loud percussion method directly along the left clavicle along the mid-clavicular line	
45	Tap on the center of the clavicle, the movement of tapping should come from the right wrist	
46	Short taps, equal strength, two at each point of percussion	
47	The interphalangeal joints of the middle finger, elbow and shoulder joints of the right hand remain motionless	
48	After the second tap, the hammer finger should not remain pressed against the clavicle	
49	Compare the percussion sound, make the conclusion (if the percussion sound is the same on the right and left or not)	
<i>Comparative percussion in the subclavian region (1st intercostal space)</i>		
50	Place the palm of the left hand on the surface of the patient's body so that the middle of the middle phalanx of the pleximeter finger corresponds to the intended point of percussion	
51	Place the pleximeter finger horizontally along the right mid-clavicular line in the 1 st intercostal space	
52	The pleximeter finger is tightly pressed to the skin	

53	Place II and IV fingers apart, without touching the pleximeter finger	
54	Perform percussion using the loud percussion method along the middle phalanx of the pleximeter finger	
55	As a hammer, use the middle finger of the right hand bent in the proximal and distal interphalangeal joints so that its terminal phalanx is perpendicular to the surface of the middle phalanx of the middle finger of the left hand	
56	Tap on the center of this phalanx, the movement of tapping should come from the right wrist	
57	Short taps, equal strength, two at each point of percussion	
58	The interphalangeal joints of the middle finger, elbow and shoulder joints of the right hand remain motionless	
59	After the second tap, the hammer finger should not remain pressed against the pleximeter finger	
60	Move the pleximeter finger and position it horizontally along the left mid-clavicular line in the 1 st intercostal space	
61	The pleximeter finger is tightly pressed to the skin	
62	Place II and IV fingers apart, without touching the pleximeter finger	
63	Perform percussion using the loud percussion method along the middle phalanx of the pleximeter finger	
64	Tap on the center of this phalanx, the movement of tapping should come from the right wrist	
65	Short taps, equal strength, two at each point of percussion	
66	The interphalangeal joints of the middle finger, elbow and shoulder joints of the right hand remain motionless	
67	After the second tap, the hammer finger should not remain pressed against the pleximeter finger	
68	Compare the percussion sound, make the conclusion (if the percussion sound is the same on the right and left or not)	
<i>Comparative percussion in the 2nd intercostal space</i>		
69	Place the palm of the left hand on the surface of the patient's body so that the middle of the middle phalanx of the pleximeter finger corresponds to the intended point of percussion	
70	The pleximeter finger is tightly pressed to the skin along the right mid-clavicular line in the 2 nd intercostal space	
71	Place II and IV fingers apart, without touching the pleximeter finger	
72	Perform percussion using the loud percussion method along the middle phalanx of the pleximeter finger	
73	As a hammer, use the middle finger of the right hand bent in the proximal and distal interphalangeal joints so that its terminal phalanx is perpendicular to the surface of the middle phalanx of the middle finger of the left hand	
74	Tap on the center of this phalanx, the movement of tapping should come from the right wrist	
75	Short taps, equal strength, two at each point of percussion	

76	The interphalangeal joints of the middle finger, elbow and shoulder joints of the right hand remain motionless	
77	After the second tap, the hammer finger should not remain pressed against the pleximeter finger	
78	Move the pleximeter finger and position it horizontally along the left mid-clavicular line in the 2 nd intercostal space	
79	The pleximeter finger is tightly pressed to the skin	
80	fingers are apart, without touching the pleximeter finger	
81	Perform percussion using the loud percussion method along the middle phalanx of the pleximeter finger	
83	Tap on the center of this phalanx, the movement of tapping should come from the right wrist	
84	Short taps, equal strength, two at each point of percussion	
85	The interphalangeal joints of the middle finger, elbow and shoulder joints of the right hand remain motionless	
86	After the second tap, the hammer finger should not remain pressed against the pleximeter finger	
87	Compare the percussion sound, make the conclusion (if the percussion sound is the same on the right and left or not)	
<i>Comparative percussion in the 3rd intercostal space</i>		
88	Place the palm of the left hand on the surface of the patient's body so that the middle of the middle phalanx of the pleximeter finger corresponds to the intended point of percussion	
89	The pleximeter finger is tightly pressed to the skin along the right mid-clavicular line in the 3 rd intercostal space	
90	Place II and IV fingers apart, without touching the pleximeter finger	
91	Perform percussion using the loud percussion method along the middle phalanx of the pleximeter finger	
92	As a hammer, use the middle finger of the right hand bent in the proximal and distal interphalangeal joints so that its terminal phalanx is perpendicular to the surface of the middle phalanx of the middle finger of the left hand	
93	Tap on the center of this phalanx, the movement of tapping should come from the right wrist	
94	Short taps, equal strength, two at each point of percussion	
95	The interphalangeal joints of the middle finger, elbow and shoulder joints of the right hand remain motionless	
96	After the second tap, the hammer finger should not remain pressed against the pleximeter finger	
97	Compare the percussion sound, make the conclusion (if the percussion sound is the same on the right 2 nd intercostal space and 3 rd intercostal space or not)	
<i>Comparative percussion in the 4th intercostal space</i>		
98	Place the palm of the left hand on the surface of the patient's body so that the middle of the middle phalanx of the pleximeter finger corresponds to the intended point of percussion	

99	The pleximeter finger is tightly pressed to the skin along the right mid-clavicular line in the 4 th intercostal space	
100	II and the IV fingers are apart, without touching the pleximeter finger	
101	Perform percussion using the loud percussion method along the middle phalanx of the pleximeter finger	
102	As a hammer, use the middle finger of the right hand bent in the proximal and distal interphalangeal joints so that its terminal phalanx is perpendicular to the surface of the middle phalanx of the middle finger of the left hand	
103	Tap on the center of this phalanx, the movement of tapping should come from the right wrist	
104	Short taps, equal strength, two at each point of percussion	
105	The interphalangeal joints of the middle finger, elbow and shoulder joints of the right hand remain motionless	
106	After the second tap, the hammer finger should not remain pressed against the pleximeter finger	
107	Compare the percussion sound, make the conclusion (if the percussion sound is the same on the right 3 rd intercostal space and 4 th intercostal space or not)	
<i>Comparative percussion in the 5th intercostal space</i>		
108	Place the palm of the left hand on the surface of the patient's body so that the middle of the middle phalanx of the pleximeter finger corresponds to the intended point of percussion	
109	The pleximeter finger is tightly pressed to the skin along the right mid-clavicular line in the 5 th intercostal space	
110	Place II and IV fingers are apart, without touching the pleximeter finger	
111	Perform percussion using the loud percussion method along the middle phalanx of the pleximeter finger	
112	As a hammer, use the middle finger of the right hand bent in the proximal and distal interphalangeal joints so that its terminal phalanx is perpendicular to the surface of the middle phalanx of the middle finger of the left hand	
113	Tap on the center of this phalanx, the movement of tapping should come from the right wrist	
114	Short taps, equal strength, two at each point of percussion	
115	The interphalangeal joints of the middle finger, elbow and shoulder joints of the right hand remain motionless	
116	After the second tap, the hammer finger should not remain pressed against the pleximeter finger	
117	Compare the percussion sound, make the conclusion (if the percussion sound is the same on the right 4 th intercostal space and 5 th intercostal space or not)	
118	When the percussion sound is shortened in the 5 th intercostal space, percussion is stopped, in the absence of shortening, the percussion is continued in the 6 th intercostal space	

<i>Percussion of the lateral surfaces of the chest</i>		
119	Ask the patient to place both hands on the back of the head	
120	Stand in front of the patient, facing him	
121	Ask the patient to turn his head to the left	
<i>Comparative percussion in the axillary pits</i>		
122	Place the pleximeter finger vertically in the right axillary fossa, the distal phalanx of the finger reaches the lower border of hair growth	
123	The pleximeter finger is tightly pressed to the skin	
124	Place II and IV fingers apart, without touching the pleximeter finger	
125	Perform percussion using the loud percussion method in the 3 rd intercostal space along the distal phalanx of the pleximeter finger	
126	As a hammer, use the middle finger of the right hand bent in the proximal and distal interphalangeal joints so that its terminal phalanx is perpendicular to the surface of the middle finger of the left hand	
127	Percuss below the nail of the distal phalanx (between the nail and the distal interphalangeal joint)	
128	Short taps, equal strength, two at each point of percussion	
129	The interphalangeal joints of the 3 rd finger, elbow and shoulder joints of the right hand remain motionless	
130	After the second tap, the hammer finger should not remain pressed against the pleximeter finger	
131	Place the pleximeter finger vertically in the left axillary fossa, the distal phalanx of the finger reaches the lower border of hair growth	
132	The pleximeter finger is tightly pressed to the skin	
133	Place II and IV fingers apart, without touching the pleximeter finger	
134	Perform percussion using the loud percussion method in the 3 rd intercostal space along the distal phalanx of the pleximeter finger	
135	As a hammer, use the middle finger of the right hand bent in the proximal and distal interphalangeal joints so that its terminal phalanx is perpendicular to the surface of the middle finger of the left hand	
136	Tap on the center of this phalanx, the movement of tapping should come from the right wrist	
137	Short taps, equal strength, two at each point of percussion	
138	The interphalangeal joints of the 3 rd finger, elbow and shoulder joints of the right hand remain motionless	
139	After the second tap, the hammer finger should not remain pressed against the pleximeter finger	
140	Compare the percussion sound, make the conclusion (if the percussion sound is the same on the right and left or not)	
<i>Comparative percussion in the 4th intercostal space</i>		
141	Place the palm of the left hand on the surface of the patient's body so that the middle of the middle phalanx of the pleximeter finger corresponds to the intended point of percussion	

142	Place the pleximeter finger horizontally (along the intercostal space) along the right mid-axillary line in the 4 th intercostal space	
143	The pleximeter finger is tightly pressed to the skin	
144	Place II and the IV fingers apart, without touching the pleximeter finger	
145	Perform percussion in the 4 th intercostal space using the loud percussion method along the middle phalanx of the pleximeter finger	
146	As a hammer, use the middle finger of the right hand bent in the proximal and distal interphalangeal joints so that its terminal phalanx is perpendicular to the surface of the middle phalanx of the middle finger of the left hand	
147	Tap on the center of this phalanx, the movement of tapping should come from the right wrist	
148	Short taps, equal strength, two at each point of percussion	
149	The interphalangeal joints of the middle finger, elbow and shoulder joints of the right hand remain motionless	
150	After the second tap, the hammer finger should not remain pressed against the pleximeter finger	
151	Move the pleximeter finger, place it horizontally (along the intercostal space) along the left mid-axillary line in the 4 th intercostal space	
152	The pleximeter finger is tightly pressed to the skin	
153	Place II and IV fingers apart, without touching the pleximeter finger	
154	Perform percussion in the 4 th intercostal space using the loud percussion method along the middle phalanx of the pleximeter finger	
155	As a hammer, use the middle finger of the right hand bent in the proximal and distal interphalangeal joints so that its terminal phalanx is perpendicular to the surface of the middle phalanx of the middle finger of the left hand	
156	Tap on the center of this phalanx, the movement of tapping should come from the right wrist	
157	Short taps, equal strength, two at each point of percussion	
158	The interphalangeal joints of the middle finger, elbow and shoulder joints of the right hand remain motionless	
159	After the second tap, the hammer finger should not remain pressed against the pleximeter finger	
160	Compare the percussion sound, make the conclusion (if the percussion sound is the same on the right and left or not)	
<i>Comparative percussion in the 5th intercostal space</i>		
161	Place the palm of the left hand on the surface of the patient's body so that the middle of the middle phalanx of the pleximeter finger corresponds to the intended point of percussion	
162	Place the pleximeter finger horizontally (along the intercostal space) along the right mid-axillary line in the 5 th intercostal space	
163	The pleximeter finger is tightly pressed to the skin	
164	Place II and IV fingers are apart, without touching the pleximeter finger	

165	Perform percussion in the 5 th intercostal space using the loud percussion method along the middle phalanx of the pleximeter finger	
166	As a hammer, use the middle finger of the right hand bent in the proximal and distal interphalangeal joints so that its terminal phalanx is perpendicular to the surface of the middle phalanx of the middle finger of the left hand	
167	Tap on the center of this phalanx, the movement of tapping should come from the right wrist	
168	Short taps, equal strength, two at each point of percussion	
169	The interphalangeal joints of the middle finger, elbow and shoulder joints of the right hand remain motionless	
170	After the second tap, the hammer finger should not remain pressed against the pleximeter finger	
171	Move the pleximeter finger, place it horizontally (along the intercostal space) along the left mid-axillary line in the 5 th intercostal space	
172	The pleximeter finger is tightly pressed to the skin	
173	Place II and IV fingers are apart, without touching the pleximeter finger	
174	Perform percussion in the 5 th intercostal space using the loud percussion method along the middle phalanx of the pleximeter finger	
175	As a hammer, use the middle finger of the right hand bent in the proximal and distal interphalangeal joints so that its terminal phalanx is perpendicular to the surface of the middle phalanx of the middle finger of the left hand	
176	Tap on the center of this phalanx, the movement of tapping should come from the right wrist	
177	Short taps, equal strength, two at each point of percussion	
178	The interphalangeal joints of the middle finger, elbow and shoulder joints of the right hand remain motionless	
179	After the second tap, the hammer finger should not remain pressed against the pleximeter finger	
180	Compare the percussion sound, make the conclusion (if the percussion sound is the same on the right and left or not)	
<i>Comparative percussion in the 6th intercostal space</i>		
181	Place the palm of the left hand on the surface of the patient's body so that the middle of the middle phalanx of the pleximeter finger corresponds to the intended point of percussion	
182	Place the pleximeter finger horizontally (along the intercostal space) along the right mid-axillary line in the 6 th intercostal space	
183	The pleximeter finger is tightly pressed to the skin	
184	Place II and IV fingers apart, without touching the pleximeter finger	
185	Perform percussion in the 6 th intercostal space using the loud percussion method along the middle phalanx of the pleximeter finger	
186	As a hammer, use the middle finger of the right hand bent in the proximal and distal interphalangeal joints so that its terminal phalanx is perpendicular to the surface of the middle phalanx of the middle finger of the left hand	

187	Tap on the center of this phalanx, the movement of tapping should come from the right wrist	
188	Short taps, equal strength, two at each point of percussion	
189	The interphalangeal joints of the middle finger, elbow and shoulder joints of the right hand remain motionless	
190	After the second tap, the hammer finger should not remain pressed against the pleximeter finger	
191	Move the pleximeter finger, place it horizontally (along the intercostal space) along the left mid-axillary line in the 6 th intercostal space	
192	The pleximeter finger is tightly pressed to the skin	
193	Place II and IV fingers apart, without touching the pleximeter finger	
194	Perform percussion in the 6 th intercostal space using the loud percussion method along the middle phalanx of the pleximeter finger	
195	As a hammer, use the middle finger of the right hand bent in the proximal and distal interphalangeal joints so that its terminal phalanx is perpendicular to the surface of the middle phalanx of the middle finger of the left hand	
196	Tap on the center of this phalanx, the movement of tapping should come from the right wrist	
197	Short taps, equal strength, two at each point of percussion	
198	The interphalangeal joints of the middle finger, elbow and shoulder joints of the right hand remain motionless	
199	After the second tap, the hammer finger should not remain pressed against the pleximeter finger	
200	Compare the percussion sound, make the conclusion (if the percussion sound is the same on the right and left or not)	
201	When the percussion sound is shortened in the 6 th intercostal space, percussion is stopped, in the absence of shortening, the percussion is continued in the 7 th intercostal space	
Completion of the procedure		
202	Make a conclusion about the results of the percussion: on comparative percussion of the lungs, a clear pulmonary sound is heard (tympanic, hyperresonant, dullness, fatness (absolute dullness))	
203	Over symmetrical sections of the lungs the percussion sound is the same / not the same	
204	Thank the patient	
205	Ask the patient to get dressed	
206	Perform hand hygiene	
Total points _____ (minimum 144 points)		Mark

Full name of the teacher _____ Signature _____

8.2. COMPARATIVE PERCUSSION OF THE LUNG AT POSTERIOR CHEST SURFACE

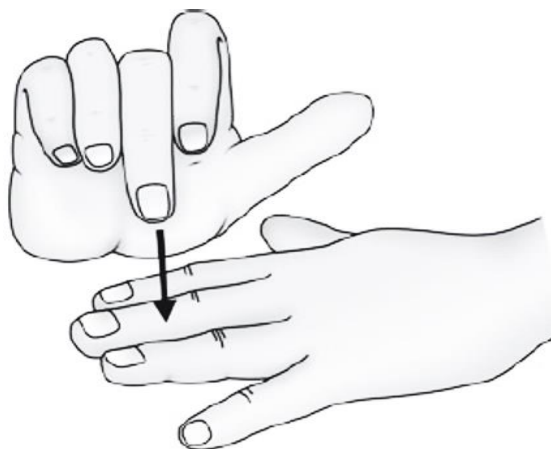


Fig. 31. Percussion technique

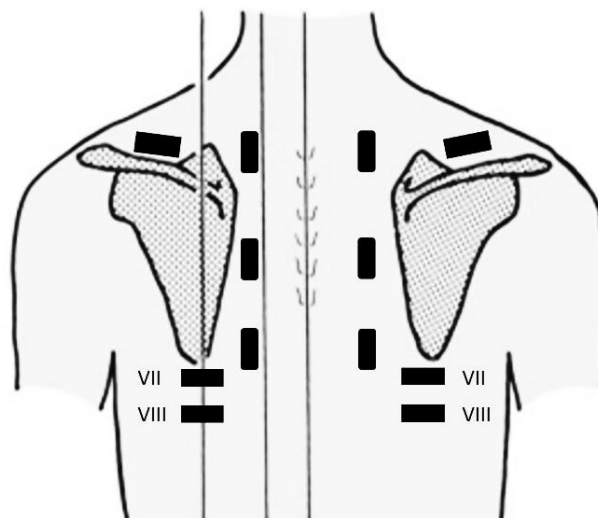


Fig. 32. Comparative percussion at posterior chest surface (points 15–130). Black lines indicate the location of pleximeter finger

PRACTICAL SKILL SCORECARD

Surname, Name _____ Group ____ Date _____

No	Compliance criteria	1 — done 0 — not done
Preparatory stage		
1	Greet the patient	
2	Introduce yourself to the patient	
3	Ask the patient's full name	
4	Ask the patient's age	
5	Ask about the patient's condition at the beginning of the examination	
6	Tell the patient the name of the examination method "Comparative percussion of the lung at posterior chest surface"	
7	Get the patient's informed consent for the examination	
8	Ask the patient to take off his clothing from his chest	
9	Ask the patient to take a vertical position and turn back to the researcher	
10	Ask the patient to cross arms to shoulder ("hug" themselves)	
11	Ask the patient to relax the shoulder muscles	
12	Ask the patient to breathe calmly and evenly	
13	Ask the patient about any pain in the chest	
14	Perform hand hygiene	

Main stage		
<i>Comparative percussion in the fossa supraspinatus area</i>		
15	Place the palm of the left hand on the surface of the patient's body so that the middle of the distal phalanx of the middle finger corresponds to the intended point of percussion	
16	Place the pleximeter finger horizontally on the left in the middle of the supraspinatus area	
17	Press the pleximeter finger tightly to the skin along the right mid-clavicular line	
18	Place II and IV fingers apart, they do not touch the pleximeter finger	
19	Perform percussion using the loud percussion method in the left supraspinatus fossa	
20	As a hammer, use the middle finger of the right hand bent in the proximal and distal interphalangeal joints so that its terminal phalanx is perpendicular to the surface of the distal phalanx of the middle finger of the left hand	
21	Tap on the center of this phalanx, the movement of tapping should come from the right wrist	
22	Short taps, equal strength, two at each point of percussion	
23	The interphalangeal joints of the middle finger, elbow and shoulder joints of the right hand remain motionless	
24	After the second tap, the hammer finger should not remain pressed against the pleximeter finger	
25	Move the pleximeter finger horizontally to the middle of the right supraspinatus fossa	
26	Press the pleximeter finger tightly to the skin	
27	Place II and IV fingers apart, they do not touch the pleximeter finger	
28	Perform percussion using the loud percussion method in the right supraspinatus fossa	
29	As a hammer, use the middle finger of the right hand bent in the proximal and distal interphalangeal joints so that its terminal phalanx is perpendicular to the surface of the distal phalanx of the middle finger of the left hand	
30	Tap on the center of this phalanx, the movement of tapping should come from the right wrist	
31	Short taps, equal strength, two at each point of percussion	
32	The interphalangeal joints of the middle finger, elbow and shoulder joints of the right hand remain motionless	
33	After the second tap, the hammer finger should not remain pressed against the pleximeter finger	
34	Compare the percussion sound, make the conclusion (if the percussion sound is the same on the right and left or not)	
<i>Comparative percussion at the level of the upper angle of the scapula</i>		
35	Place the palm of the left hand on the surface of the patient's body so that the middle of the distal phalanx of the middle finger corresponds to the intended point of percussion	

36	Place the pleximeter finger vertically at the level of the upper corner of the scapula on the left	
37	Press the pleximeter finger tightly to the skin along the right mid-clavicular line	
38	Place II and IV fingers apart, they do not touch the pleximeter finger	
39	Perform percussion using the loud percussion method at the level of the upper corner of the scapula on the left	
40	As a hammer, use the middle finger of the right hand bent in the proximal and distal interphalangeal joints so that its terminal phalanx is perpendicular to the surface of the distal phalanx of the middle finger of the left hand	
41	Tap on the center of this phalanx, the movement of tapping should come from the right wrist	
42	Short taps, equal strength, two at each point of percussion	
43	The interphalangeal joints of the middle finger, elbow and shoulder joints of the right hand remain motionless	
44	After the second tap, the hammer finger should not remain pressed against the pleximeter finger	
45	Place the pleximeter finger vertically at the level of the upper corner of the scapula on the right	
46	Press the pleximeter finger tightly to the skin	
47	Place II and IV fingers apart, they do not touch the pleximeter finger	
48	Perform percussion using loud percussion method	
49	As a hammer, use the middle finger of the right hand bent in the proximal and distal interphalangeal joints so that its terminal phalanx is perpendicular to the surface of the distal phalanx of the middle finger of the left hand	
50	Tap on the center of this phalanx, the movement of tapping should come from the right wrist	
51	Short taps, equal strength, two at each point of percussion	
52	The interphalangeal joints of the middle finger, elbow and shoulder joints of the right hand remain motionless	
53	After the second tap, the hammer finger should not remain pressed against the pleximeter finger	
54	Compare the percussion sound, make the conclusion (if the percussion sound is the same on the right and left or not)	
<i>Comparative percussion along the medial edge of the scapula (middle level)</i>		
55	Place the palm of the left hand on the surface of the patient's body so that the middle of the distal phalanx of the middle finger corresponds to the intended point of percussion	
56	Place the pleximeter finger vertically on the left near the medial edge of the scapula on the level of its middle	
57	Press the pleximeter finger tightly to the skin	
58	Place II and IV fingers apart, they do not touch the pleximeter finger	
59	Perform percussion using the loud percussion method	

60	As a hammer, use the middle finger of the right hand bent in the proximal and distal interphalangeal joints so that its terminal phalanx is perpendicular to the surface of the distal phalanx of the middle finger of the left hand	
61	Tap on the center of this phalanx, the movement of tapping should come from the right wrist	
62	Short taps, equal strength, two at each point of percussion	
63	The interphalangeal joints of the middle finger, elbow and shoulder joints of the right hand remain motionless	
64	After the second tap, the hammer finger should not remain pressed against the pleximeter finger	
65	Place the pleximeter finger vertically on the right near the medial edge of the scapula on the level of its middle	
66	Press the pleximeter finger tightly to the skin	
67	Place II and IV fingers apart, they do not touch the pleximeter finger	
68	Perform percussion using the loud percussion method	
69	As a hammer, use the middle finger of the right hand bent in the proximal and distal interphalangeal joints so that its terminal phalanx is perpendicular to the surface of the distal phalanx of the middle finger of the left hand	
70	Tap on the center of this phalanx, the movement of tapping should come from the right wrist	
71	Short taps, equal strength, two at each point of percussion	
72	The interphalangeal joints of the middle finger, elbow and shoulder joints of the right hand remain motionless	
73	After the second tap, the hammer finger should not remain pressed against the pleximeter finger	
74	Compare the percussion sound, make the conclusion (if the percussion sound is the same on the right and left or not)	
<i>Comparative percussion along the medial edge of the scapula (low level)</i>		
75	Place the palm of the left hand on the surface of the patient's body so that the middle of the distal phalanx of the middle finger corresponds to the intended point of percussion	
76	Place the pleximeter finger vertically on the left near the medial edge of the scapula on the level of the lower angle	
77	Press the pleximeter finger tightly to the skin	
78	Place II and IV fingers apart, they do not touch the pleximeter finger	
79	Perform percussion using the loud percussion method	
80	As a hammer, use the middle finger of the right hand bent in the proximal and distal interphalangeal joints so that its terminal phalanx is perpendicular to the surface of the distal phalanx of the middle finger of the left hand	
81	Tap on the center of this phalanx, the movement of tapping should come from the right wrist	
82	Short taps, equal strength, two at each point of percussion	

83	The interphalangeal joints of the middle finger, elbow and shoulder joints of the right hand remain motionless	
84	After the second tap, the hammer finger should not remain pressed against the pleximeter finger	
85	Place the pleximeter finger vertically on the right near the medial edge of the scapula on the level of its down angle	
86	Press the pleximeter finger tightly to the skin	
87	Place II and IV fingers apart, they do not touch the pleximeter finger	
88	Perform percussion using the loud percussion method	
89	As a hammer, use the middle finger of the right hand bent in the proximal and distal interphalangeal joints so that its terminal phalanx is perpendicular to the surface of the distal phalanx of the middle finger of the left hand	
90	Tap on the center of this phalanx, the movement of tapping should come from the right wrist	
91	Short taps, equal strength, two at each point of percussion	
92	The interphalangeal joints of the middle finger, elbow and shoulder joints of the right hand remain motionless	
93	After the second tap, the hammer finger should not remain pressed against the pleximeter finger	
94	Compare the percussion sound, make the conclusion (if the percussion sound is the same on the right and left or not)	
<i>Comparative percussion below the inferior angle of the scapula (7th intercostal space)</i>		
95	Place the palm of the left hand on the surface of the patient's body so that the middle of the distal phalanx of the middle finger corresponds to the intended point of percussion	
96	Place the pleximeter finger horizontally on the left below the down angle of the scapula (7 th intercostal space), press tightly to the skin	
97	Place II and IV fingers apart, they do not touch the pleximeter finger	
98	Perform percussion using the loud percussion method	
99	As a hammer, use the middle finger of the right hand bent in the proximal and distal interphalangeal joints so that its terminal phalanx is perpendicular to the surface of the distal phalanx of the middle finger of the left hand	
100	Tap on the center of this phalanx, the movement of tapping should come from the right wrist	
101	Short taps, equal strength, two at each point of percussion	
102	The interphalangeal joints of the middle finger, elbow and shoulder joints of the right hand remain motionless	
103	After the second tap, the hammer finger should not remain pressed against the pleximeter finger	
104	Place the pleximeter finger horizontally on the right below the down angle of the scapula (7 th intercostal space), press tightly to the skin	
105	Place II and IV fingers apart, they do not touch the pleximeter finger	

106	Perform percussion using the loud percussion method	
107	As a hammer, use the middle finger of the right hand bent in the proximal and distal interphalangeal joints so that its terminal phalanx is perpendicular to the surface of the distal phalanx of the middle finger of the left hand	
108	Tap on the center of this phalanx, the movement of tapping should come from the right wrist	
109	Short taps, equal strength, two at each point of percussion	
110	The interphalangeal joints of the middle finger, elbow and shoulder joints of the right hand remain motionless	
111	After the second tap, the hammer finger should not remain pressed against the pleximeter finger	
112	Compare the percussion sound, make the conclusion (if the percussion sound is the same on the right and left or not)	
<i>Comparative percussion in the 8th intercostal space</i>		
113	Place the palm of the left hand on the surface of the patient's body so that the middle of the distal phalanx of the middle finger corresponds to the intended point of percussion	
114	Place the pleximeter finger horizontally on the left in the 8 th intercostal space, press tightly to the skin	
115	Place II and IV fingers apart, they do not touch the pleximeter finger	
116	Perform percussion using the loud percussion method	
117	As a hammer, use the middle finger of the right hand bent in the proximal and distal interphalangeal joints so that its terminal phalanx is perpendicular to the surface of the distal phalanx of the middle finger of the left hand	
118	Tap on the center of this phalanx, the movement of tapping should come from the right wrist	
119	Short taps, equal strength, two at each point of percussion	
120	The interphalangeal joints of the middle finger, elbow and shoulder joints of the right hand remain motionless	
121	After the second tap, the hammer finger should not remain pressed against the pleximeter finger	
122	Place the pleximeter finger horizontally on the right in the 8 th intercostal space, press tightly to the skin	
123	Place II and IV fingers apart, they do not touch the pleximeter finger	
124	Perform percussion using the loud percussion method	
125	As a hammer, use the middle finger of the right hand bent in the proximal and distal interphalangeal joints so that its terminal phalanx is perpendicular to the surface of the distal phalanx of the middle finger of the left hand	
126	Tap on the center of this phalanx, the movement of tapping should come from the right wrist	
127	Short taps, equal strength, two at each point of percussion	
128	The interphalangeal joints of the middle finger, elbow and shoulder joints of the right hand remain motionless	

129	After the second tap, the hammer finger should not remain pressed against the pleximeter finger	
130	Compare the percussion sound, make the conclusion (if the percussion sound is the same on the right and left or not)	
Completion of the procedure		
131	Make a conclusion about the results of the percussion: on comparative percussion of the lungs, a clear pulmonary sound is heard (tympanic, hyperresonant, dullness, fatness (absolute dullness)).	
132	Over symmetrical sections of the lungs the percussion sound is the same / not the same	
133	Thank the patient	
134	Ask the patient to get dressed	
135	Perform hand hygiene	
Total points _____ (minimum 95 points)		Mark

Full name of the teacher _____ Signature _____

Assessment the inferior border of lungs (scorecards 9.1 and 9.2)

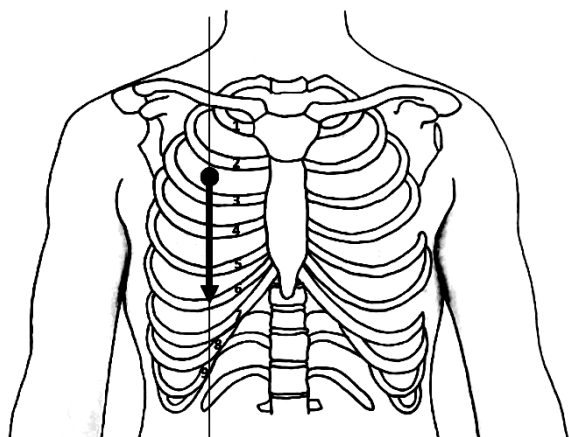


Fig. 33. Percussion on right mid-clavicular line. Arrow indicates the direction of percussion

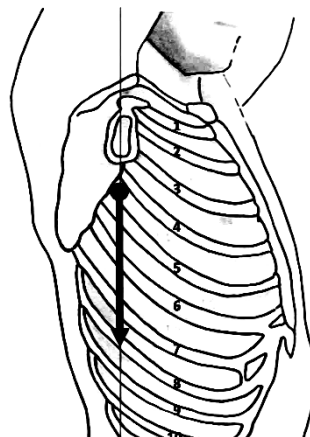


Fig. 34. Percussion on right mid-axillary line. Arrow indicates the direction of percussion

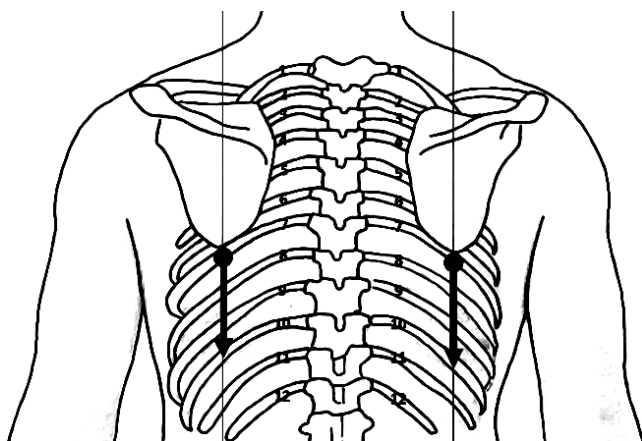


Fig. 35. Percussion on scapular lines. Arrows indicate the direction of percussion

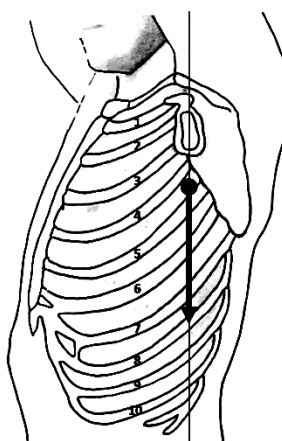


Fig. 36. Percussion on left mid-axillary line. Arrow indicates the direction of percussion

9.1. ASSESSMENT THE INFERIOR BORDER OF RIGHT LUNG

PRACTICAL SKILL SCORECARD

Surname, Name _____ Group ____ Date _____

No	Compliance criteria	1 — done 0 — not done
Preparatory stage		
1	Greet the patient	
2	Introduce yourself to the patient	
3	Ask the patient's full name	

4	Ask the patient's age	
5	Ask about the patient's condition at the beginning of the examination	
6	Tell the patient the name of the examination method "Assessment the inferior border of right lung"	
7	Get the patient's informed consent for the examination	
8	Ask the patient to take off his clothing from his chest	
9	Ask the patient to take a vertical position facing the source of daylight	
10	Ask the patient to put his arms down	
11	Ask the patient to relax the shoulder muscles	
12	Ask the patient to breathe calmly and evenly	
13	Ask the patient about any pain in the chest	
14	Perform hand hygiene	
Main stage		
<i>Percussion on right mid-clavicular line</i>		
15	Stand to the right opposite the right half of the patient's chest, facing the patient	
16	Ask the patient to turn his head to the left	
17	The palm of the left hand is placed on the surface of the patient's body so that the middle of the middle phalanx of the pleximeter finger corresponds to the intended point of percussion	
18	Press the pleximeter finger tightly on the skin along the right mid-clavicular line in the 2 nd intercostal space	
19	Place II and IV fingers apart, they do not touch the pleximeter finger	
20	Perform percussion using the quiet percussion method	
21	As a hammer, use the middle finger of the right hand bent in the proximal and distal interphalangeal joints so that its end phalanx is located perpendicular to the surface of the middle phalanx of the pleximeter finger of the left hand	
22	Tap on the center of this phalanx, the movement of tapping should come from the right wrist	
23	Short taps, equal strength, two at each point of percussion	
24	The interphalangeal joints of the middle finger, elbow and shoulder joints of the right hand remain motionless	
25	After the second tap, the hammer finger should not remain pressed against the pleximeter finger	
26	Continue percussion down using the quiet percussion method	
27	Slide the pleximeter finger down by the width of the pleximeter finger	
28	Stop the percussion when the dull sound appears	
29	Apply a mark with a dermatograph without removing your pleximeter finger	
30	The mark should be applied from the side of a clear pulmonary sound	
31	Mark the found border (normally the 6 th rib)	
<i>Percussion on right mid-axillary line</i>		
32	Ask the patient to place both hands on the back of the head	
33	Stand at the right part of the patient's chest	

34	Ask the patient to turn his head to the left	
35	The palm of the left hand is placed on the surface of the patient's body so that the middle of the middle phalanx of the pleximeter finger corresponds to the intended point of percussion	
36	Press the pleximeter finger tightly on the skin along the right mid-axillary line in the 4 th intercostal space	
37	Place II and IV fingers apart, they do not touch the pleximeter finger	
38	Perform percussion using the quiet percussion method in the right axillary region from the 4 th intercostal space along the mid-axillary line	
39	As a hammer, use the middle finger of the right hand bent in the proximal and distal interphalangeal joints so that its end phalanx is located perpendicular to the surface of the middle phalanx of the pleximeter finger of the left hand	
40	Tap on the center of this phalanx, the movement of tapping should come from the right wrist	
41	Short taps, equal strength, two at each point of percussion	
42	The interphalangeal joints of the middle finger, elbow and shoulder joints of the right hand remain motionless	
43	After the second tap, the hammer finger should not remain pressed against the pleximeter finger	
44	Continue percussion down using the quiet percussion method	
45	Slide the pleximeter finger down by the width of the pleximeter finger	
46	Stop the percussion when the dull sound appears	
47	Apply a mark with a dermatograph without removing your pleximeter finger	
48	The mark should be applied from the side of a clear pulmonary sound	
49	Mark the found border (normally the 8 th rib)	
<i>Percussion on right scapular line</i>		
51	Ask the patient to turn his back to the examiner (back to the light)	
52	Ask the patient to put his arms down	
53	The palm of the left hand is placed on the surface of the patient's body so that the middle of the middle phalanx of the pleximeter finger corresponds to the intended point of percussion	
54	Press the pleximeter finger horizontally tightly on the skin along the right scapular line below the lower angle of the scapula (at the level of the 7 th rib)	
55	Place II and IV fingers apart, they do not touch the pleximeter finger	
56	Perform percussion using the quiet percussion method along the right scapular line below the lower angle of the scapula	
57	As a hammer, use the middle finger of the right hand bent in the proximal and distal interphalangeal joints so that its end phalanx is located perpendicular to the surface of the middle phalanx of the pleximeter finger of the left hand	

58	Tap on the center of this phalanx, the movement of tapping should come from the right wrist	
59	Short taps, equal strength, two at each point of percussion	
60	The interphalangeal joints of the middle finger, elbow and shoulder joints of the right hand remain motionless	
61	After the second tap, the hammer finger should not remain pressed against the pleximeter finger	
62	Continue percussion down using the quiet percussion method	
63	Slide the pleximeter finger down by the width of the pleximeter finger	
64	Stop the percussion when the dull sound appears	
65	Apply a mark with a dermatograph without removing your pleximeter finger	
66	The mark should be applied from the side of a clear pulmonary sound	
67	Mark the found border (normally the 10 th rib)	
Completion of the procedure		
68	Make a conclusion: present the inferior borders of the lungs along the examined lines	
69	Thank the patient	
70	Ask the patient to get dressed	
71	Perform hand hygiene	
Total points _____ (minimum 76 points)		Mark

Full name of the teacher _____ Signature _____

9.2. ASSESSMENT THE INFERIOR LUNG BORDER OF LEFT LUNG

PRACTICAL SKILL SCORECARD

Surname, Name _____ Group ____ Date _____

№	Compliance criteria	1 — done 0 — not done
Preparatory stage		
1	Greet the patient	
2	Introduce yourself to the patient	
3	Ask the patient's full name	
4	Ask the patient's age	
5	Ask about the patient's condition at the beginning of the examination	
6	Tell the patient the name of the examination method "Assessment the inferior border of left lung"	
7	Get the patient's informed consent for the examination	

8	Ask the patient to take off his clothing from his chest	
9	Ask the patient to take a vertical position facing the source of daylight	
10	Ask the patient to put his arms down	
11	Ask the patient to relax the shoulder muscles	
12	Ask the patient to breathe calmly and evenly	
13	Ask the patient about any pain in the chest	
14	Perform hand hygiene	
Main stage		
<i>Percussion on the left mid-axillary line</i>		
15	Ask the patient to place both hands on the back of the head	
16	Stand at the left part of the patient's chest	
17	Ask the patient to turn his head to the left	
18	The palm of the left hand is placed on the surface of the patient's body so that the middle of the middle phalanx of the pleximeter finger corresponds to the intended point of percussion	
19	Press the pleximeter finger tightly on the skin along the left mid-axillary line in the 4 nd intercostal space	
20	Place II and IV fingers apart, they do not touch the pleximeter finger	
21	Perform percussion using the quiet percussion method in the left axillary region from the 4 th intercostal space along the mid-axillary line	
22	As a hammer, use the middle finger of the right hand bent in the proximal and distal interphalangeal joints so that its end phalanx is located perpendicular to the surface of the middle phalanx of the pleximeter finger of the left hand	
23	Tap on the center of this phalanx, the movement of tapping should come from the right wrist	
24	Short taps, equal strength, two at each point of percussion	
25	The interphalangeal joints of the middle finger, elbow and shoulder joints of the right hand remain motionless	
26	After the second tap, the hammer finger should not remain pressed against the pleximeter finger	
27	Continue percussion down using the quiet percussion method	
28	Slide the pleximeter finger down by the width of the pleximeter finger	
29	Stop the percussion when the dull sound appears	
30	Apply a mark with a dermatograph without removing your pleximeter finger	
31	The mark should be applied from the side of a clear pulmonary sound	
32	Mark the found border (normally the 8 th rib)	
<i>Percussion on the left scapular line</i>		
33	Ask the patient to turn back to the researcher	
34	Press the pleximeter finger horizontally tightly on the skin along the left scapular line below the lower angle of the scapula (at the level of the 7 th rib)	
35	Place II and IV fingers apart, they do not touch the pleximeter finger	

36	Perform percussion using the quiet percussion method along the left scapular line below the lower angle of the scapula	
37	As a hammer, use the middle finger of the right hand bent in the proximal and distal interphalangeal joints so that its end phalanx is located perpendicular to the surface of the middle phalanx of the pleximeter finger of the left hand	
38	Tap on the center of this phalanx, the movement of tapping should come from the right wrist	
39	Short taps, equal strength, two at each point of percussion	
40	The interphalangeal joints of the middle finger, elbow and shoulder joints of the right hand remain motionless	
41	After the second tap, the hammer finger should not remain pressed against the pleximeter finger	
42	Continue percussion down using the quiet percussion method	
43	Slide the pleximeter finger down by the width of the pleximeter finger	
44	Stop the percussion when the dull sound appears	
45	Apply a mark with a dermograph without removing your pleximeter finger	
46	The mark should be applied from the side of a clear pulmonary sound	
47	Mark the found border (normally 10 rib)	
Completion of the procedure		
48	Make a conclusion: present the inferior borders of the lungs along the examined lines	
49	Thank the patient	
50	Ask the patient to get dressed	
51	Perform hand hygiene	
Total points _____ (minimum 36 points)		Mark

Full name of the teacher _____ Signature _____

10. AUSCULTATION OF THE LUNGS



Fig. 37. Correct position of the fingers on the head of stethoscope

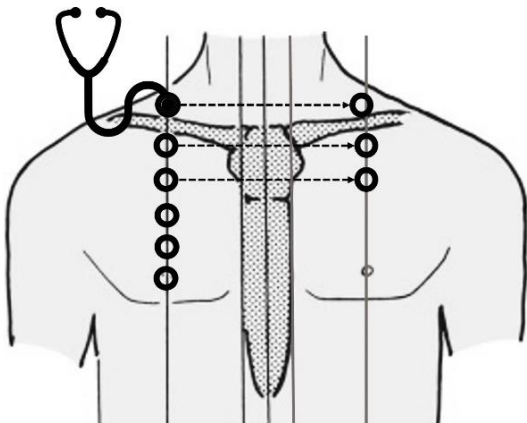


Fig. 38. Auscultation points on anterior chest surface (points 20–47)

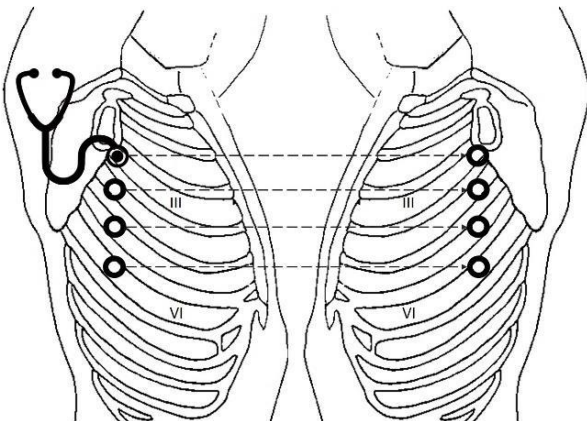


Fig. 39. Auscultation points on lateral chest surface (points 51–74)

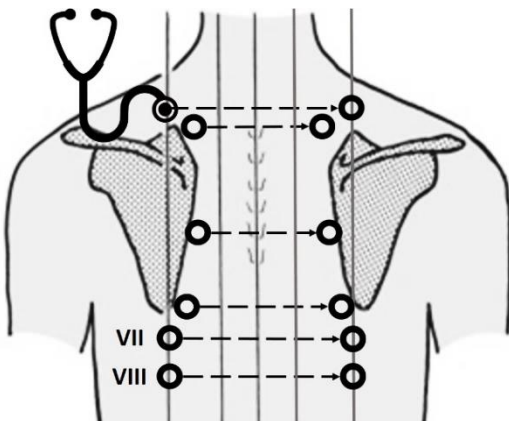


Fig. 40. Auscultation points on posterior chest surface (points 77–112)

PRACTICAL SKILL SCORECARD

Surname, Name _____ Group _____ Date _____

№	Compliance criteria	1 — done 0 — not done
Preparatory stage		
1	Greet the patient	
2	Introduce yourself to the patient	
3	Ask the patient's full name	
4	Ask the patient's age	
5	Ask about the patient's condition at the beginning of the examination	
6	Tell the patient the name of the examination method "Auscultation of the lungs"	
7	Get the patient's informed consent for the examination	
8	Ask the patient to take off his clothing from his chest	
9	Ask the patient to take a vertical position facing the source of daylight	
10	Ask the patient to put his arms down	
11	Ask the patient to breathe through the nose calmly and evenly	
12	Perform hand hygiene	
13	Clean the diaphragm of the stethoscope with an antiseptic solution	
14	Insert the ear tips of the stethoscope into the ears	
15	Make sure that the device is switched to the stethoscope diaphragm	
Main stage		
<i>Auscultation of anterior surface of the chest</i>		
16	Stand to the right opposite the right half of the patient's chest, facing the patient	
17	Ask the patient to turn head to the left	
18	Place the head of the stethoscope between the 1st and 2nd fingers of the hand	
19	Place the head of the stethoscope on the right supraclavicular fossa along the right mid-clavicular line	
20	The head of the stethoscope is firmly pressed against the skin, the researcher's fingers do not touch the patient's skin	
21	Listen to the patient's complete breathing cycle (inhalation and exhalation)	
22	Place the head of the stethoscope on the left supraclavicular fossa along the left mid-clavicular line	
23	The head of the stethoscope is firmly pressed against the skin, the researcher's fingers do not touch the patient's skin	
24	Listen to the patient's complete breathing cycle (inhalation and exhalation)	
25	Place the head of the stethoscope on the right subclavicular fossa along the right mid-clavicular line	

26	The head of the stethoscope is firmly pressed against the skin, the researcher's fingers do not touch the patient's skin	
27	Listen to the patient's complete breathing cycle (inhalation and exhalation)	
28	Place the head of the stethoscope on the left subclavicular fossa along the left mid-clavicular line	
29	The head of the stethoscope is firmly pressed against the skin, the researcher's fingers do not touch the patient's skin	
30	Listen to the patient's complete breathing cycle (inhalation and exhalation)	
31	Place the head of the stethoscope on the right 2 nd intercostal space along the right mid-clavicular line	
32	The head of the stethoscope is firmly pressed against the skin, the researcher's fingers do not touch the patient's skin	
33	Listen to the patient's complete breathing cycle (inhalation and exhalation)	
34	Place the head of the stethoscope on the left 2 nd intercostal space along the left mid-clavicular line	
35	The head of the stethoscope is firmly pressed against the skin, the researcher's fingers do not touch the patient's skin	
36	Listen to the patient's complete breathing cycle (inhalation and exhalation)	
37	Place the head of the stethoscope on the right 3 rd intercostal space along the right mid-clavicular line	
39	The head of the stethoscope is firmly pressed against the skin, the researcher's fingers do not touch the patient's skin	
40	Listen to the patient's complete breathing cycle (inhalation and exhalation)	
41	Place the head of the stethoscope on the right 4 th intercostal space along the right mid-clavicular line	
42	The head of the stethoscope is firmly pressed against the skin, the researcher's fingers do not touch the patient's skin	
43	Listen to the patient's complete breathing cycle (inhalation and exhalation)	
44	Place the head of the stethoscope on the right 5 th intercostal space along the right mid-clavicular line	
45	The head of the stethoscope is firmly pressed against the skin, the researcher's fingers do not touch the patient's skin	
46	Listen to the patient's complete breathing cycle (inhalation and exhalation)	
<i>Auscultation of lateral surfaces of the chest</i>		
48	Ask the patient to place both hands on the back of the head	
49	Stand opposite of the patient's chest, facing the patient	
50	Ask the patient to turn head to the left	


51	Place the head of the stethoscope on the right 3 rd intercostal space along the right mid-axillary line	
52	The head of the stethoscope is firmly pressed against the skin, the researcher's fingers do not touch the patient's skin	
53	Listen to the patient's complete breathing cycle (inhalation and exhalation)	
54	Place the head of the stethoscope on the left 3 rd intercostal space along the left mid-axillary line	
55	The head of the stethoscope is firmly pressed against the skin, the researcher's fingers do not touch the patient's skin	
56	Listen to the patient's complete breathing cycle (inhalation and exhalation)	
57	Place the head of the stethoscope on the right 4 th intercostal space along the right mid-axillary line	
58	The head of the stethoscope is firmly pressed against the skin, the researcher's fingers do not touch the patient's skin	
59	Listen to the patient's complete breathing cycle (inhalation and exhalation)	
60	Place the head of the stethoscope on the left 4 th intercostal space along the left mid-axillary line	
61	The head of the stethoscope is firmly pressed against the skin, the researcher's fingers do not touch the patient's skin	
62	Listen to the patient's complete breathing cycle (inhalation and exhalation)	
63	Place the head of the stethoscope on the right 5 th intercostal space along the right mid-axillary line	
64	The head of the stethoscope is firmly pressed against the skin, the researcher's fingers do not touch the patient's skin	
65	Listen to the patient's complete breathing cycle (inhalation and exhalation)	
66	Place the head of the stethoscope on the left 5 th intercostal space along the left mid-axillary line	
67	The head of the stethoscope is firmly pressed against the skin, the researcher's fingers do not touch the patient's skin	
68	Listen to the patient's complete breathing cycle (inhalation and exhalation)	
69	Place the head of the stethoscope on the right 6 th intercostal space along the right mid-axillary line	
70	The head of the stethoscope is firmly pressed against the skin, the researcher's fingers do not touch the patient's skin	
71	Listen to the patient's complete breathing cycle (inhalation and exhalation)	
72	Place the head of the stethoscope on the left 6 th intercostal space along the left mid-axillary line	
73	The head of the stethoscope is firmly pressed against the skin, the researcher's fingers do not touch the patient's skin	

74	Listen to the patient's complete breathing cycle (inhalation and exhalation)	
<i>Auscultation of posterior surfaces of the chest</i>		
75	Ask the patient to turn back to the researcher	
76	Ask the patient to cross their arms over their chest ("hug" themselves)	
77	Place the head of the stethoscope on the left supraspinatus fossa on the left scapular line	
78	The head of the stethoscope is firmly pressed against the skin, the researcher's fingers do not touch the patient's skin	
79	Listen to the patient's complete breathing cycle (inhalation and exhalation)	
80	Place the head of the stethoscope on the right supraspinatus fossa on the right scapular line	
81	The head of the stethoscope is firmly pressed against the skin, the researcher's fingers do not touch the patient's skin	
82	Listen to the patient's complete breathing cycle (inhalation and exhalation)	
83	Place the head of the stethoscope on the left at the level of the medial edge of upper scapula angle	
84	The head of the stethoscope is firmly pressed against the skin, the researcher's fingers do not touch the patient's skin	
85	Listen to the patient's complete breathing cycle (inhalation and exhalation)	
86	Place the head of the stethoscope on the right at the level of the medial edge of upper scapula angle	
87	The head of the stethoscope is firmly pressed against the skin, the researcher's fingers do not touch the patient's skin	
88	Listen to the patient's complete breathing cycle (inhalation and exhalation)	
89	Place the head of the stethoscope on the left at the level of the middle part of the scapula medial edge	
90	The head of the stethoscope is firmly pressed against the skin, the researcher's fingers do not touch the patient's skin	
91	Listen to the patient's complete breathing cycle (inhalation and exhalation)	
92	Place the head of the stethoscope on the right at the level of the middle part of the scapula medial edge	
93	The head of the stethoscope is firmly pressed against the skin, the researcher's fingers do not touch the patient's skin	
94	Listen to the patient's complete breathing cycle (inhalation and exhalation)	
95	Place the head of the stethoscope on the left at the level of the medial edge of inferior scapula angle	
96	The head of the stethoscope is firmly pressed against the skin, the researcher's fingers do not touch the patient's skin	

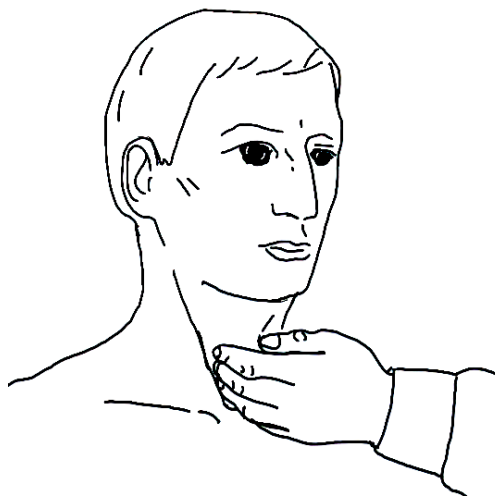
97	Listen to the patient's complete breathing cycle (inhalation and exhalation)	
98	Place the head of the stethoscope on the right at the level of the medial edge of inferior scapula angle	
99	The head of the stethoscope is firmly pressed against the skin, the researcher's fingers do not touch the patient's skin	
100	Listen to the patient's complete breathing cycle (inhalation and exhalation)	
101	Place the head of the stethoscope on the left scapular line in the 7 th intercostal space	
102	The head of the stethoscope is firmly pressed against the skin, the researcher's fingers do not touch the patient's skin	
103	Listen to the patient's complete breathing cycle (inhalation and exhalation)	
104	Place the head of the stethoscope on the right scapular line in the 7 th intercostal space	
105	The head of the stethoscope is firmly pressed against the skin, the researcher's fingers do not touch the patient's skin	
106	Listen to the patient's complete breathing cycle (inhalation and exhalation)	
107	Place the head of the stethoscope on the left scapular line in the 8 th intercostal space	
108	The head of the stethoscope is firmly pressed against the skin, the researcher's fingers do not touch the patient's skin	
109	Listen to the patient's complete breathing cycle (inhalation and exhalation)	
110	Place the head of the stethoscope on the right scapular line in the 8 th intercostal space	
111	The head of the stethoscope is firmly pressed against the skin, the researcher's fingers do not touch the patient's skin	
112	Listen to the patient's complete breathing cycle (inhalation and exhalation)	
Completion of the procedure		
113	Make a conclusion about the results of the lung's auscultation: on auscultation of the lungs over symmetrical areas vesicular breathing is heard (weakened, harsh, bronchial)	
114	Rales are heard / not heard	
115	Thank the patient	
116	Ask the patient to get dressed	
117	Perform hand hygiene	
Total points _____ (minimum 82 points)		Mark

Full name of the teacher _____ Signature _____

11. ASSESSMENT THE PULSE ON THE RADIAL, CAROTID ARTERIES AND DORSALIS PEDIS ARTERIES



*Fig. 41. Pulse palpation on radial artery
(points 14–28)*



*Fig. 42. Pulse palpation on carotid artery
(points 32–41)*

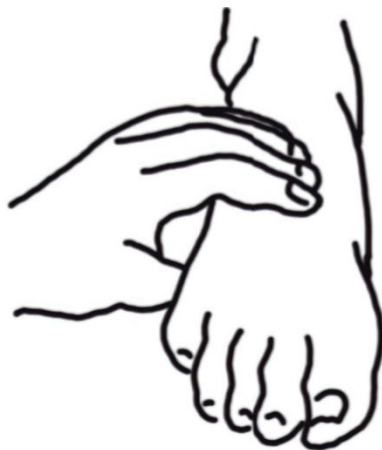

Fig. 43. Pulse palpation on a. dorsalis pedis (points 44–47)

PRACTICAL SKILL SCORECARD

Surname, Name _____ Group _____ Date _____

№	Compliance criteria	1 — done 0 — not done
Preparatory stage		
1	Greet the patient	
2	Introduce yourself to the patient	
3	Ask the patient's full name	
4	Ask the patient's age	
5	Ask about the patient's condition at the beginning of the examination	

6	Tell the patient the name of the examination method “Assessment the pulse on the radial, carotid arteries and dorsalis pedis arteries”	
7	Get the patient’s informed consent for the examination	
8	Ask the patient to take off his clothing from his chest	
9	Ask the patient to relax the shoulder muscles	
10	Ask the patient to breathe calmly and evenly	
11	Perform hand hygiene (gloves are needed to dorsalis pedis arteries palpation)	
Main stage		
<i>Assessment the pulse on the radial arteries</i>		
12	Ask the patient to place his forearms and hands on the table with palms up	
13	Ask the patient to relax hands	
14	With the fingers of both hands, cover both patient’s forearms close to the wrist joint (the thumb is located on the back surface of the wrist joint, II–IV fingers above the radial artery)	
15	Define the pulse on both hands (take the patient’s right hand with your left hand, and the left hand with your right hand)	
16	Define the symmetry of both radial arteries pulsation by volume	
17	Make the conclusion: pulse is symmetrical / not symmetrical (pulse volume is the same / not the same on both hands)	
18	Further the pulse is determined only on one hand	
19	Compare the uniformity of intervals between pulse waves (pulse rhythm)	
20	Make the conclusion: pulse is regular / irregular	
21	Define the pulse rate using a stopwatch or a watch with a second hand	
22	If the pulse irregular, the count is performed within 15 seconds and the result is multiplied by 4. If the pulse is irregular, the count is performed within 1 minute	
23	Press III–IV fingers proximally on the radial artery and hold until the pulsation disappears	
24	With the II finger palpate the radial artery fixing the moment of its disappearance and determining the degree of required pressure with III–IV fingers (pulse tension)	
25	Make the conclusion: pulse is symmetrical / not symmetrical (pulse volume is the same / not the same on both hands)	
26	Pulse is regular / irregular	
27	Heart rate per minute (normally 60–90 beats per minute)	
28	Pulse tension (moderate / hard / soft)	
<i>Assessment the pulse on the carotid arteries</i>		
29	Examine the neck area, assess the visible pulsation	
30	Make a conclusion: carotid artery pulsation is visible / not visible	
31	Check the pulse alternately on each side without applying strong pressure on the artery	

32	Ask the patient to turn his head to the right to palpate the left carotid artery	
33	Tips of II–IV fingers of right hand are placed at the inner edge of the sternocleidomastoid muscle on the left side at the level of the upper edge of the thyroid cartilage	
34	Slightly push the inner edge of the sternocleidomastoid muscle outward and apply light pressure to define the pulsating carotid artery	
35	To palpate the right carotid artery, ask the patient to turn his head to the left	
36	Tips of II–IV fingers of right hand are placed at the inner edge of the sternocleidomastoid muscle on the right at the level of the upper edge of the thyroid cartilage	
37	Slightly push the inner edge of the sternocleidomastoid muscle outward and use light pressure to define the pulsating carotid artery	
38	Compare pulse waves in volume and rhythm	
39	Make the conclusion: the pulse on the right and left carotid arteries is palpable / not palpable	
40	The pulse on the right and left carotid arteries is symmetrical / not symmetrical	
41	Carotid artery pulse is regular / irregular	
<i>Assessment the pulse on the dorsalis pedis artery</i>		
42	Put on the gloves	
43	Ask the patient to take off his shoes and socks	
44	Conduct examination simultaneously from both sides	
45	Tips of II–IV fingers should be placed on the back of the foot between the I and II metatarsal bones, parallel to them	
46	Compare volume of pulse waves on the feet with each other	
47	Make the conclusion (normally, the pulse wave is the same on both sides)	
Completion of the procedure		
48	Make the conclusion about the results of palpation: the pulse on the radial artery is symmetrical / not symmetrical; moderate / hard / soft tension; regular / irregular, pulse rate is ... per minute	
49	The pulse on the carotid arteries is symmetrical / not symmetrical	
50	The pulse on the dorsalis pedis artery is symmetrical / not symmetrical	
51	Thank the patient	
52	Ask the patient to get dressed	
53	Remove the gloves	
54	Perform hand hygiene	
Total points _____ (minimum 38 points)		Mark

Full name of the teacher _____ Signature _____

12. PALPATION OF THE APICAL IMPULSE

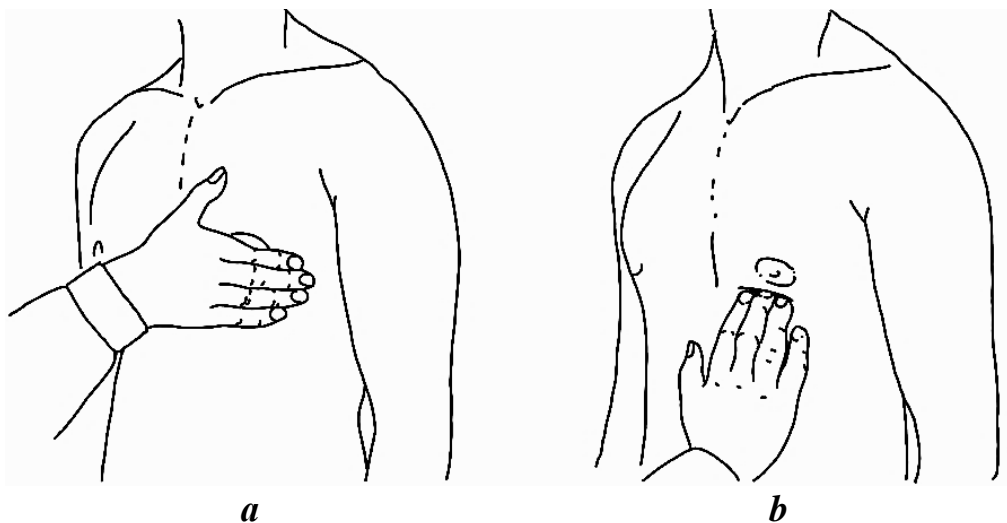


Fig. 44. Palpation of the apical impulse:
a — points 18–20; *b* — points 24–25

PRACTICAL SKILL SCORECARD

Surname, Name _____ Group ____ Date _____

№	Compliance criteria	1 — done 0 — not done
Preparatory stage		
1	Greet the patient	
2	Introduce yourself to the patient	
3	Ask the patient's full name	
4	Ask the patient's age	
5	Ask about the patient's condition at the beginning of the examination	
6	Tell the patient the name of the examination method "Palpation of the apical impulse"	
7	Get the patient's informed consent for the examination	
8	Ask the patient to take off his clothing from his chest	
9	Ask the patient to take a vertical position facing the source of daylight	
10	Ask the patient to put his arms down	
11	Ask the patient to relax the shoulder muscles	
12	Ask the patient to breathe calmly and evenly	
13	Ask the patient if he feels pain in the chest	
14	Perform hand hygiene (gloves are optional)	
Main stage		
15	Stand in front of the right half of the patient's chest, facing him	
16	Ask the patient to turn his head to the left	
17	Examine the patient's chest for visible pulsation in the apical impulse	

<i>Palpation of the apical impulse</i>		
18	Ask the patient to lean the upper half of the chest slightly forward	
19	Ask the patient to hold breath during expiration	
20	Put the palm of the right hand with closed and straight fingers flat on the patient's chest so that the base of the hand is lying at the left edge of the sternum, the thumb is positioned vertically on the sternum, and II–IV fingers are directed to the left axillary area, between the 4 and 7 ribs	
21	Bend II–IV fingers so that the distal phalanges are perpendicular to the chest surface	
22	Move the tips of the bent II–IV fingers along the intercostal space in the medial direction to the point where the fingers begin to feel pulsation if pressed with moderate force	
23	The base of the palm remains fixed on the sternum*	
24	If pulsation is detected, turn the closed tips of the II–IV fingers and place them horizontally along the pulsating area of the intercostal space	
25	Palpate the apical impulse for 5–10 seconds	
26	Allow the patient to breathe freely	
Completion of the procedure		
27	Make the conclusion: the apical impulse is visible / not visible	
28	Localization of the apical impulse (normally, the heart apex is located in the 5 th intercostal space 1–1.5 cm inside of the left midclavicular line)	
29	Define the width of the apical impulse (normally 2 cm)	
30	Define the apical impulse resistance (normally moderate)	
31	Thank the patient	
32	Ask the patient to get dressed	
33	Perform hand hygiene	
Total points _____ (minimum 23 points)		Mark

Full name of the teacher _____ Signature _____

* If the size of the researcher's hand and the patient's chest do not match, it is allowed to shift the base of the palm so that the tips of the II–IV fingers reach the left anterior axillary line.

13. ASSESSMENT OF THE RELATIVE HEART DULLNESS BORDERS

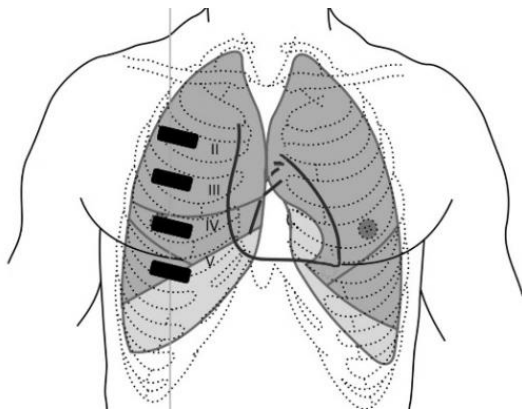


Fig. 45. Assessment of inferior border of right lung (points 22–36). Black lines indicate the location of pleximeter finger

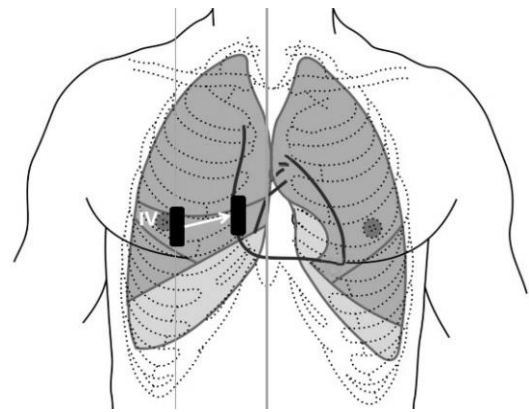


Fig. 46. Assessment of right border of the relative heart dullness (points 37–52). Black lines indicate the location of pleximeter finger

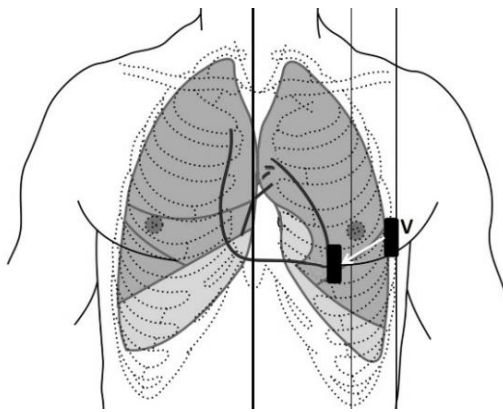


Fig. 47. Assessment of left border of the relative heart dullness (points 55–68). Black lines indicate the location of pleximeter finger

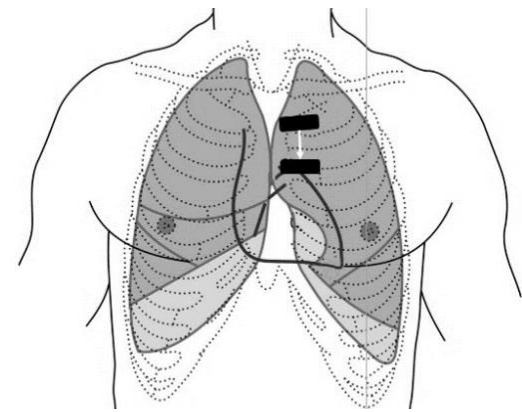


Fig. 48. Assessment of upper border of the relative heart dullness (points 72–86). Black lines indicate the location of pleximeter finger

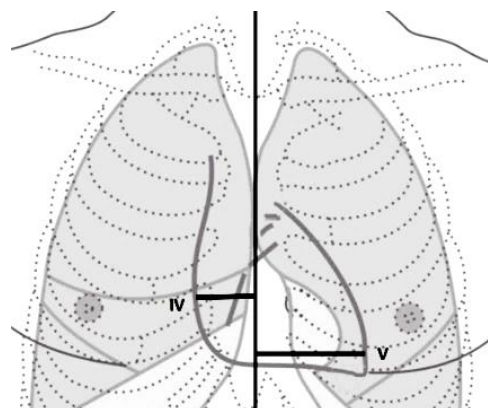


Fig. 49. Assessment of width of the relative heart dullness (points 87–88)

PRACTICAL SKILL SCORECARD

Surname, Name _____ Group ____ Date _____

№	Compliance criteria	1 — done 0 — not done
Preparatory stage		
1	Greet the patient	
2	Introduce yourself to the patient	
3	Ask the patient's full name	
4	Ask the patient's age	
5	Ask about the patient's condition at the beginning of the examination	
6	Tell the patient the name of the examination method "Assessment of the relative heart dullness borders"	
7	Get the patient's informed consent for the examination	
8	Ask the patient to take off his clothing from his chest	
9	Ask the patient to take a vertical position facing the source of daylight, and put his arms down	
10	Perform hand hygiene	
11	Stand near the patient, facing him	
Main stage		
<i>Palpation of apical impulse</i>		
12	Ask the patient to lean the upper half of the chest slightly forward	
13	Ask the patient to hold breath during expiration	
14	Put the palm of the right hand with closed straight fingers flat on the patient's chest so that the base of the hand is lying at the left edge of the sternum, the thumb is positioned vertically on the sternum, and the II–IV fingers are directed to the left axillary area, between the 4 and 7 ribs	
15	Bend the II–IV fingers so that the distal phalanges are perpendicular to the surface of the chest	
16	Move the tips of the bent II–IV fingers along the intercostal space in the medial direction to the point where the fingers begin to feel pulsation if pressed with moderate force	
17	The base of the palm remains fixed on the sternum*	
18	If pulsation is detected, turn the closed tips of the II–IV fingers and place them horizontally along the pulsating area of the intercostal space	
19	Perform palpation of the apical impulse for 5–10 seconds	
20	Allow the patient to breathe freely	
21	Make the conclusion about the localization of the apical impulse	
<i>Assessment of right border of the relative heart dullness**</i>		
22	The palm of the left hand is placed horizontally on the 2 nd right intercostal space	

23	Put the left hand middle part of the middle finger phalanx on the right midclavicular line	
24	Press the finger-pleximeter tightly on the skin	
25	Place II and IV fingers apart, they do not touch the pleximeter finger	
26	Perform percussion using the quiet percussion method down from the 2 nd intercostal space along the right midclavicular line	
27	As a hammer, use the middle finger of the right hand bent in the proximal and distal interphalangeal joints so that its end phalanx is located perpendicular to the surface of the middle phalanx of the pleximeter finger of the left hand	
28	Tap on the center of this phalanx, the movement of tapping should come from the right wrist	
29	Short taps, equal strength, two at each point of percussion	
30	The interphalangeal joints of the middle finger, elbow and shoulder joints of the right hand remain motionless	
31	After the second tap, the hammer finger should not remain pressed against the pleximeter finger	
32	Slide the finger-pleximeter down by the width of the finger-pleximeter	
33	Stop performing percussion when the dull sound appears	
34	Put a mark with a dermatograph without removing the finger-pleximeter	
35	The mark should be put from the side of a clear pulmonary sound	
36	Make the conclusion about the discovered borders (normally in 5 th intercostal space)	
37	Move the finger-pleximeter upwards for one intercostal space (from 5 th to 4 th)	
38	Place the finger-pleximeter vertically	
39	The middle phalanges of the finger-pleximeter correspond to the 4 th intercostal space on the right midclavicular line	
40	Press the finger-pleximeter tightly on the skin	
41	Place II and IV fingers apart, they do not touch the pleximeter finger	
42	As a hammer, use the middle finger of the right hand bent in the proximal and distal interphalangeal joints so that its end phalanx is located perpendicular to the surface of the middle phalanx of the pleximeter finger of the left hand	
43	Tap on the center of this phalanx, the movement of tapping should come from the right wrist	
44	Short taps, equal strength, two at each point of percussion	
45	The interphalangeal joints of the middle finger, elbow and shoulder joints of the right hand remain motionless	
46	After the second tap the hammer finger should not remain pressed against the finger-pleximeter	
47	Slide the finger-pleximeter by its width	
48	Perform percussion from the right midclavicular line to the sternum	
49	Perform percussion using the quiet percussion method	
50	Stop percussion when the dull sound appears	

51	Put the mark with a dermatograph without removing the finger-pleximeter	
52	The mark should be put from the side of the clear pulmonary sound	
53	Measure the distance between the found border and the anterior mid-line with a centimeter tape	
54	Make the conclusion about the result (normally the right border of the heart dullness is located 3–4 cm to the right of the anterior midline in the fourth intercostal space)	
<i>Assessment of left border of the relative heart dullness</i>		
55	Place the finger-pleximeter vertically on the left anterior axillary line	
56	The middle phalanges of the finger-pleximeter correspond to the heart apex (5 th intercostal space)	
57	Press the finger-pleximeter tightly on the skin	
58	Place II and IV fingers apart, they do not touch the pleximeter finger	
59	As a hammer, use the middle finger of the right hand bent in the proximal and distal interphalangeal joints so that its end phalanx is located perpendicular to the surface of the middle phalanx of the pleximeter finger of the left hand	
60	Tap on the center of this phalanx, the movement of tapping should come from the right wrist	
61	Short taps, equal strength, two at each point of percussion	
62	The interphalangeal joints of the middle finger, elbow and shoulder joints of the right hand remain motionless	
63	After the second tap the hammer finger should not remain pressed against the finger-pleximeter	
64	Slide the finger-pleximeter by the width of the finger-pleximeter	
65	Perform percussion from the left anterior axillary line to the sternum	
66	Perform percussion using the quiet percussion method	
67	Stop making percussion when the dull sound appears	
68	Put a mark without removing the finger-pleximeter with a dermatograph	
69	The mark should be put from the side of the clear pulmonary sound	
70	Measure the distance between the found border and the anterior mid-line with a centimeter tape	
71	Make the conclusion about the results (normally the left border of the heart dullness is located in the fifth intercostal space 8–9 cm to the left from the anterior midline)	
<i>Assessment of upper border of the relative heart dullness</i>		
72	Place the finger-pleximeter horizontally so that the middle phalanx of the middle finger is 1 cm outward from the left edge of the sternum in the first intercostal space	
73	Press the finger-pleximeter tightly to the skin	
74	Place II and IV fingers apart, they do not touch the pleximeter finger	
75	As a hammer, use the middle finger of the right hand bent in the proximal and distal interphalangeal joints so that its end phalanx is located perpendicular to the surface of the middle phalanx of the pleximeter finger of the left hand	

76	Tap on the center of this phalanx, the movement of tapping should come from the right wrist	
77	Short taps, equal strength, two at each point of percussion	
78	The interphalangeal joints of the middle finger, elbow and shoulder joints of the right hand remain motionless	
79	After the second tap, the hammer finger should not remain pressed against the finger-pleximeter	
80	Slide the finger-pleximeter down by its width	
81	Perform percussion from top to bottom	
82	Perform percussion using the quiet percussion method	
83	Stop percussion when the dull sound appears	
84	Put the mark with a dermatograph without removing the finger-pleximeter	
85	The mark should be put from the side of the clear pulmonary sound	
86	Make the conclusion about the results (normally the upper border of the relative heart dullness is located along the upper edge of the third rib)	
<i>Assessment of width of the relative heart dullness</i>		
87	To determine the width of the relative heart dullness, add the distance in the 4 th intercostal space on the right to the anterior midline (normally 3–4 cm) and the distance in the 5 th intercostal space on the left to the anterior midline (normally 8–9 cm)	
88	Make the conclusion about the results (normally the width of the relative heart dullness is 11–13 cm)	
Completion of the procedure		
89	Make the conclusion: the borders of the relative heart dullness are normal / not normal	
90	Thank the patient	
91	Ask the patient to get dressed	
92	Perform hand hygiene	
Total points _____ (minimum 64 points)		Mark

Full name of the teacher _____ Signature _____

* If the size of the researcher's hand and the patient's chest do not match, it is allowed to shift the base of the palm so that the tips of 2–4 fingers reach the left anterior axillary line.

** When the heart is located on the right, first it is necessary to determine the left border, then the right and upper borders of heart dullness.

14. AUSCULTATION OF THE HEART



Fig. 50. Correct position of the fingers on the head of stethoscope

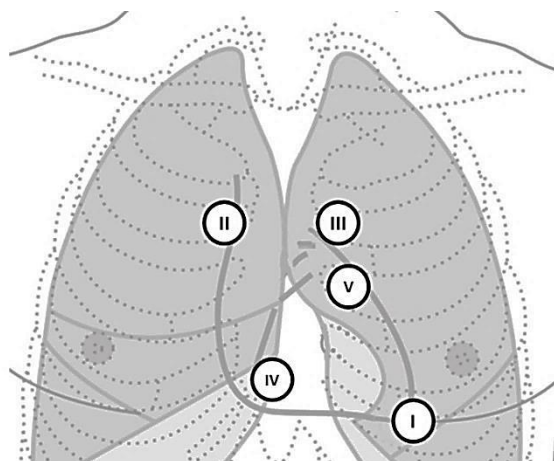


Fig. 51. Points of heart auscultation

PRACTICAL SKILL SCORECARD

Surname, Name _____ Group ____ Date _____

№	Compliance criteria	1 — done 0 — not done
Preparatory stage		
1	Greet the patient	
2	Introduce yourself to the patient	
3	Ask the patient's full name	
4	Ask the patient's age	
5	Ask about the patient's condition at the beginning of the examination	
6	Tell the patient the name of the examination method "Auscultation of the heart"	
7	Get the patient's informed consent for the examination	
8	Ask the patient to take off his clothing from his chest	
9	Ask the patient to take a vertical position facing the source of daylight	
10	Ask the patient to put his arms down	
11	Ask the patient to relax his shoulder muscles	
12	Ask the patient to breathe calmly and evenly	
13	Perform hand hygiene	
14	Clean the head of the stethoscope with an antiseptic solution	
Main stage		
15	Stand to the right opposite the right half of the patient's chest, facing the patient	
16	Ask the patient to turn the head to the left	

<i>Palpation of apical impulse</i>		
17	Ask the patient to slightly bend the upper half of the chest forward	
18	Ask the patient to hold breath during expiration	
19	Put the palm of the right hand with closed and straight fingers flat on the patient's chest so that the base of the hand lies at the left edge of the sternum, the thumb is positioned vertically on the sternum, and II–V fingers are directed towards the left axillary area, between the 4 and 7 ribs	
20	Bend II–IV fingers so that the distal phalanges are perpendicular to the surface of the chest	
21	Move the tips of the bent II–IV fingers along the intercostal space in the medial direction to the point where the fingers begin to feel pulsation if pressed with moderate force	
22	The base of the palm remains fixed on the sternum*	
23	If pulsation is detected, turn the closed tips of II–IV fingers and place them horizontally along the pulsating area of the intercostal space	
24	Perform palpation of the apical impulse for 5–10 seconds	
25	Tell the patient to breathe calmly and evenly	
26	Mark localization of the apical impulse with a dermatograph	
27	Take the head of the stethoscope between the I st and II fingers	
28	Insert the ear tips of the stethoscope into the ears	
29	Make sure that the device is switched to the stethoscope bell	
<i>1st point of auscultation (mitral valve)</i>		
30	Place the stethoscope head at the point of the apical impulse	
31	The head of the stethoscope is firmly pressed to the skin; the researcher's fingers should not touch the patient's skin	
32	For palpation of the right carotid artery the patient continues to turn his head to the left	
33	Set the tips of II–IV fingers at the inner edge of the sternocleidomastoid muscle on the right at the level of the upper edge of the thyroid cartilage	
34	Slightly push the inner edge of the sternocleidomastoid muscle outward and with slight pressure determine the pulsating carotid artery	
35	Compare the pulse waves, following one another, on the carotid artery in relation to heart sounds	
36	Make the conclusion (normally 1 st heart sound coincides with the pulse on the carotid artery)	
37	Listen to the heart sounds for 10–15 seconds	
<i>2nd point of auscultation (aortic valve)</i>		
38	Place the head of the stethoscope in the 2 nd intercostal space at the right edge of the sternum	
39	Continue palpation of the carotid pulse with the left hand**	
40	The head of the stethoscope is firmly pressed to the skin; the researcher's fingers should not touch the patient's skin	
41	Listen to the heart sounds for 10–15 seconds	

<i>3rd point of auscultation (valve of pulmonary artery)</i>		
42	Place the head of the stethoscope in the 2 nd intercostal space at the left edge of the sternum	
43	The head of the stethoscope is firmly pressed on the skin; the researcher's fingers should not touch the patient's skin	
44	Listen to the heart sounds for 10–15 seconds	
<i>4th point of auscultation (tricuspid valve)</i>		
45	Place the head of the stethoscope at the base of the xiphoid process on the right along the edge of the sternum	
46	The head of the stethoscope is firmly pressed on the skin; the researcher's fingers should not touch the patient's skin	
47	Listen to the heart sounds for 10–15 seconds	
<i>5th point of auscultation additional point for aortic valve auscultation — Botkin–Erb point)</i>		
48	Place the head of the in the 3 rd intercostal space at the left edge of the sternum	
49	The head of the stethoscope is firmly pressed on the skin; the researcher's fingers should not touch the patient's skin	
50	Listen to the heart sounds for 10–15 seconds	
Completion of the procedure		
51	Make a conclusion about the results of the heart auscultation	
52	The rhythm of the heartbeats is regular / irregular (normally, the rhythm is regular)	
53	The ratio of heart sounds corresponds / does not correspond to the norm (normally, the 1 st sound is louder in the 1 st and 4 th points of auscultation, the 2 nd sound is louder in the 2 nd and 3 rd points)	
54	Intracardiac murmurs are heard / not heard	
55	Thank the patient	
56	Ask the patient to get dressed	
57	Perform hand hygiene	
58	Clean the stethoscope head	
Total points _____ (minimum 41 points)		Mark

Full name of the teacher _____ Signature _____

* If the sizes of the researcher's hand and the patient's thoracic membrane do not match, the base of the palm may be displaced so that the tips of II–IV fingers reach the left anterior axillary line.

** Palpation of the carotid artery is required for auscultation of the 1st and 2nd points.

15. SUPERFICIAL PALPATION OF THE ABDOMEN

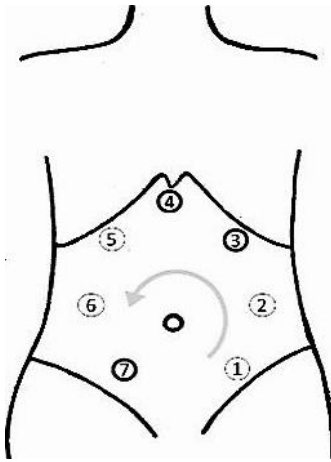


Fig. 52. Superficial indicative palpation of abdomen. Numbers indicate the sequence of palpation (points 20–45)

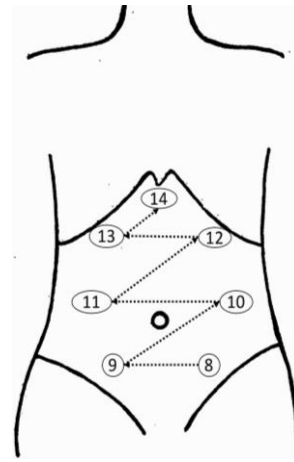


Fig. 53. Superficial comparative palpation of abdomen. Numbers indicate the sequence of palpation (points 46–69)

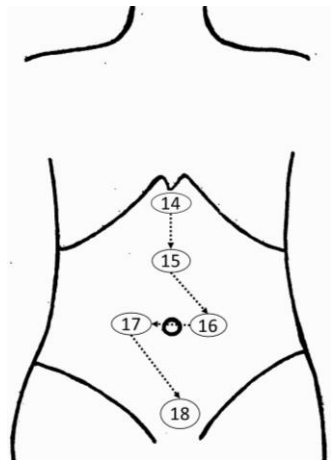


Fig. 54. Superficial comparative palpation of abdomen. Numbers indicate the sequence of palpation (points 70–83)

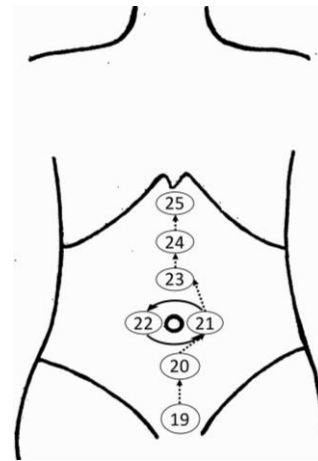


Fig. 55. Palpation of Linea Alba and umbilical area. Numbers indicate the sequence of palpation (points 84–91)

PRACTICAL SKILL SCORECARD

Surname, Name _____ Group _____ Date _____

№	Compliance criteria	1 — done 0 — not done
Preparatory stage		
1	Greet the patient	
2	Introduce yourself to the patient	
3	Ask the patient's full name	
4	Ask the patient's age	
5	Ask about the patient's condition at the beginning of the examination	

6	Tell the patient the name of the examination method “Superficial palpation of the abdomen”	
7	Get the patient’s informed consent for the examination	
8	Ask the patient to take off his clothing from his abdomen (to the upper border of the symphysis pubic)	
9	Ask the patient to take a horizontal position on his back on the couch	
10	Position the patient’s head on a low headboard	
11	Ask the patient to extend his arms along the body	
12	Ask the patient to relax his abdominal muscles	
13	Ask the patient to breathe calmly and evenly	
14	Ask if the patient feels pain (tenderness) in the abdomen	
15	Ask the patient to inform you if he feels any pain on examination	
16	Perform hand hygiene (gloves are optional)	
17	Sit to the right of the patient facing him	
18	The doctor’s chair should be at the level of the couch	
19	Look at the patient’s face during palpation and check his reaction to the appearance of pain on palpation	
Main stage		
<i>Superficial indicative palpation of abdomen</i>		
20	Place the palm of the right hand with closed and slightly bent fingers flat on the patient’s left iliac region so that the base of the hand is directed towards the front midline and the tips of the fingers are pointing laterally*	
21	Palpation should be performed only with the hand, while the elbow and shoulder joints should remain relatively motionless	
22	Move the right palm counterclockwise to the left flank	
23	Palpate the muscles of the abdominal wall and subcutaneous fat slightly pressing on the skin (no more than 2–3 cm deep)	
24	Using the tips of II–V fingers, gently perform sliding movements on the skin of abdomen to a distance of 3–4 cm	
25	Move the right palm counterclockwise up to the left hypochondrium	
26	Palpate the muscles of the abdominal wall and subcutaneous fat slightly pressing on the skin (no more than 2–3 cm in depth)	
27	Using the tips of II–V fingers, gently perform sliding movements on the skin of abdomen to a distance of 3–4 cm	
28	Ask if the patient feels pain (tenderness) on palpation	
29	Move the right palm counterclockwise to the epigastric area	
30	Palpate the muscles of the abdominal wall and subcutaneous fat slightly pressing on the skin (no more than 2–3 cm in depth)	
31	Using the tips of II–V fingers, gently perform sliding movements on the skin of abdomen to a distance of 3–4 cm	
32	Move the right palm counterclockwise to the right hypochondrium	
33	The base of the palm is directed towards the anterior midline, the tips of the fingers are pointing laterally	

34	Palpate the muscles of the abdominal wall and subcutaneous fat slightly pressing on the skin (to a depth of no more than 2–3 c)	
35	Using the tips of II–V fingers, gently perform sliding movements on the skin of abdomen to a distance of 3–4 cm	
36	Ask if the patient feels pain (tenderness) on palpation	
37	Move the right palm counterclockwise to the right flank	
38	The base of the palm is directed towards the anterior midline, the tips of the fingers are pointing laterally	
39	Palpate the muscles of the abdominal wall and subcutaneous fat slightly pressing on the skin (no more than 2–3 cm in depth)	
40	Using the tips of II–V fingers, gently perform sliding movements on the skin of abdomen to a distance of 3–4 cm	
41	Move the right palm counterclockwise to the right iliac region	
42	The base of the palm is directed towards the anterior midline, the tips of the fingers are pointing laterally	
43	Palpate the muscles of the abdominal wall and subcutaneous fat slightly pressing on the skin (no more than 2–3 cm in depth)	
44	Using the tips of II–V fingers, gently perform sliding movements on the skin of abdomen to a distance of 3–4 cm	
45	Ask if the patient feels pain (tenderness) on palpation	
<i>Superficial comparative palpation of abdomen</i>		
46	Place the palm of the right hand with closed and slightly bent fingers flat on the patient's left iliac region so that the base of the hand is pointing downward (caudally) and the tips of the fingers are pointing upward (cranially)	
47	Only the hand is involved in palpation; the elbow and shoulder joints remain relatively motionless	
48	Palpate the muscles of the abdominal wall and subcutaneous fat slightly pressing on the skin (no more than 2–3 cm in depth)	
49	Using the tips of II–V fingers, gently perform sliding movements on the skin of abdomen to a distance of 3–4 cm	
50	Place the palm of the right hand with closed and slightly bent fingers flat on the patient's right iliac region so that the base of the hand is pointing downward (caudally) and the tips of the fingers are pointing upward (cranially)	
51	Only the hand is involved in palpation; the elbow and shoulder joints remain relatively motionless	
52	Palpate the muscles of the abdominal wall and subcutaneous fat slightly pressing on the skin (no more than 2–3 cm in depth)	
53	Using the tips of II–V fingers, gently perform sliding movements on the skin of abdomen to a distance of 3–4 cm	
54	Place the palm of the right hand with closed and slightly bent fingers flat on the patient's left flank so that the base of the hand is pointed downward (caudally) and the tips of the fingers are pointing upward (cranially)	

55	Only the hand is involved in palpation; the elbow and shoulder joints remain relatively motionless	
56	Palpate the muscles of the abdominal wall and subcutaneous fat slightly pressing on the skin (no more than 2–3 cm in depth)	
57	Using the tips of II–V fingers, gently perform sliding movements on the skin of abdomen to a distance of 3–4 cm	
58	Place the palm of the right hand with closed and slightly bent fingers flat on the patient's right flank so that the base of the hand is pointed downward (caudally) and the tips of the fingers are pointed upward (cranially)	
59	Only the hand is involved in palpation; the elbow and shoulder joints remain relatively motionless	
60	Palpate the muscles of the abdominal wall and subcutaneous fat slightly pressing on the skin (no more than 2–3 cm in depth)	
61	Using the tips of II–V fingers, gently perform sliding movements on the skin of abdomen to a distance of 3–4 cm	
62	Place the palm of the right hand with closed and slightly bent fingers flat on the patient's left hypochondrium so that the hand is pointing downward (caudally) and the tips of the fingers are pointing upward (cranially)	
63	Only the hand is involved in palpation; while the elbow and shoulder joints remain relatively motionless	
64	Palpate the muscles of the abdominal wall and subcutaneous fat slightly pressing on the skin (no more than 2–3 cm in depth)	
65	Using the tips of II–V fingers, gently perform sliding movements on the skin of abdomen to a distance of 3–4 cm	
66	Place the palm of the right hand with closed and slightly bent fingers flat on the patient's right hypochondrium so that the base of the hand is pointing downward (caudally) and the tips of the fingers are pointing upward (cranially)	
67	Only the hand is involved in palpation, while the elbow and shoulder joints remain relatively motionless	
68	Palpate the muscles of the abdominal wall and subcutaneous fat slightly pressing on the skin (no more than 2–3 cm in depth)	
69	Using the tips of II–V fingers, gently perform sliding movements on the skin of abdomen to a distance of 3–4 cm	
70	Place the palm of the right hand with closed and slightly bent fingers flat on the patient's epigastric region along the anterior midline so that the base of the hand is directed downward to the umbilicus and the tips of the fingers are positioned under the xiphoid process	
71	Only the hand is involved in palpation; while the elbow and shoulder joints remain relatively motionless	
72	Palpate the muscles of the abdominal wall and subcutaneous fat slightly pressing on the skin (no more than 2–3 cm in depth)	
73	Using the tips of II–V fingers, gently perform sliding movements on the skin of abdomen to a distance of 3–4 cm	

74	Ask if the patient feels pain (tenderness) on palpation	
75	Move the right palm downwards to the umbilical region	
76	Only the hand is involved in palpation, while the elbow and shoulder joints remain relatively motionless	
77	Palpate the muscles of the abdominal wall and subcutaneous fat slightly pressing on the skin (no more than 2–3 cm in depth)	
78	Using the tips of II–V fingers, gently perform sliding movements on the skin of abdomen to a distance of 3–4 cm	
79	Ask if the patient feels pain (tenderness) on palpation	
80	Move the right palm downwards to the suprapubic region	
81	Palpate the muscles of the abdominal wall and subcutaneous fat slightly pressing on the skin (no more than 2–3 cm in depth)	
82	Using the tips of II–V fingers, gently perform sliding movements on the skin of abdomen to a distance of 3–4 cm	
83	Ask if the patient feels pain (tenderness) on palpation	
<i>Palpation of Linea Alba and umbilical area</i>		
84	Set the closed and bent fingers of the right hand along the front midline above the pubis (the tips of the II–V fingers are placed on Linea Alba ; the base of the palm is directed to the antero-superior spine of the patient’s right iliac bone)	
85	Ask the patient to raise his head (bringing the chin to the sternum)	
86	Ask the patient to breathe in and hold his/her breath on inspiration	
87	Palpate Linea Alba of abdomen from the pubis to the umbilical area with the tips of II–V fingers	
88	Palpate the umbilical area with tips of II–V fingers	
89	Palpate Linea Alba from the umbilical area to xiphoid process with tips of II–V fingers	
90	Ask the patient to lower his head and breathe freely	
91	Ask if the patient feels pain (tenderness) on palpation	
Completion of the procedure		
92	Make a conclusion about the results of superficial palpation (normally, the abdomen is soft, painless, there is no swelling of the skin, muscle tension of the anterior abdominal wall is absent, hernial protrusions and diastasis of the rectus abdominis are absent)	
93	Thank the patient	
94	Ask the patient to get dressed	
95	Perform hand hygiene	
Total points _____ (minimum 67 points)		Mark

Full name of the teacher _____ Signature _____

* If there is pain in the left abdomen, palpation is started from the right iliac region.

16. PALPATION OF THE SIGMOID COLON

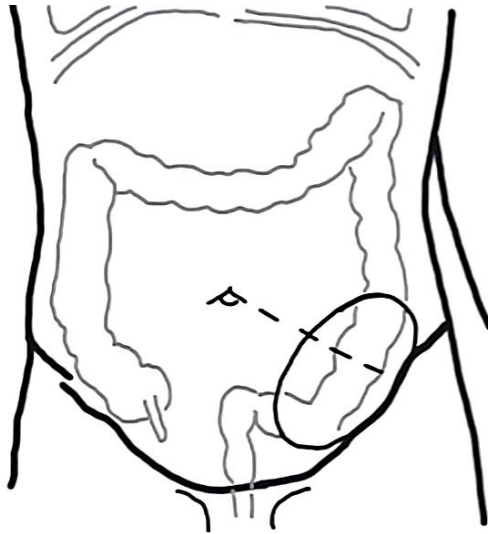


Fig. 56. Location of sigmoid colon

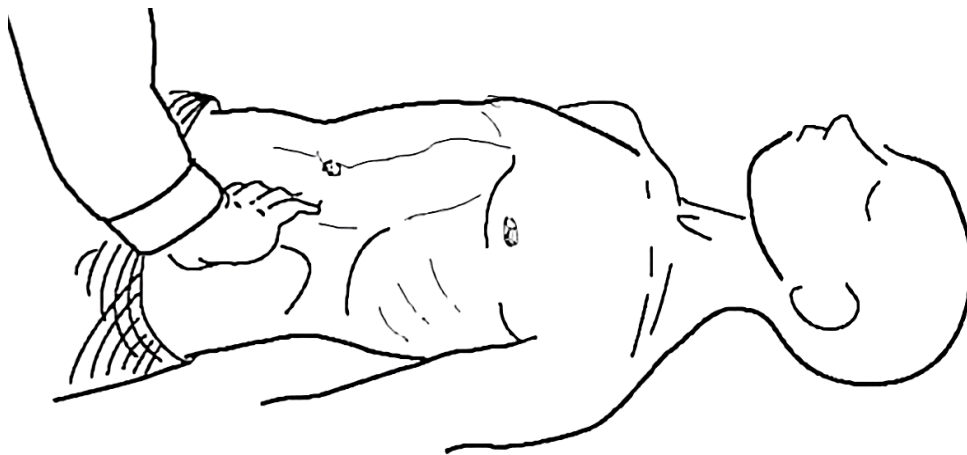


Fig. 57. Palpation of sigmoid colon (points 19–31)

PRACTICAL SKILL SCORECARD

Surname, Name _____ Group ____ Date _____

№	Compliance criteria	1 — done 0 — not done
Preparatory stage		
1	Greet the patient	
2	Introduce yourself to the patient	
3	Ask the patient's full name	
4	Ask the patient's age	
5	Ask about the patient's condition at the beginning of the examination	
6	Tell the patient the name of the examination method "Palpation of the sigmoid colon"	
7	Get the patient's informed consent for the examination	
8	Ask the patient to take off his clothing from his abdomen (to the upper border of the symphysis pubic)	
9	Ask the patient to take a horizontal position on his back on the couch	
10	Position the patient's head on a low headboard	
11	Ask the patient to extend his arms along the body	
12	Ask the patient to extend his legs	
13	Ask the patient to relax his abdominal muscles	
14	Ask if the patient feels pain/tenderness in the abdomen	
15	Ask the patient to breathe through the mouth evenly, using the diaphragmatic type of breathing, without straining the abdominal wall	
16	Perform hand hygiene (gloves are optional)	
17	Sit to the right of the patient facing him	
18	The doctor's chair should be at the level of the couch	
Main stage		
19	The tips of the II–V bent and closed fingers of the right hand are at the same level	
20	The tips of the II–V fingers lie on the border between the middle and outer third of the line connecting the navel and the anterior-superior spine of the left iliac bone	
21	The tips of the II–V fingers lie parallel to the length of the sigmoid colon	
22	The base of the right hand is directed towards the antero-superior spine of the left iliac bone, and the fingertips are in the projection of the sigmoid colon	
23	Palpation is performed by the hand and forearm	
24	On the patient's inspiration move the right hand with a superficial movement (without immersion) 3–4 cm towards the navel and form a skin fold	

25	On the patient's exhalation slowly immerse the fingers of the right hand into the abdominal cavity	
26	Keep the hand in this position until the end of the patient's next inhalation	
27	On the next exhalation slowly immerse the fingers of the right hand into the abdominal cavity a little deeper	
28	Keep the hand in this position until the end of the patient's next inhalation	
29	On the third exhalation slowly immerse the fingers of the right hand into the abdominal cavity deeper	
30	At the end of the patient's third exhalation, with the fingertips of the right hand slide perpendicularly to the length of the sigmoid colon in the direction from the navel to the antero-superior spine of the left iliac bone (II–V fingers roll through the sigmoid colon)	
31	Ask if the patient feels pain (tenderness) on palpation	
Completion of the procedure		
32	Make a conclusion about the results of the palpation: the sigmoid colon is palpable / not palpable	
33	Localization (normally located on the border of the outer and middle third of the line connecting the navel and the antero-superior spine of the left iliac bone)	
34	Shape (normally cylindrical)	
35	Size (normally 2–3 cm in diameter)	
36	Surface (smooth / nodular)	
37	Rumbling (present / absent)	
38	Mobility (normally shifted by 3–5 cm)	
39	Consistency (soft / dense)	
40	Pain (painful / not painful)	
41	Thank the patient	
42	Ask the patient to get dressed	
43	Perform hand hygiene	
Total points _____ (minimum 31 points)		Mark

Full name of the teacher _____ Signature _____

17. PALPATION OF THE CECUM

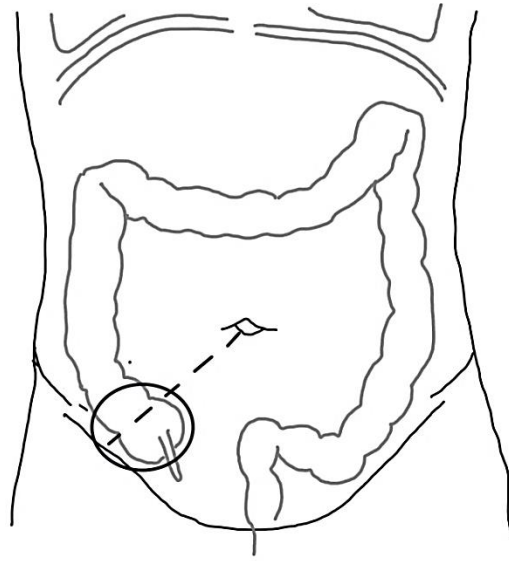


Fig. 58. Location of cecum

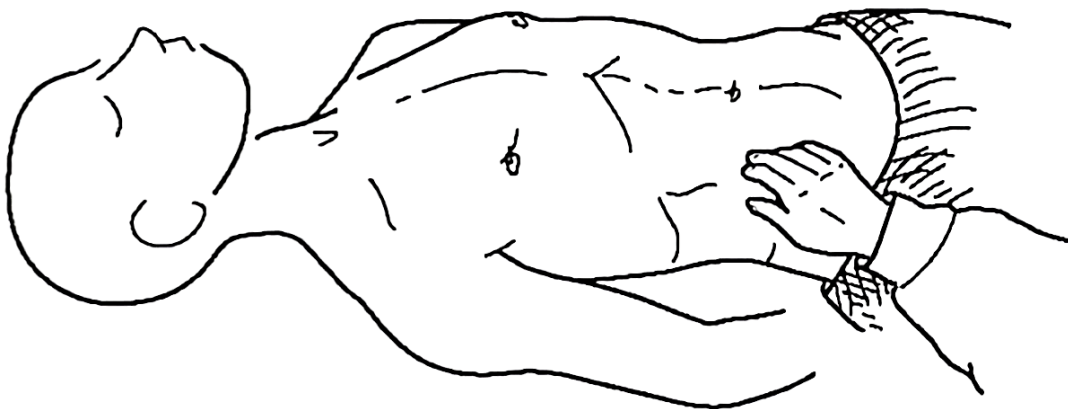


Fig. 59. Palpation of cecum (points 19–31)

PRACTICAL SKILL SCORECARD

Surname, Name _____ Group ____ Date _____

№	Compliance criteria	1 — done 0 — not done
Preparatory stage		
1	Greet the patient	
2	Introduce yourself to the patient	
3	Ask the patient's full name	
4	Ask the patient's age	
5	Ask about the patient's condition at the beginning of the examination	
6	Tell the patient the name of the examination method "Palpation of the cecum"	
7	Get the patient's informed consent for the examination	
8	Ask the patient to take off his clothing from his abdomen (to the upper border of the symphysis pubic)	
9	Ask the patient to take a horizontal position on his back on the couch	
10	Position the patient's head on a low headboard	
11	Ask the patient to extend his arms along the body	
12	Ask the patient to extend his legs	
13	Ask the patient to relax his abdominal muscles	
14	Ask if the patient feels pain / tenderness in the abdomen	
15	Ask the patient to breathe through the mouth evenly, using the diaphragmatic type of breathing, without straining the abdominal wall	
16	Perform hand hygiene	
17	Sit to the right of the patient facing him	
18	The doctor's chair should be at the level of the couch	
Main stage		
19	The tips of the II–V bent and closed fingers of the right hand are at the same level	
20	The tips of the II–V fingers lie on the border between the middle and outer third of the line connecting the navel and the antero-superior spine of the right iliac bone	
21	The tips of the II–V fingers lie parallel to the length of the cecum	
22	The base of the right hand is directed towards the antero-superior spine of the right iliac bone, and the fingertips are in the projection of the cecum	
23	Palpation is performed by the hand and forearm	
24	On the patient's inspiration move the right hand with a superficial movement (without immersion) 3–4 cm towards the navel and form a skin fold	
25	On the patient's exhalation slowly immerse the fingers of the right hand into the abdominal cavity	

26	Keep the hand in this position until the end of the patient's next inhalation	
27	On the next exhalation slowly immerse the fingers of the right hand into the abdominal cavity a little deeper	
28	Keep the hand in this position until the end of the patient's next inhalation	
29	On the third exhalation slowly immerse the fingers of the right hand into the abdominal cavity deeper	
30	At the end of the third patient's exhalation, with the fingertips of the right hand slide perpendicularly to the length of the cecum in the direction from the navel to the antero-superior spine of the right iliac bone (II–V fingers roll through the cecum)	
31	Ask if the patient feels pain (tenderness) on palpation	
Completion of the procedure		
32	Make a conclusion about the results of palpation: the cecum is palpable / not palpable	
33	Localization (the cecum is normally located on the border of the outer and middle third of the line connecting the navel and the antero-superior spine of the right iliac bone)	
34	Shape (normally cylindrical)	
35	Size (normally 2–3 cm in diameter)	
36	Surface (smooth / nodular)	
37	Rumbling (present / absent)	
38	Mobility (normally shifted by 3–5 cm)	
39	Consistency (soft / dense)	
40	Pain (painful / not painful)	
41	Thank the patient	
42	Ask the patient to get dressed	
43	Perform hand hygiene	
Total points _____ (minimum 31 points)		Mark

Full name of the teacher _____ Signature _____

18. PALPATION OF THE TRANSVERSE COLON

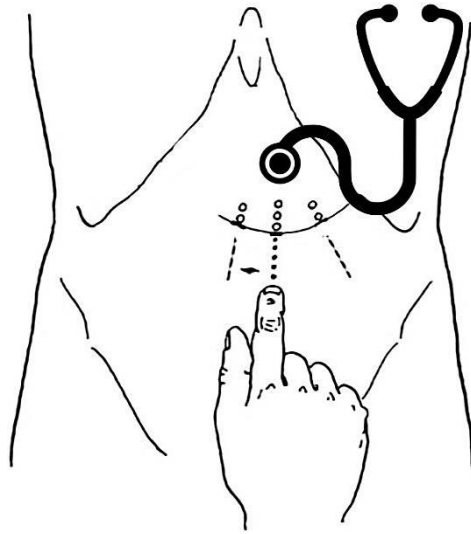


Fig. 60. Determination of inferior border of the stomach by auscultatory friction method (“rustle” method) (points 19–30)

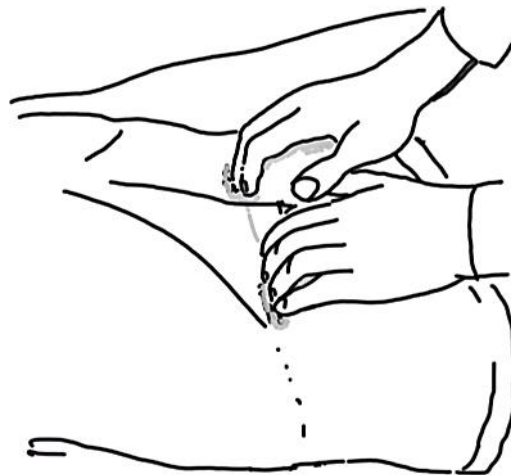

Fig. 61. Palpation of transverse colon (points 31–44)

PRACTICAL SKILL SCORECARD

Surname, Name _____ Group ____ Date _____

№	Compliance criteria	1 — done 0 — not done
Preparatory stage		
1	Greet the patient	
2	Introduce yourself to the patient	
3	Ask the patient’s full name	
4	Ask the patient’s age	
5	Ask about the patient’s condition at the beginning of the examination	

6	Tell the patient the name of the examination method “Palpation of the transverse colon”	
7	Get the patient’s informed consent for the examination	
8	Ask the patient to take off his clothing from his abdomen (to the upper border of the symphysis pubic)	
9	Ask the patient to take a horizontal position on his back on the couch	
10	Position the patient’s head on a low headboard	
11	Ask the patient to extend his arms along the body	
12	Ask the patient to extend his legs	
13	Ask the patient to relax his abdominal muscles	
14	Ask if the patient feels pain/tenderness in the abdomen	
15	Ask the patient to breathe through the mouth evenly, using the diaphragmatic type of breathing, without straining the abdominal wall	
16	Perform hand hygiene (gloves are optional)	
17	Sit to the right of the patient facing him	
18	The doctor's chair should be at the level of the couch	
Main stage		
<i>Determination of inferior border of the stomach by auscultatory affrication method (“rustle” method)</i>		
19	Clean the diaphragm of the stethoscope with an antiseptic solution	
20	Insert the ear tips of the stethoscope into the ears	
21	Make sure that the device is switched to the stethoscope diaphragm	
22	Take the head of the stethoscope between the I and II fingers of the left hand	
23	Position the head of the stethoscope on the surface of the body according to the expected auscultation point — under the xiphoid process on the left	
24	Firmly press the head of the stethoscope to the skin, without touching the patient’s skin with fingers	
25	With a finger of the right hand, perform dashed movements on the skin radially from the head of the stethoscope towards the antero-superior spine of the left iliac bone	
26	When the “rustling” sounds disappear, make a mark on the skin	
27	With a finger of the right hand, perform dashed movements radially from the xiphoid process in the direction of the navel (along the front midline)	
28	When the “rustling” sounds disappear, make a mark on the skin	
29	With a finger of the right hand, perform dashed movements radially from the xiphoid process in the direction of the anteroposterior spine of the right ilium	
30	When the “rustling” sounds disappear, make a mark on the skin	
Palpation of the transverse colon		
31	The tips of the II–V bent and closed fingers of the both hands are at the same level	

32	The tips of the II–V fingers lie 2–3 cm below the inferior border of the stomach	
33	The tips of the II–V fingers lie parallel to the length of the transverse colon	
34	The palms of the right and left hands are placed on both sides of the front midline, the base of the palms is directed downward	
35	Palpation is performed by the hand and forearm	
36	On the patient's inspiration move both hands 3–4 cm upwards with a superficial movement (without immersion) and form a skin fold	
37	On the patient's exhalation slowly immerse the fingers of the hands into the abdominal cavity	
38	Keep the hands in this position until the end of the patient's next inhalation	
39	On the next exhalation slowly immerse the fingers of both hands into the abdominal cavity a little deeper	
40	Keep both hands in this position until the end of the patient's next inhalation	
41	On the third exhalation slowly immerse the fingers of both hands into the abdominal cavity deeper	
42	At the end of the patient's third exhalation, with the fingertips of both hands slide from top to bottom perpendicularly to the length of the transverse colon (II–V fingers roll through the transverse colon)	
43	Ask if the patient feels pain (tenderness) on palpation	
44	Ask the patients about localization of pain (right / left), if any	
Completion of the procedure		
45	Make a conclusion about the results of palpation: The transverse colon is palpable / not palpable	
46	Localization (normally located 3–4 cm below the inferior border of the stomach)	
47	Shape (normally cylindrical)	
48	Size (normally 2–3 cm in diameter)	
49	Surface (smooth / nodular)	
50	Rumbling (present / absent)	
51	Mobility (normally shifted by 3–5 cm)	
52	Consistency (soft / dense)	
53	Pain (painful / not painful)	
54	Thank the patient	
55	Ask the patient to get dressed	
56	Perform hand hygiene	
Total points _____ (minimum 39 points)		Mark

Full name of the teacher _____ Signature _____

19. ASSESSMENT OF THE LIVER SIZE ACCORDING TO M. G. KURLOV'S METHOD

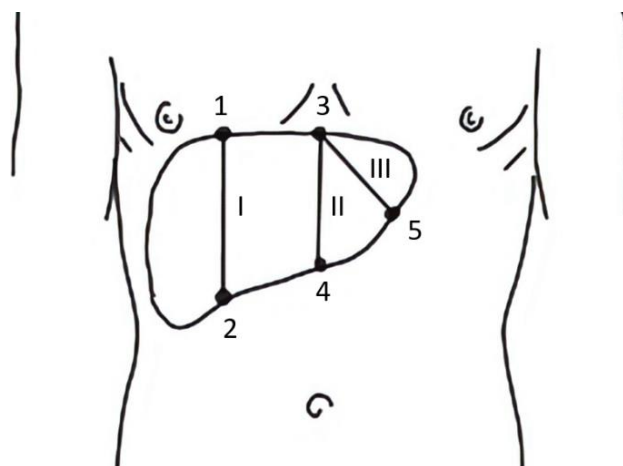


Fig. 62. The scheme for assessment the liver size according to M. G. Kurlov's method. Arabic numerals indicate the points of the liver size is measured, Roman numerals indicate the liver dimensions

PRACTICAL SKILL SCORECARD

Surname, Name _____ Group ____ Date _____

№	Compliance criteria	1 — done 0 — not done
Preparatory stage		
1	Greet the patient	
2	Introduce yourself to the patient	
3	Ask the patient's full name	
4	Ask the patient's age	
5	Ask about the patient's condition at the beginning of the examination	
6	Tell the patient the name of the examination method "Assessment of the liver size according to M. G. Kurlov's method"	
7	Get the patient's informed consent for the examination	
8	Ask the patient to take off his clothing from his abdomen (to the upper border of the symphysis pubic)	
9	Ask the patient to take a horizontal position on his back on the couch	
10	Position the patient's head on a low headboard	
11	Ask the patient to extend his arms along the body	
12	Ask the patient to extend his legs	
13	Ask the patient to breathe through the mouth evenly, using the diaphragmatic type of breathing, without straining the abdominal wall	
14	Perform hand hygiene	
15	Sit to the right of the patient facing him	
16	The doctor's chair should be at the level of the couch	

Main stage		
<i>Assessment of upper border on right mid-clavicular line</i>		
17	Place the palm of the left hand on the right side of the patient's chest parallel to the ribs	
18	Place the pleximeter finger (III finger) on 2 nd intercostal space, its middle phalanx is on the right of the mid-clavicular line	
19	The pleximeter finger is tightly pressed to the skin	
20	II and IV fingers are apart, without touching the pleximeter finger	
21	Perform percussion downwards from the 2 nd intercostal space along the right mid-clavicular line, using the quiet percussion method	
22	Use the III finger of the right hand as a hammer: bent it at the proximal and distal interphalangeal joints so that its distal phalanx is perpendicular to the surface of the middle phalanx of the III finger of the left hand (pleximeter finger)	
23	Tap on the center of this phalanx with movements of the right wrist joint	
24	Short taps, equal strength, two at each point of percussion	
25	Interphalangeal joints of the middle finger, ulnar and shoulder joints of the right hand remain motionless	
26	After the second tap the hammer finger should not remain pressed to the pleximeter finger	
27	Percuss downwards, using the method of quiet percussion	
28	Shift the pleximeter finger downward by the width of the pleximeter finger	
29	Perform percussion until the pulmonary sound becomes dull	
30	Apply a mark with a dermatograph without removing your pleximeter finger	
31	Make a mark from the side of the pulmonary sound	
<i>Assessment of inferior border on right mid-clavicular line</i>		
32	Place the palm of the left hand on the right half of the patient's abdomen (fingers are pointing towards the midline, the base of the palm is directed laterally)	
33	The middle phalanx of the III finger of the left hand is placed on the line connecting the antero-superior spines of the iliac bones, perpendicularly to the continuation of the right mid-clavicular line	
34	The pleximeter finger is tightly pressed to the skin	
35	II and IV fingers are apart, without touching the pleximeter finger	
36	Perform percussion upwards along the right mid-clavicular line, using the quietest percussion method	
37	Use the III finger of the right hand as a hammer: bend it at the proximal and distal interphalangeal joints so that its distal phalanx is perpendicular to the surface of the middle phalanx of the III finger of the left hand (pleximeter finger)	
38	Tap on the center of this phalanx with movements of the right wrist joint	

39	Short taps, equal strength, two at each point of percussion	
40	Interphalangeal joints of the middle finger, ulnar and shoulder joints of the right hand remain motionless	
41	After the second tap the hammer finger should not remain pressed to the pleximeter finger	
42	Shift the pleximeter finger upward by the width of the pleximeter finger	
43	Perform percussion until the tympanic sound becomes dull	
44	Apply a mark with a dermatograph without removing your pleximeter finger	
45	Make a mark from the side of the tympanic sound	
<i>Determination of the upper border on the anterior midline</i>		
46	Draw a perpendicular line from the top point along the right mid-clavicular line to the anterior midline	
47	Apply a dermatograph mark at the intersection of the perpendicular line and the anterior midline	
<i>Assessment of inferior border on anterior midline</i>		
48	Place the palm of the left hand in the middle of the patient's abdomen (fingers are directed toward the left half of the abdomen, the base of the palm is directed toward the right half of the abdomen)	
49	The pleximeter finger is pressed firmly to the skin along the extension of the anterior midline, at the level of the line connecting the anteroom-superior spines of the iliac bones	
50	II and IV fingers are apart, without touching the pleximeter finger	
51	Perform percussion up the front midline using the quietest percussion method	
52	Use the III finger of the right hand as a hammer: bend it at the proximal and distal interphalangeal joints so that its distal phalanx is perpendicular to the surface of the middle phalanx of the III finger of the left hand (pleximeter finger)	
53	Tap on the center of this phalanx with movements of the right wrist joint	
54	Short taps, equal strength, two at each point of percussion	
55	Interphalangeal joints of the middle finger, ulnar and shoulder joints of the right hand remain motionless	
56	After the second tap the hammer finger should not remain pressed to the pleximeter finger	
57	Shift the pleximeter finger upward by the width of the pleximeter finger	
58	Perform percussion until the tympanic sound becomes dull	
59	Apply a mark with a dermatograph without removing your pleximeter finger	
60	Make a mark from the side of the tympanic sound	
<i>Assessment of liver border on left costal arch</i>		
61	Place the palm of the left hand perpendicularly to the left costal arch	
62	The middle phalanx of the pleximeter finger is placed 0.5 cm below the intersection of the left costal arch and the left midclavicular line	

63	The pleximeter finger is tightly pressed to the skin	
64	II and IV fingers are apart, without touching the pleximeter finger	
65	Perform percussion using the quietest percussion method	
66	Use the III finger of the right hand as a hammer: bend it at the proximal and distal interphalangeal joints so that its distal phalanx is perpendicular to the surface of the middle phalanx of the III finger of the left hand (pleximeter finger)	
67	Tap on the center of this phalanx with movements of the right wrist joint	
68	Short taps, equal strength, two at each point of percussion	
69	Interphalangeal joints of the middle finger, ulnar and shoulder joints of the right hand remain motionless	
70	After the second tap the hammer finger should not remain pressed to the pleximeter finger	
71	Perform percussion in the direction of the xiphoid process	
72	Move the pleximeter finger medially and upward by the width of the pleximeter finger	
73	Continue percussion until the percussion sound changes from tympanic to dull	
74	Apply a mark with a dermatograph without removing your pleximeter finger	
75	Make a mark from the side of the tympanic sound	
76	Using a centimeter tape, measure the first size of the liver according to M. G. Kurlov: the distance between the upper and lower points on the right mid-clavicular line	
77	Make a conclusion (normal size — 9 ± 1 cm)	
78	Measure the second size of the liver according to M. G. Kurlov: the distance between the upper and lower points along the anterior midline	
79	Make a conclusion (normal size — 8 ± 1 cm)	
80	Measure the third size of the liver according to M. G. Kurlov: the distance from the point along the left costal arch to the upper point of the second size along anterior midline	
81	Make a conclusion (normal size — 7 ± 1 cm)	
Completion of the procedure		
82	Make a conclusion about the results of percussion: the size of the liver according to M. G. Kurlov is normal/not normal.	
83	Thank the patient	
84	Ask the patient to get dressed	
85	Perform hand hygiene	
Total points _____ (minimum 60 points)		Mark

Full name of the teacher _____ Signature _____

20. PALPATION OF THE LIVER

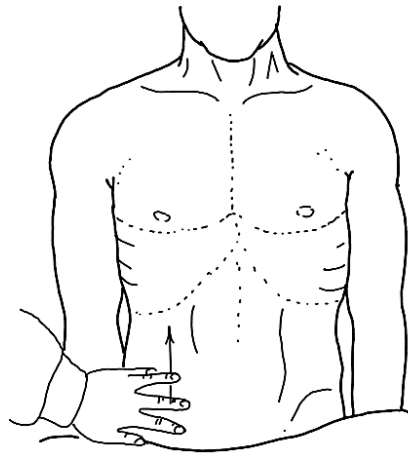


Fig. 63. Assessment of inferior liver border on right mid-clavicular line (points 19–32).
Arrow indicates the direction of percussion

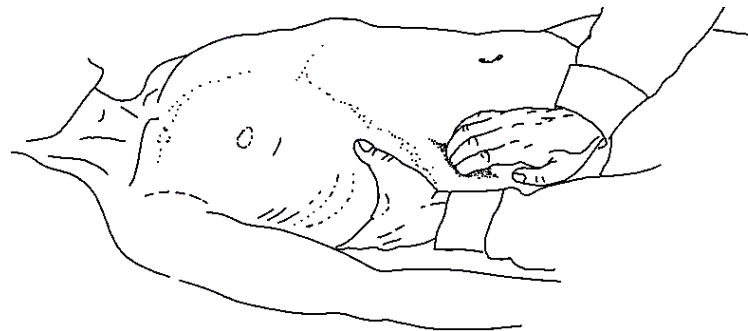


Fig. 64. Palpation of the liver (points 33–51)

PRACTICAL SKILL SCORECARD

Surname, Name _____ Group ____ Date _____

№	Compliance criteria	1 — done 0 — not done
Preparatory stage		
1	Greet the patient	
2	Introduce yourself to the patient	
3	Ask the patient's full name	
4	Ask the patient's age	
5	Ask about the patient's condition at the beginning of the examination	
6	Tell the patient the name of the examination method "Palpation of the liver"	
7	Get the patient's informed consent for the examination	
8	Ask the patient to take off his clothing from his abdomen (to the upper border of the symphysis pubic)	
9	Ask the patient to take a horizontal position on his back on the couch	

10	Position the patient's head on a low headboard	
11	Ask the patient to extend his legs	
12	Ask the patient to extend his arms along the body	
13	Ask if the patient feels pain / tenderness in the abdomen	
14	Ask the patient to relax his abdominal muscles	
15	Ask the patient to breathe through the mouth evenly, using the diaphragmatic type of breathing, without straining the abdominal wall	
16	Perform hand hygiene	
17	Sit to the right of the patient facing him	
18	The doctor's chair should be at the same level with the couch	
Main stage		
<i>Assessment of inferior border on right mid-clavicular line</i>		
19	Place the palm of the left hand on the right half of the patient's abdomen (fingers are pointing towards the midline, the base of the palm is directed laterally)	
20	The middle phalanx of the III finger of the left hand is placed on the line connecting the antero-superior spines of the iliac bones perpendicular to the continuation of the right mid-clavicular line	
21	The pleximeter finger is tightly pressed to the skin	
22	II and IV fingers are apart, without touching the pleximeter finger	
23	Perform percussion upwards along the right mid-clavicular line, using the quietest percussion method	
24	Use the III finger of the right hand as a hammer: bend it at the proximal and distal interphalangeal joints so that its distal phalanx is perpendicular to the surface of the middle phalanx of the III finger of the left hand (pleximeter finger)	
25	Tap on the center of this phalanx with movements of the right wrist joint	
26	Short taps, equal strength, two at each point of percussion	
27	Interphalangeal joints of the middle finger, ulnar and shoulder joints of the right hand remain motionless	
28	After the second tap the hammer finger should not remain pressed to the pleximeter finger	
29	Shift the pleximeter finger upward by the width of the pleximeter finger	
30	Perform percussion until the tympanic sound becomes dull	
31	Apply a mark with a dermatograph without removing your pleximeter finger	
32	Make a mark from the side of the tympanic sound	
<i>Palpation of the lower edge of the liver</i>		
33	Place the palm of the left hand on the lower part of the patient's chest from the back to the front axillary line: II–V fingers are perpendicular to the spine	
34	Place the thumb of the left hand in front on the costal arch	
35	The tips of the II–V fingers of the right hand, slightly bent and closed, should be at the same level and lie along the previously found lower edge of the liver	

36	Place the palm of the right hand on the patient's abdomen along the continuation of the right mid-clavicular line outward from the edge of the rectus abdominis muscle	
37	The palm base is directed downwards	
38	The line of the middle finger of the right hand coincides with the continuation of the right mid-clavicular line	
39	Palpation is performed by the hand and forearm	
40	Ask the patient to breathe through the mouth evenly, using the diaphragmatic type of breathing, without straining the abdominal wall	
41	On the patient's inspiration move the fingers of the right hand with a superficial movement (without immersion) by 3–4 cm downwards and form a skin fold	
42	On the patient's exhalation slowly immerse the fingers of the right hand into the abdominal cavity	
43	Keep the hand in this position until the end of the patient's next inhalation	
44	Simultaneously squeeze the right costal arch from the top and side with the left palm	
45	On the second exhalation slowly push the fingers of the right hand deeper	
46	Hold the hand in this position	
47	Simultaneously squeeze the right costal arch from the top and side with the left palm	
48	Ask the patient to take a deep breath with his abdomen	
49	Simultaneously with the patient's inhalation unbend the nail phalanges of the right hand, straightening the fingers under the costal arch	
50	The forearm and hand remain motionless	
51	Ask if the patient feels pain (tenderness) on palpation	
Completion of the procedure		
52	Make a conclusion about the results of palpation: the lower edge of the liver is palpable / not palpable	
53	The edge of the liver on palpation is painful / not painful	
54	Consistency is soft / dense	
55	The surface is smooth / nodular	
56	The edge of the liver is rounded / sharp	
57	It protrudes from under the edge of the right costal arch (by ... centimeters)/ It does not protrude from under the edge of the right costal arch	
58	Thank the patient	
59	Ask the patient to get dressed	
60	Perform hand hygiene	
Total points _____ (minimum 42 points)		Mark

Full name of the teacher _____ Signature _____

21. PALPATION OF THE KIDNEYS IN THE HORIZONTAL POSITION

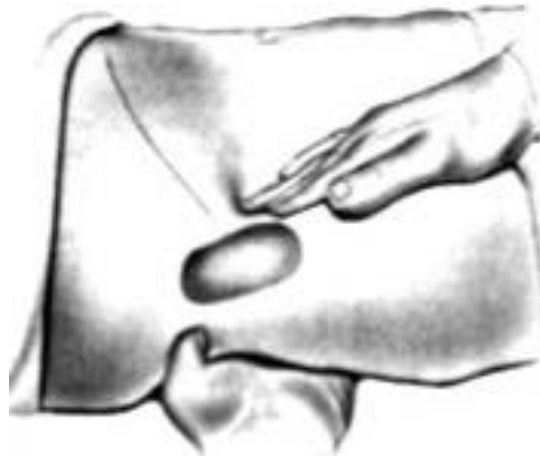

Fig. 65. Palpation of right kidney in horizontal position (points 17–33)

PRACTICAL SKILL SCORECARD

Surname, Name _____ Group ____ Date _____

№	Compliance criteria	1 — done 0 — not done
Preparatory stage		
1	Greet the patient	
2	Introduce yourself to the patient	
3	Ask the patient's full name	
4	Ask the patient's age	
5	Ask about the patient's condition at the beginning of the examination	
6	Tell the patient the name of the examination method "Palpation of the kidneys in the horizontal position"	
7	Get the patient's informed consent for the examination	
8	Ask the patient to take off his clothing from his abdomen (to the upper border of the symphysis pubic)	
9	Ask the patient to take a horizontal position on his back on the couch	
10	Position the patient's head on a low pillow	
11	Ask the patient to extend his legs	
12	Ask the patient to extend his arms along the body	
13	Ask the patient to breathe through the mouth evenly, using the diaphragmatic type of breathing, without straining the abdominal wall	
14	Perform hand hygiene	
15	Sit to the right of the patient facing him	
16	The doctor's chair should be at the same level with the couch	

Main stage		
<i>Palpation of the right kidney</i>		
17	Place the left hand under the patient's right half of the lumbar region, fingers pointing towards the spine	
18	The palmar surface of the left hand is facing up	
19	The index finger of the left hand is at the level of the XII rib on the right	
20	The tips of the II–V fingers of the right hand are at the same level and lie 1–2 cm below the right costal arch	
21	Place the palm of the right hand so that the V finger lies outside of the lateral edge of the rectus abdominis muscle	
22	The base of the right palm is directed downwards (caudally)	
23	Palpation is performed with the hand and forearm	
24	As the patient exhales, gently and slowly immerse the fingers of the right hand into the abdominal cavity	
25	Fix the hand in this position until the end of the patient's next inhalation	
26	Simultaneously, with the left palm bring the lumbar region closer to the fingers of the right hand	
27	On the second exhalation slowly immerse the fingers of the right hand into the abdominal cavity deeper	
28	Simultaneously, with the left palm bring the lumbar region closer to the fingers of the right hand	
29	Fix the hand in this position until the end of the patient's next inhalation	
30	On the third exhalation gently and slowly immerse the fingers of the right hand into the abdominal cavity even deeper	
31	Simultaneously, with the left palm bring the lumbar region closer to the fingers of the right hand	
32	Ask the patient to make a deep abdominal breath	
33	Make a conclusion about the results of palpation of the right kidney: the right kidney is palpable / not palpable	
<i>Palpation of the left kidney</i>		
34	Move the left arm under the left half of the patient's lumbar region	
35	The palmar surface of the left hand is facing up	
36	The index finger of the left hand is at the level of the XII rib on the left	
37	The left wrist joint is at the level of the spinous processes of the lumbar spine	
38	The tips of the II–V fingers of the right hand are at the same level and lie 1–2 cm below the left costal arch	
39	Place the palm of the right hand so that the index finger is located on the lateral edge of the rectus abdominis muscle on the left	
40	The base of the right palm is directed downwards (caudally)	
41	Palpation is performed with the hand and forearm	

42	As the patient exhales, gently and slowly immerse the fingers of the right hand into the abdominal cavity	
43	Fix the hand in this position until the end of the patient's next inhalation	
44	Simultaneously, with the left palm bring the lumbar region closer to the fingers of the right hand	
45	On the second exhalation slowly immerse the fingers of the right hand into the abdominal cavity deeper	
46	Simultaneously, with the left palm bring the lumbar region closer to the fingers of the right hand	
47	Fix the hand in this position until the end of the patient's next inhalation	
48	On the third exhalation gently and slowly immerse the fingers of the right hand into the abdominal cavity even deeper	
49	Simultaneously, with the left palm bring the lumbar region closer to the fingers of the right hand	
50	Ask the patient to make a deep abdominal breath	
51	Make a conclusion about the results of palpation of the left kidney: the left kidney is palpable / not palpable	
Completion of the procedure		
52	Make a conclusion about the results of palpation (normally kidneys are not palpable)	
53	Thank the patient	
54	Ask the patient to get dressed	
55	Perform hand hygiene	
Total points _____ (minimum 39 points)		Mark

Full name of the teacher _____ Signature _____

22. PALPATION OF THE KIDNEYS IN THE VERTICAL POSITION

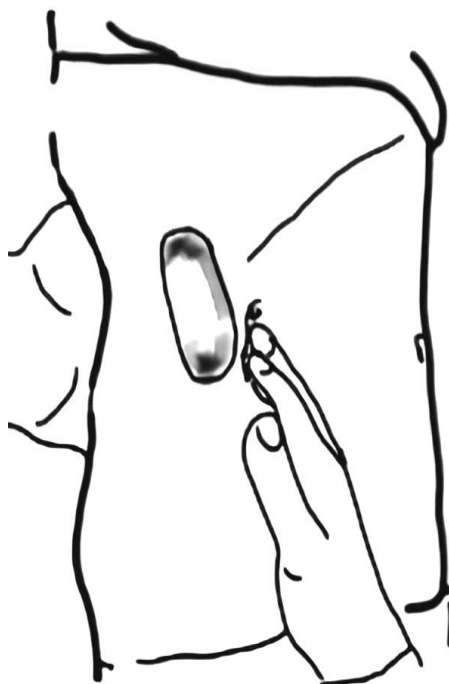


Fig. 66. Palpation of right kidney in vertical position (points 14–29)

PRACTICAL SKILL SCORECARD

Surname, Name _____ Group ____ Date _____

№	Compliance criteria	1 — done 0 — not done
Preparatory stage		
1	Greet the patient	
2	Introduce yourself to the patient	
3	Ask the patient's full name	
4	Ask the patient's age	
5	Ask about the patient's condition at the beginning of to the examination	
6	Tell the patient the name of the examination method "Palpation of the kidneys in the vertical position"	
7	Get the patient's informed consent for the examination	
8	Ask the patient to take off his clothing from his chest and abdomen (to the upper border of the symphysis pubic)	
9	Ask the patient to take a vertical position	
10	Ask the patient to stretch his arms along the body	
11	Ask the patient to breathe through the mouth evenly, using the diaphragmatic breathing, without straining the abdominal wall	
12	Perform hand hygiene	
13	Sit to the right of the patient, facing him	

Main stage		
<i>Palpation of right kidney</i>		
14	Place the left hand on the right half of the patient's lumbar region, with fingers pointing towards the spine	
15	The index finger of the left hand is at the level of the 12 rib on the right	
16	The tips of the II–IV fingers of the right hand should be at the same level and lie 2 cm below the right costal arch	
17	Place the palm of the right hand so that the IV finger lies outside of the lateral edge of the rectus abdominis muscle	
18	The base of the right palm is facing down	
19	The hand and forearm are involved in palpation	
20	As the patient exhales, gently and slowly immerse the fingers of the right hand into the abdominal cavity	
21	Until the end of the patient's next inhalation, fix the hand in this position	
22	At the same time, move the lumbar region with the left palm to the fingers of the right hand	
23	During the second exhalation, slowly immerse the fingers of the right hand deeper into the abdominal cavity	
24	At the same time, move the lumbar region to the fingers of the right hand with the left palm	
25	Fix the hand in this position until the end of the patient's next inhale	
26	During the third exhalation, gently and slowly immerse the fingers of the right hand even deeper into the abdominal cavity	
27	At the same time, move the lumbar region with the left palm to the fingers of the right hand	
28	Ask the patient to take a deep abdominal breath	
29	Make a conclusion about the right kidney palpation results: palpable / not palpable	
<i>Palpation of left kidney</i>		
30	Place the left hand on the left half of the patient's lumbar region	
31	The index finger of the left hand is at the level of the 12 rib on the left	
32	The left wrist joint is at the level of the lumbar spine spinous processes	
33	The tips of the II–IV fingers of the right hand should be at the same level and lie 1–2 cm below the left costal arch	
34	Place the palm of the right hand so that the index finger lies on the lateral edge of the rectus abdominis muscle on the left	
35	The base of the right palm is facing down	
36	The hand and forearm are involved in palpation	
37	As the patient exhales, gently and slowly immerse the fingers of the right hand into the abdominal cavity	
38	Until the end of the patient's next inhalation fix the hand in this position	

39	At the same time move the lumbar region with the left palm to the fingers of the right hand	
40	During the second exhalation, slowly immerse the fingers of the right hand deeper into the abdominal cavity	
41	At the same time move the lumbar region with the left palm to the fingers of the right hand	
42	Fix the hand in this position until the end of the patient's next inhale	
43	During the third exhalation gently and slowly immerse the fingers of the right hand even deeper into the abdominal cavity	
44	At the same time move the lumbar region with the left palm to the fingers of the right hand	
45	Ask the patient to take a deep abdominal breath	
46	Make a conclusion about the results of the left kidney palpation: palpable / not palpable	
Completion of the procedure		
47	Make a conclusion about the results of palpation (normal kidneys are not palpable)	
48	Thank the patient	
49	Ask the patient to get dressed	
50	Perform hand hygiene	
Total points _____ (minimum 42 points)		Mark

Full name of the teacher _____ Signature _____

23. PALPATION OF THE URETERAL POINTS, ASSESSMENT OF THE KIDNEY TENDERNESS, AUSCULTATION OF THE RENAL ARTERIES

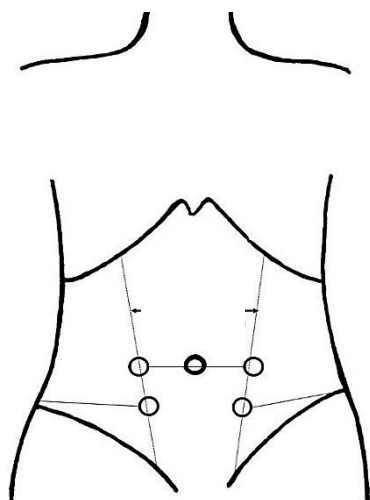


Fig. 67. Palpation of ureteral points on abdomen wall (points 14–19)

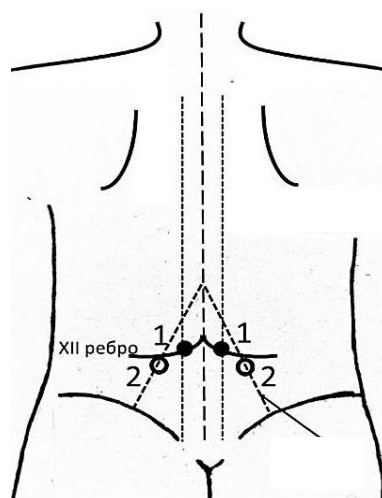


Fig. 68. Palpation of ureteral points on lumbar area (points 21–28)

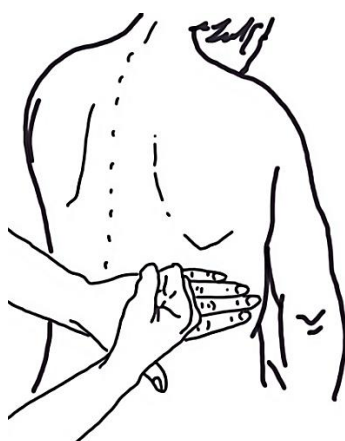


Fig. 69. Assessment of kidney tenderness (points 29–35)

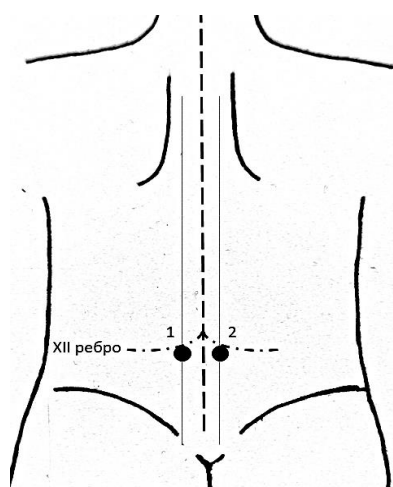


Fig. 70. Auscultation of renal arteries on lumbar area (points 36–47)

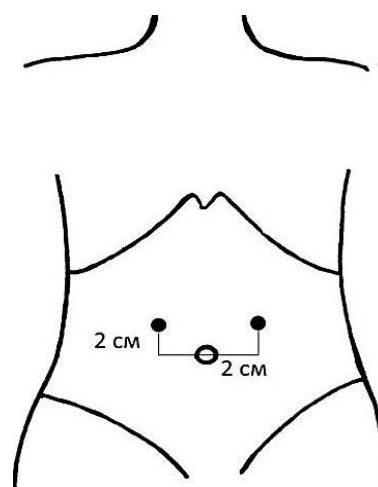


Fig. 71. Auscultation of renal arteries an abdomen wall (points 49–61)

PRACTICAL SKILL SCORECARD

Surname, Name _____ Group ____ Date _____

№	Compliance criteria	1 — done 0 — not done
Preparatory stage		
1	Greet the patient	
2	Introduce yourself to the patient	
3	Ask the patient's full name	
4	Ask the patient's age	
5	Ask about the patient's condition at the beginning of the examination	
6	Tell the patient the name of the examination method "Palpation of the ureteral points, assessment of the kidney tenderness, auscultation of the renal arteries"	
7	Get the patient's informed consent for the examination	
8	Ask the patient to take off his clothing from his abdomen (to the upper border of the symphysis pubic and the lumbar area)	
9	Ask the patient to take a vertical position	
10	Ask the patient to extend his arms along the body	
11	Ask the patient if feels pain in the abdomen or lumbar area	
12	Perform hand hygiene	
13	Sit to the right of the patient, facing him	
Main stage		
<i>Palpation of the ureteral points</i>		
14	With pulp of both thumbs palpate the ureteral points at the outer edge of the rectus abdominis muscle at the level of the navel on both sides	
15	Palpation is carried out simultaneously from both sides	
16	Ask the patient if he feels pain	
17	With pulp of both thumbs palpate the ureteral points at the outer edge of the rectus abdominis muscle at the level of the upper spine of the iliac bones	
18	Palpation is carried out simultaneously from both sides	
19	Ask the patient if he feels pain	
20	Ask the patient to turn back to the examiner	
21	With pulp of both thumbs palpate the ureteral points at the intersection of the outer edge of the psoas muscle and the 12 rib	
22	Palpation is carried out simultaneously from both sides	
23	Ask the patient if he feels pain	
24	With pulp of both thumbs palpate the ureteral points in the costal-vertebral angle (along the vertebral line under the 12 rib)	
25	Palpation is carried out simultaneously from both sides	
26	Ask the patient if he feels pain	

27	Make a conclusion about the results of palpation: pain in the area of the ureteral points is present / absent	
28	Localization of pain, if any	
<i>Kidney tenderness assessment</i>		
29	Place the palm of the left hand horizontally on the patient's right lumbar region: the base of the palm is directed towards the spine, the fingers laterally, the upper edge of the palm is at the level of the XII thoracic vertebra	
30	Tap moderately twice to the back side of the left hand with the inner side of the right hand closed into a fist	
31	Ask the patient if he feels pain	
32	Place the palm of the left hand horizontally on the patient's left lumbar region: the upper edge of the palm is at the level of the XII thoracic vertebra	
33	Tap moderately twice to the back side of the left hand with the inner side of the right hand closed into a fist	
34	Ask the patient if he feels pain	
35	Make the conclusion about the assessment results: the symptom on the right side is positive (pain) / negative; the symptom on the left side is positive / negative	
<i>Auscultation of the renal arteries</i>		
36	Clean the diaphragm of the stethoscope with an antiseptic solution	
37	Insert the ear tips of the stethoscope into the ears	
38	Make sure that the device is switched to the stethoscope diaphragm	
39	Place the head of the stethoscope in the costal-vertebral angle on the left side (along the vertebral line below the level of the 12 rib on the left)	
40	The stethoscope membrane is tightly pressed to the skin	
41	Ask the patient to take a deep breath, exhale and hold breath	
42	Listen to the sounds for 10–15 seconds	
43	Allow the patient to breathe freely	
44	Place the head of the stethoscope in the costal-vertebral angle on the right side (along the paravertebral line below the level of the XII rib on the right)	
45	The stethoscope membrane is tightly pressed to the skin	
46	Ask the patient to take a deep breath, exhale and hold his breath	
47	Listen to the sounds for 10–15 seconds	
48	Allow the patient to breathe freely	
49	Ask the patient to take a horizontal position: lying on his back, legs straightened	
50	Sit to the right of the patient, facing him	
51	Position the head of the stethoscope at the point located 2 cm to the right of the navel and 2 cm up	
52	The stethoscope membrane is tightly pressed to the skin	
53	Ask the patient to take a deep breath, exhale and hold his breath	

54	Listen to the sounds for 10–15 seconds	
55	Allow the patient to breathe freely	
56	Position the head of the stethoscope at a point located 2 cm to the left of the navel and 2 cm up	
57	The stethoscope membrane is tightly pressed to the skin	
58	Ask the patient to take a deep breath, exhale and hold his breath	
59	Listen to the sounds for 10–15 seconds	
60	Allow the patient to breathe calmly and evenly	
61	Make a conclusion about the results of auscultation: systolic murmur in the projection of the renal arteries is heard / not heard	
Completion of the procedure		
62	Thank the patient	
63	Ask the patient to get dressed	
64	Perform hand hygiene	
65	Clean the head of the stethoscope with antiseptic solution	
Total points _____ (minimum 46 points)		Mark

Full name of the teacher _____ Signature _____

24. PALPATION OF THE SPLEEN

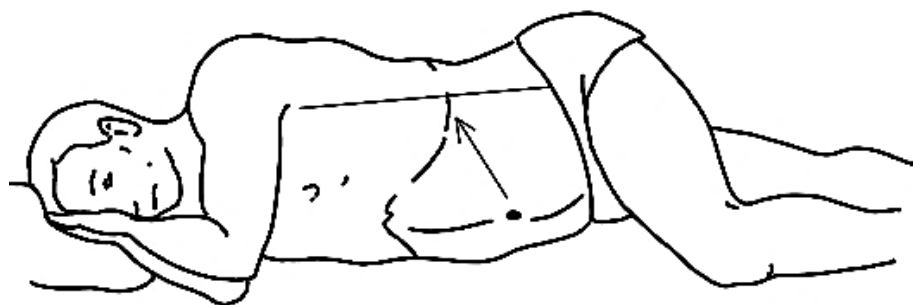


Fig. 72. Patient's position on right side. Anterior axillary line is indicated. Arrow indicates the direction of percussion (points 17–34)

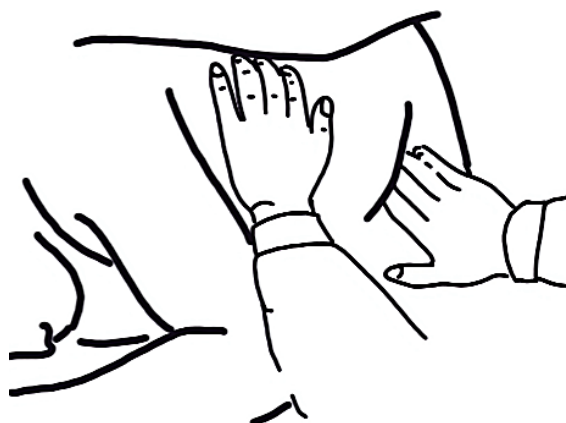

Fig. 73. Palpation of the spleen (points 35–53)

PRACTICAL SKILL SCORECARD

Surname, Name _____ Group ____ Date _____

№	Compliance criteria	1 — done 0 — not done
Preparatory stage		
1	Greet the patient	
2	Introduce yourself to the patient	
3	Ask the patient's full name	
4	Ask the patient's age	
5	Ask about the patient's condition at the beginning of the examination	
6	Tell the patient the name of the examination method "Palpation of the spleen"	
7	Get the patient's informed consent for the examination	
8	Ask the patient to take off his clothing from his abdomen (to the upper border of the symphysis pubic)	
9	Ask the patient to take a horizontal position on his right side	
10	Ask the patient to straighten the right leg	

11	Ask the patient to bend his left knee and hip joints and draw it slightly to the body	
12	Ask the patient to put both hands together and place them under the right cheek	
13	Ask if the patient feels pain/tenderness in the abdomen	
14	Ask the patient to use abdomen breathing	
15	Perform hand hygiene	
16	Sit down facing the patient's abdomen	
Main stage		
<i>Assessment of anterior point of the spleen</i>		
17	Find the 10 th rib from the left side	
18	Find the point of intersection of the 10 th rib and the anterior axillary line	
19	Put the mark with a dermatograph on this point	
20	Place the left palm on the navel, the middle finger is parallel to the left costal arch, the base of the palm is directed to the right costal arch	
21	The finger-pleximeter (III finger) is located perpendicular to the continuation of the line of 10 th rib	
22	The finger-pleximeter is tightly pressed to the skin	
23	The II and IV fingers are apart and don't touch the pleximeter finger	
24	Perform percussion using the quietest percussion method	
25	Use the III finger of the right hand as a hammer: bend it at the proximal and distal interphalangeal joints so that its distal phalanx is perpendicular to the surface of the middle phalanx of the left hand III finger (pleximeter finger)	
26	Tap to the center of this phalanx by movements of the right wrist joint	
27	Short taps, equal strength, two at each point of percussion	
28	Interphalangeal joints of the middle finger, ulnar and shoulder joints of the right hand remain motionless	
29	After the second tap the hammer finger should not remain pressed to the pleximeter finger	
30	Perform percussion from the navel to the intersection of the anterior axillary line and the 10 th rib on the left	
31	Move the finger-pleximeter by its width	
32	Perform percussion until the percussion sound changes from tympanic to dull	
33	Put the mark with a dermatograph without removing the pleximeter finger	
34	The mark should be put on the side of the tympanic percussion sound	
<i>Palpation of anterior edge of the spleen</i>		
35	Place the left hand on the lower part of the patient's chest on the left costal arch (the place of attachment of the 7–10 ribs)	
36	The left fingertips should be facing axillary lines	

37	The tips of the II–V fingers of the right hand should be at the same level	
38	Place the tips of the II–V fingers of the right hand 1 cm below the edge of the left costal arch, if the spleen doesn't extend beyond the lower edge of the costal arch*	
39	The line of the right hand middle finger coincides with the line of the 10 th rib	
40	Place the palm of the right hand with slightly bent and closed fingers on the patient's abdomen	
41	The base of the palm of the right hand is facing the navel	
42	The hand and forearm are involved in palpation	
43	Ask the patient to breathe through the mouth evenly using diaphragmatic breathing (i. e. belly), but without straining the abdominal wall	
44	During the patient's inhale, move the fingers of the right hand with a superficial movement (without immersion) down to the navel by 3–4 cm and form a skin fold	
45	As the patient exhales, gently and slowly immerse the fingers of the right hand into his abdominal cavity	
46	Until the end of the patient's next inhale, fix the hand in this position	
47	Simultaneously squeeze the left costal arch with the left palm	
48	During the second exhale, slowly move the fingers of the right hand deeper	
49	Fix your hand in this position	
50	Simultaneously squeeze the left costal arch with the left palm	
51	During the third exhale, slowly move the fingers of the right hand even deeper	
52	Ask the patient to take a deep abdominal breath	
53	Simultaneously with the patient's inhale move the right hand forward, straightening the fingers in the bent phalanges	
Completion of the procedure		
54	Make a conclusion about the results of the palpation: the spleen is palpable / not palpable	
55	Thank the patient	
56	Ask the patient to get dressed	
57	Perform hand hygiene	
Total points _____ (minimum 40 points)		Mark

Full name of the teacher _____ Signature _____

* If the anterior point of the spleen length, determined by percussion, extends beyond the edge of the left costal arch, then the fingertips of the right hand during palpation should be located at the discovered level.

CONTENTS

INTRODUCTION.....	4
GENERAL RULES AND PRINCIPLES OF OBJECTIVE EXAMINATION OF THE PATIENT	7
1. INSPECTION OF THE SKIN AND SUBCUTANEOUS TISSUES	13
2. INSPECTION AND PALPATION OF THE LYMPH NODES OF THE HEAD AND NECK	17
3. INSPECTION AND PALPATION OF SUPRA-, SUBCLAVIAN AND AXILLARY LYMPH NODES.....	22
4. INSPECTION AND PALPATION OF INGUINAL AND POPLITEAL LYMPH NODES.....	25
5. INSPECTION AND PALPATION OF THE THYROID GLAND	28
6. CHEST SHAPE ESTIMATION (INSPECTION AND PALPATION)	30
7.1. PALPATION OF THE CHEST PAIN POINTS AT ANTERIOR AND LATERAL CHEST SURFACE	33
7.2. PALPATION OF THE CHEST PAIN POINTS AT POSTERIOR CHEST SURFACE	37
8.1. COMPARATIVE PERCUSSION OF THE LUNG AT ANTERIOR AND LATERAL CHEST SURFACE	41
8.2. COMPARATIVE PERCUSSION OF THE LUNG AT POSTERIOR CHEST SURFACE	51
9.1. ASSESSMENT THE INFERIOR BORDER OF RIGHT LUNG.....	58
9.2. ASSESSMENT THE INFERIOR LUNG BORDER OF LEFT LUNG	61
10. AUSCULTATION OF THE LUNGS	64
11. ASSESSMENT THE PULSE ON THE RADIAL, CAROTID ARTERIES AND DORSALIS PEDIS ARTERY.....	70
12. PALPATION OF THE APICAL IMPULSE	73
13. ASSESSMENT OF THE RELATIVE HEART DULLNESS BORDERS.....	75
14. AUSCULTATION OF THE HEART	80
15. SUPERFICIAL PALPATION OF THE ABDOMEN	83
16. PALPATION OF THE SIGMOID COLON	88
17. PALPATION OF THE CECUM.....	91
18. PALPATION OF THE TRANSVERSE COLON	94
19. ASSESSMENT OF THE LIVER SIZE ACCORDING TO M. G. KURLOV'S METHOD	97
20. PALPATION OF THE LIVER	101
21. PALPATION OF THE KIDNEYS IN THE HORIZONTAL POSITION	104
22. PALPATION OF THE KIDNEYS IN THE VERTICAL POSITION	107
23. PALPATION OF THE URETERAL POINTS, ASSESSMENT OF THE KIDNEY TENDERNESS, AUSCULTATION OF THE RENAL ARTERIES	110
24. PALPATION OF THE SPLEEN	114

ISBN 978-985-21-1375-5

