

Babuci A., Catereniuc I.

VARIANTS OF RAMIFICATION AND CONNECTIONS OF THE TEMPORAL AND ZYGOMATIC BRANCHES OF THE FACIAL NERVE

Nicolae Testemitanu State University of Medicine and Pharmacy, Chisinau, Moldova

Etiology of the facial nerve impairments is quite variable and unpredictable because the facial nerve might be affected in many infectious and somatic diseases.

The interest in preservation of the facial nerve functions is of high significance, especially for surgeons in order to avoid iatrogenic injuries of the facial nerve branches in parotid gland ablation, in face-lift and other surgical manipulations in the facial region.

For man as one of the central figures in the society the physiognomy and facial expression is an additional mechanism of emotions expression, that plays a relevant role in human daily activities.

According to Friel [1] about 31 % of patients were not satisfied by the result of the face-lift, but nevertheless with development of the esthetic industry there is a high demand for plastic surgery. Therefore, the problem of diminishing lesions of the facial nerve branches in facial surgery is still one the most actual issues.

In this respect we consider that new data concerning course, divisions and connections of the temporal and zygomatic branches of the facial nerve would be of clinical significance for plastic surgeons, specialists in maxillofacial surgery and oncologists.

Aim of study. The purpose of our study was to evaluate the course, divisions and connections of temporal and zygomatic branches of the facial nerve.

Material and methods. Twenty four embalmed adult halves of heads of cadavers fixed in formaldehyde solution were dissected at the Department of Human Anatomy of Nicolae Testemitanu State University of Medicine and Pharmacy from Chisinau, Republic of Moldova.

An incision of the skin from the temporomandibular joint towards the angle of the mandible was made and the posterior belly of the digastric muscle was revealed and used as a main landmark for facial nerve trunk identification. By dissection the temporal and zygomatic branches of the facial nerve were located and connections of those branches among each other and with the neighbouring nerves were pointed out. All samples were photographed and processed digitally.

Our study was carried out according to the decision regulations of the Ethics Committee of Nicolae Testemitanu State University of Medicine and Pharmacy of the Republic of Moldova.

Results and discussion. The face of an individual being one of the open parts of the human body that could positively or negatively influence somebody's life is still one of the most catching subjects for investigations all over the world.

Nowadays, the people are interested in preservation and prolongation of youth as long as possible. With age the phenotypic characteristics of a man change, but nevertheless the scientists try to improve the quality of life by implementing new methods in esthetic surgery.

In face-lift and other surgical procedures of the craniofacial region there is a high risk of injury of the frontotemporal division [2] of the facial nerve.

The localization of the frontal division of the facial nerve is still problematic because the precise landmarks for it were not found. But according to Sabini [3] a series of veins located in the temporofrontal area could serve as those landmarks. The surgeons try to avoid midfacial dissection in order to avoid injury of the frontal ramification of the facial nerve.

For identification of the facial nerve trunk many landmarks are used but the most commonly the posterior belly of the digastric muscle is used [2].

In all our cases the trunk of the facial nerve was divided into two primary divisions: the temporofacial and the cervicofacial one. In all the dissected samples the temporal and the zygomatic branches derived from the temporofacial division. In the majority of cases the course of the temporal and zygomatic branches was linear and they radially spread from the temporofacial division.

A high degree of variability is characteristic for the facial nerve and it was found in all our samples [4]. Even in the same cadaver the right and left facial nerves showed high variability of division and connections of their branches and in some cases these patterns were totally different in each half of the head [5].

We suppose that due to the connections between the tertiary branches of the facial nerve the iatrogenic effect in case of surgical lesion would be diminished. It is very important to not damage the main divisions such as temporofacial one, because in this case function of the injured branches cannot be restored.

Among the most characteristic connections between the temporal and zygomatic branches the loop-shaped connections prevail and in one case a transverse connection between the temporal branches was marked out (fig. 1).

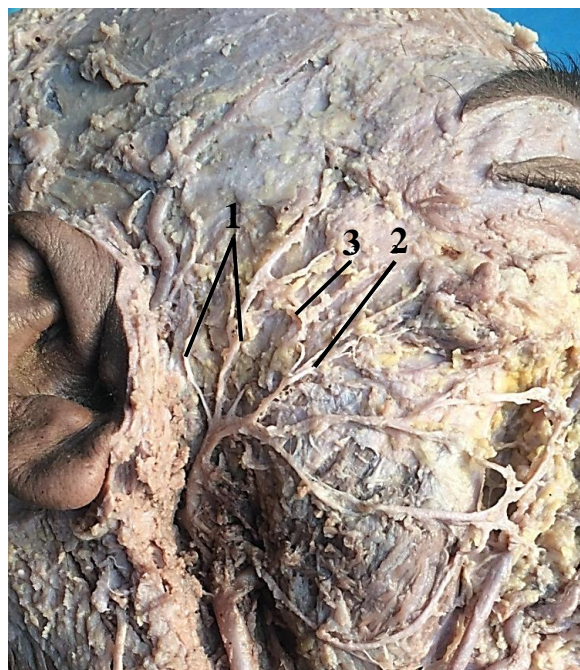


Fig. 1. Branches of the temporofacial trunk of the facial nerve:
1 — temporal branches; 2 — zygomatic branches; 3 — connections of the temporal
and zygomatic branches

Usually after forming the loop-shape connections the branches followed towards the innervated area giving off short linear branches. It should be pointed out that in majority cases a characteristic feature of the zygomatic branches was observed such as multiple terminal branching within the innervated muscles. In majority cases the temporal branch was connected to the auriculotemporal nerve (fig. 2).

In all cases the zygomatic branches were connected to the buccal branches, but connections with the temporal branch were not mentioned in 5 cases.

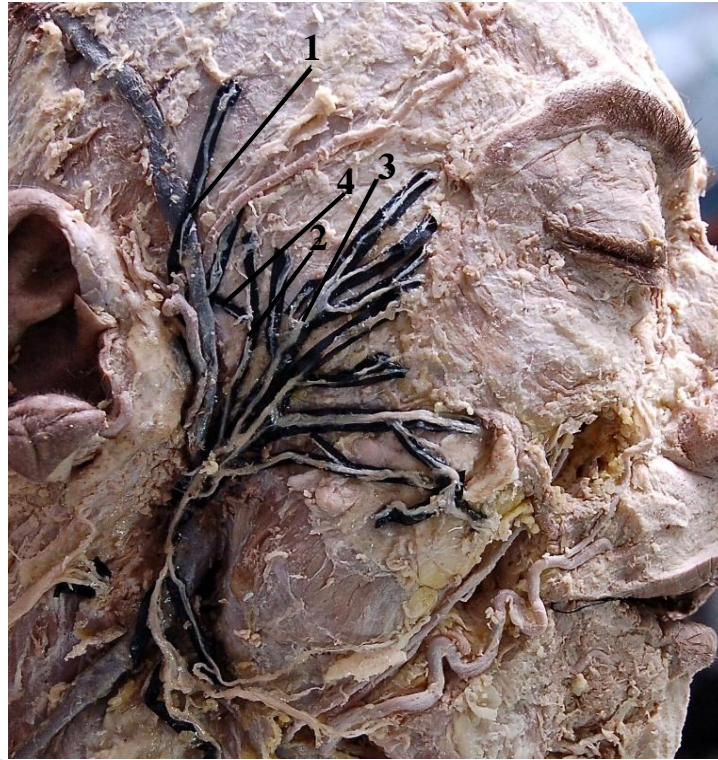

Fig. 2. Branches of the temporofacial division of the facial nerve: 1 — auriculotemporal nerve; 2 — temporal branch; 3 — zygomatic branches; 4 — connection of the temporal branch with the auriculotemporal nerve

Conclusions:

1. The course and connections of the temporal and zygomatic branches of the facial nerve varied from case to case.
2. The temporal branch usually was connected to the auriculotemporal nerve and to one of the zygomatic branches. In the majority cases loop-shape connections between the temporal and zygomatic branches were observed.
3. In all cases the zygomatic branches were connected to the buccal branches, but their connection to the temporal branch were not mentioned in 5 cases.

REFERENCES

1. *The Measures of Face-Lift Patients Satisfaction : The Owsley Facelift Satisfaction Survey with a Long-Term Follow-Up Study* / M. T. Friel [et al.] // *Plastic and Reconstructive Surgery*. 2010. Vol. 126. P. 245–257.
2. *Anatomic landmarks of the buccal branches of the facial nerve* / C. Saylam [et al.] // *Surg. Radiology Anat.* 2006. Vol. 28 (5). P. 462–7.

3. *Anatomical Guides to Precisely Localize the Frontal Branch of the Facial Nerve* / P. Sabini [et al.] // Arch. Facial Plast. Surg. 2003. Vol. 5. P. 150–152.
4. *Baker, D. C. Avoiding Facial Nerve Injuries in Rhytidectomy* / D. C. Baker, J. Conley // Plast. Reconstr. Surg. 1979. Vol. 64. P. 781–785.
5. *Babuci, A. Variations of connections of the parotid plexus branches : a cadaveric study* / A. Babuci // MJHS. 2015. Vol. 3. P. 21–26.

Бабуч А. П., Катеренюк И. М.

**Варианты разветвления и соединений височных и скуловых ветвей
лицевого нерва**

*Государственный медицинский и фармацевтический университет
им. Николае Тестемицану, г. Кишинэу, Молдова*

Исследование проведено на трупном материале с целью установления хода и межнервных связей височных и скуловых ветвей лицевого нерва.

Для идентификации ствола лицевого нерва в качестве ориентира использовались заднее брюшко двубрюшной мышцы и ушной козелок. В большинстве случаев от ствола нерва ответвлялась одна височная и по 1–2 скуловые ветви, а в трех случаях — по две височные. В одном случае две височные ветви соединялись между собой поперечной ветвью. Для височных ветвей характерно соединение с ушно-височным нервом и с одной из скуловых ветвей. Среди соединений между височной и скуловыми ветвями преобладают соединения петлеобразной формы. Скуловые ветви во всех случаях были связаны со щечными, а с височной ветвью соединения в 5 случаях отсутствовали.

Ключевые слова: лицевой нерв, височные ветви, скуловые ветви, соединения.