

**L. A. KAZEKO, O. A. TARASENKO**

**CLINICAL MANIFESTATION  
OF PERIODONTAL PATHOLOGY.  
METHODS OF DIAGNOSTICS**

Minsk BSMU 2016

МИНИСТЕРСТВО ЗДРАВООХРАНЕНИЯ РЕСПУБЛИКИ БЕЛАРУСЬ  
БЕЛОРУССКИЙ ГОСУДАРСТВЕННЫЙ МЕДИЦИНСКИЙ УНИВЕРСИТЕТ  
1-я КАФЕДРА ТЕРАПЕВТИЧЕСКОЙ СТОМАТОЛОГИИ

Л. А. КАЗЕКО, О. А. ТАРАСЕНКО

**КЛИНИЧЕСКИЕ ПРОЯВЛЕНИЯ  
ПАТОЛОГИИ ПЕРИОДОНТА.  
МЕТОДЫ ДИАГНОСТИКИ**

**CLINICAL MANIFESTATION  
OF PERIODONTAL PATHOLOGY.  
METHODS OF DIAGNOSTICS**

Учебно-методическое пособие



Минск БГМУ 2016

УДК 616.314.17-008.1-07 (811.111)-054.6 (075.8)

ББК 56.6 (81.2 Англ-923)

К14

Рекомендовано Научно-методическим советом университета в качестве учебно-методического пособия 16.03.2016 г., протокол № 7

Р е ц е н з е н т ы: канд. мед. наук, доц. Н. М. Полонейчик; канд. мед. наук, доц. А. Г. Третьякович; канд. филол. наук, доц. М. Н. Петрова

**Казеко, Л. А.**

К14 Клинические проявления патологии периодонта. Методы диагностики = Clinical manifestation of periodontal pathology. Methods of diagnostics : учеб.-метод. пособие / Л. А. Казеко, О. А. Тарасенко. – Минск : БГМУ, 2016. – 28 с.

ISBN 978-985-567-432-1.

Изложены причины, патогенез и клинические проявления воспаления тканей периодонта.

Предназначено для студентов 3-го курса медицинского факультета иностранных учащихся, обучающихся на английском языке.

УДК 616.314.17-008.1-07 (811.111)-054.6 (075.8)

ББК 56.6 (81.2 Англ-923)

---

Учебное издание

**Казеко Людмила Анатольевна  
Тарасенко Ольга Александровна**

**КЛИНИЧЕСКИЕ ПРОЯВЛЕНИЯ ПАТОЛОГИИ ПЕРИОДОНТА.  
МЕТОДЫ ДИАГНОСТИКИ**

**CLINICAL MANIFESTATION OF PERIODONTAL PATHOLOGY.  
METHODS OF DIAGNOSTICS**

Учебно-методическое пособие

На английском языке

Ответственная за выпуск Л. А. Казеко  
Переводчик О. А. Тарасенко  
Компьютерная верстка Н. М. Федорцовой

Подписано в печать 16.03.16. Формат 60×84/16. Бумага писчая «Снегурочка».

Ризография. Гарнитура «Times».

Усл. печ. л. 1,63. Уч.-изд. л. 1,63. Тираж 40 экз. Заказ 140.

Издатель и полиграфическое исполнение: учреждение образования  
«Белорусский государственный медицинский университет».

Свидетельство о государственной регистрации издателя, изготовителя,  
распространителя печатных изданий № 1/187 от 18.02.2014.

Ул. Ленинградская, 6, 220006, Минск.

**ISBN 978-985-567-432-1**

© Казеко Л. А., Тарасенко О. А., 2016

© УО «Белорусский государственный  
медицинский университет», 2016

## ANATOMY AND HISTOLOGY OF PERIODONTIUM

Periodontium is the tissue complex participating in the support of the tooth. The tissues include the gingiva, periodontal ligament, cementum and alveolar bone.

*The gingiva* is the keratinized mucosa that surrounds the teeth. It forms a collar around each tooth that ranges in width from 1 to 9 mm. The gingiva is attached in part to the cementum of the tooth and in part to the alveolar process. The gingiva is composed of masticatory mucosa. In light-skinned individuals the gingiva is typically coral pink in color and can be readily distinguished from the adjacent dark red alveolar mucosa by its lighter pink color. Its apical border, that separates it from the adjacent alveolar mucosa, is the mucogingival junction. In dark-skinned persons the gingiva may contain melanin pigment to a greater extent than the adjacent alveolar mucosa. The melanin pigment is synthesized in specialized cells, the melanocytes, located in the basal layer of the epithelium. If pigmented gingiva is surgically resected, it will often heal with little or no pigmentation. Therefore, surgical procedures should be designed so as to preserve the pigmented tissues.

Small mucosal tags on the lingual aspect of each lower canine are called retrocuspid papillae. This is a normal anatomic variation of the gingiva in this location. It does not require any corrective treatment.

The most coronal portion of the gingiva is the gingival margin. The gingival sulcus is the shallow groove between the marginal gingiva and the tooth. The gingival groove is a depression that appears in about 50 % of population. It is an indentation that parallel the oral or vestibular surface of the gingival margin. It is located at about the same level as the apical border of the junctional epithelium. Its level does not correspond to that of the bottom of the gingival sulcus. It is only present occasionally. Its presence or absence is not related to gingival health. Inflammation may cause the tissues to swell and mask its presence.

Clinicians use the terms “free” and “attached” gingiva. “Attached” gingiva refers to the portion of the gingiva apical to the “free” gingiva which is firmly bound to the underlying tooth and alveolar process. The gingiva that occupies the interdental spaces coronal to the alveolar crest is the interdental gingiva. The shape of papilla varies from triangular in the anterior regions due to point sized contacts of the teeth to broader and more square shaped tissue in the posterior sextants due to the teeth having broad contact areas. Col is a valley-like structure situated apically to the contact area (fig. 1). The interdental gingiva is attached to the tooth by junctional epithelium coronally and by connective tissue fibers apically. The most coronal portion of the interdental gingiva is lined with sulcular epithelium (fig. 2).

The texture of the gingiva varies with age and is typically smooth in youth, stippled in adulthood, and again becomes smoother with advanced age. Stippled tissue has a texture similar to the rind of an orange.

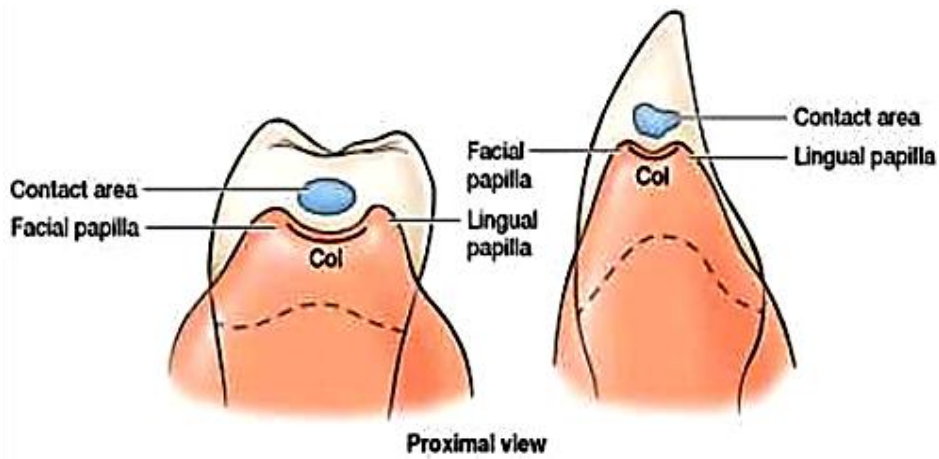


Fig. 1. “Col” is a valley like depression that connects a facial and lingual papilla

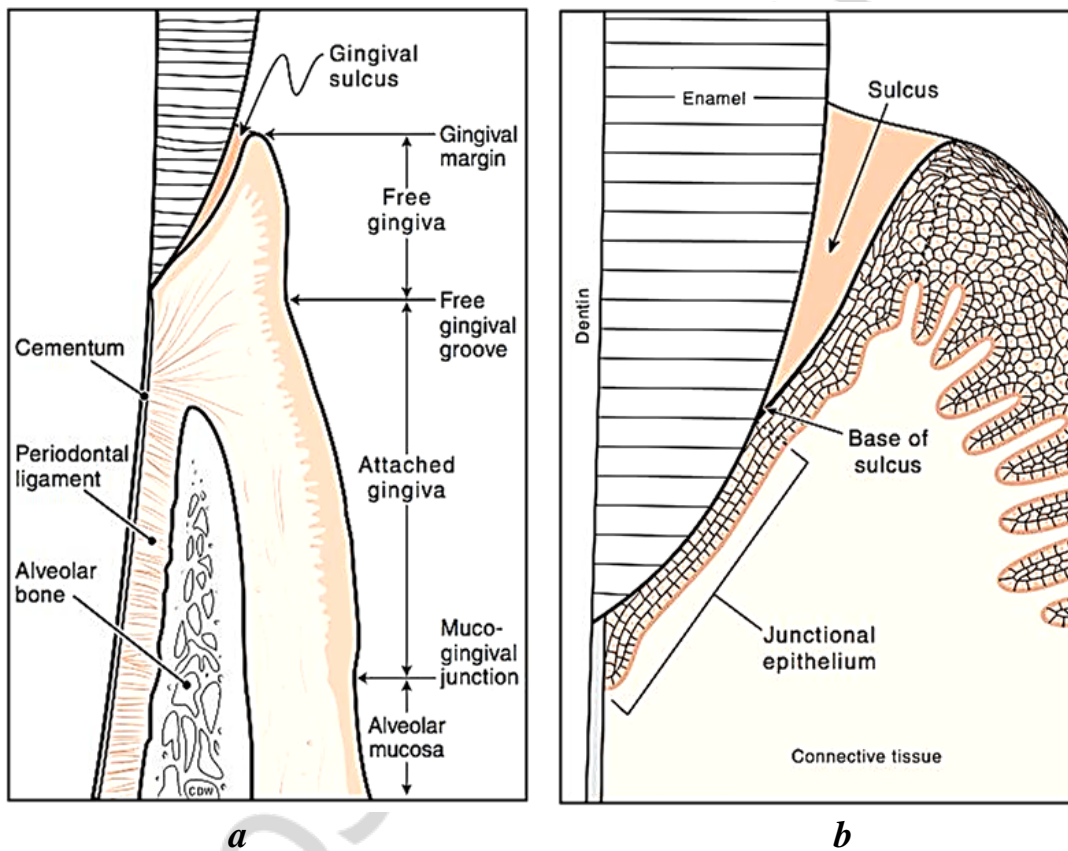


Fig. 2. The gingival tissue in cross section:

*a* — structures of the healthy periodontium in cross section; *b* — the sulcus is a V-shaped, shallow space around the tooth. The base of the sulcus is formed by the junctional epithelium (used with permission from Nield-Gehrig, J. S. and Willmann, D., Foundations of Periodontics for the Dental Hygienist, 2003. Philadelphia: Lippincott Williams & Wilkins. P.35)

*The periodontal ligament* is the connective tissue that connects the tooth to the alveolar bone. The periodontal ligament serves to allow forces to be distributed to the alveolar bone during mastication and occlusal function. The ligament is about 0.15 mm to 0.25 mm in width and has an hourglass shape with the mid root level having the narrowest width. The width of the ligament can adapt to forces by decreasing in lowered function and a widening of the ligament with increased

occlusal load or hyperfunction. With age there is a decrease in vascularity, cell mitotic activity, fiber number and in fibroblasts there is a slight decrease in width.

*The cementum* is a mineralized tissue covering the root of the tooth. It is made of collagen fibers within a mineralized matrix. The mineralized matrix is composed of mainly hydroxyapatite  $[Ca_{10}(PO_4)_6(OH)_2]$ . Cementum is continuously deposited throughout life and the apical third of the root typically has the thickest deposition. In doing so, the deposited cementum compensates for the eruption of teeth from attrition. The thickness of the cementum varies from 15 to 150 microns depending on the location on the root and age of the patient. The extent of cementum coronally exhibits different patterns.

In most instances the cementum overlaps the enamel (~60 %), and less frequently it has a butt-joint (~30 %), and least frequently it ends short of the enamel (5–10 %). This anatomical variation among the position the enamel and cementum board is clinically relevant when gingival recession occurs and patients may present with exposed dentin and root hypersensitivity.

Cementum is subdivided into acellular and cellular types. Cellular cementum is present in the apical third and in the area of furcations.

*The alveolar process* is the osseous tissue of the maxillary and mandibular jaws which houses and supports the sockets of the teeth. The process consists of an external cortical plate, the inner socket wall known as the alveolar bone proper and compact bone, and a cancellous trabecular bone between the two boney layers. The bone is typically thicker in the palatal and lingual areas when compared to the buccal areas. Some areas may be presented with defects known as dehiscences and fenestrations. Dehiscences are areas were the bone has been lost on a root surface and the root is only covered by periosteum and gingiva. Fenestrations are small areas or “windows“ where the bone has been lost on a root surface and is only covered by periosteum and gingiva (fig. 3).

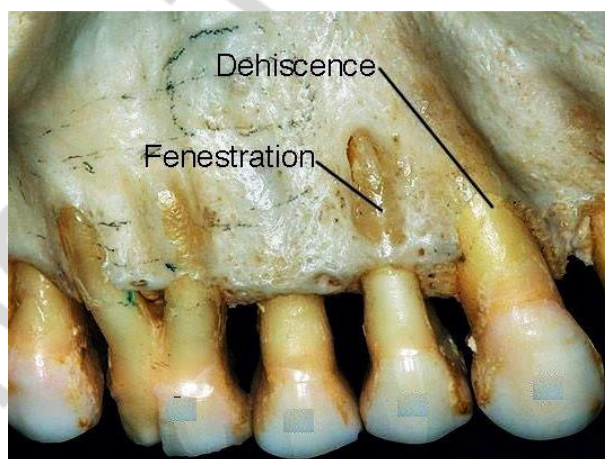


Fig. 3. Dehiscences and Fenestrations

These defects occur in about 20 % of all teeth. Dehiscences were more prevalent in the mandible, whereas fenestrations are more common in the maxilla. Some areas may be predisposed to these defects by having teeth with prominent root morphology, dental crowding, and a position extending beyond the dental

arch. These areas become crucial if periodontal disease occurs or if gingival recession takes place since they may complicate therapy and adversely affect the area's prognosis.

Cancellous or trabecular bone is found interdentially. The bone quality of the maxilla and mandible are generally different and overall the maxilla has more cancellous bone compared to the mandible.

## **ETIOLOGY AND PATHOGENESIS OF GINGIVAL INFLAMMATION**

There is close relationship between poor oral hygiene and gingival inflammation.

Local causes of gingival inflammation are:

1. It was found that microorganisms are the cause of gingival inflammation in 80 % cases.

2. Anatomical features (shallow vestibulum, short frenulums, tooth crowding, over bite).

3. Trauma (overhanging margins of restorations, unsatisfactory dentures, orthodontic appliances and others.).

General causes of gingival inflammation are as follows:

1. Hormonal disturbances (diabetes, pregnancy etc.).

2. Blood diseases.

3. Systemic diseases.

Inflammation of the gums is induced by bacterial biofilms adherent to tooth surfaces. These microorganisms are capable of synthesizing products (e. g., collagenase, hyaluronidase, protease, chondroitin sulfatase, endotoxin) that cause damage to epithelial and connective tissue cells as well as to intercellular constituents such as collagen, ground substance, and glycocalyx (cell coat). The resultant widening of the spaces between the junctional epithelial cells during early gingival inflammation may permit injurious agents derived from bacteria or bacteria themselves to gain access to the connective tissue. Microbial products activate monocytes and macrophages to produce vasoactive substances such as prostaglandin E<sub>2</sub>, interferon, tumor necrosis factor, and interleukin-1. In addition, interleukin-1 $\beta$  alters the properties of gingival fibroblasts by delaying their death via mechanism-blocking apoptosis. This stabilizes the gingival fibroblast population during inflammation.

Morphologic and functional changes in the gingiva during plaque accumulation have been thoroughly investigated, especially in beagle dogs and humans. A useful framework for the organization and consideration of these data has been defined on the basis of histopathologic, radiographic, and ultrastructural features and biochemical measurements. The sequence of events that culminates in clinically apparent gingival inflammation is categorized as the initial, early, and established stages of disease, with periodontal inflammation designated as the advanced stage (table 1). One stage evolves into the next, with no clear-cut dividing lines.

Stages of gingival inflammation

Stages of Gingival inflammation	Time (Days)	Blood Vessels	Junctional and Sulcular Epithelia	Predominant Immune Cells	Collagen	Clinical Findings
I. Initial lesion	2 to 4	Vascular dilation Vasculitis	Infiltration by PMNs	PMNs	Perivascular loss	Gingival fluid flow
II. Early lesion	4 to 7	Vascular proliferation	Same as stage I Rete pegs Atrophic areas	Lymphocytes	Increased loss around infiltrate	Erythema Bleeding on probing
III. Established lesion	14 to 21	Same as stage II, plus blood stasis	Same as stage II but more advanced	Plasma cells	Continued loss	Changes in color, size, texture, and so on

PMNs, Polymorphonuclear leukocytes (neutrophils).

### Stage I. Gingival Inflammation: The Initial Lesion.

The first manifestations of gingival inflammation are vascular changes that consist of dilated capillaries and increased blood flow. These initial inflammatory changes occur in response to the microbial activation of resident leukocytes and the subsequent stimulation of endothelial cells. Clinically, this initial response of the gingiva to bacterial plaque (i.e., subclinical gingivitis) is not apparent. We can see only the *increase of gingival fluid*, measured by weighing of paper pin before and after insertion into the gingival sulcus.

However, these findings are not accompanied by manifestations of tissue damage that are perceptible at the light microscopic or ultrastructural level; they do not form an infiltrate, and their presence is not considered to indicate pathologic changes.

Subtle changes can also be detected in the junctional epithelium and the perivascular connective tissue at this early stage. For example, the perivascular connective tissue matrix becomes altered, and there is exudation and deposition of fibrin in the affected area. In addition, lymphocytes soon begin to accumulate. The increase in the migration of leukocytes and their accumulation within the gingival sulcus may be correlated with an increase in the flow of gingival fluid into the sulcus.

The character and intensity of the host response determines whether the initial lesion resolves rapidly, with restoration of the tissue to a normal state, or evolves into a chronic inflammatory lesion. If the latter occurs, an infiltrate of macrophages and lymphoid cells appears within few days.

### Stage II. Gingival Inflammation: The Early Lesion.

The early lesion evolves from the initial lesion within about 1 week after the beginning of plaque accumulation. Clinically, the early lesion overlaps with and evolves from the initial lesion with no clear-cut dividing line. As time goes



on, clinical signs of *erythema* may appear, mainly owing to the proliferation of the capillaries and increased formation of capillary loops between rete pegs or ridges. *Bleeding on probing* may also be evident.

There is an increase in the amount of collagen destruction, 70 % of the collagen is destroyed around the cellular infiltrate. The main affected fiber groups appear to be the circular and dentogingival fiber assemblies. Alterations in blood vessel morphological features and vascular bed patterns have also been described.

PMNs that have left the blood vessels in response to chemotactic stimuli from plaque components travel to the epithelium, cross the basement lamina, and are found in the epithelium and emerging in the pocket area. PMNs are attracted to bacteria and engulf them in a process of phagocytosis. PMNs release their lysosomes in association with the ingestion of bacteria. Fibroblasts show cytotoxic alterations with a decreased capacity for collagen production.

### **Stage III. Gingival Inflammation: The Established Lesion.**

In chronic gingival inflammation (stage III), the blood vessels become engorged and congested, venous return is impaired, and the blood flow becomes sluggish. The result is localized gingival anoxemia, which superimposes a somewhat *bluish hue* on reddened gingiva. Extravasation of red blood cells into the connective tissue and breakdown of hemoglobin into its component pigments can also deepen the color of the chronically inflamed gingiva.

The established lesion can be described clinically as moderately to severely inflamed gingiva.

Collagenolytic activity is increased in inflamed gingival tissue by the enzyme collagenase. Studies have shown that chronically inflamed gingiva has elevated levels of different enzymes. Neutral mucopolysaccharide levels are decreased, presumably as a result of the ground substance degradation.

### **Stage IV. Gingival Inflammation: The Advanced Lesion.**

Extension of the lesion into alveolar bone. Acute gingival inflammation is a painful condition that comes on suddenly and is of short duration. Subacute gingival inflammation is a less severe phase of the acute condition. Chronic gingival inflammation comes on slowly, is of long duration, and is painless unless complicated by acute or subacute exacerbations. Chronic gingival inflammation is the type most commonly encountered. Acute symptoms occur rarely. Chronic gingival inflammation is a fluctuating disease in which inflammation persists or resolves and normal areas become inflamed.

## **CLINICAL MANIFESTATION OF GINGIVAL INFLAMMATION**

Localized gingival inflammation is confined to the gingiva in relation to a single tooth or group of teeth. Generalized gingival inflammation involves the entire mouth.

Marginal gingival inflammation involves the gingival margin but may include a portion of the contiguous attached gingiva.

Papillary gingival inflammation involves the interdental papillae and often extends into adjacent portion of the gingival margin. Papillae are involved more frequently than the gingival margin, and the earliest signs of gingival inflammation most often occur in the papillae.

Diffuse gingival inflammation affects the gingival margin, the attached gingiva, and interdental papillae.

A systematic clinical approach requires orderly examination of the gingiva for color, size, consistency, surface texture, position, contour, bleeding, depth of sulcus, and pain.

#### **Color changes in the gingiva.**

The normal gingival color is “coral pink”. Gingiva becomes redder when there is an increase in vascularization or the degree of epithelial keratinization becomes reduced or disappears. Thus, chronic inflammation intensifies the red or bluish red color; this is caused by vascular proliferation and reduction of keratinization owing to epithelial compression by the inflamed tissue. Venous stasis will add a bluish hue. Originally light red, the color changes through varying shades of red, reddish blue, and deep blue with increasing chronicity of the inflammatory process. The changes start in the interdental papillae and gingival margin and spread to the attached gingiva.

Small, crescent-shaped, bluish red areas may appear in the marginal gingiva. They are known to be chronic inflammatory lesions caused by local irritants. The suspected contributory role of excessive occlusal forces has never been demonstrated.

Color changes in acute gingival inflammation may be marginal, diffuse or patch-like, depending on the underlying acute condition. In all instances there is an initial bright red erythema. If the condition does not worsen, this is the only color change until the gingiva reverts to normal. In severe acute inflammation, the red color changes to a shiny slate gray, which gradually becomes a dull whitish gray.

Acute gingival inflammation is of sudden onset and short duration; and can be painful. The color of gingiva is *red* (fig. 4). Chronic gingival inflammation is slow in onset, has long duration, usually painless and the most often occurring gingival condition. The color of gingiva is *bluish* (fig. 5)

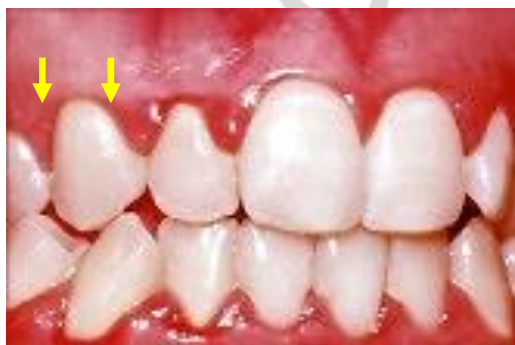

Fig. 4. Acute gingival inflammation

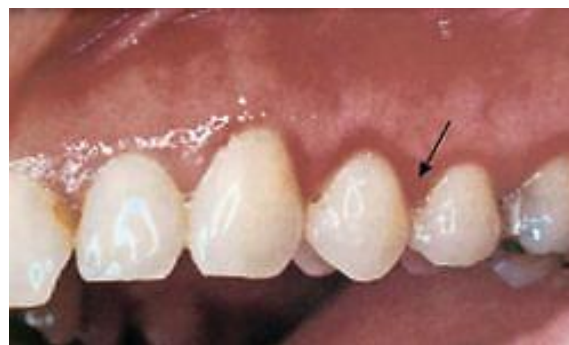

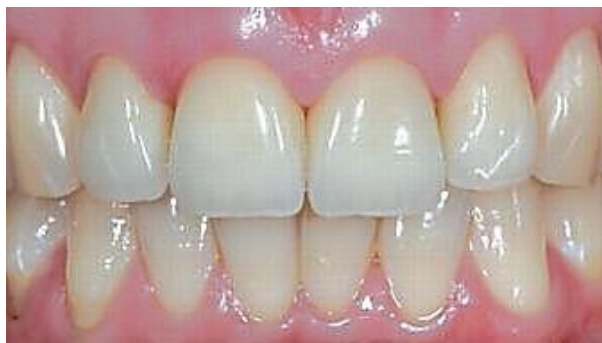Fig. 5. Chronic gingival inflammation

Color changes in gingival inflammation should be differentiated from metallic pigmentation. Bismuth, arsenic, and mercury produce a black line in the gingiva that follows the contour of the margin. The pigmentation may also appear as isolated black blotches involving the marginal, interdental, and attached gingivae. Lead results in a bluish red or deep blue linear pigmentation of the gingival margin (burtonian line). Exposure to silver (argyria) causes a violet marginal line, often accompanied by a diffuse bluish gray discoloration throughout the oral mucosa.

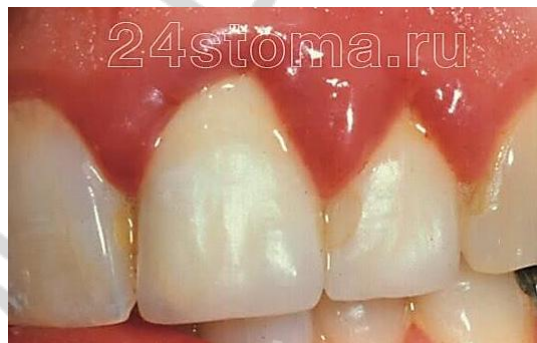#### **Changes in the size of the gingiva.**

The normal size (fig. 6) depends on the sum of the bulk cellular and intercellular elements, and their vascular supply.

In disease, the size is increased, which can be termed as gingival enlargement. The factors responsible for this are increase in fibers and decrease in cells as in the non-inflammatory type. Whereas in the inflammatory type there will be increase in cells and decrease in fibers (fig. 7).



*Fig. 6.* The normal size of gingiva



*Fig. 7.* Inflammatory type of gingival enlargement

#### **Changes in the consistency of the gingiva.**

Both chronic and acute inflammations produce changes in the normal firm, resilient consistency of the gingiva. In chronic gingival inflammation both destructive (edematous) and reparative (fibrotic) changes coexist, and the consistency of the gingiva is determined by their relative predominance.

Clinical and histopathologic changes in gingival consistency.

Chronic gingivitis is characterized by:

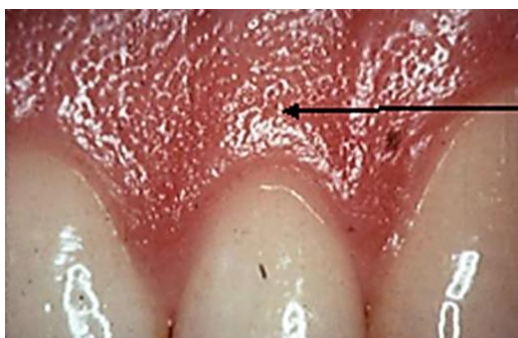1. Soggy puffiness that pits on pressure.
2. Marked softness and friability, with fragmentation on exploration with probe and pinpoint surface areas of redness and desquamation.
3. Firm, leathery, consistency.

Acute gingival inflammation is characterized by:

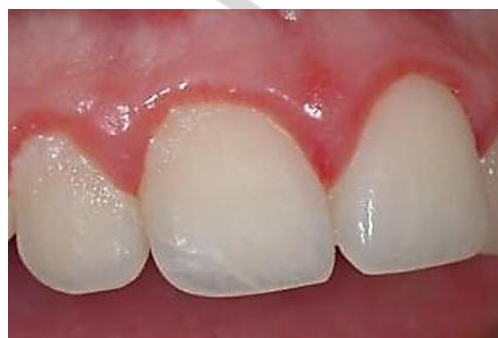1. Diffuse puffiness and softening.
2. Sloughing with grayish flake-like particles of debris adherent to eroded surface.
3. Vesicle formation.

### **Changes in the surface texture of the gingiva.**

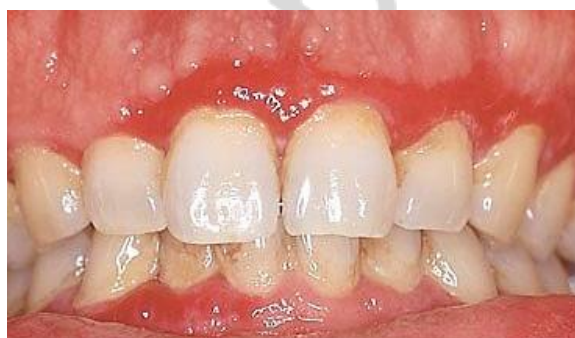Under normal conditions, gingiva appears to be stippled (orange rind appearance) due to attachment of gingival fibers to the underlying bone (fig. 8). Microscopically, alternate rounded protuberance and depressions in the gingival layer may rise to stippled appearance. Stippling is absent in disease conditions (fig. 9). Loss of surface stippling is an early sign of gingival inflammation. In chronic inflammation the surface is either smooth and shiny or firm and nodular, depending on whether the dominant changes are exudative or fibrotic. Smooth structure is also produced by epithelial atrophy in senile atrophic gingival inflammation, and peeling of the surface occurs in chronic desquamative gingival inflammation (fig. 10). Hyperkeratosis results in a leathery texture, and noninflammatory gingival hyperplasia produces a nodular surface.



*Fig. 8.* Stippled/orange rind surface



*Fig. 9.* Exudative changes of the attached gingiva (absence of stippling)



*Fig. 10.* Desquamative gingival inflammation

### **Changes in position of the gingiva.**

Recession is exposure of the root surface by an apical shift in the position of the gingiva. The severity of the recession is determined by the actual position of the gingiva, not by its apparent position. The actual position (hidden recession) is the level of the epithelial attachment on the tooth i.e. from the cemento-enamel junction (CEJ) to the probable depth of the pocket, whereas the apparent position (visible recession) is the level of the CEJ of the gingival margin (fig. 11). Senile (atrophic) gum recession may occur in old age.

Recession refers to the location of the gingiva, not to its condition. Receded gingiva is often inflamed but may be normal except of its position. There is classification of gingival recession (table 2).



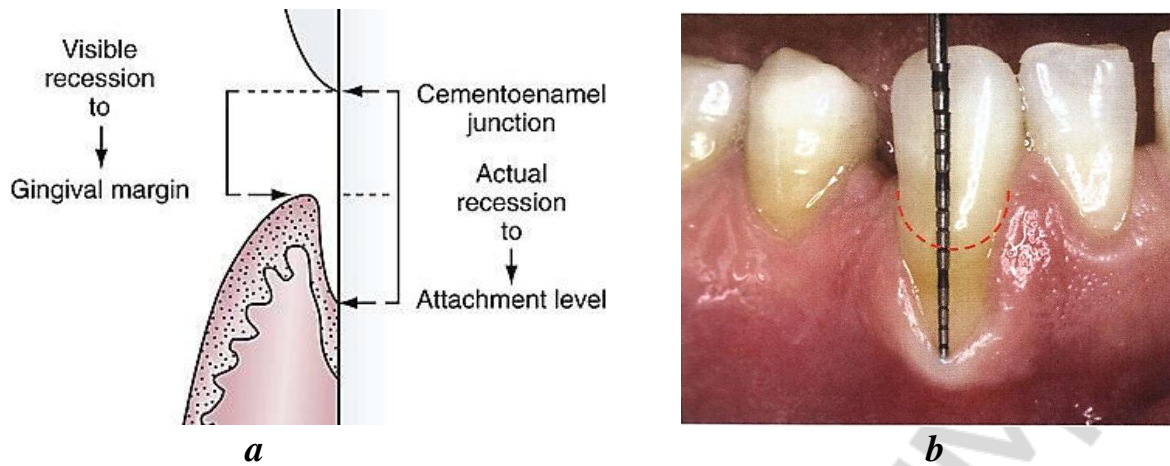


Fig. 11. Gingival recession;  
*a* — types of gingival recession; *b* — measurement of gingival recession

Table 2

**Classification of gingival recession according to P. D. Miller**

Classification	Criteria
Class-I	Marginal tissue recession that does not extend to the mucogingival junction
Class-II	Marginal tissue recession that extends to or beyond the mucogingival junction, with no periodontal attachment loss (bone or soft tissue) in the interdental area
Class III	Marginal tissue recession that extends to or beyond the mucogingival junction, with periodontal attachment loss in the interdental area or malpositioning of teeth
Class IV	Marginal tissue recession that extends to or beyond the mucogingival junction, with severe bone or soft tissue loss in the interdental area and/or severe malpositioning of teeth

Prognosis of class I and II is good to excellent.

Class III: Only partial coverage can be expected.

Class IV: Poor prognosis.

Plaque-induced gingival inflammation is the primary etiological factor responsible for gingival recession; the next common cause is faulty tooth-brushing. Other secondary factors of gingival recession are broadly categorized as: anatomic factors, habits, iatrogenic factors, physiologic factors.

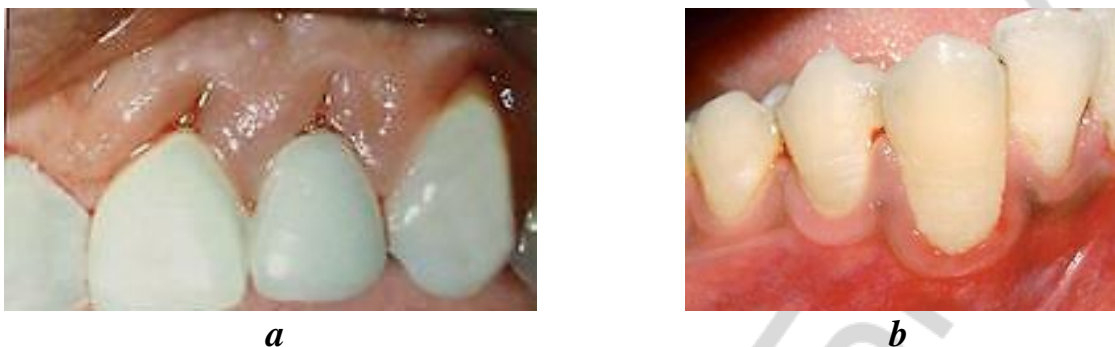Clinical significance of gingival recession:

1. The exposed root surface may be susceptible to caries.
2. The exposed root surface may be extremely sensitive.
3. Hyperemia of the pulp may occur due to gingival recession.
4. Interproximal recession creates oral hygiene problems thereby resulting in plaque accumulation.
5. Finally, it is aesthetically unacceptable.

**Changes in gingival contour.**

Healthy gingival papillae have triangular contour in the frontal part of dental arch and trapezoidal contour in the distal part of dental arch. Gingival inflammation is characterized by subdued contour. Marginal gingiva may become rounded or rolled, whereas interdental papilla can become blunt and flat.

Stillman's clefts are apostrophe-shaped indentations extending from and into the gingival margin for varying distances (fig. 12). The clefts generally occur on the facial surface. One or two may be present in relation to a single tooth. The clefts may repair spontaneously or persist as surface lesion of deep periodontal pockets that penetrate into surrounded tissues. Their association with trauma from occlusion has not been substantiated.



*Fig. 12. Changes in gingival contour:  
a — Stillman's clefts; b — McCall's festoons*

The clefts are divided into simple clefts (in which cleavage occurs in the single direction (the most common type)), and compound clefts (in which cleavage occurs in more than one direction).

McCall's festoons are life preserver-shaped enlargements of the marginal gingiva that occur more frequently in the canine and premolar areas on the facial surface. At the early stages, the color and consistency of the gingiva are normal. However, accumulation of food debris leads to secondary inflammatory changes.

### **Gingival bleeding.**

Gingival bleeding varies in severity, duration and the ease with which it is provoked. Bleeding on probing is easily detectable clinically and therefore is of great value for the early diagnosis and prevention of more advanced gingival inflammation.

Gingival bleeding on probing is one of the earliest visual signs of inflammation. It can appear earlier than color changes or any other visual signs of inflammation. It also provides an additional advantage, by being a more objective sign that requires less subjective estimation by the examiner. Gingival bleeding on probing also helps us to determine whether the lesions are in an active or inactive state. In inactive lesion, there will be little or no bleeding on probing, whereas active lesions bleed more readily on probing. Etiological factors responsible for gingival bleeding on probing can be divided into local factors (factors that result in acute bleeding and factors that cause chronic or recurrent bleeding) and systemic factors.

Acute bleeding is caused due to:

1. Toothbrush trauma.
2. Impaction of sharp pieces of hard food.
3. Gingival burns from hot foods or chemicals.
4. In conditions such as acute necrotizing ulcerative gingivitis (ANUG).

Chronic bleeding is caused due to:

1. Chronic inflammation due to the presence of plaque and calculus.
2. Mechanical trauma, e. g. from toothbrushing, tooth picks or food impaction.
3. Biting of solids foods such as apple.

Systemic factors include various systemic diseases such as vitamin K deficiency, platelet disorders such as thrombocytopenia purpura, other coagulation defects such as hemophilia, leukemia and others.

Bleeding could also occur as a result of excessive administration of drugs such as salicylates and anticoagulants such as dicumarol and heparin.

Microscopic changes associated with gingival bleeding on probing are:

- Thinning and microulcerations of the sulcular epithelium are seen in the epithelium;
- dilation of the capillaries takes place in the connective tissue.

Bleeding on probing (BoP).

A periodontal probe is inserted to the “bottom” of the gingival/periodontal pocket by applying light force and is moved gently along the tooth (root) surface. If bleeding is provoked upon retrieval of the probe, the site examined is considered “BoP” — positive and, hence, is inflamed.

The chart (fig. 12) is used to identify BoP-positive sites in a dichotomous way at the initial examination. Each tooth in the chart is represented and each tooth surface is indicated by triangle. The inner segments represent the palatal/lingual units, the outer segments the buccal/labial units, and the remaining fields the two approximal gingival units. The fields of the chart corresponding to the inflamed gingival units are marked in red. The mean BoP score (i.e. gingival inflammation) is given as percentage. This method of charting not only serves as a means of documenting areas of health and disease in the dentition, but charting during the course of therapy or maintenance will disclose sites which become healthy or remain inflamed. The topographical pattern will also identify sites with consistent or repeated BoP at various observation periods.

Patient name: *A. N. Othar*

Date: *1 November 2002*

**SITES WITH BLEEDING ON PROBING**

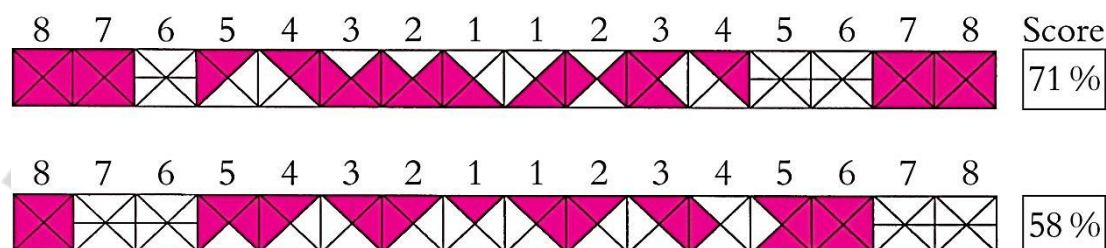


Fig. 12. The chart for identification BoP-positive sites

### **Depth of sulcus.**

The sulcus depth usually remains at 1–3 mm irrespective of the level of clinical attachment. “Pseudopockets” may be present in cases of slightly increased probing depth without concomitant attachment and alveolar bone loss and presence/absence of bleeding on probing.

### **Pain.**

Usual gingival inflammation (apart acute infections and desquamative gingivitis) is painless.

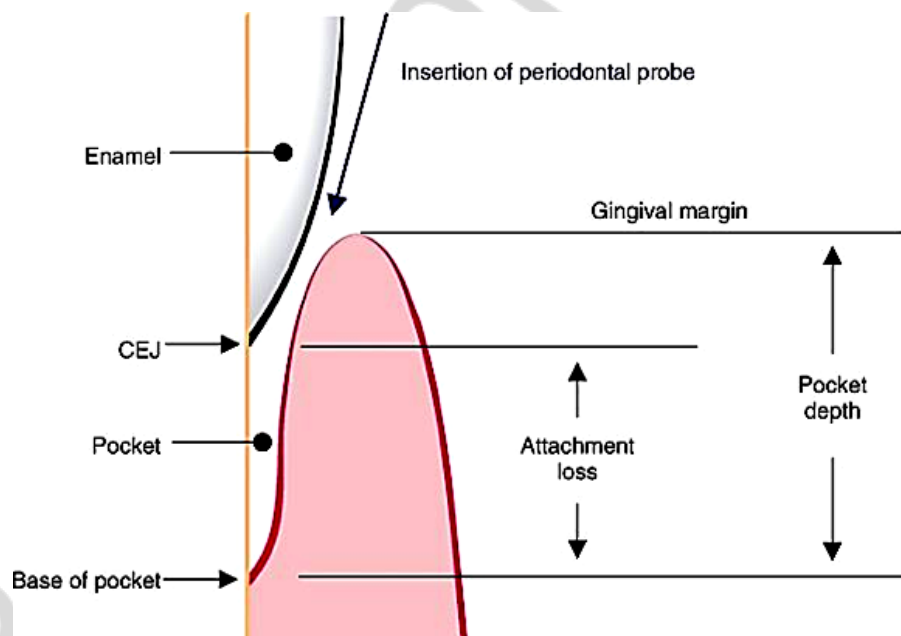
## **DESTRUCTIVE CHANGES IN PERIODONTAL TISSUES**

Signs of destructive changes in periodontal tissues are as follows:

1. Attachment loss.
2. Periodontal pocket (depth of probing more than 4 mm), suppuration.
3. Tooth mobility.
4. Pathological migration of the teeth (fan-shaped divergence).

### **Assessment of probing attachment level (PAL).**

Another measurement of the extent of the periodontal support that is often reported, but is occasionally misinterpreted is the clinical attachment level (CAL). This is the measurement of the position of the soft tissue in relation to the CEJ that is a fixed point that does not change throughout life, albeit at times it is hard to visualize (e. g. in case of abfraction lesions or chemical root erosions). Two measurements are used to calculate the CAL: the probing depth and the distance from the gingival margin to the CEJ (fig. 13).



*Fig. 13. Clinical attachment level*

A healthy sulcular depth is 3 millimeters or less. As the original sulcular depth increases and the apical migration of the junctional epithelium has simultaneously occurred, the pocket is now lined by pocket epithelium (PE)



instead of junctional epithelium (JE). To have a true periodontal pocket, a probing measurement of 4 mm or more must be clinically evidenced. In this state, much of the gingival fibers that initially attached the gingival tissue to the tooth have been irreversibly destroyed. The depth of the periodontal pockets must be recorded in the patient record for proper monitoring of periodontal disease.

PAL may be assessed to the nearest millimetre by means of a graduated probe and expressed as the distance in millimetres from the CEJ to the bottom of the probeable gingival/periodontal pocket. The clinical assessment requires the measurement of the distance from the free gingival margin to the CEJ for each tooth surface. After recording this, PAL may be calculated from the periodontal chart (i. e. PPD — distance CEJ-free gingival margin). In cases with gingival recessions, the distance CEJ-free gingival margin turns negative and, hence, will be added to the PPD to determine PAL.

In recent years, periodontal probing procedures have been standardized to the extent that automated probing systems, for example the Florida Probe, provides periodontal charts which document periodontal pocket depth, probing attachment level, bleeding on probing, furcation involvement and tooth mobility. Also, repeated examinations allow the comparison of parameters and, hence, an assessment of the healing process.

#### **Assessment of probing pocket depth (PPD).**

For effective treatment planning, the location, topography, and extent of periodontal lesions must be recognized in all part of the dentition. It is, therefore, mandatory to examine all sites of all teeth for the presence or absence of periodontal lesions. This turn means that single-rooted teeth have to be examined at four sites at least (e. g. mesial, buccal, distal, and oral) and multirooted teeth at six sites at least (e. g. mesiobuccal, buccal, distobuccal, disto-oral, oral, and mesio-oral) with special attention to the furcation areas.

The probing depth, that is the distance from the gingival margin to the bottom of the gingival sulcus/pocket, is measured to the nearest millimetre by means of a graduated periodontal probe.

Results from PPD measurements will only in rare situations (when the gingival margin co-incides with the cemento-enamel junction(CEJ)) give proper information regarding the extent of loss of probing attachment. For example, an inflammatory edema may cause swelling of the free gingival resulting in coronal displacement of the gingival margin without a concomitant migration of the dentogingival epithelium to a level apical to the CEJ. In such situation a pocket depth exceeding 3–4 mm represents a “pseudo-pocket”. In other situations, an obvious loss of periodontal attachment may have occurred without a concomitant increase of PPD (in case of multiple recessions). Hence, the assessment of the PPD in relation to the CEJ is a indispensable parameter for the evaluation of the periodontal condition (i. e. PAL).

#### **Tooth mobility.**

Normal, physiologic tooth mobility of about 0.25 mm is present in health. This is because the tooth is not fused to the bones of the jaws, but is connected to

the sockets by the periodontal ligament. This slight mobility is to accommodate forces on the teeth during chewing without damaging them. Abnormal, pathologic tooth mobility occurs when the attachment of the periodontal ligament to the tooth is reduced (attachment loss), or if the periodontal ligament is inflamed. To assess a tooth's mobility two blunt instruments are used (fig. 14). E. g. end of mirror and probe. To quantify mobility, Millers index of mobility is used:

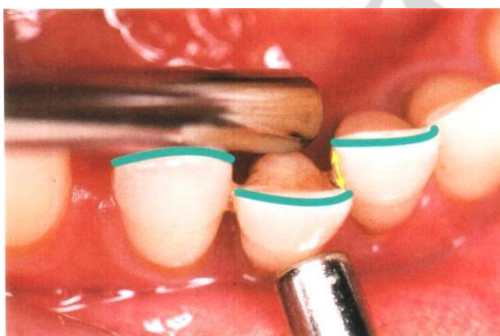Degree 0 — Normal physiological mobility measured at the crown level. The tooth show mobility of 0.1–0.2 mm in the horizontal direction within the alveolus.

Degree 1 — increased mobility of the crown of the tooth of at the most 1 mm in the horizontal direction.

Degree 2 — visually increased mobility of the crown of the tooth exceeding 1 mm in the horizontal direction.

Degree 3 — severe mobility of the crown of the tooth in both horizontal and vertical directions, and impinging of the function of the tooth.

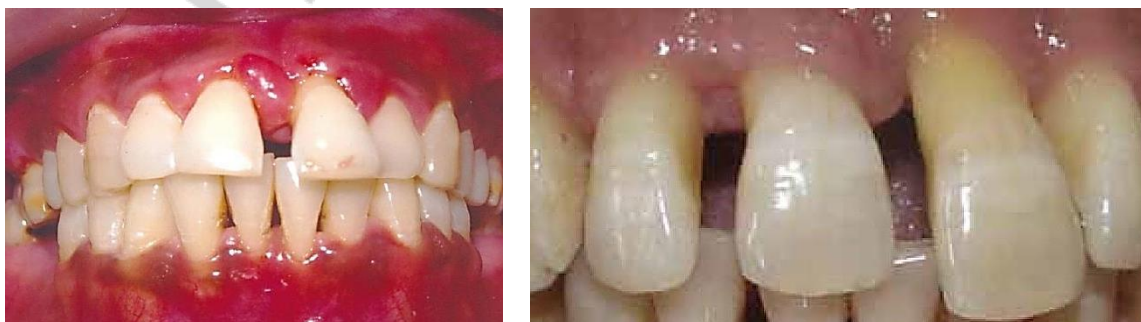The continuous loss of the supporting tissues during progression of plaque-associated periodontal disease progression may result in increased tooth mobility.



*Fig. 14.* Assessment of tooth mobility

### **Pathological migration of the teeth.**

Pathologic tooth migration is a common complication of periodontal disease and most frequently affects the anterior teeth. Many a times, pathologically migrated tooth or teeth can have a deep negative impact on self-esteem and psyche of patients and often motivates them to seek dental care (fig. 15). The etiology being complex and multifactorial, correction of pathologic tooth migration may involve either periodontal therapy alone or a multidisciplinary approach involving periodontal, orthodontic and restorative treatments.



*Fig. 15.* Pathologic tooth migration

### **Assessment of furcation involvement.**

The progression of periodontitis around multirooted teeth may involve the destruction of the supporting structures of the furcation area. In order to plan the treatment of such involvement, a detailed and precise identification of the presence and extent of periodontal tissue breakdown within the furcation area is of importance for proper diagnosis.

Furcation involvement is assessed from all the entrances of possible periodontal lesions of multirooted teeth, that is buccal and/or lingual entrances of mandibular molars. Maxillary molars and premolars are examined from the buccal, distopalatal and mesiopalatal entrances. Owing to the position of the first maxillary molars within the alveolar process, the furcation between the mesiobuccal and palatal roots is best explored from the palatal aspect.

Furcation involvement is explored using a curved periodontal probe with 3-mm graduations (Nabers furcation probe). Depending on the penetration depth, the furcation involvement is classified as “superficial” or “deep”:

Class I: horizontal probing depth of  $\leq 3$  mm from one or two entrances.

Class II: horizontal probing depth of  $> 3$  mm from at most one entrance and/or in combination with a furcation involvement class I.

Class III: horizontal probing depth of  $> 3$  mm from two or more entrances usually represents a “through-and-through” destruction of the supporting tissues in the furcation.

The furcation involvement class is presented on the periodontal chart together with a description of which tooth surface the involvement has been identified on.

## **RADIOLOGICAL ASSESSMENT OF PERIODONTIUM**

Types of Dental Imaging. There are a number of different types of imaging services available to a dentist. Each is beneficial in the diagnosis and overall care of the patient. A few examples include:

- Clinical Photographs;
- Radiographs;
- Cone Beam Computed Tomography;
- Magnetic Resonance Imaging.

Clinical Photographs. Taking such photo's before, during and after helps both the dentist and patient assess the treatment outcome.

Intra oral radiographs — *bitewings*. They are taken to find interproximal caries and to assess interproximal bone levels (fig. 16, *a*).

Intra oral radiographs — *periapicals* are used for assessment of the periodontal status (fig. 16, *b*).

Extra oral radiographs — *dental panoramic tomographs* are used for as part of a periodontal assessment of bone support, where there are pockets greater than 5 mm (fig. 17).

Radiographs provide information on the height and configuration of the interproximal alveolar bone. Obscuring structures such as tooth roots often

make it difficult to identify the outline of the buccal and lingual alveolar bony crest. The analysis of the radiographs must, therefore, be combined with a detailed evaluation of the periodontal chart in order to correctly estimate the “horizontal” and “angular” bony defects.

To enable meaningful comparative analysis, a reproducible radiographic technique should be used: a long-cone paralleling technique is recommended (fig. 16, c).

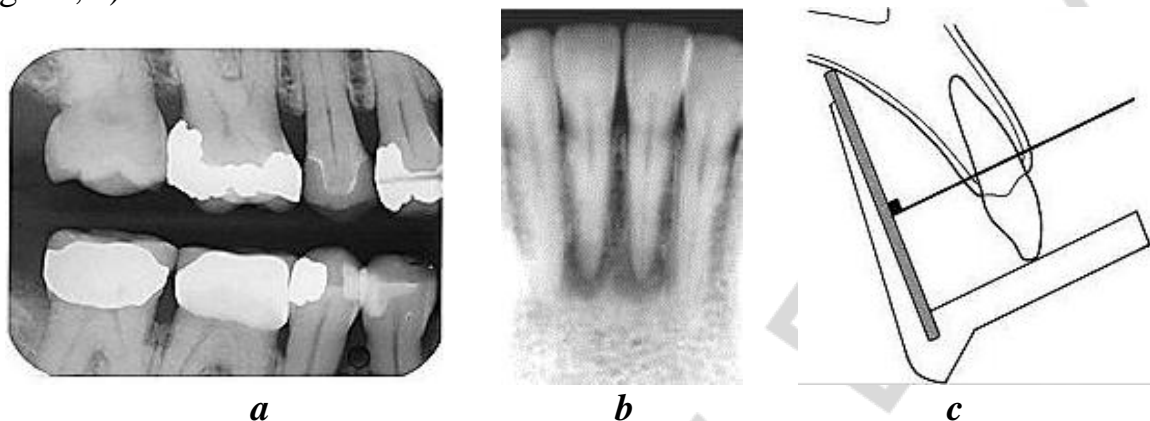


Fig. 16. Intra oral radiographs:  
a — bitewings; b — periapicals; c — long-cone paralleling tomographs technique

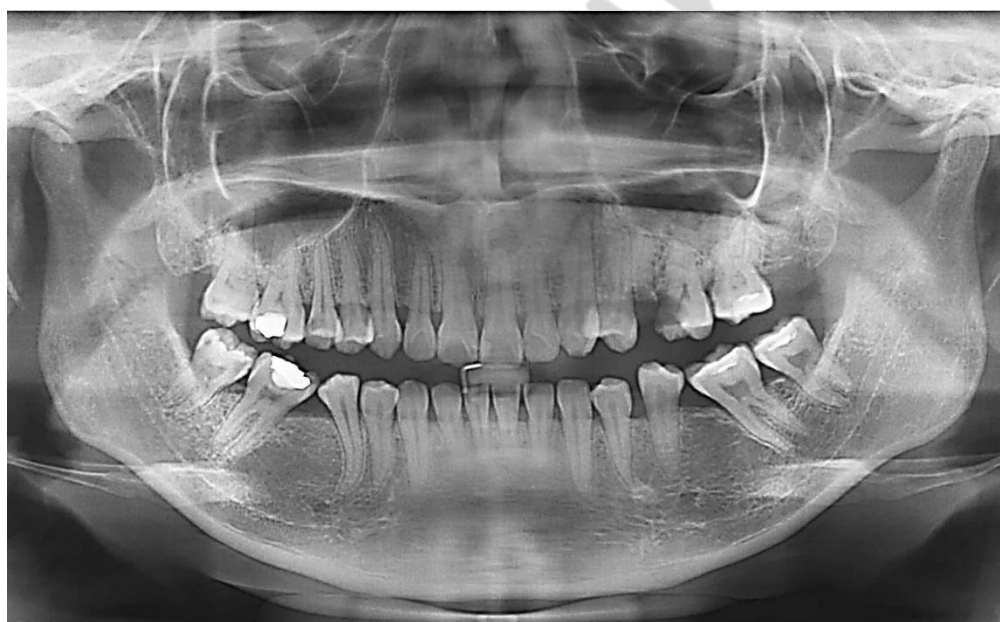
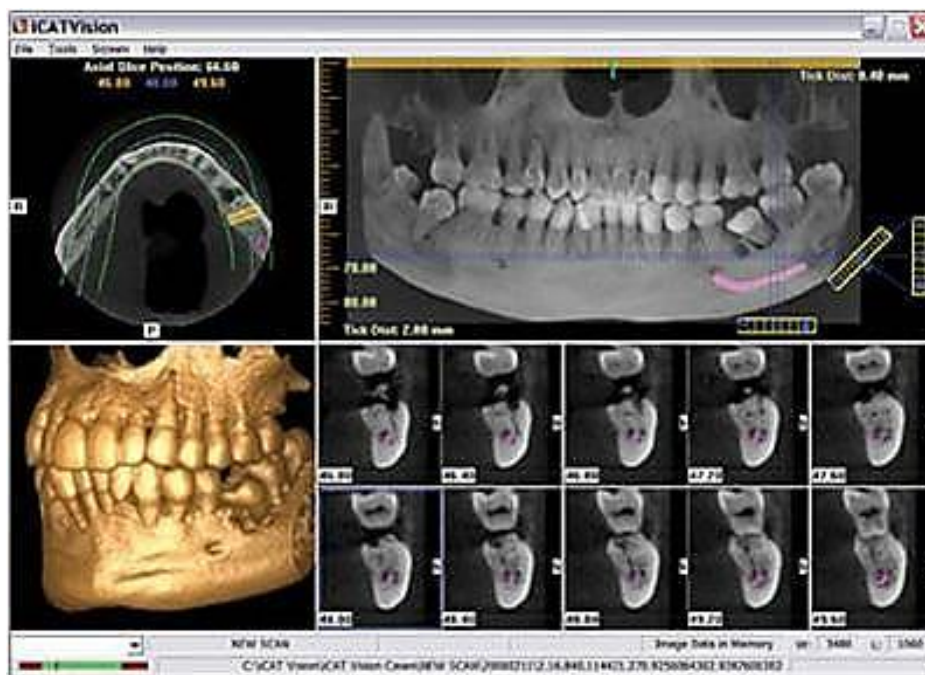
Fig. 17. Extra oral radiographs — dental panoramic tomography

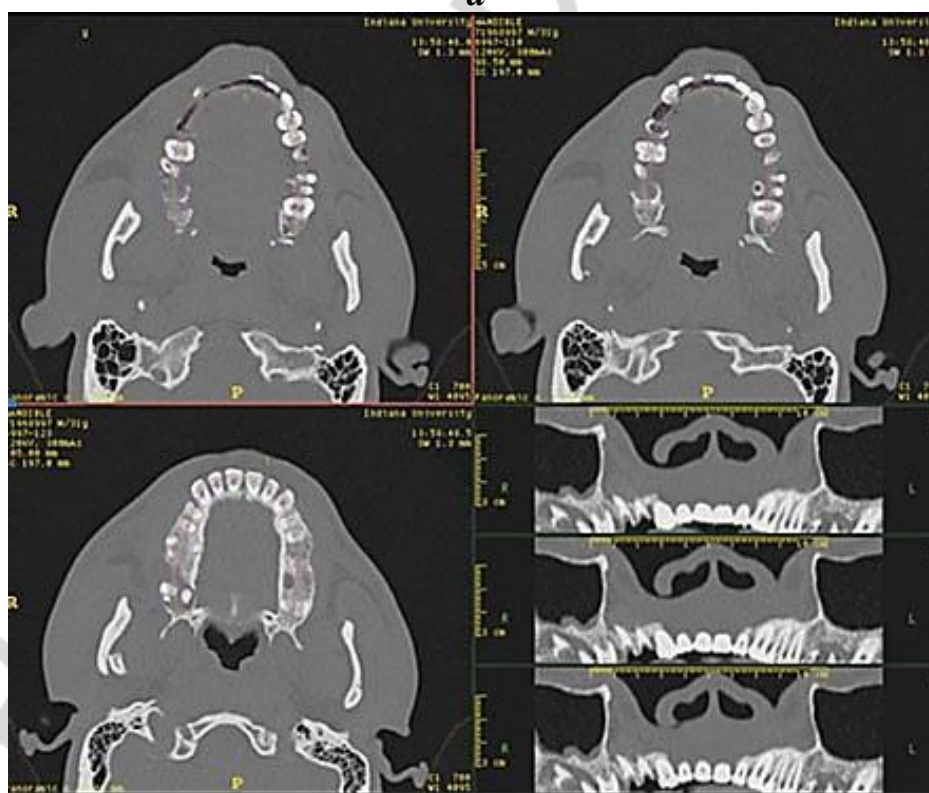
*Cone beam computed tomography* (CBCT) becoming increasingly used in dentistry in the fields of orthodontics, implantology and endodontics. It works by producing slices of images of the area concerned using x-rays. These images are divergent, forming a cone. Advantages of this technique include it’s ability to record a high level of bone detail. Therefore it is able to work around bone levels of the patient.

*Magnetic resonance imaging* (MRI). Patients are placed into an intense magnetic field. This makes their hydrogen nuclei align in the field. Radio waves

are then pulsed into the patient, the hydrogen nuclei “wobble”, producing an alteration in the magnetic field. This induces an electric current in coils placed around the patient. The computer reads this and is able to produce an image of it. It is capable of producing any image a CT Scanner can produce, however it becomes difficult as the cost of MRI scan’s is much greater than using traditional methods of radiography.



*a*



*b*

*Fig. 18.* Extra oral radiographs:  
*a* — cone beam computed tomography (CBCT); *b* — magnetic resonance imaging (MRI)



Plan of dental roentgenogram analysis (assessment of periodontium). **Never interpret a faulty radiograph.**

Conduct an analysis of tooth shadow assessing: estimate periodontal ligament space: uniformity, width, state of lamina dura of alveola (preserved, destroyed, thinned, thickened).

Estimate surrounding tissues:

- a) state of interdental septa: shape, height, state of lamina dura;
- b) presence of bone restructuring: analysis of pathologic shadow (destruction or osteosclerosis) include determination localization, shape, size, outlines, intensity, structure.

Brief plan of periodontal analysis includes evaluation of alveolar crest presence, bone resorption, type resorption and degree of severity resorption.

### **The periodontium on the X-ray image.**

The gingiva and the alveolar mucosa hardly give a visible radiographic image. This is due to the low atomic number of the elements composing these tissues. Consequently the absorption of roentgen rays is very low. This means that the gingiva and its changes are not radiographically visible.

*The periodontal ligament space* gives no visible absorption of roentgen rays. On the X-ray image, therefore, the periodontal ligament space is a radiolucent line which, from the alveolar crest on, surrounds the entire radix of the tooth. On the radiograph the periodontal ligament space is not always visible as a single dark line (near a tooth with a radicular concavity). It is thinner in the middle of the root and slightly wider near the alveolar crest and the apex, suggesting that the fulcrum of the physiologic movements is in the region where PDL is the thinnest.

*The alveolar process.* The interdental septum is made of the cancellous bone of the alveolar process. The radiographic image of the alveolar process seems to be determined by the trabeculae of the cancellous bone, which appear to be irregularly arranged. This image is known as trabecular pattern. The bone trabeculae can be arranged in various ways.

*Maxilla.* The trabeculae of the maxilla are arranged haphazardly. The marrow spaces in the maxilla are smaller than those in the mandible.

*Mandible.* In the mandible the intertrabecular space can vary from one area to the next. Characteristic radiographic configurations of the trabeculae are:

- a reticular pattern;
- a linear, horizontally oriented arrangement of the trabeculae.

Rarely the trabecular pattern in the mandible becomes less dense in the direction of the apices and towards the caudal cortical demarcation, or is even absent. In that case the bone shows a uniform radiographic density, largely caused by the cortical bone. Yet some trabeculae are often still visible at the apex and between the roots. The intertrabecular space in the mandible is usually larger than that in the maxilla. When the patterns are very different it may be useful to compare the X-ray images of the left and of the right side in order to establish whether abnormality is present. In case of doubt it is also important to repeat radiography after a certain interval.

*The alveolar bone (lamina dura)* (fig. 19, *a*). A narrow radiopaque zone around PDL represents the lamina dura (lamina cribrosa), surrounded by cancellous bone. The walls of the alveolar process consist of a layer of cortical bone (fig. 19, *b*) which influences only the density. Many foramina in the lamina dura are not visible radiographically. It is thicker than the surrounding trabecular bone and the thickness increases with increase in amount of occlusal stress. When interpreting intraoral X-ray images one should keep in mind that the “normal” image of the anatomical structures may show interindividual and even intraindividual variations.

*The alveolar crest.* The cervical demarcation of the alveolar process is the alveolar crest (fig. 19, *b*). The distance between cemento-enamel junction and alveolar crest on the radiograph should be 1–2 mm. It shows apical recession with the age or periodontal disease.

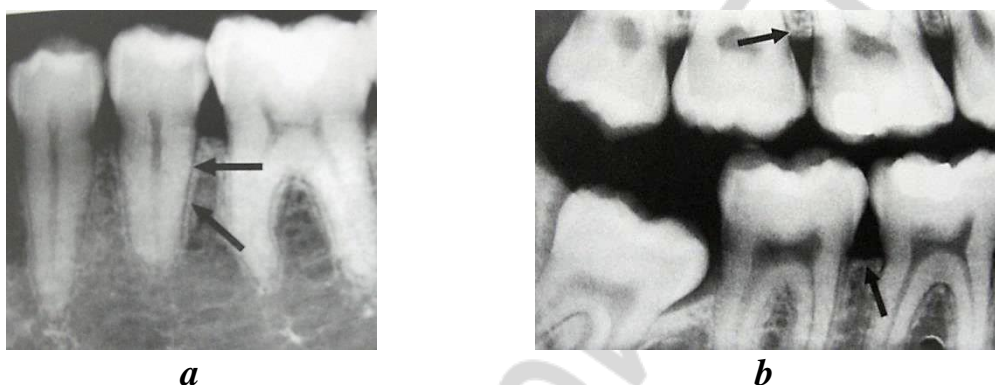


Fig. 19. Alveolar process:  
*a* — Lamina dura; *b* — Alveolar crest

### **Radiographic picture of destructive process in periodontium.**

Atrophy is the decrease of bone volume.

Destruction is breakdown of bone due to replacement by another pathologic tissue.

Deformation is the change of bone shape.

Osteoporosis is dystrophic process occurring without change of bone shape, but with thinning or decrease of bone trabeculae and the increase of spaces between them.

Osteosclerosis is compaction of bone with increase of bone trabeculae, their thickening, with a decrease spaces between them.

Periodontal ligament space widening. When traumatic forces of occlusion are placed on a tooth, the periodontal ligament widens due to the extra forces. Thus, early occlusal trauma can be viewed on radiographs as a widening of the periodontal ligament space.

Stages of the interdental septa destruction:

1. Osteoporosis of the interdental septae tip.
2. Destruction of lamina dura of interdental septae.
3. Reduction of the interdental septae height.

Generalized, extensive periodontal bone loss, where the crest of the residual bone is parallel to the cemento-enamel junction, it is referred to as *horizontal* bone loss (fig. 20, *a*).

With the periodontal disease, bone loss may be relatively severe around some teeth, while leaving the immediately adjacent teeth firmly anchored. Such focal loss creates osseous defects where height varies markedly compared to the adjacent tooth crowns. This defect is known as *vertical* bone loss and can be recognized on a radiographic image by noting that a line representing the residual bone crest sharply intersects another line between the tooth necks. Vertical loss is often occurs distal to the maxillary first molar and between the premolars (fig. 20, *b*).

Gingivitis **never** accompanies bone destruction. **Horizontal or vertical bone resorption means presence of periodontitis.**

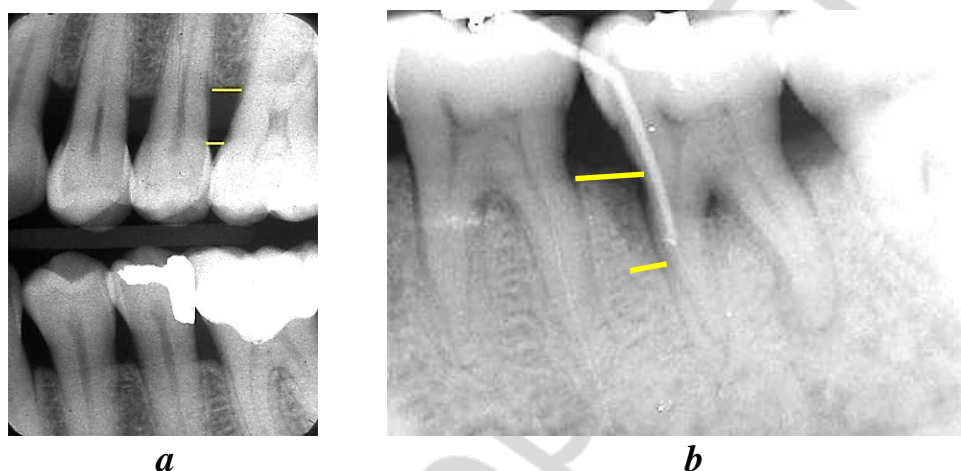


Fig. 20. Bone pockets:  
*a* — horizontal; *b* — vertical

## INDEX ASSESMENT OF PERIODONTAL TISSUES

**Gingival Index (GI)** (Loe, Silness, 1963) measures the degree of gingival inflammation.

Index teeth are 16, 21, 24, 36, 41, 44. Tissues surrounding each tooth divided into 4 gingival scoring units: distal facial papilla, facial margin, mesial facial papilla, lingual gingival margin.

Score	Sign
0	Normal gingiva
1	Mild inflammation — slight change in color, slight edema. No bleeding on probing
2	Moderate inflammation — redness, edema and glazing. Bleeding on probing
3	Severe inflammation — marked redness and edema. Ulceration. Tendency to spontaneous bleeding



The bleeding is assessed by probing gently (by blunt instrument — periodontal probe) along the wall of soft tissue of the gingival sulcus. GI scores from the 4 areas of the tooth are added and divided by four to give the GI for the tooth. Scores for individual teeth may be grouped to designate the GI for the group of teeth such as incisors, premolars and molars. The scores may be added and divided by the number of teeth examined to derive the GI for the individual. The GI may be used for the assessment of prevalence and severity of gingivitis in populations, groups and individuals.

The GI has gained wide acceptance as a simple, accurate and reproducible method for evaluating gingival health or disease in epidemiological and clinical research.

Results	Interpretation
0– 1,0	Mild inflammation
1,1– 2,0	Moderate inflammation
2,1– 3,0	Severe inflammation

**Community Periodontal Index of Treatment Needs (CPITN)** was introduced by WHO/FDI in 1982.

Index teeth are 17/16, 11, 26/27, 36/37, 31, 46/47 (fig. 21).

Every tooth should be examined in six points (fig. 22): mediovestibular, vestibular, distovestibular, distooral, oral, mediooral with special graduated probe (fig. 23, 24).

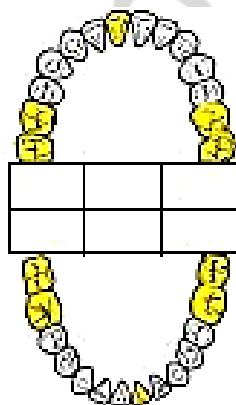


Fig. 21. Index teeth

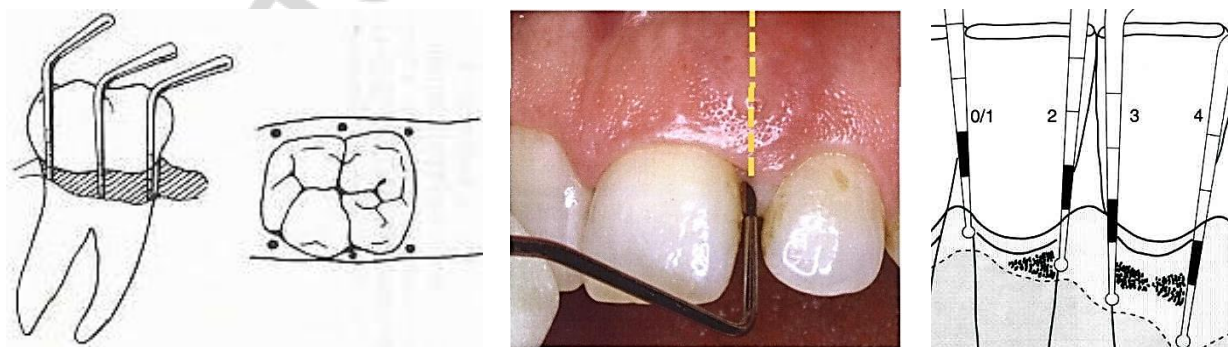
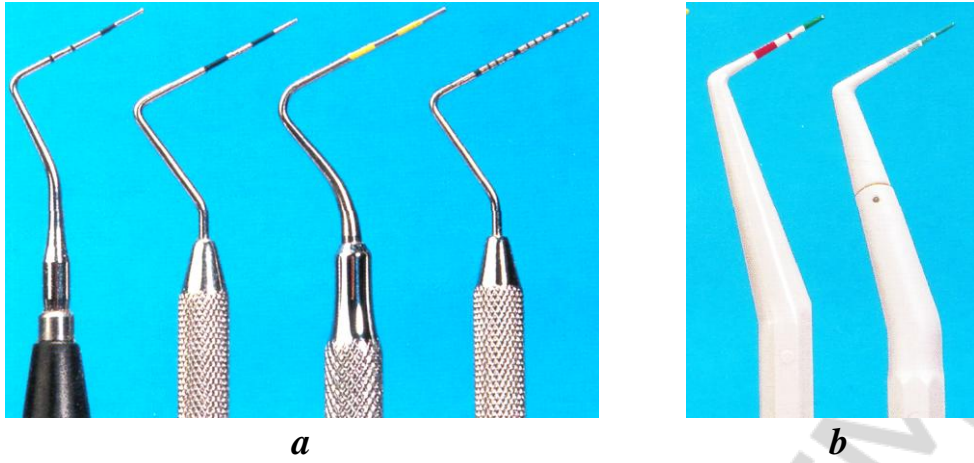
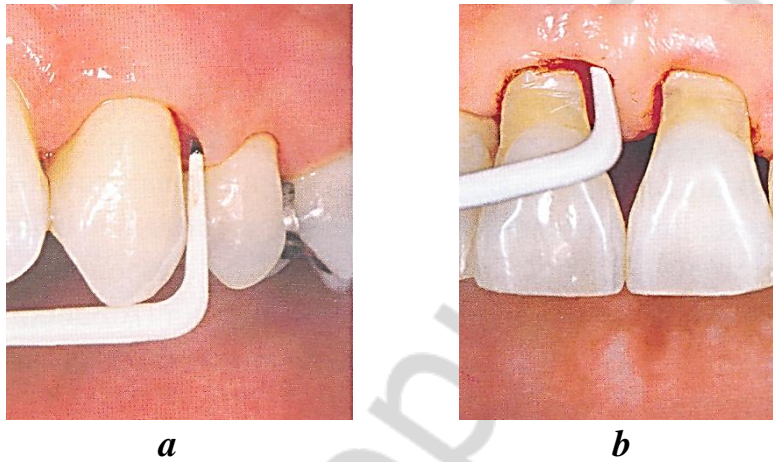

Fig. 22. Scheme of periodontal probing



**a**  
**b**  
 Fig. 23. Periodontal probes:  
 a — metallic; b — plastic



**a**  
**b**  
 Fig. 24. CPITN assessment:  
 a — code 3; b — code 4

Score	Sign
0	No periodontal disease
1	Bleeding on probing
2	Calculus with plaque seen or felt by probing
3	Pathological pocket 4–5 mm
4	Pathological pocket 6 mm or more
x	When only 1 tooth or no tooth are present

The score is identified by examination of specified index teeth or all teeth.

Score	TN criteria
0	No need for treatment
1	Personal plaque control (1–4)
2	Professional plaque control (scaling and polishing) (2–4)
3	Deep scaling , root planning, surgical procedure (3–4)

Clinical manifestations and microscopic changes of gingival inflammation are summarized in table 3.

Examination of the gingival clinical markers

	<b>Appearance in health</b>	<b>Changes in disease clinical appearance</b>	<b>Causes for changes</b>
Color	Uniformly pale pink or coral pink  Variations in pigmentation related to complexion, race	Acute: bright red	Inflammation Capillary dilation Increased blood flow
		Chronic: bluish pink, bluish red	Vessels engorged Blood flow sluggish Venous return impaired Anoxemia Increased fibrosis
		Attached gingiva: color change may extend to the mucogingival line	Deepening of pocket, mucogingival involvement
Size	Not enlarged	Enlarged	Edematous: inflammatory fluid, cellular exudate, vascular engorgement, hemorrhage Fibrotic: new collagen fibers
	Fits snugly around the tooth		
Shape (contour)	Marginal gingiva: knife-edged, flat, follows a curved line about the tooth Papillae: 1) normal contact: papilla is pointed and pyramidal: fills the interproximal area 2) space (diastema) between teeth; gingival is flat or saddle shaped	Marginal gingiva: rounded, rolled  Papillae: bulbous, flattened, blunted, cratered	Inflammatory changes: edematous or fibrous  Bulbous with gingival enlargement (see edematous or fibrotic, above)  Cratered in necrotizing ulcerative gingivitis
Consistency	Firm  Attached gingiva firmly bound down	Soft, spongy: dents readily when pressed with probe Associated with red color, smooth shiny surface, loss of stippling, bleeding on probing	Edematous: fluid between cells in connective tissue
		Firm, hard: resists probe pressure Associated with pink color, stippling, bleeding only in depth of pocket	Fibrotic: collagen fibers
Surface texture	Free gingiva: smooth Attached gingiva: stippled	Acute condition: smooth shiny gingiva Chronic: hard, firm, with stippling, sometimes heavier than normal	Inflammatory changes in the connective tissue: edema, cellular infiltration Fibrosis

	<b>Appearance in health</b>	<b>Changes in disease clinical appearance</b>	<b>Causes for changes</b>
Position of gingival margin	Fully erupted tooth: margin is 1–2 mm above cementoenamel junction, at or slightly below the enamel contour	Enlarged gingival: margin is higher on the tooth, above normal, pocket deepend Recession: margin is more apical; root surface is exposed	Edematous or fibrotic Junctional epithelium has migrated along the root, gingival margin follows
Position of junctional epithelium	During eruption along the enamel surface Fully erupted tooth: the junctional epithelium is at cementoenamel junction	Position determined by use of probe, is on the root surface	Apical migration of the epithelium along the root
Mucogingival junctions	Make clear demarcation between the pink, stippled, attached gingival and the darker alveolar mucosa with smooth shiny surface	No attached gingiva: 1) color changes may extend full height of the gingiva; mucogingival line obliterated 2) probing reveals that the bottom of the pocket extends into the alveolar mucosa 3) frenal pull may displace the gingival margin from the tooth	Apical migration of the junctional epithelium Attached gingiva decreases with pocket deepening Inflammation extends into alveolar mucosa
Bleeding	No spontaneous bleeding or upon probing	Spontaneous bleeding Bleeding on probing: bleeding near margin in acute condition; bleeding deep into pocket in chronic condition	Degeneration of the sulcular epithelium with the formation of pocket epithelium Blood vessels engorged Tissue edematous
Exudate	No exudates expressed on pressure	White fluid, pus, visible on digital pressure Amount not related to pocket depth	Inflammation in the connective tissue Excessive accumulation of white blood cells with serum and tissue makes up the exudate (pus)

## REFERENCES

1. Carranza's Clinical Periodontology / ads. : M.G. Newman. 12<sup>th</sup> ed. Saunders, 2015. 872 p.
2. [www.slideshare.net/dipika005/normal-radiographic-anatomy](http://www.slideshare.net/dipika005/normal-radiographic-anatomy)
3. <http://www.slideshare.net/milanchande/periodontal-indices-and-dental-imaging>
4. <http://www.slideshare.net/parthaprotimsingha/roll-no-29>
5. <http://www.slideshare.net/DrShilpaShiv/clinical-features-of-gingivitis-and-its-correlation-with-microscopic-findings>

## CONTENTS

Anatomy and histology of periodontium.....	3
Etiology and pathogenesis of gingival inflammation.....	6
Clinical manifestation of gingival inflammation.....	8
Destructive changes in periodontal tissues.....	15
Radiological assessment of periodontium.....	18
Index assessment of periodontal tissues.....	23
References.....	27

РЕПОЗИТОРИЙ БГМУ