A. ZHURA, A. BALSHOU

HERNIAS

Minsk BSMU 2017

Репозиторий БГМУ

МИНИСТЕРСТВО ЗДРАВООХРАНЕНИЯ РЕСПУБЛИКИ БЕЛАРУСЬ
БЕЛОРУССКИЙ ГОСУДАРСТВЕННЫЙ МЕДИЦИНСКИЙ УНИВЕРСИТЕТ
2-я КАФЕДРА ХИРУРГИЧЕСКИХ БОЛЕЗНЕЙ

А. В. Жура, А. В. Большов

ГРЫЖИ

HERNIAS

Учебно-методическое пособие

Минск БГМУ 2017

Репозиторий БГМУ

УДК 616.34-007.43(075.8)-054.6
ББК 54.57я73
Ж91

Рекомендовано Научно-методическим советом университета в качестве учебно-методического пособия 15.03.2017 г., протокол № 7

Рецензенты: д-р мед. наук, доц. В. Я. Хрыщанович; канд. мед. наук, доц. А. В. Пландовский

Жура, А. В.
Ж91 Грыжи = Hernias : учеб.-метод. пособие / А. В. Жура, А. В. Большов. – Минск : БГМУ, 2017. – 32 с.

ISBN 978-985-567-704-9.

Приведены основные типы грыж брюшной полости. Описаны основные диагностические методики, вопросы этиологии и патогенеза с приведением международных классификаций, осложнения и методы их коррекции, современные виды хирургических пособий.

Предназначено для студентов 4–6-го курсов медицинского факультета иностранных учащихся, обучающихся на английском языке.

УДК 616.34-007.43(075.8)-054.6
ББК 54.57я73

ISBN 978-985-567-704-9

© Жура А. В., Большов А. В., 2017
© УО «Белорусский государственный медицинский университет», 2017

Репозиторий БГМУ

MOTIVATIONAL CHARACTERISTIC OF THE TOPIC

Total in-class: 6 hours.

One of the most frequently performed operations by general surgeons worldwide is the repair of an abdominal wall hernia. In the past, most training programs relegated the repair of abdominal hernias to the junior members of the surgical team with little regard for results. However, in the modern era of heightened emphasis on account ability to our patients, this is changing rapidly. Interest by the academic community in the science behind hernia repair as well as an explosion in device development by industry has resulted in significant changes in many surgeons' practices.

The **purpose** is to study the etiology, pathogenesis, clinical manifestations, diagnosis, and treatment of abdominal hernias.

Objectives are:

1) to learn main etiological causes of hernias;
2) to learn classifications of hernias;
3) to learn common clinical features of hernias;
4) to make diagnosis of complicated hernia;
5) to be able to assess results of diagnostic studies and laboratory tests;
6) to be able to perform preoperative preparation;
7) to be able to make plan of treatment in complicated and non-complicated hernias;
8) to be able to prescribe the postoperative treatment.

Requirements for the initial knowledge level. To learn the topic completely the student must know:

– Propaedeutics of internal diseases (methods of clinical evaluation of abdominal organs);

– Human anatomy (localization and structure of abdominal wall);

– Topographic anatomy and operative surgery (main surgical procedures in abdominal hernias);

Test questions from related disciplines:

1. Normal and topographic anatomy of abdominal wall.
2. Clinical evaluation of abdominal cavity.
3. Methods of investigations of abdominal organs.
4. Main surgical procedures in abdominal hernias.

Test questions:

1. Embryology and pathogenesis.
2. Diagnosis.
3. Management principles.
4. Inguinal hernia.
5. Sportsman's hernia.
6. Femoral hernia.
7. Ventral hernia.
8. Rare external hernia.

Репозиторий БГМУ

BASIC ANATOMY AND FUNCTION RELATED TO PATHOLOGY

The abdominal wall is a complex structure composed primarily of muscle, bone and fascia. Its major function is to protect the enclosed organs of the gastrointestinal and urogenital tracts but a secondary role is mobility, being able to flex, extend, rotate and vary its capacity. Flexibility requires elasticity and stretch which compromise abdominal wall strength. The roof of the abdomen is formed by the diaphragm separating the thoracic cavity above with negative pressure from the abdomen below with positive pressure. Weakness of the diaphragm can lead to much of the bowel being drawn into the chest down this pressure gradient. The bony pelvis forms the floor of the cavity but a muscular central portion, the perineum, may also weaken and allow rectum, bladder and gynecological organs to bulge downwards, a condition called prolapse.

The overall design of the abdominal muscles is best seen on a transverse computed tomography (CT) scan through the mid-abdomen. Posteriorly the muscles are strong, further supported by the vertebral column, ribs and pelvis. Two regions called the posterior triangles represent areas of weakness which can lead to rare lumbar hernias. Laterally there are three thin muscle layers whose fibers crisscross for strength and flexibility. Surgeons can make use of these layers, by making releasing incisions, separating the layers and then sliding one layer on another to increase girth and allow closure of defects in the center of the abdomen, e. g. the «Ramirez slide» used in large incisional hernia repair (fig. 1).

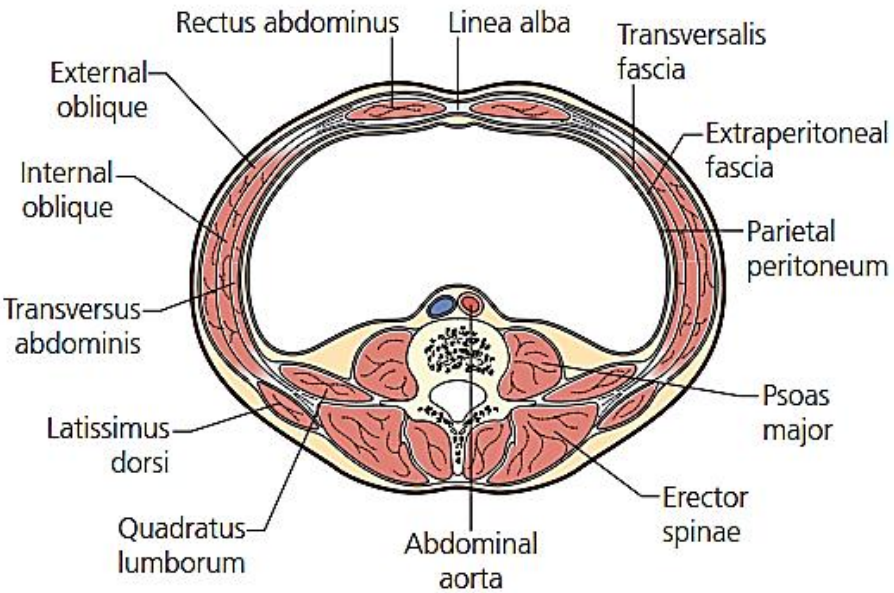

Fig. 1. A cross section of the midabdomen showing the muscular layout

Anteriorly the two powerful *rectus abdominus muscles* extend vertically from ribs to pelvis. Herniation through these strong muscles does not occur naturally but their central join, the *linea alba*, is an area of weakness resulting in epigastric and paraumbilical herniation. Divarication of the recti is the condition where the *linea alba* stretches laterally as the two rectus muscles separate. It oc-

curs in the upper abdomen in middle-aged, over-weight men (fig. 2) but also as a result of birth trauma in the female when it occurs below the umbilicus.

Fig. 2. Divarication of the *rectus muscles*

The positive pressure within the abdomen is used by a surgeon when drains are placed to allow blood, pus, bile, bowel content and urine to flow outwards down the pressure gradient. However, this constant pressure from within can also lead to the condition of abdominal hernia where tissue, meant to be within the abdominal cavity, is forced outwards through defects in the muscular wall.

ETIOLOGY AND PATHOGENESIS

Abdominal hernia - is the protrusion of an organ or part of an organ in its coverings through a congenital or acquired defect in the wall of the cavity containing it, into an abnormal position

Anatomical causes of abdominal wall herniation (*predisposing factors of hernia formation*). Despite the complex design of the abdominal wall, the only natural weaknesses caused by inadequate muscular strength are the lumbar triangles and the posterior wall of the inguinal canal (fig. 3).

Fig. 3. Posterior wall defect

Many structures pass into and out of the abdominal cavity creating weakness which can lead to hernia formation. The most common example is the inguinal canal in the male along which the testis descends from abdomen to scrotum at the time of birth. The testicular artery, veins and vas pass though this canal (the

Репозиторий БГМУ

round ligament in the female). The resultant weakness leads to an indirect or lateral-type inguinal hernia. Other examples are: esophagus → hiatus hernia, femoral vessels → femoral hernia, obturator nerve → obturator hernia, sciatic nerve → sciatic hernia.

Failure of normal development may lead to weakness of the abdominal wall. Examples are diaphragmatic, umbilical and epigastric hernias. Muscles which should unite during development fail to form strong unions with hernia development at birth or in later life. Herniation at the umbilicus has both components, i.e. weakness due to structures passing through the abdominal wall in fetal life and developmental failure of closure. The risk of inguinal hernia is related to the anatomical shape of the pelvis and is higher in patients having a wider and shorter pelvis.

Weakness of abdominal muscles may be the result of sharp trauma. Most commonly, this results from abdominal surgery but also occurs after stabbing. A surgical scar, even with perfect wound healing, has only 70 % of the initial muscle strength. This loss of strength can result in herniation in at least 10 % of surgical incisions. Smaller laparoscopic port-site incisions have a hernia rate of 1 %. Increasing use of this surgical approach should lead to a fall in the incidence of incisional hernia. Muscle damage by blunt trauma or tearing of the abdominal muscles requires exceptional force and is rare.

The sudden presence of a mass in the rectus muscle may be a rectus sheath haematoma, occasionally due to trauma but nowadays more often due to excessive anticoagulation therapy. Primary muscle pathology and neurological conditions can lead to muscle weakness and occasionally present to the surgeon as a «hernia».

Summary causes of hernia are:

- basic design weakness;
- weakness due to structures entering and leaving the abdomen;
- developmental failures;
- genetic weakness of collagen;
- sharp and blunt trauma;
- weakness due to ageing and pregnancy;
- primary neurological and muscle diseases;
- excessive intra-abdominal pressure.

Pathophysiology of hernia formation. A normal abdominal wall has sufficient strength to resist high abdominal pressure and prevent herniation of content. Herniation has been attributed to high pressures from *constipation, prostatic symptoms, excessive coughing in respiratory disease and obesity* (***causing factors of hernia formation***). However, it has been shown that hernia is no more common in Olympic weight lifters than the general population, suggesting that *high pressure is not a major factor in causing a hernia*. Many patients will first notice a hernia after excessive straining.

There is good evidence that hernia is a «collagen disease» and due to an inherited imbalance in the types of collagen. This is supported by histological evi-

dence and relationships between hernia and other diseases related to collagen, such as aortic aneurysm.

Hernia development is more common in *pregnancy* due to hormonally induced laxity of pelvic ligaments. It is also more common in the *elderly* due to degenerative weakness of muscles and fibrous tissue. Hernia is more common in smokers.

Common principles in abdominal hernia. An abdominal wall hernia has two essential components, a *defect in the wall* and *content*, that is tissue which has been forced outwards through the defect. The weakness may be entirely in *muscle*, such as an incisional hernia. It may also be in *fascia*, like an epigastric hernia through the linea alba. It may have a bony component, such as a femoral hernia. The weakness in the wall is usually the narrowest part of the hernia which expands into the subcutaneous fat outside of the muscle. The defect varies in size and may be very small or indeed very large. The nature of the defect is important to understanding the risk of hernia complications. A small defect with rigid walls traps the content and prevents it from freely moving in and out of the defect, increasing the risk of complications.

The content of the hernia may be tissue from the extraperitoneal space alone, such as fat within an epigastric hernia or urinary bladder in a direct inguinal hernia. However, if such a hernia enlarges then peritoneum may also be pulled into the hernia secondarily along with intraperitoneal structures such as bowel or omentum; a good example is a «*sliding type*» of inguinal hernia.

More commonly, when peritoneum is lying immediately deep to the abdominal wall weakness, pressure forces the peritoneum through the defect and into the subcutaneous tissues. This ***«sac»*** of peritoneum allows bowel and omentum to pass through the defect. In most cases, the intraperitoneal organs can move freely in and out of the hernia, a ***«reducible» hernia***, but if adhesions form or the defect is small, bowel can become trapped and unable to return to the main peritoneal cavity, an ***«irreducible» hernia***, with high risk of further complications.

The hernia sac consists of: a mouth, a neck, a body and a fundus (fig. 4).

Fig. 4. Parts of a hernia

Репозиторий БГМУ

The narrowest part of the sac, at the abdominal wall defect, is called the *«neck of the sac»*. When tissue is trapped inside a hernia it is in a confined space. The narrow neck acts as a constriction ring impeding venous return and increasing pressure within the hernia. Resulting tension leads to pain and tenderness. If the hernia contains bowel then it may become ***«obstructed»***, partially or totally. If the pressure rises sufficiently, arterial blood is not able to enter the hernia and the contents become ischemic and may infarct. The hernia is then said to have ***«strangulated»***. The wall of the bowel perforates, releasing infected, toxic bowel content into the tissues and ultimately back into the peritoneal cavity. The risk of strangulation is highest in hernias which have a small neck of rigid tissue leading first to irreducibility and on to strangulation. The term «incarcerated» is not clearly defined and used to imply a hernia which is irreducible and developing towards strangulation.

Types of hernia by complexity:

1. Occult — not detectable clinically; may cause severe pain.
2. Reducible — a swelling which appears and disappears.
3. Irreducible — a swelling which cannot be replaced in the abdomen, high risk of complications.
4. Obstructed — disturbances in bowel contest passing through the hernia.
5. Strangulated — painful swelling with vascular compromise, requires urgent surgery.
6. Infarcted — when contents of the hernia have become gangrenous, high mortality.

In a special circumstance (***Richter's hernia***) only part of the bowel wall enters the hernia. It may be small and difficult or even impossible to detect clinically. Bowel obstruction may not be present but the bowel wall may still become necrotic and perforate with life-threatening consequences. Femoral hernia may present in this way often with diagnostic delay and high risk to the patient (fig. 5).

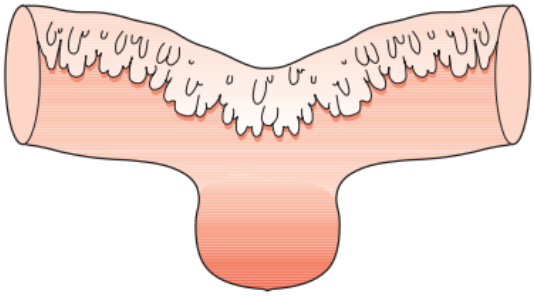

Fig. 5. Richter's hernia

An ***interstitial hernia*** occurs when the hernia extends between the layers of muscle and not directly through them. This is typical of a Spigelian hernia. An ***internal hernia*** is a termed used when adhesions form within the peritoneal cavity leading to abnormal pockets into which bowel can enter and become trapped.

DIAGNOSIS

EXAMINATION

The patient should be examined lying down initially and then standing as this will usually increase hernia size. In some cases no hernia will be apparent with the patient lying. The patient is asked to cough, when an occult hernia may appear. Divarication is best seen by asking a supine patient to simply lift his head off the pillow.

The overlying skin is usually of normal color. If bruising is present this may suggest venous engorgement of the content. If there is overlying cellulitis then hernia content is strangulating and the case should be treated as an emergency.

In most cases a ***cough impulse*** is felt. Gentle pressure is applied to the lump and the patient is asked to cough. If an impulse is felt this is due to increased abdominal pressure being transmitted into the hernia. In cases where the neck is tight and the hernia irreducible there may be no cough impulse. This can lead to failure of diagnosis and is typical of femoral hernia where lack of an impulse leads the clinician to misdiagnose a lymph node. Cough impulse can also occur in a saphenous varices which may be referred to a surgeon as a suspected inguinal hernia.

Essential checks are:

- reducibility;
- cough impulse;
- tenderness;
- overlying skin color changes;
- multiple defects/contralateral side;
- signs of previous repair;
- scrotal content for groin hernia;
- associated pathology.

INVESTIGATIONS

For most hernias, no specific investigation is required, the diagnosis being made on clinical examination. However, the patient may have symptoms suggesting a hernia but no hernia is found or have a swelling suggestive of hernia but with clinical uncertainty. It is important to be certain that any symptoms described are due to a hernia and not to coexisting pathology. There may also be a requirement for more detailed information than can be found by examination alone. *Plain x-ray* of the abdomen is of little value although a hiatus hernia and diaphragmatic hernia may be seen on chest x-ray.

Ultrasound scan may be helpful in cases of irreducible hernia, where the differential diagnosis includes a mass or fluid collection, or when the nature of the hernia content is in doubt. Ultrasound is very useful in the early postoperative period when a hematoma or seroma may develop and be difficult to distinguish from an early recurrence. Ultrasound is non-invasive and low cost but operator dependent.

Репозиторий БГМУ

Computed tomography scanning is helpful in complex incisional hernia, determining the number and size of muscle defects, identifying the content, giving some indication of presence of adhesions and excluding other intra-abdominal pathology such as ascites, occult malignancy, portal hypertension, etc. *Magnetic resonance imaging (MRI)* can help in the diagnosis of sportsman's groin where pain is the presenting feature and the surgeon needs to distinguish an occult hernia from an orthopedic injury.

Laparoscopy itself may be used. In incisional hernia, initial laparoscopy may determine that a laparoscopic approach is feasible or not depending on the extent of adhesions. In inguinal hernia repair by the transabdominal route, initial laparoscopy can determine the presence of an occult contralateral hernia which has been described in up to 20 per cent of patients.

MANAGEMENT PRINCIPLES

An abdominal wall hernia does not necessarily require repair. A patient may request surgery for relief of symptoms of discomfort, cosmetics or to establish the diagnosis when in doubt. The surgeon should recommend repair when complications are likely, the most worrying being strangulation with bowel obstruction and bowel infarction.

All cases of femoral hernia, with high risk of strangulation, should be repaired surgically. Any case of irreducible hernia, especially where there is pain and tenderness, should be offered repair unless coexisting medical factors place the patient at very high risk from surgery or anesthesia. Increasing difficulty in reduction and increasing size are indications for surgery. Surgery should be offered to younger adult patients as symptoms and complications are likely over time

Principles of management:

1. Not all hernias require surgical repair.
2. Small hernias can be more dangerous than large.
3. Pain, tenderness and skin color changes imply high risk of strangulation.
4. Irreducible hernia should be offered repair.
5. Femoral hernia should always be repaired.
6. Surgery should be offered to younger adults.

In reality, most patients with a hernia should be offered repair. In the elderly, if the hernia is asymptomatic, small in size, can be reduced easily and is not causing anxiety then observation alone should be sufficient. This policy is called «*watchful waiting*». A truss can be used to control a hernia.

Small paraumbilical hernias are often seen. They cause few symptoms and usually contain fat or omentum with a very low risk of complications.

Large incisional hernias, particularly recurrent, present a major problem. Surgical repair is a complex procedure with significant risk of complications and later recurrence. When the neck is wide, the risk of strangulation is low. In the

Репозиторий БГМУ

obese and elderly patient, these risks may outweigh the benefits of surgery and it is common for surgeons to adopt a conservative approach.

Any patient who presents with acute pain in a hernia, particularly if irreducible, should be offered surgery. Often, in a patient with an irreducible hernia, after admission to hospital and adequate analgesia, the hernia will reduce due to muscle relaxation. The likelihood of similar episodes is very high and surgery should be recommended at this admission or soon after.

Operative approaches to hernia.

All surgical repairs follow the same basic principles:

− reduction of the hernia content into the abdominal cavity with removal of any non-viable tissue and bowel repair if necessary;

− excision and closure of a peritoneal sac if present or replacing it deep to the muscles;

− reapproximation of the walls of the neck of the hernia if possible;

− permanent reinforcement of the abdominal wall defect with sutures or mesh.

Reduction of hernia content is essential for a successful repair. It is rare that a surgeon fails to reduce the hernia but extensive dissection can lead to bowel injury sometimes requiring bowel resection with subsequent risks of infection and bowel anastomotic complications.

Excision and closure of the peritoneal sac is ideal but not essential. During laparoscopic repair of incisional hernia, surgeons will often leave the sac in situ after reducing hernia contents and simply fix a mesh over the neck to prevent recurrence. There is risk of fluid formation within the sac (seroma). This is a common complication in all forms of hernia repair.

Closure of the abdominal wall defect is ideal but may not be possible when the defect is large or when tissues are rigid. Plastic surgical techniques have been developed to ‘borrow’ tissue from elsewhere in order to cover large muscle defects but usually at the cost of leaving a weak area elsewhere. Over the past 20 to 30 years, surgeons have realized that simple closure of a hernia defect by sutures alone leads to a high recurrence rate. Additional reinforcement of the defect with a *non-absorbable mesh* (fig. 6) is now widely practiced in most hernia repairs and evidence has shown that recurrence rates have improved but recurrence still remains a problem. Mesh repair has become so important in hernia surgery that some understanding of mesh technology is essential for the modern surgeon.



Fig. 6. Surgical meshes

Репозиторий БГМУ

Mesh in hernia repair. The term «mesh» refers to prosthetic material, either a net or a flat sheet which is used to strengthen a hernia repair. Mesh can be used:

- to bridge a defect: the mesh is simply fixed over the defect as a tension-free patch;
- to plug a defect: a plug of mesh is pushed into the defect;
- to augment a repair: the defect is closed with sutures and the mesh added for reinforcement.

A well-placed mesh should have good overlap around all margins of the defect, at least 2 cm but up to 5 cm if possible. Suturing a mesh edge-to-edge into the defect (*inlay*), with no overlap, is not recommended. Mesh plug repairs have gained some popularity in small defects especially where overlap is hard to achieve. Plug operations are fast but plugs can form a dense «meshoma» of plug and collagen. Other complications include migration, erosion into adjacent organs, fistula formation and chronic pain.

Net meshes allow fibrous tissue in growth between the strands and becoming adherent and integrated into host tissues within a few months. Initial fixation of the mesh is by glue, sutures or staples which may be absorbable. In laparoscopic inguinal hernia, no fixation is required at all as friction is sufficient to hold the mesh.

The majority of meshes used today are ***synthetic*** polymers of polypropylene, polyester or polytetrafluoroethylene (PTFE). They are non-absorbable and provoke little tissue reaction.

There are «***biological meshes»*** which are sheets of sterilized, decellularized, non-immunogenic connective tissue. They derive from human or animal dermis, bovine pericardium or porcine intestinal submucosa. They are expensive.

There are also synthetic ***absorbable meshes***, such as those made from polyglycolic acid fibers. They are used in temporary abdominal wall closure and to buttress sutured repairs. They have no current role in hernia repair as they absorb and induce minimal collagen deposition.

Most meshes induce fibrosis and, if placed within the peritoneal cavity, promote unwanted adhesions. New meshes have been designed for intraperitoneal use (t***issue-separating meshes***). Most of these have very different surfaces, one being sticky and one being slippery. Good adherence and host–tissue in-growth is required on the parietal (muscle) side of the mesh but the opposite (bowel) side needs to prevent adhesions to bowel.

Positioning the mesh

The strength of a mesh repair depends on host–tissue in-growth. Meshes should be placed on a firm, well-vascularized tissue bed with generous overlap of the defect. The mesh can be placed (fig. 7):

- just outside of the muscle in the subcutaneous space (onlay);
- within the defect (inlay) – only applies to mesh plugs in small defects;
- between fascial layers in the abdominal wall (intraparietal or sublay);
- immediately extraperitoneally, against muscle or fascia (also sublay);
- intraperitoneally.

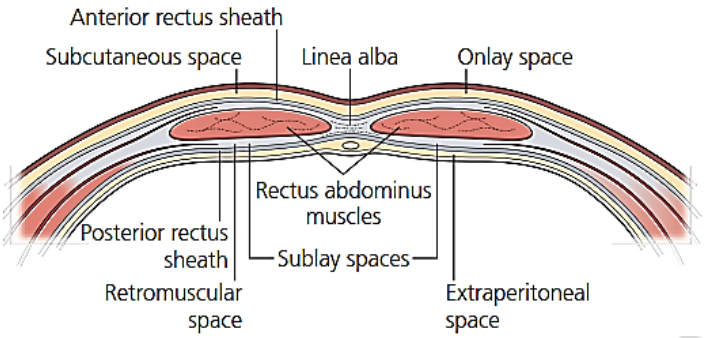

Fig. 6. Diagrammatic representation of the various layers into which meshes are placed in ventral hernia repair

At open surgery all of these planes are used but laparoscopic surgeons currently only use intraperitoneal or extraperitoneal planes.

Limitations to the use of mesh

The presence of infection limits the use of mesh, particularly heavyweight types. If a mesh becomes infected then it often needs to be removed. Some infected meshes can be salvaged using a combination of debridement of non-incorporated mesh, appropriate antibiotics and modern vacuum-assisted dressings. In addition, meshes are expensive, especially those for intraperitoneal use, but prices are falling.

SPECIFIC HERNIA TYPES

Common hernia sites are shown in fig. 8.

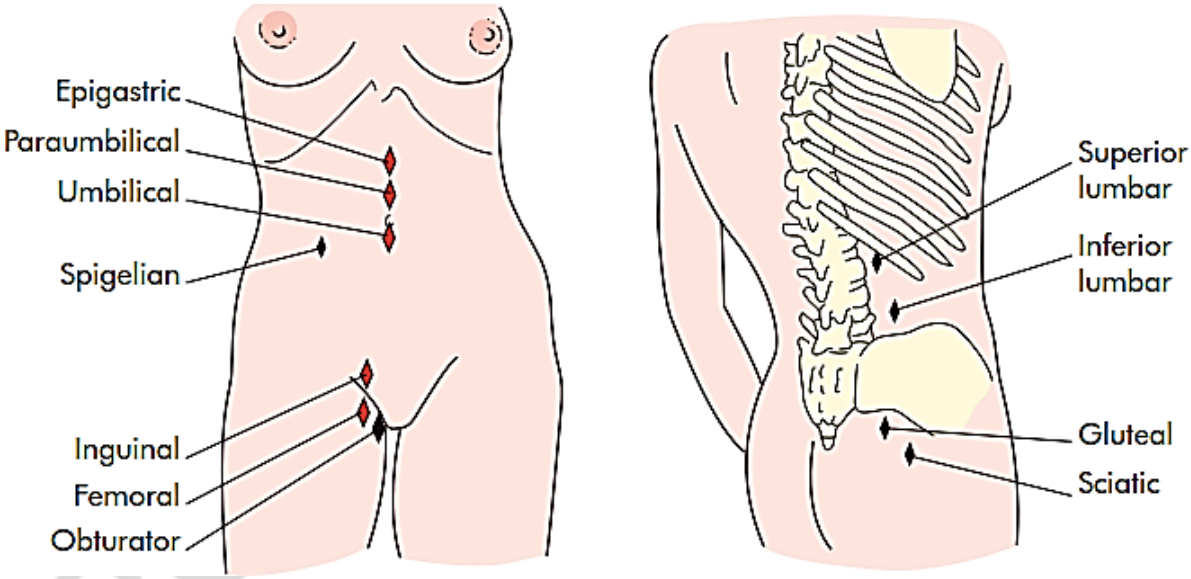

Fig. 7. Diagram to show the sites of abdominal wall hernias, common in red and rare in black. Incisional and parastomal hernias can be found at various sites

INGUINAL HERNIA

The inguinal hernia is the most common hernia in men and women but much more common in men. There are two basic types (oblique and direct) which are fundamentally different in anatomy, causation and complications. However, they are anatomically very close to one another, surgical repair techniques are very similar and ultimate reinforcement of the weakened anatomy is identical so they are often referred to together as inguinal hernia.

Inguinal hernia summary:

- types – lateral (oblique, indirect); medial (direct), sliding;
- origin – congenital or acquired;
- anatomy – inguinal canal;
- diagnosis – usually clinical but radiological in special circumstances;
- surgery – open and laparoscopic.

The congenital inguinal hernia is known as *indirect, oblique or lateral* while the acquired hernia is called *direct or medial*. There is a third *«sliding» hernia* which is acquired but is lateral in position.

Basic anatomy of the inguinal canal. As the testis descends from the abdominal cavity to the scrotum in the male it firsts passes through a defect called the deep inguinal ring in the transversalis fascia, just deep to the abdominal muscles. This ring lies midway between the anterior superior iliac spine and the pubic tubercle, approximately 2–3 cm above the femoral artery pulse in the groin. The inferior epigastric vessels lie just medial to the deep inguinal ring passing from the iliac vessels to the rectus abdominus muscle. Muscle fibres of the innermost two layers of the lateral abdominal wall, the transversus muscle and the internal oblique muscle, arch over the deep inguinal ring from lateral to medial before descending to become attached to the pubic tubercle. These two muscles fuse and become tendinous, hence this arch is referred to as the conjoint tendon. Below this arch there is no muscle but only transversalis fascia and external oblique aponeurosis resulting in weakness (fig. 9Fig. 8).

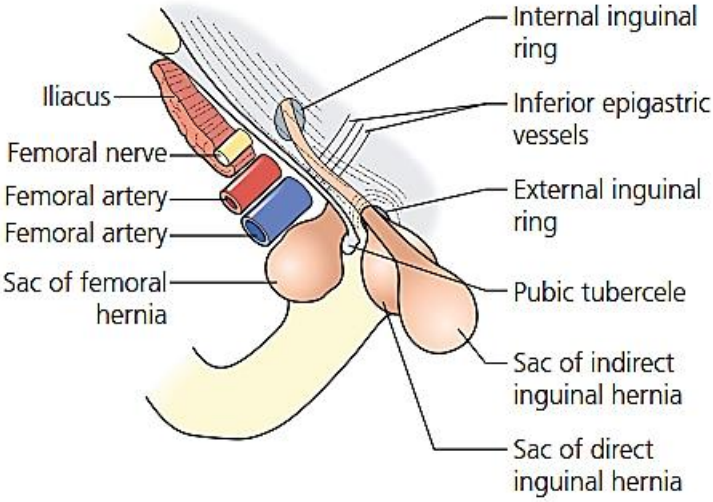

Fig. 8. The close relationships of direct inguinal, indirect inguinal and femoral hernias

The inguinal canal is roofed by the conjoint tendon, its posterior wall is transversalis fascia, an anterior wall is the external oblique aponeurosis and a floor which is also external oblique which rolls inwards at its lower margin and thickens to become the inguinal ligament (Poupart's). The inguinal canal in the male contains the testicular artery, veins, lymphatics and the vas deferens. In the female, the round ligament descends through the canal to end in the vulva. Three important nerves, *the ilioinguinal, the iliohypogastric* and *the genital branch of the genitofemoral nerve* also pass through the canal.

As the testis descends, a tube of peritoneum is pulled with the testis and wraps around it ultimately to form the tunica vaginalis. This peritoneal tube should obliterate, possibly under hormonal control, but it commonly fails to fuse either in part or totally. As a result, bowel within the peritoneal cavity is able to pass inside the tube down towards the scrotum. Inguinal hernia in neonates and young children is always of this congenital type. However, in other patients, the muscles around the deep inguinal ring are able to prevent a hernia from developing until later in life, when under the constant positive abdominal pressure, the deep inguinal ring and muscles are stretched and a hernia becomes apparent. As the hernia increases in size, the contents are directed down into the scrotum. These hernias can become massive and may be referred to as a scrotal hernia.

An indirect hernia is lateral to the inferior epigastric vessels. It is also oblique as the hernia passes obliquely from lateral to medial through the abdominal muscle layers.

The second type of inguinal hernia, referred to as ***direct or medial***, is acquired. It is a result of stretching and weakening of the abdominal wall just medial to the inferior epigastric (IE) vessels. Looked at from within the abdominal cavity, there is a triangle referred to as Hasselbach's triangle, whose three sides are the IE vessels laterally, the lateral edge of the rectus abdominus muscle medially and the pubic bone below (the iliopubic tract). This area is weak as the abdominal wall here only consists of transversalis fascia covered by the external oblique aponeurosis. A direct, medial hernia is more likely in elderly patients. It is broadly based and therefore unlikely to strangulate.

The third type of inguinal hernia is referred to as a ***sliding hernia***. This is also an acquired hernia due to weakening of the abdominal wall but this occurs at the deep inguinal ring lateral to the IE vessels. Retroperitoneal fatty tissue is pushed downwards along the inguinal canal. As more tissue enters the hernia, peritoneum is pulled with it, thus creating a sac. However the sac has formed secondarily, distinguishing it from a classic indirect hernia. On the left side, sigmoid colon may be pulled into a sliding hernia and on the right side the cecum. Surgeons need extra caution during repair as the wall of the large bowel may not be covered by peritoneum and can be damaged.Occasionally, both lateral and medial hernias are present in the same patient (*pantaloon hernia*).

Classification. Many surgeons over the past hundred years have attempted to classify inguinal (and femoral) hernias, including Casten, Halverson and McVay, Zollinger, Ponka, Gilbert and Nyhus.

The **European Hernia Society Classification** has recently suggested a simplified system of:

- primary or recurrent (P or R);
- lateral, medial or femoral (L, M or F);
- defect size in finger breadths assumed to be 1.5 cm.

A primary, indirect, inguinal hernia with a 3 cm defect size would be PL2.

Diagnosis of an inguinal hernia. In most cases, the diagnosis of an inguinal hernia is simple and patients often know their diagnosis as they are so common. Usually these hernias are reducible presenting as intermittent swellings, lying above and lateral to the pubic tubercle with an associated cough impulse. Often the hernia will reduce on lying and reappear on standing.

Confirmation of the diagnosis may not be possible when the patient describes an intermittent swelling but nothing is found on examination. Surgeons will often accept the diagnosis on history alone but re-examination at a later date or investigation by *ultrasound scan* may be requested.

If an inguinal hernia becomes irreducible and tense there may be no cough impulse. Differential diagnosis would include a *lymph node groin mass or an abdominal mass*. Such cases require urgent investigation by either ultrasound or CT scan.

Large scrotal hernias may be misdiagnosed as a *hydrocoele* or other *testicular swelling*. The surgeon should be able to identify the upper limit of a scrotal swelling but a large scrotal hernia has no upper limit as it extends back along the inguinal canal to the peritoneal cavity. In cases of doubt, ultrasound scanning should establish the diagnosis.

As inguinal hernia is so common, less-experienced clinicians might suggest this diagnosis when referring cases of femoral hernia or spigelian hernia. Also patients with a *saphena varix* may present with a swelling which increases in size on standing and with a definite cough impulse and be misdiagnosed as a hernia. The same can be true for a *varicocoele*.

It is essential to examine the scrotal contents to exclude other pathologies and to check that the patient has two testes. It is important to examine the opposite side as contralateral hernia is common.

Management of inguinal hernia. It is safe to recommend no active treatment in cases of early, asymptomatic, direct hernia, particularly in elderly patients who do not wish surgical intervention. These patients should be warned to seek early advice if the hernia increases in size or becomes symptomatic. Surgical trusses are not recommended but may be required for occasional patients who refuse any form of surgical intervention.

Elective surgery for inguinal hernia is a common and simple operation. It can be undertaken under local, regional or general anesthesia with minimal risk even in high-risk patients.

*Herniotomy***.** *In children who have lateral hernias with a persistent processus, it is sufficient only to remove and close the sac*. This is called a herniotomy. In

Репозиторий БГМУ

adult surgery, herniotomy alone has a high recurrence rate and some form of muscle strengthening is added (herniorrhaphy).

Open suture repair. In 1890, Eduardo *Bassini* described suture repair for inguinal hernia (fig. 10). This was a massive leap forward and has been the basis of open repair for over 100 years. The surgeon enters the inguinal canal by opening its anterior wall, the external oblique aponeurosis. The spermatic cord is dissected free and the presence of a lateral or a medial hernia is confirmed. The sac of a lateral hernia is separated from the cord, opened and any contents reduced. The sac is then sutured closed at its neck and excess sac removed. If there is a medial hernia then it is inverted and the transversalis fascia is suture plicated. Sutures are now placed between the conjoint tendon above and the inguinal ligament below, extending from the pubic tubercle to the deep inguinal ring. The posterior wall of the inguinal canal is thus strengthened.

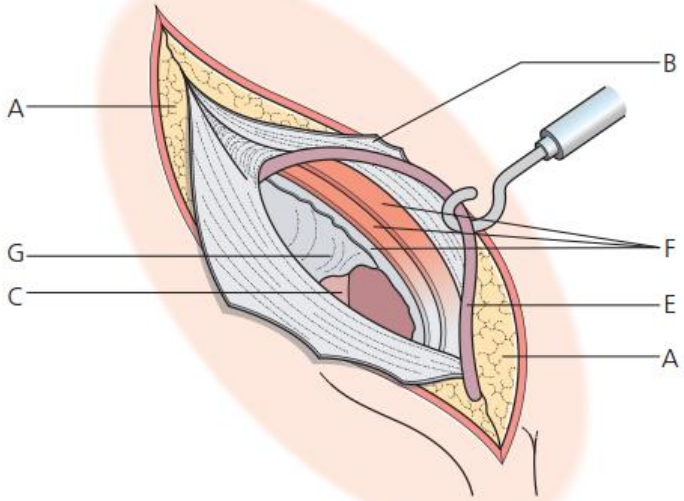

Fig. 9. Bassini's original diagram:
A — subcutaneous fat; *B* — external oblique; *C* — iliac vein; *E* — spermatic cord;
F — nerves in inguinal canal; *G* — transversalis fascia

Over 150 modifications to the Bassini operation have been described with little or no benefit except for the *Shouldice modification*. In this operation, the transversalis fascia is opened by a central incision from the deep inguinal ring to the pubic tubercle and then closed to create a double-thick, two-layered posterior wall (double breasting). The external oblique is closed in similar fashion.

Today, when a Bassini-type operation is done, most surgeons use a continuous, non-absorbable nylon or polypropylene suture which is darned between the conjoint tendon and inguinal ligament. It is the most common operation performed in countries where mesh is too expensive.

Suture repair is still under development, and recently, Desarda has described an operation where a 1–2 cm strip of external oblique aponeurosis lying over the inguinal canal is isolated from the main muscle but left attached both medially and laterally. It is then sutured to the conjoint tendon and inguinal ligament,

reinforcing the posterior wall of the inguinal canal. As the abdominal muscles contract, this strip of aponeurosis tightens to add further physiological support to the posterior wall. This operation is currently being evaluated.

Open mesh repair. Synthetic mesh has been used since the 1950s to reinforce hernia repair, and in the 1980s Lichtenstein described a tensionfree, simple, flat, polypropylene mesh repair for inguinal hernia (fig. 11). Once the hernia sac has been removed and any medial defect closed, a piece of mesh, measuring 8 × × 15 cm, is placed over the posterior wall, behind the spermatic cord. Today, the Lichtenstein repair is the most common operation for inguinal hernia in the developed world.

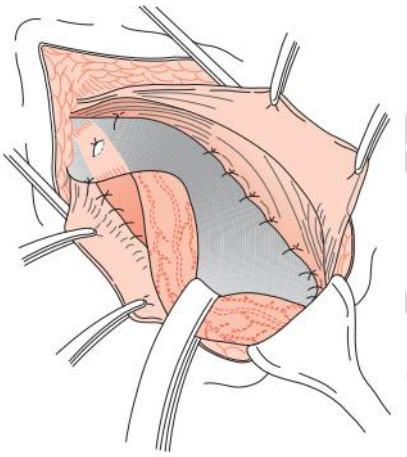

Fig. 10. Lichtenstein repair

Open preperitoneal repair. This approach was first described by Annandale in 1880, but was largely discarded until the 1950s when Stoppa, a French surgeon, described it with mesh reconstruction. It is useful when multiple attempts at open standard surgery have failed and the hernia(s) keeps recurring. It may now be superseded by the totally extraperitoneal laparoscopic approach which is modelled on the Stoppa operation and first described by Ger, also French.

Laparoscopic inguinal hernia repair. Two techniques are described. The totally extraperitoneal (TEP) approach is more widely used than the transabdominal preperitoneal (TAPP) approach. In both, the aim of surgery is to reduce the hernia and hernia sac within the abdomen and then place a 10 × 15 cm mesh just deep to the abdominal wall, extending across the midline into the retropubic space and 5 cm lateral to the deep inguinal ring. The mesh covers Hasselbach's triangle, the deep inguinal ring and the femoral canal. In TEP, the surgeon is able to create a space just deep to the abdominal muscles without entering the peritoneal cavity whereas, in TAPP, the surgeon enters the peritoneal cavity then incises the peritoneum above the hernia defects and reflects it away from the muscles, essentially entering the same space as in TEP. Once the hernia is reduced, an identical mesh is inserted and the peritoneum closed over the mesh. Although the laparoscopic operation takes longer to perform, proven advantages are reduced pain both following surgery and up to five years later, more rapid return to full activity and reduced incidence of the wound complications of infection, bleeding and

Репозиторий БГМУ

seroma. Laparoscopic surgery is of particular benefit in bilateral cases and in patients with hernia recurrence after open surgery.

Summary, operations for inguinal hernia:

1. Herniotomy.
2. Open suture repair:
- Bassini;
- Shouldice;
- Desarda;
- McVay.
3. Open mesh repair:
- Lichtenstein;
- Plugs;
- Hernia systems.
4. Open preperitoneal repair:
- Stoppa.
5. Laparoscopic repair:
- TEP;
- TAPP.

SPORTSMAN'S HERNIA

This specific entity is well described and presents as severe pain in the groin area, extending into the scrotum and upper thigh. It is almost entirely restricted to young men who play contact sports such as football and rugby. The pain can be debilitating and prevent the patient from exercising. On examination there may be some tenderness in the region of the inguinal canal, over the pubic tubercle and over the insertion of the thigh adductor muscles. Usually no hernia can be felt and only occasionally can a true inguinal hernia be found.

In most cases, the pain is due to an orthopedic injury, such as adductor strain or pubic symphasis diastasis. However, some believe that it can be due to muscle tearing (Gilmore's groin) or stretching of the posterior wall of the inguinal canal. Other causes of pain should be excluded, such as hip, pelvic or lumbar spinal disease and bladder/prostate problems. MRI scanning is most likely to detect an orthopedic problem but ultrasound, herniography or even laparoscopy may be used.

There are many anecdotal reports of successful treatment using all types of inguinal hernia surgery, suture and mesh, open and laparoscopic, but no randomized trials. Hernia surgery should be a last resort and the patient warned of a significant risk of failure to cure the pain.

FEMORAL HERNIA

The iliac artery and vein pass below the inguinal ligament to become the femoral vessels in the leg. The vein lies medially and the artery just lateral to the artery with the femoral nerve lateral to the artery. They are enclosed in a fibrous sheath. Just medial to the vein is a small space containing fat and some lymphatic

Репозиторий БГМУ

tissue (node of Cloquet). It is this space which is exploited by a femoral hernia. *The walls of a femoral hernia are* the femoral vein laterally, the inguinal ligament anteriorly, the pelvic bone covered by the ileopectineal ligament (Cooper's) posteriorly and the lacunar ligament (Gimbernat's) medially. This is a strong curved ligament with a sharp unyielding edge which impedes reduction of a femoral hernia.

The female pelvis has a different shape to the male, increasing the size of the femoral canal and the risk of hernia. In old age, the femoral defect increases and ***femoral hernia is commonly seen in low-weight, elderly females***. There is a substantial risk of developing a femoral hernia after a sutured inguinal hernia repair.

Summary femoral hernia:

1. Less common than inguinal hernia.
2. It is more common in females than in males.
3. Easily missed on examination.
4. Fifty per cent of cases present as an emergency with very high risk of strangulation.

Diagnostic error is common and often leads to delay in diagnosis and treatment. The hernia appears below and lateral to the pubic tubercle and lies in the upper leg rather than in the lower abdomen. Inadequate exposure of this area during routine examination leads to failure to detect the hernia. The hernia often rapidly becomes irreducible and loses any cough impulse due to the tightness of the neck. It may only be 1–2 cm in size and can easily be mistaken for a lymph node. As it increases in size, it is reflected superiorly and becomes difficult to distinguish from a medial direct hernia which arises only a few centimeters above the femoral canal. A direct inguinal hernia leaves the abdominal cavity just above the inguinal ligament and a femoral hernia just below.

Differential diagnosis:

- direct inguinal hernia;
- lymph node;
- saphena varix;
- femoral artery aneurysm;
- psoas abscess;
- rupture of adductor longus with hematoma.

In routine cases, no specific investigations are required. However, if there is uncertainly then ultrasound or CT should be requested. In the emergency patient, bowel obstruction usually occurs and a plain x-ray is likely to show small bowel obstruction. ***All patients with unexplained small bowel obstruction should undergo careful examination for a femoral hernia***.

Surgery for femoral hernia. There is no alternative to surgery for femoral hernia and it is wise to treat such cases with some urgency. There are three open approaches and appropriate cases can be managed laparoscopically.

Low approach (Lockwood-Bassini). This is the simplest operation for femoral hernia but only suitable when there is no risk of bowel resection. It can easily be performed under local anesthesia. A transverse incision is made over the hernia. The sac of the hernia is opened and its contents reduced. The sac is also re-

репозиторий БГМУ

duced and non-absorbable sutures placed between the inguinal ligament above and the fascia overlying the bone below. A small incision can be made in the medial lacunar ligament to aid reduction but there may be an abnormal branch of the obturator artery just deep to it which can bleed (***Corona Mortis***). The femoral vein, lateral to the hernia, needs to be protected.

The inguinal approach (Lotheissen). The initial incision is identical to that of a Bassini or Lichtenstein operation into the inguinal canal. The spermatic cord (or round ligament) is mobilized and the transversalis fascia opened from deep inguinal ring to pubic tubercle. A femoral hernia lies immediately below this incision and can be reduced. Once reduced, the neck of the hernia is closed with sutures or a mesh plug, protecting the iliac vein throughout. The layers are closed as for inguinal hernia and the surgeon may place a mesh into the inguinal canal to protect against development of an inguinal hernia.

High approach (McEvedy). This more complex operation is ideal in the emergency situation where the risk of bowel strangulation is high. It requires regional or general anesthesia. A horizontal incision (classically vertical) is made in the lower abdomen centered at the lateral edge of the rectus muscle. The anterior rectus sheath is incised and the rectus muscle displaced medially. The surgeon proceeds deep to the muscle in the preperitoneal space. The femoral hernia is reduced and the sac opened to allow careful inspection of the bowel, and a decision made regarding the need for bowel resection. This is performed if necessary. In dubious cases, the bowel is replaced into the peritoneal cavity for 5 minutes and then re-examined. The femoral defect is then closed with sutures, mesh or plug.

Laparoscopic approach. Both the TEP and TAPP approaches can be used for femoral hernia and a standard mesh inserted. This is ideal for reducible femoral hernias presenting electively but not in emergency cases nor for irreducible hernia.

VENTRAL HERNIAS

This term refers to hernias of the anterior abdominal wall. Inguinal and femoral hernias are not included even though they are ventral. Lumbar hernia is included despite being dorsolateral. The European Hernia Society classification (2009) distinguished primary ventral from incisional hernia but did not include parastomal hernia. We have included parastomal hernia and traumatic hernia.

Ventral hernias:

- umbilical – paraumbilical;
- epigastric;
- incisional;
- parastomal;
- spigelian;
- lumbar;
- traumatic.

Репозиторий БГМУ

Umbilical hernia. The umbilical defect is present at birth but closes as the stump of the umbilical cord heals, usually within a week of birth. This process may be delayed, leading to the development of herniation in the neonatal period. The umbilical ring may also stretch and reopen in adult life.

Umbilical hernia in children. This common condition occurs in up to 10 per cent of infants, with a higher incidence in premature babies. The hernia appears within a few weeks of birth and is often symptomless but increases in size on crying and assumes a classical conical shape. Sexes are equally affected but the incidence in black infants is up to eight times higher than in white. Obstruction and/or strangulation are extremely uncommon below the age of three years.

Conservative treatment is indicated under the age of two years when the hernia is symptomless. Parental reassurance is all that is necessary. Ninety-five per cent of hernias will resolve spontaneously. If the hernia persists beyond the age of two years it is unlikely to resolve and surgical repair is indicated.

A small curved incision is made immediately below the umbilicus. The neck of the sac is defined, opened and any contents are returned to the peritoneal cavity. The sac is closed and redundant sac is excised. The defect in the linea alba is closed with interrupted sutures.

Umbilical hernia in adults. Conditions which cause stretching and thinning of the midline raphe (linea alba), such as pregnancy, obesity and liver disease with cirrhosis, predispose to reopening of the umbilical defect. In adults, the defect in the median raphe is immediately adjacent to (most often above) the true umbilicus, although at operation this is indistinguishable. The term paraumbilical hernia is commonly used. The defect is rounded with a well-defined fibrous margin. Small umbilical hernias often contain extraperitoneal fat or omentum. Larger hernias can contain small or large bowel but, even when very large, the neck of the sac is narrow compared with the volume of its contents. As a result, ***in adults, umbilical hernias which include bowel are prone to become irreducible, obstructed and strangulated***.

Patients are commonly overweight with a thinned and attenuated midline raphe. The bulge is typically slightly to one side of the umbilical depression, creating a crescent-shaped appearance to the umbilicus. Women are affected more than men. Most patients complain of pain due to tissue tension or symptoms of intermittent bowel obstruction. In large hernias, the overlying skin may become thinned, stretched and develop dermatitis.

Because of the high risk of strangulation, operation should be advised in cases where the hernia contains bowel. Small hernias may be left alone if they are asymptomatic, but they may enlarge and require surgery at a later date. Surgery may be performed open or laparoscopically.

Open umbilical hernia repair. Very small defects less than 1 cm in size may be closed with a simple figure-of-eight suture, or repaired by a darn technique where a non-absorbable, monofilament suture is criss-crossed across the defect and anchored firmly to the fascia all around.

Репозиторий БГМУ

Defects up to 2 cm in diameter may be sutured primarily with minimal tension, although the larger the defect, the more tension and the more likely it is that mesh reinforcement will be beneficial. The classical repair was described by *Mayo*. A transverse incision is made and the hernia sac dissected, opened and its content reduced. Any non-viable tissue is removed, sometimes involving bowel resection. The peritoneum is closed. The defect in the anterior rectus sheath is extended laterally on both sides and elevated to create an upper and lower flap. The lower flap is then inserted beneath the upper flap and sutured to it, with the upper flap being brought downwards over it so that the tissue is two-layered (double breasted). Non-absorbable sutures are used. There is often a large subcutaneous space. A suction drain is placed to reduce the risk of seroma and hematoma. The skin is closed but stretched or redundant skin may need to be excised (apronectomy) to achieve a better cosmetic result.

Today, with modern suture materials, surgeons simply close the anterior sheath in a single layer. For defects larger than 2 cm in diameter, mesh repair is recommended.

The mesh may be placed in one of several anatomical planes:

− *Within the peritoneal cavity* — a tissue separating mesh is placed through the defect and spread out on the underside of the abdominal wall and fixed to it, ideally, with an overlap of 5 cm in each direction. This is a quick repair but requires the use of expensive mesh.

− *In the retromuscular space* — the linea alba is opened both vertically and both left and right posterior rectus sheaths are incised 1 cm to the side of the midline exposing the rectus muscle. The posterior sheaths are sutured together and the muscles elevated away from the sheath to develop the retromuscular space into which a sheet of mesh is placed and fixed by sutures. The mesh should overlap the midline by 5 cm laterally and the umbilicus vertically. It should therefore be a minimum diameter of 10 cm. A drain may be placed deep to the linea alba. This is a very secure repair but requires extensive dissection.

− *In the extraperitoneal space* — it is difficult, but possible, to develop the plane below the posterior rectus sheath, just outside the peritoneum. Care must be taken to avoid «button-holing» the peritoneum as it is thin and fragile. Mesh can then be tucked into in this space, ensuring a good overlap as before. Ideally, the linea alba is closed over the mesh but if this is not possible, a flap of peritoneal sac can be used to cover the mesh. This is a good repair, but if the peritoneum is extensively damaged during the dissection, it will have to be abandoned in favour of an alternative technique.

− *In the subcutaneous plane* — this is the simplest technique, called an onlay mesh. The peritoneal sac and contents are dealt with as above. An attempt is made to close linea alba vertically with sutures and a disc of mesh is placed on the anterior rectus sheath and sutured to it. The mesh is lying in the subcutaneous space and is prone to infection.

Laparoscopic umbilical hernia repair. Three ports are placed laterally on the abdominal wall, usually on the left side unless adhesions from previous sur-

репозиторий БГМУ

gery are likely. The contents of the hernia are reduced by traction and external pressure. A disc of non-adherent mesh, designed for intraperitoneal use, is introduced and positioned on the under surface of the abdominal wall, centered on the defect. It is then fixed to the peritoneum and posterior rectus sheaths using staples, tacks or sutures (fig. 12).

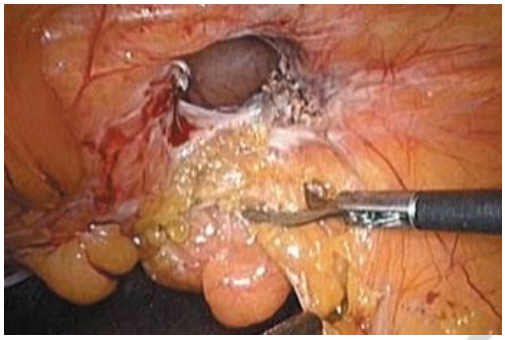

Fig. 11. Paraumbilical defect – laparoscopic view

Epigastric hernia. These arise through the midline raphe (linea alba) anywhere between the xiphoid process and the umbilicus, usually midway. When close to the umbilicus they are called supraumbilical hernias. Epigastric hernias begin with a transverse split in the midline raphe so, in contrast to umbilical hernias, the defect is elliptical. It has been hypothesised that the defect occurs at the site where small blood vessels pierce the linea alba or, more likely, that it arises at weaknesses due to abnormal decussation of aponeurotic fibres related to heavy physical activity.

Epigastric hernia defects are usually less than 1 cm in maximum diameter and commonly contain only extraperitoneal fat which gradually enlarges, spreading in the subcutaneous plane to resemble the shape of a mushroom. When very large they may contain a peritoneal sac but rarely any bowel. More than one hernia may be present.

The patients are often fit, healthy males between 25 and 40 years of age. These hernias can be very painful even when the swelling is the size of a pea due to the fatty contents becoming nipped sufficiently to produce partial strangulation. The pain may mimic that of a peptic ulcer but symptoms should not be ascribed to the hernia until gastrointestinal pathology has been excluded. A soft midline swelling can often be felt more easily than it can be seen. It may be locally tender. It is unlikely to be reducible because of the narrow neck. It may resemble a lipoma. A cough impulse may or may not be felt.

Very small epigastric hernias have been known to disappear spontaneously, probably due to infarction of the fat. Small to moderate-sized hernias without a peritoneal sac are not inherently dangerous and surgery should only be offered if the hernia is sufficiently symptomatic.

This may be done by *open or laparoscopic surgery*. At open surgery, a vertical or transverse incision is made over the swelling and down to the linea alba. Protruding extraperitoneal fat can simply be pushed back through the defect or ex-

Репозиторий БГМУ

cised. The defect in the linea alba is closed with non-absorbable sutures in adults and absorbable sutures in children. In larger hernias and when a peritoneal sac is present, the surgical approach is similar to an umbilical mesh repair. Laparoscopic repair is very similar to that for umbilical hernia except that the defect is hidden behind the falciform ligament.

Incisional hernia. These arise through a defect in the musculofascial layers of the abdominal wall in the region of a postoperative scar. Thus they may appear anywhere on the abdominal surface.

Incisional hernias have been reported in 10–50 % of laparotomy incisions and 1–5 per cent of laparoscopic port-site incisions. ***Factors predisposing to their development are*** patient factors (obesity, general poor healing due to malnutrition, immunosuppression or steroid therapy, chronic cough, cancer), wound factors (poor quality tissues, wound infection) and surgical factors (inappropriate suture material, incorrect suture placement).

An incisional hernia usually starts as disruption of the musculofascial layers of a wound in the early postoperative period. Often the event passes unnoticed if the overlying skin wound has healed securely. ***Many incisional hernias may be preventable with the use of good surgical technique***. The classic sign of wound disruption is a *serosanguinous discharge*.

These hernias commonly appear as a localized swelling involving a small portion of the scar but may present as a diffuse bulging of the whole length of the incision. There may be several discrete hernias along the length of the incision and unsuspected defects are often found at operation. *Incisional hernias tend to increase steadily in size with time.* Attacks of partial intestinal obstruction are common as there are usually coexisting internal adhesions. Strangulation is less frequent because most incisional hernias are broad-necked and carry a low risk of strangulation.

Incisional hernia summary:

1. Incidence 10–50 per cent after surgery.
2. Causation due to patient, wound and surgeon factors.
3. Wide variation in size.
4. Often multiple defects within the same scar.
5. Obstruction is common but strangulation is rare.
6. Open and laparoscopic repairs possible.

Asymptomatic incisional hernias may not require treatment at all. The wearing of an abdominal binder or belt may prevent the hernia from increasing in size.

Principles of surgery. For the majority of incisional hernias, surgery is relatively straightforward and both open and laparoscopic options are available. A number of principles apply, irrespective of the technique used.

The repair should cover the whole length of the previous incision. Approximation of the musculofascial layers should be done with minimal tension and prosthetic mesh should be used to reduce the risk of recurrence.

Reducing the risk of incisional hernia (prophylaxis). The incidence of incisional hernia may be reduced by improving the patients' general condition pre-

Репозиторий БГМУ

operatively where possible — e. g. weight loss for obesity, or improving nutritional state for malnutrition. Closing the fascial layers with non-absorbable, or very slowly absorbable, sutures of adequate gauge is important. .

There is no evidence that interrupted sutures are better or worse than continuous. However, if continuous suturing is used, the tissue bites must not be too near the fascial edge nor pulled too tight or they may cut out. It has also been confirmed that the optimal ratio of suture length to wound length is 4 : 1.

Drains should be brought out through separate incisions and not through the wound itself as this leads to hernia formation.

Spigelian hernia. These hernias are uncommon although are probably underdiagnosed. They affect men and women equally and can occur at any age, but are most common in the elderly. They arise through a defect in the Spigelian fascia which is the aponeurosis of the transversus abdominis muscle. Often these hernias advance through the internal oblique as well and spread out deep to the external oblique aponeurosis. The Spigelian fascia extends between the transversus muscle and the lateral border of the rectus sheath from the costal margin to the groin where it blends into the conjoint tendon. Most Spigelian hernias appear below the level of the umbilicus near the edge of the rectus sheath but they can be found anywhere along the «Spigelian line».

Surgery is recommended as the narrow and fibrous neck predisposes to strangulation. Surgery can be open or laparoscopic.

Lumbar hernia. Most primary lumbar hernias occur through the inferior lumbar triangle of Petit bounded below by the crest of the ilium, laterally by the external oblique muscle and medially by the latissimus dorsi.

A lumbar hernia must be distinguished from:

- a lipoma;
- a cold (tuberculous) abscess pointing to this position;
- pseudo-hernia due to local muscular paralysis. Lumbar pseudo-hernia can result from any interference with the nerve supply of the affected muscles, the most common cause being injury to the subcostal nerve during a renal operation.

The natural history is for these hernias to increase in size and surgery is recommended. Lumbar hernias can be approached by open or laparoscopic surgery. The defects can be difficult to close with sutures and mesh is recommended.

Parastomal hernia. When surgeons create a stoma, such as a colostomy or ileostomy, they are effectively creating a hernia by bringing bowel out through the abdominal wall. The muscle defect created tends to increase in size over time and can ultimately lead to massive herniation around the stoma. The rate of parastomal hernia is over 50 per cent. Various open suture and mesh techniques have been described to repair parastomal hernia but failure rates are high.

Traumatic hernia. These hernias arise through non-anatomic defects caused by injury. They can be classified into three types:

1. Hernias through abdominal stab wound sites. These are effectively incisional hernias.

РЕПОЗИТОРИЙ БГМУ

2. Hernias protruding through splits or tears in the abdominal muscles following blunt trauma.

3. Abdominal bulging secondary to muscle atrophy which occurs as a result of nerve injury or other traumatic denervation. Akin to the lumbar pseudo-hernia seen after open nephrectomy, these can arise following chest injury with damage to the intercostal nerves.

Surgery may be justified if the hernia is sufficiently symptomatic, or if investigations suggest a narrow neck and hence a risk of obstruction or strangulation. Stab wound traumatic hernias are straightforward to repair using open or laparoscopic techiques as for other ventral hernias. Diffuse abdominal bulges are more difficult to correct and require some form of plication of the stretched musculofascial layer with mesh reinforcement to prevent further bulging in the future. Some bulging may persist however.

RARE EXTERNAL HERNIAS

Perineal hernia. This type of hernia is very rare and includes:

− postoperative hernia through a perineal scar, which may occur after excision of the rectum;

− median sliding perineal hernia, which is a complete prolapse of the rectum;

− anterolateral perineal hernia, which occurs in women and presents as a swelling of the labium majus;

− posterolateral perineal hernia, which passes through the levator ani to enter the ischiorectal fossa.

Obturator hernia. Obturator hernia, which passes through the obturator canal, occurs six times more frequently in women than in men. Most patients are over 60 years of age. The swelling is liable to be overlooked because it is covered by the pectineus. It seldom causes a definite swelling in Scarpa's triangle, but if the limb is flexed, abducted and rotated outwards, the hernia sometimes becomes apparent. The leg is usually kept in a semiflexed position and movement increases the pain. In more than 50 per cent of cases of strangulated obturator hernia, pain is referred along the obturator nerve by its geniculate branch to the knee. On vaginal or rectal examination the hernia can sometimes be felt as a tender swelling in the region of the obturator foramen.

These hernias have often undergone strangulation, frequently of the Richter type, by the time of presentation.

Operation is indicated. The diagnosis is rarely made preoperatively and so it is often approached through a laparotomy incision

Gluteal and sciatic hernias. Both of these hernias are very rare. A gluteal hernia passes through the greater sciatic foramen, either above or below the piriformis. A sciatic hernia passes through the lesser sciatic foramen. Differential diagnosis must be made between these conditions and:

− a lipoma or other soft tissue tumour beneath the gluteus maximus;

Репозиторий БГМУ

– a tuberculous abscess;
– a gluteal aneurysm.

All doubtful swellings in this situation can be characterised with CT scanning but, if in doubt, they should be explored by operation.

INTERNAL HERNIAS

Internal herniation occurs when a portion of the small intestine becomes entrapped in one of the retroperitoneal fossae or in a congenital mesenteric defect.

The following are potential sites of internal herniation (all are rare):

– the foramen of Winslow;
– a defect in the mesentery;
– a defect in the transverse mesocolon;
– defects in the broad ligament;
– congenital or acquired diaphragmatic hernia;
– duodenal retroperitoneal fossae — left paraduodenal and right duodenojejunal;
– caecal/appendiceal retroperitoneal fossae — superior, inferior and retrocaecal;
– intersigmoid fossa.

Internal herniation in the absence of adhesions is rare and a preoperative diagnosis is unusual. The standard treatment of an obstructed hernia is to release the constricting agent by division. This should not be undertaken in cases of herniation involving the foramen of Winslow, mesenteric defects and the paraduodenal/duodenojejunal fossae as major blood vessels run in the edge of the constriction ring. The distended loop in such circumstances must first be decompressed (minimizing contamination) and then reduced.

TESTS

1. Predisposing factors of hernia formation are:

a) weakness due to structures entering and leaving the abdomen;
b) sharp and blunt trauma, operation;
c) weakness due to ageing and pregnancy;
d) obesity;
e) professional sport;
f) middle age;
g) smoking;
h) atherosclerotic disease;
i) developmental failures;
j) genetic weakness of collagen.

2. Irreducible hernia when:

a) the hernia content can move freely in and out of the hernia;
b) the hernia content cannot return to the peritoneal cavity;

Репозиторий БГМУ

c) the passage of bowel content is affected;
d) the hernia content become infarcted due to the break of blood supply.

3. **Richter's hernia when:**
   a) only part of the bowel wall enters the hernia;
   b) the hernia content cannot return to the peritoneal cavity;
   c) the hernia content become infarcted due to the break of blood supply;
   d) hernia extends between the layers of muscle.
4. **Use of mesh in hernia repair is preferable in:**
   a) inflamed hernia;
   b) infarction of hernia content;
   c) young age;
   d) large defect of abdominal wall;
   e) recurrent hernias;
   f) big size of hernia.
5. **The most common hernia in men:**
   a) femoral;
   b) umbilical;
   c) inguinal;
   d) ventral;
   e) incisional.
6. **Open suture repair of inguinal hernia:**
   a) TEP;
   b) Bassini;
   c) Shouldice;
   d) TAPP;
   e) McVay;
   f) Lichtenstein.
7. **Umbilical hernia may be**
   a) lateral (oblique, indirect);
   b) medial (direct);
   c) congenital;
   d) acquired;
   e) transverse.
8. **Rate of incisional hernia after laparotomy:**
   a) 10–50 %;
   b) < 1 %;
   c) > 90 %;
   d) 70–90 %.

Answers: 1 — a, b, f, h; **2** — b; **3** — e; **4** — c; **5** — a, b, c, f; **6** — b, c, e; **7** — c, d; **8** — a.

Репозиторий БГМУ

LITERATURE

Basic

1. *Essentials* of general surgery / Peter F. Lawrence [et. al.]. 5th ed. Philadelphia [etc.] : Wolters Kluwer : Lippincott Williams & Wilkins, 2013. 586 p.
2. *Schwartz`s* principles of surgery / F. Chatles Brunicardi [et. al.]. 9th ed. MeGraw Hill Professional, 2009. 1888 p.

Additional

3. *Greenfield's* Surgery: Scientific Principles & Practice / Michael W. Mulholland [et. al.]. 5th ed., 2010. 2074 p.
4. *Clinical* surgery / H. John Davis [et al.]. St. Louis : The C.V. Mosby Company, 1987. 3264 p.
5. *Surgery* : tests for the 4th year students of the faculty of foreign students with English language medium : тесты для студентов 4 курса фак. иностр. учащихся (курс обучения на англ. яз.) / Н. И. Батвинков [и др.]. Гродно : ГрГМУ, 2012. 3350 с.

Репозиторий БГМУ

CONTENTS

Motivational characteristic of the topic 4
Basic anatomy and function related to pathology.....5
Etiology and Pathogenesis 6
Diagnosis..... 10
Examination. 10
Investigations. 10
Management principles 11
Specific hernia types 14
Inguinal hernia..... 15
Sportsman's hernia 20
Femoral hernia..... 20
Ventral Hernias..... 22
Rare external hernias 28
Internal hernias 29
Tests 29
Literature..... 30

Репозиторий БГМУ

Учебное издание

Жура Александр Владимирович
Большов Андрей Владимирович

ГРЫЖИ
HERNIAS

Учебно-методическое пособие

На английском языке

Ответственный за выпуск С. И. Третьяк
Переводчик А. В. Жура
Компьютерная верстка А. В. Янушкевич

Подписано в печать 26.04.17. Формат 60×84/16. Бумага писчая «Снегурочка».
Ризография. Гарнитура «Times».
Усл. печ. л. 1,86. Уч.-изд. л. 1,79. Тираж 40 экз. Заказ 242.

Издатель и полиграфическое исполнение: учреждение образования
«Белорусский государственный медицинский университет».
Свидетельство о государственной регистрации издателя, изготовителя,
распространителя печатных изданий № 1/187 от 18.02.2014.
Ул. Ленинградская, 6, 220006, Минск.

Репозиторий БГМУ