

L. N. PALIANSKAYA, I. A. ZAKHARAVA

**WHITE LESIONS
OF ORAL MUCOSA**

Minsk BSMU 2019

МИНИСТЕРСТВО ЗДРАВООХРАНЕНИЯ РЕСПУБЛИКИ БЕЛАРУСЬ
БЕЛОРУССКИЙ ГОСУДАРСТВЕННЫЙ МЕДИЦИНСКИЙ УНИВЕРСИТЕТ
2-я КАФЕДРА ТЕРАПЕВТИЧЕСКОЙ СТОМАТОЛОГИИ

Л. Н. Полянская, И. А. Захарова

БЕЛЫЕ ПОРАЖЕНИЯ СЛИЗИСТОЙ ОБОЛОЧКИ ПОЛОСТИ РТА

WHITE LESIONS OF ORAL MUCOSA

Учебно-методическое пособие



Минск БГМУ 2019

УДК 616.311-001-07-08(075.8)-054.6

ББК 56.6я73

П54

Рекомендовано Научно-методическим советом университета в качестве учебно-методического пособия 20.03.2019 г., протокол № 7

Р е ц е н з е н т ы: д-р мед. наук, проф. Белорусской медицинской академии последипломного образования Н. А. Юдина; канд. мед. наук, доц. Белорусской медицинской академии последипломного образования С. А. Гранько; канд. филол. наук, доц. Белорусского государственного медицинского университета М. Н. Петрова

Полянская, Л. Н.

П54 Белые поражения слизистой оболочки полости рта = White lesions of oral mucosa : учебно-методическое пособие / Л. Н. Полянская, И. А. Захарова. – Минск : БГМУ, 2019. – 20 с.

ISBN 978-985-21-0271-1.

Рассмотрены клинические проявления, подходы к дифференциальной диагностике и лечению белых поражений слизистой оболочки полости рта.

Предназначено для студентов 5-го курса медицинского факультета иностранных учащихся, обучающихся на английском языке по специальности «Стоматология».

УДК 616.311-001-07-08(075.8)-054.6

ББК 56.6я73

ISBN 978-985-21-0271-1

© Полянская Л. Н., Захарова И. А., 2019
© УО «Белорусский государственный медицинский университет», 2019

MOTIVATIONAL CHARACTERISTIC OF THE THEME

Total time: 70–90 minutes (seminar).

In day-to-day clinical practice oral physicians often come across with a wide spectrum of oromucosal lesions. These lesions range from harmless mucosal alterations like changing in the color and texture of the oral mucosa, needing simple therapeutic remedies and a patient's attitude to lesions of a life-threatening nature. White colored alterations of the oral mucosa are commonly seen in dental practice. Recognizing and differentiating these mucosal alterations from normal anatomic variations is very important for the effective management of these lesions.

The purpose of the seminar: to summarize the knowledge of the basic principles of diagnosis and treatment of white lesions of oral mucosa.

The tasks of the seminar. The student should know:

1. The scheme of clinical examination of the patient with oral mucosa disease.
2. Description of sequent and characteristic features of oral mucosa lesions.
3. Additional methods of examination and laboratory diagnosis of oral mucosa diseases.
4. Principles of differential diagnosis of white lesions of oral mucosa.
5. Basic principles and methods of treatment of patients with the diseases of oral mucosa. Groups of medicines.

Requirements for the initial level of knowledge. To understand the topic completely the student must revise:

- anatomical features of oral mucosa from human anatomy;
- morphological structure of oral mucosa from histology, cytology, embryology;
- dental examination, basic and additional methods, types of oral mucosa lesions from therapeutic dentistry.

Control questions from related disciplines:

1. Anatomical and histological structure of oral mucosa.
2. Classification and characteristics of oral mucosal lesions.
3. Cytological, histological, microbiological, allergic, biochemical methods of examination.

Control questions for the seminar:

1. Classification of oral mucosa diseases (WHO).
2. Methods of examination in patients with oral mucosa diseases.
3. Diagnosis and clinical features of white lesions of oral mucosa.
4. Differential diagnosis of white lesions.
5. Contemporary principles of treatment of white lesions of oral mucosa.

White Lesions

White lesion is a non-specific term used to describe any abnormal area of the oral mucosa that on clinical examination appears whiter than the surrounding tissue. It is usually slightly raised, roughened or of different texture from the adjacent normal mucosa.

A white appearance of the oral mucosa may be caused by a variety of factors. The oral epithelium may be stimulated to an increased production of keratin (hyperkeratosis) or an abnormal but benign thickening of stratum spinosum (acanthosis). Intra- and extracellular accumulation of fluid in the epithelium may also result in clinical whitening. Microbes, particularly fungi, can produce whitish pseudomembranes consisting of sloughed epithelial cells, fungal mycelium, and neutrophils, which are loosely attached to the oral mucosa.

There are many classifications of white lesions of oral mucosa according to their etiology, pathogenesis, clinical manifestations, course, etc. Here is a **fragment of the International Classification of Diseases (ICD-DA 1994 WHO)**, which are manifested by white lesions:

Section I. Certain infectious and parasitic diseases

Infections with a predominantly sexual mode of transmission (A 50–58):

A 51.3 Secondary syphilis of the skin and mucous membranes

A 51.3X Oral manifestations

Viral infections characterized by the skin and mucous membrane lesions (B 00–08):

B 05.8 Measles with other complications

B 05.8X Oral manifestations

Mycosis (B 35–48):

B 37.0 Candidal stomatitis

B 37.00 Acute pseudomembranous candidal stomatitis

B 37.02 Chronic hyperplastic candidal stomatitis

Section XI. Diseases of the digestive system

Diseases of oral cavity, salivary glands and jaws (K 00–14):

K 13.1 Cheek and lip biting

K 13.2 Leukoplakia and other disturbances of oral epithelium, including the tongue

K 13.20 Leukoplakia, idiopathic

K 13.21 Leukoplakia, tobacco-associated

K 13.23 Leukoedema

K 13.24 Smoker's palate (nicotinic stomatitis)

K 13.3 Hairy leukoplakia

K 14.1 Geographic tongue

Section XII. Diseases of the skin and subcutaneous tissue

Papulosquamous disorders (L 40–48):

L 43.8 Other Lichen planus

L 43.80 Oral manifestations of lichen planus, papular

L 43.81 Oral manifestations of lichen planus, reticular

L 43.82 Oral manifestations of lichen planus, atrophic and erosive

L 43.83 Oral manifestations of lichen planus, plaque type

Let's have a look at the most common white lesion of oral mucosa.

Focal (frictional) hyperkeratosis

Definition. Frictional hyperkeratosis is a white patch which is clearly related to a source of mechanical irritation and that will disappear over a period of time with the removal of the stimuli.

Etiology. The white lesions are associated with various etiologic agents, including ill-fitting dental prostheses, chronic irritational habits such as cheek- or lip-biting, overzealous tooth brushing, and white calluses formed from occlusions on the edentulous ridges or the retromolar pads.

Clinical features. Friction-induced hyperkeratosis occurs in areas that are commonly traumatized, such as the lips, lateral margins of the tongue, buccal mucosa along the occlusal line, and edentulous alveolar ridges. The individual lesions usually present as asymptomatic, smooth or irregular in texture, thickened whitish areas (fig. 1, 2).

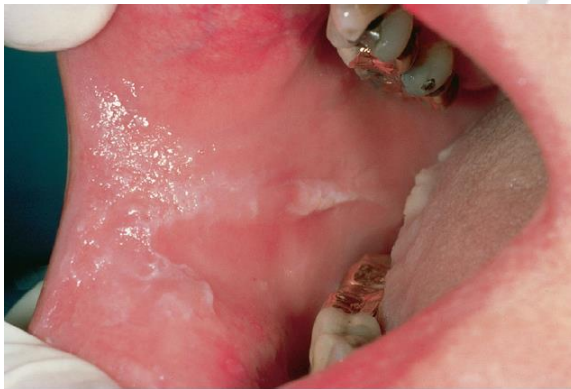

Fig. 1. Focal hyperkeratosis caused by the cheek chewing

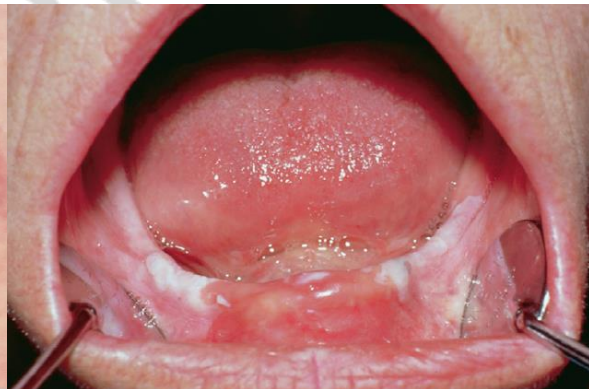

Fig. 2. Focal hyperkeratosis associated with an ill-fitting lower denture

Diagnosis. For most lesions, the diagnosis can be established based on clinical features. If the diagnosis is doubtful, biopsy is mandatory to exclude premalignant lesions. The histopathologic picture is characterized by hyperkeratosis without dysplasia and no or mild subepithelial inflammation.

Treatment. No surgical intervention is indicated. Information about the nonmalignant nature of the lesions and attempts to reduce predisposing factors are sufficient.

Leukoplakia

Definition. Leukoplakia is a descriptive clinical term indicating a white patch or plaque that cannot be rubbed off and cannot be characterized clinically as any other disease. It is a premalignant lesion.

Etiology. The exact etiology remains unknown. Tobacco, alcohol, chronic local trauma, and *C. albicans* infection are important predisposing factors. *Human papilloma virus* (HPV) and some nutritional factors (related to iron deficiency anemia) may also be involved in the pathogenesis of oral leukoplakia.

Clinical features. Leukoplakia is a condition associated with middle-aged and older populations. The typical *homogeneous* leukoplakia is clinically characterized as a white, often well-demarcated plaque with an identical reaction pattern throughout the entire lesion (fig. 3). The surface texture can vary from a smooth and thin to a leathery appearance with surface fissures sometimes referred to as «cracked mud». The demarcation is usually distinct, which is different from an oral lichen planus (OLP) lesion, where the white components have a more diffuse transition to the normal oral mucosa. Another difference between these two lesions is the lack of a peripheral erythematous zone in homogeneous oral leukoplakia. The lesions are asymptomatic in most patients.

The *nonhomogeneous* type of oral leukoplakia may have white patches or plaques intermingled with red elements. It's called *speckled leukoplakia* (erythroleukoplakia) and has a greater risk for malignant transformation than the homogeneous form (fig. 4).

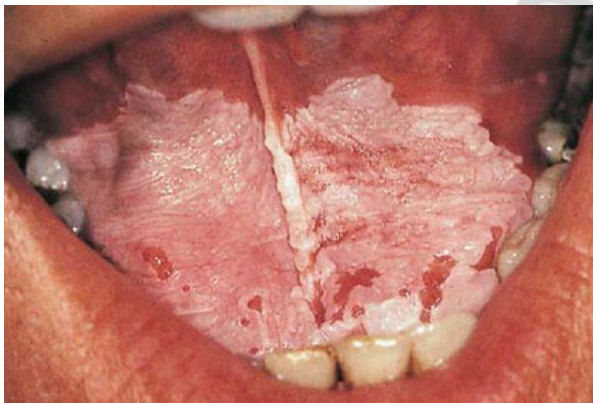


Fig. 3. Homogeneous leukoplakia

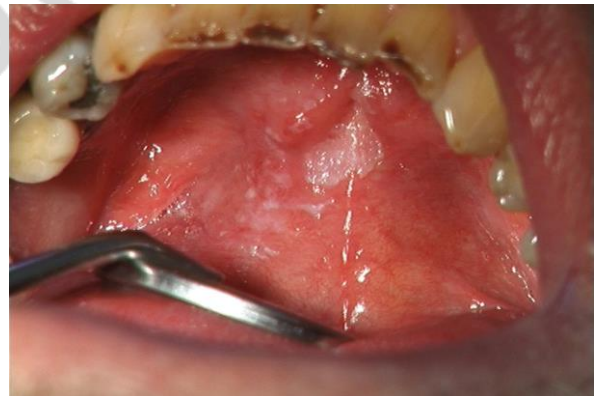

Fig. 4. Speckled leukoplakia

Oral leukoplakia, where the white component is dominated by papillary projections, similar to oral papillomas, is referred to as *verrucous leukoplakia*. Proliferative verrucous leukoplakia (PVL) is usually encountered in older women, and the lower gingiva is a predilection site. Malignant potential is very high.

Oral leukoplakia may be found at all sites of the oral mucosa. The floor of the mouth and the lateral borders of the tongue have been considered high-risk sites for malignant transformation.

Diagnosis. The provisional diagnosis is based on the clinical observation of a white patch that is not explained by a definable cause, such as trauma. If trauma is suspected, the cause, such as a sharp tooth or restoration, should be eliminated. If healing does not occur in two weeks, a tissue biopsy is essential to rule out malignancy. Histopathologic features of the epithelium may include hyperkeratosis, atrophy, and hyperplasia with or without dysplasia.

Differential diagnosis. The first step in developing a differential diagnosis for a white patch is to determine whether it can be removed. If the lesion can be removed, it may represent a pseudomembrane, a fungus colony, or debris. If bilateral buccal mucosal disease is evident, then hereditary conditions, cheek chewing, OLP, and lupus erythematosus (LE) should be considered. Concomitant cutaneous lesions would give weight to the latter two. If chronic trauma or tobacco use is elicited in the patient's history, frictional or tobacco-associated hyperkeratosis, respectively, should be considered. Elimination of a suspected cause should result in some clinical improvement. Hairy leukoplakia and geographic tongue would also be included in differential diagnosis for the tongue leukoplakia.

If the lesion is not removable and is not clinically diagnosed, it should be considered an idiopathic leukoplakia and a biopsy should be performed.

Treatment. Since oral leukoplakia is a lesion with an increased risk of malignant transformation, measures for elimination of all predisposing factors should be taken into consideration. Surgical excision is the treatment of choice. Cold-knife surgical excision, as well as laser surgery, is widely used to eradicate leukoplakias but will not prevent all premalignant lesions from malignant development. A general recommendation is to reexamine the premalignant site irrespective by of surgical excision every three months for the first year, and then once every six months.

LEUKOEDEMA

Definition. Leukoedema is a white and veil-like alteration of the oral mucosa that is merely considered a normal variant.

Etiology. Is not clear.

Clinical features. Leukoedema appears as a filmy, opaque, white to slate gray discoloration of mucosa. The condition is often encountered bilaterally in the buccal mucosa (fig. 5) and sometimes at the borders of the tongue. Leukoedema is less clinically evident after stretching the mucosa but reappearing after this manipulation is discontinued. In more pronounced cases, leukoedema is accompanied by mucous folds. The condition is asymptomatic and has no malignant potential. The lesion is more prevalent in the black population. It's also accentuated in smokers.

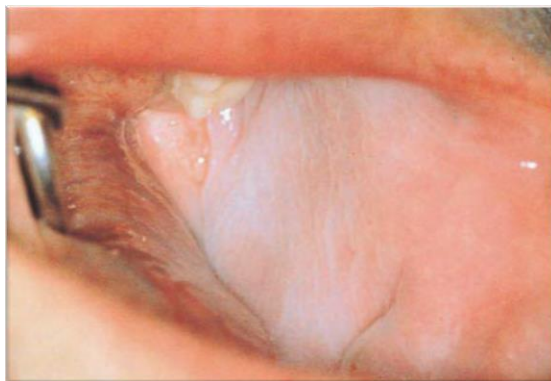


Fig. 5. Leukoedema

Diagnosis. The clinical features of leukoedema are quite different from oral keratosis, such as leukoplakia, as the demarcation is diffused and gentle stretching results in a temporary disappearance. The histopathology is characterized by parakeratosis and acanthosis together with intracellular edema in epithelial cells of the stratum spinosum.

Treatment. Not required as the condition is non-symptomatic and has no complications.

NICOTINIC STOMATITIS

Definition. Nicotinic stomatitis is a common tobacco-related form of keratosis manifested by white leathery lesions of the palate.

Etiology. Smoker's palate is more prevalent in men, high consumers of pipe tobacco and cigarettes. The etiology is probably more related to the high temperature rather than to the chemical composition of the smoke, although there is a synergistic effect of the two.

Clinical features. An erythematous irritation is initially seen, and this lesion is followed by a whitish palatal mucosa reflecting a hyperkeratosis. As part of this lesion, red dots can be observed representing orifices of accessory salivary glands, which can be enlarged and display metaplasia. The most severe changes are usually seen in individuals who practice reverse smoking (fig. 6).

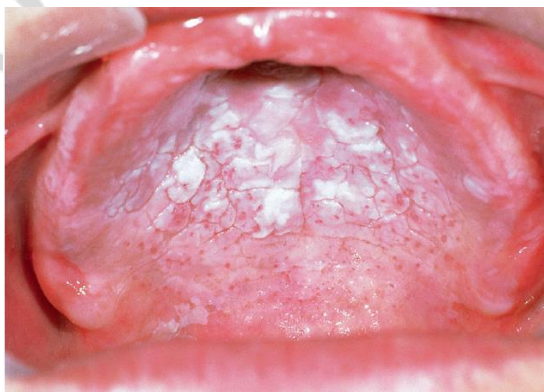

Fig. 6. Revers smoker's palate

Diagnosis. Diagnosis is based on the anamnesis of smoking habits and typical clinical appearance of the palate. Histopathology shows epithelial hyperplasia and hyperkeratosis. The minor salivary glands show inflammatory changes, and excretory ducts may show squamous metaplasia.

Treatment. This condition rarely evolves into malignancy except in individuals who reverse smoking. However nicotine stomatitis may indicate risk of epithelial dysplasia and neoplasia elsewhere in the oral cavity, oropharynx, and respiratory tract. Therefore, the habit of utilizing tobacco should be eliminated or strictly limited.

ORAL LICHEN PLANUS

Definition. Lichen planus is a chronic inflammatory mucocutaneous disease affecting 0.5 % to 2.2 % of the population, mostly women in middle ages.

Etiology. Although the cause of OLP is not well known, it has become evident that the immune system plays a primary role in the development of this disease. An expression of the cell-mediated arm of the immune system is involved in the pathogenesis of OLP through T-lymphocyte cytotoxicity directed against antigens expressed by the basal cell layer. The severity of the disease often parallels to a patient's level of stress that appears to be a modifying factor in some cases.

Clinical features. OLP may contain different elements and provide, together with the different textures, the basis for the classification of clinical types:

- Reticular;
- Papular;
- Plaque-like;
- Bullous;
- Erythematous;
- Ulcerative.

To establish a clinical diagnosis of OLP, reticular or papular textures have to be present. If, in addition, plaque-like, bullous, erythematous, or ulcerative areas are present, the OLP lesion is developed accordingly.

The *reticular* form of OLP is characterized by fine white lines or striae (so-called Wickham's striae). They may form a network but can also show annular (circular) patterns. The striae often display a peripheral erythematous zone, which reflects a subepithelial inflammation. Although reticular OLP may be encountered in all regions of the oral mucosa, most frequently this form is observed bilaterally in the buccal mucosa (fig. 7) and rarely on the mucosal side of the lips.

The *papular* type of OLP is usually present in the initial phase of the disease. In this type, pinhead size papules are present spaced apart but distributed close enough that the lesion has a pebble white or gray appearance (fig. 8).

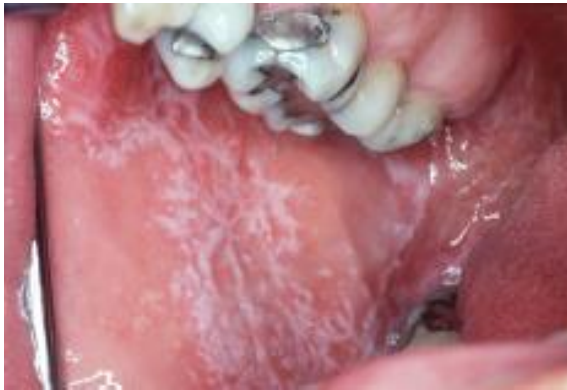

Fig. 7. Oral lichen planus, reticular form

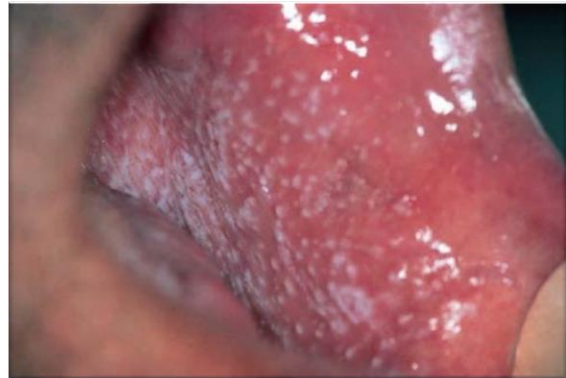


Fig. 8. Oral lichen planus, papular form

These two forms generally present with minimal clinical symptoms and are often accidental discoveries.

Plaque-type OLP shows a white plaque that occurs together with striae (fig. 9). The patient may experience the feeling of roughness. Plaque-type lesions may clinically be very similar to homogeneous oral leukoplakia. The difference between these two mucosal disorders is multifocal distribution and the presence of reticular or papular structures in the case of plaque-like OLP.

The *bullous* form is very unusual but may appear as bullous structures surrounded by a reticular network.

Erythematous (atrophic) OLP is characterized by a homogeneous red area. When this type of OLP is present in the buccal mucosa or in the palate, striae are frequently seen in the periphery of the lesion. Some patients may display erythematous OLP exclusively affecting the attached gingiva (fig. 10). This form of lesion may occur without any papules or striae and presents as desquamative gingivitis. Therefore, erythematous OLP may require a histopathologic examination in order to make at a correct diagnosis.

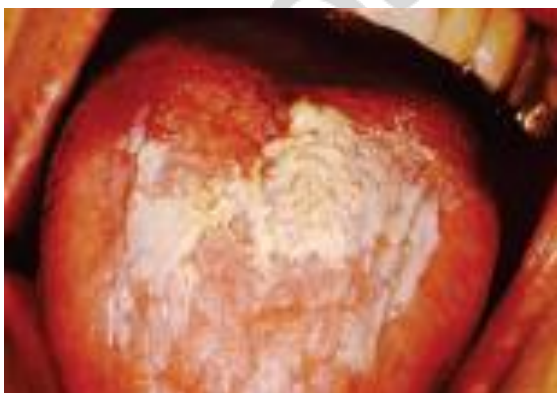

Fig. 9. Oral lichen planus, plaque-type

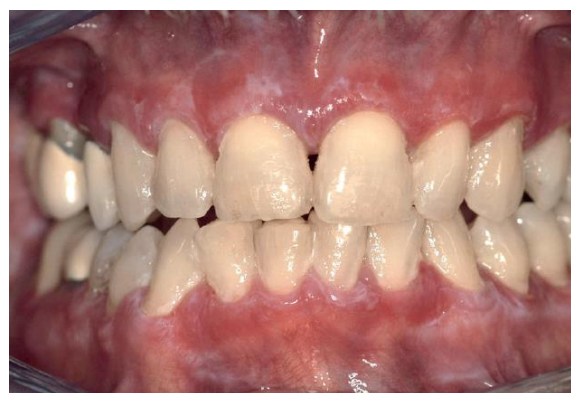

Fig. 10. Oral lichen planus, erythematous

Ulcerative lesions are the most disabling forms of OLP (fig. 11). Clinically, the fibrin-coated ulcers are surrounded by an erythematous zone with white striae in the periphery. As for the erythematous form of OLP, the affected patient complains of burning, sensitivity, and generalized discomfort.

The classic appearance of skin lesions consists of pruritic erythematous to violaceous papules that are flat topped. The predilection sites are the trunk and flexor surfaces of arms and legs (fig. 12). The papules may be discrete or coalesce to form plaques. The patients report relief following by intense scratching of the lesions, but trauma may aggravate the disease, which is referred to as a Koebner phenomenon.

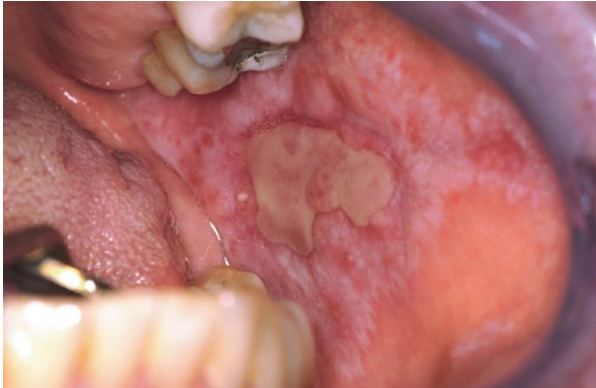

Fig. 11. Oral lichen planus, ulcerative form

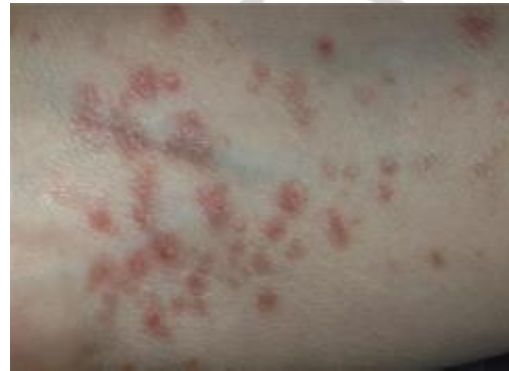

Fig. 12. Oral lichen planus, cutaneous lesions

Diagnosis. Histopathological examination is very helpful. Direct immunofluorescence can also be used, although the features are not specific. The microscopic criteria include hyperkeratosis, basal layer vacuolization with apoptotic keratinocytes, and a lymphohagocytic infiltrate at the epithelium-connective tissue interface. Direct immunofluorescence demonstrates the present of fibrinogen in the basement membrane zone in 90 % to 100 % of cases.

Differential diagnosis. Other diseases with multifocal bilateral presentation that should be included in a clinical differential diagnosis are lichenoid drug reaction, lupus erythematosus (LE), white sponge nevus, hairy leukoplakia, cheek chewing, and candidiasis. Idiopathic leukoplakia and squamous cell carcinoma might be considered when lesions are plaque-like. Erythematous lichen planus affecting the attached gingiva must be differentiated from mucous membrane pemphigoid, pemphigus vulgaris, chronic LE, contact hypersensitivity, and chronic candidiasis.

Treatment. Since the etiology behind OLP is unknown, all current treatment strategies are aiming at reducing or eliminating symptoms. Asymptomatic forms generally require no treatment.

For symptomatic cases various treatment options have been suggested (tabl. 1). Among these, *topical steroids* are widely used and accepted as the primary treatment of choice. When potent topical steroids are used, a fungal infec-

tion may emerge, and a parallel treatment with antifungal drugs may be necessary. Systemic corticosteroids should be reserved for acute exacerbation, multiple or widespread lesions or those unresponsive to topical steroids.

Table 1

Empirical treatment for OPL

<p>Immunomodulators Immunosuppressive agents <u>Corticosteroids</u> <i>Systemic:</i> – Prednisone – Methylprednisolone <i>Topical:</i> – Betamethasone – Clobetasol – Fluocinolone acetonide – Fluocinonide – Fluticasone – Hydrocortisone – Triamcinolone <i>Intralesional:</i> – Dexamethasone – Hydrocortisone – Methyl prednisolone – Triamcinolone Other immunosuppressive agents – Cyclosporin – Interferon alpha – Interferon beta – Pimecrolimus – Tacrolimus – Thalidomide – Azathioprine Immunostimulants – Levamisole</p>	<p><u>Anti-fungals</u> – Griseofulvin – Azoles – Polyenes</p> <p><u>Surgery</u> – Conventional – Cryosurgery – Laser surgery – Grafting</p> <p><u>UV radiation</u> – UV light – PUVA</p> <p><u>Others</u> – Eiconol – Enoxaparin – Glycyrrhizin – Mesalazine, etc.</p> <p><u>Retinoids</u> – Acitretin – Etreinate – Fenretinide – Iso-tretinoin – Tazarotene – Temarotene – Tretinoin</p>
---	---

Erythematous OLP of the gingiva constitutes a therapeutic challenge. To be successful, it is critical to remove both sub- and supragingival plaque and calculus. Oral hygiene should be optimized prior to the beginning of steroid treatment. Steroid gels in pre-fabricated plastic trays may be used for 30 minutes at each application to increase the concentration of steroids in the gingival tissue.

Topical application of cyclosporine, tacrolimus, and retinoids has been suggested as a second-line therapy for OLP. Surgical excision is recommended for isolated plaques or non-healing erosions. Some patients may also require stress management.

There are reports that lichen planus predisposes the patient to oral cancer. Although the risk is low, a minimum of annual monitoring has been suggested in connection with routine dental examination.

ORAL CANDIDIASIS

Definition. Candidiasis is a common opportunistic oral mycotic infection that develops in the presence of one or several predisposing conditions.

Etiology. *C. albicans*, *C. tropicalis*, and *C. glabrata* comprise together over 80% of the species isolated from human candidal infections. *Candida* is usually a weak pathogen, and candidiasis is said to affect the very young, the very old, and the very sick. There is an apparent association between oral candidiasis and the influence of local and general predisposing factors (tabl. 2).

Table 2

Factors that predispose the host to oral candidiasis

<i>Predisposing factor</i>	<i>Mechanism of effects on host</i>
Physiological	Old age, infancy, or pregnancy that associate with altered host immunity, hyposalivation, etc.
Local trauma	Mucosal irritation, poor denture hygiene
Malnutrition	High-carbohydrate diet, iron, foliate and vitamin B ₁₂ deficiencies
Broad-spectrum anti-biotics	Altered oral microbiology
Corticosteroids	Steroid inhalers, systemic steroids suppressing oral immunity
Immune defects	HIV infection, AIDS, thymic aplasia
Endocrine disorders	Hypoadrenal states (e. g. hypothyroidism, Addison's disease)
Malignancies	Including blood disorders e. g. acute leukemia, agranulocytosis that impairs host's immunity
Hyposalivation	Autoimmune disease: Sjögren's syndrome; acquired: head and neck irradiation. Medication including cytotoxic drug therapy

Clinical features. The classic triad of oral candidiasis is:

- Pseudomembranous type;
- Hyperplastic type;
- Erythematous type.

First two variants are manifested by white lesions of oral mucosa, and the third one — by red lesions.

Pseudomembranous candidiasis, classically termed as «thrush» (fig. 13), is an acute infection but may persist intermittently for many months or even years in patients using corticosteroids topically or by aerosol, in HIV-infected individuals, and in other immunocompromised patients. It may also be seen in neonates and in the terminally ill, particularly in association with serious underlying conditions such as leukemia. The infection typically presents with loosely attached membranes comprising fungal organisms and cellular debris, which

leaves an inflamed, sometimes bleeding area if the pseudomembrane is removed. In severe cases patients may complain of tenderness, burning and dysphagia.

Hyperplastic candidiasis. The lesions in hyperplastic candidiasis present as chronic, discrete raised areas that vary from small, palpable, translucent, whitish areas to large, dense, opaque plaques hard and rough to the touch (fig. 14). The lesions are often asymptomatic and usually occur on the inside surface of one or both cheeks (retrocommissural area).

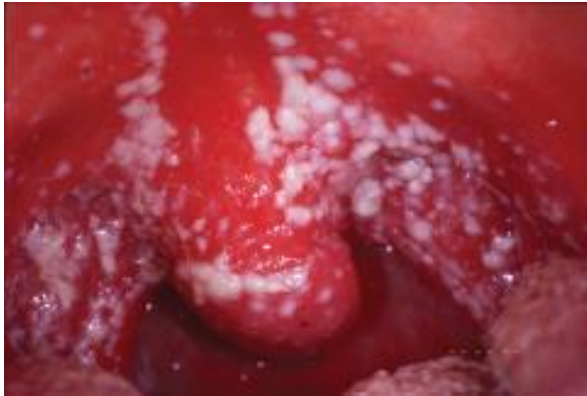

Fig. 13. Pseudomembranous candidiasis

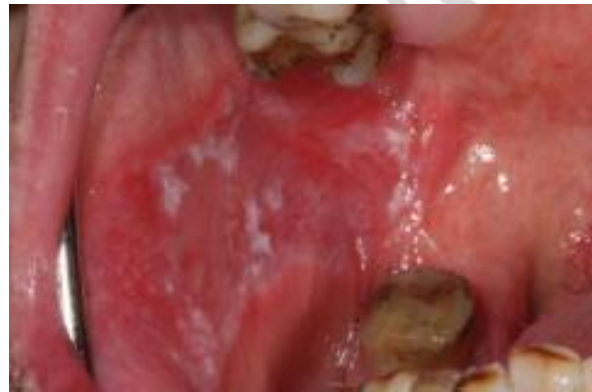

Fig. 14. Hyperplastic candidiasis

Diagnosis. The presence of candidal microorganisms as a member of the commensal flora complicates the discrimination of the normal state from infection. It is imperative that both clinical findings and laboratory data are balanced in order to make at a correct diagnosis.

The detection of yeast organisms in the form of hyphae- or pseudohyphae-like structures in the smear from the infected area is usually considered a sign of infection although these structures have also been identified in normal oral mucosa. To increase the sensitivity, a second scrape can be transferred to a transport medium followed by cultivation on Sabouraud agar. Patients who display clinical signs of oral candidiasis usually have more than 400 CFU/mL. In chronic hyperplastic candidiasis cultivation techniques have to be supplemented by a histopathologic examination to identify the presence of epithelial dysplasia.

Differential diagnosis. Candidal white lesions should be differentiated from slough associated with chemical burns, traumatic ulcerations, mucous patches of syphilis, and white keratotic lesions.

Treatment. Whenever possible, elimination or reduction of predisposing factors should always be the first goal for treatment. Scrupulous oral hygiene and a diet with a low content of fermentable carbohydrates are important.

Local factors are often easy to identify but sometimes not possible to reduce or eradicate. Antifungal drugs (tabl. 3) have a primary role in such cases. Polyenes such as nystatin and amphotericin B are usually the first choices and are both well tolerated. Polyenes are not absorbed from the gastrointestinal tract

and are not associated with development of resistance. Topical application of antifungals should be continued for at least 1 week beyond the disappearance of the clinical manifestations of the disease.

Table 3

Antifungal agents used in the treatment of oral candidiasis

Drug	Form	Dosage	Comments
Amphotericin B	<i>Lozenge, 10 mg</i>	Slowly dissolved in mouth 3–4 × /d after meals for 2 wk minimum	Negligible absorption from gastrointestinal tract. When given IV for deep mycoses may cause thrombophlebitis, anorexia, nausea, vomiting, fever, headache, weight loss, anemia, hypokalemia, nephrotoxicity, hypotension, arrhythmias, etc.
	<i>Oral suspension, 100 mg/mL</i>	Placed in the mouth after food and retained near lesions 4 × /d for 2 wk	
Nystatin	<i>Cream</i>	Apply to affected area 3–4 × /d	Negligible absorption from gastrointestinal tract. Nausea and vomiting with high doses.
	<i>Pastille, 100,000 U</i>	Dissolve 1 pastille slowly after meals 4 × /d, usually for 7 d	
	<i>Oral suspension, 100,000 U</i>	Apply after meals 4 × /d, usually for 7 d, and continue use for several days after postclinical healing	
Clotrimazole	<i>Cream</i>	Apply to the affected area 2–3 times daily for 3–4 wk	Mild local effects. Also has antistaphylococcal activity.
	<i>Solution</i>	5 ml 3–4 times daily for 2 wk minimum.	
Miconazole	<i>Oral gel</i>	Apply to the affected area 3–4 times daily	Occasional mild local reactions. Also has antibacterial activity. Theoretically the best antifungal to treat angular cheilitis. Interacts with anticoagulants (warfarin), terfenadine, cisapride, and astemizole. Avoid in pregnancy and liver disease.
	<i>Cream</i>	Apply twice per day and continue for 10–14 d after the lesion heals	
Ketoconazole	<i>Tablets</i>	200–400 mg tablets taken once or twice daily with food for 2 wk	May cause nausea, vomiting, rashes, pruritus, and liver damage. Interacts with anticoagulants, terfenadine, cisapride, and astemizole. Contraindicated in pregnancy and liver disease.
Fluconazole	<i>Capsules</i>	50–100 mg capsules once daily for 2–3 wk.	Interacts with anticoagulants, terfenadine, cisapride, and astemizole. Contraindicated in pregnancy and liver and renal disease. May cause nausea, diarrhea, headache, rash, liver dysfunction.
Itraconazole	<i>Capsules</i>	100 mg capsules daily taken immediately after meals for 2 wk	Interacts with terfenadine, cisapride, and astemizole. Contraindicated in pregnancy and liver disease. May cause nausea, neuropathy, rash.

Systemic azoles (fluconazole, ketoconazole and itraconazole) may be used for therapy-resistant cases and chronic hyperplastic candidiasis. The azoles are also used in the treatment of secondary oral candidiasis associated with systemic

predisposing factors. Caution must be exercised, however, as these drugs may interact with other medicines and may be hepatotoxic.

Prognosis of oral candidiasis is good when predisposing factors associated with the infection are reduced or eliminated. Persistent chronic hyperplastic candidiasis has been suggested to be associated with an increased risk for malignant transformation.

Geographic Tongue

Definition. The term *geographic tongue* is descriptive in that the foci of desquamation appear as islands and continents in a sea of normal-appearing glossal mucosa. The lesion is also known as benign migratory glossitis.

Etiology. The cause of the disease is unknown. Heredity has been reported, suggesting the involvement of genetic factors in the etiology. It is strongly associated with fissured tongue, but inversely associated with cigarette smoking. In a few patients, emotional stress may enhance the process. Geographic tongue has been associated, coincidentally, with several different conditions including psoriasis, seborrheic dermatitis, Reiter's syndrome and atopy.

Clinical features. Geographic tongue is characterized by periods of exacerbation and remission with different durations over time. The disorder is usually non-symptomatic, but some patients are experiencing a smarting sensation.

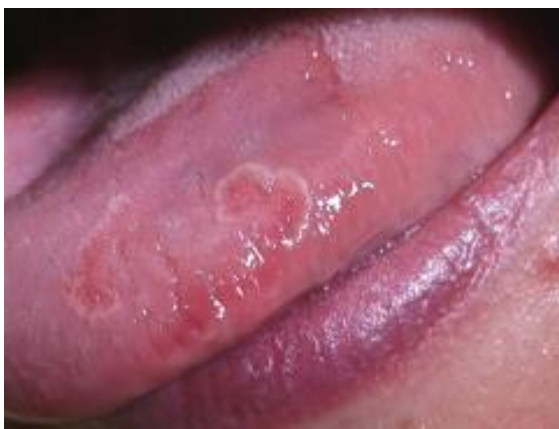

Fig. 15. Geographic tongue

Depending on the activity of the lesion, the clinical appearance may vary from single to multiple lesions occupying the entire dorsum of the tongue. Geographic tongue is circumferentially migrating and leaves an erythematous area behind, reflecting atrophy of the filiform papillae. The typical clinical presentation comprises a white, yellow, or gray slightly elevated peripheral zone (fig. 15). It disappears after some time, and healing of the depapillated and erythematous area starts.

Diagnosis. The clinical features of this mucosal disorder are quite characteristic, and histopathologic confirmation is rarely needed. If biopsy is considered, it should involve the peripheral zone to capture the typical histopathologic features of the lesion. These include parakeratosis, acanthosis, subepithelial inflammation of T lymphocytes, and transepithelial migrating neutrophilic granulocytes.

Differential diagnosis. The clinical features, age, and history of chronicity with a tendency of the lesions to migrate are characteristic. Other diffuse erythemas that may mimic geographic tongue include candidiasis and erosive lichen planus, both of which manifest lesions in extraglossal mucosa.

Treatment. As the etiology is unknown, no causal treatment strategy is available. Symptoms are rarely present, and the management is confined to proper information about the benign character of the disorder. When symptoms are reported, topical anesthetics may be used to obtain temporary relief. Other suggested treatment strategies include antihistamines, anxiolytic drugs, or steroids, but none of these has been systematically evaluated.

SECONDARY SYPHILIS

Definition. Nearly one-third of the patients with secondary syphilis may have oral lesions. Mucous patches are the most common lesion found on the oral mucosa.

Etiology. Oral lesions in secondary syphilis is the result of blood-borne spread of *Treponema pallidum*. A history of promiscuous sexual activity can usually be obtained, although some patients may deny such activities.

Clinical features. Mucous patches are smooth-surfaced plaques that manifest a glistening, opalescent character and are seen 6 to 8 weeks after formation of the chancre. These are usually distributed over the tonsils, soft palate, tongue and cheek (fig. 16). The grayish surface of the lesions is easily removable and contains numerous spirochetes. Therefore, the lesions themselves are infectious. Coalescence of these lesions lead to serpiginous lesions termed as 'snail tract ulcers'. Regional lymph node enlargement is a common feature and they tend to have a rubbery consistency. In addition to the mucous patches, condyloma latum at the commissure and a maculopapular rash may be present.

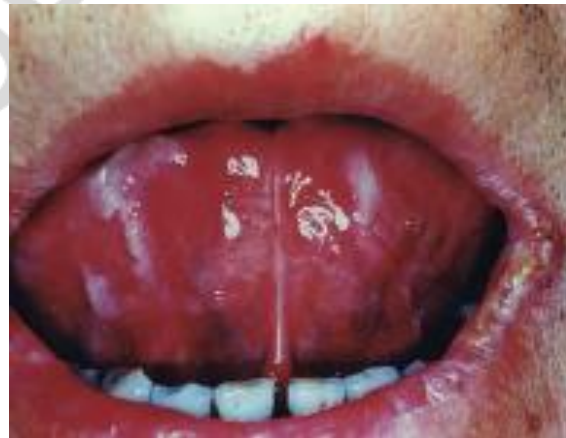

Fig. 16. Mucous patches of secondary syphilis

Diagnosis. Clinically, syphilis is said to be a great imitator because of its resemblance to many other unrelated conditions. An adequate history should elicit suspicion of syphilis, and the diagnosis should be confirmed by laboratory tests. Serologic tests for antibodies to *T. pallidum* are most widely used.

Differential diagnosis. Mucous patches may resemble a variety of white lesions of the oral cavity; because they are highly infectious, the clinician should

always be aware of the fact that oral white lesions may be luetic. The primary considerations in the clinical differential diagnosis include candidiasis, plaque-form lichen planus, or leukoplakia of one type or another.

Treatment. The drug for treatment of all stages of syphilis is penicillin. The patient can be referred to a dermatologist or general physician for treatment.

BIBLIOGRAPHY

1. *Казеко, Л. А.* Диагностика в терапевтической стоматологии = Diagnostic procedures in therapeutic dentistry : учеб.-метод. пособие / Л. А. Казеко, Е. Л. Колб. Минск : БГМУ, 2016. 51 с.
2. *Glick, M.* Burket's Oral Medicine / M. Glick, W. M. Feagans. 12th ed. Shelton, CT: People's Medical Publishing House-USA, 2015. 716 p.
3. *Eversole, L. R.* Clinical Outline of Oral Pathology: Diagnosis and Treatment / L. R. Eversole. 4th ed. Shelton, CT : People's Medical Publishing House-USA, 2011. 738 p.
4. *Warnakulasuriya, S.* Oral Medicine and Pathology : A Guide to Diagnosis and Management / S. Warnakulasuriya, W. M. Tilakarante. 1st ed. New Delhi : Jaypee Brothers Medical Publishers, 2014. 563 p.
5. *Regezi, J. A.* Oral Pathology : Clinical Pathologic Correlations / J. A. Regezi, J. J. Sciubba, R. C. K. Jordan. 7th ed. Elsevier, 2017. 473 p.

CONTENTS

Motivational characteristic of the theme	3
White Lesions	4
Focal (frictional) hyperkeratosis	5
Leukoplakia	6
Leukoedema	7
Nicotinic Stomatitis	8
Oral Lichen Planus	9
Oral Candidiasis	13
Geographic Tongue	16
Secondary syphilis	17
Bibliography	18

Учебное издание

Полянская Лариса Николаевна
Захарова Ирина Анатольевна

**БЕЛЫЕ ПОРАЖЕНИЯ СЛИЗИСТОЙ ОБОЛОЧКИ
ПОЛОСТИ РТА
WHITE LESIONS OF ORAL MUCOSA**

Учебно-методическое пособие
На английском языке

Ответственная за выпуск Т. Н. Манак
Переводчик Л. Н. Полянская
Компьютерная вёрстка А. В. Янушкевич

Подписано в печать 03.04.19. Формат 60×84/16. Бумага писчая «Хероx office».
Ризография. Гарнитура «Times».
Усл. печ. л. 1,16. Уч.-изд. л. 0,99. Тираж 80 экз. Заказ 198.

Издатель и полиграфическое исполнение: учреждение образования
«Белорусский государственный медицинский университет».
Свидетельство о государственной регистрации издателя, изготовителя,
распространителя печатных изданий № 1/187 от 18.02.2014.
Ул. Ленинградская, 6, 220006, Минск.

ISBN 978-985-21-0271-1



9 789852 102711

УЗІТОРІЙ БГМУ