

МИНИСТЕРСТВО ЗДРАВООХРАНЕНИЯ РЕСПУБЛИКИ БЕЛАРУСЬ  
БЕЛОРУССКИЙ ГОСУДАРСТВЕННЫЙ МЕДИЦИНСКИЙ УНИВЕРСИТЕТ  
КАФЕДРА ПРОПЕДВТИКИ ВНУТРЕННИХ БОЛЕЗНЕЙ

**М. В. Шолкова, Э. А. Доценко, И. И. Бураков**

**ПРАКТИЧЕСКИЕ НАВЫКИ  
ПО ОБСЛЕДОВАНИЮ ОРГАНОВ  
ЖЕЛУДОЧНО-КИШЕЧНОГО ТРАКТА**

**MANUAL IN GASTROINTESTINAL  
SYSTEM EXAMINATION**

Учебно-методическое пособие



Минск БГМУ 2019

УДК 616.33/.34-07(075.8)-054.6  
ББК 54.1я73  
Ш78

Рекомендовано Научно-методическим советом университета в качестве учебно-методического пособия 20.02.2019 г., протокол № 6

Рецензенты: канд. мед. наук, доц. каф. терапии Белорусской медицинской академии последипломного образования И. И. Семененков; каф. пропедевтики внутренних болезней Витебского государственного ордена Дружбы народов медицинского университета

**Шолкова, М. В.**

Ш78 Практические навыки по обследованию органов желудочно-кишечного тракта = Manual in Gastrointestinal System Examination : учебно-методическое пособие / М. В. Шолкова, Э. А. Доценко, И. И. Бураков. – Минск : БГМУ, 2019. – 40 с.

ISBN 978-985-21-0267-4.

В сжатой форме представлены информационные блоки и практические навыки, необходимые для клинического обследования органов желудочно-кишечного тракта.

Предназначено для студентов 2–3-го курсов медицинского факультета иностранных учащихся, обучающихся на английском языке по специальности «Лечебное дело».

УДК 616.33/.34-07(075.8)-054.6  
ББК 54.1я73

ISBN 978-985-21-0267-4

© М. В. Шолкова, Э. А. Доценко, И. И. Бураков, 2019  
© УО «Белорусский государственный медицинский университет», 2019

## EXPLANATORY NOTE

According to the curriculum of higher educational institution in the educational discipline «Propedeutics of Internal Diseases» for the specialty 1-79 01 01 «Internal Medicine», approved 14.07.2015, Reg. NoУД-L 399a/1415/p, the teaching of general semiotics precedes the teaching of the diseases. To unify the knowledge of the propedeutics of internal diseases, the manual presents theoretical issues and practical skills on the gastrointestinal diseases semiotics according to the course plan of practical training curriculum.

Diseases of the gastrointestinal tract have a variety of symptoms. Students should have a clear understanding of complaints and objective signs of a disease, be able to identify symptoms and determine the characteristics of the affected organs.

### CHAPTER 1 SUBJECTIVE AND OBJECTIVE EXAMINATION METHODS OF THE PATIENTS WITH STOMACH AND BOWEL DISEASES

#### SUBJECTIVE EXAMINATION

Complaints of patients in case of esophagus diseases are:

- *Dysphagia*, i. e. difficult passage of food via the esophagus.
- *Odynophagia*, i. e. pain on swallowing
- *Esophageal pain*, i. e. pain in the center of the chest, sometimes also described as a pain behind the breastbone.
- *Esophageal vomiting* occurs without nausea and is preceded by a feeling of food retained behind the sternum; the vomitus includes unaltered (non-digested) food.
- *Regurgitation*, i. e. return of the swallowed food or wind into the mouth.
- *Hypersalivation*, i. e. excessive salivation.
- *Heartburn*, i. e. a specific burning sensation behind the sternum associated with regurgitation of gastric contents into the inferior portion of the esophagus. It can be a burning pain in the epigastric and retrosternal region.

**Complaints of patients in case of stomach and duodenum diseases are:**

*Appetite disorders* (loss of appetite, abnormal appetite, aversion to meat, perverted taste: abnormal taste changes, for example, all food seems bitter). Poor appetite or its complete absence (anorexia) is usually characteristic of gastric cancer. Appetite often increases in peptic ulcer, especially in duodenal ulcer. *Sitophobia* is a condition when the patient refuses to eat food for fear of pain.

- *Regurgitation*. Acid regurgitation is usually associated with hypersecretion of gastric juice. Bitter regurgitation occurs when bile goes up into esophagus and oral cavity.
- *Heartburn* (see above).

- *Nausea*, i. e. an indefinite feeling of sickness and sensation of compression in the epigastrium.
- *Vomiting*, i. e. a reflex act of forcible ejection of the stomach contents through the mouth (Fig. 1).
- *Epigastric pain* (see below).
- Feeling of overfilled stomach after meals.
- *Hematemesis* (vomiting of blood).



Fig. 1. Vomiting  
(<https://www.canstockphoto.com>)

Vomiting can be divided into 4 types (according to the reasons):

1. *Nervous (central) vomiting* isn't usually associated with any nausea, or gastrointestinal diseases; the main reason is brain vomiting center irritation due to stroke, brain damage or inflammation.
2. *Visceral vomiting* in case of internal diseases (gastritis, stomach or duodenum ulcer, intestinal inflammatory process, hepatitis, pancreatitis etc.).
3. *Hematogenic and toxic vomiting* (different toxins are in the blood).
4. *Esophageal vomiting* can result from gullet (esophagus) tumor, stricture (narrowing) or achalasia. Dilated esophagus could not transport the food to the stomach. This vomiting starts immediately after a meal, without any nausea, and contains a small amount of undigested food.

In case of some pain a patient should be asked to describe it. The doctor should assess pain.

- Location (Where is the pain located? Ask the patient «point» with a finger to where it hurts»).
- Type (What does it feel like? Describe the pain — is it sharp, throbbing, dull, aching, stabbing, burning?).
- Radiation («Does the pain stay there or spread anywhere? Show me where it goes with your finger»).
- Severity (none, moderate, severe, or excruciating).

– Duration («When did this pain start?») Acute pain is usually sudden, chronic pain may exist for months or years).

– Influencing factors (What makes the pain subside? What makes the pain increase? Are you taking any medications for the pain?).

Epigastric pain is usually related to the food intake. In case of stomach diseases a patient usually feels *early pain* (occurring 30–40 min after meals). If a patient has some duodenum diseases, e. g. duodenum ulcer, he/she can have *delayed pain* (90–120 min after meals), *nocturnal pain* (a patient awakes at night due to the pain) or *hunger pain* (which disappears after eating).

**Patient's complaints in case of intestinal diseases:**

- Abdominal pain;
- Meteorism (flatulence), i. e. the inflation of the abdomen;
- Motor dysfunction of the intestine (constipation and diarrhea);
- Intestinal hemorrhage.

Peculiarities of intestinal abdominal pain:

1. This pain can be in different abdominal parts depending on the affected part of intestine.

2. It isn't related to meals.

3. It has close relation to defecation: pain occurs before, during, and (rarely) after defecation.

4. The pain subsides after defecation or passage of flatus.

Human feces is called a stool. It is the waste residue of indigestible materials of the digestive tract expelled through the anus during defecation. Normal stool ranges from two times a day to three times a week. It is less than 200 g per day, yellowish brown color.

*Diarrhea* is defined as an increase in frequency (more than 2 times a day), fluidity, and volume of defecation (Fig. 2). Mechanisms of diarrhea are:

- accelerated intestine movement
- intestine absorption disorders
- inflammation of the intestine

*Constipation* is generally described as having fewer than 2 *defecation* a week. The stool is often hard and dry. Constipation can be divided into two main variants:

– *Organic constipation*. It is associated with mechanical obstruction, such as narrowing of the intestinal lumen due to a tumor, scar, adhesion, etc.

– *Functional constipation* isn't associated with mechanical obstruction of intestine. It is caused by some functional disorders (low level of intestinal contraction, muscular spasm, dehydration, etc.).



Fig. 2. Diarrhea  
(<http://worldartsme.com>)

## VISUAL EXAMINATION

Specific features of patients in diseases of digestive system (visible on general examination) are:

- *Cachexia* or wasting syndrome, which is loss of weight, muscle atrophy, fatigue, weakness, and significant loss of appetite (Fig. 3).
- *Edema* (possible loss of protein due to poor absorption).
- Skin can be *dry and pale* (in case of anemia due to gastric and intestinal hemorrhage or poor absorption of nutrients).

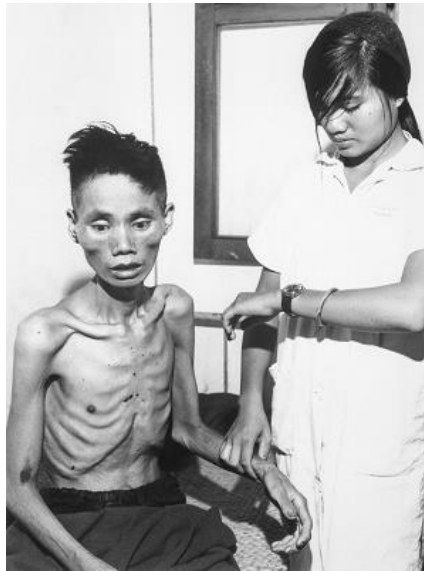

Fig. 3. Cachexia  
(<https://study.com>)

### «*Facies Hippocratica*» or «*Hippocrates Face*»

This face is characterized by sunken eyes, sharp nose, deadly livid and cyanotic skin, which is sometimes covered with large drops of cold sweat. «Hippocrates Face» is associated with collapse in severe diseases of the abdominal organs and indicates approaching death (Fig. 4).

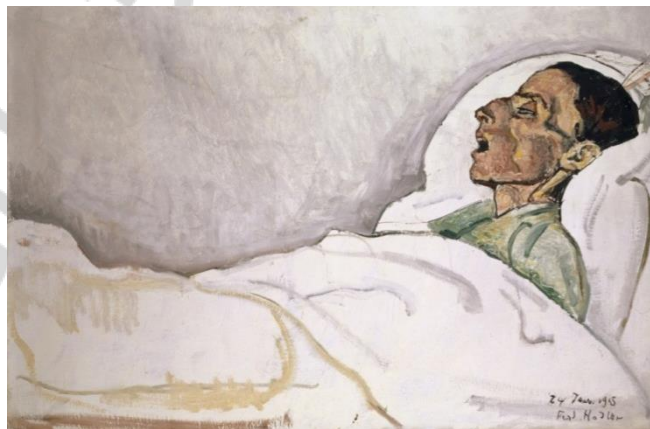
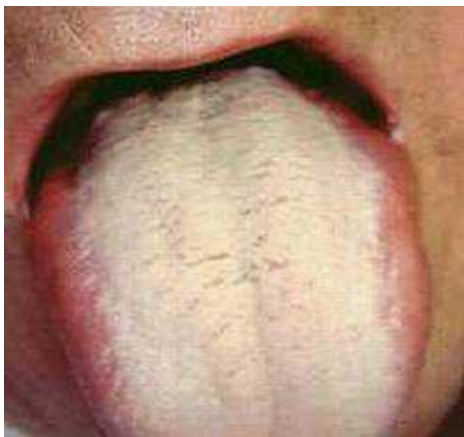

Fig. 4. Ferdinand Hodler: Valentine Godé-Darel Agony  
(Fine Arts Museum (Kunstmuseum), Basel, Switzerland) (<https://artchive.ru>)

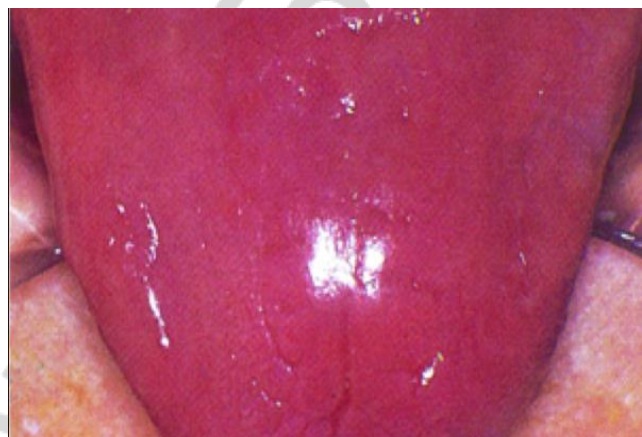## TONGUE INSPECTION

Tongue inspection:

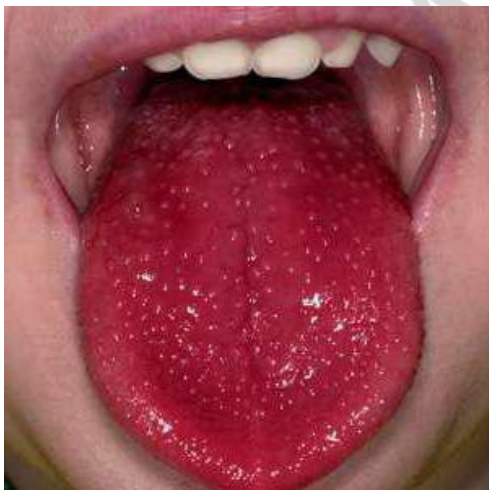1. The tongue coated with a white-grey material is characteristic of gastritis or other gastrointestinal diseases (Fig. 5).
2. A dry tongue indicates a severe abdominal pathology or acute pancreatitis.
3. A tongue with atrophied papillae suggests cancer of the stomach, atrophic gastritis, or lack of vitamins (Fig. 6).
4. The tongue in case of intestinal diseases often becomes crimson in vitamin PP deficiency (pellagra), its papillae are smoothed (Fig. 7).
5. Aphtha is a small ulcer occurring in groups in the mouth or on the tongue, an open sore in the mouth (Fig. 8).



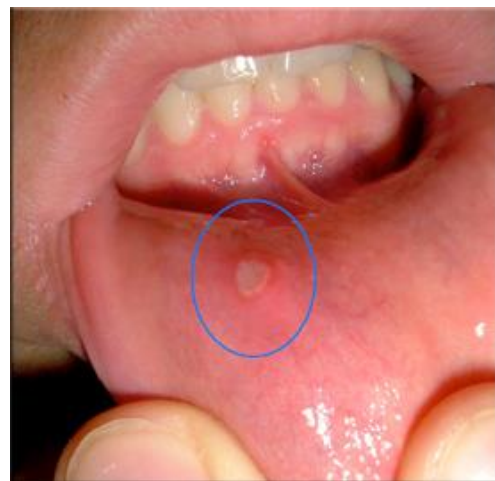
*Fig. 5. Coated tongue*  
(<http://zdravotvet.ru>)



*Fig. 6. Tongue with atrophied papillae*  
(<https://stomaget.ru>)



*Fig. 7. Crimson tongue*  
(<http://fb.ru>)



*Fig. 8. Aphtha*  
(<https://en.wikipedia.org>)



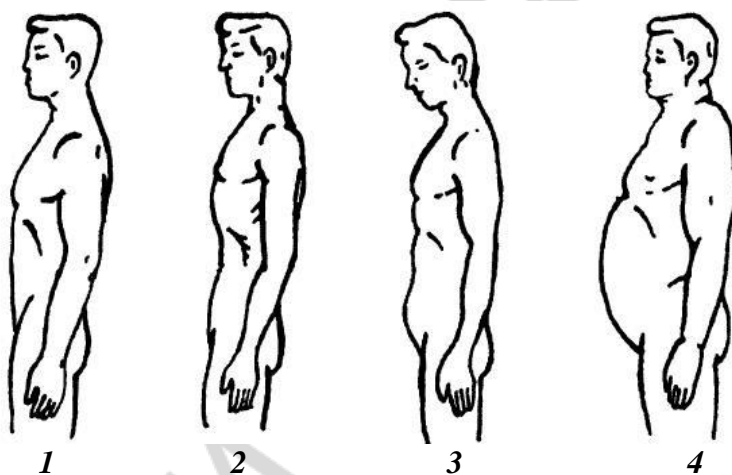
## CHAPTER 2 ABDOMEN EXAMINATION

Abdomen examination includes: 1) inspection 2) palpation 3) percussion 4) auscultation. For a good abdominal examination, you need the following conditions:

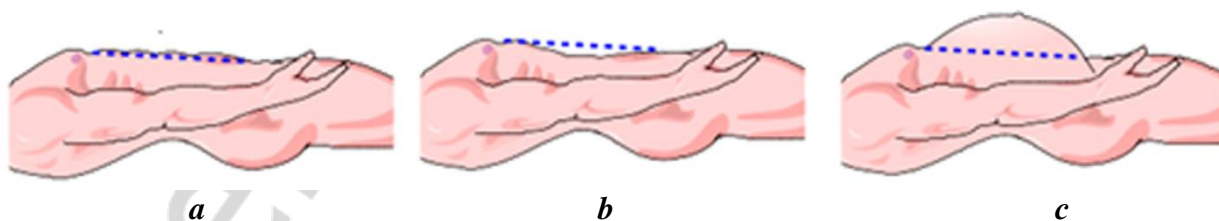
- short nails;
- warm hands;
- good light;
- a relaxed patient;
- full exposure of the abdomen from above the xiphoid process to the symphysis pubis. The groin should be visible; the genitalia should remain draped.

### ABDOMEN INSPECTION

Inspection of the abdomen should be done on the patient in the vertical and horizontal position (Fig. 9–10).



*Fig. 9. Abdomen shapes in vertical position:*  
1 — normal, 2 — drawn in, 3 — low, 4 — enlarged  
(<https://dyagnoz.ru>)



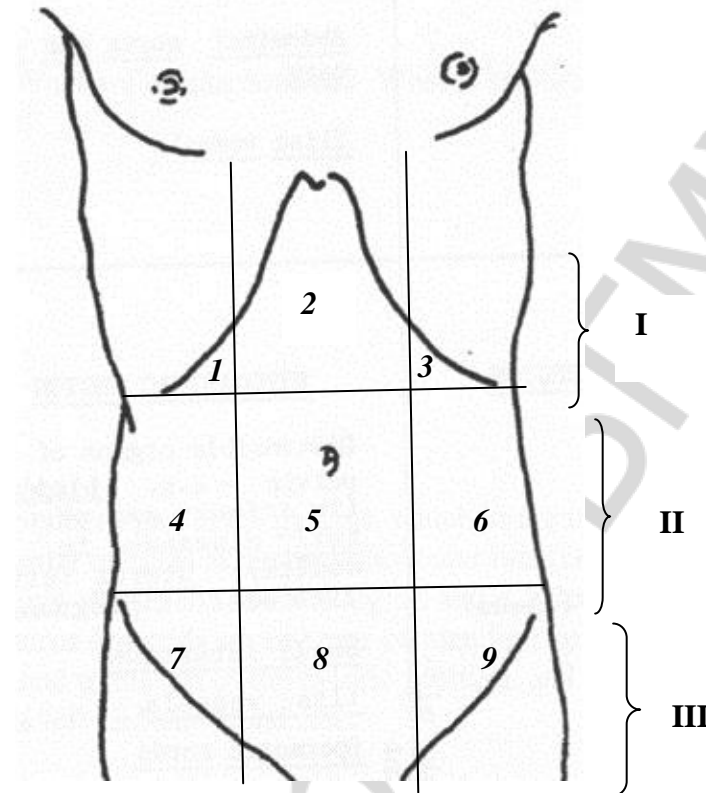
*Fig. 10. Abdomen shapes in horizontal position:*  
a — flat; b — scaphoid; c — distended  
(<http://ktthebest4u.blogspot.com>)

Abdomen inspection includes:

- estimation the abdomen shape and size;



- observation for abdominal movements associated with respiration, peristalsis, aortic pulsation;
- comparison of two abdomen sides (symmetry) in each region (Fig. 11).



*Fig. 11. Abdominal regions:*

I regions — epigastric section:

1 — right subcostal (hypochondriac) region; 2 — subxyphoid (epigastric in narrow sense) region; 3 — left subcostal (hypochondriac) region.

II regions — mesogastric section:

4 — right flank (lumbar) region; 5 — umbilical region; 6 — left flank (lumbar) region.

III regions — hypogastric section:

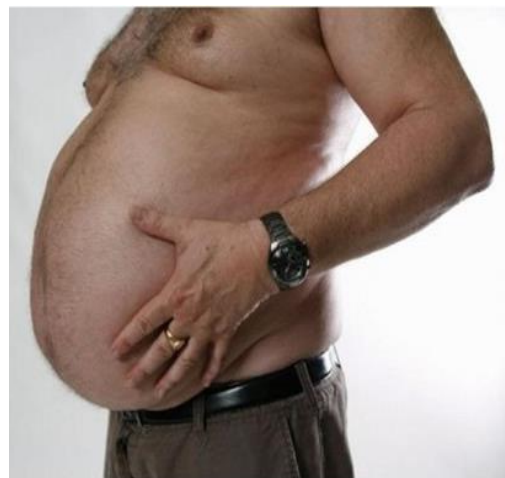7 — right inguinal (iliac) region; 8 — suprapubic region; 9 — left inguinal (iliac) region.

The most common causes of abdomen enlargement (except pregnancy) are the following (Fig. 12):

- accumulation of fat (obesity);
- accumulation of liquid (ascites);
- accumulation of gas (meteorism, flatulence).

Obesity has the following signs:

- navel (umbilicus) is retracted;
- when the patient lies on his back, abdomen is a little flattened;
- percussion gives a dull sound.



*Fig. 12. Abdomen enlargement (obesity) (https://sovdok.ru)*

Ascites has the following signs (Fig. 13):

- when the patient lies on his back, his abdomen is flat («frog belly»);
- ascites makes navel convex;
- percussion (Fig. 14) gives a dull note in lower areas of the abdomen, this dullness changes after changing the patient's position (Fig. 15).

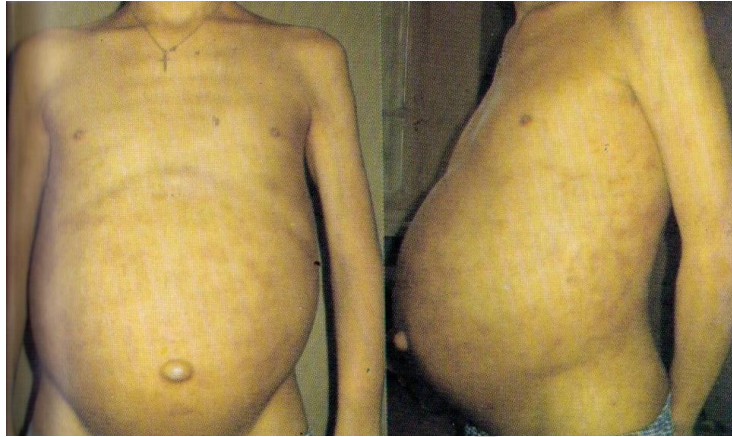

Fig. 13. Ascites

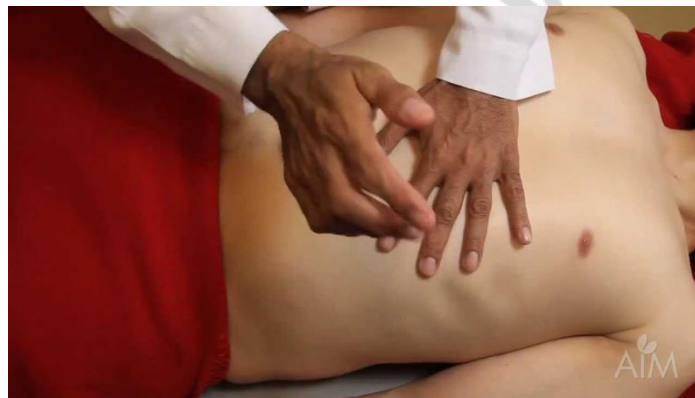

Fig. 14. Abdominal percussion  
(<https://www.youtube.com>)

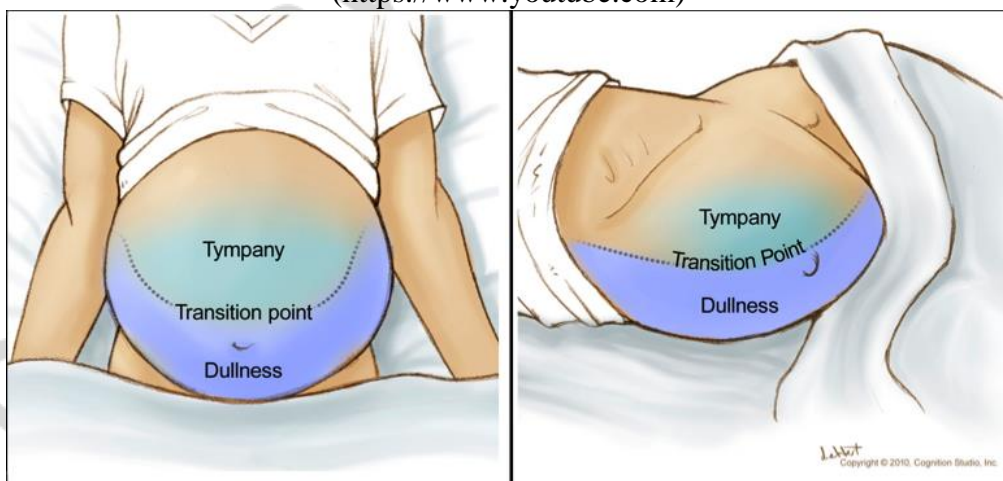


Fig. 15. The dullness changes after changing patient's position  
(<https://www.hepatitisc.uw.edu>)

Flatulence:

- flatulence makes abdomen bulge, in the supine position it does not change.
- percussion gives a tympanic sound.

### PERCUSSION

**Percussion** is the act of tapping the body surface to elicit sounds that can be heard. It is used to guess the size, borders, and texture of some organs (Fig. 14).

### AUSCULTATION

**Auscultation** is listening to sounds produced by the body. Auscultation of the abdomen has certain rules:

- use a stethoscope's diaphragm
- place it at 4 abdomen quadrants
- listen for active bowel sounds – irregular gurgling sound occurring every 5–20 sec.

During auscultation of the abdomen, in addition to intestinal motility, you can listen to other sounds (Fig. 16).

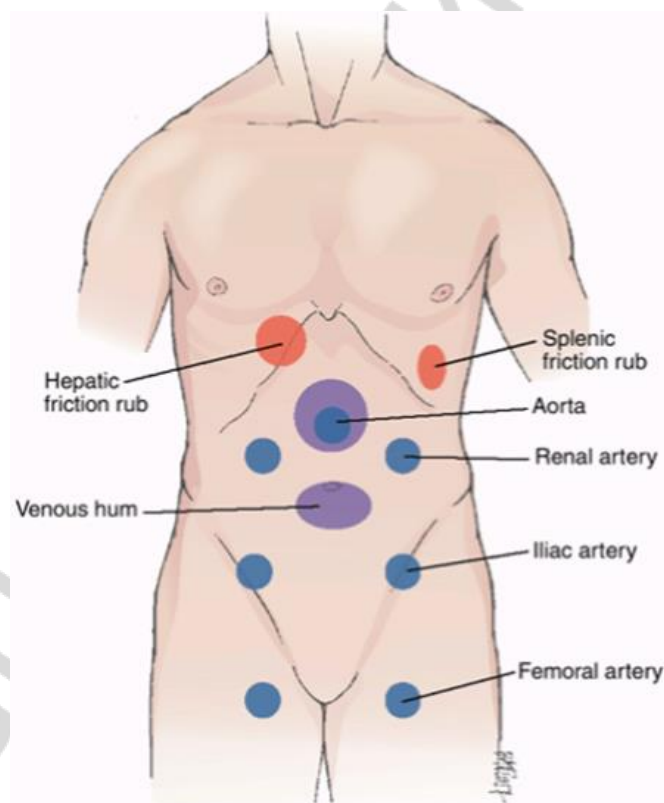


Fig. 16. Possible sounds on the abdominal auscultation (<http://ktthebest4u.blogspot.com>)

## CHAPTER 3 ABDOMEN PALPATION

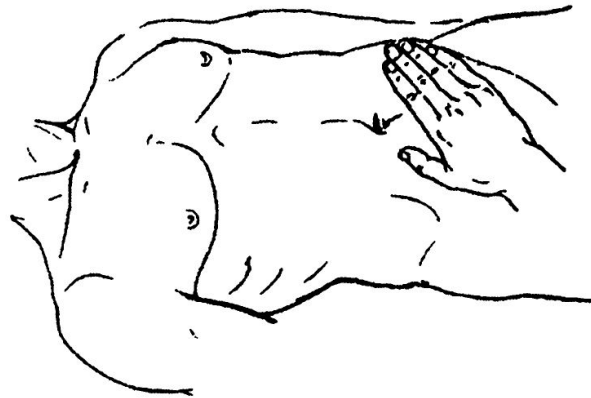
**Palpation** is the examination of the body using the sense of touch. The sense of touch is used to assess organ texture, temperature, moisture, location, size, pulsation, tenderness or pain.

Palpation Rules:

- The patient should have an empty bladder.
- The patient should be relaxed in his bed in a supine position.
- Have the patient keep arms at the sides or folded across the chest. Often patients raise their arms over their heads, but this stretches and tightens the abdominal wall, making palpation difficult.
- Before you begin palpation, ask the patient to point to any areas of pain and examine these areas last.
- Approach slowly and avoid quick unexpected movements. Watch the patient's face closely for any signs of pain or discomfort.
- Distract the patient if necessary with conversation or questions.

### SURFACE PALPATION

**Surface** (light) **palpation** is used to assess the anterior abdominal wall (pain, rigidity) (Fig. 17). **Deep palpation** is used to examine abdominal organs, to determine their structure (size, shape, consistency, mobility).



*Fig. 17.* Hand position for the beginning of surface palpation  
([https:// www.med24info.com/](https://www.med24info.com/))

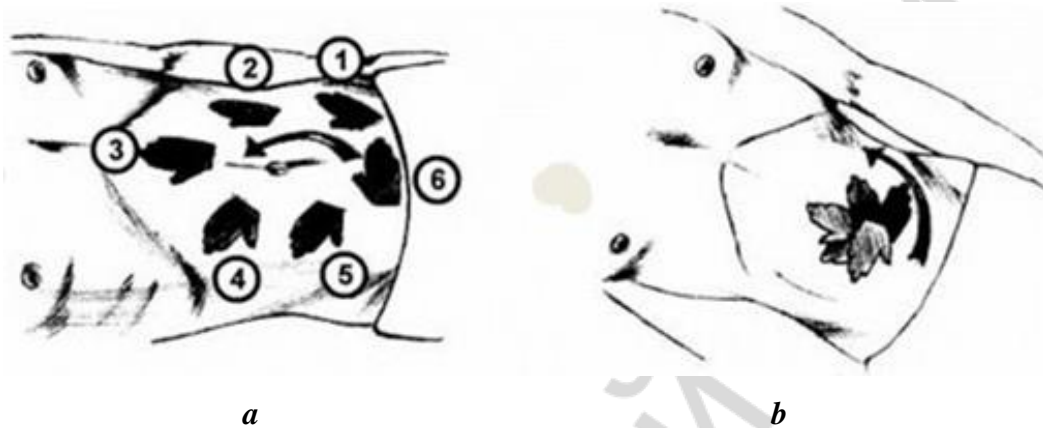
Surface palpation has 3 parts:

1. Tentative palpation;
2. Comparative palpation;
3. White line (Linea Alba) palpation.

Tentative palpation (Fig. 18):

- Place right hand flat on the abdomen of the patient to examine it carefully and gradually without trying to penetrate the deep parts of the abdomen.

- Palpation direction is counterclockwise.
- Start in the left inguinal area,
- continue on the left flank in an upward direction up to the left hypochondrium;
  - then the epigastric area;
  - the right hypochondrium;
  - the right flank in a downward direction to the right inguinal area.




*Fig. 18.* Steps of the surface tentative palpation:  
*a* — palpation order; *b* — hand position  
 (<http://www.med24info.com>)

#### Comparative Palpation:

- Touch symmetrical areas of the abdomen on the left and right sides from inguinal area up to the epigastric region.
- Check the resistance of the abdominal wall in the symmetric areas.

#### Palpation of the White line (Linea Alba) (Fig. 19):

- place the right arm in the epigastric area to palpate the median line from a xiphoid process down to the suprapubic area,
- ask your patient to raise his head,
- check the presence of hernias or muscle divergence.



*Fig. 19.* Possible methods of White Line palpation:  
*a* — palpation by the edge of the palm; *b* — palpation by fingertips  
 (<http://www.med24info.com>)



During superficial palpation of the abdomen, it is necessary to check the symptom of peritoneal irritation (Shchetkin-Blumberg symptom, *rebound tenderness*). This is the test for peritoneal inflammation (irritation). Local pressure causes strong pain but it becomes more severe when the pressure is released.

- Press deeply and slowly on the abdomen.

- Quickly release pressure.

If the patient feels pain when the pressure disappears (when the arm is taken away), the symptom is positive (Fig. 20).

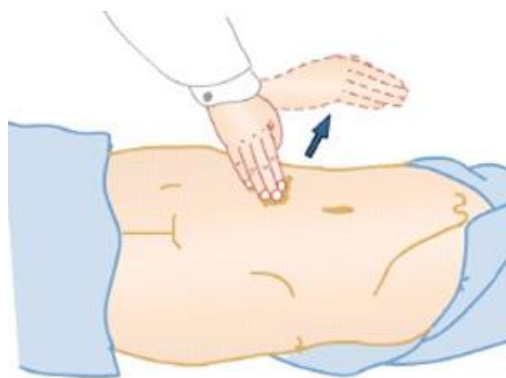

Fig. 20. Shchetkin-Blumberg symptom, rebound tenderness

(<http://cnhealthexperts.com>)

### DEEP PALPATION

**Deep palpation** (*the deep sliding methodical topographic palpation according to Obraztsov and Strazhesko*) is performed in the following order:

- the left ileum and flank area — the sigmoid and the descending colon;
- the right and flank ileum area — the cecum and the ascending colon;
- the epigastric and umbilical regions — the stomach and the transverse colon;
- the liver, the spleen and kidneys.

Deep palpation allows the physician to evaluate the characteristics of the organs (Tab. 1).

Table 1

#### Characteristics of organs

Location	Region of the abdomen
Size	Length and width in cm
Shape	Oval, round, elongated, irregular
Consistency	Soft, firm, hard
Surface	Smooth, nodular
Mobility	Fixed/mobile
Pulsatility	Present/absent
Tenderness (pain)	Degree of tenderness to palpation
Sounds (gurgling)	Present/absent

Deep palpation is performed only after the surface palpation. Conditions required for deep palpation are:

- muscle relaxation
- patient's deep breathing
- fingers are placed together and slightly flexed
- fingers are moved with patient's **expirations!!!**

#### Four Steps of Deep Palpation:

1. Place your hand on the abdominal wall parallel to the axis of the examined organ (Fig. 21).
2. Form a skin fold.
3. Move the hand inward the abdomen. Move your fingers gradually with each expiration deeper into the abdomen when the abdominal wall is relaxed.
4. Perform a sliding movement with your fingertips in the direction perpendicular to the transverse axis of the examined organ.

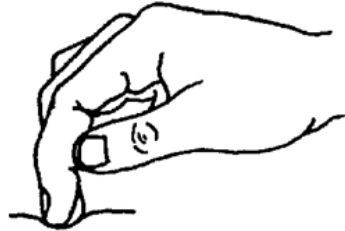

Fig. 21. Fingers position at the beginning of deep palpation

**Sigmoid colon palpation** (Fig. 22). Normally the sigmoid colon is palpable in 90% of cases. Only severe obesity or bloating, strong abdominals, or ascites do not allow palpating this part of intestine.

- It is palpable as a smooth firm cylinder.
- It has diameter of a thumb or an index finger (2–3 cm).
- It is painless to palpation.
- It does not produce gurgling sounds.
- It can be displaced 3–5 cm to either side.

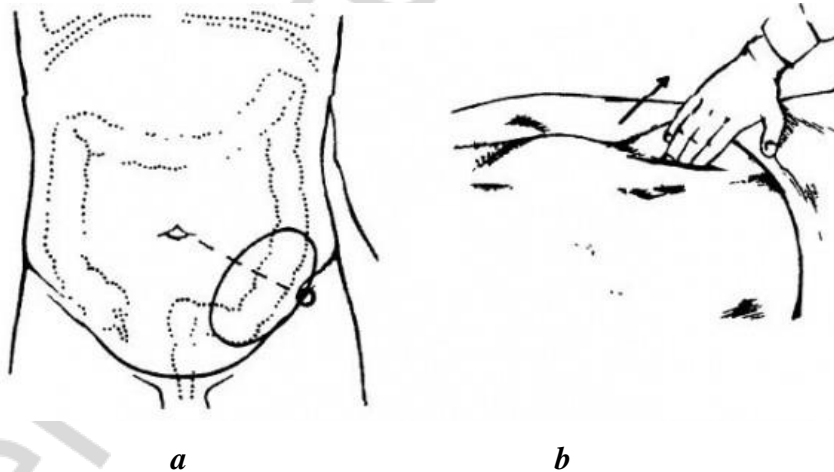


Fig. 22. Sigmoid colon palpation:

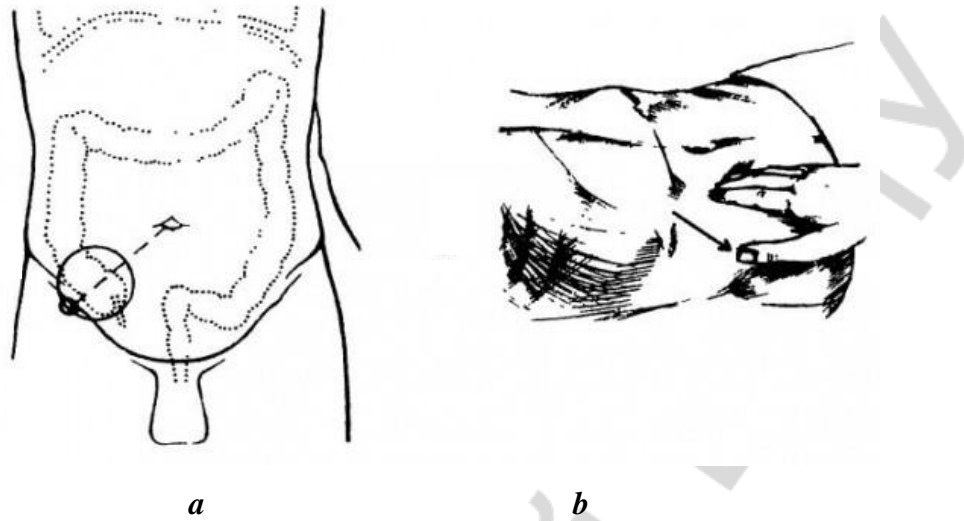
*a* — sigmoid colon location; *b* — direction of sliding movement  
(<https://dyagnoz.ru>)

#### **Cecum Palpation** (Fig. 23):

- A normal cecum is palpable in approximately 80% of healthy people.
- It is palpable as a softer cylinder 2–3 cm in diameter.



- When pressed upon, it gurgles.
- It is painless.
- It can be displaced 2–3 cm to either side.



*Fig. 23. Cecum Palpation:*  
*a* — cecum location; *b* — direction of sliding movement  
 (<https://dyagnoz.ru>)

**Inferior border of the stomach** (greater curvature) can be found in three ways:

- succussion (splashing sound, shaking);
- stethacoustic palpation;
- deep palpation.

Succussion is a method of determining the boundaries of the stomach by eliciting a splash sound (Fig. 24). This method is possible in the presence of water and air in the stomach. If the test fails, the patient is asked to drink 1-2 glasses of warm water. The doctor presses upon the epigastrium below the xiphoid process with his left hand. Then, the doctor makes light jerks along the abdominal wall with his right hand from the hepatic dullness to the lower edge of the stomach. The moment of disappearance of the splash sound will correspond to the lower border of the stomach.

Stethacoustic palpation is the method of determining the stomach size using auscultation in combination with friction on the surface of the abdominal wall. The stethoscope is placed on the skin of the abdomen under the xiphoid process. The doctor using the index finger of the right hand makes a sliding movement on the surface of the abdominal wall (Fig. 25). If the finger is over the stomach, the doctor hears a rustle through the stethoscope. When the finger goes beyond the border of the stomach, rustling disappears.




Fig. 24. Succussion (splashing sound)  
(<https://dyagnoz.ru>)




Fig. 25. Stethacoustic palpation

### **Transverse colon palpation:**

- bimanual palpation (use both hands) (Fig. 26);
- 2–3 cm below the lower stomach border.

Both hands with bent fingers are laid on the anterior abdominal wall 2–3 cm below the inferior border of the stomach on both sides of the midline. More often it is 2–3 cm above the navel.

Normally, transverse colon is:

- a cylinder of moderate density (2–2,5 cm diameter);
- easily movable up and down;
- painless;
- silent (without gurgling).

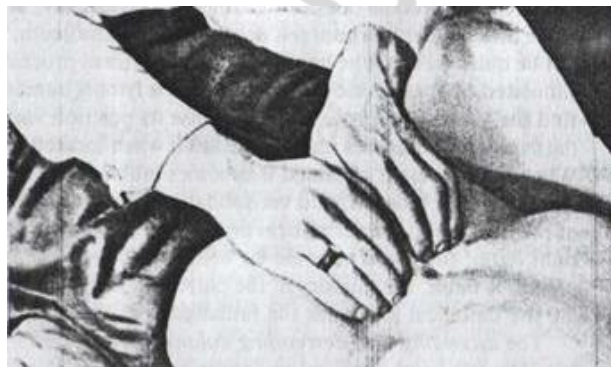

Fig. 26. Bimanual palpation of transverse colon  
(<https://studfiles.net>)

## **CHAPTER 4**

### **MAJOR CLINICAL SYNDROMES OF GASTROINTESTINAL DISEASES**

Syndromes of gastrointestinal diseases are:

1. Constipation.
2. Diarrhea.
3. Syndrome of inadequate absorption (maldigestion and malabsorbtion).
4. Gastrointestinal bleeding syndrome.

## CONSTIPATION

*Constipation* is a difficult or infrequent passage of feces (3 times a week or less) with hardness of stool and feeling of incomplete evacuation. Other symptoms include:

- straining, hard stools;
- non-productive calls (impulses);
- infrequent stools, or incomplete evacuation;
- < 3 bowel movements (defecations) per week;
- daily stool weight < 35g/day.

Constipation can be acute or chronic, functional or organic.

## DIARRHEA

*Diarrhea* is the passage of 3 or more loose or liquid stools per day, or more frequently than is normal for the individual. It is usually a symptom of gastrointestinal infection, which can be caused by a variety of bacterial, viral and parasitic organisms.

- $\geq 3$  times a day;
- increased weight (>200 g/day).

Mechanisms of Diarrhea:

1. Accelerated movement the intestine
2. Intestine absorption disorders (retention of water within the lumen)
3. Excessive secretion of water and electrolytes into the intestinal lumen
4. Inflammation of the intestine (exudation of fluid and protein from the intestinal mucosa)

*Osmotic Diarrhea* occurs when poorly absorbable solutes remain in the bowel, where they retain water. Possible reasons include sugar intolerance (for example, lactose intolerance, use of poorly absorbed salts (Magnesium sulfate, Sodium phosphates) as laxatives or antacids.

*Secretory Diarrhea* occurs when the intestine secretes more electrolytes and water than it absorbs. Possible reasons include bacterial toxins, viruses, unabsorbed dietary fat, drugs and hormones.

Acute diarrhea lasts longer than 3–4 days, chronic diarrhea — lasts longer than 2 weeks.

Symptoms and signs of diarrhea:

- Stool:
  - ✓ Loose;
  - ✓ Bloody;
  - ✓ Bad smell;
  - ✓ Steatorrhea (oily, floating, difficult to flush).
- Sudden onset of bowel frequency.
- Crampy abdominal pain.

- Urgency.
- Loss of appetite.
- Loss of weight.
- Sunken eyes.
- Decreased skin turgor (Fig. 27).
- Dry mouth or tongue.
- Thirst.

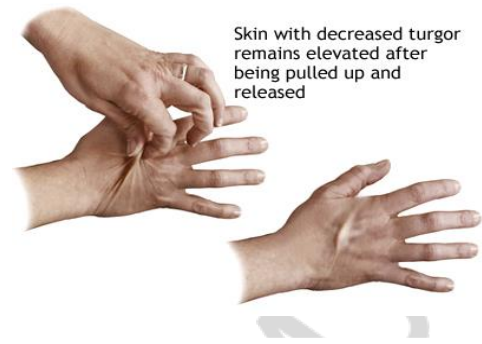

Fig. 27. Decreased skin turgor  
(<https://medlineplus.gov>)

### SYNDROME OF INADEQUATE ABSORPTION

*Syndrome of inadequate absorption (maldigestion and malabsorption):*

- *Maldigestion* is the impaired breakdown of nutrients (carbohydrates, protein, fat) to absorbable split-products (mono-, di-, or oligosaccharides; amino acids; fatty acids; monoglycerides);
- *Malabsorption* is the defective mucosal uptake and transport of adequately digested nutrients including vitamins and trace elements.

Clinical signs of maldigestion are the following:

- Weight loss;
- Diarrhea, steatorrhea;
- Flatulence (meteorism);
- Abdominal pain.

Clinical signs of malabsorption are the deficiency of vitamins, minerals, proteins:

- Glossitis, cheilosis, stomatitis (in case of iron, vitamin B12, folate, vitamin A deficiency);
- Bone pain (in case of calcium, vitamin D deficiency);
- Bleeding (in case of vitamin K deficiency);
- Vision dysfunction (in case of vitamin A deficiency);
- Amenorrhea, decreased libido (in case of proteins, vitamin E deficiency);
- Edema (hypoalbuminemia);
- Anemia (deficiency of iron, vitamin B12, folate, proteins).

### GASTROINTESTINAL BLEEDING SYNDROME

Gastrointestinal bleeding (*hemorrhage*) is a common syndrome.

Patient's complaints in case of gastric bleeding are:

- Vomiting of bright-red blood (hematemesis).
- Vomitus looks like coffee grounds.
- Black tarry stools (*melena*).
- Weakness, dizziness, syncope.

The differences between gastric and pulmonary bleeding are presented in the table 2.

Table 2

**Differences in gastrointestinal and pulmonary bleeding**

<b>Gastrointestinal bleeding</b>	<b>Pulmonary bleeding</b>
blood comes out with vomiting	blood comes out with a cough
dark blood	bright blood
blood may contain food	blood contains foam
blood pH<7	blood pH>7

In the case of intestinal bleeding, vomiting is rare. The blood changes the color of the stool: it can have a red-brown color; when bleeding is from the large intestine, unchanged blood can be visible in the stool.

On examination, the patient's skin is pale, the blood pressure is low, the pulse is frequent (tachycardia), and weak. When evaluating a blood test, the concentration of hemoglobin and red blood cells may be low (if the bleeding started more than 12–24 hours ago).

## **CHAPTER 5**

### **SUBJECTIVE AND OBJECTIVE EXAMINATION METHODS OF THE PATIENTS WITH LIVER AND BILE DUCTS DISEASES**

#### **SUBJECTIVE EXAMINATION**

The main complains in case of liver and bile ducts diseases are:

- Abdominal pain;
- Dyspepsia;
- Skin pruritus (itching);
- Jaundice;
- Enlargement of the abdomen;
- Fever;
- Weakness.

Pain is localized in the right subcostal region (hypochondrium) or in the epigastrium, may radiate to the right shoulder, scapula, and in the interscapular space, may be persistent and dull, or it may be severe and occur in case of attacks, becomes more severe in deep breathing. Dull pain usually occurs in case of chronic cholecystitis, hepatitis. Acute pain — in biliary (hepatic) colic (gallstones).

Dyspepsia (indigestion) includes:

- Loss of appetite;
- Bitter taste in the mouth;
- Eructation (regurgitation);
- Nausea;
- Vomiting;

- Abdominal distension, pain or discomfort;
- Rumbling (gurgling) — a deep, resonant sound;
- Constipations or diarrhea.

*Skin pruritus* (itching) is the result of *cholestasis* (the slowing or stopping of bile flow), accumulation in the blood of bile acids. Bile salts are deposited into the skin, they are responsible for the pruritus (itching). You can see scratching on the patient's skin.

*Jaundice* (icterus) is yellow discoloration of the skin, sclerae, mucous membranes and nails (Fig. 28).




Fig. 28. Jaundice  
(<https://www.healthunbox.com>)

«True» jaundice is associated with high bilirubin level. «False» jaundice can happen if a patient eats foods rich in beta-carotene (e. g., oranges and carrots) (Fig. 29). Unlike true jaundice, a patient doesn't have yellow eyes, or changes in the bilirubin level.



Fig. 29. Products producing «false jaundice»  
(<https://from-ua.com>)

History of the present disease:

- A past history of jaundice;
- Diseases of the liver;
- Attacks of hepatic colic.



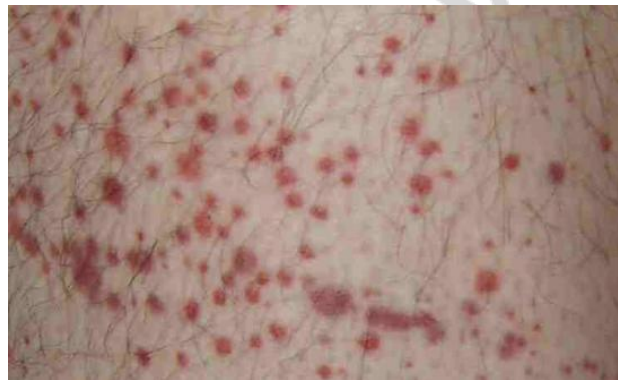
A Patient's life history:

- Exposure to poisons (alcohol, chemicals, mushrooms);
- Infectious diseases (hepatitis, lambliosis, malaria);
- Family history (Have your relatives had any liver diseases?).

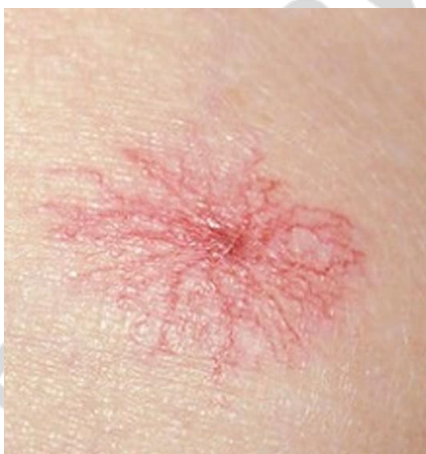### OBJECTIVE EXAMINATION

**Visual examination.** On general visual inspection (survey) you can find:

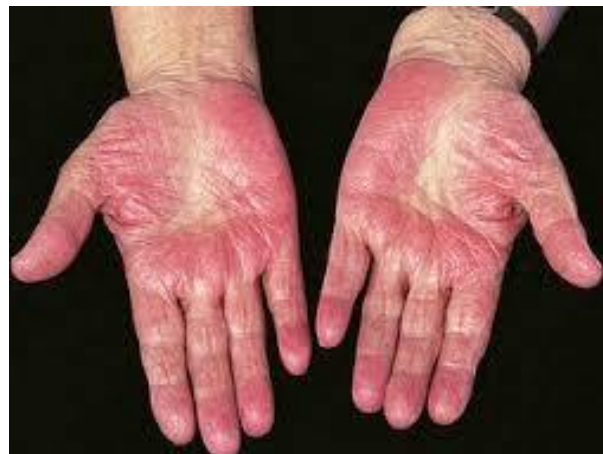- Icteric skin (jaundice).
- Pale skin (anemia).
- Brown skin (hemochromatosis).
- Skin scratches (due to severe itching).
- Petechial rash (small red or purple spot on the skin, caused by a minor bleeding from broken capillary blood vessels) (Fig. 30).
- Spider angioma (small dilated blood vessels ) (Fig. 31).
- Liver Palms (palmar erythema) is reddening of the skin on the palmar sides of the hands, usually over the hypothenar eminence (Fig. 32).



*Fig. 30. Petechial rash*  
(<https://www.medicalnewstoday.com>)



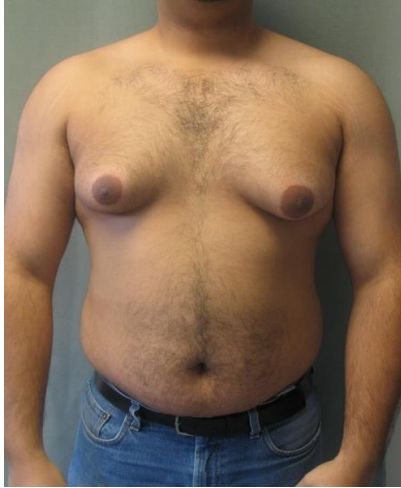*Fig. 31. Spider angioma*  
(<https://www.docmuscles.com>)



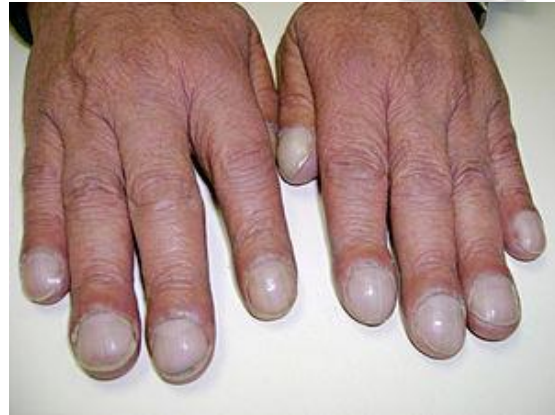*Fig. 32. Liver Palms*  
(<https://clinicalgate.com>)



- Gynecomastia increase in size of male breast tissue due to estrogen excess (Fig. 33).
- Drum (Hippocratic) fingers = nail clubbing (digital clubbing) is a deformity of the finger or toe nails (Fig. 34).
- Ascites.



*Fig. 33. Gynecomastia*  
(<https://chekininstitute.com>)



*Fig. 34. Nail clubbing*  
(<https://en.wikipedia.org>)

#### **Percussion of Liver:**

- The liver produces a dull percussion sound.
- The lung produces a clear pulmonary sound.
- The stomach and intestine produce a tympanic sound.

There are two types of liver percussion: topographic percussion and percussion by Kurlov's method. **Topographic percussion** determines the upper and lower boundaries of the liver.

#### *Superior Border of Hepatic Dullness* (Fig. 35):

- the right parasternalis line — the upper edge of the 6-th rib;
- the midclavicular line — the inferior edge of the 6-th rib;
- the anterior axillary line — the inferior edge of the 7-th rib.

#### *Inferior Border of Hepatic Dullness:*

- The right anterior axillary line — upper edge of the 10-th rib;
- The right midclavicular line — at the inferior edge of the right arch;
- The right parasternal line — 2 cm below the interior edge of the right costal arch;
- The anterior median line — 3–6 cm below the inferior edge of the xiphoid process;
- The inferior edge at the left costal arch — on the left parasternalis line.

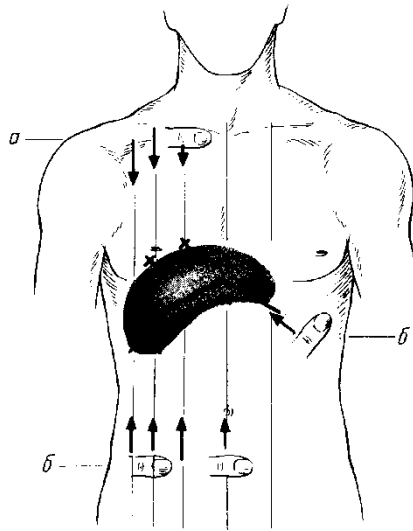


Fig. 35. Percussion of Liver  
(<https://studfiles.net>)

*Kurlov's method* allows you to estimate three liver sizes (Fig. 36):

- The first size  $9 \pm 1$  cm (on the right midclavicular line);
- The second size  $8 \pm 1$  cm (on the middle line);
- The third size  $7 \pm 1$  cm (on the left costal margin).

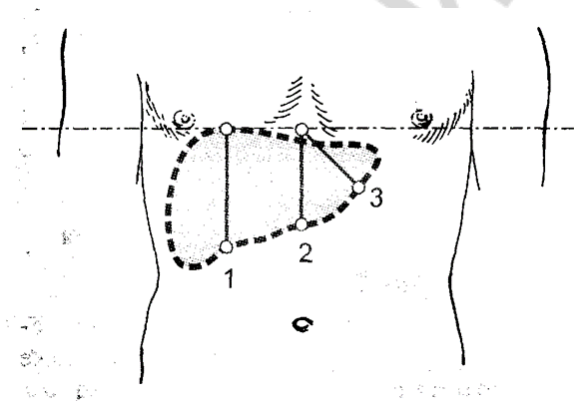


Fig. 36. Kurlov's method  
(<https://studfiles.net>)

### **Liver palpation:**

- Determine the lower border of the liver by percussion (in the midclavicular line).
- Place the right hand in the right hypochondrium quadrant in the right midclavicular line 3–5 cm below the inferior border of the liver (Fig. 37).
- Hug the right half of the chest with your left hand, placing four fingers on the patient's back and the thumb on the costal margin) (to restrict motility of the chest).
- During one expiration make a superficial motion and push the fingertips of the right hand down into the abdominal cavity.

- On inspiration the liver moves down, touches the physician's fingers and then slides to bypass them.
- Normal liver edge is soft, sharp or slightly rounded under the form, readily flexible, smooth and painless.

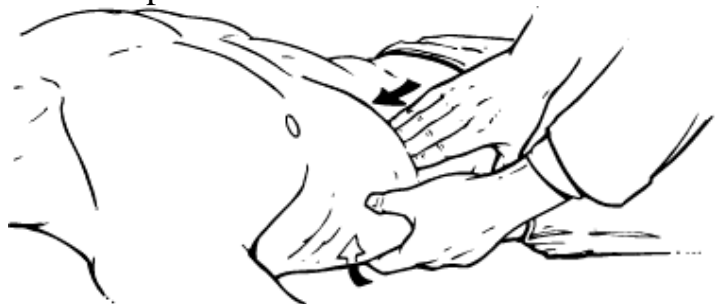

Fig. 37. Liver palpation  
(<http://www.accessmedicine.com>)

## CHAPTER 6

### MAJOR CLINICAL SYNDROMES OF HEPATOBILIARY DISEASES

#### JAUNDICE

*Jaundice* is one of the most common syndrome in case of liver diseases (Fig. 38).

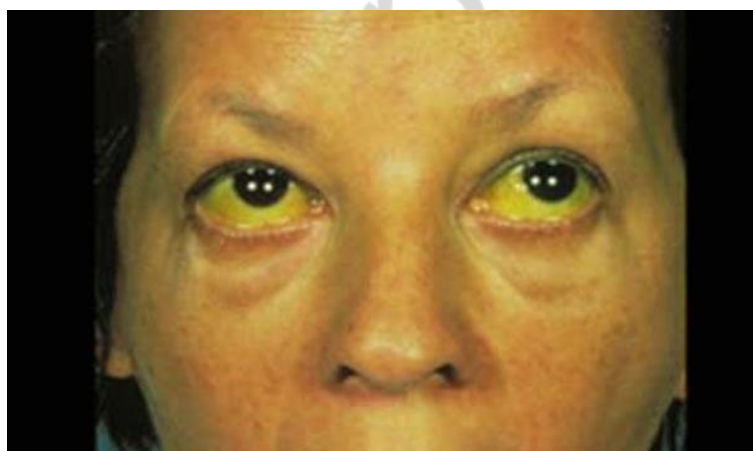

Fig. 38. Jaundice  
(<https://community.tes.com>)

There are 3 main types of jaundice: *hemolytic*, *hepatic* and *obstructive* (Fig. 39). Difference between these three jaundice types see below in Table 2. It is important to remember that.

**Unconjugated bilirubin = indirect bilirubin** (it is formed from hemoglobin during the breakdown of red blood cells).

**Conjugated bilirubin = direct bilirubin** (it is formed in the liver).

**Hemolytic** (*hematogenous, pre-hepatic*) **jaundice** develops as a result of excessive destruction of erythrocytes (hemolytic anemia)

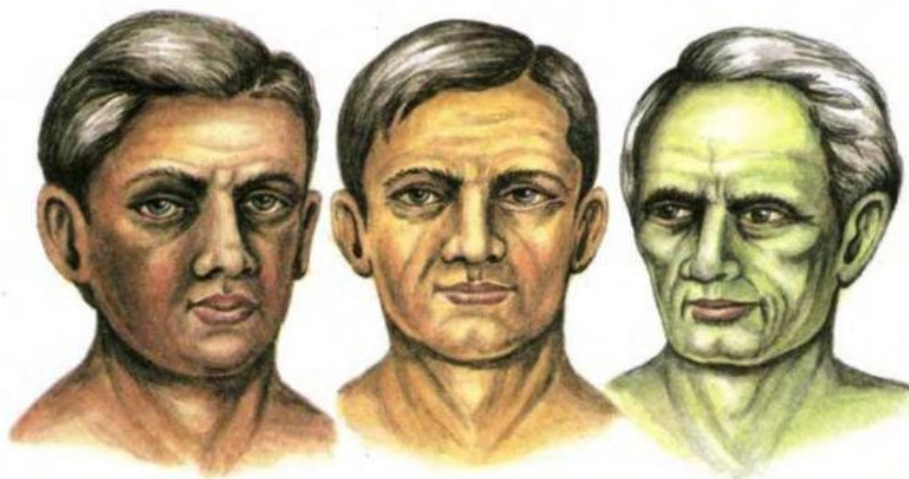
- Pathology occurs in the blood (RBC destruction);
- The skin is lemon-yellow;
- Skin pruritus (itching) is absent;
- Stool color is dark;
- Urine color is normal or slightly dark;
- ↑ indirect bilirubin.

**Hepatic** (hepatocellular) **jaundice** develops as a result of impaired capture of bilirubin by the liver cells (liver cell damage due to cirrhosis, hepatitis)

- Pathology occurs in the liver (cell damage due to cirrhosis, hepatitis);
- The skin is yellow with a reddish tint;
- Skin pruritus can occur;
- Stool color is normal;
- Urine color is dark;
- ↑ direct bilirubin.

**Obstructive** (mechanical, post-hepatic) **jaundice** develops as a result of bile duct obstruction and reabsorption of direct bilirubin in the blood (bile stones, cancer):

- Pathology after formation of bilirubin in the liver (compression of the duct by gallstones, tumor);
- The skin is yellow-green (olive color);
- Skin pruritus is present;
- Stool is colorless;
- Urine color is dark;
- ↑ direct bilirubin.



**a**                      **b**                      **c**  
*Fig. 39. Skin color in case of different types of jaundice:  
a — obstructive, b — hepatic, c — hemolytic*  
(<https://simptomov.com>)

Difference among three types of jaundice see in the table 3.

Table 3

**Difference between three types of jaundice\***

Functional test	Pre-hepatic Jaundice	Hepatic Jaundice	Post-hepatic Jaundice
Total bilirubin	Normal / Increased	Increased	
Conjugated bilirubin	Normal	Increased	Increased
Unconjugated bilirubin	Normal / Increased	Increased	Normal
Urobilinogen	Normal / Increased	Increased	Decreased / Negative
Urine Color	Normal	Dark (urobilinogen + conjugated bilirubin)	Dark (conjugated bilirubin)
Stool Color	Normal	Normal / Pale	Pale
Alkiline phosphatase level	Normal	Increased	Increased
Alanine transferase and Aspartate transferase levels		Increased	Increased
Conjugated Bilirubin in Urine	Not Present	Present	Present
Splenomegaly	Present	Present	Absent

### PORTAL HYPERTENSION

Portal Hypertension is a syndrome of increased pressure in the portal venous system. *Prehepatic* portal hypertension is due to portal or splenic vein thrombosis. *Hepatic portal* hypertension usually occurs due to liver cirrhosis, hepatitis, congenital hepatic fibrosis. *Posthepatic* portal hypertension has such reasons as thrombosis hepatic veins or inferior vena cava (Budd-Chiari syndrome), obstruction of inferior vena cava, cardiac causes (e. g., constrictive pericarditis). Portal hypertension symptoms are: portocaval anastomoses dilation (Caput Medusae, bleeding), ascites, enlargement of spleen (splenomegaly).

Mechanisms of portal hypertension development:

- Increased resistance to portal blood flow
- Formation of collateral veins that bypass the liver
- Enlarged vessels are prone to rupture causing bleeding
- The left gastric vein anastomoses with the esophageal veins, which flow into the azygos vein.
- The superior rectal vein anastomoses with the middle and inferior rectal veins, which flow into the internal iliac veins.
- The paraumbilical vein anastomoses with subcutaneous veins in the anterior abdominal wall, we can see them as Caput Medusae (*head of Medusa*) (Fig. 40, 41).

\* <https://slideplayer.com/slide/9926830>





Fig. 40. Medusa, Caravaggio  
(Galleria Uffizi, Florence, Italy)  
(<https://www.caravaggio-foundation.org>)

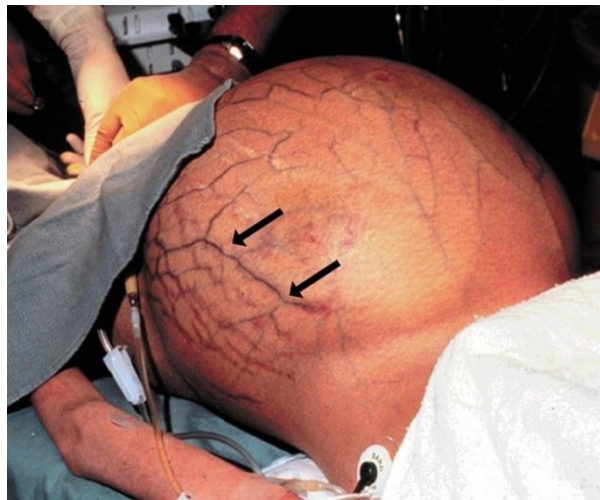

Fig. 41. Caput Medusae (head of Medusa)  
at the abdominal wall  
(<http://radiographics.rsna.org>)

### PORTOSYSTEMIC ENCEPHALOPATHY

*Portosystemic (hepatic) Encephalopathy* is caused by accumulation in the bloodstream of toxic substances that are normally removed by the liver.

Portosystemic (hepatic) encephalopathy:

- Shunting of portal blood directly into systemic circulation bypassing liver.
- Toxic substances absorbed from the intestine are not metabolized by the liver.

- Toxins are accumulated in the brain.

Portosystemic encephalopathy signs are as follows:

- Impairment of consciousness.
- Impairment of sleep pattern.
- Fixed stare.
- Impaired memory.
- Mental confusion.
- Apathy.
- Drowsiness.
- Coma.

### HYPERSPLENISM

*Hypersplenism* is a condition in which the spleen becomes increasingly active and then rapidly removes the blood cells. It can result from any splenomegaly. It has the following signs: *splenomegaly* (spleen enlargement) and *pancytopenia* (anemia, leukopenia, thrombocytopenia).

## HEPATIC FAILURE

*Hepatic Failure (hepatic insufficiency)* is a result of hepatitis, liver cirrhosis, tumors of liver and poisoning. It has the following signs (Fig. 42).

- Fatigue, weakness;
- Poor appetite;
- Dyspepsia (meteorism, rumbling, abdominal pain);
- Stool disorders;
- Loss of weight, edema and ascites (albumin synthesis decreases);
- Coagulopathy (skin hemorrhages, nasal bleeding, intestinal bleeding) due to upset synthesis of blood coagulating factors and decreased platelet content;
- Jaundice;
- Gynaecomastia, menstrual disorders, hair loss, palmar erythema, and spiders angioma (estrogen excess);
- Portosystemic encephalopathy;
- Decreased level of albumin, cholesterol, prothrombin, fibrinogen.

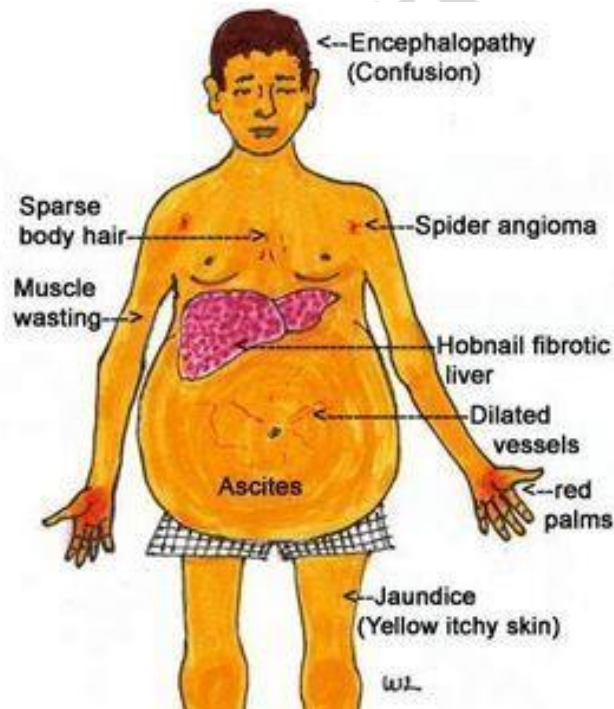


Fig. 42. Hepatic failure symptoms  
(<https://www.slideshare.net>)



## CHAPTER 7

### LABORATORY AND INSTRUMENTAL METHODS OF EXAMINATION IN CASE OF GASTROINTESTINAL DISEASES

Laboratory tests are important in assisting and management of the patient during treatment and diagnosis. They are used for:

1. Screening in asymptomatic individuals.
2. Diagnosis in symptomatic patients.
3. Assisting the practitioner in the patient management.

#### **Blood Clotting Tests:**

– Prothrombin time (the rate at which prothrombin is converted to thrombin, **normal range is 10–14 seconds**)

– Severe acute or chronic liver damage leads to prolongation of the prothrombin time due to impaired synthesis of clotting proteins (Fig. 43).

**Complete Blood Count** (Fig. 44) may reveal anemia ( $\downarrow$ Hb,  $\downarrow$  RBC) due to:

- blood loss (gastrointestinal bleeding);
- nutritional deficiency (*Fe, vitamin B12, protein deficiency*);
- destruction of RBC (hypersplenism).

**Red blood cells (Erythrocytes) normal range is 3,8–5,7/l.**

**Hemoglobin normal range is 120–170 g/l.**

*Erythrocyte sedimentation rate (ESR)* can be useful to check the degree of inflammation. It is especially useful in assessing the chronic diseases and their prognosis during treatment. **ESR normal range is 2–15 mm/hour.**

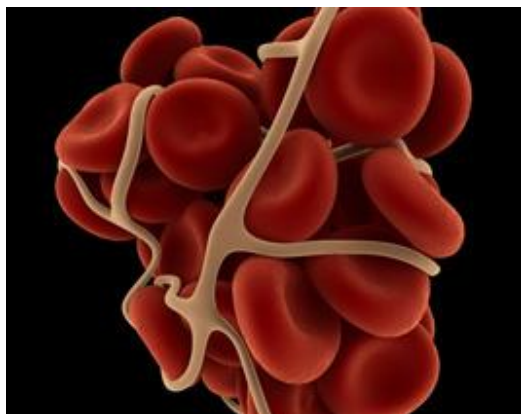

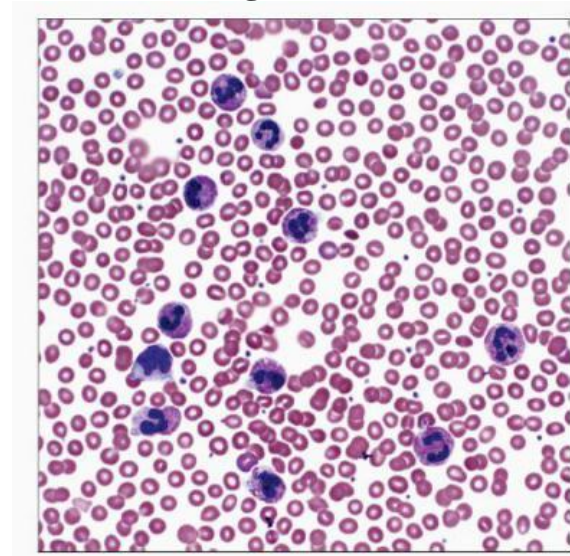
Fig. 43. Blood clot  
(<https://www.health24.com>)

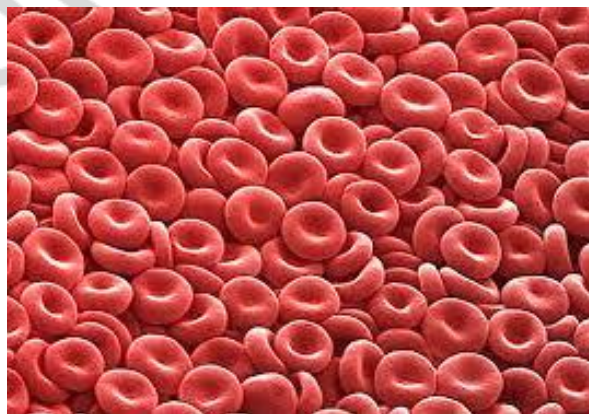

Fig. 44. Erythrocytes  
(<http://www.anatomybox.com>)

Complete Blood Count (Fig. 45) may reveal leukopenia (total WBC  $< 4 \times 10^9/l$ ). It can be result of infection (bacterial or viral) or hypersplenism. Complete Blood Count may reveal *Leukocytosis* (WBC  $> 9 \times 10^9/l$ ). It also can be related to infection or chronic inflammation. **Left shift** is an increase in the number of immature (band) leukocytes in the peripheral blood, particularly neutrophil band cells. Left shift means that the patient has infection, inflammation or necrosis.

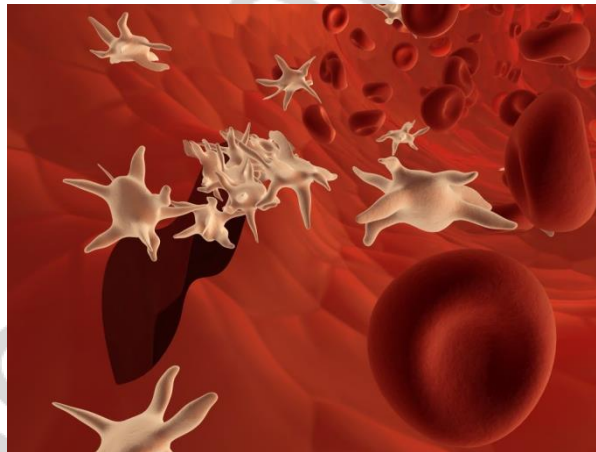
**Leucocytes (WBC) normal range is  $4-9 \times 10^9/l$ .**



*Fig. 45. Leukocytes and red blood cells in a blood smear*  
(<http://fb.ru>)

Complete Blood Count may present thrombocytosis (platelet count  $> 450 \times 10^9/l$ ) (Fig. 46). It can be caused by iron deficiency, splenectomy (spleen absence due to surgery), infection, malignancy or inflammatory disease. Thrombocytopenia (platelet count  $< 150 \times 10^9/l$ ) is usually associated with liver disease, hypersplenism, autoimmune disease, acute bleeding or malignant tumor.

**Thrombocytes (platelets) normal range is  $150-450 \times 10^9/l$ .**



*Fig. 46. Platelets*  
(<https://www.bumc.bu.edu>)

### **Blood Chemistry Tests**

Biochemical blood test can provide a large amount of information about the state of the gastrointestinal tract.

Liver Function:

- Serum bilirubin (total, direct, indirect);
- Serum albumin – globulin;

- Serum alkaline phosphatase;
- AST & ALT;
- LDH.

Bilirubin:

- Jaundice — total serum bilirubin rises;
- **Normal Value (total) is 5–21 mmol/l.**

High values:

- Hemolytic anemia;
- Biliary obstruction;
- Hepatitis;
- Cirrhosis;
- Liver cancer.

Serum enzymes — *Aspartate aminotransferase* (AST) and *Alanine aminotransferase* (ALT) are two enzymes found in the liver and other organs.

Normal Value:

- **AST 5–45 units/l;**
- **ALT 5–45 units/l.**

High values:

- Hepatitis;
- Liver damage from alcohol abuse, drugs or fatty liver;
- Cirrhosis.

*Lactate dehydrogenase* (LDH) is a non-specific test. The isoenzymes of LDH are LDH-1, LDH-2, LDH-3, LDH-4, and LDH-5. The isoenzyme LDH-5 is related with liver diseases.

**LDH Normal value (total) 130–220 U/l.**

Increased: Tissue necrosis, particularly associated with the acute injury of the heart, red cells, kidneys, skeletal muscles, liver, lungs.

**Alkaline phosphatase (ALP) normal level is 30 to 130 U/l.**

ALP is decreased in case of malnutrition. It is increased in case of:

- Liver disease / bile obstruction by stone, stricture, cancer
- Bone diseases (increased bone cell activity)
- Pregnancy

**Serum amylase has normal level 25 to 75 IU/l.** It increases in case of pancreatitis, obstruction of pancreatic ducts (carcinoma, stone and stricture). It decreases in case of acute or chronic hepatitis, pancreatic insufficiency.

*Cholestasis* is a condition where bile cannot flow from the liver to the duodenum.

Cholestasis signs:

- Obstructive jaundice;
- Increased level of:
  - ✓ cholesterol;
  - ✓ bile acids;

- ✓ direct bilirubin;
- ✓ alkaline phosphatase (AP);
- ✓  $\gamma$ -glutamyl transpeptidase (GGT).

*Cytolysis (Liver Injury)* is an increased concentration in blood of liver cell enzymes:

- aspartate aminotransferase (AsAT, AST);
- alanine aminotransferase (AlAT, ALT);
- lactic dehydrogenase (LDH, LDH-5);
- $\gamma$ -glutamyl transpeptidase (gamma-glutamyltransferase, GGT).

*Serum Proteins:*

- Serum albumin is synthesized in liver;
- Serum globulins is produced by plasma cells (lymphocytes).

**Normal Values:**

- **Total Protein 60–80 gram/l;**
- **Albumin 35 to 55 gram/l;**
- **Globulin 23 to 35 gram/l;**
- Albumin / Globulin ratio is 1,5 : 1–2,5 : 1.

*C-reactive protein (CRP)* is a substance produced by the liver in response to inflammation. CRP measures general levels of inflammation in the body (Fig. 47).

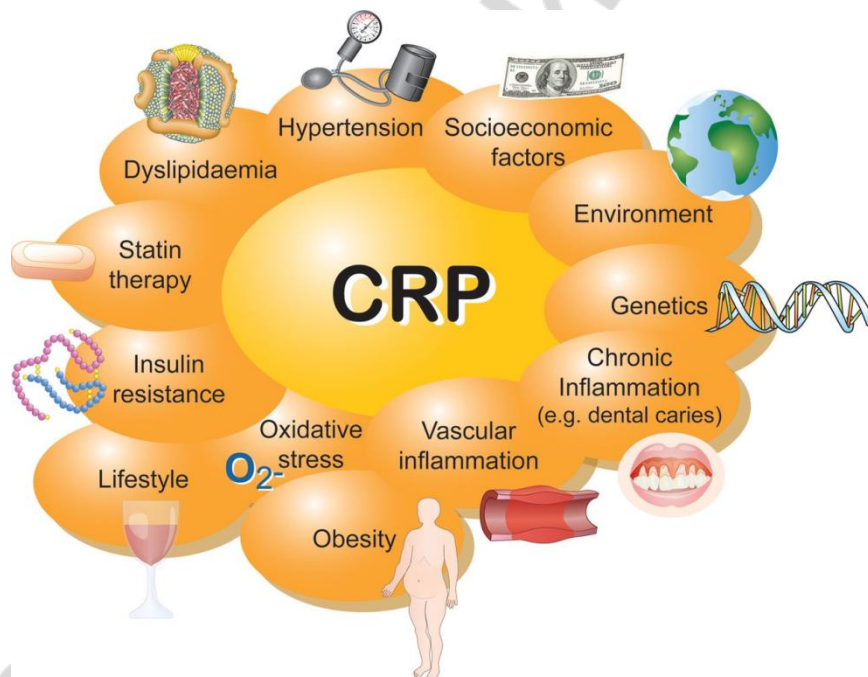

Fig. 47. Conditions at which the CRP level may increase (<https://www.thesnowboots.com>)

**Urine Tests** can reveal abnormalities in the gastrointestinal tract (Fig. 48).

- Urine urobilinogene (liver disorders, jaundice);
- Amylase (pancreatitis).



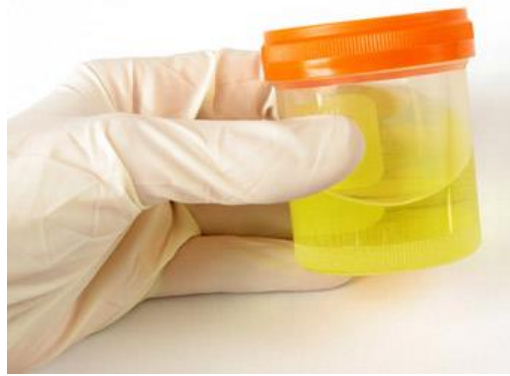

Fig. 48. Urine test  
(<https://www.growingyourbaby.com>)

**Stool Tests.** The stool is a natural product of the gastrointestinal tract. Therefore, it may indicate an impairment of the digestive system.

Changes in color, consistency and pH, and the presence of mucus, blood, white blood cells, bile, fat, sugars, etc. help diagnose GI conditions.

**A stool culture** can help diagnose bacterial infection.

**Increased fat** levels in the stool (*steatorrhea*) may be seen in celiac disease, pancreatitis, etc. Fat is normally absorbed in the small intestine in the presence of biliary and pancreatic secretions.

High pH of the stool can indicate inflammation, cancer, etc.

**Fecal occult blood test (FOBT)** indicates gastrointestinal bleeding

**Ova and parasites.** This test reveals ova (eggs) or parasites.

Some **enzyme** immunoassays are used to detect viral and bacterial antigen in a stool sample.

**Endoscopy** is a procedure in which a tube is inserted into the mouth (endoscopy) or rectum (colonoscopy) so that the doctor can examine the intestine (Fig. 49).

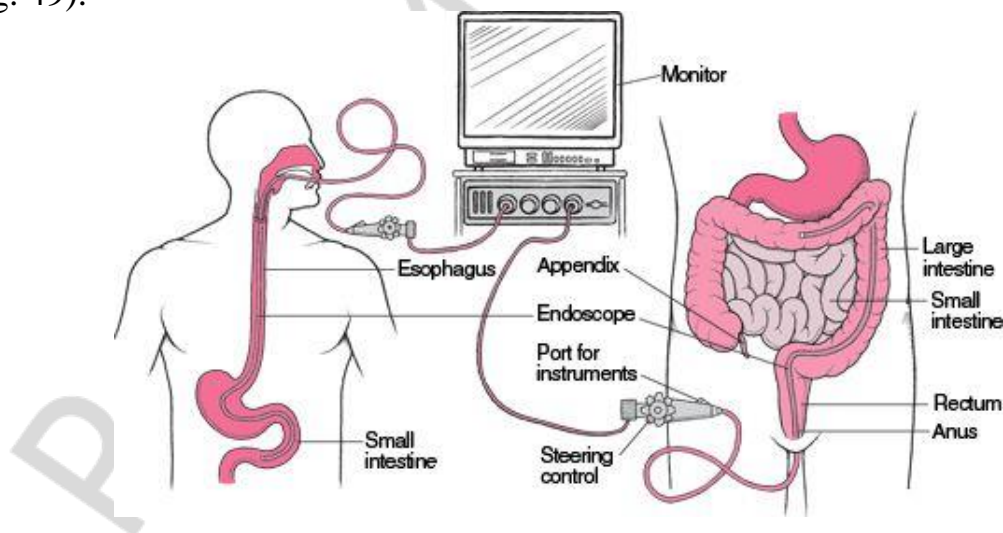
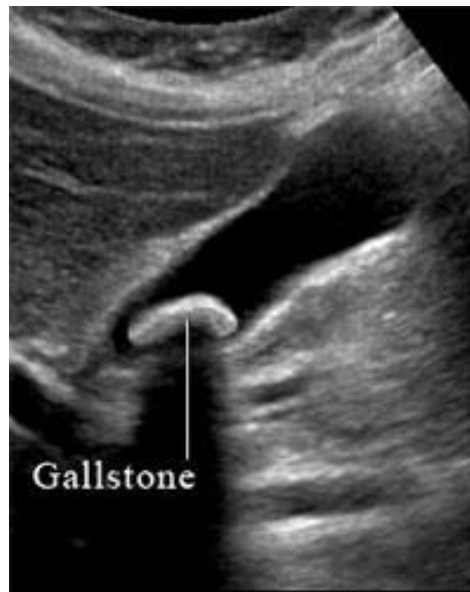

Fig. 49. Endoscopy and colonoscopy  
(<https://www.merckmanuals.com>)

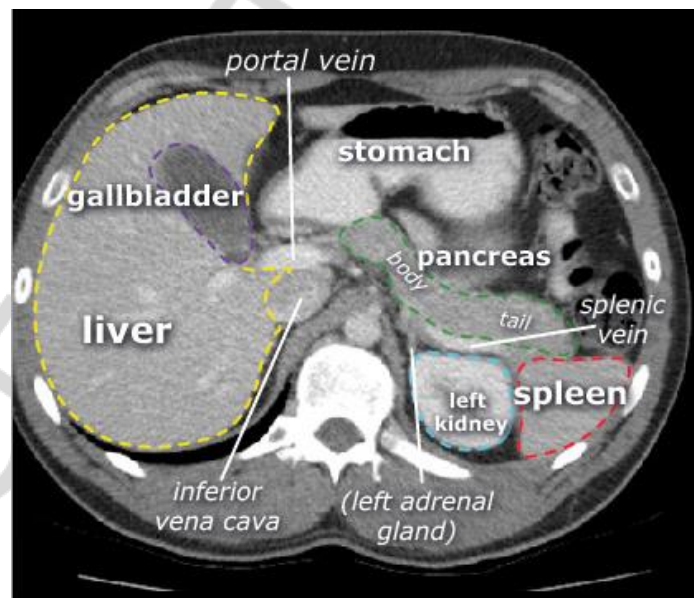
**Abdominal Ultrasound** (Fig. 50) is used to examine organs and their blood vessels (liver, pancreas, gallbladder, etc.).



*Fig. 50.* Gallbladder ultrasound  
(<https://myhealth.alberta.ca>)

**Computerized topography (CT) scan** is a computerized X-ray technique. These images give a cross sectional view of the internal organs which helps analyze the internal structures of the body (Fig. 51).

**In magnetic resonance imaging (MRI)**, a beam of radio waves and magnetic fields is sent through the body to detect a defect in the target organ. It gives an accurate image of the organ and structures within it.



*Fig. 51.* Normal abdominal CT  
(<http://www.startradiology.com>)

**Barium X-ray** is a diagnostic test when a chalky liquid (barium) visible on an X-ray, is used. When ingested, barium can help get an image of the stomach and the small intestines on an X-ray (barium meal, barium swallow). When administered rectally as enema, the colon and terminal ileum can be seen on X-ray. This test helps diagnose gut narrowing, fistulae, ulcerations, etc. (Fig. 52, 53).

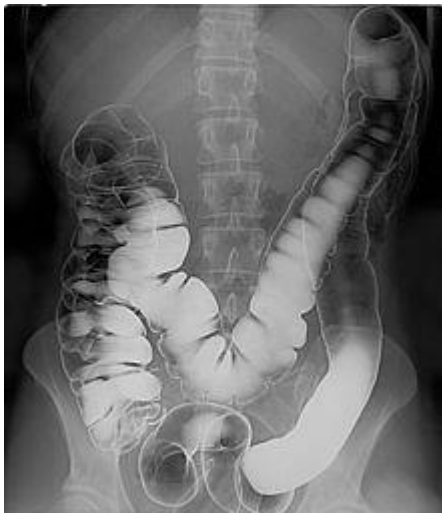

Fig. 52. Barium enema  
(<https://en.wikipedia.org>)

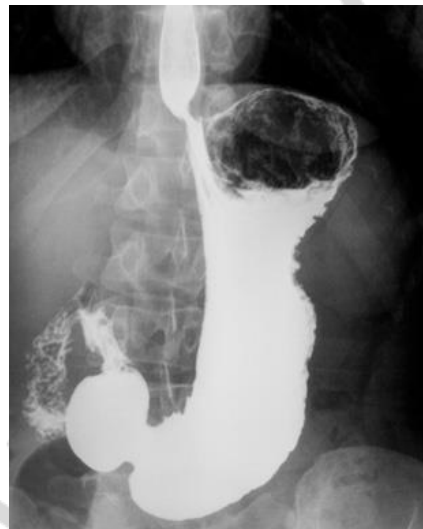

Fig. 53. Stomach barium study  
(<http://www.alara.co.za>)

## TESTS

### 1. What is the sign of stomach dyspepsia?

- a) Diarrhea;
- b) Vomiting;
- c) Odynophagia;
- d) Constipation.

### 2. What is NOT a sign of gastrointestinal bleeding?

- a) Melena;
- b) Hematochezia;
- c) Vomiting with «coffee ground» masses;
- d) High blood pressure.

### 3. In case of stomach pathology pain is typically localized:

- a) In costovertebral angle;
- b) In xiphoid (substernal) region;
- c) Round the navel;
- d) In right inguinal area.

### 4. Auscultation of the abdomen is carried out to reveal:

- a) Peristaltic sound;
- b) Vesicular breathing;
- c) Popliteal artery murmur;
- d) Functional heart murmur.

### 5. Diarrhea is:

- a) a liquid stool more than 2 times a day;
- b) black stool;
- c) tarry stool;
- d) hematemesis.



**6. Constipation is:**

- a) Absence of stool more than 24 hours;
- b) Absence of stool more than 2 days;
- c) Absence of stool more than 7 days;
- d) Liquid stool.

**7. How many steps does deep abdominal palpation have?**

- a) 2;
- b) 3;
- c) 4;
- d) 5.

**8. Odynophagia is:**

- a) An abdominal pain;
- b) Pain on urination;
- c) Pain on swallowing;
- d) Difficulty during swallowing.

**9. The healthy liver sizes by Kurlov are:**

- a)  $8 \pm 1$  cm,  $7 \pm 1$  cm,  $6 \pm 1$  cm;
- b)  $9 \pm 1$  cm,  $8 \pm 1$  cm,  $7 \pm 1$  cm;
- c)  $10 \pm 1$  cm,  $9 \pm 1$  cm,  $8 \pm 1$  cm;
- d)  $11 \pm 1$  cm,  $10 \pm 1$  cm,  $9 \pm 1$  cm.

**10. Melena is a symptom of:**

- a) Rectum bleeding;
- b) Sigmoid colon bleeding;
- c) Portal hypertension syndrome;
- d) Upper gastrointestinal bleeding.

**Answers:**

**1 – b, 2 – d, 3 – b, 4 – a, 5 – a, 6 – b, 7 – c, 8 – c, 9 – b, 10 – d.**

## REFERENCES

1. *General propedeutics of internal diseases : lecture course* / Vitebsk State Medical University ; compiled by L. M. Nemtsov. Vitebsk : VSMU, 2016.
2. *Ivashkin, V. T. Internal diseases propedeutics* / V. T. Ivashkin, A. V. Okhlobystin Moscow : ГЭОТАР-Медиа, 2014.
3. *Bates' Guide to Physical Examination and History-Taking* – 11 ed. (2012).
4. *Арсентьева, И. Л. Учебная история болезни* / И. Л. Арсентьева // Минск : БГМУ, 2015.

РЕПОЗИТОРИЙ БГМУ

## CONTENTS

Explanatory note .....	3
Chapter 1. Subjective and objective examination methods of the patients with stomach and bowel diseases .....	3
Subjective examination .....	3
Visual examination .....	6
Tongue inspection.....	7
Chapter 2. Abdomen examination .....	8
Abdomen inspection .....	8
Percussion .....	11
Auscultation.....	11
Chapter 3. Abdomen palpation .....	12
Surface palpation .....	12
Deep palpation.....	14
Chapter 4. Major clinical syndromes of gastrointestinal diseases.....	17
Constipation.....	18
Diarrhea .....	18
Syndrome of inadequate absorption .....	19
Gastrointestinal bleeding syndrome .....	19
Chapter 5. Subjective and objective examination methods of the patients with liver and bile ducts diseases.....	20
Subjective examination .....	20
Objective examination.....	22
Chapter 6. Major clinical syndromes of hepatobiliary diseases .....	25
Jaundice .....	25
Portal hypertension .....	27
Portosystemic encephalopathy .....	28
Hypersplenism .....	28
Hepatic failure .....	29
Chapter 7. Laboratory and instrumental methods of examination in case of gastrointestinal diseases.....	30
Tests .....	36
References.....	37

Учебное издание

**Шолкова Мария Владимировна**  
**Доценко Эдуард Анатольевич**  
**Бураков Иван Иванович**

**ПРАКТИЧЕСКИЕ НАВЫКИ  
ПО ОБСЛЕДОВАНИЮ ОРГАНОВ  
ЖЕЛУДОЧНО-КИШЕЧНОГО ТРАКТА**

**MANUAL IN GASTROINTESTINAL SYSTEM  
EXAMINATION**

Учебно-методическое пособие

На английском языке

Ответственный за выпуск Э. А. Доценко  
Переводчик М. В. Шолкова  
Компьютерная вёрстка А. В. Янушкевич

Подписано в печать 28.03.19. Формат 60×84/16. Бумага писчая «Хероx office».  
Ризография. Гарнитура «Times».  
Усл. печ. л. 2,32. Уч.-изд. л. 1,62. Тираж 99 экз. Заказ 185.

Издатель и полиграфическое исполнение: учреждение образования  
«Белорусский государственный медицинский университет».  
Свидетельство о государственной регистрации издателя, изготовителя,  
распространителя печатных изданий № 1/187 от 18.02.2014.  
Ул. Ленинградская, 6, 220006, Минск.