

**L. N. PALIANSKAYA, I. A. ZAKHARAVA**

**VESICULOBULLOUS LESIONS  
OF ORAL MUCOSA**

Minsk BSMU 2020

МИНИСТЕРСТВО ЗДРАВООХРАНЕНИЯ РЕСПУБЛИКИ БЕЛАРУСЬ  
БЕЛОРУССКИЙ ГОСУДАРСТВЕННЫЙ МЕДИЦИНСКИЙ УНИВЕРСИТЕТ  
2-я КАФЕДРА ТЕРАПЕВТИЧЕСКОЙ СТОМАТОЛОГИИ

**Л. Н. Полянская, И. А. Захарова**

# **ВЕЗИКУЛОБУЛЛЕЗНЫЕ ПОРАЖЕНИЯ СЛИЗИСТОЙ ОБОЛОЧКИ ПОЛОСТИ РТА**

## **VESICULOBULLOUS LESIONS OF ORAL MUCOSA**

Учебно-методическое пособие



Минск БГМУ 2020

УДК 616.311.1-06:616.5-002(075.8)-054.6

ББК 56.6я73

П54

Рекомендовано Научно-методическим советом университета в качестве учебно-методического пособия 26.06.2020 г., протокол № 10

Р е ц е н з е н т ы: д-р мед. наук, проф. Белорусской медицинской академии последипломного образования Н. А. Юдина; канд. мед. наук, доц. Белорусской медицинской академии последипломного образования С. А. Гранько; канд. филол. наук, доц. Белорусского государственного медицинского университета М. Н. Петрова

**Полянская, Л. Н.**

П54 Везикулобуллезные поражения слизистой оболочки полости рта = Vesiculobullous lesions of oral mucosa : учебно-методическое пособие / Л. Н. Полянская, И. А. Захарова. – Минск : БГМУ, 2020. – 20 с.

ISBN 978-985-21-0649-8.

Рассмотрены клинические проявления, подходы к дифференциальной диагностике и лечению везикулобуллезных поражений слизистой оболочки полости рта.

Предназначено для студентов 5-го курса медицинского факультета иностранных учащихся, обучающихся на английском языке по специальности «Стоматология».

УДК 616.311.1-06:616.5-002(075.8)-054.6

ББК 56.6я73

ISBN 978-985-21-0649-8

© Полянская Л. Н., Захарова И. А., 2020

© УО «Белорусский государственный медицинский университет», 2020

## MOTIVATIONAL CHARACTERISTIC OF THE THEME

**Total time:** 70–90 minutes (seminar).

Many vesiculobullous diseases of the mouth have a similar clinical appearance. The oral mucosa is thin, and even slight trauma leads to rupture of vesicles and bullae forming eroded, red areas; fibrin forms over the erosion and an ulcer develops. As such, vesiculobullous lesions that have a characteristic appearance on the skin have a somewhat nonspecific appearance on the oral mucosa. Four key points in particular help the clinician rapidly categorize a patient's disease and simplify the diagnosis: the length of time the lesions have been present (acute or chronic lesions), a history of similar lesions (primary or recurrent disease), the number of lesions present (single or multiple), and the location of lesions.

**The purpose of the seminar:** to integrate knowledge about the basic principles of diagnosis and treatment of oral mucosa vesiculobullous lesions.

**The tasks of the seminar.** The student should know:

1. The scheme of clinical examination of the patient with oral mucosa disease.
2. Description sequence and characteristic features of oral mucosa lesions.
3. Additional methods of examination and laboratory diagnosis of oral mucosa diseases.
4. Principles of differential diagnosis of vesiculobullous lesions of oral mucosa.
5. Basic principles and methods of treatment of patients with the diseases of oral mucosa. Groups of medicines.

**Requirements for the initial level of knowledge.** For full understanding of the topic the student must revise:

- from human anatomy: anatomical features of oral mucosa;
- from histology, cytology, embryology: morphological structure of oral mucosa;
- from therapeutic dentistry: dental examination, basic and additional methods, types of oral mucosa lesions.

**Control questions from related disciplines:**

1. Anatomical and histological structure of oral mucosa.
2. Classification and characteristics of oral mucosal lesions.
3. Cytological, histological, microbiological, allergic, biochemical methods of examination.

**Control questions for the seminar:**

1. Classification of oral mucosa diseases (WHO).
2. Methods of examination in patients with oral mucosa diseases.
3. Diagnosis and clinical features of vesiculobullous lesions of oral mucosa.

4. Differential diagnosis of vesiculobullous lesions.
5. Contemporary principles of treatment of oral mucosa vesiculobullous lesions.

## **VESICULOBULLOUS LESIONS**

*Vesicles* are small, fluid-filled blisters measuring less than 5 mm. In the case of viral diseases vesicles occur in clusters, in other diseases they may occur singularly. *Bullae* resemble vesicles in appearance but are larger in size and scope. They may occur singularly or coalesce to form large areas of involvement. On skin, vesicles and bullae are bleb-like and tense. In the oral cavity, both vesicles and bullae are more flattened, with a smooth gelatinous surface. Because of chronic masticatory forces and a less rigid epithelial surface, oral vesicles and bullae are prone to rupture, leaving erosive and ulcerative lesions later in the course of disease.

There are many classifications of oral mucosa lesions according to their etiology, pathogenesis, clinical manifestations, course, etc. Here is a **fragment of the International Classification of Diseases (ICD-DA 1994 WHO)**, which are manifested by vesiculobullous lesions:

### **Section I. Certain infectious and parasitic diseases**

*Viral infections characterized by the skin and mucous membrane lesions (B 00–09):*

- B 00 Herpesviral [herpes simplex] infections
  - B 00.2 Herpesviral gingivostomatitis
- B 02 Zoster [herpes zoster]
- B 08 Other viral infections characterized by skin and mucous membrane lesions, not elsewhere classified
  - B 08.5 Enteroviral vesicular pharyngitis [Herpangina]

### **Section XI Diseases of the digestive system**

*Stomatitis and related lesions (K 12):*

- K 12.1 Other forms of stomatitis
  - K 12.14 Contact stomatitis

### **Section XII. Diseases of the skin and subcutaneous tissue**

*Bullous disorders (L 10–14):*

- L 10 **Pemphigus**
  - L 10.00 Pemphigus vulgaris
  - L 10.1 Pemphigus vegetans
  - L 10.2 Pemphigus foliaceus
  - L 10.5 Drug-induced pemphigus
  - L 10.8 Other pemphigus

## L 12 Pemphigoid

L 12.0 Bullous pemphigoid

L12.1 Cicatricial pemphigoid [Benign mucous membrane pemphigoid]

## Urticaria and erythema (L50–54)

L 51 Erythema multiforme

L 51.0 Nonbullous erythema multiforme

L 51.1 Bullous erythema multiforme [Stevens-Johnson syndrome]

## HERPES SIMPLEX INFECTION

**Definition.** Herpes simplex virus (HSV) infections are common vesicular eruptions of the skin and mucosa that occur in two forms — primary (systemic) as the result of initial infection in a previously uninfected person and secondary (localized) as the result of viral reactivation in a previously infected individual.

**Etiology.** Most oral-facial herpetic lesions are due to HSV type 1, although a small percentage may be caused by HSV type 2. The primary infection, which occurs on initial contact with the virus, is acquired by inoculation of the mucosa, skin, and eye with infected secretions. The virus then travels along the sensory nerve axons and establishes chronic, latent infection in the sensory ganglion (such as the trigeminal ganglion). Reactivation of virus may follow exposure to sunlight (fever blisters), prior to a cold (cold sores), trauma, menstrual cycle, stress, or immunosuppression causing a secondary or recurrent infection.

**Clinical features.** Primary disease is usually seen in children, although adults who have not been previously exposed to HSV may be affected. The primary lesions are accompanied by fever, arthralgia, malaise, anorexia, headache, and cervical lymphadenopathy. The vesicular eruption may appear on the skin, vermilion, and oral mucous membranes. Intraorally, lesions may appear on any mucosal surface. Vesicles break rapidly down to form raw or white pseudomembranous erosions that are usually 1–5 mm (Fig. 1) and may coalesce to form larger lesions with irregular borders and marked surrounding erythema. The gingiva is often erythematous, and the mouth is extremely painful, causing difficulty with eating. The disease runs its course in 10 to 14 days, and healing develops without scar formation.

In recurrent form of the disease patients usually have prodromal symptoms of tingling, burning, or pain at the site where lesions will appear. Within a matter of hours, multiple fragile and short-lived vesicles appear. The lesions are confined to the lips (Fig. 2), hard palate, and gingiva. They become unroofed and coalesce to form map-like superficial erosions. The lesions heal without scarring in 1 to 2 weeks and rarely become secondarily infected.

**Diagnosis.** Herpetic gingivostomatitis is usually apparent from clinical features. It can be confirmed by a virus culture (the gold standard test), Tzanck smear (demonstrates the characteristic multinucleated giant cells or intranuclear

inclusions), serology (IgM and IgG titers), immunohistochemistry, or polymerase chain reaction (PCR) testing.

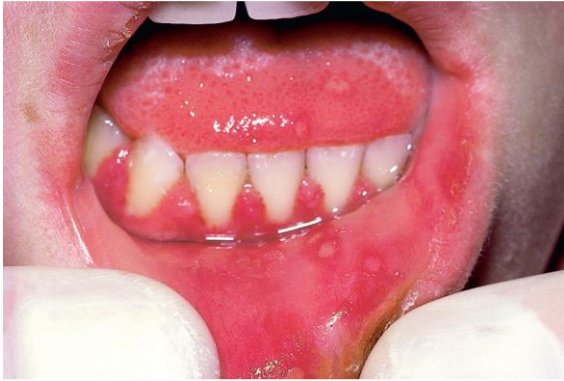

Fig. 1. Primary HSV infection

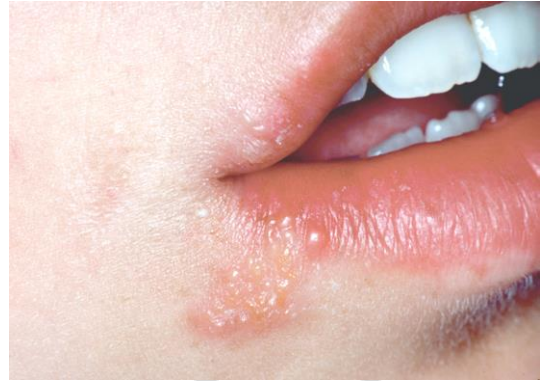

Fig. 2. Secondary (recurrent) HSV infection

**Differential diagnosis.** Systemic signs and symptoms coupled with the oral ulcers may require differentiation from streptococcal pharyngitis, erythema multiforme, and acute necrotizing ulcerative gingivitis (ANUG, or Vincent's infection). Clinically, streptococcal pharyngitis does not involve the lips or perioral tissues, and vesicles do not precede the ulcers. Oral ulcers of erythema multiforme are larger, usually without a vesicular stage, and are less likely to affect the gingiva. ANUG also commonly affects young adults; however, oral lesions are limited to the gingiva and are not preceded by vesicles. Moreover, considerable pain and oral malodor are often reported with ANUG.

Secondary herpes is often confused with recurrent aphthous stomatitis (RAS) but can usually be distinguished from it on the basis of clinical features. Multiple lesions, neurologic prodrome (tingling), vesicles preceding ulcers, and palatal and gingival location are indicative of herpesvirus infection. In contrast to herpetic lesions, aphthae are found almost exclusively on nonkeratinized mucosa, such as the floor of the mouth, the alveolar mucosa, and the buccal labial mucosa.

**Treatment.** Management is directed toward pain control, supportive care, and definitive treatment (Table 1). In the past, healthy patients with primary herpetic gingivostomatitis were treated only with hydration and supportive measures. However, since the acyclovir family of drugs is inexpensive, safe, and readily available, it is appropriate to treat even primary infections definitively because it reduces viral shedding and infectivity. One of the most important factors in the treatment of HSV infection is timing. For any drug to be effective, it must be used as soon as possible after recognition of early or prodromal symptoms. No later than 48 to 72 hours from the onset of symptoms is generally regarded as the ideal time to start therapeutic measures.

Acyclovir inhibits viral replication and is activated by virally produced thymidine kinase. It's used at 15 mg/kg five times a day. Valacyclovir,

a prodrug of acyclovir, has three to five times the bioavailability of acyclovir and, together with famciclovir, is now widely used.

Table 1

**Pain Management and Supportive Care Measures**

<b>Pain management</b>	<b>Supportive care</b>
2 % viscous lidocaine (swish and spit out 5 mL 4–5 times/d)	Hydration
Liquid diphenhydramine (swish and spit out 5 mL 4–5 times/d)	Rest
Combination of viscous lidocaine, diphenhydramine, and a covering agent (such as Kaopectate or Maalox) in 1:1:1 ratio	Soft bland diet
0.1 % dyclonine hydrochloride	Oral lavage
Benzydamine	Antipyretics such as ibuprofen as needed (avoid aspirin products)
Systemic analgesia	

In recurrent infection the use of topical antiviral medications reduces shedding, infectivity, pain, and the size and duration of lesions. Topical antiviral medications such as 5 % acyclovir cream, 1 % penciclovir cream, and 10 % docosanol cream are efficacious if applied five to eight times a day at the first prodrome or sign of a lesion. Suppression of HSV infection in patients who develop frequent episodes, large lesions, or erythema multiforme is effected with variable doses of acyclovir, valacyclovir, and famciclovir.

**VARICELLA-ZOSTER INFECTION**

**Definition.** In seronegative individuals, primary varicella-zoster virus (VZV) infection is known as *varicella* or chickenpox, while secondary or reactivated disease is known as *herpes zoster* or shingles.

**Etiology.** VZV is believed to be transmitted predominantly through direct contact by contaminated droplets from skin lesions or by the inhalation of aerosolized virus. During the disease process, VZV may progress along sensory nerves to the sensory ganglia, where it can reside in a latent, undetectable form. Reactivation of latent VZV is associated with a decline in cell-mediated immunity in elderly population and can follow the presence of an immunosuppressed state resulting from malignancy (especially lymphomas and leukemias), drug administration, or HIV infection.

**Clinical features.** Primary VZV infection generally occurs in the first two decades of life. Herpes zoster occurs in adults and starts with a prodrome of deep, aching, or burning pain. There is usually little to no fever or lymphadenopathy. This is followed within two to four days by the appearance of crops of vesicles in a dermatomal or “zosteriform” pattern. This pattern describes the unilateral, linear, and clustered distribution of the vesicles, ulcers, and scabs in a dermatome supplied by one nerve. Lesions heal within two to



four weeks, often with scarring and hypopigmentation. One of the most important complications is postherpetic neuralgia, defined as pain that lingers for 120 days after the onset of the acute rash.

Although the thoracic and abdominal nerves are most frequently involved, the facial skin (Fig. 3) and oral mucosa (Fig. 4) supplied by the second or third division of the trigeminal nerve may be the site of infection if the virus is harbored and propagated within the Gasserian ganglion. The vesicles are unilaterally distributed, stop at the midline, and are extremely painful. The most common intraoral sites affected are the anterior half of the tongue, the palate and the cheek. The vesicles break down intraorally within a few hours to give very painful ulcerated areas with a yellowish-gray surface and erythematous borders. The oral lesions heal more quickly than the skin lesions and rarely scar.

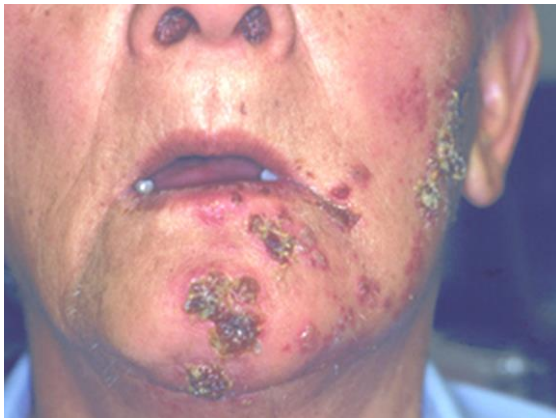

Fig. 3. Facial lesions of herpes zoster

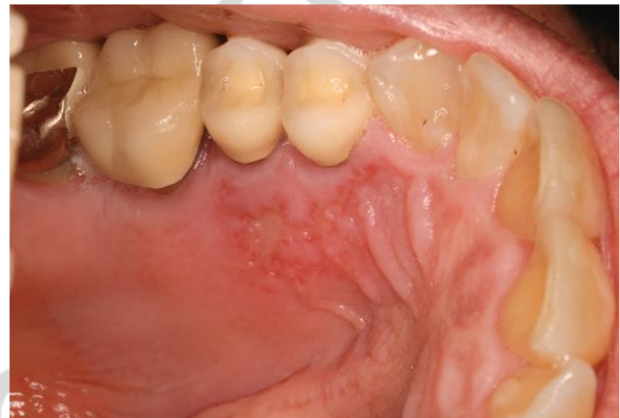

Fig. 4. Herpes zoster of the palate

**Diagnosis.** The clinical presentation is usually characteristic. Unilateral segmental distribution, prevalence in adults, and severe pain are features that allow for clinical diagnosis. Laboratory testing includes the same methods as with HSV infection.

**Differential diagnosis.** The pain that is often experienced in the prodrome before the onset of vesicles and ulcers may lead to an incorrect diagnosis of pulpitis, leading to unnecessary dental treatment such as endodontic therapy.

Herpes zoster is most commonly confused with recurrent HSV infection and may be indistinguishable from it on clinical grounds. Longer duration, greater intensity of prodromal symptoms, unilateral distribution with abrupt ending at the midline, and post-herpetic neuralgia all favor a clinical diagnosis of herpes zoster. Other blistering/ulcerative conditions such as pemphigus or pemphigoid are chronic and/or progressive diseases that do not present unilaterally.

**Treatment.** As with HSV infection, management of oral lesions of varicella-zoster infection is directed toward pain control (particularly, the prevention of postherpetic neuralgia), supportive care, and hydration (see

Table 1), and definitive treatment to minimize the risk for dissemination, particularly in immunocompromised patients. Treatment includes the use of high-dose acyclovir (800 mg five times a day). Valacyclovir (1000 mg three times a day), or famciclovir (500 mg three times a day) for 7 days are also effective. These drugs reduce the incidence of postherpetic neuralgia compared with acyclovir.

## HERPANGINA

**Definition.** Herpangina is an acute self-limiting viral infection, a contagious disease of children characterized by fever, headache, and vesicular eruption in the throat, usually caused by another Coxsackie type A virus (types A1-6, A8, A10, A22, B3, and possibly others).

**Etiology.** The virus is typically transmitted via saliva or occasionally through contaminated feces. The infection is usually endemic, with outbreaks occurring typically in summer or early autumn, while in tropical countries it can occur in any season.

**Clinical features.** Herpangina is a vesicular enanthem (rash on the mucous membranes) and is more common in children aged 3 to 10 than in adults. The disease presents with an acute onset of fever, sore throat, dysphagia, headache, and malaise, followed by diffuse erythema and vesicles. The vesicles are small and numerous, and rupture rapidly, leaving painful ulcers that heal within 7–10 days (Fig. 5). Characteristically, the lesions appear on the soft palate and uvula, tonsillar pillars, and posterior pharyngeal wall. No associated exanthema (skin rash) is typically seen.

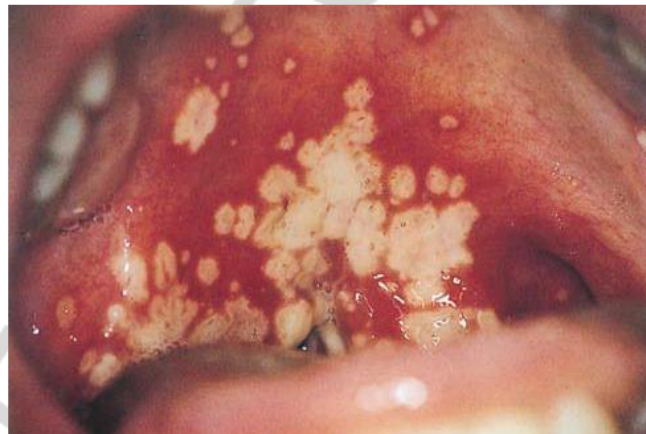

Fig. 5. Herpangina: numerous shallow ulcers on the soft palate

**Diagnosis.** The diagnosis of herpangina is usually based on historical and clinical information.

**Differential diagnosis.** The characteristic distribution and short duration of herpangina separate it from other primary viral infections such as herpetic

gingivostomatitis and varicella. The vesicular eruption, described as having mild symptoms, occurring in summer or early autumn, and with diffuse pharyngitis, also distinguishes the condition from streptococcal pharyngitis, and the systemic symptoms distinguish it from aphthous stomatitis. Laboratory confirmation can be made by virus isolation or by detection of serum antibodies.

**Treatment.** Because herpangina is self-limiting, is mild and of short duration, and causes few complications, treatment beyond local measures at times is usually not required.

## ERYTHEMA MULTIFORME

**Definition.** Erythema multiforme (EM) is an acute, self-limited, inflammatory mucocutaneous disease that manifests on the skin and often oral mucosa, although other mucosal surfaces may also be involved.

**Etiology.** EM presents a hypersensitivity reaction to infectious agents or medications. The most common inciting factors are HSV, mycoplasma and Chlamydia pneumonia. Drug reactions to barbiturates, sulfonamides, analgetics, anticonvulsants, or other drugs play a smaller role. Disease mechanism may be related to antigen-antibody complexes that are targeted for small vessels in the skin or mucosa.

**Clinical features.** Young adults are most commonly affected. Individuals often develop EM in the spring or fall and may have such recrudescences chronically. There may be a prodrome of fever, malaise, headache, sore throat, rhinorrhea, and cough. The term erythema multiforme was coined to indicate the multiple and varied clinical appearances that are associated with cutaneous manifestations of this disease. The classic skin lesion of EM is the target or iris lesion (Fig. 6). It consists of a central blister or necrosis with concentric rings of variable color. Typically, the extremities are involved, usually in a symmetric distribution. Other types of skin manifestations of EM include macules, papules, vesicles, bullae, and urticarial plaques.

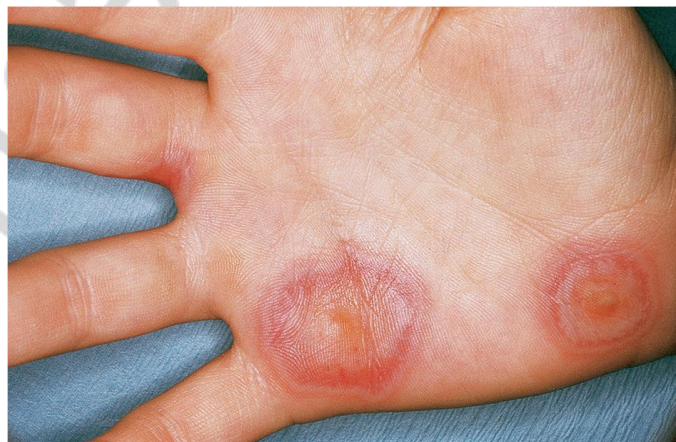

Fig. 6. EM cutaneous target lesions

The oral findings in EM range from mild erythema and erosion to large painful ulcerations. Short-lived vesicles or bullae are infrequently seen at initial presentation. Within the mouth any area may be involved, with the lips, buccal mucosa and tongue being most frequently affected. Extensive lip involvement with inflammation, ulceration, and crusting (Fig. 7) is common, but not always present. The symptoms range from mild discomfort to severe pain.

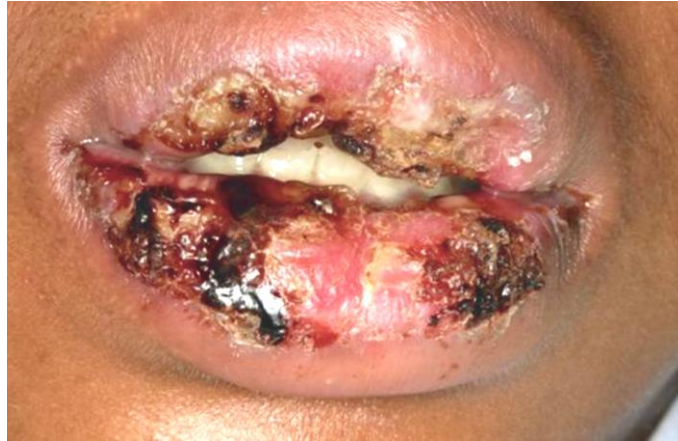

Fig. 7. EM with hemorrhagic crusts of the lips

**Diagnosis.** The diagnosis is made primarily on clinical findings and a recent history of infection or drug ingestion. Target lesions of skin, severe involvement of the lips, and slight elevation of temperature are indicative of EM. Immunopathologic studies are nonspecific. Biopsy should be performed to rule out the other bullous dermatoses.

**Differential diagnosis.** Primary HSV gingivostomatitis with its viral prodrome and erosions and ulcerations may resemble oral EM, but these lesions are culture positive for HSV and do not present with the typical skin rash. Oral ulcers of HSV are usually smaller and well circumscribed, whereas EM lesions are larger and irregular.

Autoimmune vesiculobullous disease such as pemphigus and pemphigoid may have oral ulcers and skin lesions, although skin lesions are bullous in nature and not maculopapular, without the centripetal progression seen in EM. They are chronic, slowly progressive diseases that usually persist for months, whereas EM heals within weeks.

Recurrent oral EM in the absence of skin findings may be confused with recurrent aphthous ulcers, but aphthous ulcers present as discrete ovoid or round ulcers, whereas ulcers of EM are more diffuse and irregular with marked erythema.

**Treatment.** Mild oral EM can be managed with systemic or topical analgesics for pain and supportive care (oral irrigation, adequate fluid intake, soft diet, use of antipyretics) since the disease is self-limiting and resolves within a few weeks. More severe cases are usually managed with systemic

corticosteroids although patients often worsen on discontinuation of steroid therapy. Topical steroids may also help resolve lesions. Cases suspected of having HSV-associated EM should be treated with antiviral medications (400 mg acyclovir daily).

## STEVENS–JOHNSON SYNDROME

**Definition.** Stevens–Johnson syndrome (SJS), or erythema multiforme major, or bullous erythema multiforme, is a less severe variant of Toxic Epidermal Necrolysis that predominantly affects the mucous membranes.

**Etiology.** Severe hypersensitivity reaction to different allergens. SJS is much more likely to be associated with medication use and *Mycoplasma pneumoniae* infection (especially in children) and rarely with HSV infection. The more common inciting drugs include antibacterial sulfonamides, penicillin, anticonvulsants, and NSAIDs in children and allopurinol, oxicams, and nevirapine in adults.

**Clinical features.** Adults between the age of 20 and 40 are most commonly affected, with 20 % of the cases occurring in children with a slight predilection for females. The oral lesions are always present, and are characterized by extensive bullae, erosions, ulcers, and hemorrhagic crusts on the vermilion (Fig. 8). The lesions may extend to the pharynx, larynx, and esophagus. The ocular lesions consist of conjunctivitis, uveitis, symblepharon, or even panophthalmitis. The genital lesions are balanitis or vulvovaginitis, and scrotal erosions. The skin lesions of SJS are different from EM. They are more severe and tend to arise on the chest rather than the extremities on erythematous and purpuric macules; these lesions are called “atypical targets.”

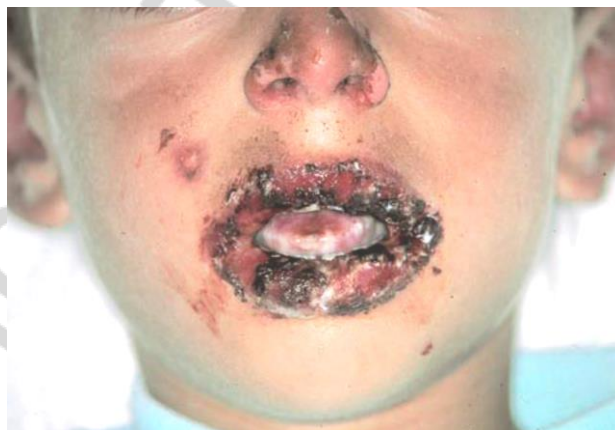

Fig. 8. Stevens–Johnson syndrome: severe erosions on the lips, tongue, and the nose in an 8-year-old boy

**Diagnosis.** The diagnosis is mainly made on the basis of the clinical presentation. A careful history taking and bloodwork as mentioned above are essential for establishing whether the trigger is infectious or medication-induced.

**Differential diagnosis.** The bullous and erosive lesions of Stevens-Johnson syndrome may be confused with other bullous dermatoses. The triad of oral, eye, and genital involvement is classic for SJS. This distribution should not present a problem when differentiating this disease from the mucocutaneous lesions of Behcet's syndrome and Reiter's disease because these latter two disorders manifest aphthous-like ulcerations rather than desquamating bullae of the oral cavity.

**Treatment.** Because of the severity of this condition, treatment is generally with intensive supportive care because of loss of skin barrier. Intravenous immunoglobulin, systemic steroids, antibiotics, cyclosporine, plasmapheresis, cyclophosphamide, and TNF- $\alpha$ inhibitor are usually used.

## PEMPHIGUS VULGARIS

**Definition.** Pemphigus includes a group of autoimmune, potentially life-threatening diseases that cause blisters and erosions of the skin and mucous membranes, characterized by intraepithelial acantholysis. Pemphigus vulgaris (PV) is the most common form of pemphigus, accounting for more than 80 % of cases.

**Etiology.** The disease has an autoimmune etiology. The predisposition for developing the autoantibodies that cause pemphigus is genetically determined, but the triggering mechanism that initiates the immune response is unknown. The underlying mechanism responsible for causing the intraepithelial lesion of PV is the binding of IgG autoantibodies to desmoglein 3, a transmembrane glycoprotein adhesion molecule present on desmosomes. The loss of this glycoprotein results in loss of cell-to-cell adhesion resulting in intra-epithelial blisters.

**Clinical features.** Middle-aged and elderly adults are usually affected, the incidence of pemphigus vulgaris is unaffected by gender. The disease is persistent and progressive. The classic lesion of PV is a thin-walled bulla arising on otherwise normal skin or mucosa. The bulla rapidly breaks but continues to extend peripherally. A characteristic sign of the disease may be obtained by applying pressure to an intact bulla. In patients with PV, the bulla enlarges by extending to an apparently normal surface. Another characteristic sign of the disease is that pressure to an apparently normal area results in the formation of a new lesion. This phenomenon, called the Nikolsky sign, results from the upper layer of the skin pulling away from the basal layer. If left untreated, the disease may be fatal due to dehydration and septicemia.

Up to 80–90 % of patients with PV develop oral lesions sometime during the course of the disease, and in 60 % of cases, the oral lesions are the first sign. The oral lesions may begin as the classic bulla on a noninflamed base; more frequently, the clinician sees shallow irregular erosions and ulcers because

the bullae rapidly break. The edges of the lesion continue to extend peripherally over a period of weeks until they involve large portions of the oral mucosa. The lesions are usually painful. Most commonly, the lesions start on the buccal mucosa, often in areas of trauma along the occlusal plane (Fig. 9). The palatal mucosa and gingiva are other common sites of involvement. In some cases, the lesions may start on the gingiva as desquamative gingivitis (Fig. 10).

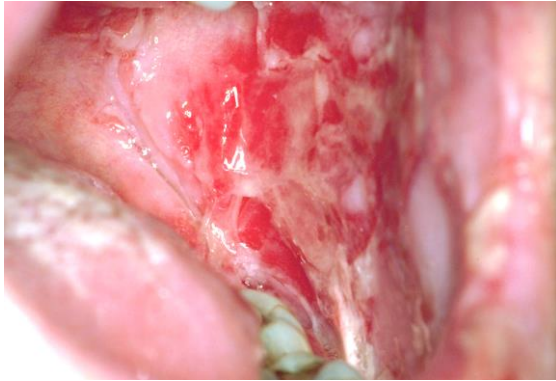

Fig. 9. Oral pemphigus vulgaris

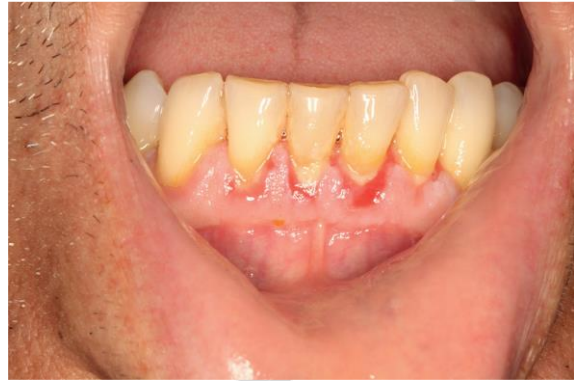

Fig. 10. Pemphigus vulgaris presenting as erosions of the gingiva

**Diagnosis.** Diagnosis is made on the basis of history and examination, biopsy and blood tests. Biopsy is necessary to distinguish the condition from other vesiculobullous disorders and to confirm the presence of autoantibodies in the tissues. It is important to biopsy peri-lesional rather than lesional tissue. Pemphigus vulgaris appears as intraepithelial clefting with keratinocyte acantholysis. Loss of desmosomal attachments and retraction of tonofilaments result in free-floating, or acantholytic, Tzanck cells. Bullae are suprabasal, and the basal layer remains attached to the basement membrane.

In addition to standard biopsy, confirmation of pemphigus vulgaris can be made with the use of direct immunofluorescence (DIF) testing. It uses a biopsy specimen in an attempt to demonstrate autoantibodies already attached to the tissue. This is preferable to less sensitive indirect immunofluorescence, which uses patient serum to identify circulating antibodies.

To identify the antigens more precisely immunoblotting, enzyme linked immunoabsorbant assay and immuno precipitation tests can also be used.

**Differential diagnosis.** If an accurate history and examination is performed, the clinician should be able to distinguish the lesions of pemphigus from those caused by acute viral infections or EM because of the acute nature of the latter diseases. It is also important for the clinician to distinguish pemphigus lesions from RAS. RAS lesions may be severe, but individual lesions heal and recur. In pemphigus, the same lesions continue to extend peripherally over a period of weeks to months. Lesions of PV are not round and symmetric like RAS lesions but are shallow and irregular and often have detached epithelium at the periphery.

It should be remembered that desquamative gingivitis is not a diagnosis in itself; these lesions must be biopsied to distinguish PV from subepithelial blistering diseases such as mucous membrane pemphigoid.

**Treatment.** Pemphigus vulgaris should be treated by a general physician or dermatologist; high-dose, long-term systemic steroid therapy is required for control of the disease. With severe dermal involvement, fluid/electrolyte balance must be controlled and septicemia must be prevented. Immunosuppressive drugs in conjunction with prednisone allows for lower steroid dosage. Most recently the use of targeted therapy in the form of an anti-CD 20 monoclonal antibody (rituximab) has been very effective in cases of severe or unresponsive disease, with effective outcomes.

Topical corticosteroids may be used intraorally as an adjunct to systemic therapy. Because topical steroids can facilitate the overgrowth of *Candida albicans* orally, antifungal therapy may be needed, especially with use of high-potency corticosteroids.

### **MUCOUS MEMBRANE PEMPHIGOID (CICATRICAL PEMPHIGOID)**

**Definition.** Mucous membrane pemphigoid (MMP) is a chronic autoimmune subepithelial disease that primarily affects the mucous membranes of patients older than the age of 50 years, resulting in mucosal blistering, ulceration, and subsequent scarring in some organs.

**Etiology.** MMP is an autoimmune process with an unknown stimulus or etiology. The primary lesion of MMP occurs when autoantibodies directed against proteins in the basement membrane zone, acting with complement (C3), cause a subepithelial split and subsequent vesicle formation.

**Clinical features.** The disease occurs twice as frequently in women. Lesions of MMP may involve any mucosal surface, but the oral mucosa is involved in more than 80 % of cases, rarely with scarring. The conjunctiva is the second most common site of involvement and can lead to scarring and adhesions developing between the bulbar and palpebral conjunctiva called symblepharon. Skin lesions, usually of the head and neck region, are present in 20–30 % of patients.

In the oral cavity any area may be affected but lesions on the hard and soft palate, buccal mucosa and gingivae are common. Lesions may present as intact vesicles or tense fluid-filled bullae (Fig. 11), but more frequently they appear as nonspecific-appearing erythema and erosions. Desquamative gingivitis is the most common manifestation and may be the only manifestation of the disease appearing bright red (Fig. 12). Because of patient discomfort, routine oral hygiene is often compromised. This results in dental plaque accumulation, which in turn superimposes an additional, but nonspecific, inflammatory



response. With chronicity, the pain associated with oral MMP typically diminishes in intensity.

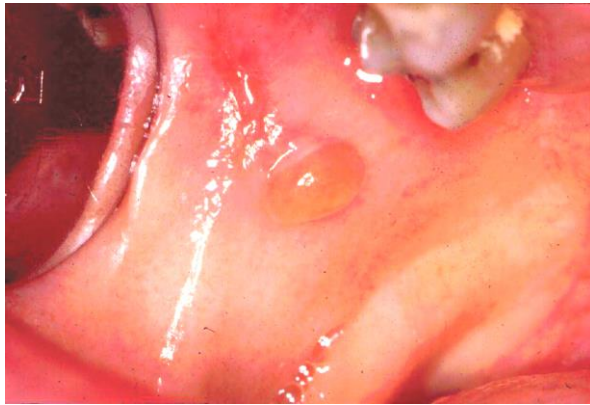


Fig. 11. Intact vesicle of buccal mucosa in a patient with mucous membrane pemphigoid

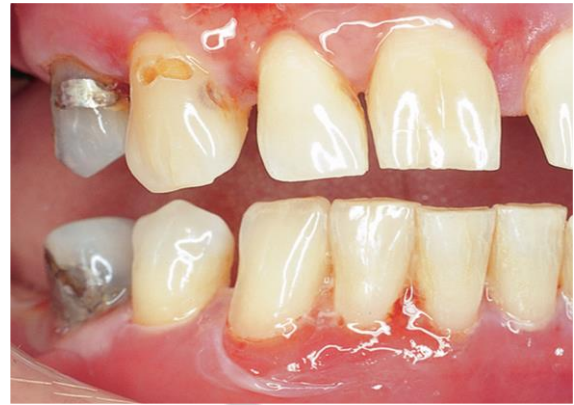

Fig. 12. Mucous membrane pemphigoid of the gingiva

**Diagnosis.** Patients with suspected MMP should have biopsy specimens taken for both routine and DIF studies. The specimen for routine histology and DIF should be taken from the edge of an ulcer, vesicle, or erythema and tissue. Histopathology reveals subepithelial clefting with preservation of basal cells and variable inflammation. Direct immunofluorescence shows basement membrane linear distribution of IgG, complement fraction 3, and IgA.

**Differential diagnosis.** The clinical differential diagnosis for this vesiculobullous disease must include pemphigus vulgaris and erosive lichen planus (LP) among others (Table 2). The erosive and ulcerative forms of LP frequently exhibit white Wickham striae at the periphery, along with ulcerations and erosions. PV usually has more extensive erosion of mucosa as well as skin involvement, and the lesions do not have the inflammation associated with MMP.

Table 2

**Pemphigus Vulgaris versus Mucous Membrane Pemphigoid**

	<b>Pemphigus</b>	<b>Pemphigoid</b>
Tissue antibody	IgG, C3 Circulating auto-IgG	IgG, IgA, C3 No circulating auto-IgG
Target protein(s)	Desmoglein 3 (desmosomes)	Lamin5 and BP180 (basement membrane)
Vesicles	Intraepithelial	Subepithelial
Sites	Oral and skin	Oral and eyes
Treatment	Corticosteroids, steroid sparing agents; rituximab	Corticosteroid
Prognosis	Fair, significant mortality if untreated	Good, significant morbidity

When the attached gingiva is the exclusive site of involvement, atrophic lichen planus, linear IgA disease, discoid lupus erythematosus, and contact allergy should be included. Final diagnosis will usually require DIF confirmation.

MMP also resembles bullous pemphigoid which is the most common subepithelial, blistering disorder affecting the skin and oral lesions are uncommon (10–20 % cases).

**Treatment.** Management of MMP depends on the severity of symptoms and site of involvement. When the lesions are confined to the oral mucosa, use of systemic corticosteroids should only be considered for short periods. Unlike PV, MMP is rarely a fatal disease, and long-term use of systemic steroids for oral lesion involvement alone is seldom indicated.

Patients with mild oral disease may be treated with topical and intralesional steroids. Desquamative gingivitis can often be managed with topical steroids in a soft dental splint that covers the gingiva, although the clinician using topical steroids over large areas of mucosa must closely monitor the patient for side effects such as candidiasis and effects of systemic absorption. Scrupulous oral hygiene, including use of chlorhexidine rinses, further enhances the effectiveness of topical corticosteroids when gingival involvement is marked.

## CONTACT STOMATITIS

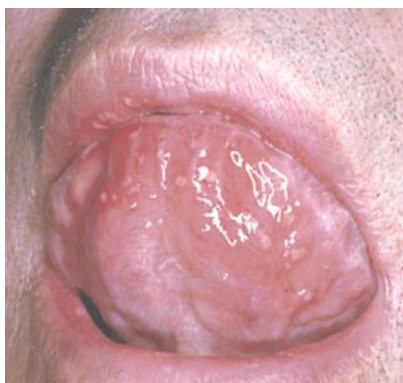**Definition.** Contact stomatitis is immediate or humorally mediated immune reaction to allergens contacting the oral mucous membranes.

**Etiology.** Intraorally, various substances may elicit hypersensitivity responses in patients who are allergic. Specifically, mouthwashes, dentifrices, lipstick, acrylic, topical antibiotics, and foods can be responsebed. Cosmetic products contain various chemical agents, such as the methyl paraben, colophony, para phenylene diamine, flavours (e.g., cinnamic aldehyde, cinnamon oil and peppermint) and preservatives. Para phenylene diamine (35 %) is the most common allergen followed by balsam peru (22.5 %) and parabens (19.25 %).

**Clinical features.** The clinical picture of contact stomatitis depends on the type of products used (and consequently, the sites of application) and the degree of the patient's sensitivity. Symptoms include stomatitis, cheilitis, glossitis, gingivitis, perioral dermatitis and immediate hypersensitivity. Usually, cosmetics and their ingredients are weak allergens, and the lesion resulting from cosmetic allergy is mild: erythema, mild edema, vesiculation, desquamation and papules. The vesicles do not tend to cluster and are superimposed on a broad matted erythematous base (Fig. 13). Pain or burning, rather than pruritus, is present. The lesions regress within 3 to 5 days, providing repeated contact with allergen is avoided.

**Diagnosis.** The diagnosis should initially be suspected based on the patient history, physical examination and the distribution of the lesions. Patients who present with allergic reaction should be patch tested with the standard series, all possibly relevant personal products, such as lipsticks, toothpastes, oral rinses, cleansers, mouthwashes and dentifrices, and a cosmetics series, including

fragrances, preservatives, base ingredients and UV-filters. Intraepithelial vesicles are present. In microscopic examination the vesicular contents are composed of an eosinophilic exudate and an acute inflammatory cell infiltrate composed of both neutrophils and eosinophils.



*Fig. 13.* Multiple vesicles and small ulcers appearing as a manifestation of allergy to various substances

**Differential diagnosis.** The vesicular eruption of allergic mucositis may resemble primary herpes and erythema multiforme. Because the patient is afebrile, this feature tends to eliminate the aforementioned diseases from the differential diagnosis. Questioning the patient with regard to the use of newly contacted materials or chemicals usually provides the necessary clue to the nature of the allergen.

**Treatment.** Suspected contact allergens should be discontinued. Steroid creams or ointments, topically applied, help soothe the rash of contact stomatitis. A topical steroid may be applied one or two times a day for two to four weeks. In severe cases, prescribe oral corticosteroids to reduce inflammation, antihistamines to relieve itching or antibiotics to fight a bacterial infection.

## BIBLIOGRAPHY

1. Казеко, Л. А. Диагностика в терапевтической стоматологии = Diagnostic procedures in therapeutic dentistry : учеб.-метод. пособие / Л. А. Казеко, Е. Л. Колб. Минск : БГМУ, 2016. 51 с.
2. *Application of the International Classification of Diseases to Dentistry and Stomatology (ICD-DA)*. 3<sup>rd</sup> ed. Geneva, World Health Organization, 1995. 239 p.
3. *Glick, M. Burket's Oral Medicine* / M. Glick, W. M. Feagans. 12<sup>th</sup> ed. Shelton, CT : People's Medical Publishing House — USA, 2015. 716 p.
4. *Eversole, L. R. Clinical Outline of Oral Pathology : Diagnosis and Treatment* / L. R. Eversole. 4<sup>th</sup> ed. Shelton, CT : People's Medical Publishing House — USA, 2011. 738 p.
5. *Warnakulasuriya, S. Oral Medicine and Pathology: A Guide to Diagnosis and Management* / S. Warnakulasuriya, W.M. Tilakarante. New Delhi : Jaypee Brothers Medical Publishers, 2014. 563 p.
6. *Regezi, J. A. Oral Pathology : Clinical Pathologic Correlations* / J. A. Regezi, J. J. Sciubba, R. C. K. Jordan. 7<sup>th</sup> ed. Elsevier, 2017. 473 p.

## CONTENTS

Motivational characteristic of the theme .....	3
Vesiculobullous lesions .....	4
Herpes simplex infection .....	5
Varicella-zoster infection.....	7
Herpangina.....	9
Erythema multiforme.....	10
Stevens–Johnson syndrome .....	12
Pemphigus vulgaris.....	13
Mucous membrane pemphigoid (cicatricial pemphigoid).....	15
Contact stomatitis .....	17
Bibliography .....	18

РЕПОЗИТОРИЙ БГМУ

Учебное издание

**Полянская** Лариса Николаевна  
**Захарова** Ирина Анатольевна

**ВЕЗИКУЛОБУЛЛЕЗНЫЕ ПОРАЖЕНИЯ  
СЛИЗИСТОЙ ОБОЛОЧКИ ПОЛОСТИ РТА**  
**VESICULOBULLOUS LESIONS OF ORAL MUCOSA**

Учебно-методическое пособие

На английском языке


Ответственная за выпуск Т. Н. Манак  
Переводчик Л. Н. Полянская  
Компьютерная вёрстка Н. М. Федорцовой

Подписано в печать 23.09.20. Формат 60×84/16. Бумага писчая «Херох office».  
Ризография. Гарнитура «Times».  
Усл. печ. л. 1,16. Уч.-изд. л. 1,1. Тираж 80 экз. Заказ 461.

Издатель и полиграфическое исполнение: учреждение образования  
«Белорусский государственный медицинский университет».  
Свидетельство о государственной регистрации издателя, изготовителя,  
распространителя печатных изданий № 1/187 от 18.02.2014.  
Ул. Ленинградская, 6, 220006, Минск.

ЛОЗИТОРИЙ БГМУ

ISBN 978-985-21-0649-8



9 789852 106498