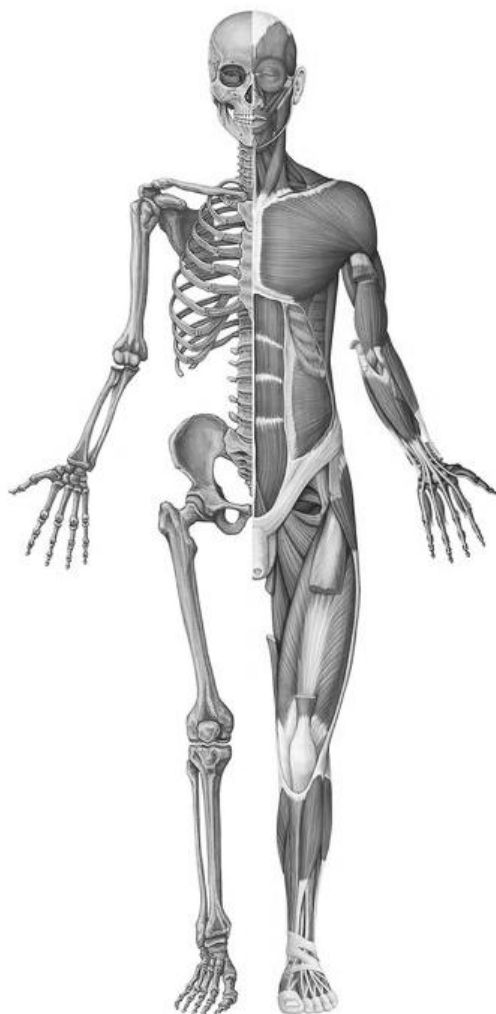


S. L. KABAK, V. V. ZATOCHNAYA, N. V. ZHURAVLEVA

MUSKULOSKELETAL SYSTEM



Minsk BSMU 2024

МИНИСТЕРСТВО ЗДРАВООХРАНЕНИЯ РЕСПУБЛИКИ БЕЛАРУСЬ
БЕЛОРУССКИЙ ГОСУДАРСТВЕННЫЙ МЕДИЦИНСКИЙ УНИВЕРСИТЕТ
КАФЕДРА МОРФОЛОГИИ ЧЕЛОВЕКА

С. Л. КАБАК, В. В. ЗАТОЧНАЯ, Н. В. ЖУРАВЛЁВА

**ОПОРНО-ДВИГАТЕЛЬНЫЙ
АППАРАТ
MUSKULOSKELETAL SYSTEM**

Практикум по анатомии человека

2-е издание, исправленное и дополненное



Минск БГМУ 2024

УДК 611.7(076.5)(075.8)-054.6
ББК 28.706я73
К12

Рекомендовано Научно-методическим советом университета в качестве
практикума 30.04.2024 г., протокол № 16

Рецензенты: канд. мед. наук, доц. каф. нормальной анатомии Белорусского государственного медицинского университета А. А. Пасюк; каф. анатомии человека с курсом топографической анатомии и оперативной хирургии Гомельского государственного медицинского университета

Кабак, С. Л.

К12 Опорно-двигательный аппарат = Muskuloskeletal system : практикум по анатомии человека / С. Л. Кабак, В. В. Заточная, Н. В. Журавлёва. – 2-е изд., испр. и доп. – Минск : БГМУ, 2024. – 52 с.

ISBN 978-985-21-1630-5.

Содержит контрольные вопросы и учебные задания по разделам «Остеология», «Артросиндесмология» и «Миология». Контрольные вопросы ориентированы на приоритетные разделы изучаемой темы. Учебные задания по каждой теме занятия представлены в виде оригинальных рисунков и схем, что позволяет студенту осуществить самоконтроль уровня знаний. Включает перечень специализированных терминов с их толкованием (глоссарий). Первое издание вышло в 2023 году.

Предназначен для аудиторной и самостоятельной работы студентов 1-го курса медицинского факультета иностранных учащихся, обучающихся на английском языке по специальности «Стоматология».

УДК 611.7(076.5)(075.8)-054.6
ББК 28.706я73

Учебное издание

Кабак Сергей Львович
Заточная Валентина Владимировна
Журавлёва Наталья Викторовна

ОПОРНО-ДВИГАТЕЛЬНЫЙ АППАРАТ

MUSKULOSKELETAL SYSTEM

Практикум по анатомии человека

На английском языке

2-е издание, исправленное и дополненное

Ответственный за выпуск С. Л. Кабак
Компьютерная вёрстка Н. М. Федорцовой

Подписано в печать 26.08.24. Формат 60×84/8. Бумага писчая «Снегурочка».
Ризография. Гарнитура «Times». Усл. печ. л. 6,04. Уч.-изд. л. 3,4. Тираж 68 экз. Заказ 442.

Издатель и полиграфическое исполнение: учреждение образования
«Белорусский государственный медицинский университет».
Свидетельство о государственной регистрации издателя, изготовителя,
распространителя печатных изданий № 1/187 от 24.11.2023.
Ул. Ленинградская, 6, 220006, Минск.

ISBN 978-985-21-1630-5

© Кабак С. Л., Заточная В. В., Журавлёва Н. В., 2024
© УО «Белорусский государственный
медицинский университет», 2024

INTRODUCTION

The study of Human Anatomy involves memorizing a large amount of information and a lot of special terms. It is important not only to remember this or that term, but also understand the composition of the structure it denotes. This approach involves mastering the applied knowledge necessary for subsequent clinical training.

Taking into account that junior students are not adapted to higher education, and the logical components of their thinking are not yet formed, there are real challenges in mastering the curriculum in Human Anatomy. This guide will help the students cope with the difficulties and is aimed at organizing their educational activities in the most efficient way. Due to the presence of control questions focused on the basic concepts of the topics studied, a differentiated approach to the selection of educational material is implemented. The selective principle is also applied to the list of terms that are required for memorization. Assignments for independent work — drawings, diagrams, tables, etc. — help the student not only “see” the studied object, but also form an idea of its topography. The indisputable advantage of this publication is the glossary, which includes a list of specialized terms with their interpretation.

This practical work guide is intended for first-year students majoring in “Dentistry” 7-07-0911-03.

It documents students’ independent work and must be completed in accordance with the requirements formulated below.

1. The tasks included in the practical work guide are performed by the student in the process of self-study on the subject of the lesson.
2. Signatures to drawings, designations of structures, completing the tables, etc., should be carried out accurately, competently and in accordance with anatomical terminology.
3. The quality of accomplishing the tasks is assessed by the teacher at the lesson.
4. The correctness of completing the practical work guide is taken into account when giving final grades on the sections of the discipline under study.
5. Constructive suggestions of students on the content and design of the practical work guide can be taken into account when it is reissued.

LABORATORY CLASS № 1
ANATOMY AS AN ACADEMIC DISCIPLINE. THE AXIAL SKELETON
VERTEBRAL COLUMN. THORAX SKELETON

Control questions:

1. Methods of studying the structure of the human body.
2. The concept of planes and axes.
3. Anatomical terminology.
4. Classification of bones.
5. The axial skeleton. The vertebral column: departments, functions. Formation of the spinal column curvatures.
6. The general structure of a vertebra.
7. The structure of the cervical vertebrae. The structural features of the first, second and seventh cervical vertebrae.
8. The structure of the thoracic, lumbar and sacral vertebrae.
9. Sternum: position, structure.
10. Classification of ribs. The structure of the ribs. The structural features of the first rib.
11. The skeleton of thorax. The boundaries of the upper and lower apertures, costal margin, infrasternal angle. Age and individual differences of thorax.

Students should be able to find on anatomical preparations and visual aids following structures and to know their Latin names:

Spine. 1. Spinal canal. 2. Cervical vertebra. 3. Thoracic vertebra. 4. Lumbar vertebra. 5. Sacral vertebrae (sacrum). 6. Coccygeal vertebrae (coccyx). 7. Vertebral body. 8. Vertebral arch. 9. Intervertebral foramen. 10. Superior (inferior) vertebral notch. 11. Transverse process. 12. Superior (inferior) articular process. 13. Spinous process. 14. Foramen transversarium. 15. Atlas. 16. Lateral mass of atlas. 17. Superior (inferior) articular surface of atlas. 18. Anterior (posterior) arch of atlas. 19. Dens of axis.

Skeleton of thorax. 1. Thorax. 2. Superior (inferior) aperture of thorax. 3. Costal margin. 4. Infrasternal (subcostal) angle. 5. Sternum. 6. Manubrium, body of sternum. 7. Xiphoid process. 8. Jugular, clavicular notches. 9. Sternal angle. 10. Costal notches. 11. Rib. 12. Head of rib. 13. Neck of rib. 14. Body of rib. 15. Tubercle of rib. 16. Angle of rib. 17. Costal groove.

GLOSSARY

Skeleton is the framework of bones and cartilage that supports and protects the soft tissues and the internal organs of the body. The major functions of the skeletal system are body support, facilitation of movement, protection of internal organs, storage of minerals and fat, and blood cell formation. The skeleton is subdivided into two divisions: the axial skeleton, the bones that form the longitudinal axis of the body, and the appendicular skeleton, the bones of the limbs and girdles.

Axial skeleton forms the longitudinal axis of the body, is divided into three parts: the skull, the vertebral column, and the bony thorax.

Appendicular skeleton is composed of bones of the limbs and the pectoral and pelvic girdles, which attach the limbs to the axial skeleton

Vertebral column (*columna vertebralis*) extends from the skull, which it supports, to the pelvis, where it transmits the weight of the body to the lower limbs. It consists of vertebrae separated by intervertebral discs. The vertebral column houses the spinal canal, a cavity that encloses and protects the spinal cord. The vertebral column consists of 33 vertebrae in total, divided as follows: cervical (7), thoracic (12), lumbar (5), sacrum (5 fused), coccyx (3–4 fused).

Kyphosis is a convex curvature of the spine as it occurs in the thoracic and sacral regions.

Lordosis is the inward curve of the spine, often in the neck (cervical lordosis) or lower back (lumbar lordosis).

Scoliosis is an abnormal lateral curvature of the spine. It is most often diagnosed in childhood or early adolescence. Expressed scoliosis refers to pathological curvatures.

Typical **vertebra** (*vertebra*) consists of two parts: the vertebral body and the vertebral arch. Together, these enclose the vertebral foramen, which contains the spinal cord. The vertebral arch is formed by a pair of pedicles and a pair of laminae, and supports seven processes, four articular, two transverse, and one spinous, the latter also being known as the neural spine.

Cervical vertebrae (*vertebrae cervicales*, C_1 – C_7) are the vertebrae of the neck. Have distinctive features like small size, transverse foramina, two tubercles (anterior, posterior) and split (bifid) spinous processes. The atlas (C_1) consists of two arches (anterior, posterior) and contains two lateral masses. The masses articulate with the occipital condyles of the skull, supporting its weight. The axis (C_2) contains an upwards tooth-like projection (dens or odontoid process) and two superior articular facets. Vertebra prominens (C_7) has the longest spinous process.

Thoracic vertebrae (*vertebrae thoracicae*, Th_1 – Th_{12}) form the thoracic spine (upper back). They play a role in forming the thoracic cage. Thoracic vertebrae contain several distinctive features: costal facets that articulate with the ribs, heart shaped vertebral bodies, smaller vertebral foramina, and long and strong spinous and transverse processes which point inferiorly.

Lumbar vertebrae (*vertebrae lumbales*, L_1 – L_5) form the lumbar spine (lower back). They have the largest vertebral bodies in the entire vertebral column. The pedicles and laminae are thick and strong. Their spinous processes are short. The articular processes are oriented in sagittal plane. The lumbar spine also contains accessory and mammillary processes.

Sacrum (*sacrum*) consists of five sacral vertebrae (*vertebrae sacrales*, S_1 – S_5) fused together. The sacrum has a base, an apex, and three surfaces (pelvic, posterior, lateral). Within its center is the sacral canal which is the continuation of the spinal canal. The sacral canal contains the cauda equina of the spinal cord.

Coccyx (*coccyx*) articulates with the sacrum and consists of three to four fused coccygeal vertebrae (*vertebrae coccigeae*). It has two surfaces (pelvic, posterior), short transverse processes, and coccygeal cornua.

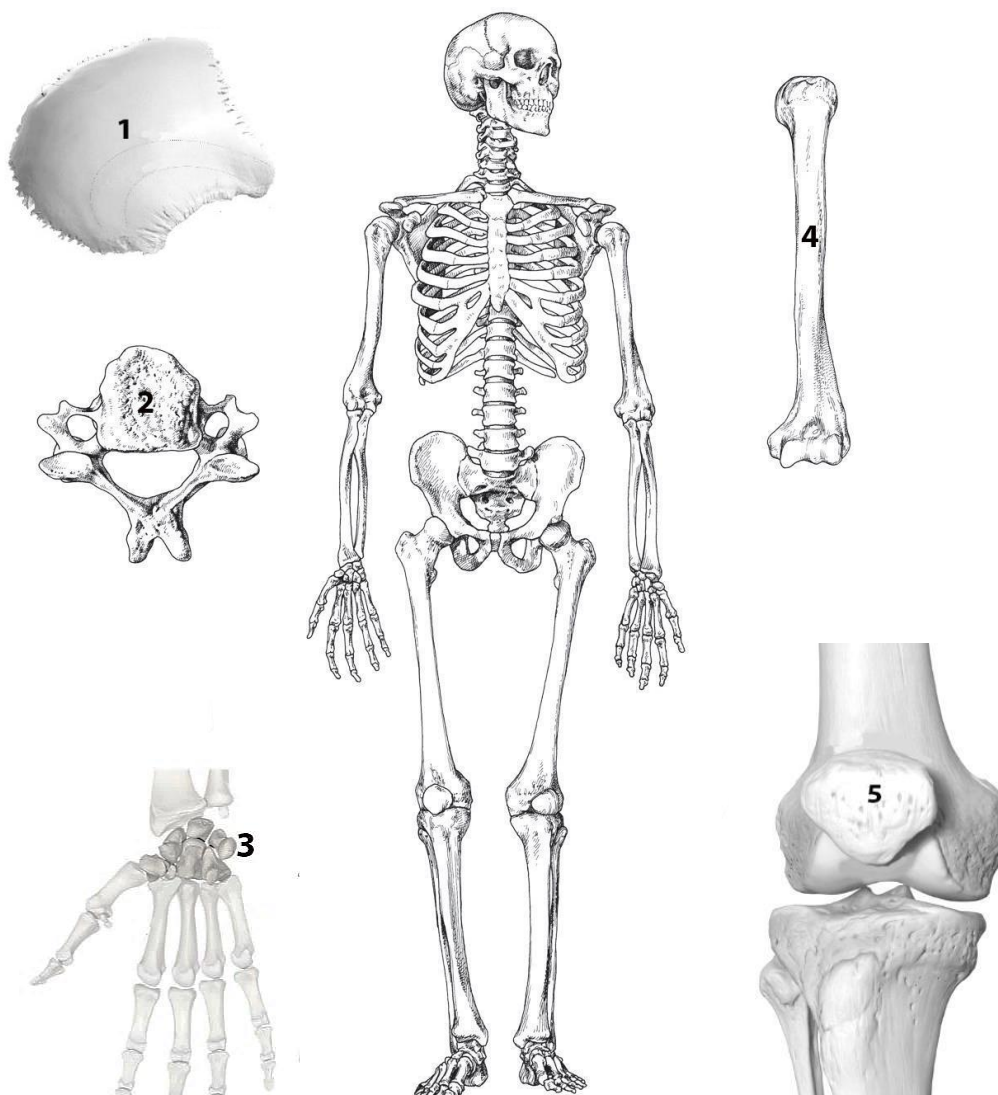
Thoracic cage (*cavea thoracis*), also known as the rib cage, is the osteocartilaginous structure that encloses the thorax. It is formed by the 12 thoracic vertebrae, 12 pairs of ribs and associated costal cartilages and the sternum.

Sternum (*sternum*) is an unpaired flat bone that forms anterior part of the thoracic wall. It has manubrium, body and xiphoid process. It is connected with the clavicles and the first seven pairs of costal cartilage.

Rib (*costa*) consists of the bone part and costal cartilage. Ribs are curved, flat bones which form the majority of the thoracic cage. There are 12 pairs of ribs, all of which articulate with the vertebral column. Ribs I–VII attach directly to the sternum there are true ribs. Ribs VIII–XII attach to the costal cartilages superior to them (false ribs). Ribs XI–XII do not have an anterior attachment and end in the abdominal musculature (floating ribs). Each typical rib consists of the head, neck, tubercle and body.

SELF-INSTRUCTIONAL MATERIALS

Bone classification



COLOR each skeleton region a different color to differentiate them from one another:

- Axial skeleton
- Appendicular skeleton

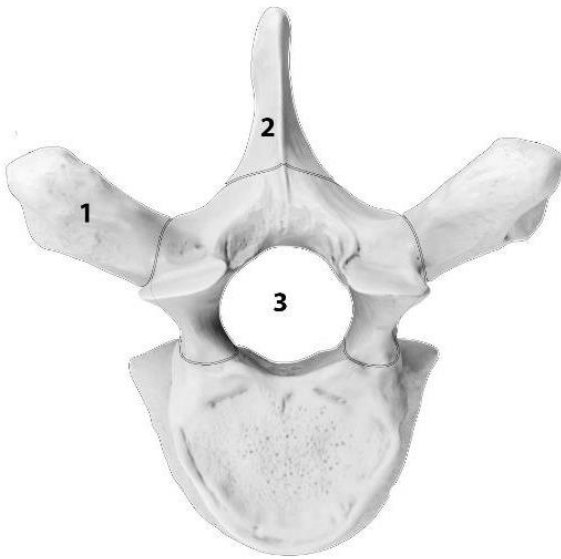
Axial skeleton includes: _____

Appendicular skeleton includes: _____

WRITE the name of the five different types of bones:

1. Flat bone (_____ bone)
2. Irregular bone (_____)
3. Short bone (_____ bones)
4. Long bone (_____)
5. Sesamoid bone (_____)

Typical thoracic vertebra (top view)



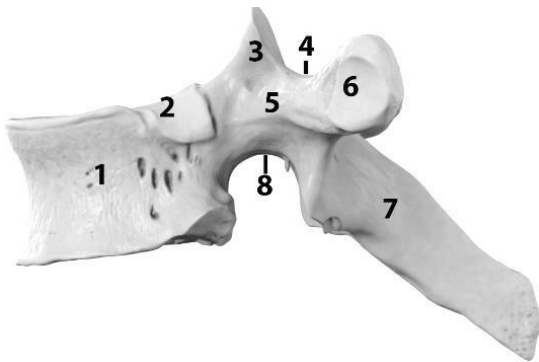
COLOR the following three parts of vertebra:

- Vertebral body
- Vertebral arch
- Processes

WRITE the name of structures labeled by the number:

- 1. _____ process
- 2. _____ process
- 3. Vertebral _____

Typical thoracic vertebra (side view)

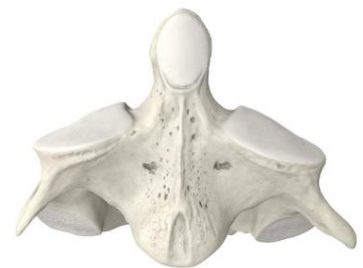
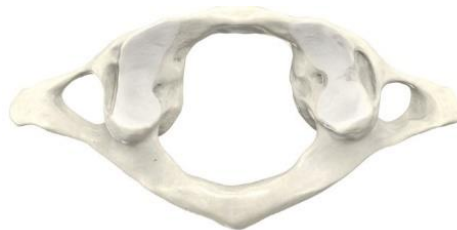
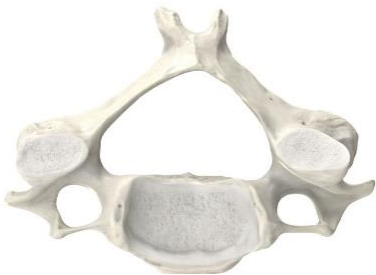WRITE the name of structures labeled by the number:

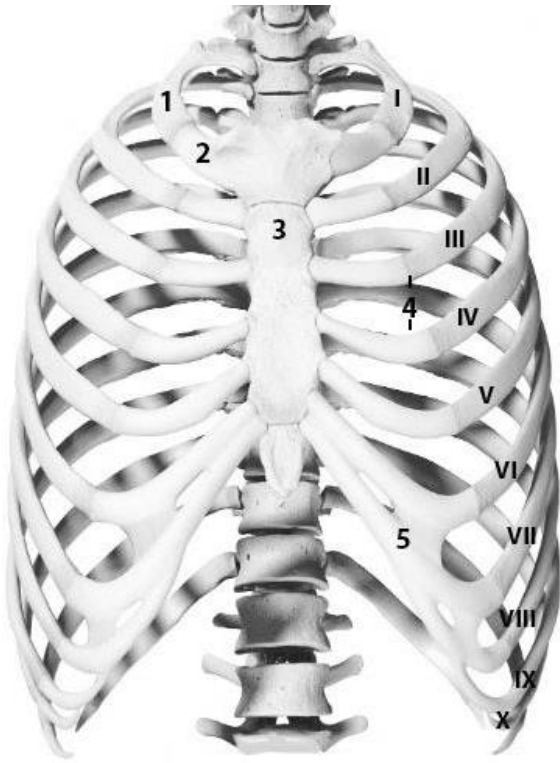
- 1. Vertebral _____
- 2. _____ facet
- 3. _____ process
- 4. _____ notch
- 5. Vertebral _____
- 6. _____ facet
- 7. _____ process
- 8. _____ notch

Cervical vertebrae

WRITE the name of the cervical vertebrae from left to right:



Thorax (anterior aspect)



WRITE the name of structures labeled by the number:

1. _____
2. Costal _____
3. _____
4. _____
- I-VII _____
- VIII-X _____
- XI-XII _____
5. Costal _____

Sternum

The relations between a typical rib and thoracic vertebrae



COLOR the following three parts of sternum:

- Manubrium
- Body
- Xiphoid process

WRITE the name of structures labeled by the number:

1. _____ notch
2. _____ notch
3. _____ notches



WRITE the name of structures labeled by the number:

1. Vertebral _____
2. _____ of the rib
3. _____ process
4. _____ of the rib

LABORATORY CLASS № 2 SKULL. NEUROCRANIUM

Control questions:

1. Skull: neurocranium and viscerocranium, the name and location of bones.
2. Structure of the occipital bone: parts, the relief of the outer and inner surfaces. Canals, apertures and grooves of the occipital bone.
3. Structure of the parietal bone: borders, angles, the relief of the outer and inner surfaces.
4. Structure of the frontal bone: parts, the relief of the outer and inner surfaces, frontal sinus.
5. Structure of the sphenoid bone: parts, canals, foramina, sphenoidal sinus.
6. Structure of the ethmoid bone. Ethmoidal labyrinth.
7. Structure of the temporal bone: parts. The relief of the outer and inner surfaces. Tympanic cavity. Structure of the mastoid process.
8. Canals and canaliculi of the temporal bone: openings, contents.

Students should:

1) be able to find on anatomical preparations and visual aids following structures and to know their Latin names:

Occipital bone. 1. Foramen magnum. 2. Occipital condyle. 3. Condylar canal. 4. Hypoglossal canal. 5. Jugular notch. 6. External (internal) occipital protuberance. 7. External (internal) occipital crest. 8. Superior (inferior) nuchal line. 9. Cruciform eminence. 10. Groove of the superior sagittal (transvers, sigmoid) sinus.

Parietal bone. 1. Superior (inferior) temporal line. 2. Parietal tuber. 3. Parietal foramen.

Frontal bone. 1. Squamous part. 2. Nasal part. 3. Orbital part. 4. Frontal tuber. 5. Superciliary arch. 6. Glabella. 7. Supraorbital margin, notch, foramen. 8. Zygomatic process.

Sphenoid bone. 1. Body. 2. Greater (lesser) wing. 3. Pterygoid process. 4. Pterygoid notch. 5. Pterygoid canal. 6. Sella turcica. 7. Hypophysial fossa. 8. Dorsum sellae. 9. Prechiasmatic sulcus. 10. Optic canal. 11. Carotid sulcus. 12. Superior orbital fissure. 13. Rotundum, ovale, spinosum foramen. 14. Infratemporal crest.

Ethmoid bone. 1. Cribriform (perpendicular, orbital) plate. 2. Crista galli. 3. Ethmoidal labyrinth. 4. Superior, middle nasal concha.

Temporal bone. 1. Pyramid. 2. Petrous, tympanic, squamous parts. 3. Zygomatic, styloid, mastoid processes. 4. Mandibular fossa. 5. Articular tubercle. 6. Petrotympanic fissure. 7. External, internal acoustic opening. 8. External acoustic meatus. 9. Arcuate eminence. 10. Groove of greater (lesser) petrosal nerve. 11. Hiatus of greater (lesser) petrosal nerve. 12. Tegmen tympani. 13. Trigeminal impression. 14. Groove of superior (inferior) petrosal sinus. 15. Stylomastoid foramen. 16. Jugular fossa. 17. Mastoid foramen. 18. Groove of sigmoid sinus. 19. Tympanic cavity.

2) palpate the on a living person: external occipital protuberance; parietal tuber; frontal tuber; supraorbital margin (notch); mastoid process.

GLOSSARY

Skull (*cranium*) is the skeletal structure of the head that supports the face and protects the brain. It consists of 22 bones (or 29, including the inner ear bones and hyoid bone) which are connected together by sutures. The skull is divided into the braincase (neurocranium) and the facial skeleton (viscerocranium).

Neurocranium encloses and protects the brain, meninges, and cerebral vasculature. Anatomically, the cranium can be subdivided into skullcap (calvarium) and cranial base:

Calvarium — comprised of the frontal, occipital and two parietal bones.

Cranial base — comprised of the frontal, sphenoid, ethmoid, occipital, parietal, and temporal bones.

Viscerocranium supports the soft tissues of the face. It consists of 14 bones, which fuse to house the orbits of the eyes, the nasal and oral cavities, and the sinuses.

Occipital bone (*os occipitale*) is a flat, unpaired bone that forms a major part of the posterior wall and base of the skull. It consists of one basilar, one squamous, and two condylar parts, that encircle the foramen magnum.

Parietal bone (*os parietale*) paired, quadrilateral skull bone that forms calvarium. It has 4 margins and 4 angles. The external surface of the parietal bone features the following anatomical landmarks: parietal tuber, superior temporal line, inferior temporal line.

Frontal bone (*os frontale*) is unpaired, flat, pneumatic bone in the forehead region. It forms part of the calvaria and base of the skull, the walls of the orbit and the nasal cavity. The frontal bone consists of six main parts: the squamous part, nasal part, two orbital parts and two zygomatic processes.

Sphenoid bone (*os sphenoidale*) is an unpaired, butterfly-shaped cranial bone that is located in the middle of the skull between the frontal and temporal bones. It has a body, greater and lesser wings, pterygoid processes and contain sphenoid sinus.

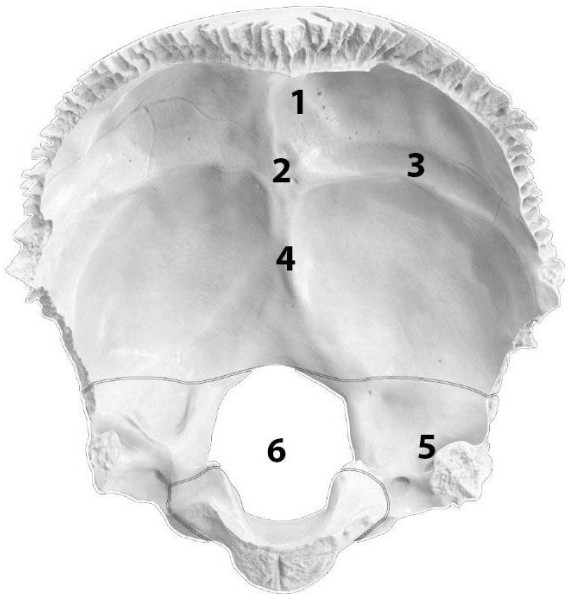
Ethmoid bone (*os ethmoidale*) is an unpaired, pneumatic, small cuboidal bone that forms the lateral boundaries of orbit, anterior cranial fossa superiorly, and nasal cavities inferiorly, participates in the formation of the anterior cranial fossa, walls of the nasal cavity and orbit. The bone consists of a horizontally located cribriform and perpendicular plates. The part of ethmoid bone is the ethmoid labyrinth with anterior, middle and posterior cells.

Temporal bone (*os temporale*) is paired, forms the base and the calvaria. It consists of four parts — the squamous, mastoid, petrous and tympanic parts. The zygomatic process is a long, arched process projecting from the lower region of the squamous part and it articulates with the zygomatic bone. The styloid process directed inferiorly and anteromedially between the parotid gland and internal jugular vein. The bone contains 3 canals (carotid, facial, muscular-tubular) and canaliculi (caroticotympanic, tympanic, mastoid, chorda tympani).

For the notes:

SELF-INSTRUCTIONAL MATERIALS

Occipital bone (anterior aspect)



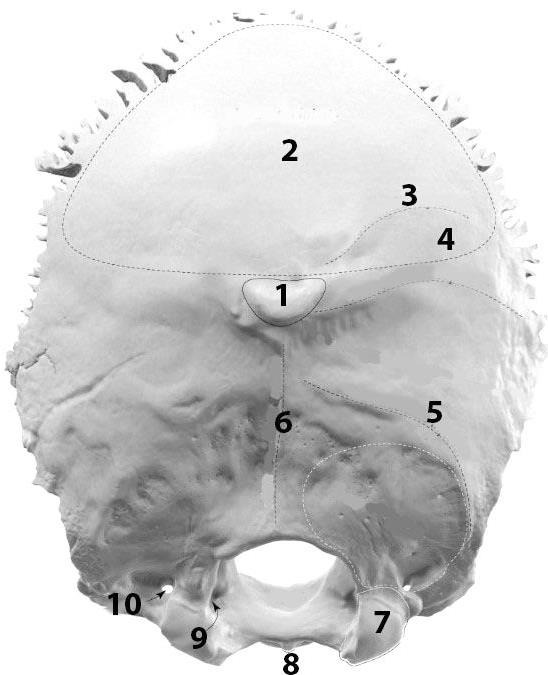
COLOR the following parts of the occipital bone, using a different color for each of them:

- Basilar part
- Lateral part
- Squamous part of occipital bone

WRITE the name of structures labeled by the number:

1. Groove for _____
2. _____ protuberance
3. Groove for _____
4. _____ crest
5. Groove of _____
6. _____

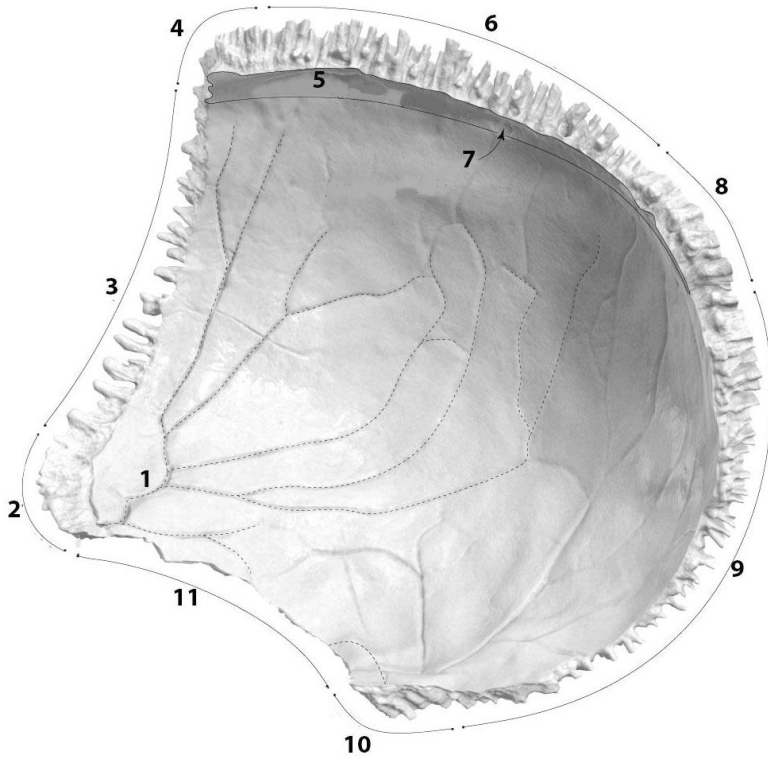
Occipital bone (posterior aspects)



WRITE the name of structures labeled by the number:

1. _____ protuberance
2. Occipital plane
3. Highest _____
4. _____ line
5. _____ line
6. _____ crest
7. _____
8. _____ tubercle
9. _____ canal
10. _____ canal

Right parietal bone (inner surface)



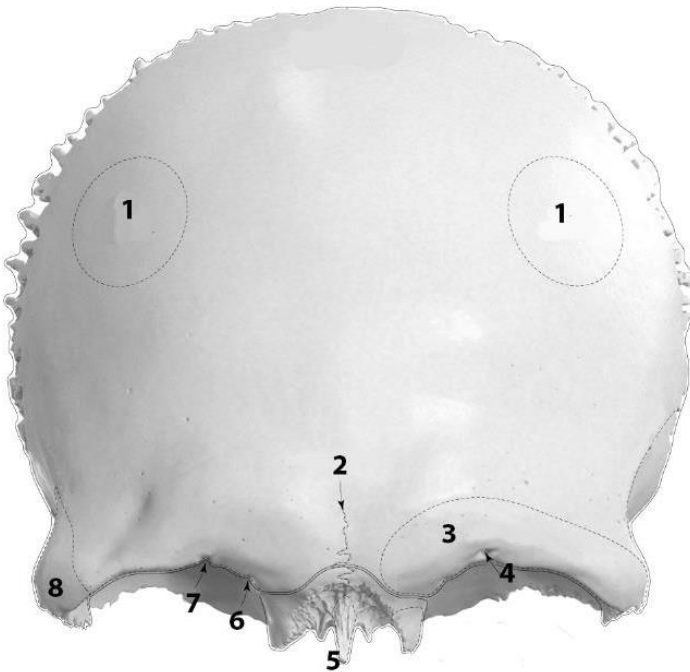
WRITE the name of structures labeled by the number:

1. Groove of _____

2. _____ angle
3. _____ border
4. _____ angle
5. Groove of _____

6. _____ border
7. _____ foramen
8. _____ angle
9. _____ border
10. _____ angle
11. _____ border

Frontal bone (anterior aspect)



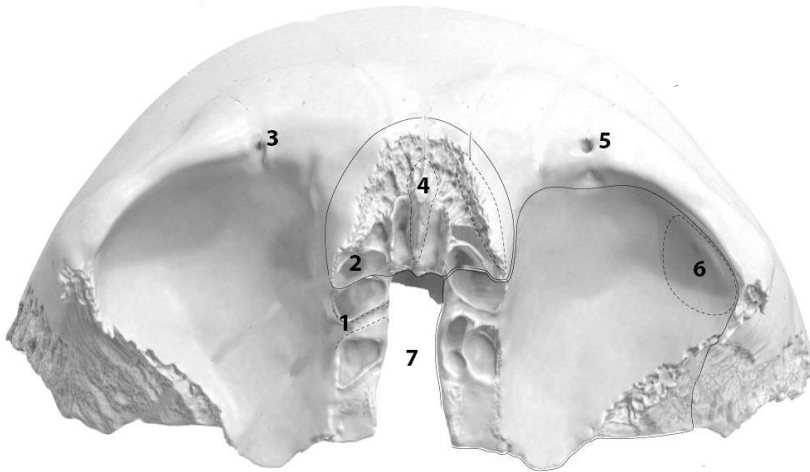
COLOR the following parts of the frontal bone, using a different color for each of them:

- Squamous part
- Nasal part
- Orbital parts

WRITE the name of structures labeled by the number:

1. _____
2. Frontal (metopic) _____
3. _____ arch
4. _____ foramen
5. _____ spine
6. Frontal notch
7. Supraorbital _____
8. _____ process

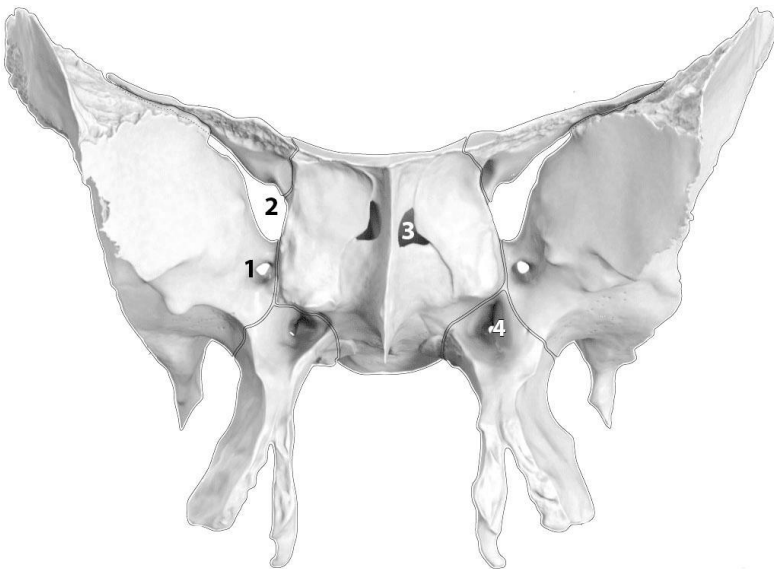
Frontal bone (bottom aspect)



WRITE the name of structures labeled by the number:

1. _____ foramen
2. Opening of _____ sinus
3. _____ notch
4. _____
5. _____ foramen
6. _____ fossa
7. _____ notch

Sphenoid bone (ventral aspect)



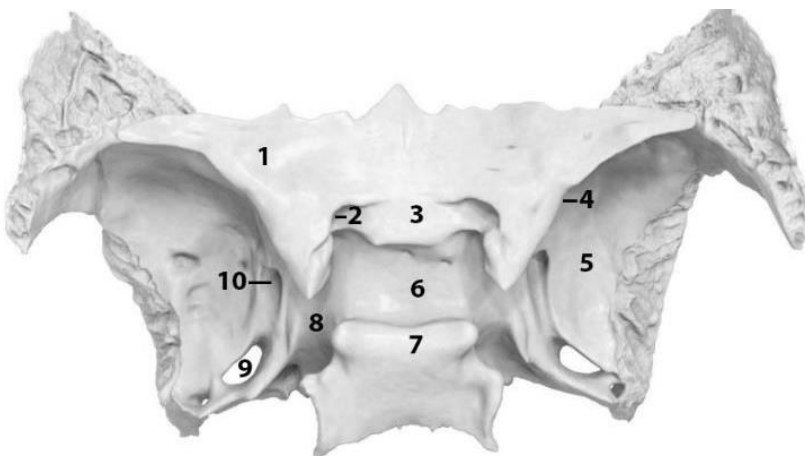
COLOR the following parts of the sphenoid bone, using a different color for each of them

- Body
- Lesser wing
- Greater wing
- Pterygoid process

WRITE the name of structures labeled by the number:

1. _____
2. _____
3. Opening of _____
4. _____ canal

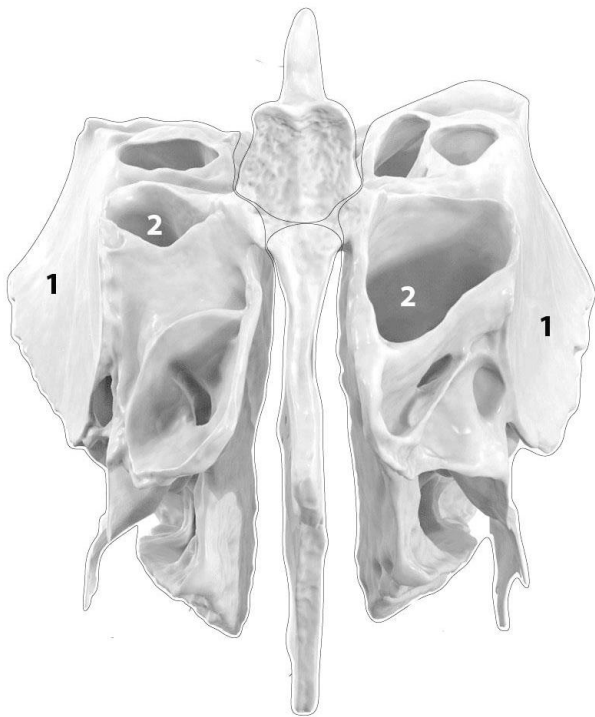
Sphenoid bone (top view)



WRITE the name of structures labeled by the number:

1. _____
2. _____
3. _____ sulcus
4. _____ fissure
5. _____
6. Sella _____
7. Dorsum _____
8. _____ sulcus
9. _____
10. Foramen _____

Ethmoid (anterior aspect)



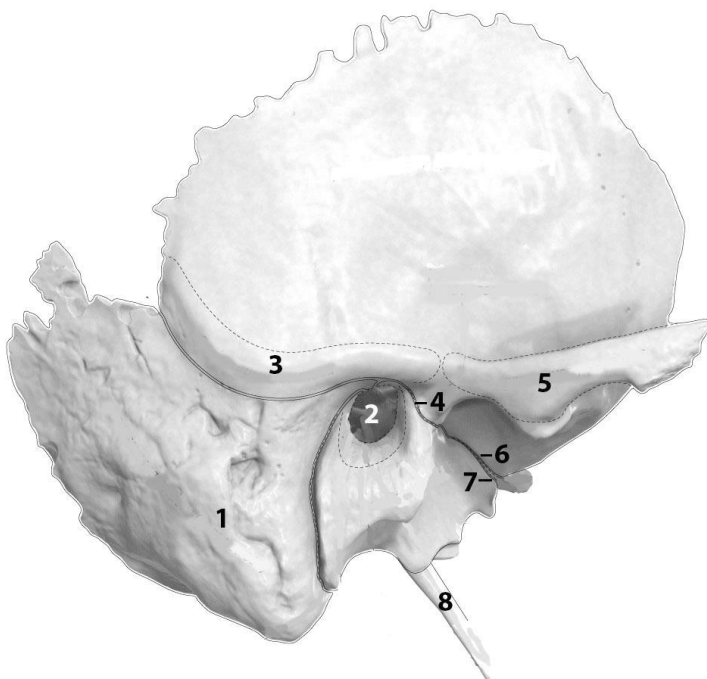
COLOR the following parts of the ethmoidal bone, using a different color for each of them:

- Ethmoidal labyrinths
- Perpendicular plate
- Crista galli

WRITE the name of structures labeled by the number:

1. _____ plate
2. _____

Right temporal bone (lateral aspect)



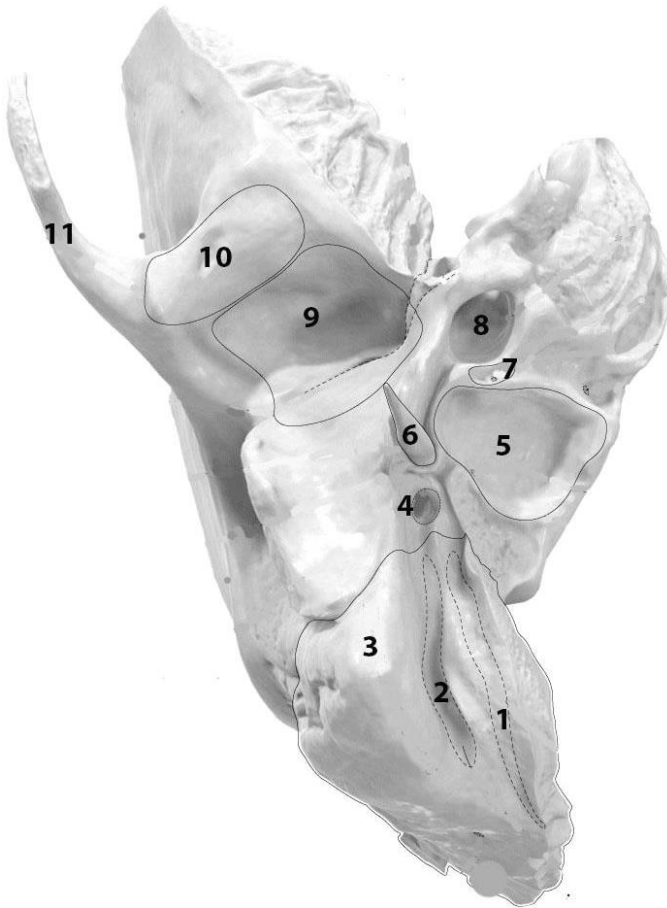
COLOR the following parts of the temporal bone, using a different color for each of them:

- Petrous part
- Tympanic part
- Squamous part

WRITE the name of structures labeled by the number:

1. _____
2. _____ opening
3. Supramastoid _____
4. _____ fissure
5. _____ process
6. _____ fissure
7. _____ fissure
8. Styloid process

Right temporal bone (bottom aspect)



WRITE the name of structures labeled by the number:

1. _____ groove
2. _____ notch
3. Mastoid _____
4. _____ foramen
5. _____ fossa
6. _____ process
7. _____ fossula
8. _____ canal
9. Mandibular _____
10. _____ tubercle
11. _____ process

For the notes:

LABORATORY CLASS № 3 BONES OF THE FACIAL SKULL

Control questions:

1. Structure of maxilla: parts, their processes. Surface relief of the body and processes of the maxilla.
2. Maxillary sinus: localization, walls, communication with the nasal cavity.
3. Palatine bone: parts, its interposition, relief.
4. Structure of the hard palate.
5. Mandible: parts, relief of the body and processes. Mandibular canal: foramens, contents.
6. Small bones of the facial skull: zygomatic, lacrimal, nasal, inferior nasal concha, vomer. Location and structure.
7. Hyoid bone: topography, structure.
8. Development of the hard palate, maxilla and mandible.

Students should:

1) be able to find on anatomical preparations and visual aids following structures and to know their Latin names:

Maxilla. 1. Infraorbital margin, foramen. 2. Canine fossa. 3. Tuber of the maxilla. 4. Alveolar foramina. 5. Infraorbital groove, canal. 6. Maxillary sinus. 7. Lacrimal groove. 8. Greater palatine groove. 9. Frontal, zygomatic, palatine, alveolar processes. 10. Anterior nasal spine. 11. Incisive foramen, canal. 12. Dental alveolus. 13. Alveolar yokes. 14. Inter-alveolar, interradicular septa.

Palatine bone. 1. Perpendicular, horizontal plate. 2. Greater palatine groove. 3. Lesser palatine foramina. 4. Pyramidal, orbital, sphenoidal processes. 5. Sphenopalatine notch.

Mandible. 1. Body, base of mandible. 2. Mental foramen. 3. Mental tubercle, protuberance. 4. Oblique line. 5. Digastric fossa. 6. Superior, inferior mental spine. 7. Mylohyoid line, groove. 8. Sublingual, submandibular fossa. 9. Alveolar part. 10. Ramus of mandible. 11. Angle of mandible. 12. Masseteric, pterygoid tuberosity. 13. Mandibular foramen. 14. Lingula of mandible. 15. Mandibular canal. 16. Coronoid, condylar process. 17. Mandibular notch. 18. Head, neck of mandible. 19. Pterygoid fossa.

Zygomatic bone. Zygomatico-orbital, zygomaticofacial, zygomaticotemporal foramina.
Lacrimal bone. Nasal bone. Inferior nasal concha. Vomer. Hyoid bone.

2) palpate the on a living person: infraorbital margin, zygomatic arch, zygomatic bone, base of mandible, the angle of mandible.

GLOSSARY

Maxilla (*maxilla*) is a paired bone of the facial skull, and it has a *body* and *four processes*. The two maxillary bones (*maxillae*) are fused in the midline by the intermaxillary suture to form the upper jaw. The alveolar process is an inferior extension of the maxilla with a porous structure. It forms the maxillary *dental arch* containing 8 cavities where the upper teeth are held.

Alveolar arch of the maxilla (as the alveolar arch of the mandible) features the following structures: dental alveoli, interalveolar septa, interradicular septa, alveolar yokes. The dental alveoli are sockets in the alveolar process where the roots of the teeth lie. The dental alveoli of the mandible house the roots of the lower teeth, while the dental alveoli of the maxilla — the upper teeth. The interalveolar septa are bony ridges between adjacent dental alveoli. But the interradicular septa are bony ridges forming compartments in dental alveoli for the roots of the teeth in both the upper and lower jaw bones.

Maxillary sinus (*sinus maxillaris*) is a paired air-filled cavity located within the body of the maxilla. Each maxillary sinus opens into the nasal cavity via the maxillary hiatus. The maxillary sinus drains into the middle nasal meatus of the nasal cavity. The walls of the maxilla are as follows:

Medial — nasal surface of the body;

Lateral — zygomatic process of the maxilla;

Inferior — alveolar process and part of the palatine process of the maxilla;

Superior — orbital surface of the body;

Anterior — anterior surface of the body;

Posterior — infratemporal surface of the body.

Palatine bone (*os palatinum*) is a paired L-shaped bone that forms part of the posterior nasal cavity, hard palate, and a small part of the orbit. Each palatine bone is made up of a perpendicular and a horizontal plate.

Mandible (*mandibula*) is the only movable bone of the skull and the largest, strongest facial bone. It is a single bone connected to the skull by the temporomandibular joint. The mandible houses the lower teeth. It has three main parts: a *body* and *two rami*, connected at the angle of mandible. The *alveolar part* is the upper portion of the body. It has interalveolar septa, which cut the trench into sockets which house the 16 mandibular teeth. *Mandibular canal* is a canal within the mandible that contains the inferior alveolar nerve, inferior alveolar artery, and inferior alveolar vein. It starts at the mandibular foramen, on the lingual side of the ramus, continues on the buccal surface of the mandibular body and ends at the mental foramen.

Zygomatic bone (*os zygomaticum*) is paired quadrangular shaped bone. The zygomatic bone has several parts: a body and three processes — the frontal, temporal, and maxillary processes. The frontal process and maxillary process both are involved in forming the orbits. They articulate with the frontal and maxillary bones. The zygomatic bone's temporal process forms the *zygomatic arch* by articulating with the zygomatic process of the temporal bone. Inside the zygomatic bone there is *canal*, which begins with a zygomatico-orbital foramen and ends with zygomaticofacial and zygomaticotemporal foramina.

Lacrimal bone (*os lacrimale*) is paired thin and fragile rectangular-shaped bone. They form the medial wall of the orbit and a small portion of the nasal cavity.

Nasal bone (*os nasale*) is paired bone, form the nose bridge and articulate at the middle of the bridge with the opposing nasal bone. Interior parts of these bones form the superior margin of the nasal aperture.

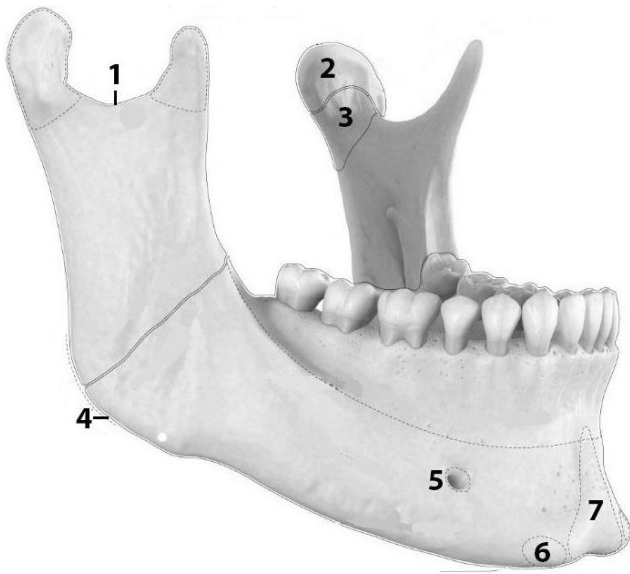
Vomer (*vomer*) is an unpaired plow-shaped bone that forms the posteroinferior part of the nasal septum.

Inferior nasal concha (*concha nasalis inferior*) is a curved paired bone located within the lateral wall of the nasal cavity.

Hyoid bone (*os hyoideum*) is a single “U” shaped bone situated in the anterior part of the neck between the chin and the thyroid cartilage. The hyoid bone is attached to the skull with the help of ligaments. The main parts of the hyoid bone are: body, lesser horn (2), greater horn (2).

SELF-INSTRUCTIONAL MATERIALS

Mandible (anterolateral view)



COLOR the following parts of the mandible, using a different color for each of them:

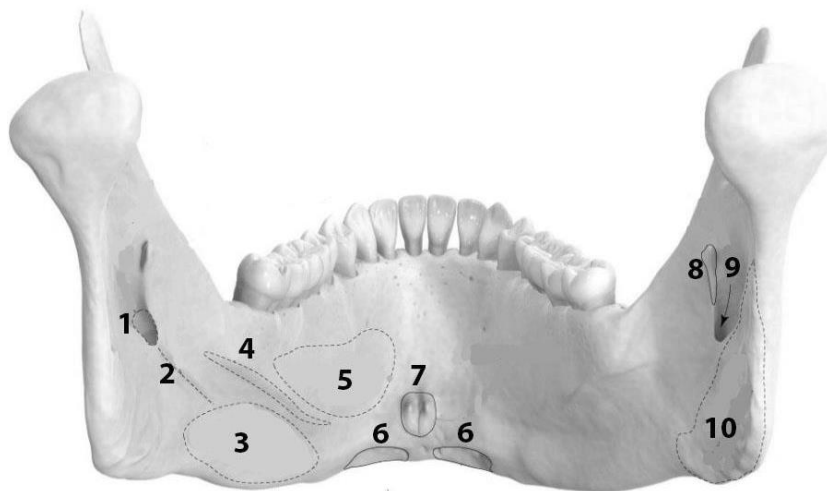
- Base of mandible
- Alveolar part
- Ramus of mandible
- Condylar process
- Coronoid process

WRITE the name of structures labeled by the number:

1. _____
2. _____ of mandible
3. _____ of mandible
4. _____ of mandible
5. _____
6. _____ tubercle
7. _____

Base of mandible + alveolar part = _____

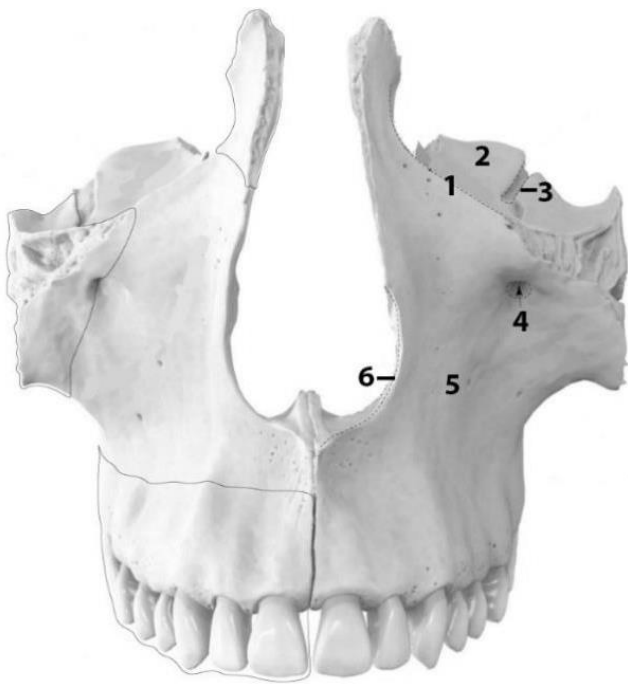
Mandible (back view)



WRITE the name of structures labeled by the number:

- | | |
|------------------|----------------------|
| 1. _____ foramen | 6. _____ fossa |
| 2. _____ sulcus | 7. _____ spines |
| 3. _____ fossa | 8. _____ of mandible |
| 4. _____ line | 9. _____ canal |
| 5. _____ fossa | 10. _____ tuberosity |

Maxilla (anterior view)



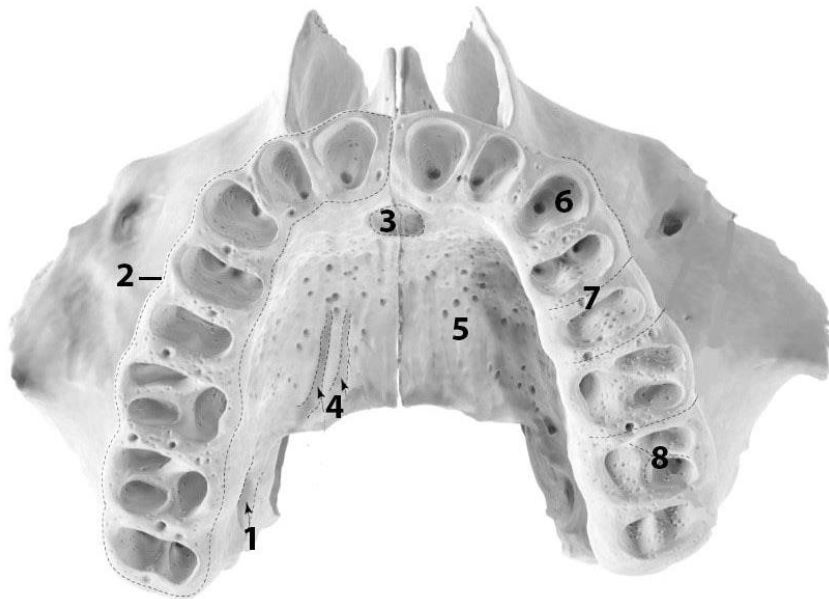
COLOR the following parts of the maxilla, using a different color for each of them:

- Body of maxilla
- Alveolar process
- Frontal process
- Zygomatic process

WRITE the name of structures labeled by the number:

1. _____ margin
2. _____ surface
(the body of the maxilla)
3. _____ groove
4. _____
5. _____ surface
(the body of the maxilla)
6. _____ notch

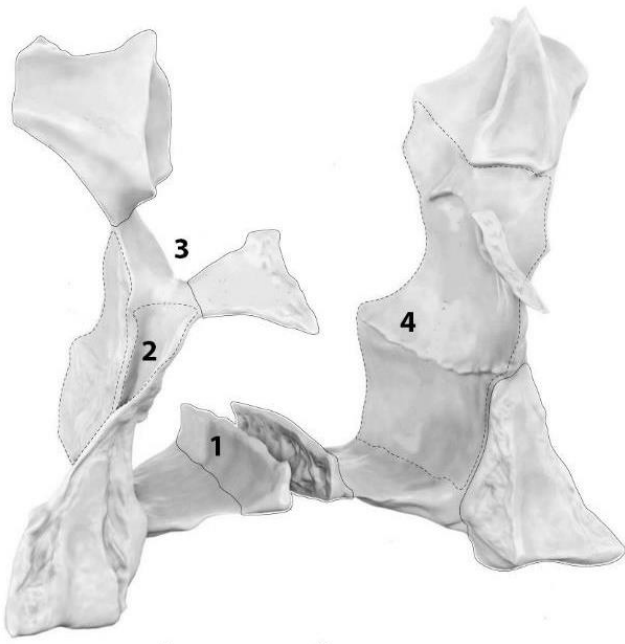The bottom view of two maxillae



WRITE the name of structures labeled by the number:

1. _____ groove
2. _____ arch
3. _____
4. _____ grooves
5. _____ process
6. _____
7. _____
8. _____

Palatine bones (lateral & posterior aspect)



COLOR the following parts of the maxilla, using a different color for each of them:

- Perpendicular plate
- Horizontal plate
- Sphenoidal process
- Orbital process
- Pyramidal process

WRITE the name of structures labeled by the number:

1. _____ crest
2. _____ groove
3. _____ notch
4. _____ surface

For the notes:

LABORATORY CLASS № 4
SKULL AS A WHOLE. FRONTAL, LATERAL, POSTERIOR, SUPERIOR ASPECTS.
AGE ANATOMY OF THE SKULL

Control questions:

1. Orbit: structure of the walls. Foramina, fissures and canals of the orbit, communication with other cavities of the skull.
2. Bony nasal cavity: structure of the lateral, medial, superior and inferior walls.
3. Nasal meatuses: borders, communication with other cavities of the skull.
4. Fosses of the lateral aspect of the skull. Borders, the name of the bones that make up the bone base of the temporal and infratemporal fosses. Fissures and foramina, communication of fosses with other cavities of the skull.
5. Pterygopalatine fossa: walls, communication with other cavities of the skull.
6. Internal (surface of) cranial base. Anterior, middle and posterior cranial fossa; foramina, canals, fissures.
7. Grooves for the sinuses of the dura mater.
8. External (surface of) cranial base; foramina, canals.
9. Calvaria; features of the structure and development of bones. Sutures of the skull.
10. Age anatomy of the facial and cranial skull.

Students should:

1) be able to find on anatomical preparations and visual aids following structures and to know their Latin names:

Orbit. 1. Anterior, posterior ethmoidal foramina. 2. Superior, inferior orbital fissures. 3. Nasolacrimal canal. 4. Lacrimal fossa. 5. Supraorbital margin. 6. Infraorbital margin.

Bone nasal cavity. 1. Piriform aperture. 2. Choanae. 3. Superior, middle, inferior nasal meatus. 4. Sphenopalatine foramen. 5. Ostium of the nasolacrimal canal.

Lateral aspect. 1. Zygomatic arch. 2. Temporal fossa. 3. Infratemporal fossa. 4. Pterygopalatine fossa. 5. Pterygomaxillary fissure.

Base of the skull. 1. Hard palate. 2. Median palatal suture. 3. Transverse palatal suture. 4. Greater palatine canal. 5. Greater, lesser palatine foramina. 6. Foramen lacerum. 7. Jugular foramen. 8. Anterior, middle, posterior cranial fosses. 9. Clivus. 10. Grooves of the superior, inferior petrosal sinuses. 11. Grooves of the sigmoid, transverse sinuses. 12. Groove of the superior sagittal sinus.

Calvaria. 1. Coronal suture. 2. Sagittal suture. 3. Lambdoid suture. 4. Metopic suture. 5. Squamous suture.

2) palpate the on a living person: supraorbital and infraorbital margins, zygomatic arch, base of mandible, angle of mandible, zygomatic bone, mastoid process, external occipital protuberance.

GLOSSARY

Frontal aspect of cranium (*norma facialis cranii*) refers to the anterior view of the skull, which comprises of various regions including the orbit, the nasal cavity, the oral cavity.

The **orbit**, or eye socket (*orbita*) is a bilateral and symmetrical bony cavity in the head. It encloses the eyeball and its associated structures. The orbit appears as a quadrangular pyramidal cavern. The apex of the orbit is the optic canal. The base of the orbit is called the orbital margin.

The roof, or superior wall, of the orbit separates the orbit from the anterior cranial fossa, contains depression called the lacrimal fossa.

The floor, or inferior wall, separates the orbit and the maxillary sinus. The most important landmark of the floor is the inferior orbital fissure.

Lateral wall is the thickest and strongest wall of the orbit, which posteriorly separates the orbit from the middle cranial and temporal fossae. The most prominent landmark of the lateral wall is the superior orbital fissure.

The *medial wall* is built out of four bones: the maxilla, lacrimal bone, ethmoid bone, and sphenoid bone. A useful mnemonic to remember them is, “My Little Eye Sits in the orbit.” Important landmarks are the anterior and posterior ethmoidal foramina, trochlea, lacrimal groove.

Nasal cavity (*cavum nasi*) is irregular space, is divided into the right and left halves by a thin vertical bony septum situated one on the middle line of the face. Is open on the face through the pear-shaped anterior nasal aperture, and her posterior openings or choanae communicate with the nasal part of the pharynx. Each half of nasal cavity has a roof, floor, and lateral and medial walls. On the lateral wall of the nasal cavity there are superior, middle and inferior nasal conches, under which nasal meatuses pass.

Superior nasal meatus communicates with the sphenoidal sinus and the posterior ethmoidal cells.

The *middle nasal meatus* communicates with the frontal and maxillary sinuses, anterior and middle ethmoidal cells.

The nasolacrimal canal opens into the *inferior nasal meatus*.

Bony nasal septum (*septum nasi osseum*) is formed by the perpendicular plate of the ethmoid and the vomer. It is frequently deflected to one or other side, more often to the left than to the right.

The **lateral aspect** (*norma lateralis cranii*) of the skull includes the temporal, infratemporal and pterygopalatine fossa.

Temporal fossa (*fossa temporalis*) is a shallow depression on the side of the skull bounded from above by the superior temporal line, from below — by the infratemporal crest of the greater wing of the sphenoid bone, from the outside — by the zygomatic arch. The temporalis muscle originates from the bones of the temporal fossa.

Infratemporal fossa (*fossa infratemporalis*) is an irregular space at the lateral aspect of the skull bounded from the top by a greater wing of the sphenoid bone, in front — by a tuber of maxilla, posteriorly — by a styloid process, medially — by lateral plate of the pterygoid process of the sphenoid bone, laterally — by the branch of mandible. The temporal and infratemporal fossae communicate with each other through the opening deep to the zygomatic arch. In addition, the infratemporal fossa communicates medially with the pterygopalatine fossa through the pterygomaxillary fissure and anteriorly with the orbit through the inferior orbital fissure. The major structures present in the infratemporal fossa: lateral and medial pterygoid muscles, blood vessels and nerves. Medially infratemporal fossa continues into the pterygopalatine fossa.

Pterygopalatine fossa (*fossa pterygopalatina*) is a small, triangular space in the skull bounded in front, by the tuber of maxilla; behind, by the pterygoid process of the sphenoid bone; above by the body of the sphenoid and by the orbital process of the palatine bone; medially, by perpendicular plate of the palatine bone. This fossa communicates with the orbit by the inferior orbital fissure, with the nasal cavity by the sphenopalatine foramen, with the infratemporal fossa, by the pterygomaxillary fissure, with the skull cavity, by a foramen rotundum, with the external cranial base, by the pterygoid canal, and with the oral cavity, by the greater palatine canal.

The **inferior view** (*norma basalis cranii*) is formed by the base of skull.

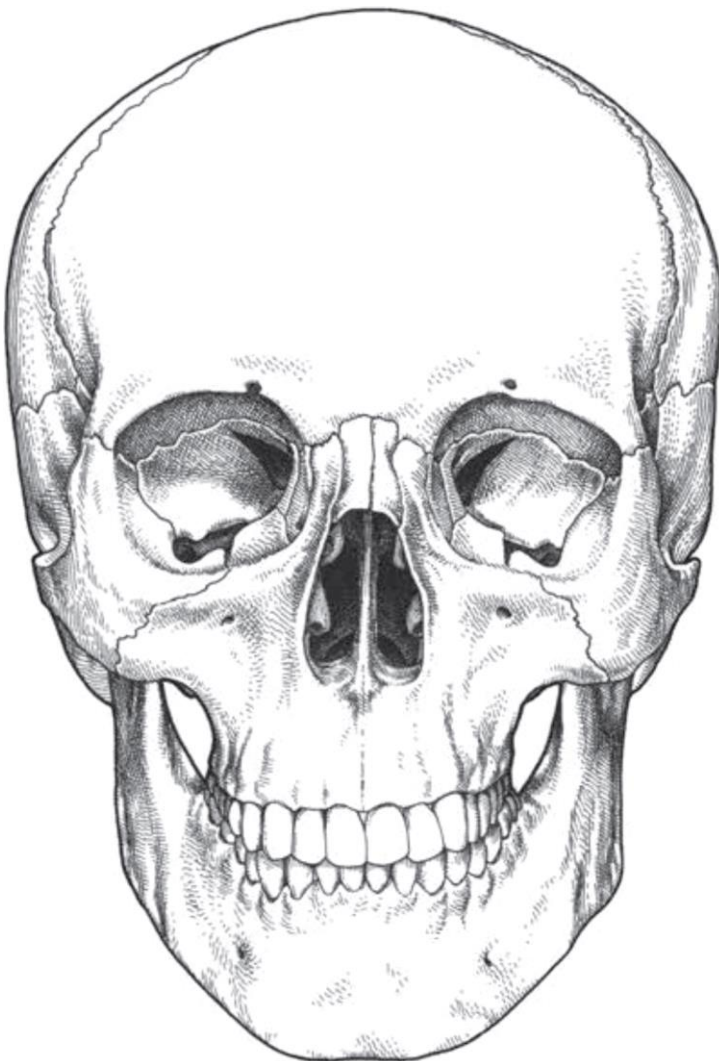
The **external surface** of base of skull (*basis cranii externa*) is the outer or inferior aspect of the skull base. This part of the skull extends from the superior incisor teeth to the superior nuchal lines of the occipital bone. Is formed by the maxillary, palatine, vomer, sphenoid, and occipital bones, in the midline; and the zygomatic and temporal bones laterally. In the most anterior part of the cranial base, there are the alveolar arch and the hard palate.

The **internal surface** of base of skull (*basis cranii interna*) refers to the inside aspect of the base of the skull. Anteriorly, is bounded by parts of the frontal, sphenoid, ethmoid bones. Laterally, it is bounded by the parietal and temporal bones. Posteriorly, the boundary is formed by the squamous part of the occipital bone. Three regions known as the cranial fossae can be distinguished in the internal cranial base: *anterior cranial fossa*, *middle cranial fossa* and *posterior cranial fossa*. The internal cranial base has many openings which connect the cranial cavity with other cavities and the outer side of the skull.

The **calvaria** (*calvaria*) or skull cap is the upper part of the cranium is formed by the occipital squama, two parietal bones and frontal squama. Bones of the calvaria are formed by the hard outer cortical shell and brittle inner cortical shell, between which there is a thin layer of diploe. External bone surfaces are covered with the periosteum, internal surfaces are covered with a dura mater.

SELF-INSTRUCTIONAL MATERIALS

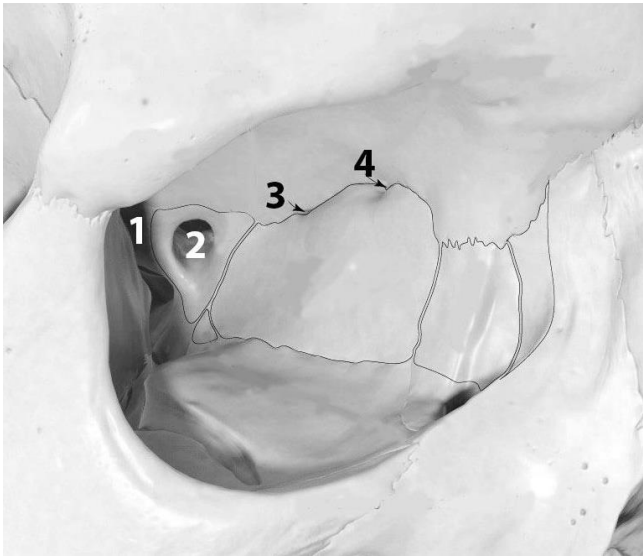
Viscerocranium (frontal view)



COLOR the bones of the facial skeleton, using different colors

- Nasal
- Lacrimal
- Zygomatic
- Maxilla
- Inferior nasal concha
- Vomer
- Mandible

Right orbit (frontal view)



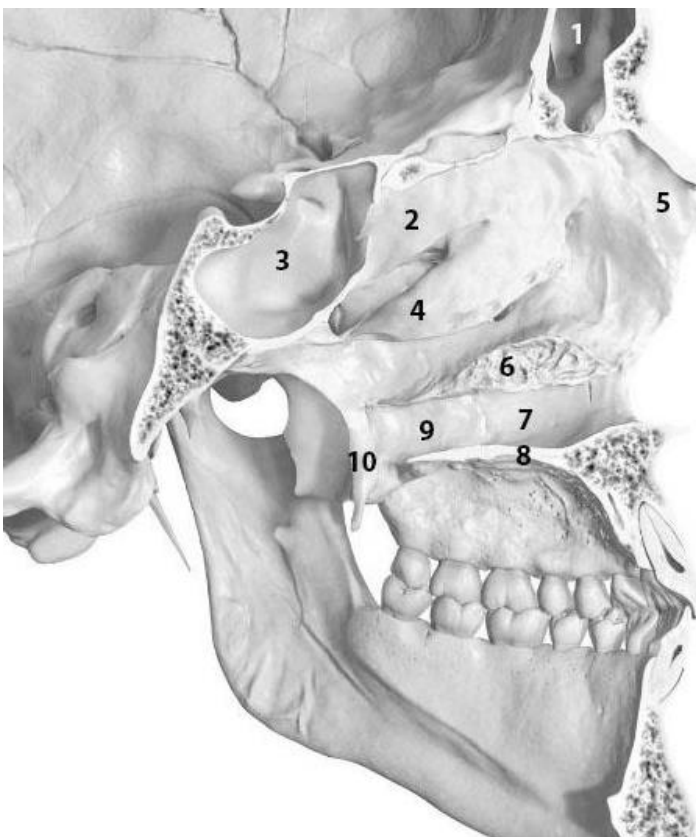
COLOR the following bones forming walls of the orbit, using different colors:

- Lacrimal bone
- Ethmoidal bone (orbital plate)
- Frontal bone
- Sphenoidal bone (body)
- Zygomatic bone
- Maxilla (body)

WRITE the name of structures labeled by the number:

1. _____
2. _____
3. _____
4. _____

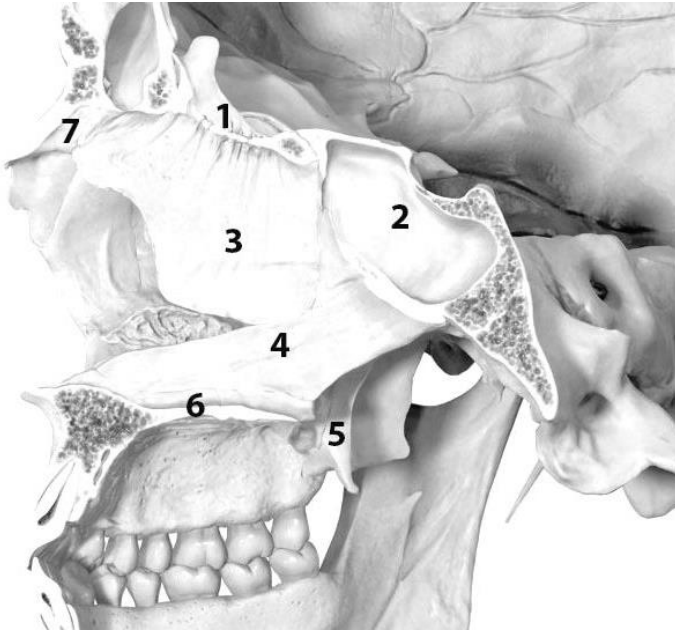
Nasal cavity (lateral wall)



WRITE the name of structures labeled by the number:

1. _____ sinus
2. _____ concha
3. _____
4. _____ concha
5. _____ bone
6. _____ concha
7. _____ surface of maxilla
8. _____ of maxilla
9. _____ plate
10. _____

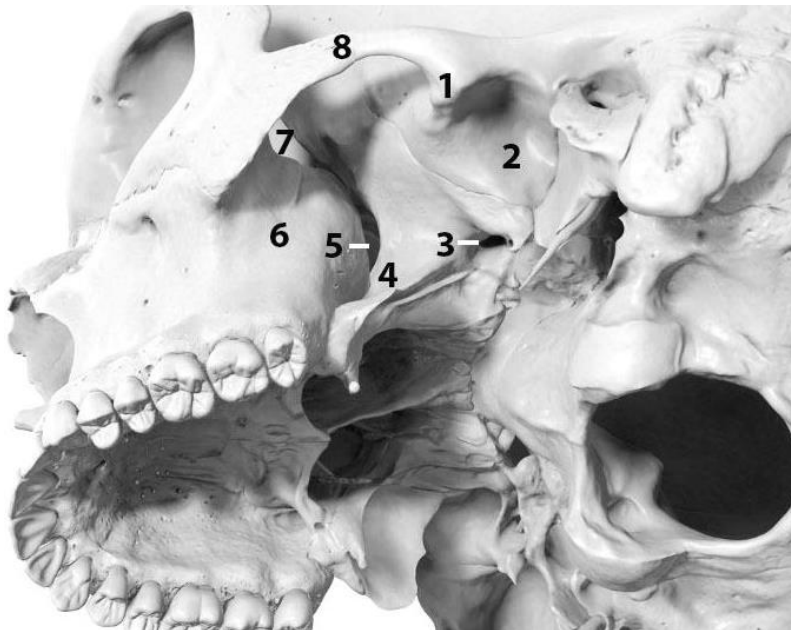
Nasal cavity (medial wall)



WRITE the name of structures labeled by the number:

1. _____ plate
2. _____
3. _____ plate
4. _____
5. _____
6. Hard palate
7. _____ bone

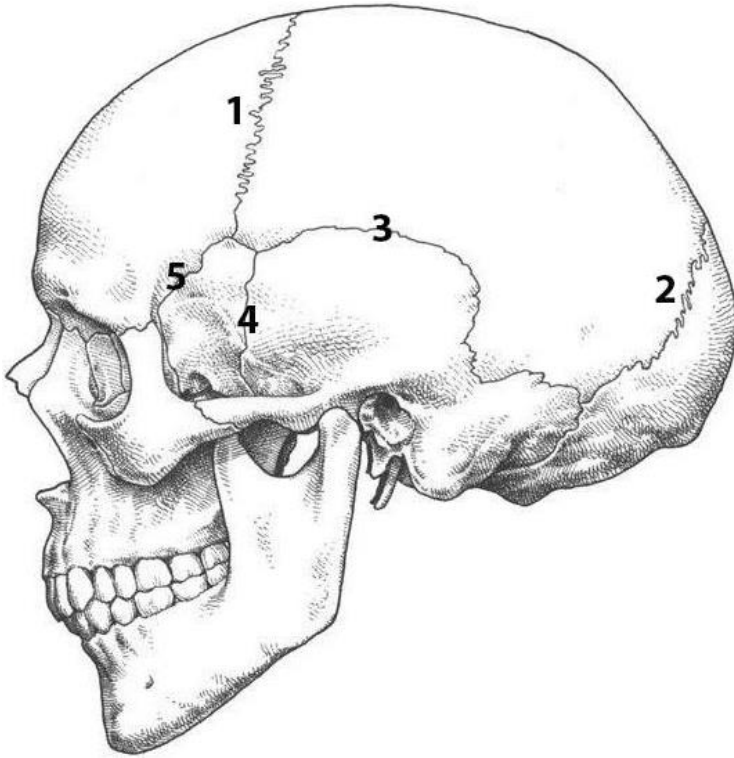
Infratemporal fossa (inferolateral aspect)



WRITE the name of structures labeled by the number:

1. _____ tubercle
2. _____ fossa
3. _____ foramen
4. _____ process
5. _____ fissure
6. Maxilla
7. _____ fissure
8. _____ arch

External features of the skull (external view)



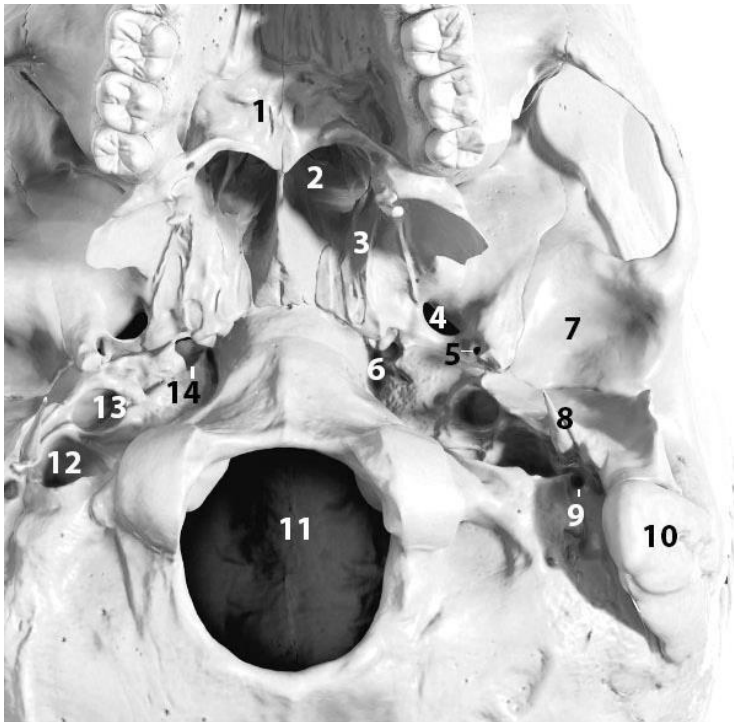
COLOR the bones of the calvaria, using either solid color, or diagonal lines or stippling of different colors for the larger bones:

- Frontal bone
- Parietal bone
- Sphenoid bone
- Temporal bone
- Occipital bone
- Zygomatic bone
- Mandible
- Maxilla

WRITE the name of sutures labeled by the number:

1. _____ suture
2. _____ suture
3. _____ suture
4. _____ suture
5. _____ suture

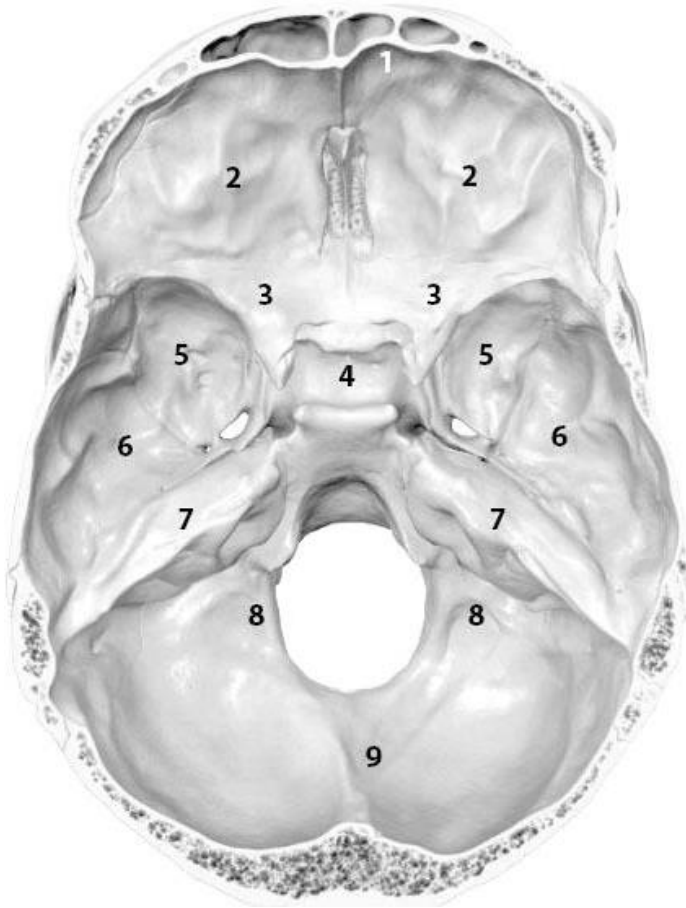
Base of the skull (external surface)



WRITE the name of structures labeled by the number:

1. _____ palate
2. _____
3. _____ process
4. Foramen _____
5. Foramen _____
6. Foramen _____
7. _____ fossa
8. _____ process
9. _____ foramen
10. _____
11. _____
12. _____ foramen
13. _____ of carotid canal
14. _____ of carotid canal

Base of the skull (internal surface)




COLOR the following parts of the internal surface of the base of the skull:

- Anterior cranial fossa
- Middle cranial fossa
- Posterior cranial fossa

WRITE the name of structures labeled by the number:

1. _____ part of frontal bone
2. _____ part of frontal bone
3. _____
4. _____
5. _____
6. _____ part of temporal bone
7. _____ part of temporal bone
8. _____ part of occipital bone
9. _____ part of occipital bone

Calvaria (norma verticalis)



WRITE the name of structures labeled by the number:

1. _____ bone
2. _____ suture
3. Bregma
4. _____
5. _____
6. _____ foramen
7. _____
8. Lambda

LABORATORY CLASS № 5
THE APPENDICULAR SKELETON. SKELETON OF UPPER AND LOWER LIMBS

Control questions:

1. Structure of the bones of the shoulder girdle.
2. Skeleton of the free part of the upper limb: arm, forearm, hand.
3. Pelvic girdle; structure of the hip bone.
4. The pelvis as a whole. Sex differences in the pelvis.
5. Skeleton of the free part of the lower limb: thigh, leg, foot.
6. Similarity and differences in the structure of the skeleton of the upper and lower limbs.

Students should:

1) be able to find on anatomical preparations and visual aids following structures and to know their Latin names:

Bones of upper and lower limbs. 1. Scapula. 2. Clavicle. 3. Humerus. 4. Radius. 5. Ulna. 6. Carpal bones. 7. Metacarpal bones. 8. Phalanges. 9. Hip bone. 10. Ilium. 11. Ischium. 12. Pubic bone. 13. Femur. 14. Tibia. 15. Fibula. 16. Tarsus. 17. Metatarsus.

2) palpate the on a living person: epicondyles of the humerus, olecranon, styloid processes (radial and ulnar bones), patella, tuberosity of the tibia, lateral and medial malleolus.

GLOSSARY

Shoulder girdle is composed of the clavicle and the scapula, which articulates with the proximal humerus of the upper limb.

Free part of the upper limb is divided into the arm (humerus), the forearm (ulna and radius) and the hand (carpal bones, metacarpal bones and phalanges).

Arm

Humerus is a long bone in the arm that runs from the shoulder to the elbow. It connects the scapula and the two bones of the lower arm, the radius and ulna, and consists of three. The humeral upper extremity consists of a rounded head, a narrow neck, and two short processes. The body is cylindrical in its upper portion, and more prismatic below. The lower section consists of 2 epicondyles, 2 processes (trochlea & capitulum), and 3 fossae (radial fossa, coronoid fossa, and olecranon fossa). As well as its true anatomical neck, the constriction below the greater and lesser tubercles of the humerus is referred to as its surgical neck due to its tendency to fracture, thus often becoming the focus of surgeons.

Forearm is the section of the upper limb from the elbow to the wrist, whose bony structure is formed by the radius (laterally) and ulna (medially)

Radius extends from the lateral side of the elbow to the thumb side of the wrist and runs parallel to the ulna. It is a long bone, prism-shaped and slightly curved longitudinally. It has three main parts: a proximal end, shaft and a distal end. The proximal end has a head which articulates with both the distal humerus and the proximal ulna, while the distal end articulates with the head of the ulna and carpal bones at the wrist.

Ulna is the medial bone of the forearm and the longer of the two parallel forearm bones. Like the radius, the ulna also has three main parts: a proximal end, shaft and a distal end. The proximal end articulates with the distal humerus and the head of the radius. The distal end, on the other hand, has a head which articulates with the distal radius. The interosseous membrane joins the shaft (body) of the ulna to the shaft of the radius.

Skeleton of the **hand** has three sections: the wrist, palm and fingers.

The wrist (*carpus*) consists of eight spongy bones arranged in two rows, four in each row. Proximal row: scaphoid, lunate, triquetral, pisiform; distal row: trapezium, trapezoid, capitate, hamate.

Palm consists of *metacarpal bones* — five short bones.

Each finger has three *phalanges*: proximal, middle and distal (nail). The thumb is formed by two phalanges — proximal and distal.

Pelvic girdle is a bony ring, formed by the left and right hip bones and the sacrum, and it surrounds the pelvic cavity, and connects the vertebral column to the lower limbs.

Hip bone is a large flat bone, constricted in the center and expanded above and below, before puberty it is composed of three separate parts the ilium, ischium, and the pubis.

Free part of the lower limb is formed by the thigh (femur), leg (tibia and fibula) and foot (tarsus, metatarsus and phalanges).

Thigh

Femur is the strongest and longest bone in the body, occupying the space of the lower limb, between the hip and knee joints. Proximally, the femur articulates with the pelvic bone. Distally, it interacts with the patella and the proximal aspect of the tibia.

Leg

Tibia is a long bone of the leg, found medial to the fibula. It is largest bone in the body after the femur. Like other long bones, there are three parts of the tibia: proximal, shaft, and distal. The proximal part participates in the knee joint, whereas the distal part contributes to the ankle joint.

Fibula is a slender, cylindrical leg bone that is located on the posterior portion of the limb. Fibula has a proximal end (with a head and neck), a shaft, and a distal end. The fibula and tibia run parallel to each other in the leg and are similar in length but the fibula is much thinner than the tibia.

Foot

Tarsus (tarsal bones) consists of 7 bones which form the posterior aspect of the foot. Bones of the tarsus include the calcaneus, talus, navicular, cuboid and cuneiform (medial, intermediate and lateral) bones.

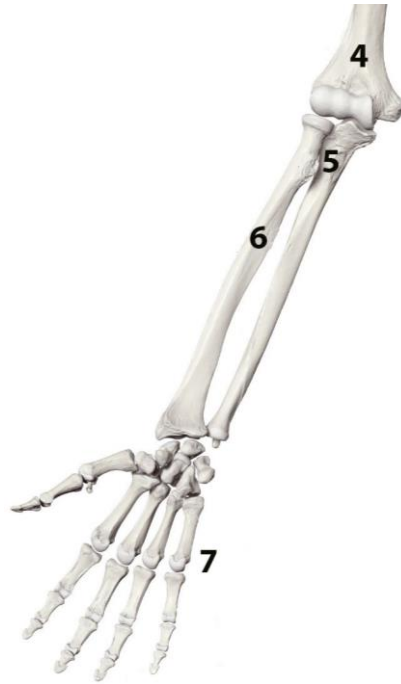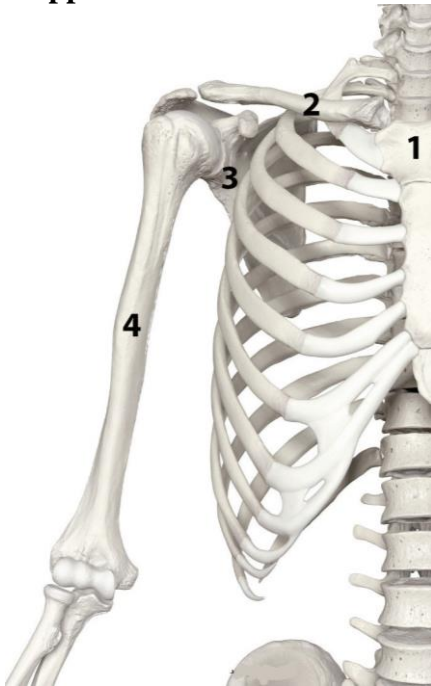
Metatarsus (metatarsal bones) are a group of five long bones in the foot, located between the tarsal bones of the hind- and midfoot and the phalanges of the toes.

Phalanges: proximal, middle and distal. The hallux is formed by two phalanges — proximal and distal.

For the notes:

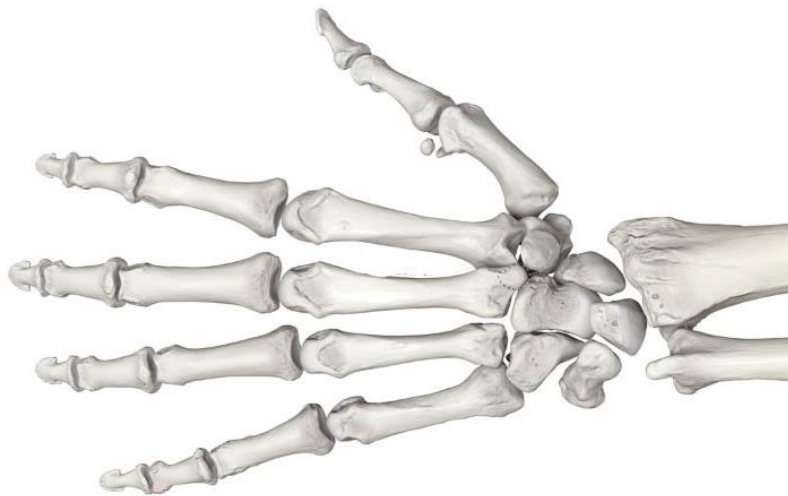
SELF-INSTRUCTIONAL MATERIALS

Bones of upper limb



WRITE the name of structures labeled by the number:

1. _____
2. _____
3. _____
4. _____
5. _____
6. _____
7. _____



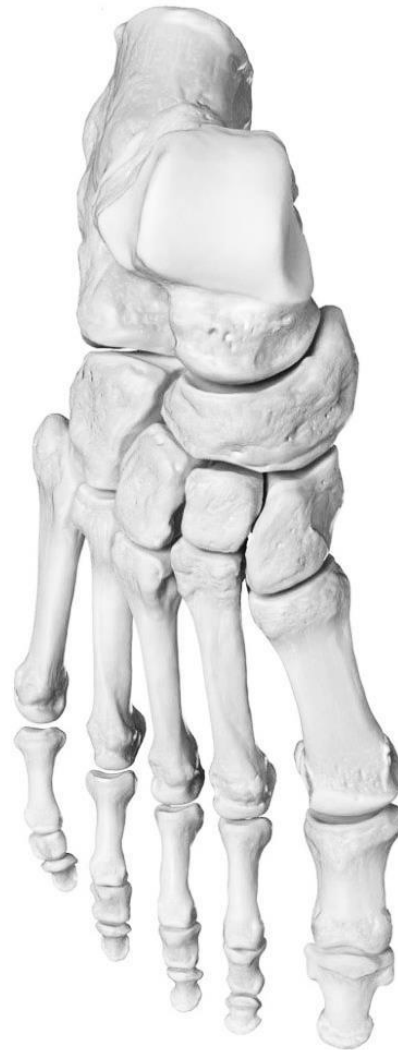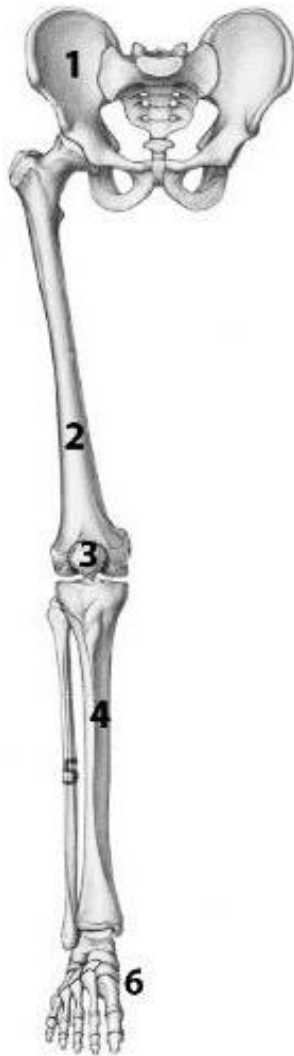COLOR the following bones of hand:

Carpal bone

Metacarpals

Phalanges

Bones of lower limb



COLOR the following bones of foot:

- Tarsal bones
- Metatarsals
- Phalanges

WRITE the name of structures labeled by the number:

1. _____
2. _____
3. _____
4. _____
5. _____
6. _____

LABORATORY CLASS № 6
CLASSIFICATION OF BONE CONNECTION. CONNECTION OF CRANIUM BONES,
TRUNK, UPPER AND LOWER LIMBS. FINAL CONTROL OF THE SECTION
“OSTEOLOGY. ARTHROLOGY”

Control questions:

1. Classification of bone connections.
2. Morphofunctional characteristics of continuous and discontinuous (synovial) connections. Connections of the spine: syndesmosis, structure of the intervertebral symphysis.
3. Joints of the spinal column: structure of the middle and lateral atlantoaxial joints. Atlantooccipital joint: articular surfaces, ligaments, movements.
4. Joints of thorax: costovertebral and sternocostal joints: structure, types of movements.
5. Temporomandibular joint: morphofunctional characteristics.
6. Names and general morphofunctional characteristics of the joints of the upper and lower limbs.

Students should be able to find on anatomical preparations and visual aids following structures and to know their Latin names:

Connections of bones. 1. Intervertebral disc. 2. Intervertebral joint. 3. Atlanto-occipital joint. 4. Median atlanto-axial joint. 5. Lateral atlanto-axial joint. 6. Shoulder joint. 7. Elbow joint. 8. Hand joint. 9. Hip joint. 10. Knee joint. 11. Ankle joint. 12. *Temporomandibular joint* (articular disc, lateral ligament, sphenomandibular ligament, stylomandibular ligament).

GLOSSARY

Joints, also known as articulations, are a form of connection between bones. They provide stability to the skeletal system as well as allowing for specialized movement.

Joints can be classified:

1. Histologically, on the dominant type of connective tissue (fibrous, cartilaginous, and synovial).
2. Functionally, based on the amount of movement permitted (synarthrosis (immovable), amphiarthrosis (slightly moveable), and diarthrosis (freely moveable)).

The two classification schemes correlate:

1. *Fibrous joints* are *synarthroses*.
2. *Cartilaginous joints* are *amphiarthroses*.
3. *Synovial joints* are *diarthroses*.

Fibrous joints are also called “fixed” or “immovable”. These joints have no joint cavity and are connected via fibrous connective tissue. They are divided into suture, schindylesis, syndesmosis and gomphosis.

Suture is a type of fibrous joint that is only found in the skull. Many of the bones of the skull to remain unfused at birth. The term “fontanelle” is used to describe the resulting “soft spots”. The relative positions of the bones continue to change during the life of the adult. In old age, cranial sutures may ossify (turn to bone) completely.

Types of sutures:

Serrate sutures — similar to a denticulate suture (coronal suture, sagittal suture).

Plane sutures — edges of the bones are flush with each other (internasal suture).

Squamosal sutures — edges are bevelled so the plane of the suture is sloping (temporo-parietal suture).

Schindylesis is an articulation where a ridge gets into a grooved surface (articulation between the rostrum of the sphenoid and the upper border of the vomer).

Syndesmosis is a fibrous joint held together by a strong membrane or ligaments (tibiofibular syndesmosis).

Gomphosis is the junction of a tooth and a socket in the jaw. The tooth is attached by a ligament called the periodontium.

Cartilaginous joints are connected entirely by cartilage (fibrocartilage or hyaline). Cartilaginous joints allow little movement.

Primary cartilaginous joints are known as “synchondrosis”. These bones are connected by hyaline cartilage and sometimes occur between ossification centers. These joints here allow for only a little movement, such as in the spine or ribs.

Secondary cartilaginous joints are known as “symphysis”. These include fibrocartilaginous and hyaline joints, which usually occur at the midline. Some examples of secondary cartilaginous joints in human anatomy would be the manubriosternal joint (between the manubrium and the body of the sternum), intervertebral discs and the pubic symphysis.

Synovial joints join bones or cartilage with a fibrous joint capsule that is continuous with the periosteum of the joined bones, constitutes the outer boundary of a synovial cavity, and surrounds the bones’ articulating surfaces. They are the most common type of joint in the human body. This joint unites long bones and permits free body movement and greater mobility. The synovial cavity is filled with synovial fluid. The joint capsule is made up of an outer layer of fibrous membrane, which keeps the bones together structurally, and an inner layer, the synovial membrane, which seals in the synovial fluid. Depending on **the number of articulating bones** *simple* (two articular surfaces) and *compound* joints are distinguished. Movements in the joints are carried out around one, two or three axes (respectively *uniaxial*, *biaxial* and *multiaxial joints*). *Complex* joint is characterized by the presence of an intracapsular articular disc or meniscus between the articulating surfaces. According to **the shape** of the articular surfaces they can be *pivot*, *hinge*, *saddle*, *ellipsoid*, *plane*, *ball and socket*.

Joints of the vertebral column are craniovertebral joints, intervertebral joints, costovertebral joints, and the sacroiliac joints.

Craniovertebral junction is composed of two major joints: the atlantooccipital joint and the atlantoaxial joint.

Atlantooccipital joint is a paired synovial ellipsoid articulation between the occipital bone and the first cervical vertebra (atlas). The principal movement at the atlantooccipital joint is flexion-extension.

Atlantoaxial joint is a complex joint between the atlas (C1) and the axis (C2). It is composed of three synovial joints:

Median atlantoaxial joint is formed between the dens of axis and an osteoligamentous ring of the atlas anteriorly and transverse ligament posteriorly. It is classified as a pivot joint.

Lateral atlantoaxial joints are bilateral joints formed between the lateral masses of the atlas and axis. These joints are classified as plane joints.

The primary movement of the atlantoaxial joint complex is rotation.

Intervertebral joints connect directly adjacent vertebrae of the vertebral column.

Connection of the vertebral bodies:

Intervertebral discs. Each disc consists of a thick outer ring of fibrous cartilage called the annulus fibrosus which surrounds an inner, central gelatinous core called the nucleus pulposus.

Anterior longitudinal ligament is a strong and broad band of fibrous tissue connects the anterolateral surfaces of the vertebral bodies and intervertebral disks from occipital bone and anterior tubercle of vertebra C1 (atlas) to the sacrum.

Posterior longitudinal ligament runs along the posterior surfaces of the vertebral bodies within the vertebral canal. It is attached to the vertebral bodies and mainly the intervertebral discs along its length from the body of C2 (axis) to the sacrum.

Connection of the vertebral arches:

Zygapophyseal joints are formed between the superior and the inferior articular processes of adjoining vertebrae.

Ligamenta flava (singular: ligamentum flavum) are thin, broad ligaments that connect the laminae of adjacent vertebral arches on each side.

Interspinous ligaments connect adjacent vertebral spinous processes.

Supraspinous ligament connects the tips of the spinous processes from vertebra C7 to the sacrum.

Nuchal ligament is a thick, triangular, fibroelastic band at the back of the neck that extends between the base of the skull and C7 in the midline.

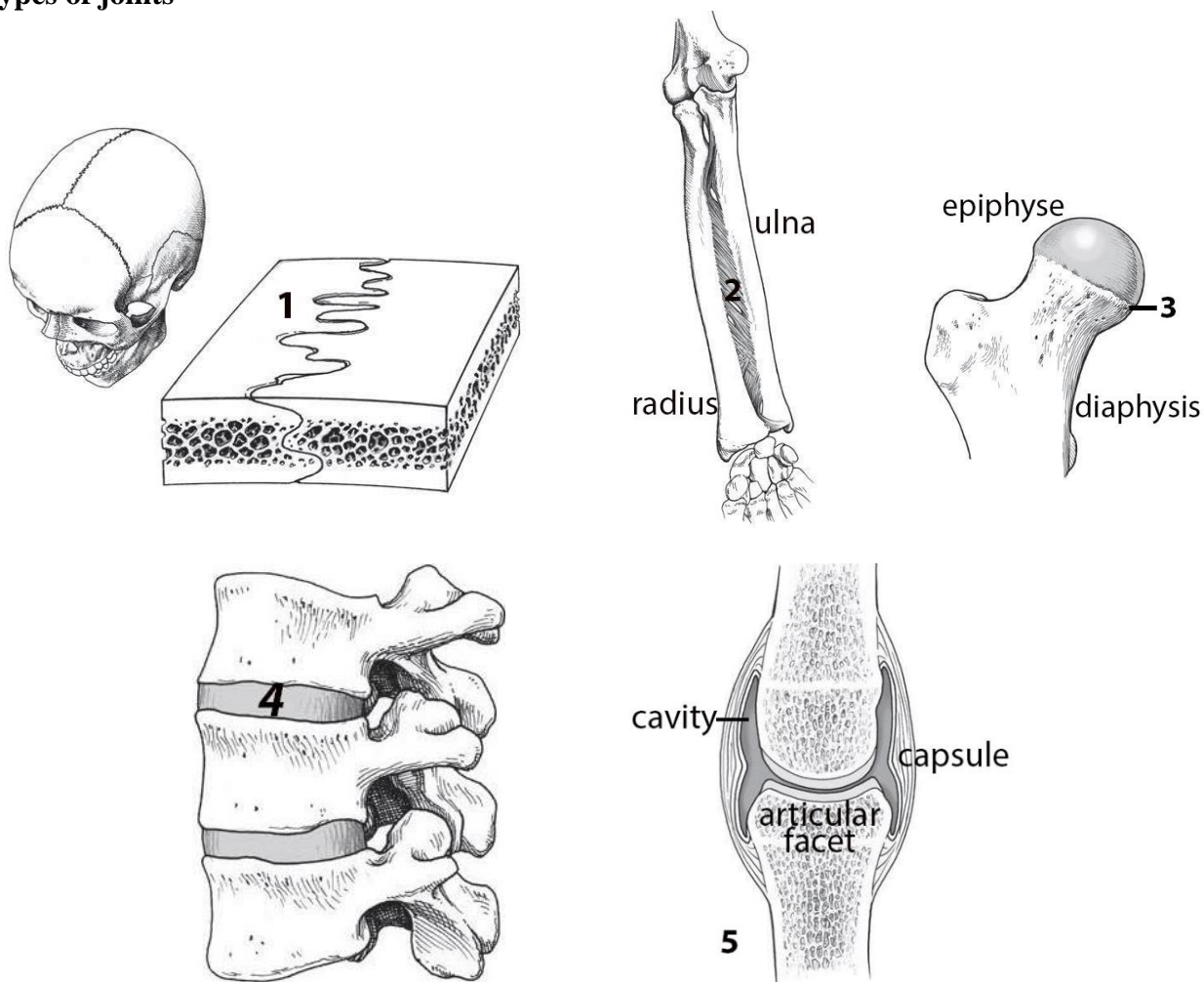
Intertransverse ligaments connect the transverse processes of adjoining vertebrae.

Temporomandibular joints (TMJ) are the two joints connecting the jawbone to the skull. It is a bilateral synovial articulation between the temporal bone of the skull above and the mandible below. This joint is unique in that it is a bilateral joint that functions as one unit. The main components of TMG are the joint capsule, articular disc, mandibular condyles, mandibular fossa, articular tubercle of the temporal bone, temporomandibular ligament, stylomandibular ligament and sphenomandibular ligament. Cartilage disc corrects discrepancy between the shape and size of the articular surfaces and separates the joint cavity into the upper and lower floors. The movements of the mandible are carried out around the frontal (depression and elevation) and the sagittal axis (displacement to the side).

For the notes:

SELF-INSTRUCTIONAL MATERIALS

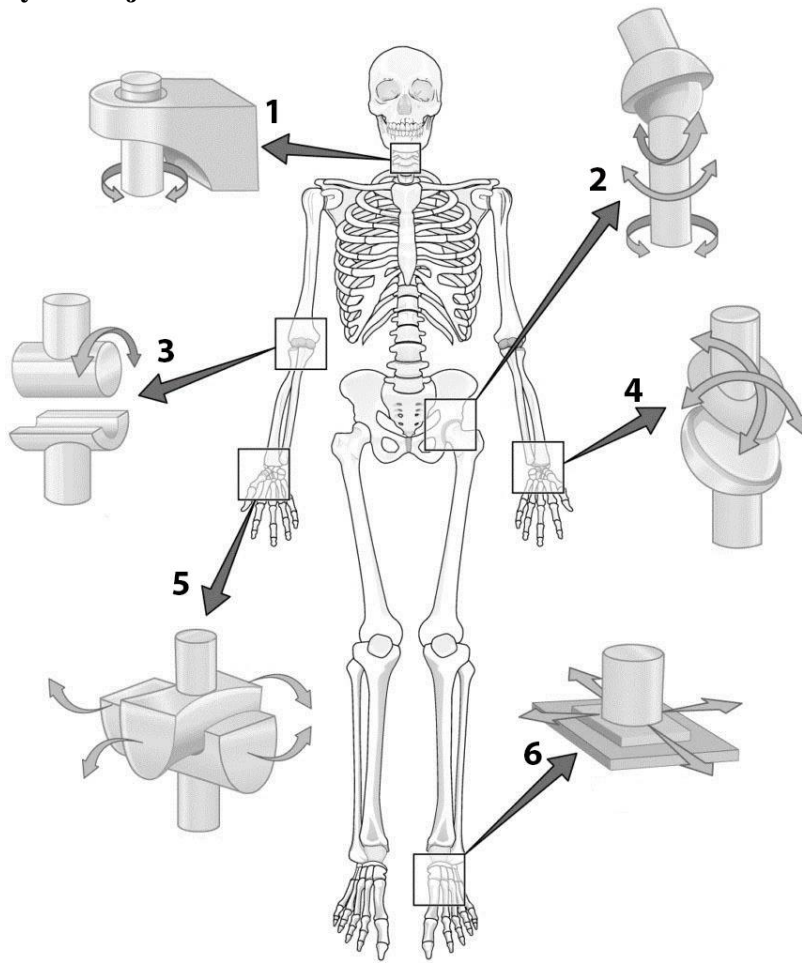
Types of joints



WRITE the name of joints, indicated by numbers:

1. Suture (_____)
2. Interosseous membrane (_____)
3. Epiphyseal plate (_____)
4. Secondary cartilaginous (_____)
5. _____

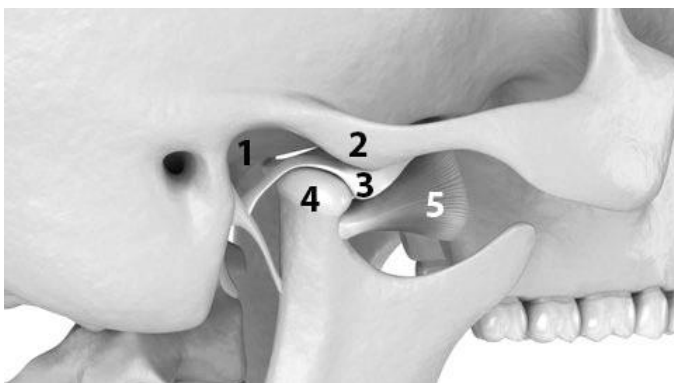
Different types of synovial joints



WRITE the name kinds of joints, indicated by numbers:

1. _____ joint (between C1 & C2)
2. _____ joint (hip joint)
3. _____ joint (elbow)
4. _____ joint (between radius & carpal bone of wrist)
5. _____ joint (between trapezium carpal bone & 1st metacarpal bone)
6. _____ joint (between tarsal bones)

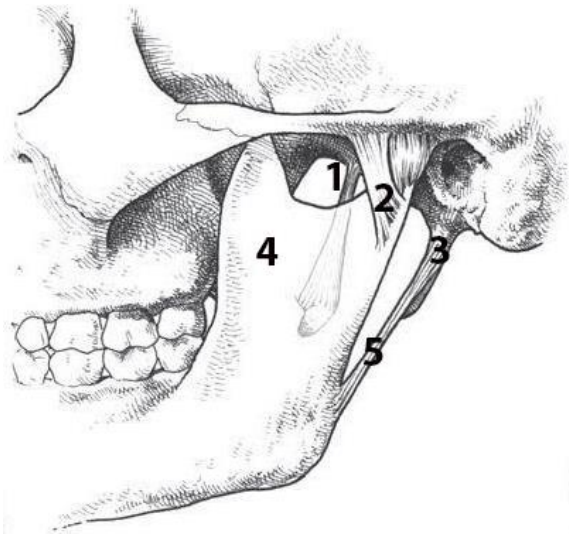
Temporomandibular joint (lateral view)



WRITE the name of structures labeled by the number:

1. _____
2. _____
3. Articular _____
4. _____ of mandible
5. Lateral pterygoid muscle

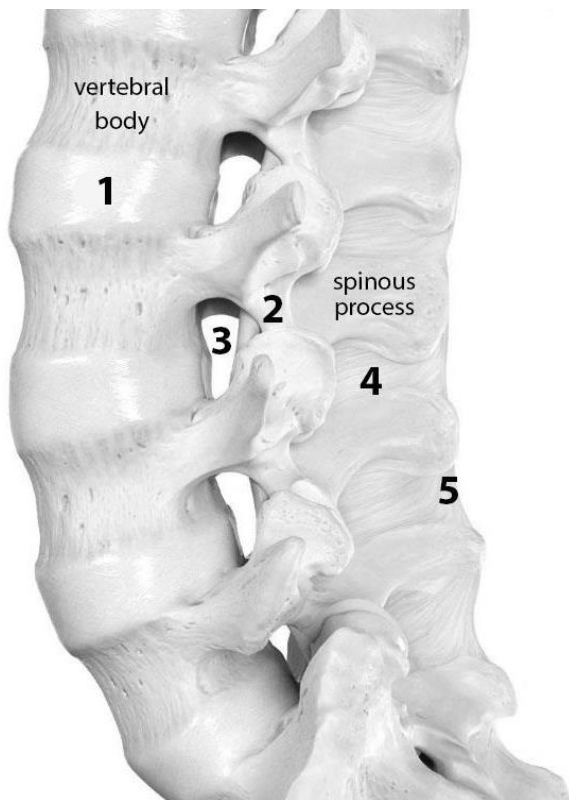
Ligaments of temporomandibular joint



WRITE the name of structures labeled by the number:

1. _____ ligament
2. _____ ligament
3. _____
4. Mandible
5. _____ ligament

The lumbar spine with ligaments (lateral view)



WRITE the name of structures labeled by the number:

1. _____
2. _____ ligament
3. _____ foramen
4. _____ ligament
5. _____ ligament

FINAL QUIZ «BONES, JOINTS»

Control questions:

1. Classification of bones.
2. Vertebral column.
3. Structure of the cervical vertebrae. Characteristic features of the structure of atlas and axis.
4. Structure of thoracic vertebrae.
5. Ribs and sternum: structure, classification of ribs.
6. Thoracic cage.
7. Skull: bone names, division into the neurocranium and viscerocranium.
8. Structure of the skull bones: frontal, occipital, parietal, sphenoid, ethmoid, temporal.
9. Structure of maxilla and mandible.
10. Nasal cavity: bone walls, nasal meatuses and communication with the paranasal sinuses.
11. Orbit: bone walls, foramina, fissures and canals of the orbit.
12. Calvaria bones; characteristic features of structure and development. Sutures of calvaria.
13. External and internal base of the skull; topography of surfaces.
14. Structure of the hard palate.
15. Lateral aspect of the skull: bone walls of the temporal and infratemporal fossa.
16. Pterygopalatine fossa. Connection with other skull cavities.
17. Specific features of the structure of the newborn's skull.
18. Skeleton of the upper limb: departments, interposition of bones, general plan of the structure.
19. Skeleton of the lower limb: departments, interposition of bones, general plan of the structure.
20. Classification of bone connections.
21. Connections of the vertebral column: ligaments, joints. Connections of thorax.
22. Atlantoaxial joints: articular surfaces, ligaments, movements.
23. Atlantooccipital joint: articular surfaces, ligaments, movements.
24. Temporomandibular joint: characteristic, structure, types of movements.
25. Names and general characteristics of the joints of the upper and lower limbs.

LABORATORY CLASS № 7

GENERAL CHARACTERISTICS OF MUSCLES. NECK. MUSCLES. NECK FASCIA

Control questions:

1. Structure of the muscle as an organ. Classification and functions of skeletal muscles.
2. Auxillary apparatus of muscles: fascia, synovial sheath and bursa, osteofibrous canals, sesamoid bones.
3. Classification of the neck muscles: genetic and topographic.
4. Anterior neck muscles: origin and insertion, functions.
5. Lateral neck muscles: origin and insertion, functions.
6. Posterior neck muscles: origin and insertion, functions.
7. Structure of the neck fasciae and topography of its plates. Spaces.
8. Neck topography, division into regions. Anterior and posterior neck triangles.

Students should be able to find on anatomical preparations and visual aids following structures and to know their Latin names:

Muscles and fasciae of the neck. 1. Platysma. 2. Sternocleidomastoid muscle. 3. Digastric muscle. 4. Stylohyoid muscle. 5. Mylohyoid muscle. 6. Geniohyoid muscle. 7. Sternohyoid muscle. 8. Omohyoid muscle. 9. Sternothyroid muscle. 10. Thyrohyoid muscle. 11. Anterior, middle, posterior scalenus muscles. 12. Longus colli muscle. 13. Longus capitis muscle. 14. Superficial, pretracheal, prevertebral layers of deep cervical fascia. 15. Suprasternal space. 16. Pretracheal space. 17. Retropharyngeal space. 18. Carotid sheath. 19. Interscalene space. 18. Anterior triangle of the neck. 19. Carotid triangle. 20. Omotracheal triangle. 21. Submandibular triangle. 22. Submental triangle. 23. Lateral triangle of the neck. 24. Omotrapezoid triangle. 25. Omoclavicular triangle.

GLOSSARY

Skeletal muscles consist of striated muscle tissue and attached by tendons to bones of a skeleton. Skeletal muscles are voluntary muscles under the control of the somatic nervous system. The skeletal muscles are a vital part of the musculoskeletal system. They serve a variety of functions, including: chewing and swallowing, expanding and contracting of chest cavity by breathing, maintaining body posture, moving the bones in different parts of body, protecting joints and holding them in place, etc.

Fascia is a layer of fibrous connective tissue that surrounds muscles, groups of muscles, blood vessels, and nerves, binding some structures together, while permitting others to slide smoothly over each other.

Synovial sheath is one of the two membranes of a tendon sheath which covers a tendon. The other membrane is the outer fibrous tendon sheath. The tendon invaginates the synovial sheath from one side so that the tendon is suspended from the membrane by the mesotendon, through which the blood vessels reach the tendon.

Synovial bursa is a small fluid-filled sac lined by synovial membrane with an inner capillary layer of viscous synovial fluid. It provides a cushion between bones and tendons and/or muscles around a joint. This helps to reduce friction between the bones and allows free movement. Bursae are found around most major joints of the body.

Osteofibrous canal exists between the bone and the fibrous bridge formed by the thickening of the fascia. The canal contains the tendon of the muscle, surrounded by the sheath. Sheath consists of two plates of the synovial membrane, one of which fuses with the tendon. The presence of fluid between the sheets reduces friction when the muscle contracts.

Trochlea — is a term in anatomy. It refers to a grooved structure reminiscent bone protuberance through which the tendon of the muscle is tossed.

The muscles of the neck consist of 3 main groups of muscles: anterior, lateral and posterior groups, based on their position in the neck.

Anterior neck muscles are a group of muscles covering the anterior aspect of the neck. They are further divided into 3 subgroups:

The *superficial muscles* are the most superficial in the anterior neck, and include the platysma and sternocleidomastoid.

The *suprahyoid muscles* are found superior to the hyoid bone, connect the hyoid bone to the mandible and the base of the skull and form the floor of the oral cavity and include the digastric, mylohyoid, geniohyoid and stylohyoid.

The *infrahyoid muscles* are four muscles located inferior to the hyoid bone, that connect it to the larynx, sternum and scapula and consist of the sternohyoid, omohyoid, sternothyroid and thyrohyoid.

The *anterior vertebral muscles* are a deep group of muscles located just anterior to the cervical vertebral column. These include the rectus capitis anterior, rectus capitis lateralis, longus capitis and longus colli. These muscles are surrounded by the prevertebral fascia of the neck, which is why they are commonly referred to as prevertebral muscles. The principal function of these muscles is flexion of the head to varying degrees.

The **lateral neck muscles**, also called the lateral vertebral muscles, are a group of muscles that pass obliquely along the lateral sides of the neck. These include the anterior, middle and posterior scalene muscles, which extend between the transverse processes of the cervical vertebrae and the upper two ribs. Due to their attachments, these muscles mainly produce ipsilateral flexion of the neck.

The **posterior neck muscles** connect the skull to the spinal column and pectoral girdle. These muscles can be divided into three layers.

Superficial layer: Trapezius, splenius capitis and splenius cervicis.

Deep layer: cervical transversospinalis muscles (semispinalis capitis, semispinalis cervicis, multifidus cervicis).

Deepest layer: suboccipital muscles, interspinales cervicis and intertransversarii colli muscles.

Structures making up the neck are surrounded by a layer of subcutaneous tissue called the **superficial cervical fascia**, and are compartmentalized by a second group of fasciae referred to as **deep cervical fascia**.

Superficial cervical fascia is a thin layer of subcutaneous connective tissue that lies between the dermis of the skin and the investing layer of deep cervical fascia. It surrounds and contains platysma muscle, cutaneous nerves, blood and lymphatic vessels, superficial lymph nodes, and variable amounts of fat.

The **deep cervical fascia** acts to compartmentalize most structures of the neck and prevents the spread of infections. It consists of fascial layers (or sheaths). These layers of the deep cervical fascia also function to support the viscera of the neck (e.g., the thyroid gland), muscles, blood and lymphatic vessels, and deep lymph nodes. They also form the

Investing layer covers sternocleidomastoid and trapezius muscles and is fixed to the spinous and transverse processes of the vertebrae, the body of mandible, the sternum and clavicle.

Pretracheal layer extends from the posterior surface of the sternum and clavicle to the hyoid bone. It is made up of two parts, a muscular part (forms the fascial sheath for the infrahyoid muscles) and a visceral (contains the trachea, thyroid gland and the oesophagus).

Prevertebral layer surrounds the deep muscles of the neck and is fixed to the transverse processes of the vertebrae.

Carotid sheath that wraps around vessels like the common carotid arteries, internal jugular veins, and the vagus nerves.

The fascial **neck spaces** are theoretical spaces that are created between the layers of the deep cervical fascia and are filled with loose areolar connective tissue. The hyoid bone is the main anatomical structure that limits the spread of infection between the spaces and for that reason they are categorised according to their position in relation to the hyoid bone. The three main groups of fascial spaces are known as the: suprahyoid, infrahyoid, fascial spaces that span the entire length of the neck.

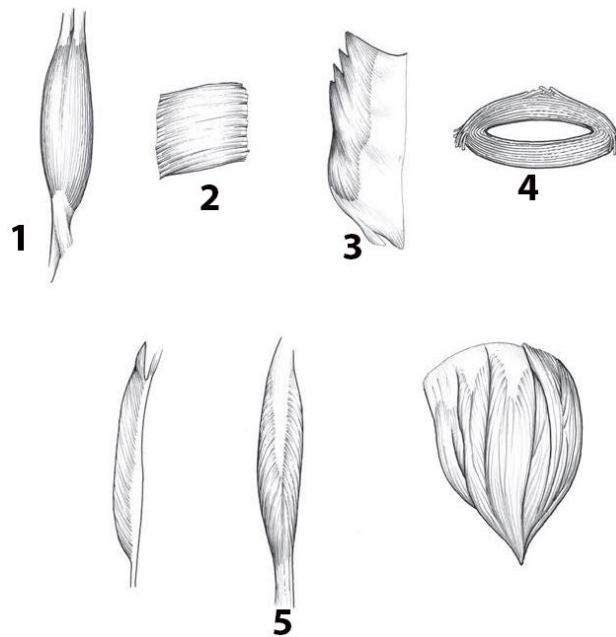
The **triangles** of the neck are the topographic areas of the neck bounded by the neck muscles. The sternocleidomastoid muscle divides the neck into the two major neck triangles; the **anterior triangle** and the **posterior triangle** of the neck, each of them containing a few subdivisions.

The **anterior triangle** is found anteriorly to the sternocleidomastoid muscle. It is formed by the anterior border of sternocleidomastoid laterally the median line of the neck medially and by the inferior border of the mandible superiorly. The anterior triangle is further subdivided into the: *submandibular triangle*, *submental triangle*, *carotid triangle*, *muscular (omotracheal) triangle*.

The **posterior triangle** is found posteriorly to the sternocleidomastoid muscle. It has three borders. The anterior border is the posterior margin of the sternocleidomastoid muscle. The posterior border is the anterior margin of the trapezius muscle, while the inferior border is the middle one-third of the clavicle. Subdivisions: *occipital (omotrapezoid triangle) triangle*, *supraclavicular (omoclavicular) triangle*.

SELF-INSTRUCTIONAL MATERIALS

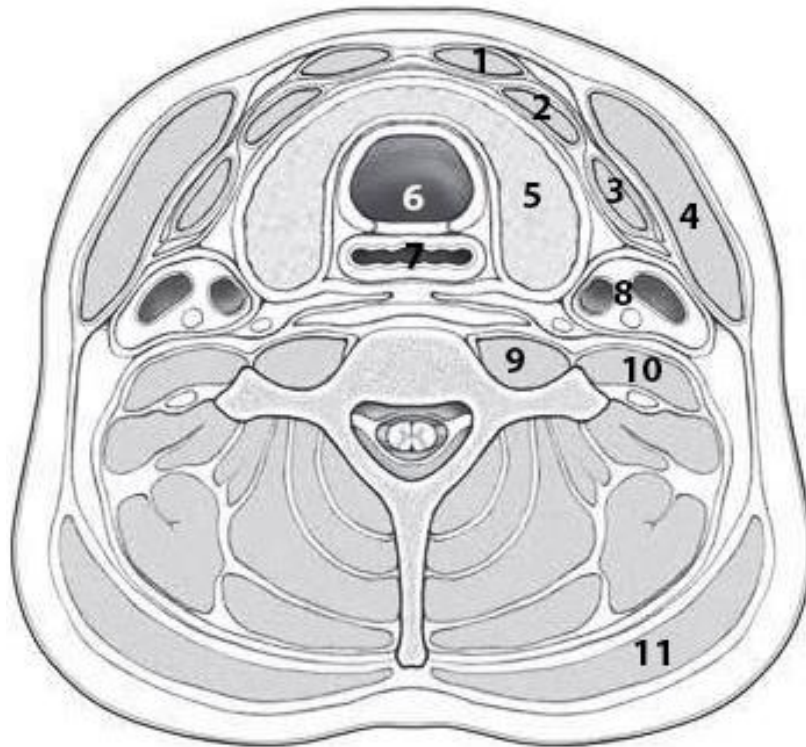
Skeletal Muscle Shapes



WRITE the name of the five different conformations that characterize the gross appearance of skeletal muscle:

1. _____ (thick in the center and tapered at the ends)
2. _____ (four-sided muscle)
3. _____ (parallel fibers)
4. _____ (form sphincters that close off tubes)
5. _____ (feathered in appearance: unipennate, bipennate, or multipennate forms)

Transverse section through the neck at the T₁ level (superior view)



COLOR each of the following layers of cervical fascia, using a different color for each of them:

- Investing layer
- Pretracheal layer (muscular plate)
- Pretracheal layer (visceral plate)
- Prevertebral layer
- Carotid sheath

WRITE the name of structures labeled by the number:

1. _____
2. _____
3. _____
4. _____
5. _____
6. _____
7. _____

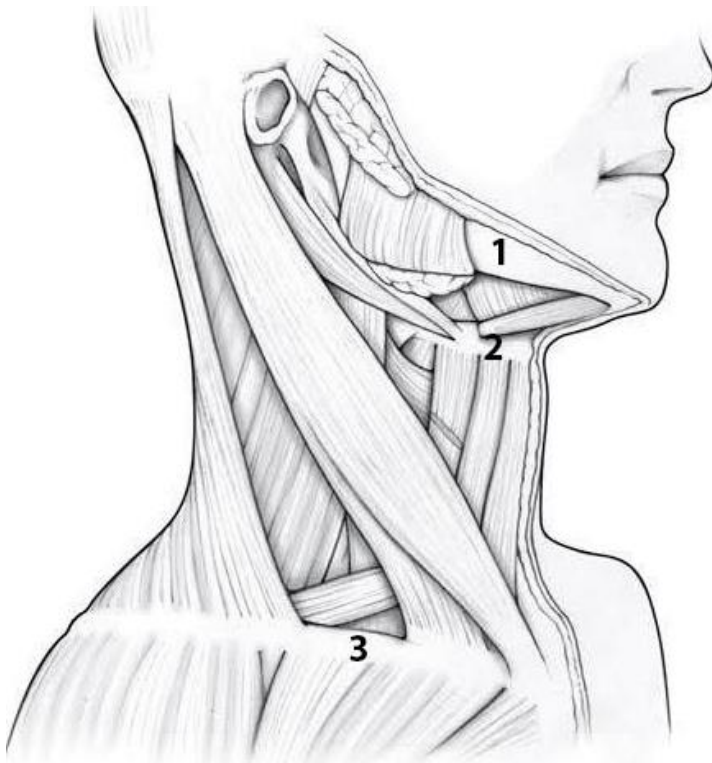
8. Common carotid artery, internal jugular vein & vagus nerve

9. Longus colli

10. Scalenus anterior

11. Trapezius

Muscles of the neck (lateral view)



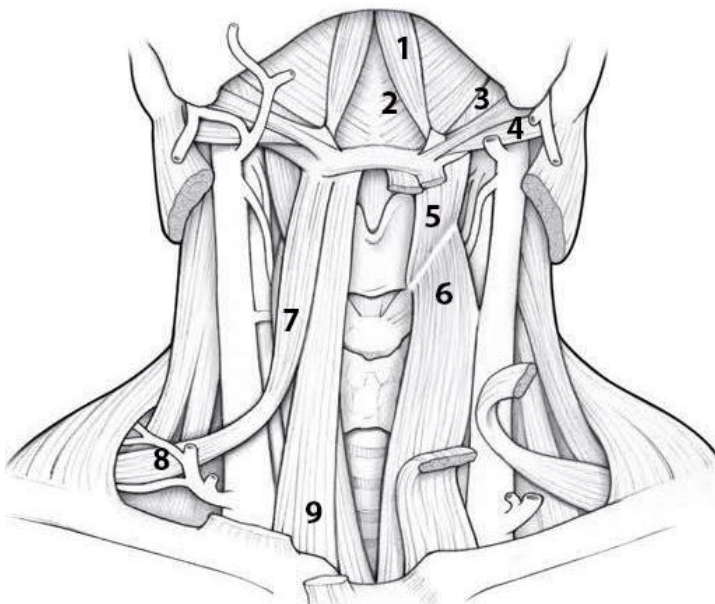
COLOR each of the following muscles, using a different color for each muscle:

- Digastric
- Sternocleidomastoid
- Thyrohyoid
- Sternohyoid
- Sternothyroid
- Omohyoid

WRITE the name of structures labeled by the number:

- 1. _____
- 2. _____
- 3. _____

Muscles of the neck (anterior view)



WRITE the name of muscles labeled by the number:

- 1. _____
- 2. _____
- 3. _____
- 4. _____
- 5. _____
- 6. _____
- 7. _____
- 8. _____
- 9. _____

LABORATORY CLASS № 8 MUSCLES AND FASCIAE OF THE HEAD

Control questions:

1. Classification of the muscles of the head.
2. Muscles of mastication: sources of development, general characteristics.
3. Parts, origin and insertion of the masseter muscle, functions.
4. Temporalis muscle: origin and insertion, functions.
5. Medial pterygoid muscle: origin and insertion, functions.
6. Origin and insertion of the lateral pterygoid muscle, functions.
7. Sources of development, general characteristics and classification of facial muscles. Origin and insertion, functions.
8. Fascia of the head: masseteric, temporal, buccopharyngeal. Pterygomandibular raphe.

Students should be able to find on anatomical preparations and visual aids following structures and to know their Latin names:

Muscles and fascia of the head. 1. Masseter muscle. 2. Temporalis muscle. 3. Lateral, medial, pterygoid muscles. 4. Occipitofrontalis muscle. 5. Nasal muscle. 6. Orbicularis oculi muscle. 7. Orbicularis oris muscle. 8. Major (minor) zygomatic muscle. 9. Levator labii superioris muscle. 10. Depressor labii inferioris muscle. 11. Levator labii inferioris muscle. 12. Depressor anguli oris muscle. 13. Mentalis muscle. 14. Buccinator muscle. 15. Temporal, masseteric, buccopharyngeal fascia. 16. Pterygomandibular raphe.

GLOSSARY

The **muscles of mastication** develop from the first pharyngeal arch and are innervated by the trigeminal nerve. They originate on the bones of the skull and are attached to the lower jaw, ensuring its movement in the temporomandibular joint.

Masseter muscle has superficial and deep parts. The superficial part starts from the anterior $2/3$ of the zygomatic arch, the deep part — from the posterior $2/3$ of the zygomatic arch. Both parts of the masseter are attached to the masticatory tuberosity of the lower jaw. Function: raises the lower jaw, with unilateral contraction, shifts the jaw to its side. The superficial part of masseter pushes the lower jaw forward.

Temporalis muscle is the greatest masticatory muscle, its belly originates from the bones of the temporal fossa and is attached to the coronoid process of the mandible. Function: closes the mouth, raising the lower jaw; the posterior muscle fibers pull the protruding lower jaw backward.

Medial pterygoid muscle originates in the pterygoid fossa of the pterygoid process of the sphenoid bone and is attached to the pterygoid tuberosity of the mandible. Function: raises the lower jaw, with one-sided contraction, shifts it to the opposite side.

Lateral pterygoid muscle has two heads — upper and lower. The superior head originates from the infratemporal crest of the greater wing of the sphenoid bone; attached to the capsule of the temporomandibular joint and the articular disc. The lower head starts from the lateral plate of the pterygoid process of the sphenoid bone, attaches to the pterygoid fossa (on the neck of the mandible). With bilateral muscle contraction, the lower jaw moves forward, with unilateral contraction, it shifts in the opposite direction.

The **facial muscles** also known as the mimetic muscles are the main constituents of your face, playing a significant role in facial expression. They develop from the second pharyngeal arch, have one source of innervation — the facial nerve and blood supply — branches of the external carotid artery. These muscles do not have a double attachment to the bones, with two or one end they are fixed to the skin or mucous membranes. Subdivided into *orbital group, nasal group, oral group, auricular group, scalp and neck group*. When contracting, the muscles of the face change the depth

of skin folds (facial expressions), narrow or expand the oral and palpebral fissures, take part in chewing and speech.

The **masseteric fascia** (parotideomasseteric fascia) is a strong layer of fascia derived from the deep cervical fascia on the human head and neck. It covers the masseter, and is firmly connected to it. Above, this fascia is attached to the lower border of the zygomatic arch, and behind, it invests the parotid gland proceeding into the parotid fascia.

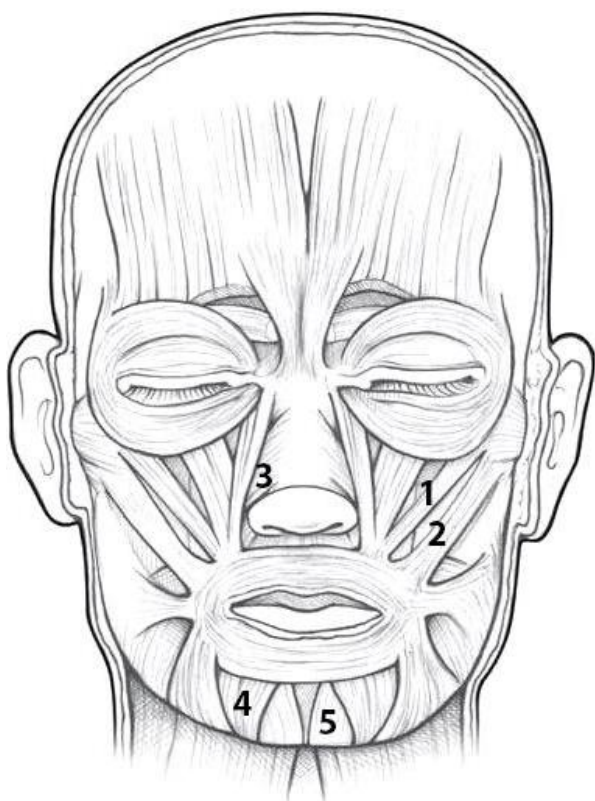
The **temporal fascia** covers the temporalis muscle. It is a strong, fibrous investment, covered, laterally, by the auricularis anterior and superior, by the galea aponeurotica, and by part of the orbicularis oculi. Superiorly, it is a single layer, attached to the entire extent of the superior temporal line; but inferiorly, where it is fixed to the zygomatic arch, it consists of two layers, one of which is inserted into the lateral, and the other into the medial border of the arch. The parotid fascia proceeds to the temporal fascia.

The **buccopharyngeal fascia** represents the posterior portion of the pretracheal fascia. It covers the superior pharyngeal constrictor muscles, and buccinator.

The **pterygomandibular raphe** (pterygomandibular ligament) is a ligamentous band of the buccopharyngeal fascia. It is attached superiorly to the pterygoid hamulus of the medial pterygoid plate, and inferiorly to the posterior end of the mylohyoid line of the mandible. It connects the buccinator muscle in front to the superior pharyngeal constrictor muscle behind.

SELF-INSTRUCTIONAL MATERIALS

Muscles of facial expression (frontal view)



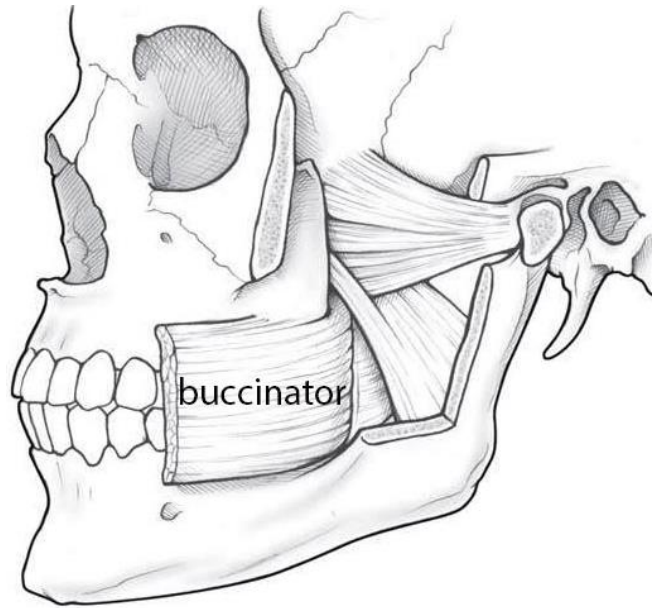
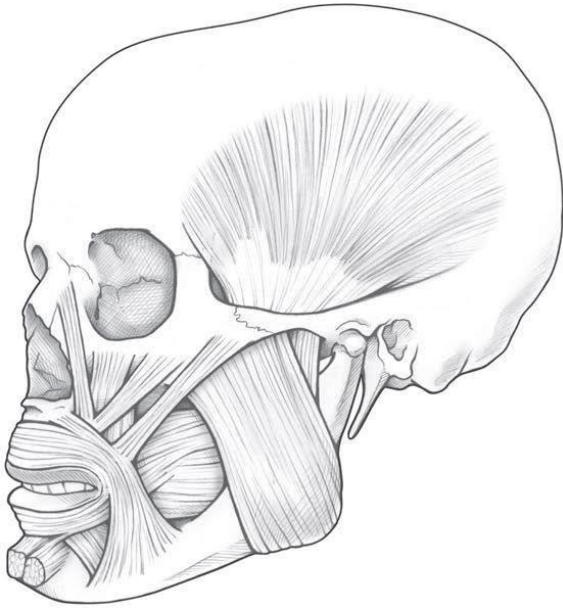
COLOR some of the more important muscles of facial expression listed below, using a different color for each muscle:

- Epicranius (frontal belly)
- Orbicularis oculi
- Levator labii superioris
- Orbicularis oris
- Depressor anguli oris
- Risorius

WRITE the name of structures labeled by the number:

1. _____
2. _____
3. _____
4. _____
5. _____

Muscles of mastication



COLOR each of the following muscles of mastication, using a different color for each:

- Temporalis
- Masseter
- Lateral pterygoid
- Medial pterygoid

For the notes:

LABORATORY CLASS № 9
MUSCLES OF TRUNK, UPPER AND LOWER LIMBS. FINAL CONTROL
OF THE SECTION “MYOLOGY”

Control questions:

1. Muscles of back: superficial and deep, general characteristics, functions.
2. Muscles of thorax superficial and deep, general characteristics, functions.
3. Diaphragm: topography, structure, functions.
4. Muscles of abdomen: general morphofunctional characteristics.
5. Topography of the anterior abdominal wall: linea alba, umbilical ring, inguinal canal.
6. Muscles of the shoulder girdle and free part of the upper limb: general morphofunctional characteristics.
7. Muscles of the pelvic girdle and free part of the lower limb: general morphofunctional characteristics.

Students should be able to find on anatomical preparations and visual aids following structures and to know their Latin names:

Muscles of back. 1. Trapezius muscle. 2. Latissimus dorsi muscle. 3. Rhomboid muscles. 4. Serratus posterior superior and inferior muscle.

Muscles of thorax. 1. Serratus posterior muscle. 2. Levatores costarum muscle. 3. Intercostal (external, internal) muscle. 3. Subcostal muscle. 4. Transversus thoracis muscle. 5. Subclavius muscle. 6. Pectoralis major and minor muscles. 7. Serratus anterior muscle.

Muscles of abdomen. 1. External and internal oblique abdominal muscles. 2. Transverse abdominal muscle. 3. Rectus abdominis muscle. 4. Linea alba. 5. Umbilical ring. 6. Inguinal canal.

Muscles of the upper limb. 1. Muscles of the shoulder girdle: deltoid, supraspinatus, infraspinatus and subscapularis muscles; teres minor and major muscles. 2. Muscles of the arm: biceps, triceps, coracobrachialis and brachial muscles. 3. Anterior muscles of the forearm: flexor carpi radialis and flexor carpi ulnaris; flexor digitorum superficialis and profundus; brachioradialis muscle; pronator quadratus and teres. 4. Posterior muscles of the forearm: extensor carpi radialis longus; extensor carpi ulnaris; extensor digitorum; supinator. 5. Muscles of the hand: extensor pollicis longus and brevis, opponens pollicis and digiti minimi.

Muscles of the lower limb. 1. Muscles of the pelvic girdle: gluteus maximus, medius, minimus. 2. Muscles of the thigh: quadriceps femoris; sartorius muscle; biceps, semitendinosus and semimembranosus muscles; brevis, longus magnus adductor. 3. Muscles of leg: anterior and posterior tibialis muscles; extensor digitorum longus; triceps surae; flexor digitorum longus; fibularis longus and brevis. 4. Dorsal and plantar interossei muscles.

GLOSSARY

Muscles of back are a group of strong, paired muscles that lie on the posterior aspect of the trunk. The back muscles are divided into two large groups:

The *extrinsic (superficial) back muscles*, which lie most superficially on the back. These muscles are also called immigrant muscles, since they actually represent muscles of the upper limb that have migrated to the back during fetal development. These muscles are divided into superficial (trapezius, latissimus dorsi, rhomboid major, rhomboid minor, and levator scapulae) and intermediate (serratus posterior superior and serratus posterior inferior muscles).

The *intrinsic (deep) back muscles*, which are also called true back muscles. They are located deep to the extrinsic muscles. Their primary function is to produce movements of the vertebral column. These muscles are divided into superficial (splenius muscles, erector spinae muscles), deep (transversospinales (semispinalis, multifidus and rotatores)), and deepest layers (interspinales and intertransversarii muscles).

Muscles of thorax are the muscles that attach to the thoracic cage. They mainly adjust the volume of the thoracic cavity during inspiration and expiration. The thoracic muscles are grouped into intrinsic and extrinsic.

The *intrinsic muscles* of the thoracic wall are the serratus posterior, levatores costarum, intercostal (external, internal), subcostal and transversus thoracis muscles. Since their primary function is to aid respiratory movements, these muscles are also known as the respiratory muscles.

The *extrinsic muscles* of the thoracic wall are the subclavius, pectoralis major and minor muscles and inferior portion of the serratus anterior muscle. Their main function is to provide functional connection between the thorax and upper limb and neck and through that, to assist movements of the shoulder (pectoral) girdle.

Diaphragm (*m. phrenicus*) is an unpaired, dome shaped skeletal muscle that is located in the trunk. It separates the thoracic and abdominal cavities from each other by closing the inferior thoracic aperture. The diaphragm is the primary muscle that is active in inspiration. There are lumbar, costal and sternal parts of the diaphragm, which converge in the tendon center. In the diaphragm there is an opening of the inferior vena cava, aortic and esophageal hiatus.

Muscles of abdomen consists of five paired muscles and their respective aponeuroses. The muscles of the anterolateral abdominal wall are divided into two main groups:

Lateral flat muscle group situated on either side of the abdomen, which includes three muscles: external oblique, internal oblique and transversus abdominis.

Anterior vertical muscles situated bilaterally to the median fibrous structure called linea alba. They are called rectus abdominis and pyramidalis muscles.

Linea alba extends from the xiphoid process of the sternum to the pubic symphysis and is formed by intertwining bundles of aponeuroses of oblique and transverse abdominal muscles. Approximately in the middle of the alba line there is **an umbilical ring**.

Inguinal canal (*canalis inguinalis*) is a slanting slit in the lower median abdomen above the inguinal ligament, 4–5 cm long. The male canal contains the spermatic cord, the female canal contains the round ligament of the uterus. It has an anterior, posterior, upper and lower walls, a superficial and deep inguinal ring.

Muscles of the upper limb are divided into the muscles of the shoulder girdle and the free part of the upper limb. The latter are divided into the muscles of the arm, forearm and hand.

Muscles of the shoulder girdle perform movements in the shoulder joint. These include the deltoid, subscapularis, supraspinatus and infraspinatus muscles, teres minor and major muscles.

Muscles of the arm are divided into the anterior and posterior groups. Anterior group: biceps, coracobrachialis and brachial muscles, perform flexion in the shoulder and elbow joints. Posterior group — triceps and elbow muscles, perform extension in these joints.

Muscles of the forearm are divided into anterior and posterior groups, arranged in several layers. Anterior group muscles are pronators and flexors of the hand and fingers. Posterior group muscles are supinators and extensors of the hand and fingers.

Muscles of the hand are placed on the palm side, forming the elevation of the thumb (thenar), elevation of the digiti minimi (hypothenar) and muscles of the palm cavity.

Muscles of the lower limb keep the body in a vertical position and carry out movements in the hip, knee, ankle and foot joints. The muscles of the lower limb are divided into the muscles of the lower limb girdle and the muscles of the free lower limb. The latter are divided into hip muscles, leg muscles and foot muscles.

Muscles of the pelvic girdle surround the hip joint, stabilize it and set it in motion.

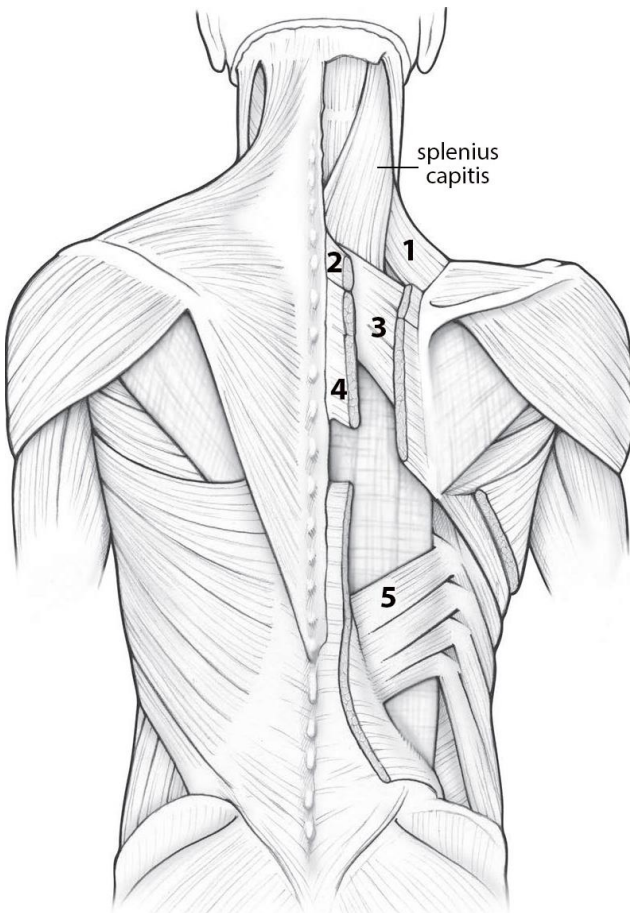
Hip muscles are divided into anterior (extensor), medial (adductors) and posterior (flexor) groups.

Leg muscles are located on the anterior, lateral and posterior surfaces, they carry out movement of the foot in the ankle joint.

Foot muscles lie on its back and plantar surfaces. Back muscles are mainly extensors of the fingers, plantar muscles — flexors.

SELF-INSTRUCTIONAL MATERIALS

Superficial and intermediate back muscles



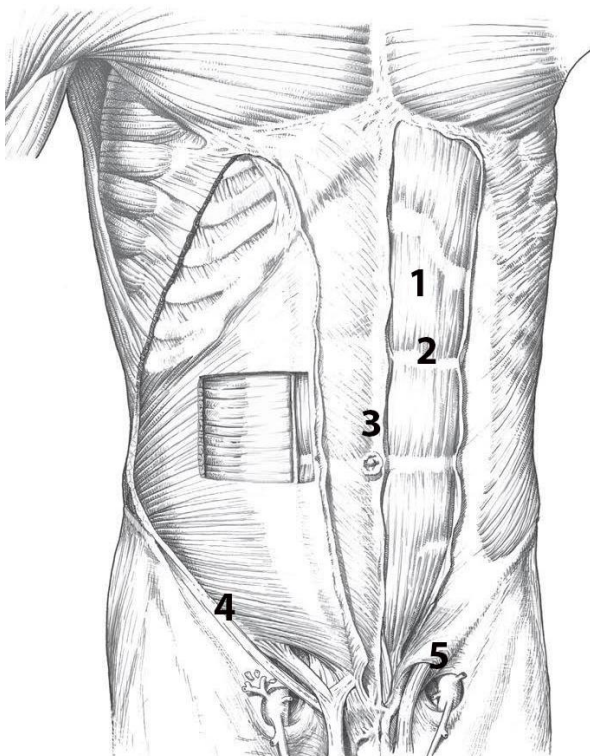
COLOR the following superficial muscles, using a different color for each:

- Trapezius
- Latissimus dorsi

WRITE the name of structures labeled by the number:

1. _____
2. _____ minor
3. _____ superior
4. _____ major
5. _____ inferior

Anterior abdominal wall muscles



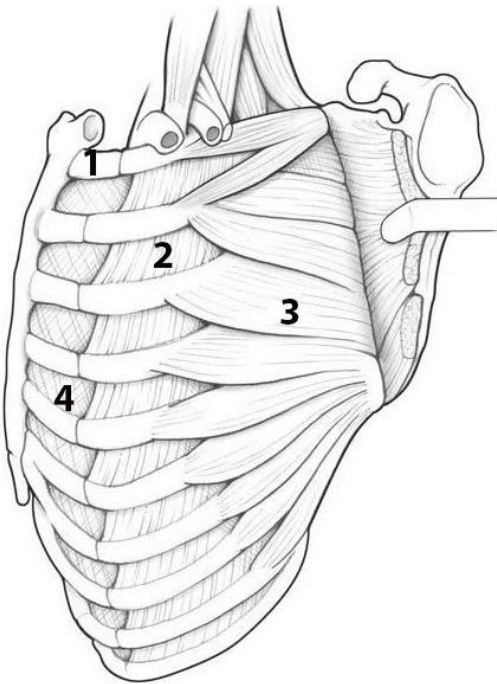
COLOR the following muscles using a different color for each:

- External abdominal oblique
- Internal abdominal oblique
- Transversus abdominis

WRITE the name of structures labeled by the number:

1. _____ abdominis
2. Tendinous intersection
3. _____
4. _____ ligament
5. Superficial _____

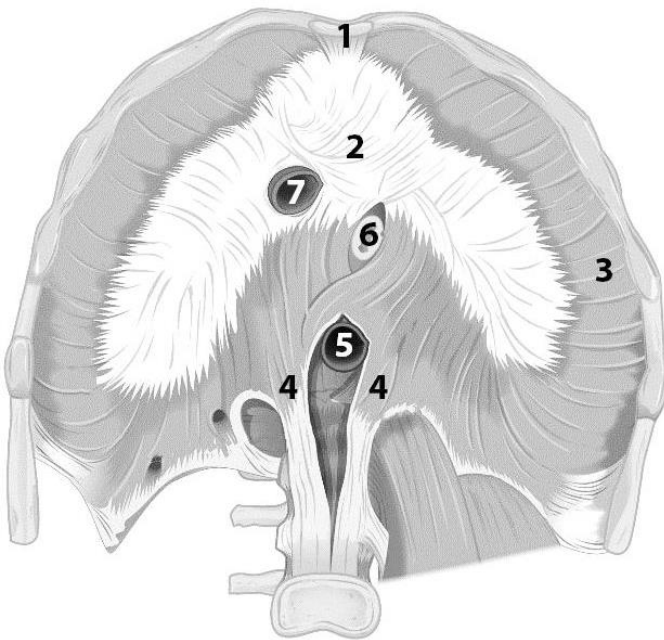
Muscles of thorax



WRITE the name of structures labeled by the number:

1. _____
2. _____ muscle
3. _____
4. _____ muscle

Diaphragm



WRITE the name of structures labeled by the number:

1. _____ part
2. Central tendon
3. _____ part
4. _____ part
5. _____ hiatus
6. _____ hiatus
7. _____ opening

For the notes:

FINAL QUIZ «MUSCLES OF HEAD, NECK, TRUNK, LIMBS»

Control questions:

1. Classification, structure of skeletal muscles.
2. Auxiliary apparatus of muscles.
3. Classification of the neck muscles. Superficial muscles of the neck: origin and insertion, functions.
4. Suprahyoid neck muscles: origin and insertion, functions.
5. Infrahyoid neck muscles: origin and insertion, functions.
6. Anterior vertebral neck muscles: origin and insertion, functions.
7. Lateral neck muscles: origin and insertion, functions.
8. Structure of the cervical fascia and the topography of its layers.
9. Topography of the neck: division into areas. Anterior and posterior triangles of the neck.
10. Muscles of mastication: sources of development, structure, function.
11. Facial muscles sources of development, classification, structure, functions.
12. Muscles of the trunk; classification. General morphofunctional characteristics of the muscles of back.
13. Muscles of thorax: classification, general description.
14. Diaphragm: structure, functions.
15. Muscles of abdomen; general characteristics.
16. Topography of the anterolateral abdominal wall: Linea alba, umbilical ring, inguinal canal.
17. Muscles of the shoulder girdle and free part of the upper limb: general morphofunctional characteristics.
18. Muscles of the pelvic girdle and free part of the lower limb: general morphofunctional characteristics.

CONTENTS

Introduction.....	3
Laboratory class № 1	4
Laboratory class № 2	9
Laboratory class № 3	16
Laboratory class № 4	21
Laboratory class № 5	28
Laboratory class № 6	32
Final quiz «Bones, joints».....	38
Laboratory class № 7	39
Laboratory class № 8	44
Laboratory class № 9	47
Final quiz «Muscles of head, neck, trunk, limbs»	51

ISBN 978-985-21-1630-5



9 789852 116305