



МИНИСТЕРСТВО ЗДРАВООХРАНЕНИЯ РЕСПУБЛИКИ БЕЛАРУСЬ
БЕЛОРУССКИЙ ГОСУДАРСТВЕННЫЙ МЕДИЦИНСКИЙ УНИВЕРСИТЕТ
КАФЕДРА ГИСТОЛОГИИ, ЦИТОЛОГИИ И ЭМБРИОЛОГИИ

ГИСТОЛОГИЯ, ЦИТОЛОГИЯ, ЭМБРИОЛОГИЯ. ПРАКТИКУМ

HISTOLOGY, CYTOLOGY, EMBRYOLOGY. PRACTICUM

Допущено Министерством образования Республики Беларусь в качестве учебного пособия
для иностранных студентов учреждений высшего образования по специальности «Лечебное дело»

4-е издание



Минск БГМУ 2026

УДК [611.018+611/018.1+611.013](076.5)(075.8)-054.6

ББК 28.06+28.05я73

Г51

А в т о р ы: Т. М. Студеникина, Т. А. Вылегжанина, Т. И. Островская, Н. А. Юзефович

Р е ц е н з е н т ы: д-р биол. наук, проф., зав. каф. гистологии, цитологии и эмбриологии Гродненского государственного медицинского университета С. М. Зиматкин; каф. гистологии, цитологии и эмбриологии Витебского государственного ордена Дружбы народов медицинского университета; канд. филол. наук, доц. каф. современных технологий перевода Минского государственного лингвистического университета Т. И. Голикова

Гистология, цитология, эмбриология. Практикум = Histology, G51 cytology, embryology. Practicum : учебное пособие / Т. М. Студеникина, Т. А. Вылегжанина, Т. И. Островская, Н. А. Юзефович. – 4-е изд. – Минск : БГМУ, 2026. – 123 с.

ISBN 978-985-21-2176-7.

Содержит справочные данные, а также задания для самостоятельной (домашней) и лабораторной работы в виде текстовых и графических материалов по курсу гистологии, цитологии, эмбриологии. Первое издание вышло в 2023 году.

Предназначено для самостоятельной работы студентов медицинского факультета иностранных учащихся, обучающихся на английском языке по специальности «Лечебное дело».

УДК [611.018+611/018.1+611.013](076.5)(075.8)-054.6

ББК 28.06+28.05я73

ISBN 978-985-21-2176-7

© УО «Белорусский государственный
медицинский университет», 2026

Histology, Cytology, Embryology. Practicum

Student _____ group _____

The Results of Intermediate Assessment

Spring semester 1st course	Colloquium 1 st		Colloquium 2 nd		Permission to the credit		
	test		test	slides	Lectures	Classes	Practicum
Mark							
Lecturer's signature							
Autumn semester 2nd course	Colloquium 3 rd		Colloquium 4 th		Permission to the exam		
	test	slides	test	slides	Credit	Lectures	Classes
Mark							
Lecturer's signature							

The Instructions of the Histology, Cytology and Embryology Department for the students to follow

1. Students are to handle the department property, microscopes and other equipment with care and caution.
2. Students are to follow a dress-code: all coats should be left in the wardrobe and all students wear medical gowns.
3. Students are to come to the lectures and the practical classes on time.
4. Students are to have practicum and colored pencils for drawing slides at every practical class.
5. To get the permission for intermediate assessment or credit, students are to attend all lectures and practical classes and perform correctly all tasks in the practicum.
6. If students are missing practical classes, they have to take a permission and work off a missed class within two weeks. To work off, students should come to the Department according to the schedule with the permission, practicum and colored pencils and work with the lecturer on duty.
7. If students are missing lectures, they will have to give the lecturer a permission and the notes for the lecture.
8. If students have good marks (4 and higher) as a result of the intermediated assessment (including the practical skills) the credit will be given at the final practical class.
9. If students have bad results for the intermediated assessment they will take a credit test (free) at the final practical class.
10. In case of the credit's failure, another attempt (paid) will be set by the lecturer on the basis of the agreement between the student and the lecturer. The student is to obtain a permission for the credit and the payment **in advance**.
11. The date of the last attempt to pass a credit (paid) will be set by the Head of the Department for all students. The board of lecturers will supervise the credit. The student is to obtain a permission for the credit and the payment **in advance**.
12. To get the permission for an exam, students are to have the credit and to attend all lectures and practical classes in autumn semester, perform correctly all tasks in the practicum.
13. The schedule of the exams is set by the Dean and should be **strictly fulfilled**.

I've read the Instruction of the Department: _____ 20_____ (signature)

**Topic 1. OVERVIEW OF OBJECTS, MICROSCOPIC AND HISTOLOGICAL TECHNIQUE.
OVERVIEW OF THE CELL STRUCTURE**

1. Tasks, objects and methods of modern histology.
2. Histological research methods.
3. Techniques of the histological preparation making.
4. The principles and methods of staining histological preparations. Basophilia and oxyphilia (acidophilia).
5. The definition of a cell. Cell derivatives.
6. Structural organization of cellular synthetic apparatus: ribosomes, polyribosomes, endoplasmic reticulum, Golgi complex.
7. Structural organization of cellular digestion apparatus: endosomes, lysosomes, peroxysomes.
8. Structural elements of cellular energy apparatus: mitochondria.
9. Cellular inclusions: classifications, structure and functions.
10. Nucleus and its components.
11. Cell cycle.

Definition of *Histology* _____

Definition of *Cytology* _____

Definition of *Cell* _____

Task 1.1. BIOLOGICAL MICROSCOPE

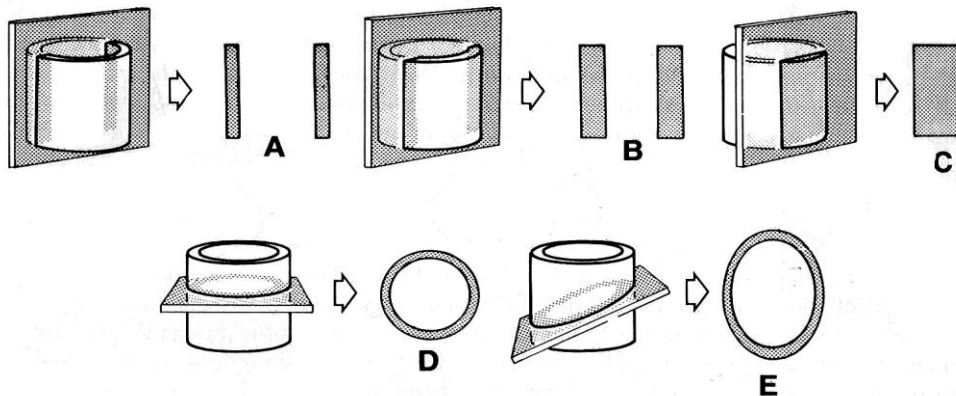
Designate in the picture:

- 1 — stand;
- 2 — on/off switch;
- 3 — regulator of light, power control;
- 4 — macrometer focusing knob;
- 5 — micrometer focusing knob;
- 6 — objective revolver;
- 7 — objectives;
- 8 — object stage;
- 9 — handle of the stage control;
- 10 — slide holder;
- 11 — ocular



Instruction for working with a microscope

1. Check the regulator of a light power control (should be at minimum).
2. Turn on (switch on) the microscopes.
3. Turn slightly the regulator of light power control and make the light brighter.
4. Put the slide on the stage *with the cover glass upwards*. Turn the handle of the stage control and set the specimen in the middle of the hole over the condenser. First use only objective $\times 4$ (low magnification).
5. To focus on the slide, turn the *macrometer focusing knob alone*. Lower the drawtube very carefully, *so as not to damage the slide*.
6. Turn the revolver at the middle or high magnification (objective $\times 10$ and $\times 40$). If necessary, turn the regulator of light power control and make the light brighter. To focus on the slide, turn the *micrometer focusing knob alone, so as not to damage the slide*.
7. After completing the work, turn the revolver at the low magnification. Remove the glass from the object stage.
8. Turn the regulator of the light power control at minimum and **only after this** switch off the microscope.


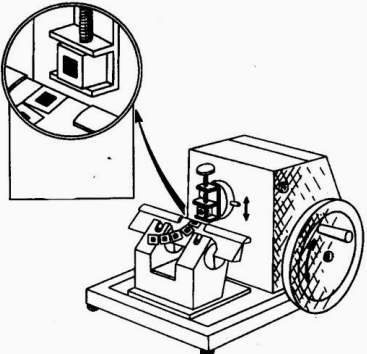


Task 1.2. SERIES OF DIAGRAMS ILLUSTRATING THE APPEARANCE OF SECTIONS OF STRAIGHT TUBE CUT IN VARIOUS PLANES

- A, B, C** — longitudinal sections cut at different levels relative to the center of the lumen.
 Sections **C** — cuts the wall of the tube so we can't see the lumen in the section.
D — transverse or cross section.
E — oblique sections.

PATTERN OF BASIC STAGES OF MAKING HISTOLOGICAL PREPARATIONS

To preserve the structural relationship between cells in tissues, it is necessary to cut a very thin slice of the tissue, called the section, that is suitable for the light or the electron microscopy

Process	Purpose	Process	Purpose
1. Taking material	For the light microscopy take a sample of $1 \times 1 \times 0,5$ cm, for the electron microscopy — 1×1 mm	4. Embedding in paraffin A tissue block must be put in a suitable medium — paraffin wax or plastic resin 	To obtain thin sections with a microtome, tissues should be infiltrated with embedding substance that impart a rigid consistency to the tissue
2. Fixation <i>A. Chemical:</i> simple fixators; compound fixators; <i>B. Physical:</i> freezing heating drying microwave treatment	The process of the fixation prevents a tissue from denaturing its proteins, preserves the structure and hardens a soft tissue	5. Preparation of histological sections with a microtome 	Sections cut for the light microscopy should be thin enough to transmit sufficient light, thinner than the diameter of most cells ($5-10 \mu\text{m}$ thin — for transmission light microscopy, $0,05-0,1 \mu\text{m}$ — for transmission electron microscopy)
3. Dehydration The fixed and rinsed samples are dehydrated in the series of alcohol solutions of ascending concentration (from 70 % to 100 %). The material is kept in each of them from 12 to 24 hours	The water should be extracted from the samples	6. Staining, impregnating, contrasting histological preparations 7. Place the section between the cover glass adding a drop of Canadian balsam	The methods are chosen according to the objective of the investigation

STAINING

Hematoxylin and eosin are the dyes used for histological sections routinely.

Hematoxylin (H) is a basic stain, *eosin (E)* is an acid stain. Substances stained by H are *basophilic*, by E — are *acidophilic (oxyphilic)*.

The results of a staining test:

– **basophilic** cell structures (nucleus) obtain a **blue** or **violet** color after hematoxylin treatment;

– **acidophilic** structures (cytoplasm) obtain a **pink** or **red** color after eosin treatment.

Designate in the scheme:

- 1 — plasma membrane;
- 2 — rough endoplasmic reticulum (rER);
- 3 — ribosomes;
- 4 — Golgi complex;
- 5 — inclusion;

Task 1.3. CELLULAR STRUCTURE

Staining: Hematoxylin-eosin

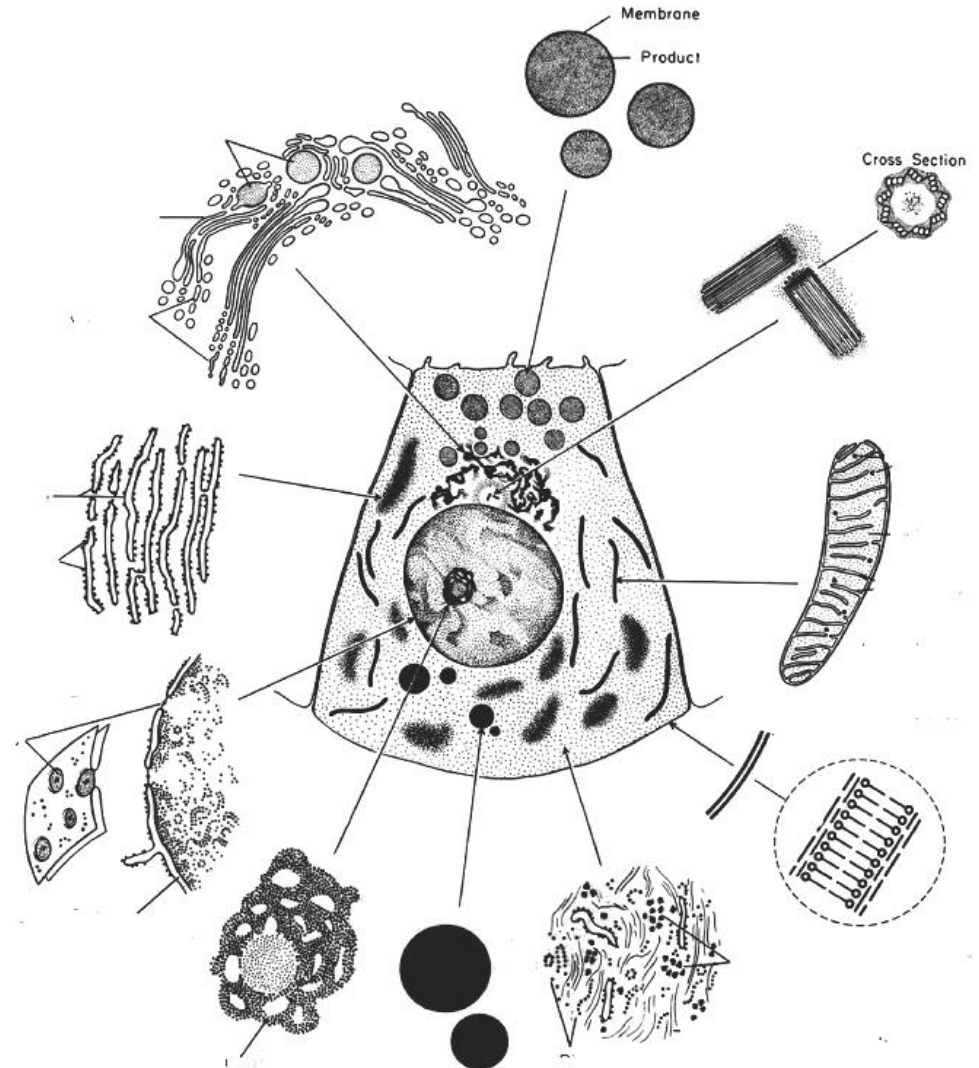
Magnification: 400×

Draw and designate:

- 1 — nucleus (basophilic staining);
- 2 — cytoplasm (acidophilic staining)

- 6 — mitochondria;
- 7 — nucleus;
- 8 — cell center;
- 9 — hyaloplasm;
- 10 — nucleolus;
- 11 — nuclear pores

Task 1.4. SCHEME OF EUKARYOTIC CELL STRUCTURE



Task 1.5. CYTOPLASMIC ORGANELLES

Definition of *Organelles* _____

Organelles classification:

I.

Membranous: _____

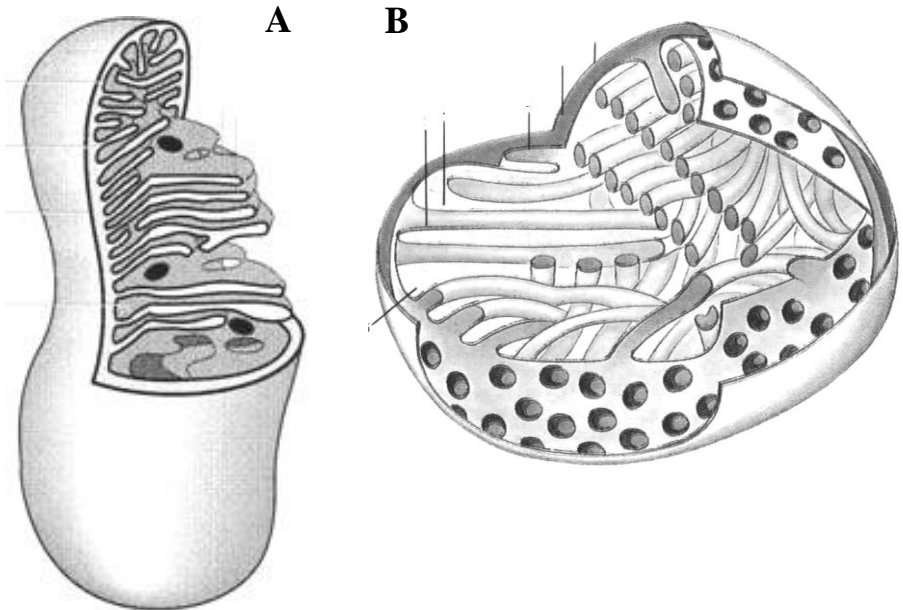
Nonmembranous: _____

II.

General organelles: _____

Special organelles: _____

Task 1.6. SCHEME OF MITOCHONDRIA



Designate: mitochondria with plate (A) and tubular (B) cristae:

- 1 — outer membrane;
- 2 — inner membrane;
- 3 — cristae;
- 4 — matrix;
- 5 — matrix granule

Task 1.7. INCLUSIONS**Definition of *Cellular inclusions*** _____**Classification of inclusions:**

Trophic	proteins	
	polysaccharides	
	lipids	
Secretory		
Excretory		
Pigment	endogenous	melanin lipofuscin hemoglobin
	exogenous	carotene

Correct tasks № _____**Lecturer** _____**Date** « ____ » _____**Task 1.8. LIPID INCLUSIONS IN HEPATIC CELLS**

Staining: Osmic acid

Magnification: 400×

Draw a cell and designate:

1 — cell nucleus; 2 — lipid inclusions

Task 1.9. GLYCOGEN INCLUSIONS IN HEPATIC CELLS

Staining: Karmin on Best

Magnification: 400×

Draw a cell and designate:

1 — cell nucleus;

2 — glycogen inclusions

Topic 2. CYTOLOGY. STRUCTURAL ORGANIZATION OF CELLULAR SURFACE

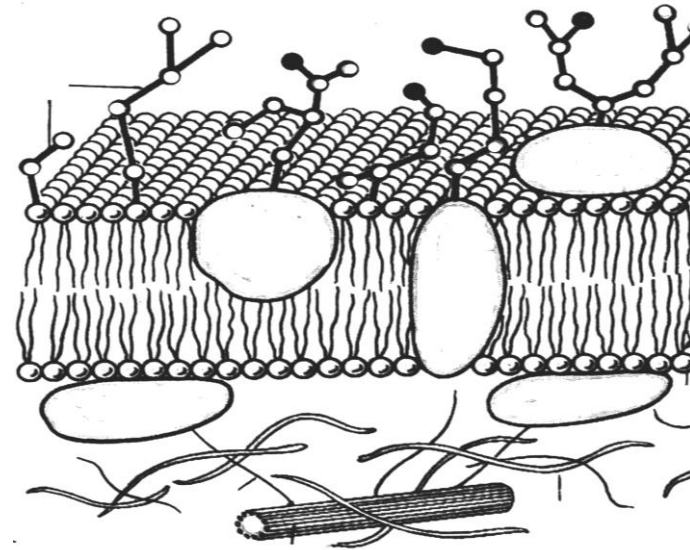
1. Membrane principle of the cell organization. Molecular structure of the plasma membrane.
2. Free cell surface structure: glycocalyx. Submembrane complex of the cells.
3. Cell receptors, their classification, and structural organization.
4. Transport of the substance through the plasmalemma: endocytosis, exocytosis.
5. Cytoskeleton morphology: microfilaments, microtubules, intermediated filaments.
6. The structure of special organelles: microvilli and cilia.
7. Morphology of cell contact surfaces. Classification and structure of intercellular contacts.

Home task: 2.1–2.5.

Functions of plasmalemma:

1. _____
2. _____
3. _____
4. _____
5. _____

Task 2.1. SCHEME OF THE STRUCTURAL AND MOLECULAR ORGANIZATION OF PLASMATIC MEMBRANE (plasmalemma)

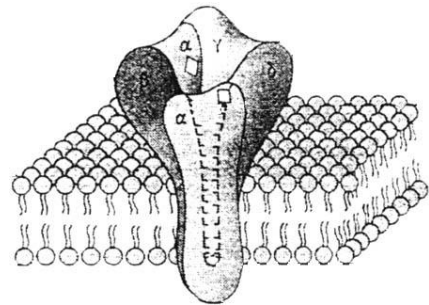
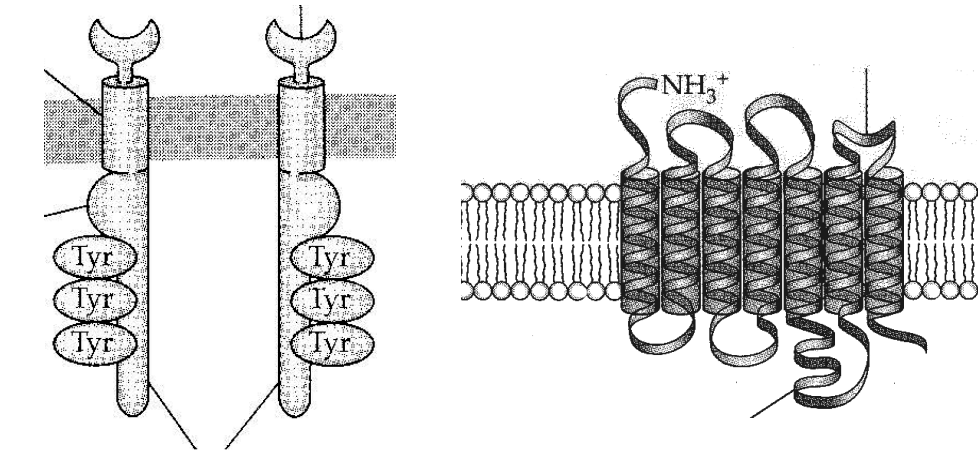


Designate: I — glycocalyx; II — biological membrane;
III — submembrane complex.

- 1 — phospholipid bilayer;
- 2 — membrane proteins: a — integral protein, b — semi-integral protein, c — peripheral protein;
- 3 — glycoproteins;
- 4 — glycolipids;
- 5 — actin microfilaments;
- 6 — microtubules

Task 2.2. PLASMALEMMA RECEPTORS

Definition of *Receptor* _____

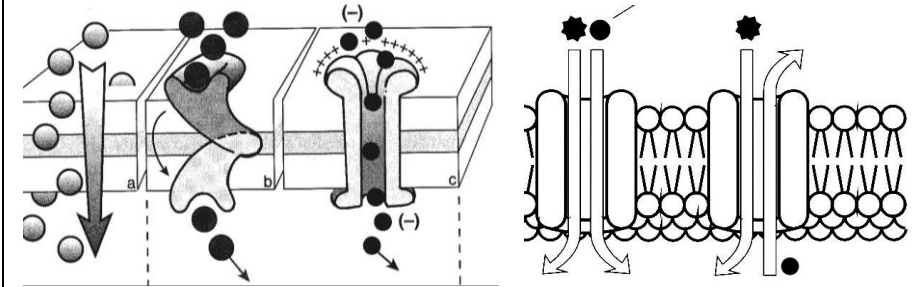


Designate in the picture:

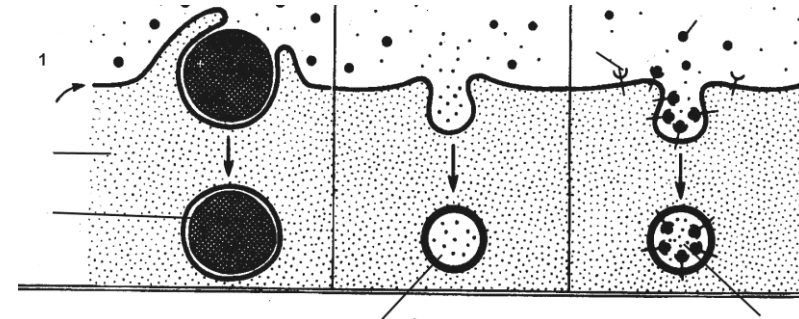
- 1 — 1-segment catalytic tyrosine-kinase receptor;
- 2 — 7-segment receptor associated with G-protein;
- 3 — acetylcholine canal-forming receptor;
- 4 — extracellular domain;
- 5 — intramembrane domain;
- 6 — intracellular domain

Task 2.3. SCHEME OF TRANSPORT

I



II



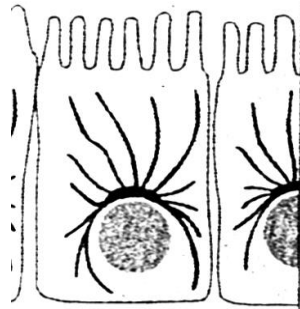
Designate:

- I — transport of molecules through the plasma membrane:
 - a — simple diffusion; b — carrier protein; c — channel protein;
 - d — cotransport (simport); e — antiport.
- II — vesicular transport:
 - 1 — phagocytosis; 2 — pinocytosis;
 - 3 — receptor mediated transport: a — cytoplasm; b — phagosome; c — receptor; d — ligand

Task 2.4. CYTOSKELETON

Learn:

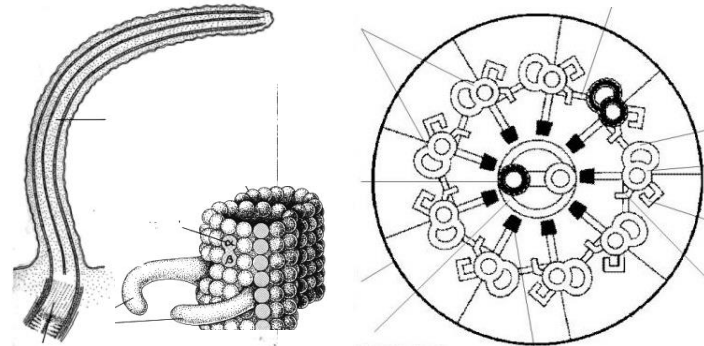
MICROTUBULES



Functions:

- intercellular transport;
- movement of chromosomes during mitosis;
- maintain cell shape;
- beating of cilia and flagella.

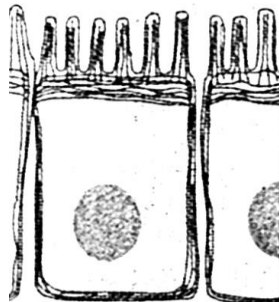
Task 2.5. SCHEME OF CILIA AND MICROVILLI MOLECULAR STRUCTURE



Designate:

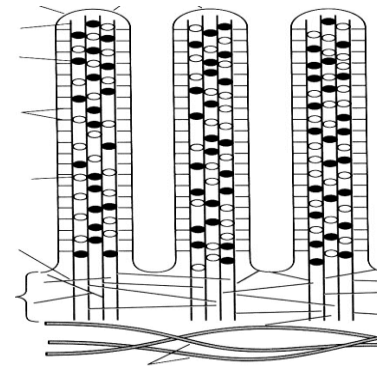
- A** — longitudinal;
- B** — cross sections;
- 1 — microtubule doublets (A and B);
- 2 — central pair of microtubules;
- 3 — dynein arms;
- 4 — basal corpuscle

MICROFILAMENTS



Functions:

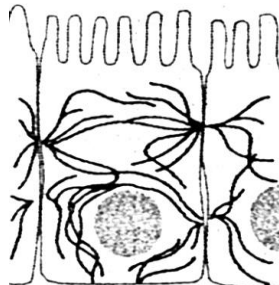
- support the cell shape;
- formation of the structural core of microvilli;
- locomotion of cells.



Designate:

- 1 — plasmalemma;
- 2 — actin filaments;
- 3 — cytoskeleton terminal reticulum;
- 4 — intermediate filaments

INTERMEDIATE FILAMENTS



Functions:

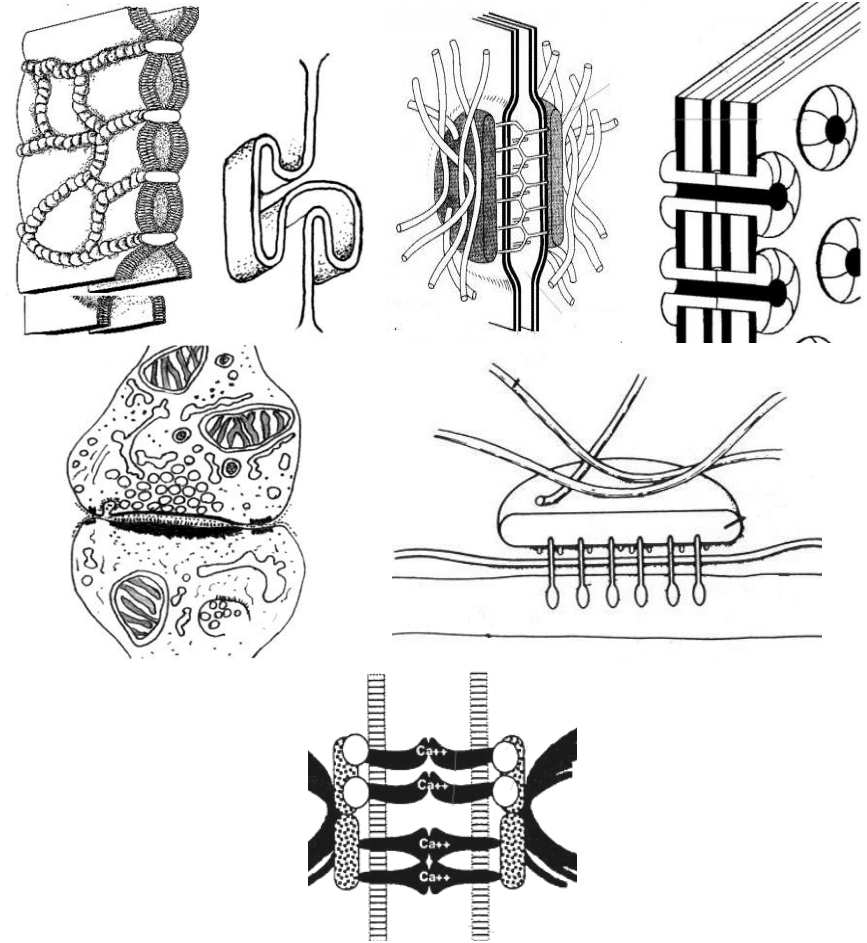
- provide structural support;
- take part in intercellular junction.

INTERMEDIATE FILAMENTS

Protein	Type of tissue
Keratin filaments	epithelial
Vimentin filaments	muscle
Desmin	muscle
Glial fibrillary acidic protein	nerve

Task 2.6. CLASSIFICATION AND STRUCTURE OF CELL JUNCTIONS

Groups of contacts	Types of contacts	Space between two membrane c	Function
Ocluding junctions Cell – to – cell	tight junction or zonula occludens	–	non-permeable for micromolecules and ions
Adhesive junctions Cell – to – cell	junction simplex	15–20 nm	mechanical linkage of cells, permeable for micromolecules and ions
	denticulate junction zonula adherens desmosome or macula adherens	15–20 nm 25–30 nm	
Adhesive junctions Cell – to – extra-cellular matrix	focal adhesive hemidesmosome		anchor the actin cytoskeleton or intermediate filament to the extracellular matrix, transducer signals from outside to the cell
Communicating junctions Cell – to – cell	nexus (gap junction)	2–3 nm	permeable for ions and substances with M. M. < 2000 dalton transmit impulses
	synapses	20–30 nm	



Correct tasks № _____

Lecturer _____

Date « ____ » _____

Designate in the scheme:

1 — zonula occludens; 2 — junction denticulate; 3 — macula adherens; 4 — zonula adherens; 5 — nexus; 6 — synapses; 7 — hemidesmosome

**Topic 3. EMBRYOLOGY. PROGENESIS. STAGES OF HUMAN EMBRYONIC DEVELOPMENT.
FERTILIZATION, CLEAVAGE**

1. Ontogenesis. Its periods.
2. Progenesis. Germ cells (gametes). Morphological and functional characteristics. Role in transmitting the genetic information. Differences from somatic cells.
3. The stages of embryonic development.
4. Fertilization. Definition, biological significance. Duration. Phases.
5. Cleavage. Definition, biological significance. Duration. Type of cleavage.
6. Human blastula. Its structure.

Home task: 3.1, 3.3, 3.5–3.8.

Task 3.1. Fill in the table.

Definition of *Embryology*:

Definition of *Ontogenesis*:

The main periods of ontogenesis:

1. _____
2. _____
 - a) _____
 - b) _____
 - c) _____
 - d) _____
3. _____

Definition of *Fertilization*:

Definition of *Cleavage*:

Definition of *Gastrulation*:

Definition of *Organo- and histogenesis*:

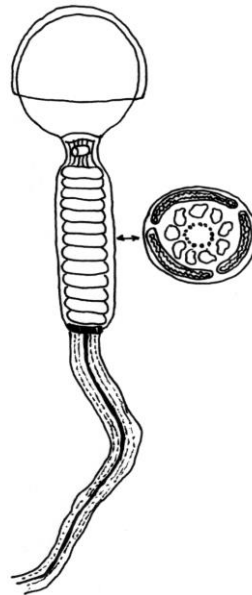
Task 3.2. SPERM'S STRUCTURE

Preparation: Spermatozoa of a guinea pig
Staining: Iron hematoxylin
Magnification: 400×

Draw and designate:

- A** — head:
1 — acrosome;
2 — nucleus;
B — tail:
3 — neck;
4 — middle part;
5 — principal part;
6 — end piece

Task 3.3. SCHEME OF HUMAN SPERMATOZOON STRUCTURE (under the electron microscope)



Designate:

- 1 — cytoplasmic membrane;
2 — acrosome;
3 — nucleus;
4 — neck;
5 — mitochondria;
6 — centriole;
7 — circular fibrils;
8 — axonemal complex

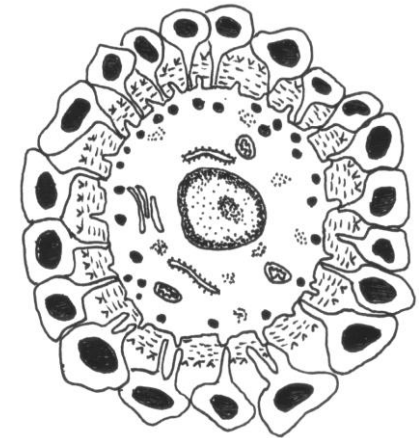Task 3.4. OOCYTE STRUCTURE

Preparation: Mammal ovum
Staining: Hematoxylin-eosin
Magnification: 400×

Draw and designate:

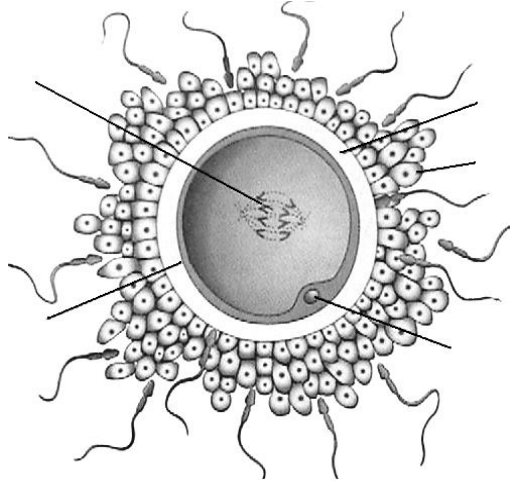
- 1 — nucleus of oocyte;
2 — cytoplasm of oocyte;
3 — oolemma;
4 — zona pellucida;
5 — follicular cells of corona radiata

Task 3.5. SCHEME OF OOCYTE STRUCTURE (under the electron microscope)

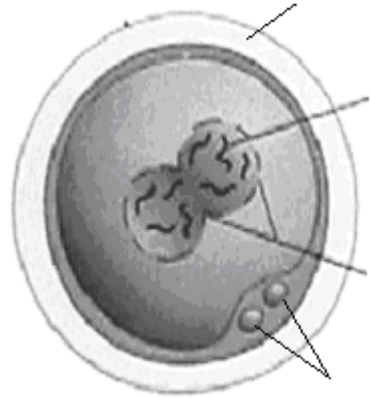


Designate:

- 1 — nucleus;
2 — cytolemma;
3 — cortical granules;
4 — yolk granules;
5 — zona pellucida;
6 — ZP-proteins;
7 — follicular epithelium (corona radiata)



A



B

Task 3.6. FERTILIZATION

Designate:

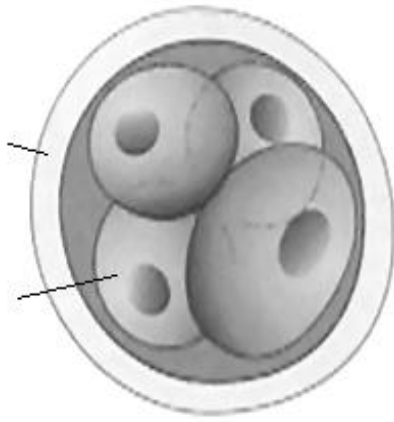
A — contact interaction phase; B — synkaryon phase.

1 — chromosomes; 2 — oolemma; 3 — nuclear membrane;
 4 — polar bodies; 5 — zona pellucida; 6 — follicular cells of corona radiata; 7 — zona reaction

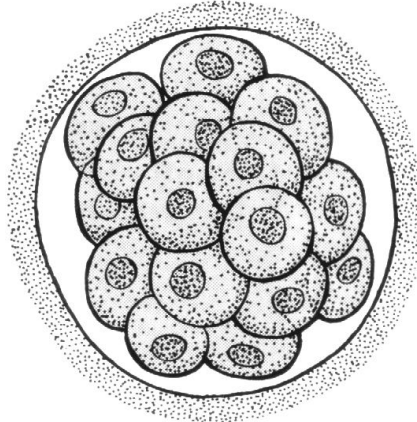
Task 3.7. TYPE OF CLEAVAGE

Based on:

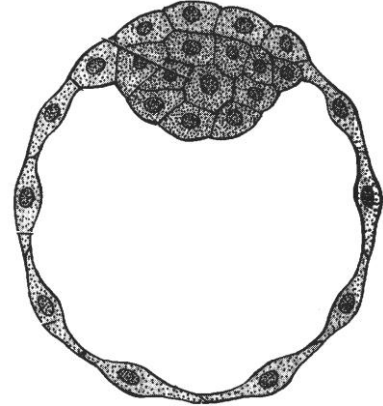
- the coverage of the zygote material _____
- the similarity of the blastomere size _____
- cleavage synchronization _____



A



B



C

Task 3.8. CLEAVAGE

Designate:

A — four-cell stage;

B — morula;

C — blastocyst.

1 — blastomeres;

2 — zona reaction;

3 — embryoblast;

4 — trophoblast;

5 — blastocyst cavity

Correct tasks № _____

Lecturer _____

Date « ____ » _____

Topic 4. EMBRYOLOGY. GASTRULATION. DIFFERENTIATION OF THE EMBRYONIC GERM LAYERS

1. Gastrulation. Definition, duration.
2. Early gastrulation. Embryonic disc.
3. Late gastrulation. Primitive node and primitive streak.
4. Formation of the embryonic layers and axial organs.
Neurulation. Folding of the embryonic disc.
5. Differentiation of the embryonic germ layers.
6. Organo- and histogenesis. Definition, duration.
7. Components and regulation mechanisms of embryogenesis.

Home task: 4.1–4.3, 4.5–4.8.

Task 4.1. STAGES OF HUMAN EMBRYOGENESIS

Learn.

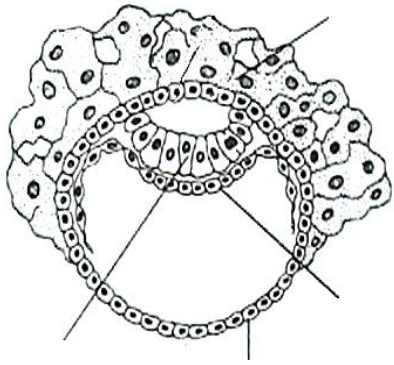
Stage of embryogenesis	Name of organism	Time of embryogenesis	Duration
Fertilization	Conceptus	1 st day	≈ 1 day
Cleavage		2 nd – 5 th day	≈ 4 days
Gastrulation: early		6 th – 13 th day (2 nd week)	≈ 2 weeks
late	14 th – 21 st day (3 rd week)		
Organo- and histogenesis	Embryo	4 th – 8 th week	≈ 35 weeks
		Fetus	

Task 4.2. THE RESULTS OF THE STAGES OF EMBRYOGENESIS

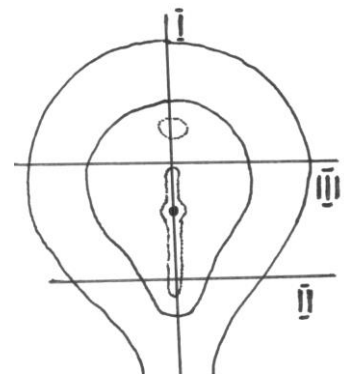
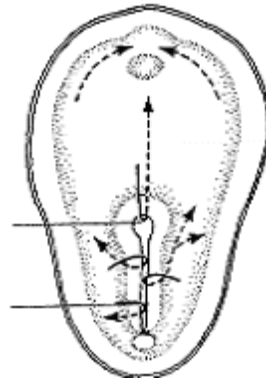
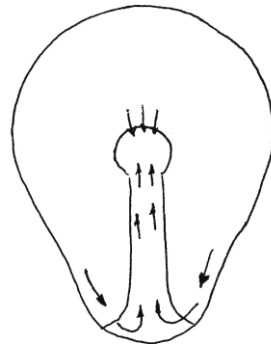
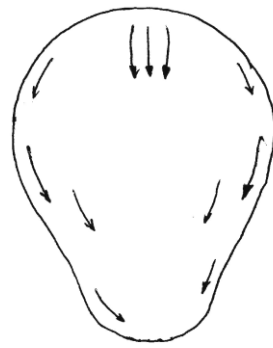
Learn.

Stage of embryogenesis	The result of the appropriate stage is forming of ...	
Fertilization	unicellular organism — zygote	
Cleavage	multicellular organism — blastula	
Gastrulation: early	epiblast, hypoblast — embryonic disc	the result of gastrulation is forming 3 embryonic layers and 3 axial organs
late	1) cells' migration within epiblast results in appearance of primitive node and primitive streak ; 2) cells migrated through the primitive node (pit) under the epiblast form notochord ; 3) cells migrated through the primitive streak under the epiblast form endoderm and mesoderm ; 4) rest of epiblast's cells forms ectoderm ; 5) the notochord induces the development of neural tube and neural crest (parts of ectoderm); 6) the margins of the embryonic disc turn up and form primitive gut (endoderm)	
Organo- and histogenesis	definite organism	

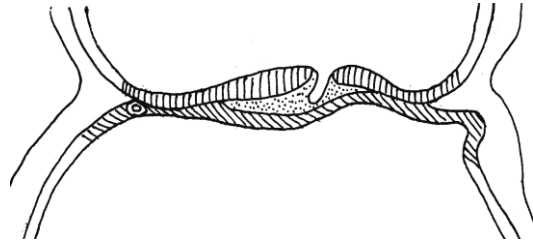
Task 4.3. GASTRULATION



A



B



C

A — delamination (8 days);
 B, C, D — immigration (10–15 days);
 C — section along line I;
 D — section along line II;
 E — (16 days); section along line III
 F — (18 days); section along line III

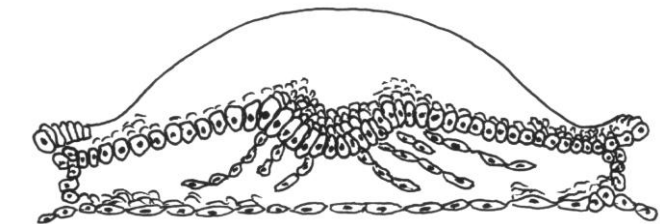
Designate:

in picture A–D:

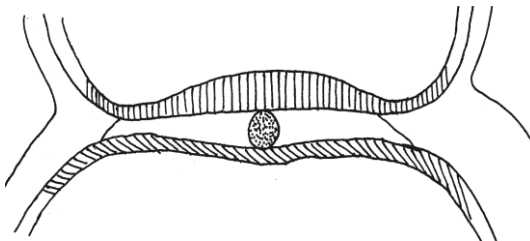
- 1 — epiblast;
- 2 — hypoblast;
- 3 — cytotrophoblast;
- 4 — symplatotrophoblast;
- 5 — primitive node;
- 6 — primitive streak;
- 7 — prechordal plate;
- 8 — notochord;
- 9 — formation of mesoderm;

in picture E–F:

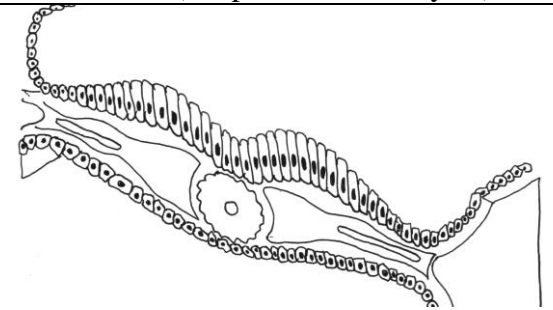
- 8 — notochord;
- 9 — mesoderm;
- 10 — ectoderm;
- 11 — endoderm;
- 12 — neural groove;
- 13 — somites;
- 14 — coelom;
- 15 — parietal mesoderm layer;
- 16 — visceral mesoderm layer (or splanchnotom layers)



D



E



F

Task 4.4. SOMITES, NOTOCHORD, NERVE TUBE OF CHICKEN'S EMBRYO

Staining: Hematoxylin

Magnification: 80×, 400×

Designate:

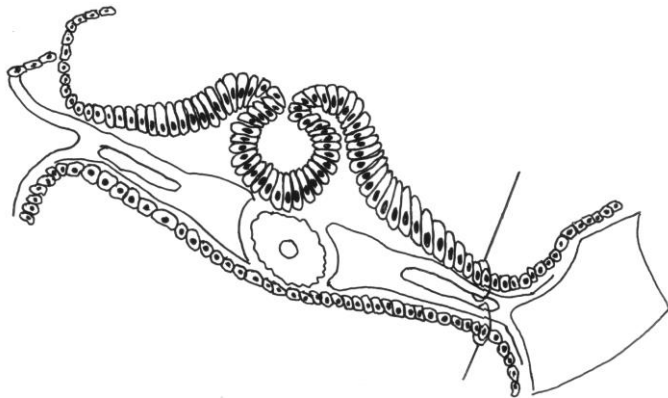
1 — neural tube; 2 — ectoderm; 3 — notochord; 4 — somite; 5 — nephrotome; 6 — splanchnotome (or mesoderm) parietal layer; 7 — splanchnotome (or mesoderm) visceral layer; 8 — coelom; 9 — endoderm

Task 4.5. NEURULATION. FORMATION OF THE PRIMITIVE GUT AND THE EMBRYONIC BODY

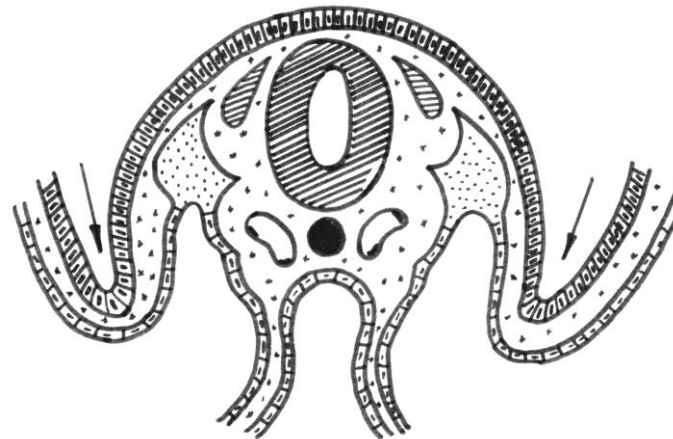
Designate:

1 — neural tube; 2 — neural crest (spinal ganglia); 3 — notochord; 4 — ectoderm; 5 — somite; 6 — nephrogonotome; 7 — parietal splanchnotome layer (7a — somatopleure); 8 — visceral splanchnotome layer (8a — splanchnopleure); 9 — coelom; 10 — endoderm; 11 — forming primitive gut; 12 — primary vessels

A



B



A — closure of neural tube
(21st day);

B — formation of embryonic
body and primary gut
(22^d–23^d days)

Colour:

Ectoderm — in green;

Endoderm — in red;

Mesoderm and its derivatives —
in blue;

Notochord — in brown;

Neural tube and ganglia —
in yellow

Task 4.6. COMPONENTS AND REGULATION MECHANISMS OF EMBRYONIC DEVELOPMENT

Proliferation is mitotic division of the cells

Migration is the movement of cells and cells groups

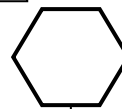
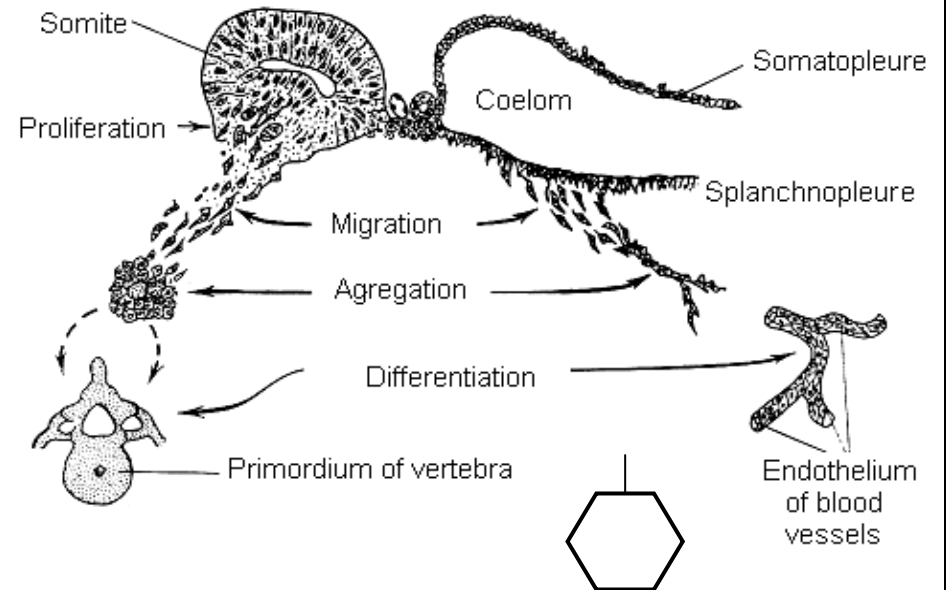
Adhesion is an interaction between adjacent cellular surface or a cellular surface and extracellular matrix

Determination is a choice of the way of the cell development

Differentiation is a formation of the organelles, inclusions and appearance of particular function on the basis of determination

Growth is an increase of the cell's size and cell's mass

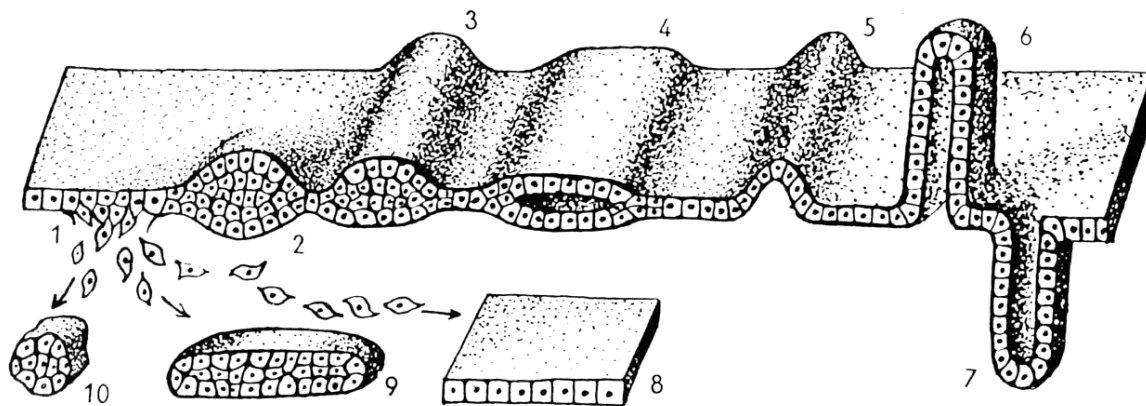
Physiological death of cells



Designate:

A — an example of primordial formation;

B — an example of cellular layer modification during organogenesis:



1 — migration;

2 — local thickening;

3 — cellular strip;

4 — cellular layer fission;

5 — cellular layer curve (fold);

6 — bulging with an inner opening;

7 — bulging under the layer surface;

8 — cellular lamina;

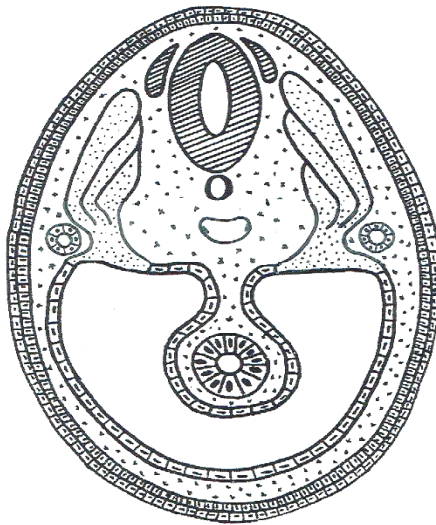
9 — cellular trabecula;

10 — cellular nodule

Task 4.7. CROSS-SECTION OF HUMAN EMBRYO AT THE 8th WEEK OF THE DEVELOPMENT

Designate and colour:

- 1 — neural tube (in yellow);
- 2 — spinal ganglia (in yellow);
- 3 — notochord (in brown);
- 4 — ectoderm (in green);
- 5 — somites: a — dermatome; b — myotome; c — sclerotome (in blue);
- 6 — nephrogonotome (in blue);
- 7 — parietal splanchnotome layer (in blue);
- 8 — visceral splanchnotome layer (in blue);
- 9 — coelom;
- 10 — mesenchyme;
- 11 — endoderm (in red);
- 12 — primary vessels



Task 4.8. DIFFERENTIATION OF EMBRYONIC LAYERS

Write the names of embryonic layers and their derivatives, *learn* the origin of different tissue types.

I.		Nerve tissue Epithelial tissue (stratified epithelium: epidermis and its gland, oral cavity and its glands, anus)
II.		Epithelial tissue (simple columnar in the digestive system)
III.	III A	Epithelial (simple squamous = mesothelium, secretory epithelium of the adrenal gland's cortex) Cardiac muscle tissue
	III B	Epithelial tissue of the kidney and gonads (simple cuboidal)
	III C	— — — Connective tissue of the skin Skeletal muscular tissue Skeletal connective tissue (bone, cartilage)
	III D	Blood, endothelium Connective tissue Smooth muscular tissue

Correct tasks № _____

Lecturer _____

Date « ____ » _____

Topic 5. OVERVIEW OF TISSUES. EPITHELIAL TISSUE

1. Tissue as one of the levels of a cellular organization. Definition of the term tissue. Classification of tissues, ability of regeneration, interaction of tissues.
2. Morphological, functional and histogenetic properties of the epithelial tissues.
3. Morphofunctional and histogenetic classifications of the epithelia.
4. Covering epithelia: structure of different types of the epithelia.
5. Glandular epithelium: structure and classifications of the exocrine glands. Classification and characteristics of the endocrine glands.
6. Characteristics of the secretory process. Types of secretion.

Home task: 5.1, 5.4, 5.6, 5.8–5.12.

Definition of Tissue: _____

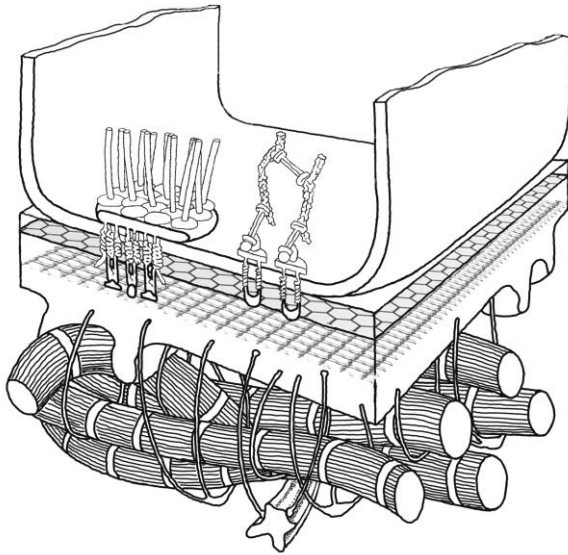
The basic types of tissues:

- 1.
- 2.
- 3.
- 4.

The main property of every type of the tissue:

- 1.
- 2.
- 3.
- 4.

**Task 5.1. SCHEME
OF MOLECULAR ORGANIZATION
OF BASEMENT MEMBRANE**

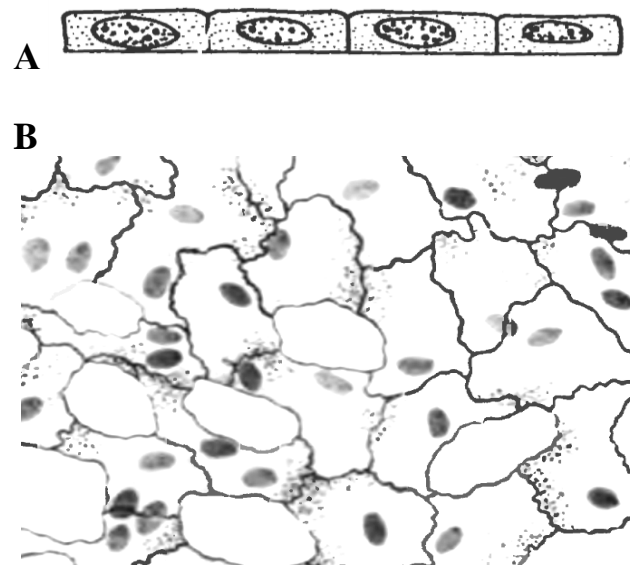


Designate:

- 1 — lamina lucida;
- 2 — lamina densa;
- 3 — reticular lamina;
- 4 — reticular fibrils;
- 5 — anchoring fibril loops;
- 6 — laminin;
- 7 — type IY collagen;
- 8 — hemidesmosome

**Task 5.2. SIMPLE SQUAMOUS
EPITHELIUM (MESOTHELIUM)**

Staining: Impregnation with nitrogenous
acidic silver-hematoxylin
Magnification: 400×



A — cross-section of mesothelium:

- 1 — basement membrane;

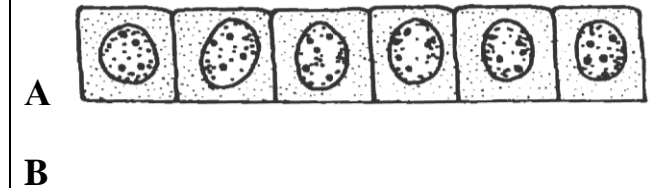
Color and designate:

B — portion of total preparation:

- 2 — cell borders;
- 3 — cytoplasm;
- 4 — nuclei;
- 5 — stomatas

**Task 5.3. SIMPLE CUBOIDAL
EPITHELIUM OF RENAL TUBULES**

Staining: Hematoxylin-eosin
Magnification: 400×



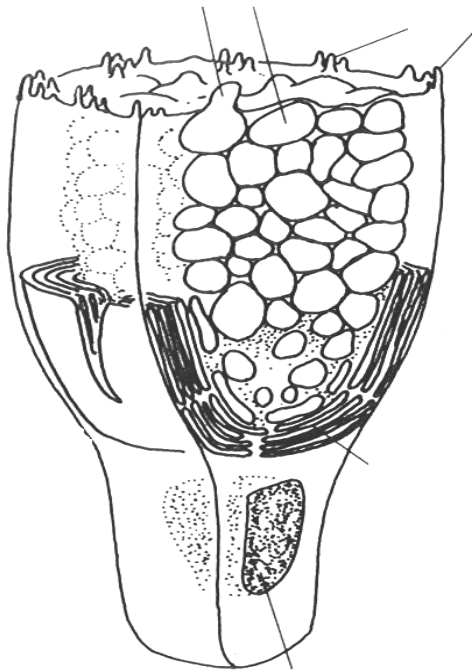
A — simple cuboidal epithelium;

Draw and designate:

B — kidney tubule:

- 1 — cell borders;
- 2 — nuclei;
- 3 — cytoplasm;
- 4 — basement membrane

Task 5.4. STRUCTURE OF GOBLET CELL



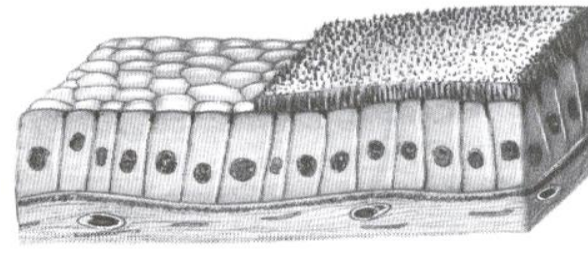
Designate:

- 1 — basal part of the cell;
- 2 — apical part of the cell;
- 3 — nucleus
- 4 — microvilli;
- 5 — secretory vesicles;
- 6 — Golgi complex

Task 5.5. SIMPLE COLUMNAR INTESTINAL EPITHELIUM

Staining: Hematoxylin-eosin
Magnification: 400×

A



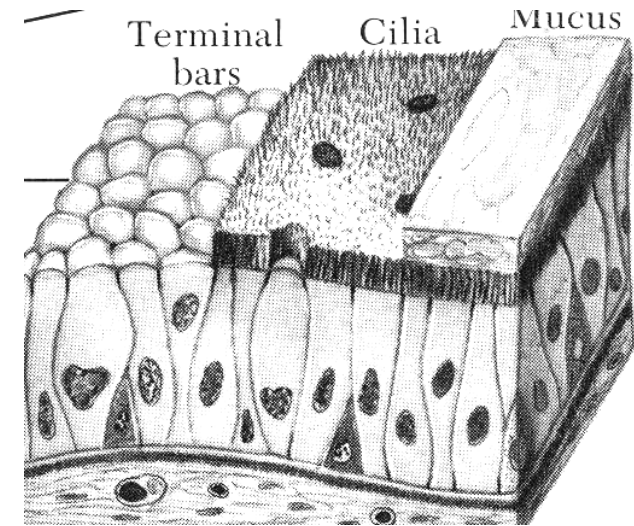
B

Draw intestinal epithelium and designate in scheme (A) and picture (B):

- 1 — microvilli (brush border);
- 2 — columnar cells;
- 3 — basement membrane

Task 5.6. PSEUDOSTRATIFIED CILIATED EPITHELIUM OF TRACHEA

Staining: Hematoxylin-eosin
Magnification: 400×



Designate:

- 1 — ciliated cells;
- 2 — cilia;
- 3 — basal cells;
- 4 — goblet cells;
- 5 — basement membrane

Task 5.7. STRATIFIED SQUAMOUS NONKERATINIZED EPITHELIUM OF EYE CORNEA

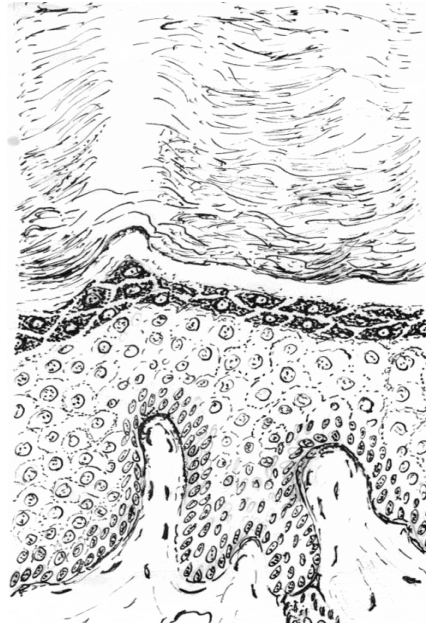
Staining: Hematoxylin-eosin
Magnification: 400×

Designate:

- 1 — basement membrane;
- 2 — basal layer;
- 3 — intermediate layer;
- 4 — flattened surface layer;
- 5 — germinal layer

Task 5.8. STRATIFIED SQUAMOUS KERATINIZED EPITHELIUM OF FINGER'S SKIN

Staining: Hematoxylin-eosin
Magnification: 80×




Designate:

- 1 — basement membrane;
- 2 — stratum basale;
- 3 — stratum spinosum;
- 4 — stratum granulosum;
- 5 — stratum lucidum;
- 6 — stratum corneum;
- 7 — granules in the cells of stratum granulosum

Task 5.9. STRATIFIED TRANSITIONAL EPITHELIUM OF URINARY BLADDER

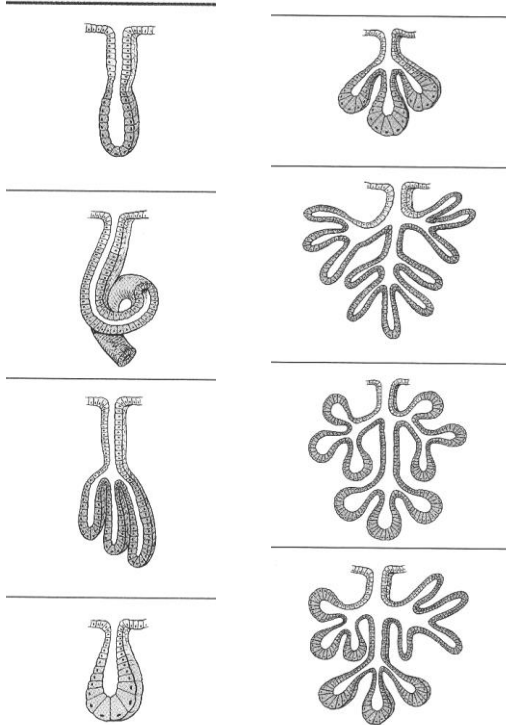
Staining: Hematoxylin-eosin
Magnification: 400×



Designate:

- A — epithelium in the stretched state;
- B — epithelium in the non-distended state:
- 1 — basement membrane;
- 2 — basal cells;
- 3 — intermediate cells;
- 4 — surface cells

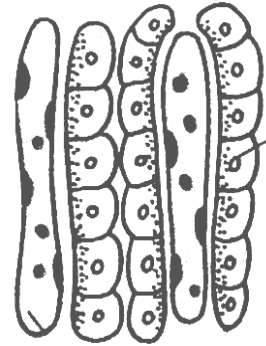
Task 5.10. GIVE FULL NAMES OF THE EXOCRINE GLANDS



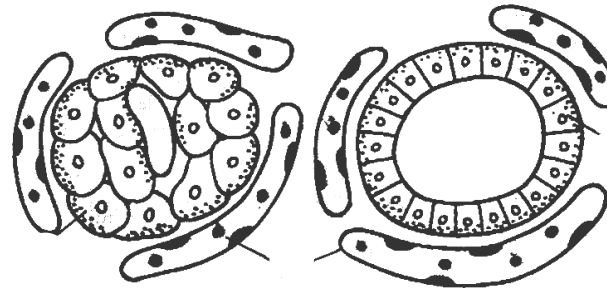
Give a full name:

- 1 —
- 2 —
- 3 —
- 4 —
- 5 —
- 6 —
- 7 —
- 8 —

Task 5.11. IDENTIFY MORPHOLOGICAL TYPES OF THE ENDOCRINE GLANDS



A. _____ type

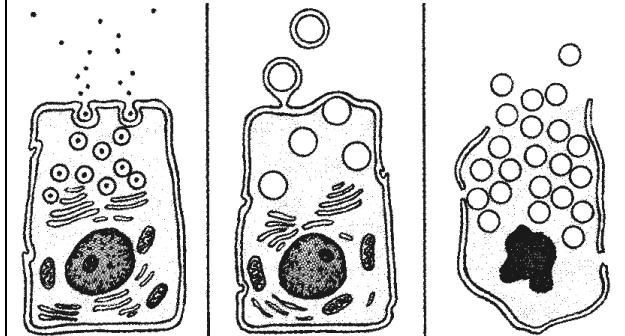


B _____ type

Identify and designate:

- 1 — secretory cells,
- 2 — capillaries

Task 5.12. DESIGNATE THE TYPE OF SECRETION



Designate:

- 1 — Merocrine;
- 2 — Apocrine;
- 3 — Holocrine

Correct tasks № _____

Lecturer _____

Date « ____ » _____

Topic 6. BLOOD AND LYMPH

1. Blood and lymph as types of the inner tissues. Functions of the blood and lymph.
2. General components of the blood as the tissue — plasma and cells.
3. Hemogramme. Sex characteristics of the blood.
4. Erythrocytes: shape, size, structure, function, lifespan.
5. Leucocytes, general characteristics, classification.
6. Leucocytes: granulocytes, shape, size, structure, function, lifespan.
7. Leucocytes: agranulocytes, shape, size, structure, function, lifespan.
8. Leukocyte formula, shift of the blood formular to the left.
9. Thrombocytes: shape, size, structure, function, lifespan.

Functions of the blood:

1. _____
2. _____
3. _____
4. _____
5. _____

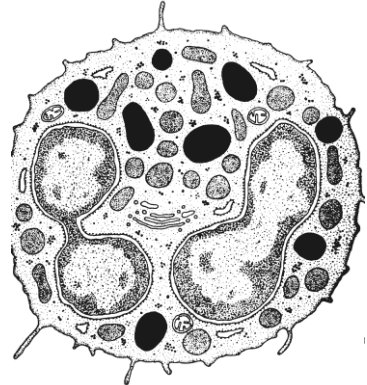

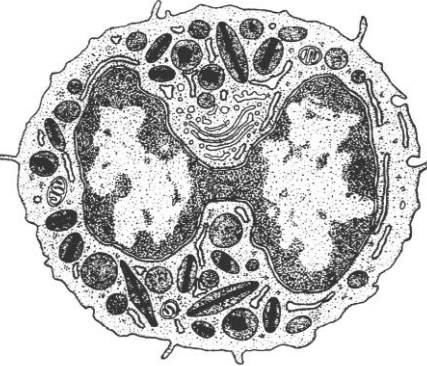

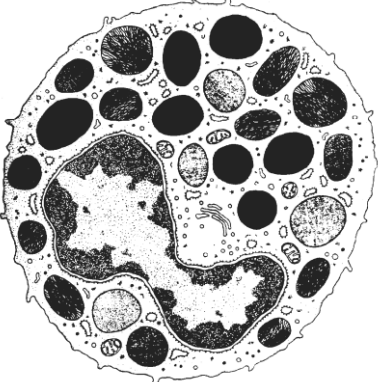

Home task: 6.1, 6.2 (note functions of the blood cells).

Task 6.1

Learn: Hemogramme

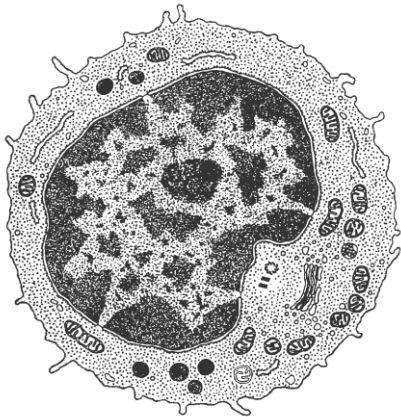
Findings	Value
Hematocrit	0,41–0,47
Hemoglobin	120–140 g/l
Erythrocytes	F — $3,7\text{--}4,9 \times 10^{12} /l$ M — $3,9\text{--}5,2 \times 10^{12} /l$
Reticulocytes	0,7–1,0 %
Leucocytes	$3,8\text{--}9,8 \times 10^9 /l$
Thrombocytes	$200\text{--}400 \times 10^9 /l$
ESR	4–12 mm/h
Leukocyte formula (%)	

Neutrophils	Totally 65–75
Among them:	Y-ng. band-n. Segm-n
	0–1 1–5 60–70
Eosinophils	1–5
Basophils	0–1
Lymphocytes	20–40
Monocytes	6–8


<p>Neutrophil (granulocyte)</p> <p>Size 9–12 μm</p>		<p>Neutrophils in smear: a — young b — band c — segmented</p> 	<p>Function</p> <p><i>The specific granules contain:</i></p> <ol style="list-style-type: none"> 1. 2. 3.
<p>Eosinophil (granulocyte)</p> <p>Size 12–17 μm</p>		<p>Eosinophil in smear</p> 	<p>Function</p> <p><i>Specific granules contain:</i></p> <ol style="list-style-type: none"> 1. 2. 3. 4.
<p>Basophil (granulocyte)</p> <p>Size 9 μm</p>		<p>Basophil in smear</p> 	<p>Function</p> <p><i>Specific granules contain:</i></p> <ol style="list-style-type: none"> 1. 2. 3.

**Lymphocyte
(agranulocyte)**

Size 5–13 μm



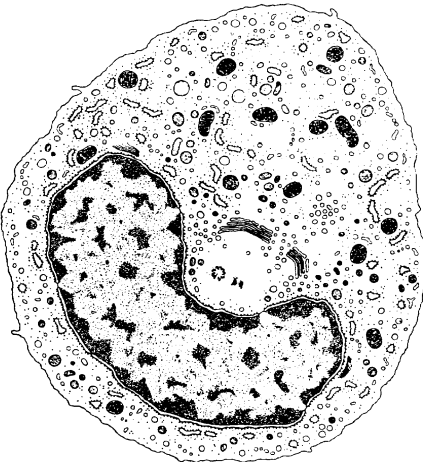
Lymphocyte in smear




Function

**Monocyte
(agranulocyte)**

Size 20 μm



Monocyte in smear



Function

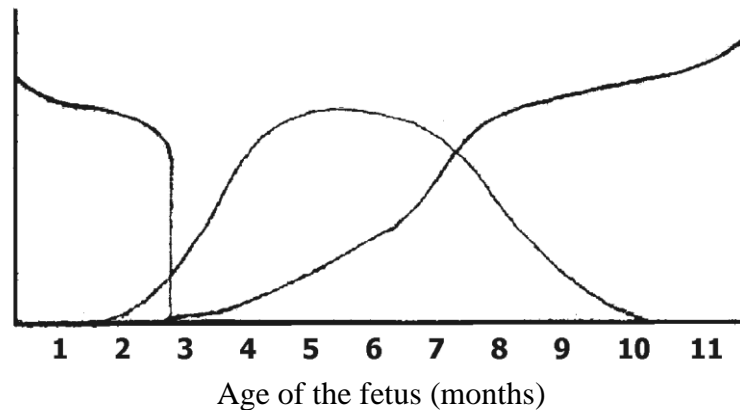
Correct tasks № _____
Lecturer _____
Date « ____ » _____

Topic 7. BLOOD AND LYMPH. HEMOPOIESIS

1. Hemopoiesis. Hemopoietic stem cell.
2. Embryonic hemopoiesis, formation of the blood as a tissue. Stages of embryonic hemopoiesis.
3. Postembryonic hemopoiesis: physiological regeneration of the blood.
4. Myelopoiesis: erythropoiesis, thrombocytopoiesis, granulocytopoiesis, monocytopenoiesis.
5. Lymphopoiesis. Characteristic of T- and B-lymphopoiesis: antigenindependent and antigendependent lymphopoiesis.

Home task: 7.1, 7.3 part B, 7.4 part B.

Task 7.1. STAGES OF HUMAN HEMOPOIESIS



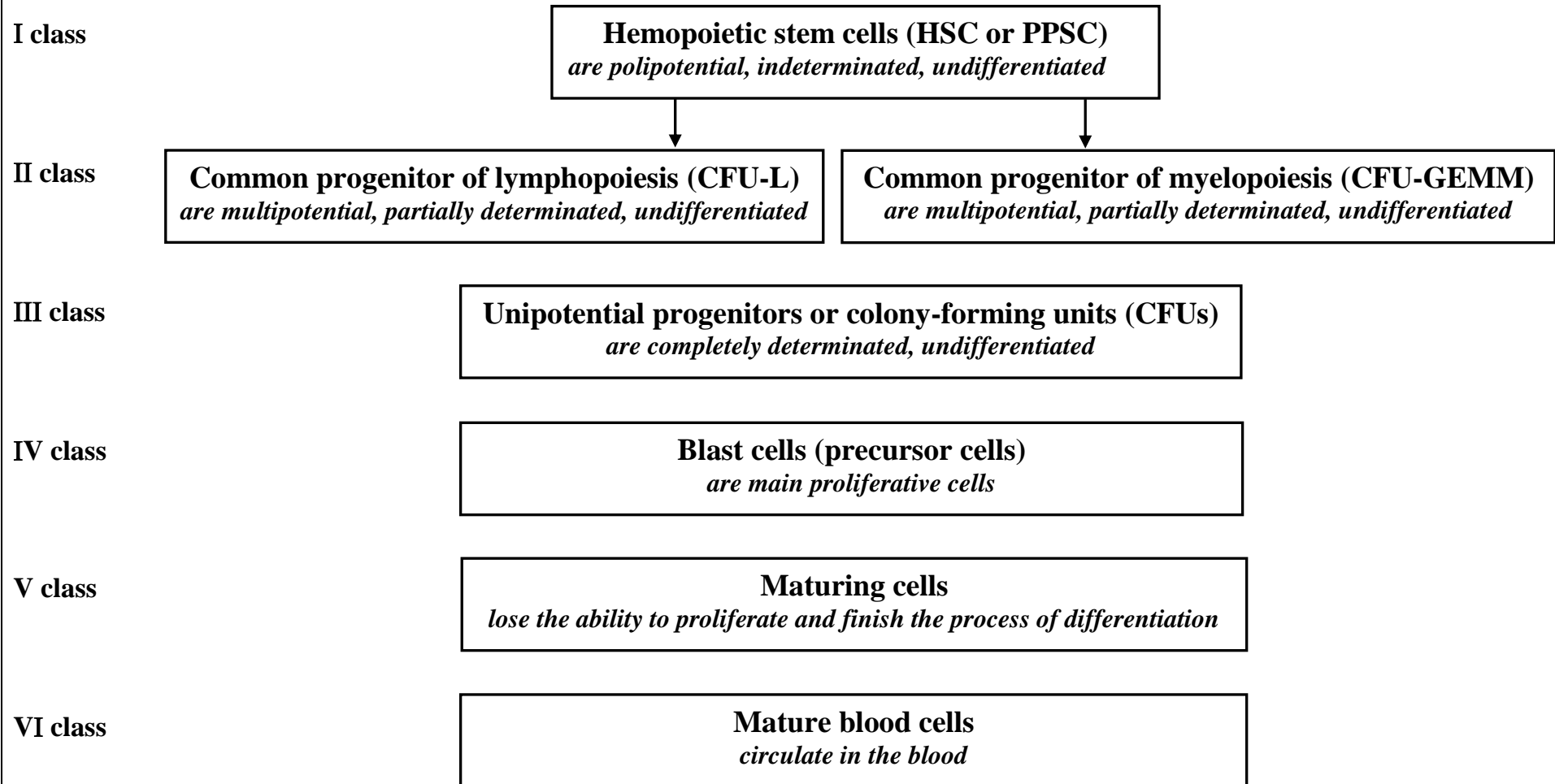
Color different periods of hemopoiesis:

yolk-sac stage – **in yellow**; hepatic stage – **in green**;
bone marrow stage – **in red**.


BASIC CHARACTERISTICS OF EMBRYONIC STAGES OF HEMOPOIESIS

Stage	Organ	Duration	Cells
YOLK SAC	Wall of the yolk sac. Intravascular	from the 2 nd to the 9 th week of gestation	Stem cells, primary erythrocytes — megalocytes, leukocytes
	Liver Extravascular	from the 6 th week to the birth	Stem cells. Predominant erythrocytes, thrombocytes, granulocytes
HEPATIC	Spleen Extravascular	from the 7 th week to the birth	All blood cells before the birth. Only lymphocyte after the birth
	Thymus Extravascular	from the 7 th week of gestation — throughout life	T-lymphocyte
BONE MARROW	Red bone marrow	from the 12 th week of gestation — throughout life	All blood cells except T-lymphocytes


Task 7.2. SCHEME OF HEMOPOIESIS




Task 7.3. SCHEME OF ERYTHROCYTOPOIESIS




proerythroblast



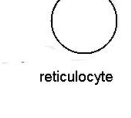
basophilic erythroblast



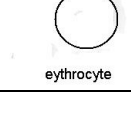
polychromatophilic erythroblast



oxyphilic erythroblast



reticulocyte



erythrocyte

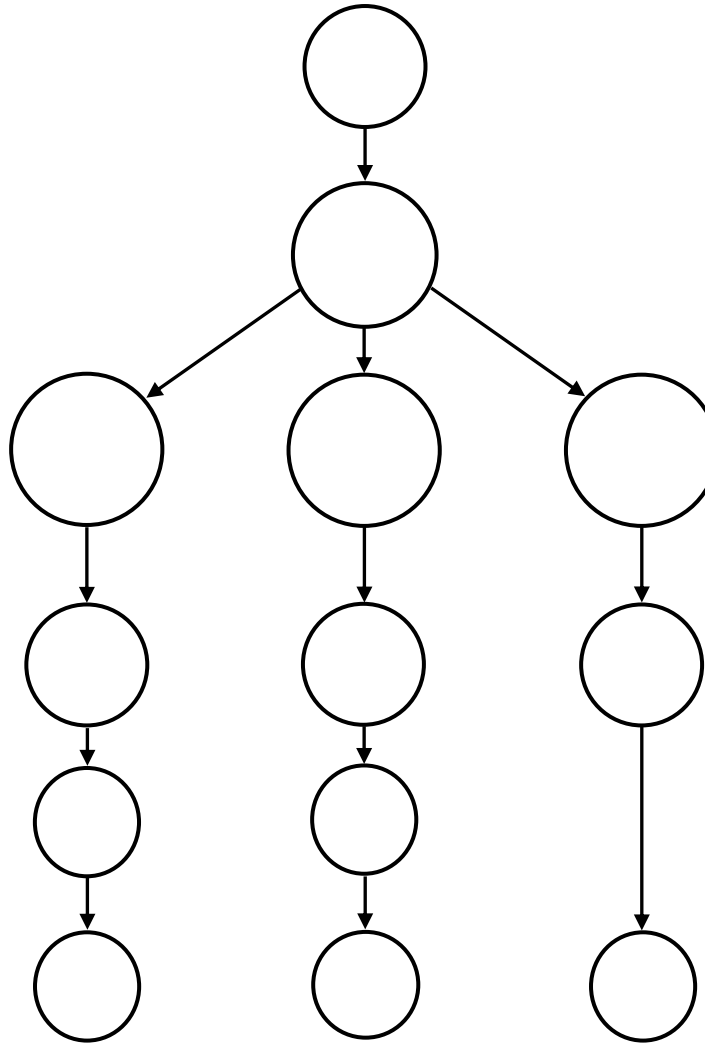
A. Draw cytoplasm in color and designate

- 1 — differentiating cells;
- 2 — maturing cells;
- 3 — mature cell

B. Write the main characteristic of erythrocytopoiesis

- 1.
- 2.
- 3.
- 4.
- 5.
- 6.

Task 7.4. SCHEME OF GRANULOCYTOPOESIS



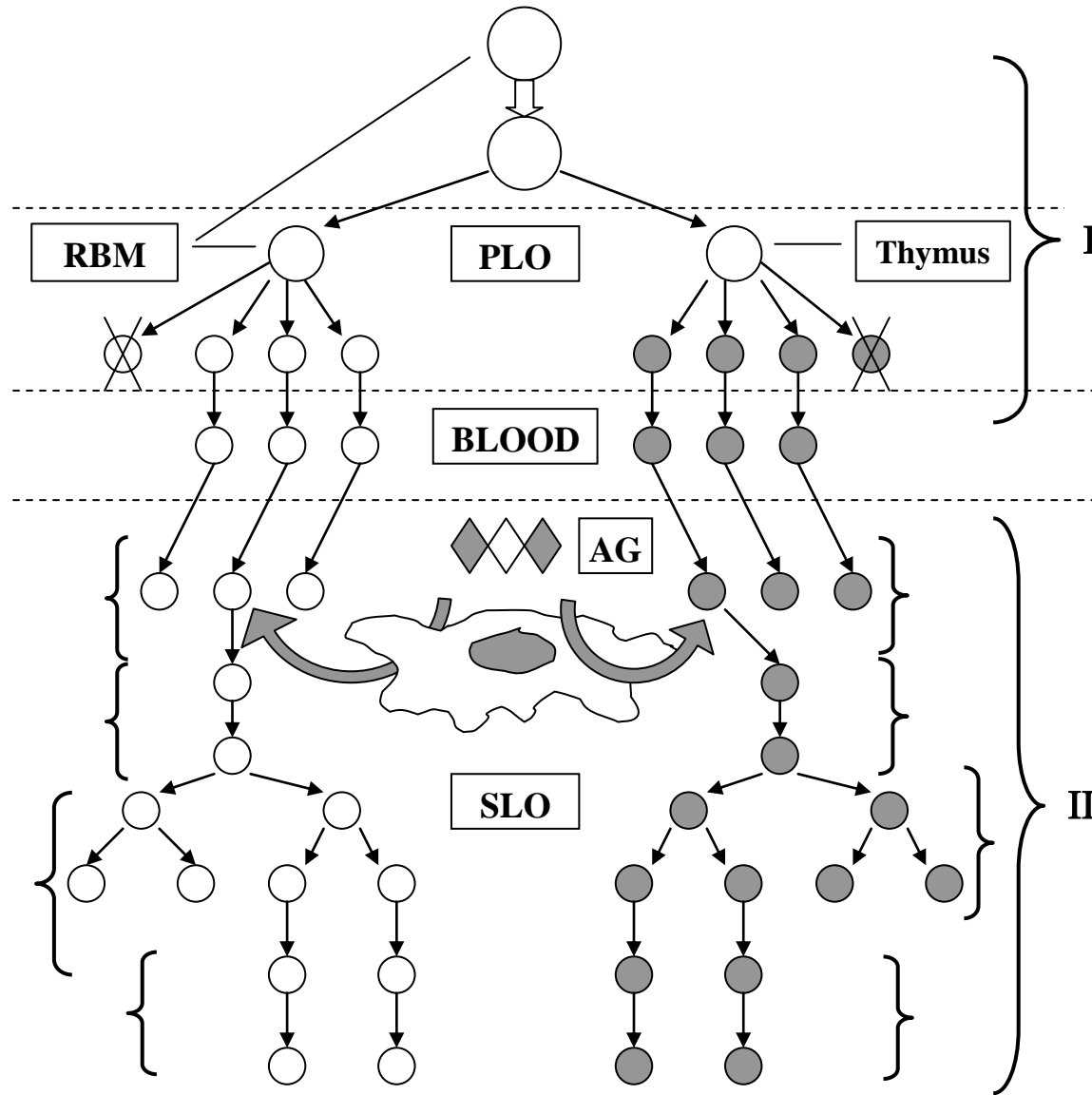
A. Draw the cell and write their name:

- I. Blast cell — myeloblast.
- II. Differentiating cells:
 - 1 — promyelocytes;
 - 2 — myelocytes.
- III. Maturing cells:
 - 3 — metamyelocytes;
 - 4 — band cells.
- IV. Mature cell:
 - 5 — neutrophil;
 - 6 — eosinophil;
 - 7 — basophil.

B. Write the main characteristic of granulocytopoiesis:

- 1.
- 2.
- 3.
- 4.
- 5.

Task 7.5. SCHEME OF LYMPHOPOIESIS



Designate the stages of lymphopoiesis:

I. AG-independent differentiation:

(**PLO** — primary lymphoid organs,
RBM — red bone marrow);

- 1 — hemopoietic stem cell (HSC);
- 2 — hemistem-precursor of lymphocytes (CFU-L);
- 3 — unipotential cell precursor of T- or B-lymphocytes;
- 4 — T- or B- lymphoblast, than T- or B-prelymphocytes;
- 5 — dead lymphocytes (with receptors to auto-Ag);
- 6 — T- or B-lymphocytes.

II. AG-dependent differentiation:

(**SLO** — secondary lymphoid organs,
AG — antigens)

- 7 — activation of lymphocytes;
- 8 — blasttransformation;
- 9 — proliferation;
- 10 — differentiation to the effector T-lymphocytes or plasma cells.

Correct tasks № _____

Lecturer _____

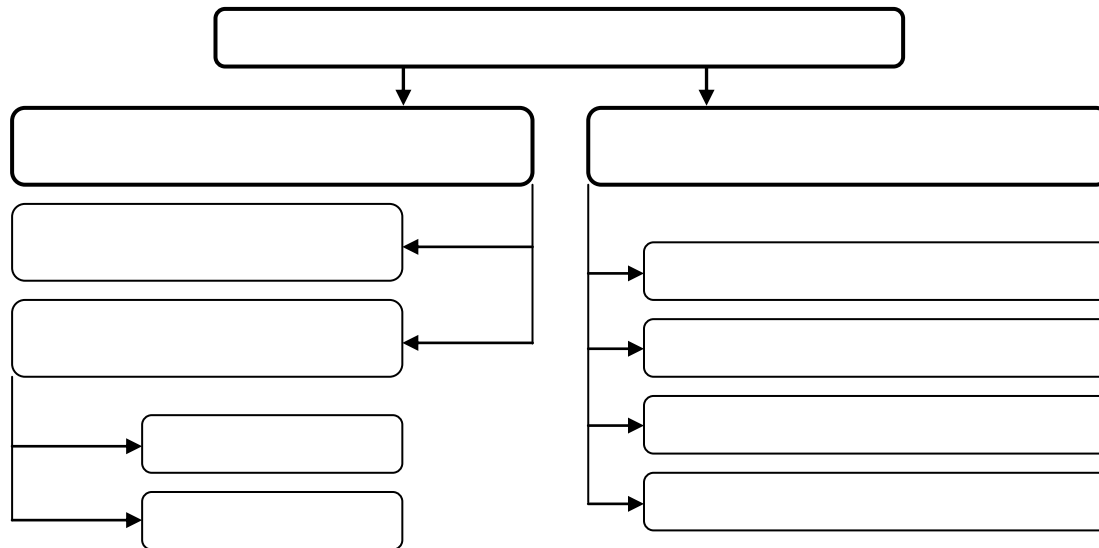
Date « ____ » _____

Topic 8. CONNECTIVE TISSUE. CONNECTIVE TISSUE PROPER

1. Mesenchyme: origin, localization, morphological and functional characteristics; its derivatives.
2. General characteristics and classification of the connective tissues.
3. Development, structure and functions of the loose connective tissue.
4. Cells of the loose connective tissue: origin, morphological and functional characteristics. System of the mononuclear phagocytes.
5. Formation and structure of the extracellular matrix of the loose connective tissue.
6. Specialized connective tissue.
7. Structure and functions of the dense connective tissues.

Home task: 8.1, 8.4–8.6.

Classification of the connective tissues



Task 8.1. ORGANIZATION OF CONNECTIVE TISSUE

Cells

Derivatives of the mesenchyme	Derivatives of the stem blood cell
Derivatives of the nerve crest	

EXTRACELLULAR MATRIX

Fibers:

- 1.
- 2.
- 3.

Ground substance

Synthesized by cells	Come from the blood

Task 8.2. MESENCHYME IN EMBRYON SECTION

Staining: Hematoxylin-eosin
Magnification: 400×

Draw and designate:
1 — mesenchymal cells nuclei;
2 — mesenchymal cells processes;
3 — extracellular matrix

Task 8.3. LOOSE CONNECTIVE TISSUE

Staining: Ferrous hematoxylin
Magnification: 400×

Draw and designate:
1 — collagen fiber;
2 — elastic fiber;
3 — ground substance;
4 — fibroblast;
5 — macrophage;
6 — lymphocyte;
7 — mast cell nucleus;
8 — granules in mast cell cytoplasm;
9 — mast cell degranulation

Task 8.4. STRUCTURAL ORGANIZATION OF COLLAGEN AND ELASTIC FIBERS

Intracellular: Amino acids are taken up by the cell and linked to form

↓

PRO- α -CHAINS

↓

PROCOLLAGEN MOLECULE

↓

Extracellular
Such molecules leave the cell through the secretory vacuoles to form

TROPICOLLAGEN MOLECULES

↓

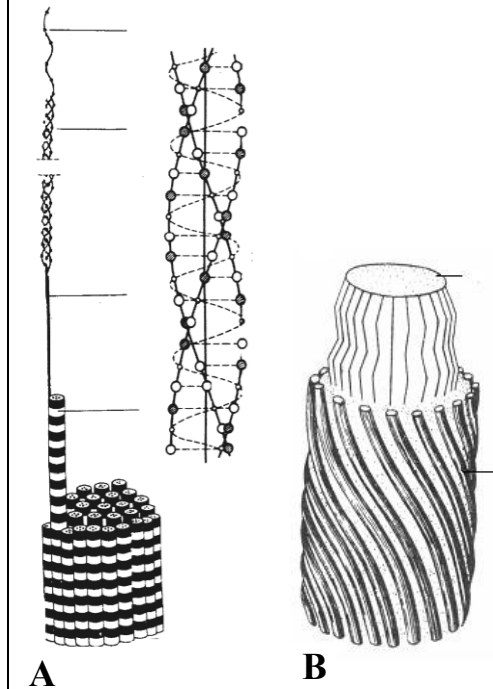
Which aggregate to form

↓

COLLAGEN FIBRILS

↓

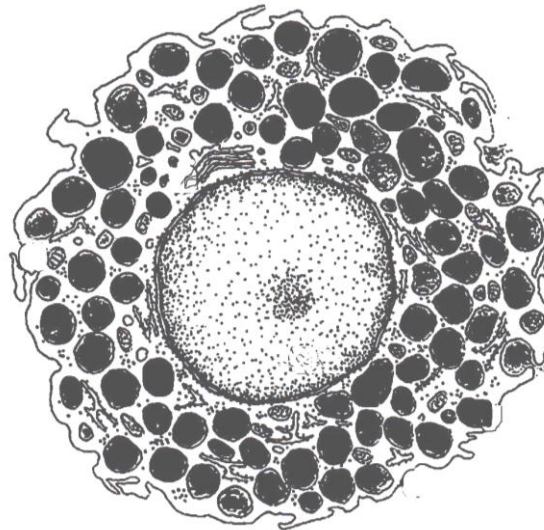
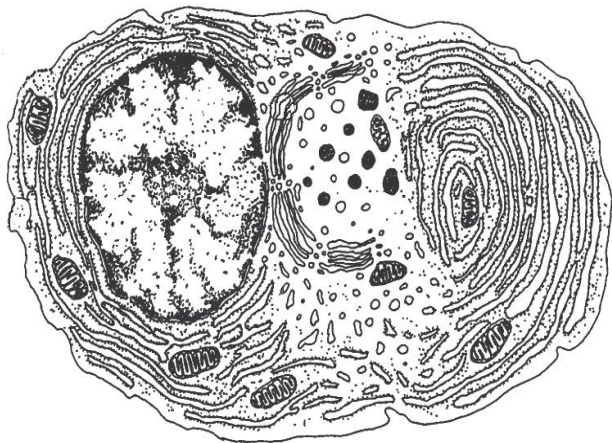
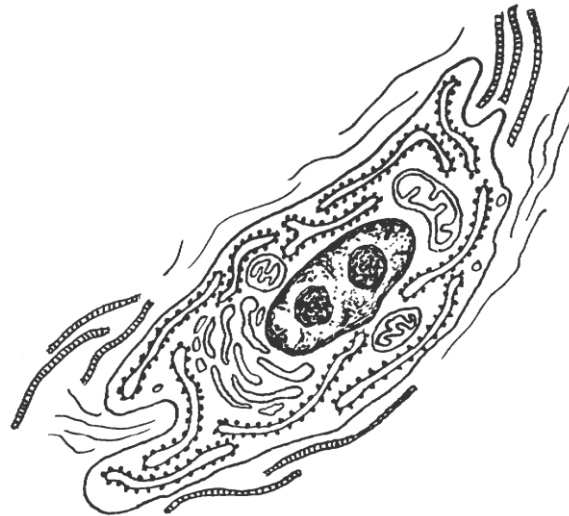
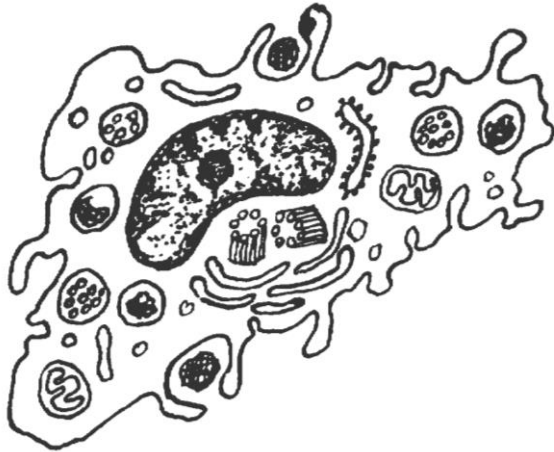COLLAGEN FIBERS



Designate: A
1 — polypeptide chain
2 — procollagen molecules
3 — tropocollagen molecules
4 — collagen fibrils
5 — collagen fibers

B
6 — elastin
7 — microfibrils — fibrillin

Task 8.5. ULTRASTRUCTURE OF LOOSE CONNECTIVE TISSUE CELLS



Designate:

I — fibroblast:

- 1 — rER;
- 2 — complex Golgi;
- 3 — collagen and elastic fiber.

Name:

precursor cell _____
 function _____

II — macrophage (histiocyte):

- 1 — lysosome;
- 2 — phagosome;
- 3 — pinocytotic vesicles.

Name:

precursor cell _____
 function _____

III — plasma cell:

- 1 — numerous rER;
- 2 — Golgi complex.

Name:

precursor cell _____
 function _____

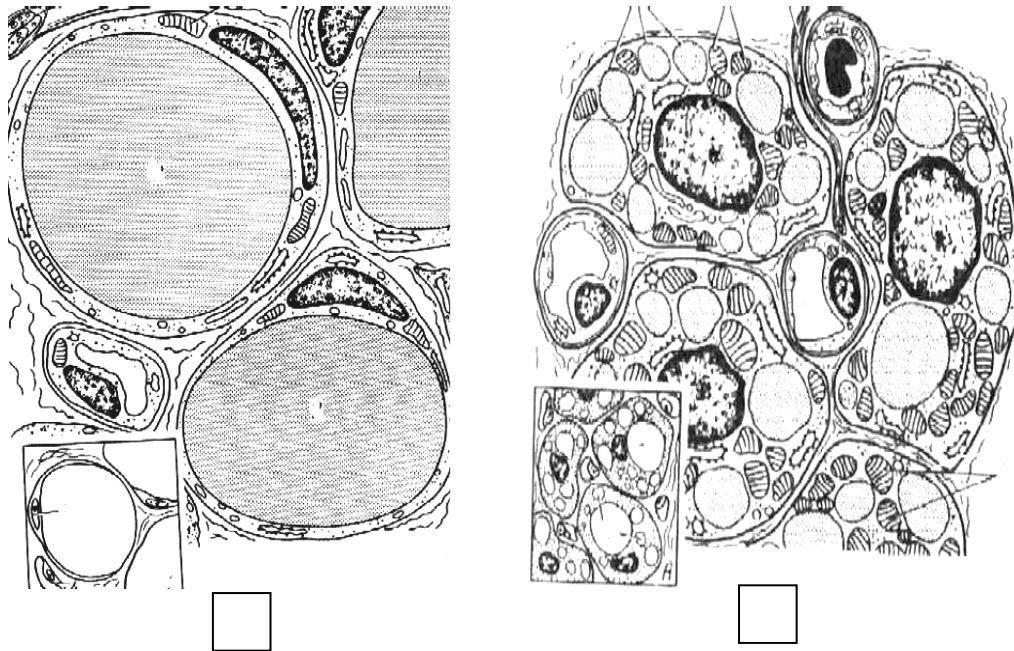
IV — Mast cell:

- 1 — heterogenous granules with heparin and histamine.

Name:

precursor cell _____
 function _____

Task 8.6. ADIPOSE TISSUE



Designate:

A — white adipose tissue; **B** — brown adipose tissue

- 1 — adipocyte;
- 2 — adipocyte nucleus;
- 3 — fat droplets;
- 4 — mitochondria;
- 5 — blood capillaries;
- 6 — nerve fiber


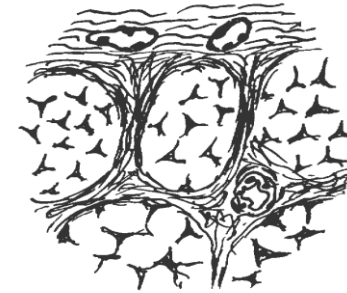
Correct tasks № _____

Lecturer _____

Date « ____ » _____

Task 8.7. DENSE REGULAR CONNECTIVE TISSUE OF THE TENDON

Staining: Magnification
Hematoxylin-eosin: 400×



A — cross-section

B — longitudinal section

Color and designate in the picture and scheme:

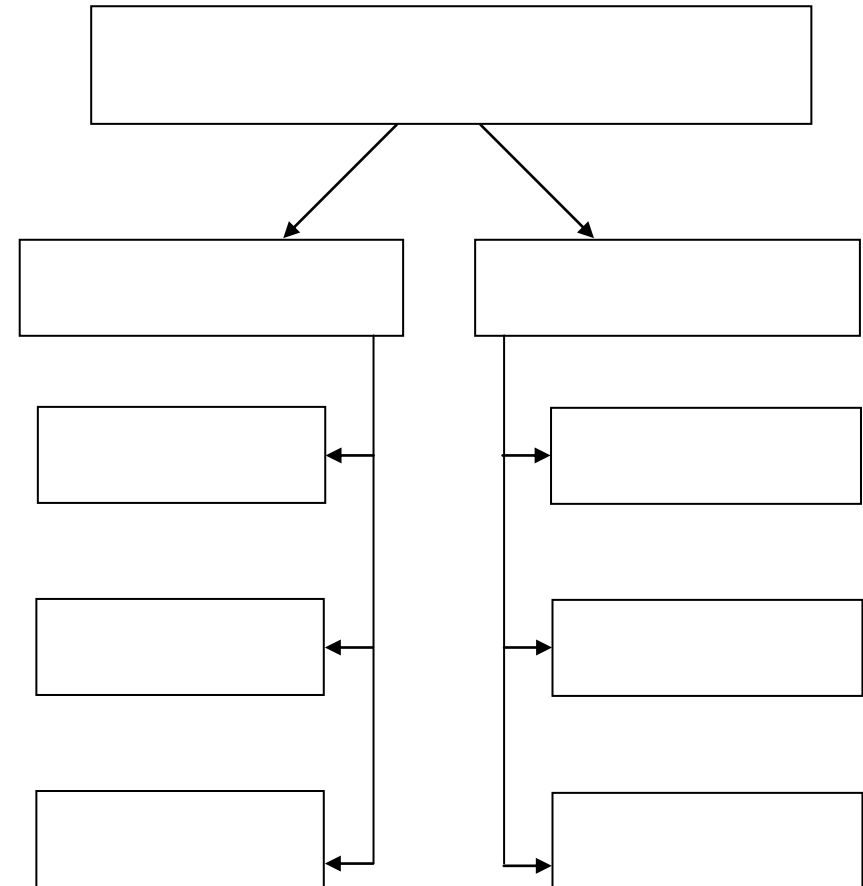
- 1 — bands of the collagen fibers;
- 2 — fascicles of the collagen bands;
- 3 — fibrocytes (tendinocytes);
- 4 — endotendineum;
- 5 — peritendineum;
- 6 — blood vessels

Topic 9. CONNECTIVE TISSUE. SKELETAL TISSUE

1. General morphological and functional characteristics, classification of cartilage tissues.
2. Structural peculiarities of different cartilage tissue types.
3. Development, growth, regeneration and age-related changes of cartilage as an organ.
4. General morphological and functional characteristics and classification of the bone tissues.
5. Structure of woven (immature) bone tissue: cells, extracellular matrix.
6. Structure of the lamellar (mature) bone tissue. Compact and spongy bone substance.
7. Bone as an organ. Periosteum: structure and function.
8. Development of the bone tissue: intramembranous and endochondral ossification.

Home task: 9.1, 9.6, 9.7.

Task 9.1. CLASSIFICATION OF SKELETAL TISSUE



Task 9.2. HYALINE CARTILAGE

Staining: Hematoxylin-eosin

Magnification: 400×

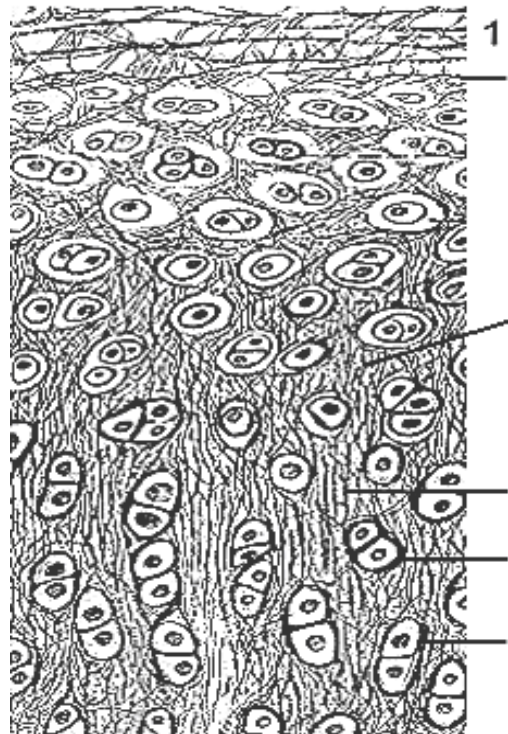
Draw and designate:

- 1 — perichondrium with blood vessels;
- 2 — chondroblasts;
- 3 — chondrocytes;
- 4 — isogenous groups of cells;
- 5 — extracellular matrix ;
- 6 — basophilic area of the extracellular matrix

Task 9.3. ELASTIC CARTILAGE

Staining: Hematoxylin-orsein

Magnification: 400×



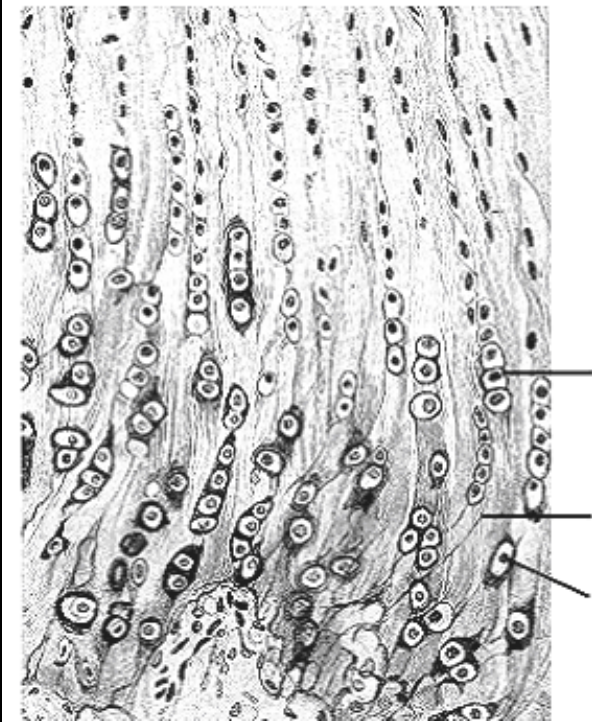
Designate:

- 1 — perichondrium;
- 2 — chondroblasts;
- 3 — chondrocytes;
- 4 — isogenous groups of cells;
- 5 — elastic fibers of the extracellular matrix

Task 9.4. FIBROCARTILAGE

Staining: Hematoxylin-eosin

Magnification: 400×



Designate:

- 1 — chondrocytes;
- 2 — isogenous groups of cells;
- 3 — collagen fibers

**Task 9.5. INTRAMEMBRANOUS
OSSIFICATION (DIRECT OSTEOGENESIS)**

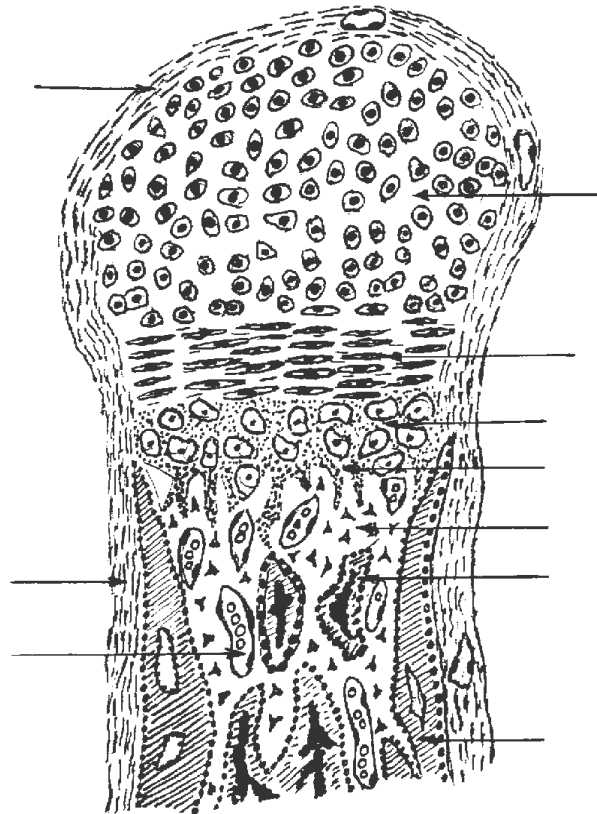
Staining: Hematoxylin-eosin
Magnification: 400×

Draw and designate:

- 1 — mesenchyme;
- 2 — osteoblasts;
- 3 — osteocytes;
- 4 — osteoclasts;
- 5 — extracellular matrix of woven bone tissue;
- 6 — blood vessels

**Task 9.6. ENDOCHONDRAL OSSIFICATION
(INDIRECT OSTEOGENESIS)**

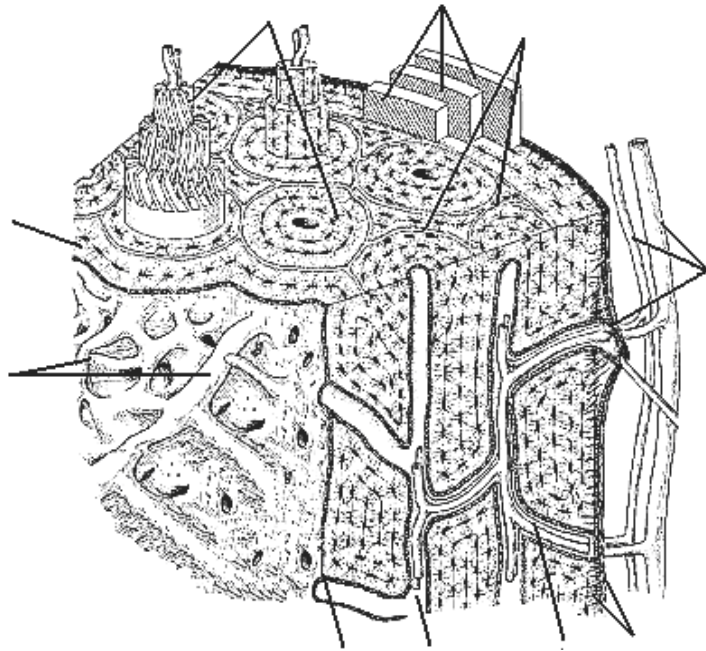
Staining: Hematoxylin-eosin
Magnification: 400×



Designate:

- 1 — perichondrium
- 2 — zone of the resting cartilage;
- 3 — zone of the proliferation;
- 4 — zone of the hypertrophy;
- 5 — zone of the calcification;
- 6 — zone of the resorption and ossification

Task 9.7. STRUCTURAL SCHEME OF THE COMPACT SUBSTANCE OF THE LONG BONE



Designate:

- 1 — periosteum with blood vessels;
- 2 — blood vessels;
- 3 — external circumferential lamellae;
- 4 — osteons;
- 5 — osteon canals;
- 6 — trophic canal;
- 7 — system of the interstitial lamellae;
- 8 — inner circumferential lamellae;
- 9 — endosteum

Task 9.8. CROSS-SECTION OF COMPACT SUBSTANCE OF THE LONG BONE

Staining: Schmorl method
Magnification: 400×

Designate:

- 1 — osteon canal;
- 2 — osteon lamellae;
- 3 — lacuna (osteocyte bodies);
- 4 — canaliculi osseous (osteocyte processes);
- 5 — interstitial lamellae

Correct tasks № _____

Lecturer _____

Date « ____ » _____

Topic 10. MUSCLE TISSUES

1. General characteristics of the muscle tissues (classification, sources of the development, location in the body, basic principles of the structural organization, functions, regeneration, peculiarities of the blood supply and innervation).
2. Comparative characteristics of different types of the muscle tissue structural units: morphofunctional units, peculiarities of its structure, principles of the location in the tissue and types of the intercellular contacts.
3. Skeletal muscle tissue. Muscle fiber as a structural and functional unit. Contraction apparatus of the muscle fiber, supporting and trophic apparatuses. Structure of the sarcomere. Mechanism of the muscle contraction. Possibilities of regeneration.
4. Structure of the skeletal muscle as an organ. Motor unit. Comparative characteristic of different types of the skeletal muscular fibers (red, white and intermediate fibers).
5. Cardiac muscular tissue: source of the development, structural and functional unit. Types of cardiomyocytes (typical — contractile, atypical — conducting and secretory —endocrine). Possibilities of regeneration.
6. Smooth muscle tissues: sources of the development, structural and functional unit. Morphofunctional characteristic of the smooth muscle cells, molecular mechanism of their contraction. Possibilities of regeneration.

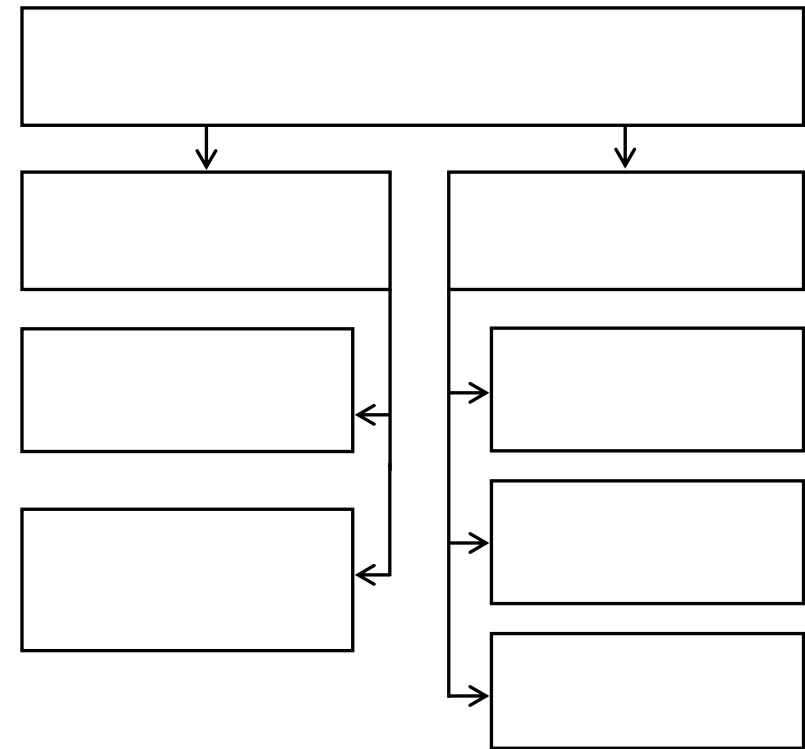
Home task: 10.1, 10.3, 10.5, 10.7, 10.8.

Task 10.1

Muscle tissues provide movement of the whole body, its parts and inner organs.

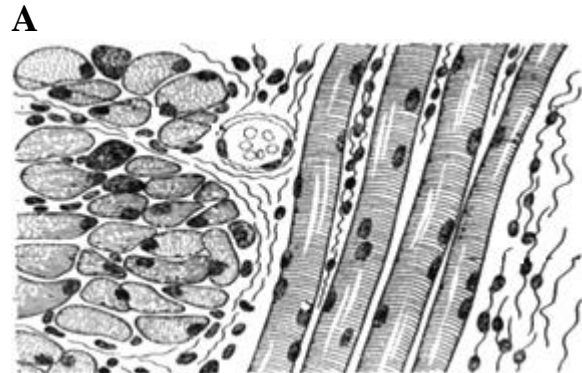
It results from the constriction (shortening) of the muscle cells or fibers as a result of the movement of their special elements — **myofilaments** in the form of actin and myosin.

CLASSIFICATION OF THE MUSCLE TISSUE



**Task 10.2. SKELETAL MUSCLE
TISSUE OF THE TONGUE**

Staining: Iron hematoxylin
Magnification: 400×



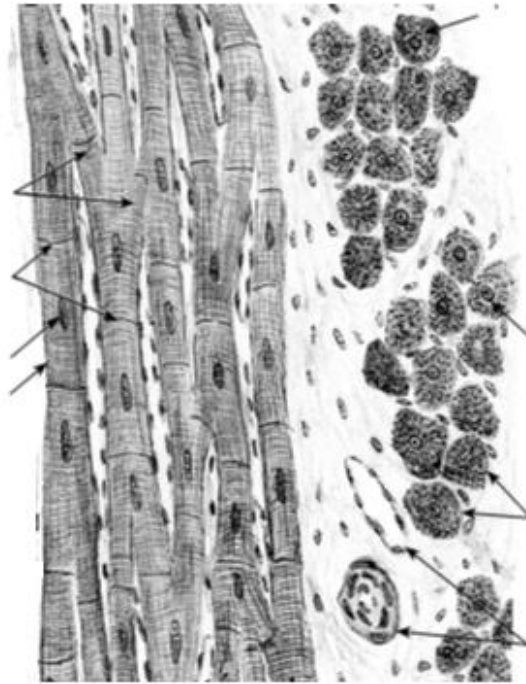
B

Designate scheme (A) and picture (B):

- 1 — longitudinal section of the muscle fibers;
- 2 — transversal section of the muscle fibers;
- 3 — sarcolemma; 4 — myosymplast nuclei;
- 5 — endomysium; 6 — perimysium

**Task 10.3. CARDIAC MUSCLE
TISSUE**

Staining: Iron hematoxylin
Magnification: 400×



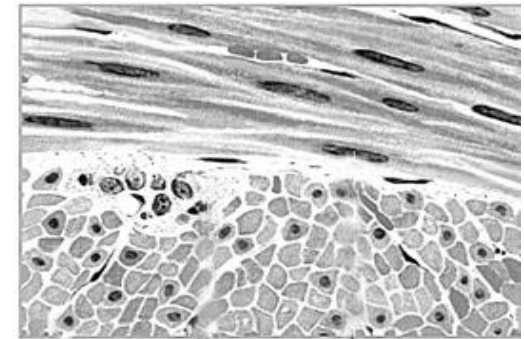
Designate:

- 1 — cardiomyocyte nuclei;
- 2 — intercalated discs
- 3 — anastomosis;
- 4 — myofibrils;
- 5 — blood vessels in the connective tissue;
- 6 — membrane of cardiomyocyte

**Task 10.4. SMOOTH MUSCLE
TISSUE OF URINARY BLADDER**

Staining: Hematoxylin-eosin
Magnification: 400×

A

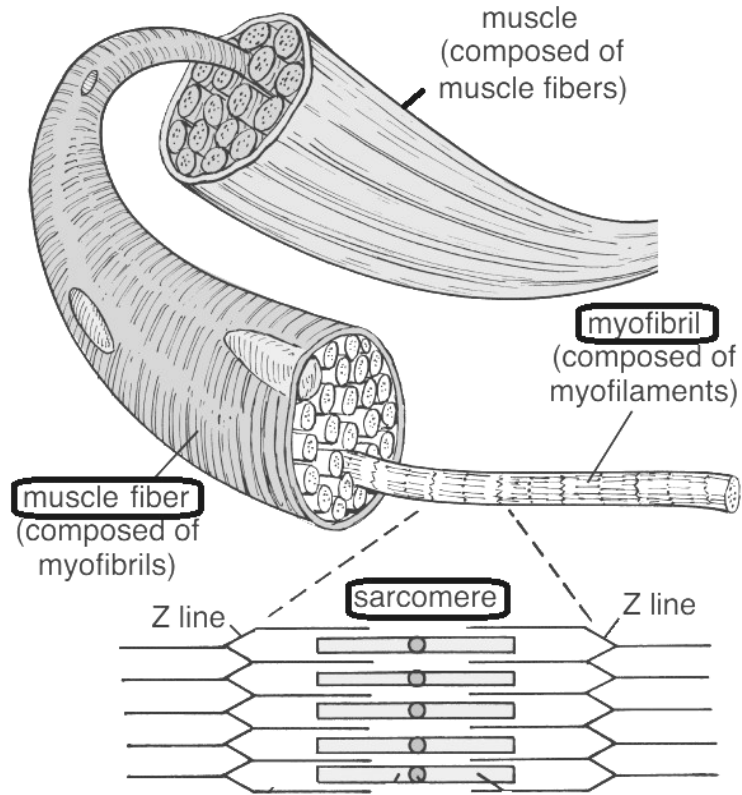


B

Designate scheme (A) and picture (B):

- 1 — muscular cells in longitudinal section;
- 2 — muscular cells in cross section;
- 3 — nuclei of muscular cells;
- 4 — connective tissue (perimysium)

Task 10.5. ULTRASTRUCTURE OF THE SKELETAL MUSCLE FIBER



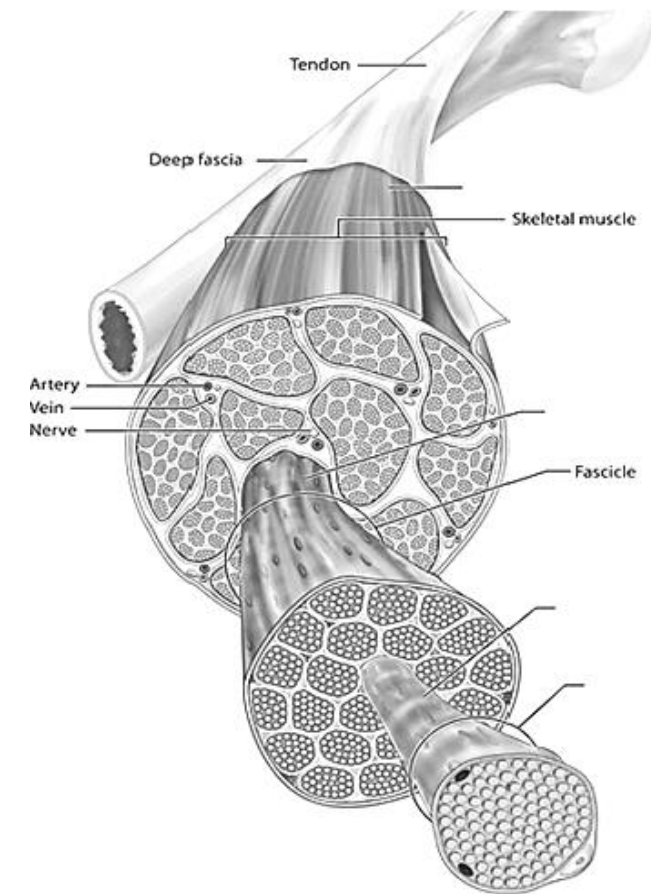
Note:

The structural and functional unit of the skeletal muscle is

The special organelle consisting of the actin and myosin myofilaments is

The structural and functional unit of the myofibril is

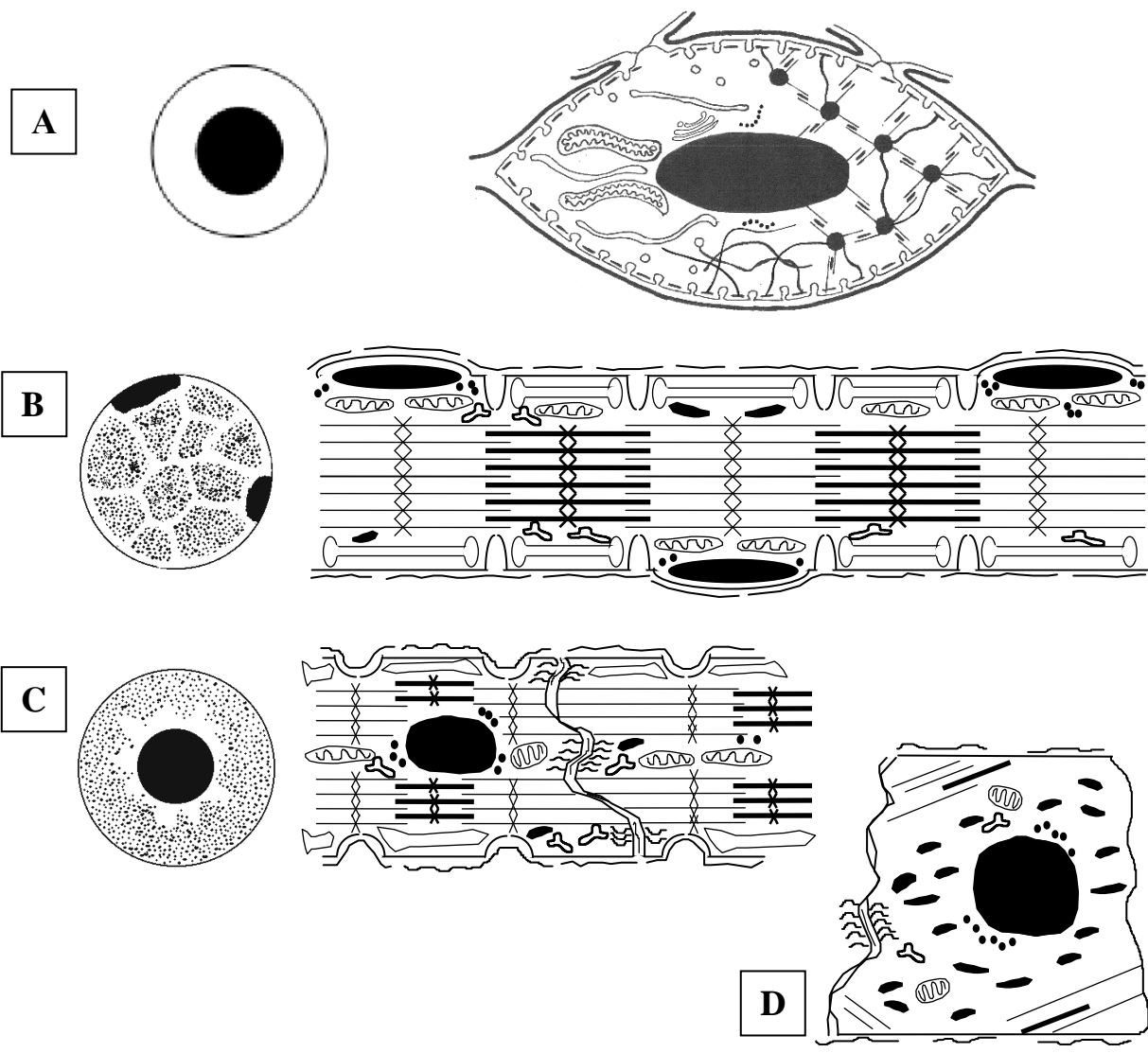
Task 10.6. SCHEME OF THE MUSCLE'S STRUCTURE AS AN ORGAN



Designate:

- 1 — Muscle fiber
- 2 — Endomysium
- 3 — Perimysium
- 4 — Epimysium

Task 10.7. STRUCTURAL SCHEME OF THE MUSCULAR TISSUE ELEMENTS



Designate:

- A** — cell of the smooth muscle tissue — smooth myocyte (SMC);
- B** — unit of the skeletal muscle tissue — myosymplast;
- C** — contractile cardiomyocytes (CMC);
- D** — conductive cardiomyocyte (CMC)

Supporting structure

- 1 — sarcolemma: 1a — cytolemma; 1b — basal membrane; 1c — T-tubules; 1d — caveolae;
- 2 — myofilaments' attachment site: 2a — dense bodies (in SMC); 2b — dense stripes (in SMC); 2c — Z-lines (in myosymplast, CMC); 2d — M-lines (in myosymplast, CMC)

Trophic apparatus

- 3 — nucleus; 4 — mitochondria; 5 — smooth endoplasmic reticulum (Ca⁺⁺ reserv.); 5a — SMC vesicles; 5b — L-tubules and terminal cisterns in myosymplast, CMC; 6 — ribosomes; 7 — glycogen inclusions; 8 — myoglobin inclusions

Contractile apparatus

- 9 — actin myofilaments;
- 10 — myosin myofilaments;

Intercellular junctions

- 11 — nexuses; 12 — desmosomes;
- 13 — interdigitations;

Cross sections

- 14 — nuclei; 15 — myofibrillar fields

Task 10.8. COMPARATIVE CHARACTERISTICS OF VARIOUS TYPES OF THE MUSCLE TISSUE

	skeletal	cardiac	smooth
Structural and functional unit			
Nucleus(i): number and localization			
Presence of myofibrils (= striation)			
Source of the development	1.	1.	1. 2. 3.
Regeneration: – division of the stem cells – intracellular regeneration			
Cell-to-cell junctions			
Sarcotubular system: – conduction of the impulse inside – Ca-storage			
Type of innervation			

Correct tasks № _____
Lecturer _____
Date « ____ » _____

Topic 11. NERVE TISSUE

1. Nerve tissue. General morphological and functional characteristics. Sources of the development, histogenesis.
2. Neurons. Classification (morphological, functional, mediatorial). Morphological and functional characteristics of the neurons. Transporting processes in neurons.
3. Neuroglia. Classification and development. Morphological and functional characteristics of different types of the neuroglia.
4. Nerve fibers. Classification. Morphological and functional characteristics of myelinated and unmyelinated fibers. Degeneration and regeneration of the nerve fibers.
5. Nerve endings (receptive and efferent types), classification and structure.
6. Interneuron synapses. General plan of synapses organization. Classification, structure, transmission of the nerve impulse.
7. Reflex arch - morphological base of the neurons activity. Basic structural elements of a reflex arch.

Home task: 11.1, 11.5, 11.6, 11.9–11.11.

Development sources of the nerve tissue { I –
II –
III –

Morphological and functional unit of nerve tissue: _____

Classifications of neurons

I. Morphological

- 1.
- 2.
- 3.
- 4.

II. Functional

- 1.
- 2.
- 3.
- 4.

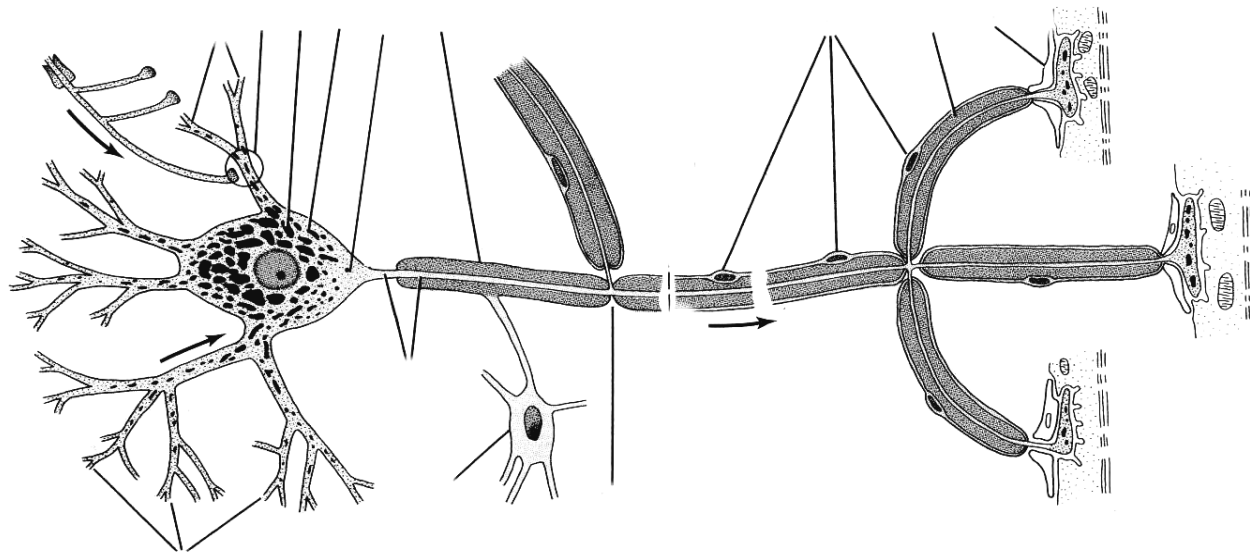
III. Mediatorial

- 1.
- 2.
- 3.
- 4.
- 5.

Task 11.1. STRUCTURAL ORGANIZATION OF THE NEURON (SCHEME)

Designate:

- 1 — nerve cell nucleus; 2 — axon;
- 3 — dendrites; 4 — cell body;
- 5 — basophilic substance (Nissl bodies);
- 6 — axon hillock; 7 — oligodendrocyte;
- 8 — recurrent axonal branch;
- 9 — axodendritic synapse;
- 10 — axial cylinder;
- 11 — myelin sheath;
- 12 — node of Ranvier;
- 13 — lemmocytes nucleus;
- 14 — neuromuscular synapse;
- 15 — striated muscular fiber



Task 11.2. BASOPHILIC SUBSTANCE OF THE SPINAL CORD'S NEURONS

Staining: Toluidine blue
Magnification: 400×

Designate:

- 1 — nucleus; 2 — basophilic substance (Nissl bodies); 3 — axon;
- 4 — dendrites

Task 11.3. NEUROFIBRILS OF THE SPINAL CORD'S NEURONS

Staining: Silver impregnation
Magnification: 400×

Designate:

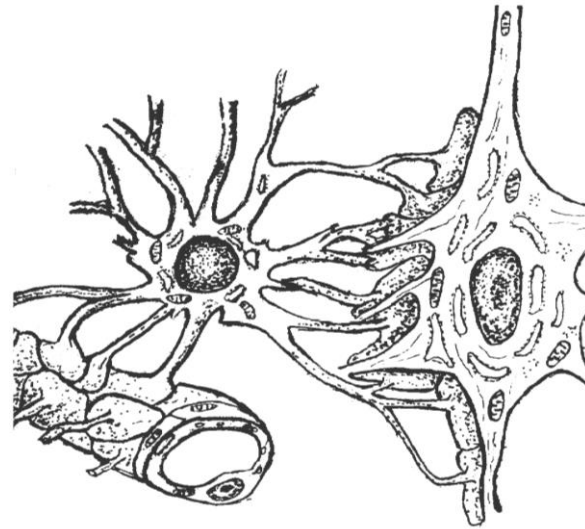
- 1 — nucleus of neuron; 2 — neurofibrils; 3 — axon; 4 — dendrites

Task 11.4. MICROGLIA

Staining: Silver impregnation
Magnification: 400×

Draw and designate:
1 — microglial cells

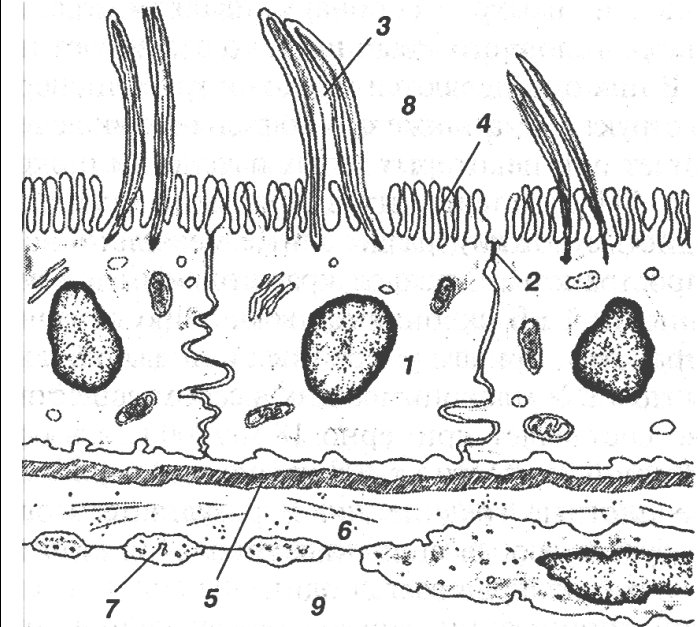
Task 11.5. SCHEME OF INTERACTIONS OF ASTROCYTE WITH HEMOCAPILLARY AND NEURON (BLOOD-BRAIN BARRIER)



Designate:

- 1 — astrocyte body; 2 — astrocyte nucleus;
- 3 — perivascular feet; 4 — perineural feet;
- 5 — hemocapillary endothelium; 6 — neuron;
- 7 — neuron nucleus; 8 — perikaryon;
- 9 — neuron processes

Task 11.6. SCHEME OF A HEMATO-LIQUOR BARRIER



Learn:

- 1 — ependymocyte; 2 — tight junction;
- 3 — ependymocyte cilia; 4 — ependymocyte microvilli;
- 5 — basal membrane; 6 — perivascular space; 7 — fenestrated endothelium

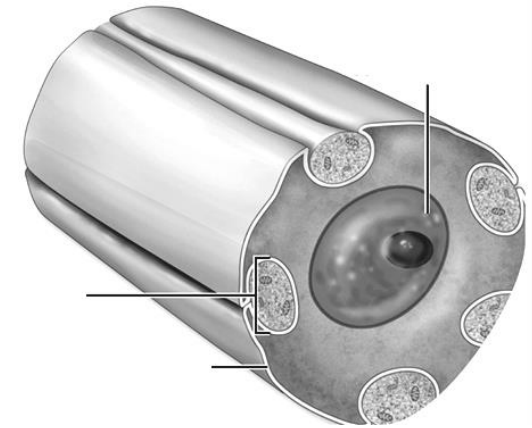
Origin		Origin		Origin	
Function		Function		Function	

Task 11.7. UNMYELINATED NERVE FIBERS

Staining: Hematoxylin-eosin

Magnification: 400×

Nerve fiber is a neuron's processes covered by the glial sheath.



A

Designate picture (A) and scheme (B):

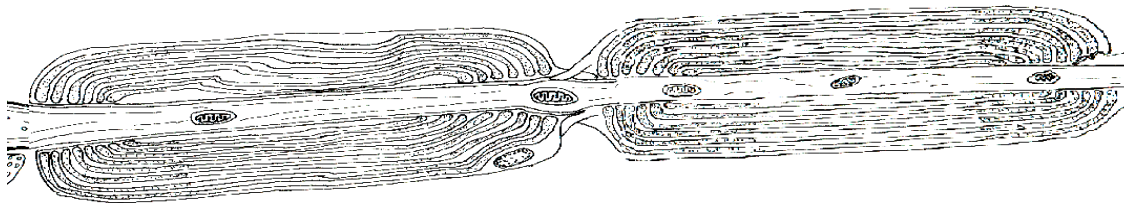
1 — lemmocytes nuclei; 2 — unmyelinated nerve fibers; 3 — axis cylinders; 4 — mesaxon

B

Task 11.8. MYELINATED NERVE FIBERS

Staining: Osmic acid

Magnification: 400×

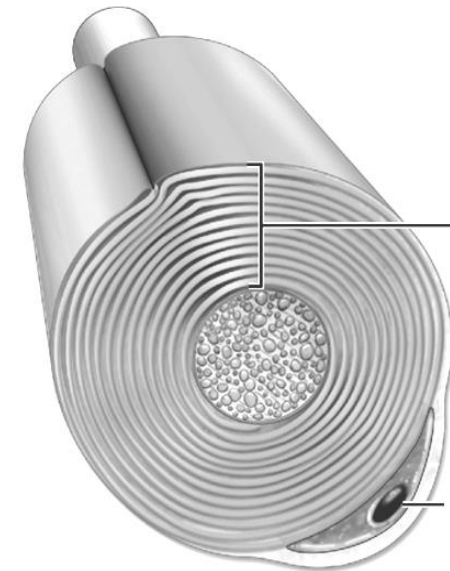


A

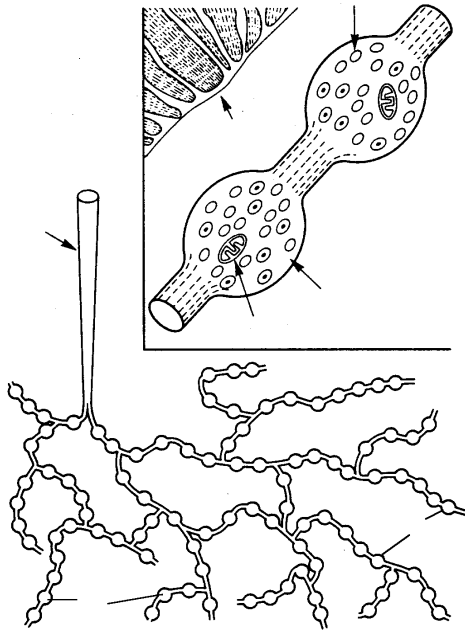
Designate schemes (A & B):

1 — axis cylinder; 2 — myelinated nerve fiber; 3 — neurilemma; 4 — lemmocytes nuclei;
5 — node of Ranvier; 6 — myelin layer

B



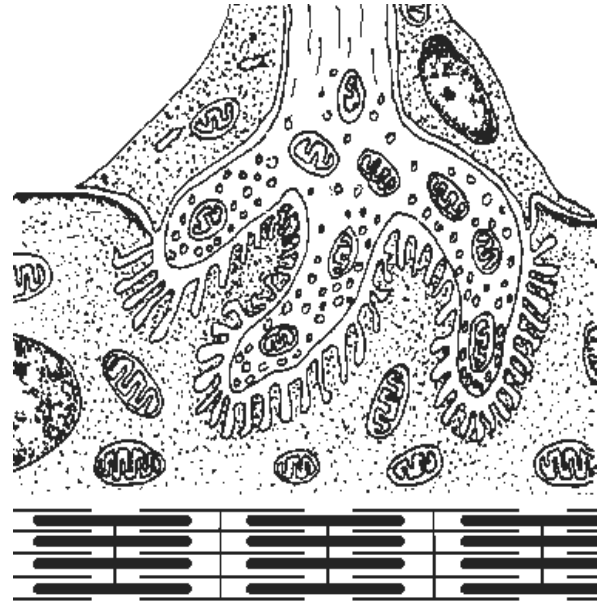
Task 11.9. EFFERENT ENDING OF SMOOTH MUSCLE



Designate:

- 1 — smooth cells;
- 2 — axon;
- 3 — axon terminals;
- 4 — varicose dilations;
- 5 — vesicles with mediator;
- 6 — mitochondria

Task 11.10. NEUROMUSCULAR SYNAPSE

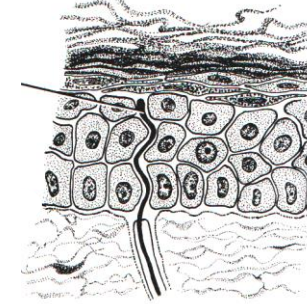


Designate:

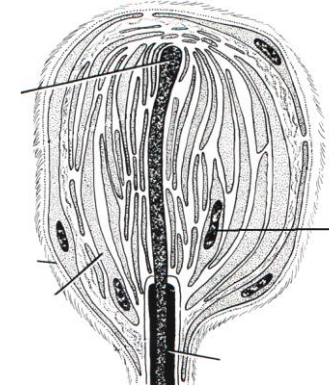
- 1 — presynaptic membrane;
- 2 — synaptic vesicles;
- 3 — axon mitochondria;
- 4 — lemmocyte;
- 5 — postsynaptic membrane;
- 6 — myosymplast nucleus;
- 7 — mitochondrion of muscle fiber;
- 8 — myofibrils;
- 9 — synaptic cleft

Task 11.11. AFFERENT NERVE ENDINGS

A — free nerve ending



B — encapsulated nonfree nerve ending



Designate:

- 1 — terminal of the sensory nerve fibers;
- 2 — Schwann cells; 3 — nucleus of Schwann cell; 4 — myelin; 5 — connective tissue capsule

Correct tasks № _____

Lecturer _____

Date « ____ » _____

Topic 12. CARDIOVASCULAR SYSTEM

1. General morphological and functional description of the cardiovascular system. Principles of vessel innervation and nourishment.
2. Classification of vessels, their development, general structure.
3. Arteries. Classification. Dependence of the artery wall structure on haemodynamic conditions.
4. Veins. Classification. Influence of haemodynamic conditions on the vein wall structure.
5. Microcirculation. The structure and functional description of its vessels. Capillaries: classification, organ specificity. Lymphatic capillaries.
6. Anastomoses between arterioles and venules. Classification. Structure, functional description.
7. The heart. Sources and stages of the development, structure of cardiac membranes. Structure of the heart valves.
8. Morphofunctional and histochemical description of the contractile cardiac muscle tissue. Regeneration.
9. Conductive cardiac system. Ultrastructural and histochemical description of the conductive myocytes. Peculiarities of the interaction between the conductive cardiac system and the contractile cardiomyocytes.
10. Secretory cardiomyocytes, their morphological and functional description.

Home task: 12.1, 12.2, 12.4, 12.7, 12.8.

The functions of the cardiovascular system:

1. _____
2. _____
3. _____
4. _____

Definition of *Organ* _____

Classification of organs:

Components of parenchymal organ:

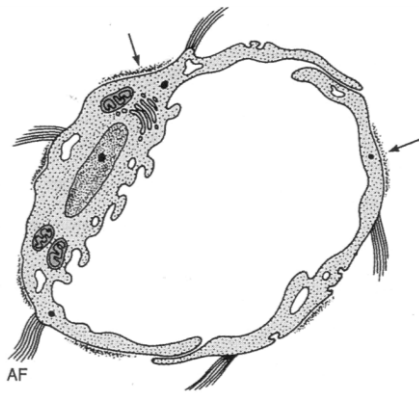
Stroma _____

Parenchyma _____

**Components of the wall of the tubular organ
(wall of intestine):**

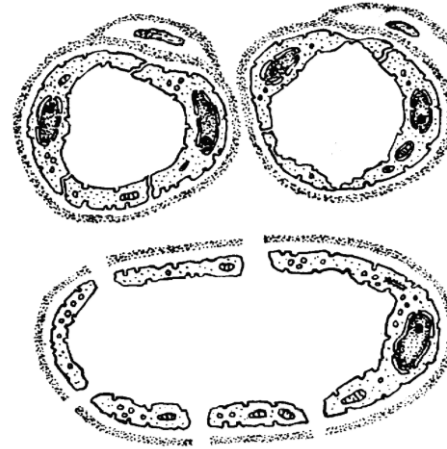
Membrane or tunic	Layer or lamina
1.	1. 2. 3.
2.	
3.	
4.	

Task 12.1. ULTRAMICROSCOPIC STRUCTURE OF THE LYMPHATIC CAPILLARY WALL



- Designate:**
 1 — endothelial cells (EC);
 2 — EC nucleus;
 3 — discontinuous basal membrane;
 4 — anchoring (collagen) fibrils

Task 12.2. ULTRAMICROSCOPIC STRUCTURE OF THE BLOOD-CAPILLARY WALL



- Designate:**
 A — somatic capillary;
 B — fenestrated capillary;
 C — sinusoidal capillary.
- 1 — endothelial cells (EC);
 2 — EC nucleus;
 3 — basal membrane;
 4 — pericytes;
 5 — EC fenestras;
 6 — pores in the EC

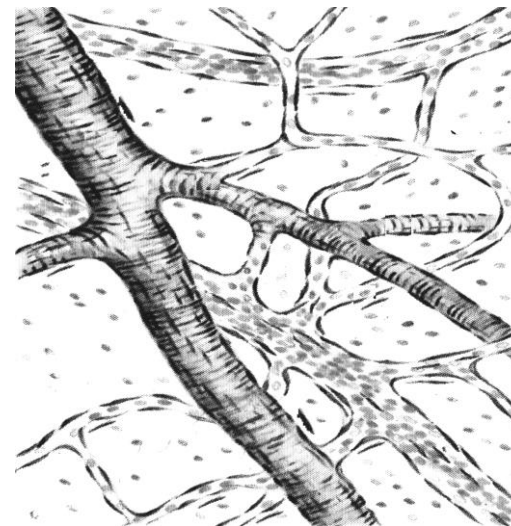
Task 12.3. ELASTIC ARTERY (aorta)

Staining: Orsein
 Magnification: 400×

Draw and designate the elastic fibers and elastic fenestrated lamellae:

- 1 — tunica intima; 2 — tunica media; 3 — tunica externa

Task 12.4. SMALL BLOOD VESSELS OF THE SOFT BRAIN MEMBRANE



- Designate:**
 1 — arteriole;
 2 — venule;
 3 — capillary;
 4 — myocytes;
 5 — endotheliocytes nuclei;
 6 — adventitious cells;
 7 — erythrocytes;
 8 — connective tissue cells

Task 12.5. MUSCULAR ARTERY

Staining: Hematoxylin-eosin
Magnification: 400×

Draw and to designate:

I — Tunica intima:

- 1 — endothelium;
- 2 — subendothelial layer;
- 3 — internal elastic membrane.

II — Tunica media:

- 4 — smooth muscle cells;
- 5 — intercellular substance;
- 6 — external elastic membrane.

III — Tunica externa (adventitia):

- 7 — intercellular substance;
- 8 — connective tissue cell nuclei;
- 9 — vascular vessels

Task 12.6. VEIN (femoral vein)

Staining: Hematoxylin-eosin
Magnification: 400×

Draw and designate:

I — Tunica intima:

- 1 — endothelium;
- 2 — subendothelial layer.

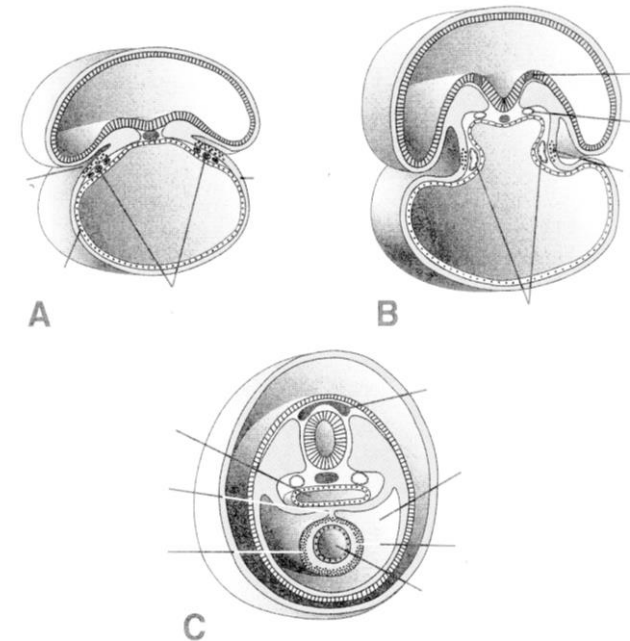
II — Tunica media:

- 3 — muscular cells with a circular orientation; 4 — intercellular substance with elastic fibers;

III — Tunica externa:

- 5 — intercellular substance;
- 6 — connective tissue cell nuclei;
- 7 — longitudinal bundles of the smooth muscle cells; 8 — vascular vessels

Task 12.7. SCHEME OF HEART DEVELOPMENT



Designate:

A — paired primordia of the heart; B — paired primordia of the heart are converged; C — paired primordia unite and form endothelial tube.

- 1 — ectoderm; 2 — endoderm;
- 3 — parietal mesodermal layer;
- 4 — visceral mesodermal layer; 5 — neural groove;
- 6 — neural tube; 7 — neural crest; 8 — coelom;
- 9 — foregut; 10 — angioblast and endocardial tube;
- 11 — myoepicardial plate; 12 — myocardium;
- 13 — epicardium; 14 — pericardial cavity

Task 12.8. COMPARATIVE CHARACTERISTICS OF VARIOUS TYPES OF CARDIOMYOCYTES

	Contractile	Conductive
Functions		
Type of metabolism		
Resistance to oxygen insufficiency		
Predominant type of inclusions		
Mitochondria (number and size)		
Myofibrils (number and location)		
Location in myocardium		

Correct tasks № _____

Lecturer _____

Date « ____ » _____

Task 12.9. THE CARDIAC WALL

Staining: Haematoxylin-eosin
Magnification: 400×

Draw and designate:

I — Endocardium:

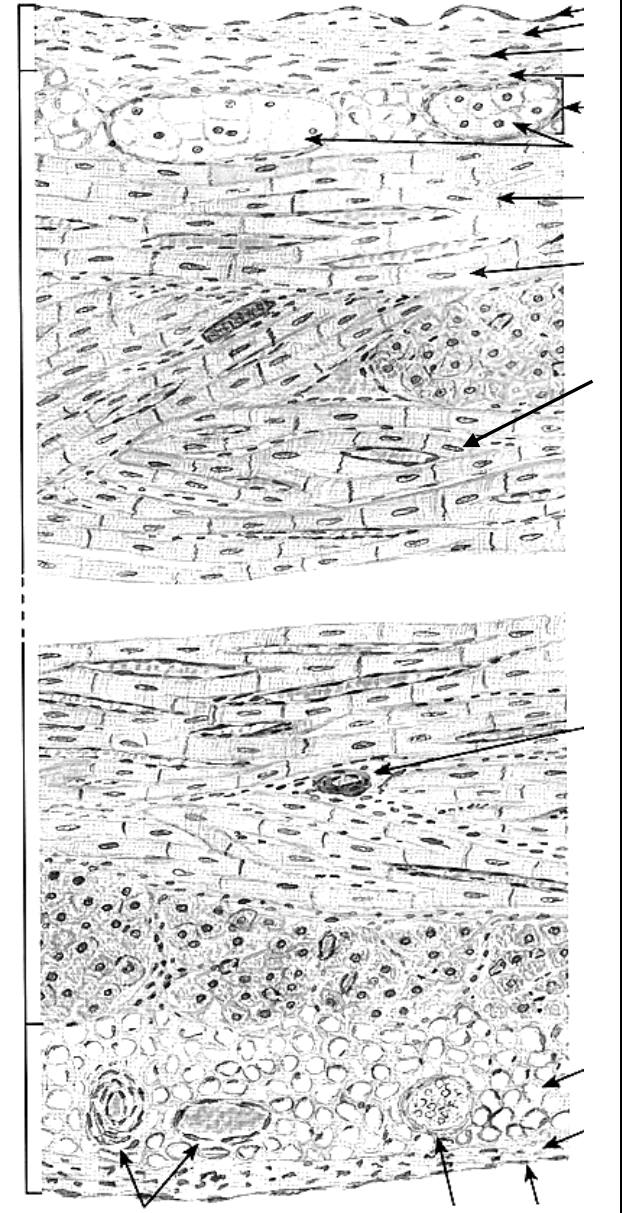
- 1 — endothelial layer;
- 2 — subendothelial layer;
- 3 — myoelastic layer;
- 4 — subendocardial layer.

II — Myocardium:

- 5 — typical cardiomyocytes;
- 6 — intercalated disc;
- 7 — connective tissue with capillaries;
- 8 — conducting cardiomyocytes (Purkinje fibers);
- 9 — anastomoses between cardiomyocytes.

III — Epicardium:

- 10 — lamina propria with adipose cells;
- 11 — mesothelial cells;
- 12 — blood vessels



Topic 13. RESPIRATORY SYSTEM

1. Respiratory system. Parts of the respiratory system. Morphological and functional characteristics. Respiratory and non-respiratory functions.
2. Lung development.
3. Structure and functions of the conducting part. Nasal cavity, larynx.
4. Structure of trachea and bronchi. Bronchial secret. Terminal bronchioles.
5. Respiratory part. Acinus. Respiratory bronchioles.
6. Alveoli. Cellular structure of the alveolar wall. Air-blood barrier.
7. Surfactant complex.

Home task: 13.1–13.4, 13.6.

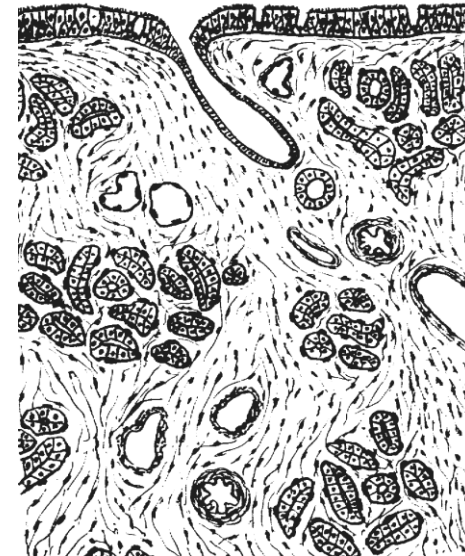Task 13.1. Fill in the table.

Air passage	Respiratory part
1.	1.
2.	2.
3.	3.
4.	4.
5.	
a)	
b)	
c)	
6.	

Task 13.2. NASAL MUCOSA (RESPIRATORY AREA)

Staining: Hematoxylin-eosin



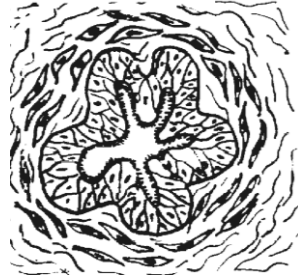
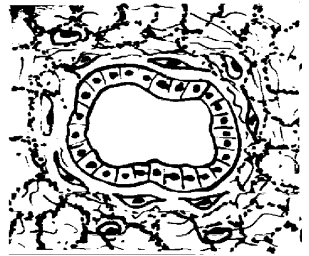
Magnification: 400×



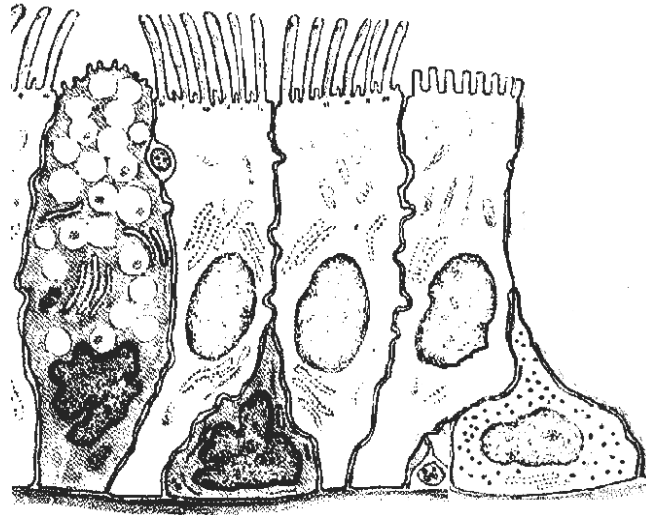
Designate:

- 1 — pseudostratified ciliated epithelium;
- 2 — ciliated cells; 3 — goblet cells;
- 4 — excretory ducts of protein-mucous glands;
- 5 — terminal portions of the glands;
- 6 — lamina propria of the mucous membrane;
- 7 — arteries; 8 — veins; 9 — venous sinuses

Task 13.3. STRUCTURE OF DIFFERENT PARTS OF THE CONDUCTING PART

Membrane	Trachea	Principal bronchi (large)	Lobar (medium) bronchi	Small bronchi	Terminal bronchiole
I. The mucous membrane:					
1) Epithelium	1. a) b) c) d)				
2) Lamina propria					
3) Lamina muscularis					
Folds of mucosa					
II. Submucous membrane					
III. Cartilaginous membrane					
IV. Adventitial membrane					

Task 13.4. EPITHELIAL CELLS OF CONDUCTING PART



Designate:

- 1 — goblet cell;
- 2 — ciliated cells;
- 3 — neuroendocrine cells;
with microvilli (brush cell);
- 4 — neuroendocrine cell;
(small granular cell);
- 5 — basal cell;
- 6 — nerve ending

Task 13.5. TRACHEA

Staining: Hematoxylin-eosin

Magnification: 400×

Draw and designate:

I. Mucous membrane:

- 1 — pseudostratified ciliated epithelium;
- 2 — ciliated cells;
- 3 — goblet cells;
- 4 — basal cells;
- 5 — lamina propria;

II. Submucous membrane:

- 6 — secretory portions
of serous-mucous glands;

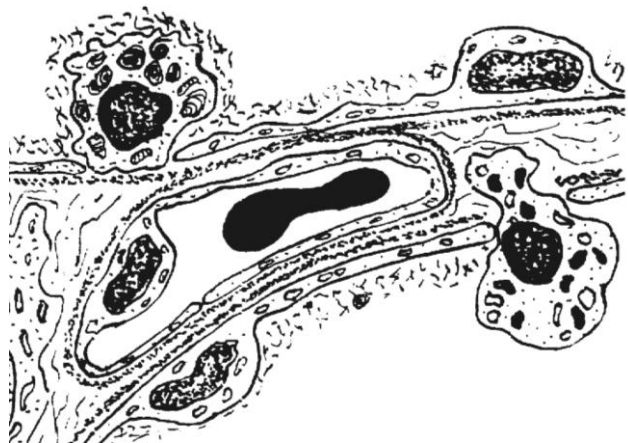
III. Cartilaginous membrane:

- 7 — perichondrium;
- 8 — hyaline cartilage;

IV. Adventitial membrane:

- 9 — blood vessels

Task 13.6. STRUCTURE OF THE ALVEOLAR WALL



Designate:

- 1 — type I pneumocyte;
- 2 — type II pneumocyte;
- 3 — alveolar macrophage;
- 4 — common basal lamina of capillary endothelium and type I pneumocyte;
- 5 — capillary endothelium;
- 6 — surfactant.

Correct tasks № _____

Lecturer _____

Date « ____ » _____

Task 13.7. MIDDLE BRONCHUS

Staining: Hematoxylin-eosin

Magnification: 400×

Draw and designate:

- I** — mucous membrane:
 - 1 — pseudostratified ciliated epithelium; 2 — lamina propria;
 - 3 — lamina muscularis;
- II** — submucous membrane;
- 4 — secretory portions of glands;
- III** — cartilaginous membrane;
- 5 — cartilage
- IV** — adventitial membrane;
- 6 — connective tissue; 7 — vessels

Task 13.8. SMALL BRONCHUS

Staining: Hematoxylin-eosin

Magnification: 400×

Draw and designate:

- I** — mucous membrane:
 - 1 — pseudostratified ciliated epithelium; 2 — lamina propria;
 - 3 — lamina muscularis;
- II** — adventitial membrane;
- 4 — connective tissue; 5 — vessels

Topic 14. INTEGUMENTARY SYSTEM

1. Integumentary system (the skin). Morphological and functional characteristics. Sources of the development.
2. Skin. Morphological and functional characteristics of the thick skin epidermis (that of the palms and feet). Keratinization and regeneration of the skin epidermis.
3. Morphological and functional characteristics of the skin epidermis melanocytes and dendrocytes and their development.
4. Structure and function of the connective tissue basis of the skin (dermis). Structural features of the papillary and the reticular tissue layers. Skin receptors.
5. Skin glands. Morphological and functional characteristics of the eccrine and apocrine sweat glands. Topographic, structural and secretory peculiarities of the sebaceous glands.
6. Development and structure of hair. Hair types. Hair growth and replacement. Nail structure.
7. Age- and sex-related peculiarities of the skin.

Revise: epithelial tissue.

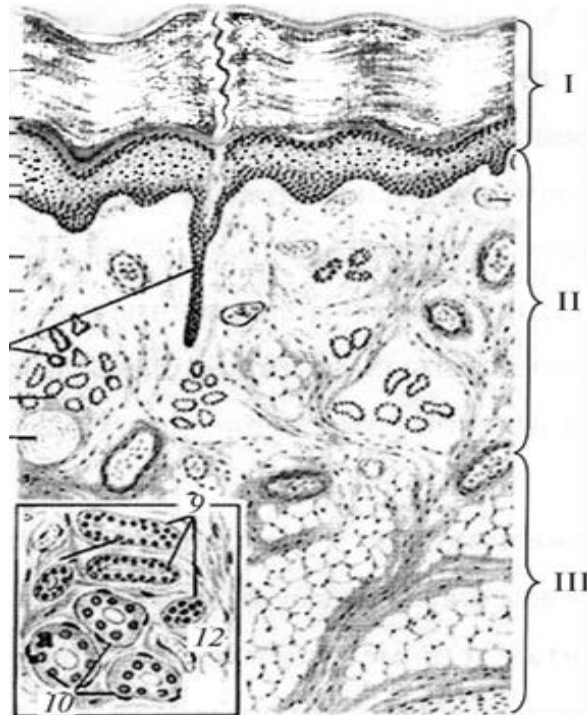
Home task: 14.1, 14.3–14.5.

Task 14.1. ORIGIN AND FUNCTIONS OF THE EPIDERMIS CELLS (fill in the table)

Type of epidermis cell	Source of development	Function
Keratinocyte		I. II. Synthesis of proteins: 1. 2. 3.
Melanocyte		
Merkel's cell		
Dendrite cell of Langerhans		
T-lymphocyte		

Task 14.2. FINGER'S SKIN

Staining: Hematoxylin-eosin
Magnification: 400×



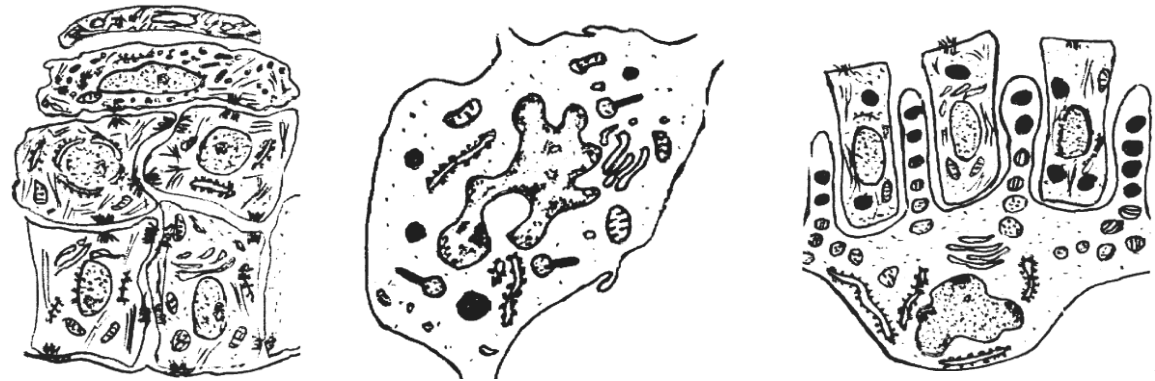Color and designate:

I — epidermis: 1 — stratum basale; 2 — stratum spinosum; 3 — stratum granulosum; 4 — stratum lucidum; 5 — stratum corneum.

II — dermis: 6 — papillary layer; 7 — reticular layer; 8 — sweat glands; 9 — blood vessels.

III — hypodermis

Task 14.3. TYPES OF SKIN EPIDERMIS CELLS



Designate:

I — keratinocytes: 1 — basal cell; 2 — spinous cell; 3 — granular cell; 4 — corneocyte.

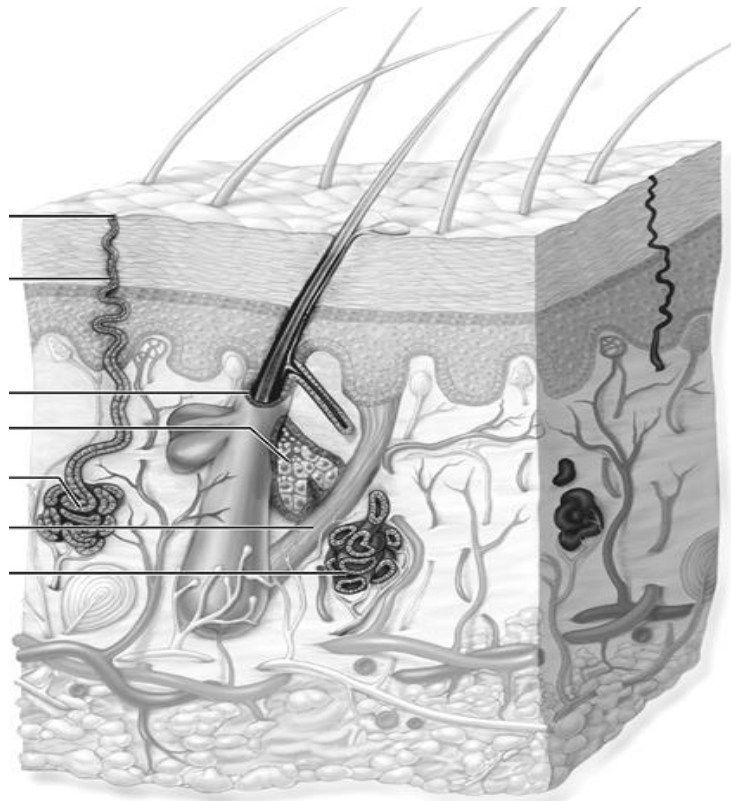
II — melanocyte: 5 — melanosomes of melanocytes;

III — dendrocytes: 6 — tennis racquet-shaped granules

Task 14.4. SKIN GLANDS

Types of glands	Structural type	Type of secretion	Location in the skin
1. Sweat glands a) merocrine b) apocrine			
2. Sebaceous			
3. Mammary			

Task 14.5. SKIN AND ITS APPENDAGES (SCHEME)



Designate:

- 1 — sweat pore;
- 2 — sweat excretory duct;
- 3 — merocrine sweat gland;
- 4 — apocrine sweat gland,
- 5 — sebaceous gland;
- 6 — hair follicle;
- 7 — arrector pili muscle

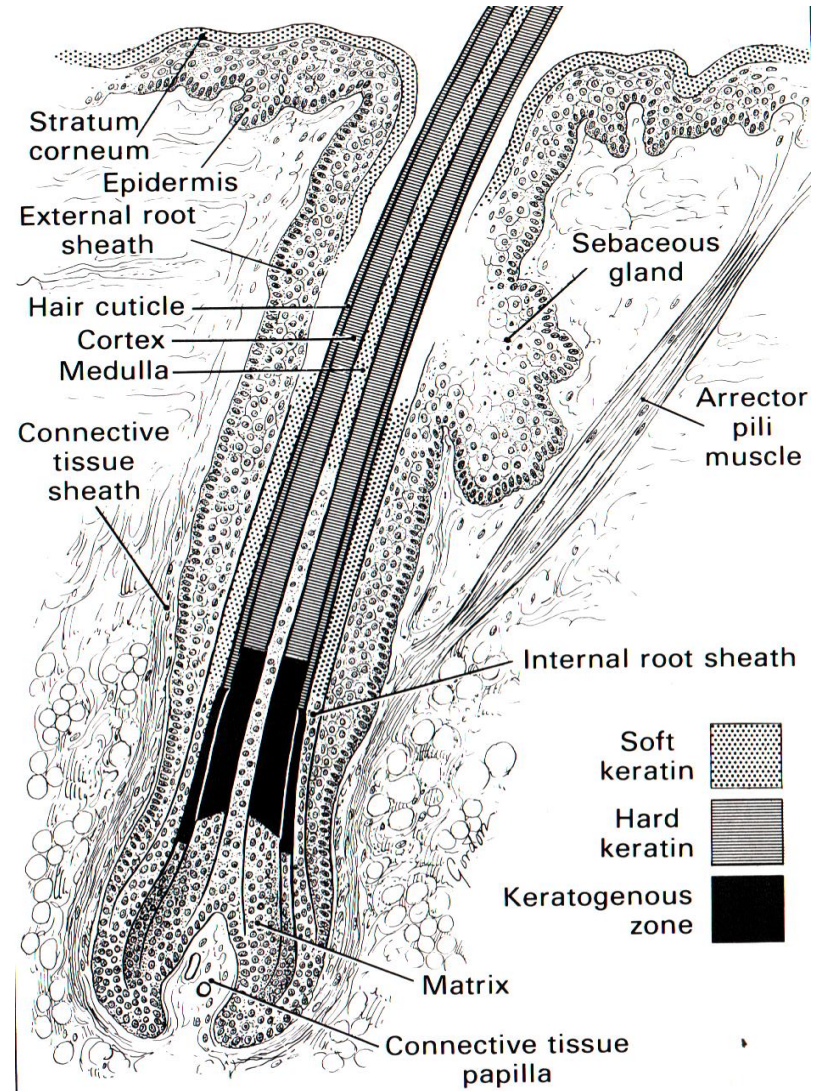
Correct tasks № _____

Lecturer _____

Date « ____ » _____

Task 14.6. LONGITUDINAL SECTION OF HAIR

Learn



Topic 15. DIGESTIVE SYSTEM. ANTERIOR PART

1. Digestive system: development sources and their derivatives, general structure (membranes and layers), functions.
2. Oral cavity, structural organization of its mucous membrane and function.
3. The lips, gums, cheeks, hard and soft palate. Their histological and physiological features.
4. Structure of the tongue. Characteristics of the tongue papillae. Taste buds.
5. Teeth. Sources and basic stages of the development. Microscopic structure of the dentine, enamel, cementum and pulp. Tooth supporting structures.
6. Age-related changes of the oral mucous membrane.
7. Esophagus. Sources and features of the development. Oesophageal membrane structure and their topographic features. Functions of the oesophagus.

Revise: epithelial tissue.

Home task: 15.1, 15.3, 15.4, 15.8.

Definition of the term Digestion _____

Write down the organs of the digestive tract:

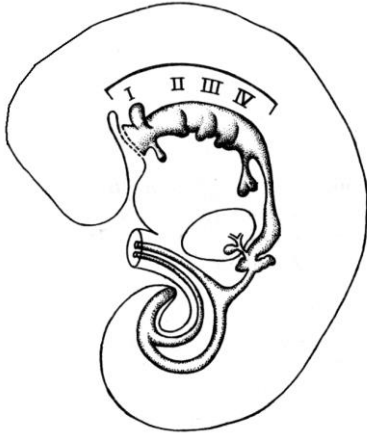
I. Organs of the alimentary canal

- 1.
- 2.
- 3.
- 4.
- 5.
- 6.

II. Digestive glands

1.
 - a)
 - b)
 - c)
- 2.
- 3.

Task 15.1. DEVELOPMENT SOURCES OF THE DIGESTIVE SYSTEM

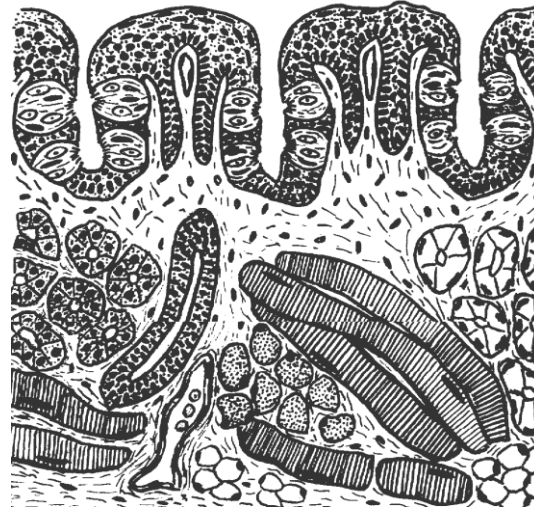


Color:
foregut — in **blue**;
midgut — in **yellow**;
hindgut — in **red**.

Designate:
1 — stomodeum;
2 — oropharyngeal membrane;
3 — pharyngeal pouches;
4 — primordia esophagus;
5 — trachea and primordia of lung;
6 — primordia of the stomach;
7 — primordia of the liver;
8 — primordia of the pancreas;
9 — cloacal membrane;
10 — midgut; 11 — hindgut;
12 — allantois; 13 — vitelline duct

Task 15.2. TONGUE OF A RABBIT. FOLIATE PAPILLAE

Staining: Hematoxylin-eosin
Magnification: 80×, 400×



Designate:
I — Mucous membrane:
1 — stratified nonkeratinized squamous epithelium;
2 — taste buds in epithelium;
3 — lamina propria of the mucous membrane;
4 — primary connective-tissue papillae;
5 — secondary connective-tissue papillae;
II — Muscular coat (muscular body):
6 — striated muscles of the tongue;
7 — secretory portions of the glands;
8 — excretory duct of salivary gland;
9 — adipose cells;
10 — blood vessels

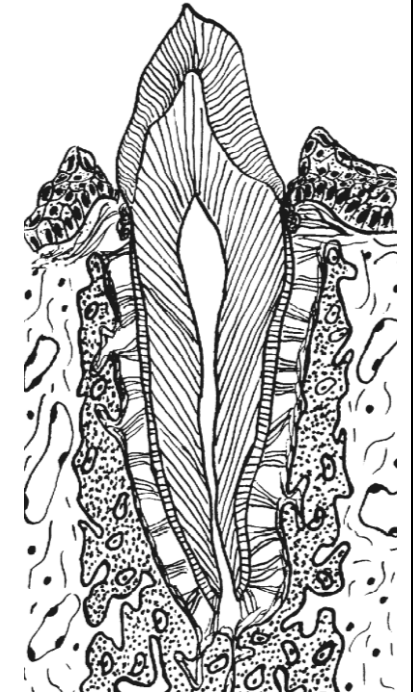
Task 15.3. TOOTH STRUCTURES AND THEIR TISSUE COMPONENTS

Designate and complete:

- 1 — crown, consisting of:
a)
b)
c)
2 — neck of the tooth;
3 — root, consisting of
a)
b)
c)

Dental ligaments (periodontal membrane), consisting of:

- 4 — gum (gingival);
5 — alveolar bone;
6 — periodontium;
7 — cementum




Task 15.4. Fill in the table.

	tissue	regeneration degree
enamel		
dentin		
cementum		
pulp		
periodontium		

Task 15.5. TOOTH DEVELOPMENT. CAP STAGE

Staining: Hematoxylin-eosin
Magnification: 80×, 400×

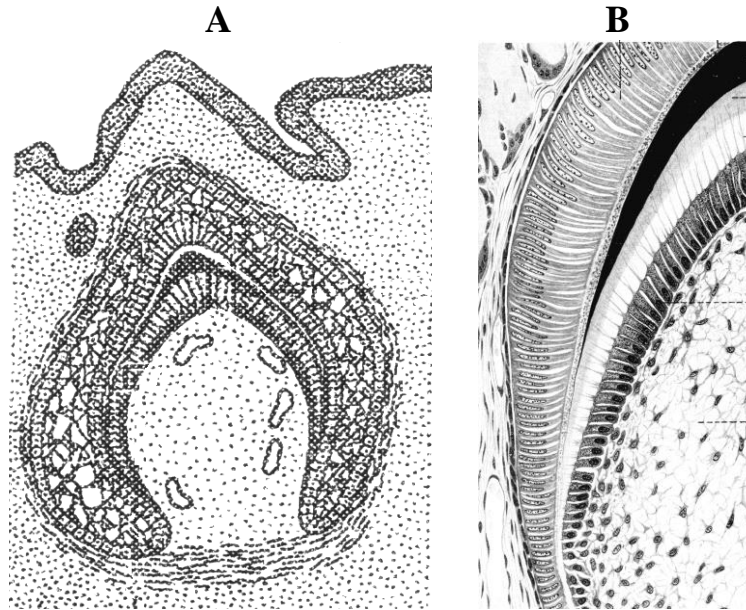


Designate:

- 1 — oral epithelium; 2 — mesenchyme;
- 3 — blood vessels; 4 — dental lamina;
- 5 — outer enamel epithelium;
- 6 — inner enamel epithelium;
- 7 — stratum intermedium;
- 8 — pulp of enamel organ;
- 9 — dental papilla; 10 — dental sac;
- 11 — dental alveolar rudiment

Task 15.6. TOOTH DEVELOPMENT. DENTIN AND ENAMEL STAGE

Staining: Hematoxylin-eosin
Magnification: 80×, 400×



Designate in schemes A, B and picture C:

- 1 — external enamel epithelium;
- 2 — enameloblasts;
- 3 — enamel;
- 4 — odontoblasts;
- 5 — pre dentine;
- 6 — dentine;
- 7 — dentinal tubules;
- 8 — pulp;
- 9 — blood vessels

Complete the table and write down dental tissues developing:

1. From enamel organ: – from the inner layer:	
– from the outer layer and the pulp:	
2. From the dental papilla:	1. 2.
3. From the dental sac:	1. 2.

Task 15.7. CROSS-SECTION OF THE ESOPHAGUS

Staining: Hematoxylin-eosin
Magnification: 400×

Draw and designate:

I — mucous membrane:

- 1 — stratified nonkeratinized squamous epithelium;
- 2 — excretory ducts of the proper glands;
- 3 — lamina propria;
- 4 — lamina muscularis;

II — submucous membrane:

- 5 — proper glands;

III — muscular membrane:

- 6 — a) circular; b) longitudinal layers;
- 7 — intramuscular nerve ganglion;

IV — adventitial membrane:

- 8 — connective tissue;
- 9 — blood vessels

Designate:

I — mucous membrane:

- 1 — epithelium; 2 — lamina propria;
- 3 — lymphoid nodule in lamina propria;
- 4 — muscular lamina; 5 — crypts;
- 6 — villi; 7 — folds.

II — submucous membrane:

- 8 — complex glands.

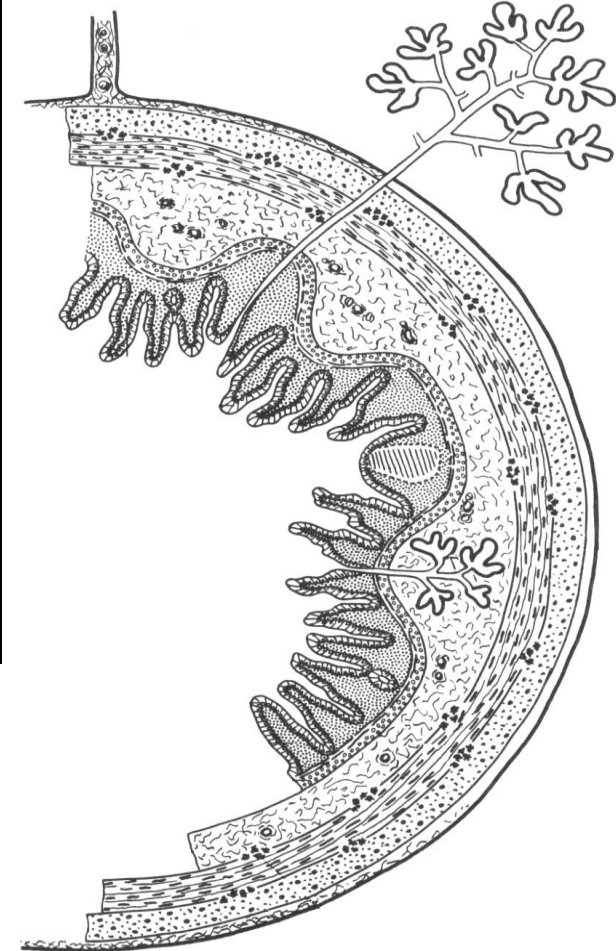
III — muscular membrane:

- 9 — inner circular layer;
- 10 — outer longitudinal layer;

IV — external membrane

- V — extramural glands

Task 15.8. DIGESTIVE TUBE



Correct tasks № _____

Lecturer _____

Date « ____ » _____

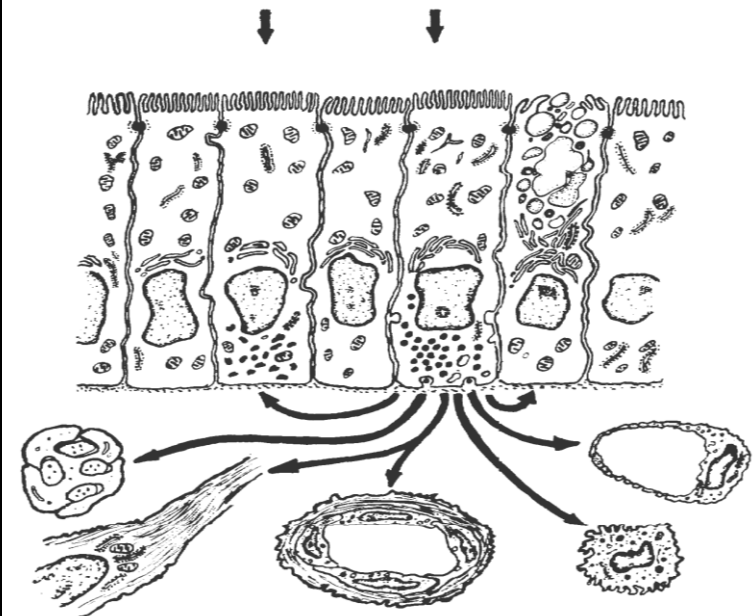
Topic 16. DIGESTIVE SYSTEM. MIDDLE AND POSTERIOR PART

1. Stomach: Source of the development, general characteristics of its membranes, functions.
2. Morphological characteristics of the different gastric parts: Relief of gastric mucosa, glands (branching, character of the secretion, cellular structure), peculiarities of the muscular membrane.
3. Main gastric glands: topography, characteristics of the excretory duct and secretory portion (degree of branching, shape), cellular structure (cell localization, micro- and ultramicroscopic structure, functions).
4. Structural peculiarities of the gastric wall and its glands in the cardiac and pyloric regions.
5. Structure and functions of the small and large intestines.
6. Microscopic structure of the small intestine villi, their functions. Ultramicroscopic structure and regeneration of the small intestine epithelium.
7. Cavernous, membranous and intracellular digestion. Histophysiology of the crypt — villus system.
8. Structural features of the duodenal wall.
9. Morphology of the large intestine wall.
10. Structural features of the appendix.
11. Endocrine system of the digestive tract.

Revise smooth muscle and striated visceral muscle tissues.

Home task: 16.1, 16.4–16.7, 16.10, 16.14.

Task 16.1. HORMONAL ACTIVITY OF GASTROINTESTINAL ENDOCRINE CELLS




Designate:

- 1 — enteroendocrine cells; 2 — adjacent enterocytes;
- 3 — nerve fibers; 4 — smooth muscle cells;
- 5 — arterioles; 6 — connective tissue cells;
- 7 — capillaries; 8 — goblet cell

Task 16.2. FUNDUS OF THE STOMACH

Staining: Hematoxylin and congo-red
Magnification: 400×



Draw and designate:

I — Mucous membrane:

- 1 — gastric pits;
- 2 — surface columnar epithelium;
- 3 — parietal cells;
- 4 — chief cells;
- 5 — mucous cells;
- 6 — endocrine cells;
- 7 — undifferentiated cells;
- 8 — muscular lamina.

II — Submucous membrane:

- 9 — blood vessels

III — Muscular membrane:

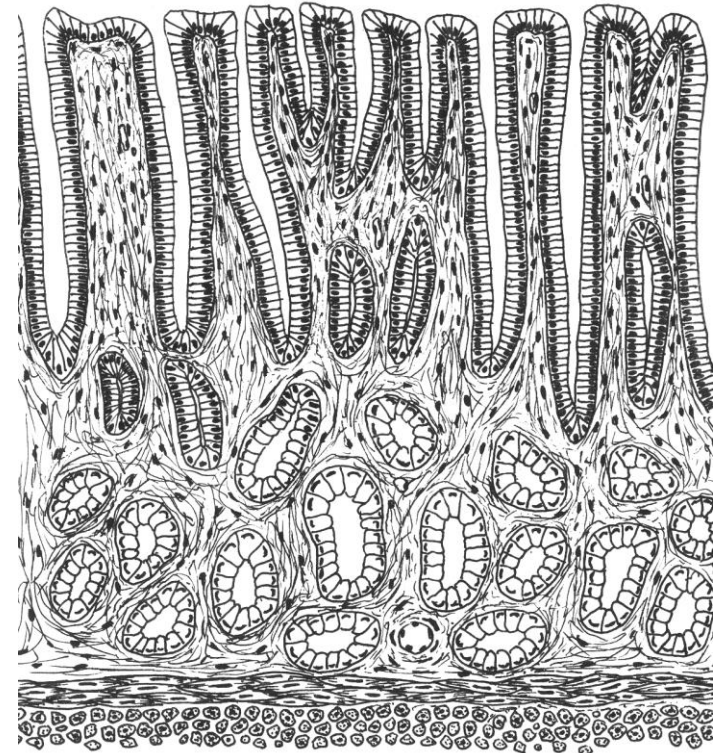
- 10 — oblique (a), circular (b) and longitudinal (c) layers;
- 11 — intramuscular nerve ganglion.

IV — Serosus membrane:

- 12 — connective tissue lamina;
- 13 — nuclei of mesothelial cell

Task 16.3. PYLORIC PORTION OF THE STOMACH

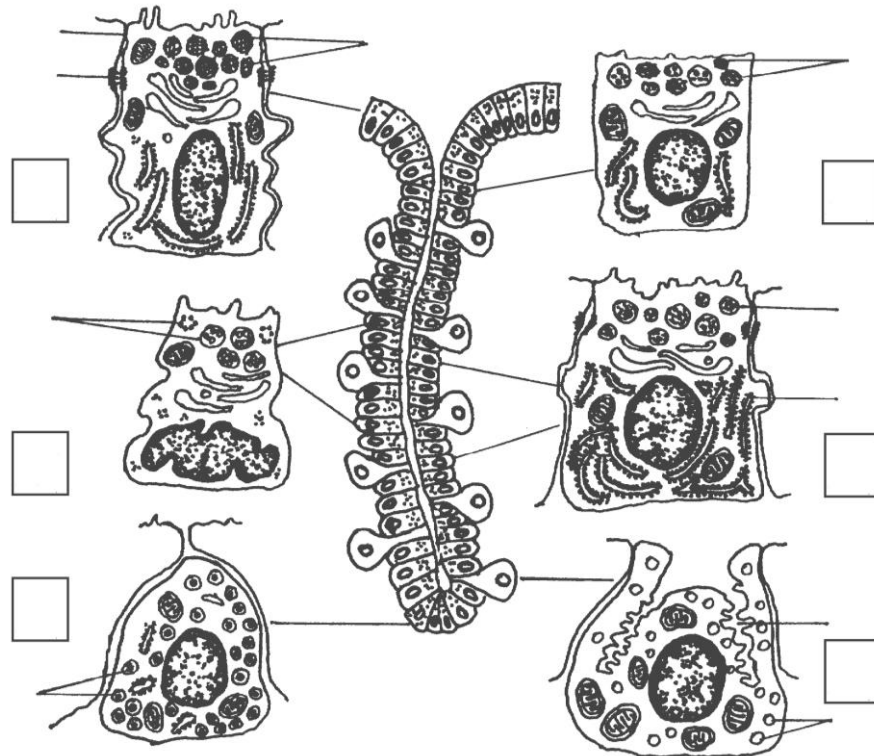
Staining: Hematoxylin-eosin
Magnification: 400×



Designate the structures of mucous membrane:

- 1 — surface mucous epithelium;
- 2 — longitudinal section of gastric pits;
- 3 — cross-section of gastric pits;
- 4 — secretory portions of pyloric glands

Task 16.4. SURFACE EPITHELIUM AND CELLS OF MAIN GASTRIC GLANDS (based on electron microscopic image)



Designate:

I — surface mucous columnar epithelium:

1 — granules of mucous secretion; 2 — close contact;

II — mucous neck cells (undifferentiated cells):

3 — secretory granules of different types;

III — chief cells:

4 — protein secretory granules;

5 — granular endoplasmic reticulum;

IV — mucous cells of the gland body:

6 — mucous secretory granules;

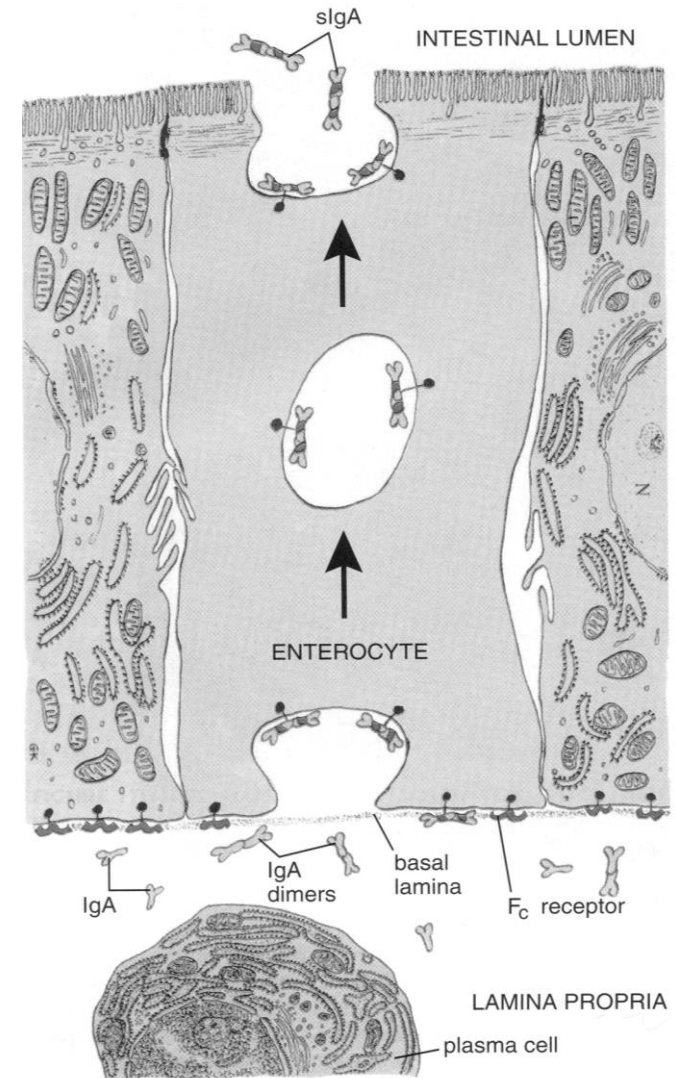
V — parietal cells:

7 — intracellular secretory tubule; 8 — vacuoles;

VI — endocrine cells:

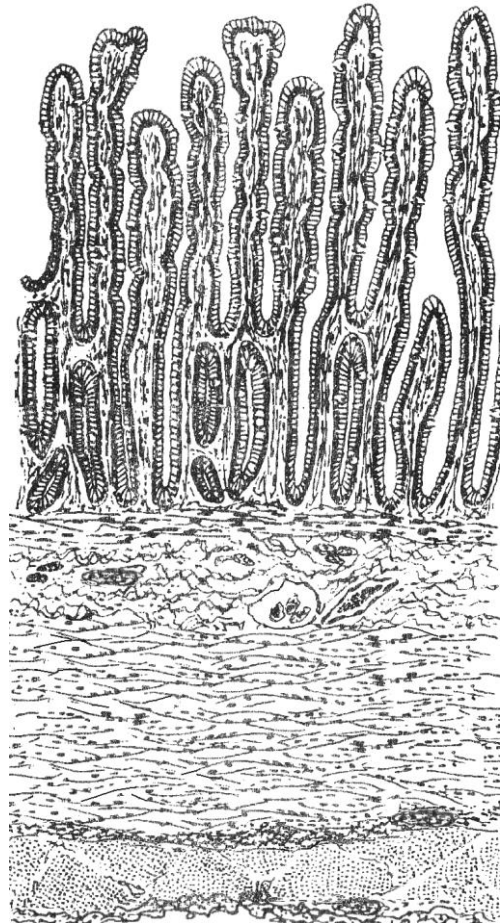
9 — secretory granules

Task 16.5. DIAGRAM OF IgA SECRETION AND TRANSPORT



Task 16.6. JEJUNUM (transverse section)

Staining: Hematoxylin-eosin
Magnification: 80×, 400×



Designate and color after studying the preparation:

I — mucous membrane:

- 1 — villi;
- 2 — crypts;
- 3 — absorptive cells;
- 4 — goblet cells;
- 5 — lamina propria of the mucous membrane;
- 6 — lamina muscularis of the mucous membrane;

II — submucous membrane:

- 7 — nerve plexus node (Meisner's node);
- 8 — blood vessels;

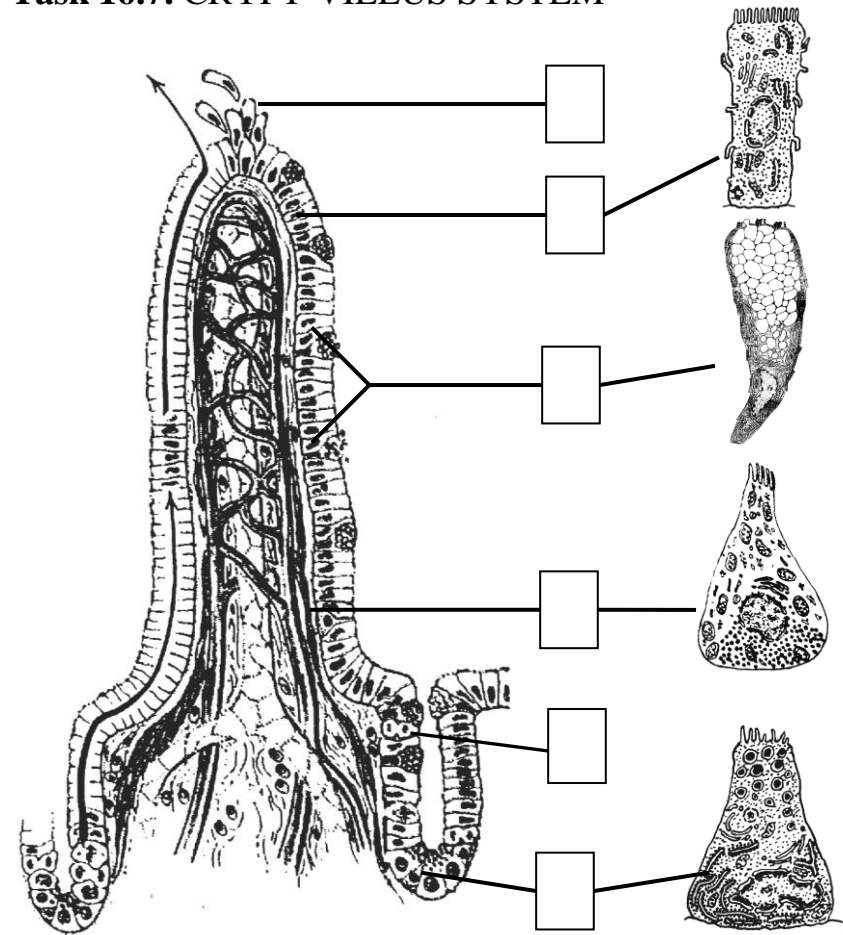
III — muscular membrane:

- 9 — internal circular layer;
- 10 — external longitudinal layer;
- 11 — intermuscular nerve plexus node (Auerbach's node);

IV — serous membrane:

- 12 — connective tissue lamina;
- 13 — mesothelium

Task 16.7. CRYPT-VILLUS SYSTEM



Designate:

- 1 — stem cell of intestinal epithelium (mitosis);
- 2 — absorptive cells; 3 — goblet cell; 4 — Paneth cell;
- 5 — endocrine cell; 6 — fenestrated blood capillaries;
- 7 — lymphatic capillary; 8 — enterocytes exfoliation

Task 16.8. DUODENUM

Staining: Hematoxylin-eosin

Magnification: 80×, 400×

Draw and designate:

I — mucous membrane:

- 1 — villus;
- 2 — crypts;
- 3 — absorptive columnar cells;
- 4 — proper lamina;
- 5 — muscular lamina;

II — submucous membrane:

- 6 — secretory portions of the duodenal glands;

III — muscular membrane:

- 7 — circular layer;
- 8 — longitudinal layer;
- 9 — nerve plexus node;

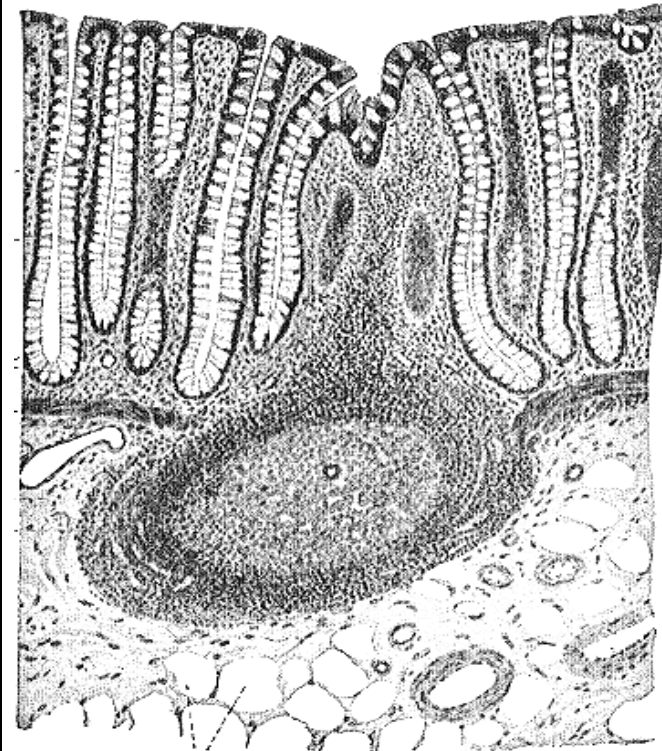
IV — serous/adventitial membrane:

- 10 — connective tissue lamina;
- 11 — mesothelial cell (in case of the serous membrane)

Task 16.9. LARGE INTESTINE

Staining: Hematoxylin-eosin

Magnification: 400×



Designate the cells and structures of mucous membrane:

- 1 — crypts; 2 — absorptive cells; 3 — Goblet cells;
- 4 — proper lamina; 5 — muscular lamina;
- 6 — lymphoid nodule

Task 16.10. THE LINING EPITHELIUM AND GLANDS IN DIFFERENT PARTS OF THE ALIMENTARY CANAL

Fill in the table:

	Part of the alimentary canal	Lining epithelium	Alimentary glands and their localization
1.	Oral cavity		
2.	Esophagus		
3.	Stomach		
4.	Small intestine		
5.	Large intestine		

Correct tasks № _____

Lecturer _____

Date « ____ » _____

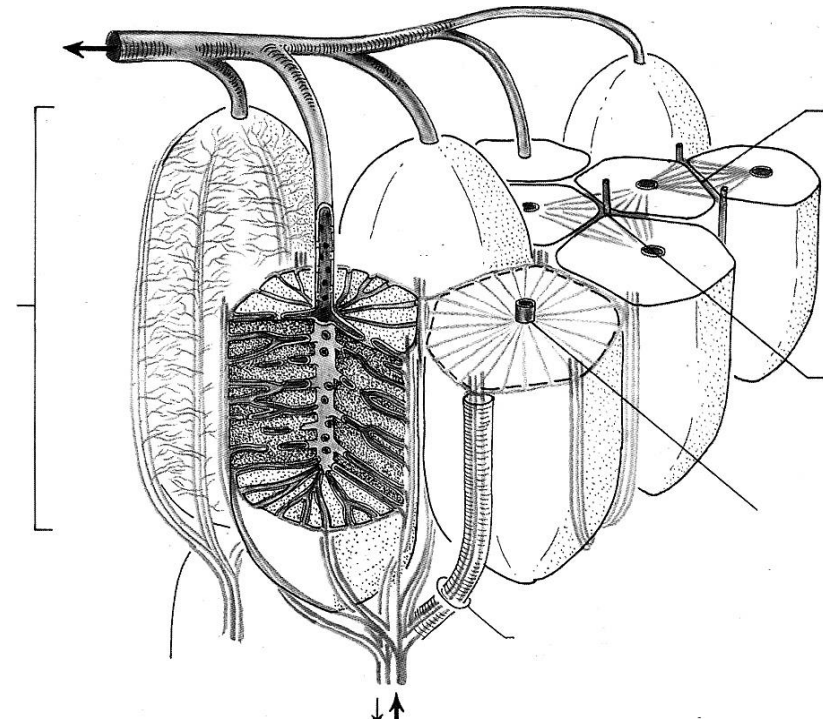
Topic 17. DIGESTIVE SYSTEM. GLANDS

1. Liver: Source of the development, functions, general characteristics, blood supply.
2. Structure of a classic hepatic lobe. The concept of the portal lobe and hepatic acinus.
3. Bile ducts: Structure of the bile ducts and gallbladder.
4. Pancreas: Source of the development, general characteristics.
5. Structure and functions of the exocrine part of the pancreas: lobes, secretory portions, excretory ducts.
6. Pancreatic islets: Structure and functions of the endocrine part of the pancreas.
7. Large salivary glands: Classification, origin of development, structure, functions.

Revise: structure of the exocrine and the endocrine glands.

Home task: 17.1–7.3, 17.5, 17.7, 17.8, 17.10.

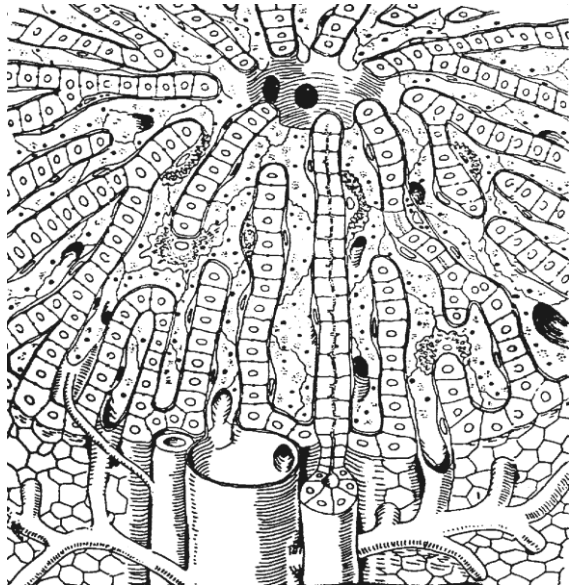
Task 17.1. STRUCTURAL SCHEME OF THE HEPATIC PORTAL LOBE AND ACINUS



Designate:

- 1 — classic hepatic lobe;
- 2 — portal lobe;
- 3 — acinus;
- 4 — portal canal (triads);
- 5 — central vein.

**Task 17.2. SCHEME
OF THE HEPATIC LOBULE**



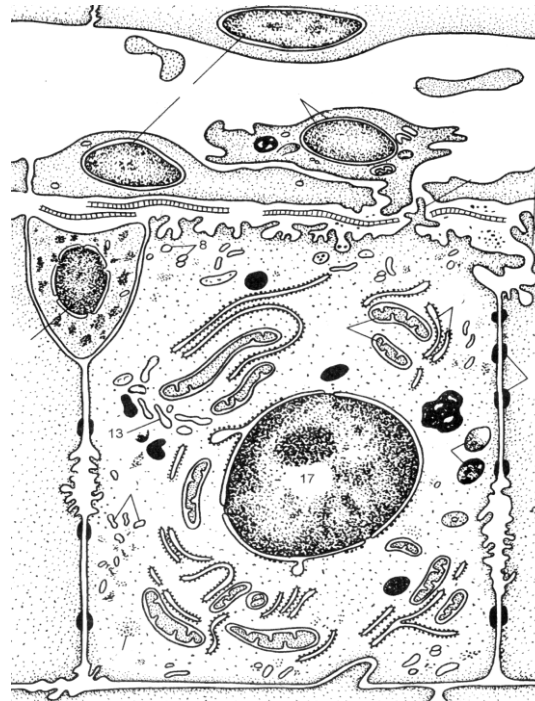
Designate:

- 1 — interlobular vein;
- 2 — interlobular artery;
- 3 — interlobular bile duct and capillaries;
- 4 — central vein.

Colour:

venous flow — in **blue**, arterial flow — in **red**, bile ducts — in **green**

**Task 17.3. ULTRAMICROSCOPIC
STRUCTURE OF THE LIVER**



Designate:

- 1 — hepatic sinusoid;
- 2 — endothelial cells;
- 3 — macrophage;
- 4 — space of Disse;
- 5 — reticular fibers;
- 6 — Ito cell;
- 7 — tight junction (zonula occludens);
- 8 — bile canaliculus

Task 17.4. HUMAN LIVER

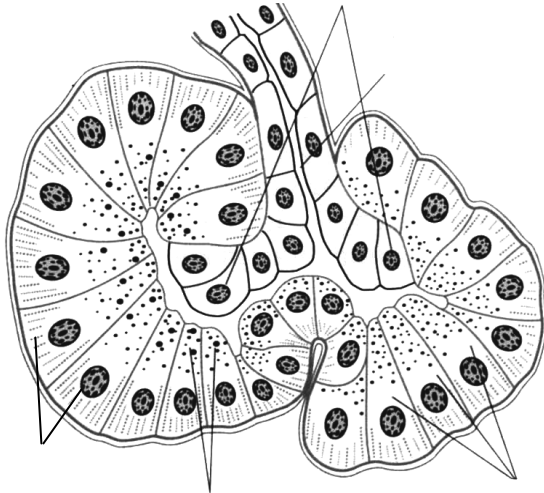
Staining: Hematoxylin-eosin

Magnification: 80×, 400×

Draw and designate:

- 1 — interlobular artery;
- 2 — interlobular vein;
- 3 — interlobular bile duct;
- 4 — central vein;
- 5 — plates of hepatocytes;
- 6 — intralobular sinusoid capillary;
- 7 — endothelial cells

**Task 17.5. SCHEME
OF THE PANCREATIC ACINUS**



Designate:

- 1 — intercalated duct;
- 2 — centroacinous cells;
- 3 — exocrine pancreatocyte;
- 4 — secretory granules in zymogenic area;
- 5 — homogenous area

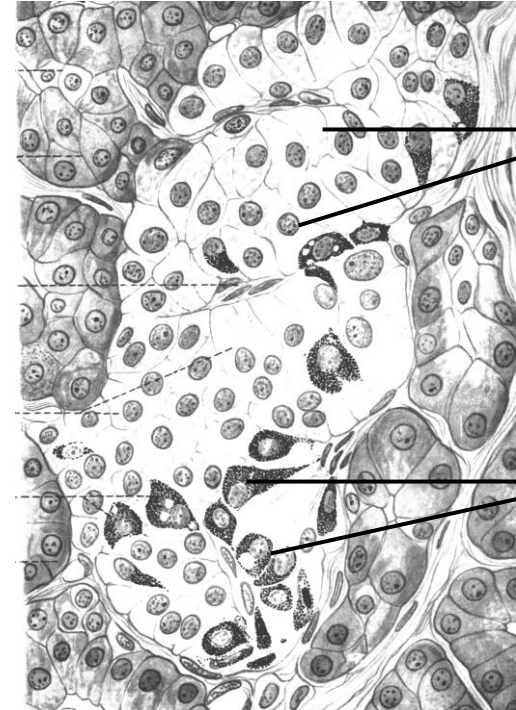Task 17.6. PANCREAS

Staining: Hematoxylin-eosin
Magnification: 80×, 400×

Draw and designate:

- 1 — interlobular connective tissue;
- 2 — interlobular excretory duct;
- 3 — interlobular artery;
- 4 — interlobular vein;
- 5 — acinus:
 - a) homogenous (basophilic) zone of the acinar cells;
 - б) zymogenic (oxyphilic) zone;
- 6 — pancreatic islet;
- 7 — blood capillaries in the islet

**Task 17.7. SCHEME OF THE ENDOCRINE
PART OF THE PANCREAS**



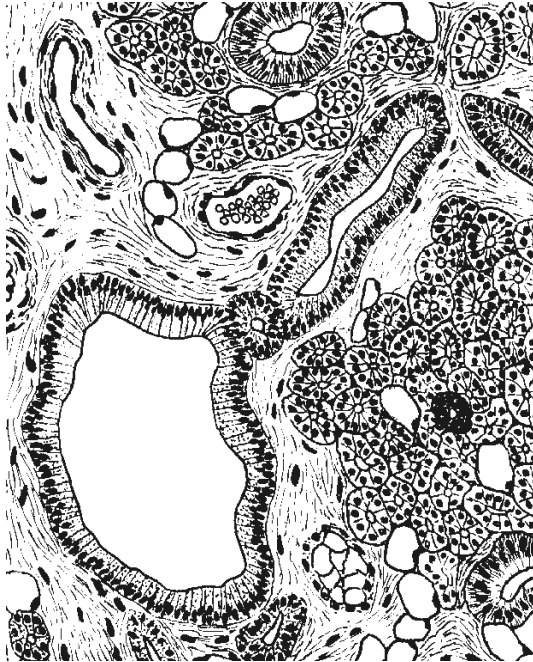
Write hormones:

- β-cells _____
- α-cells _____
- D-cells _____
- D₁-cells _____
- PP-cells _____

Task 17.8. PAROTID GLAND

Staining: Hematoxylin-eosin

Magnification: 80×, 400×



Designate:

- 1 — interlobular connective tissue;
- 2 — interlobular excretory duct;
- 3 — protein secretory portion;
- 4 — intercalated duct;
- 5 — striated duct;
- 6 — blood vessels;
- 7 — adipose cells.

Task 17.9. SUBMANDIBULAR GLAND

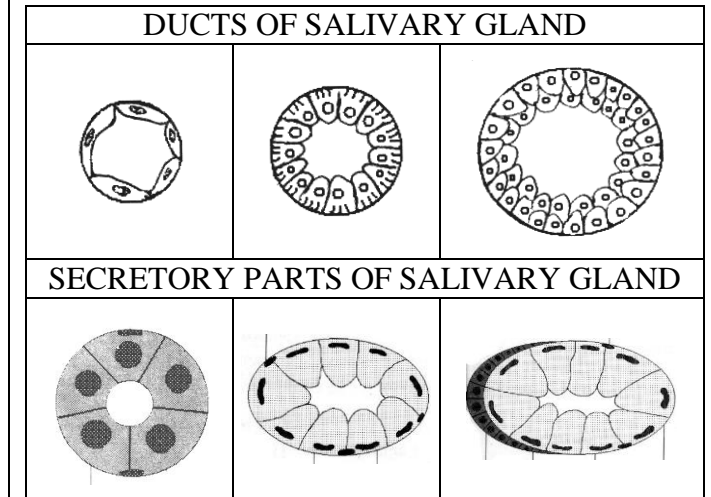
Staining: Hematoxylin-eosin

Magnification: 400×

Draw and designate:

- 1 — serous secretory portion;
- 2 — serous-mucosal secretory portion;
- 3 — serous demilunes;
- 4 — myoepithelial cells;
- 5 — striated duct;
- 6 — interlobular duct;
- 7 — interlobular connective tissue;
- 8 — blood vessel.

Task 17.10. SCHEME OF THE SALIVARY GLAND



Designate:

- 1 — intercalated duct; 2 — striated duct;
- 3 — interlobular duct; 4 — mucous acini;
- 5 — serous acini; 6 — mixed acini;
- 7 — serous demilune; 8 — myoepithelial cell

Correct tasks № _____

Lecturer _____

Date « ____ » _____

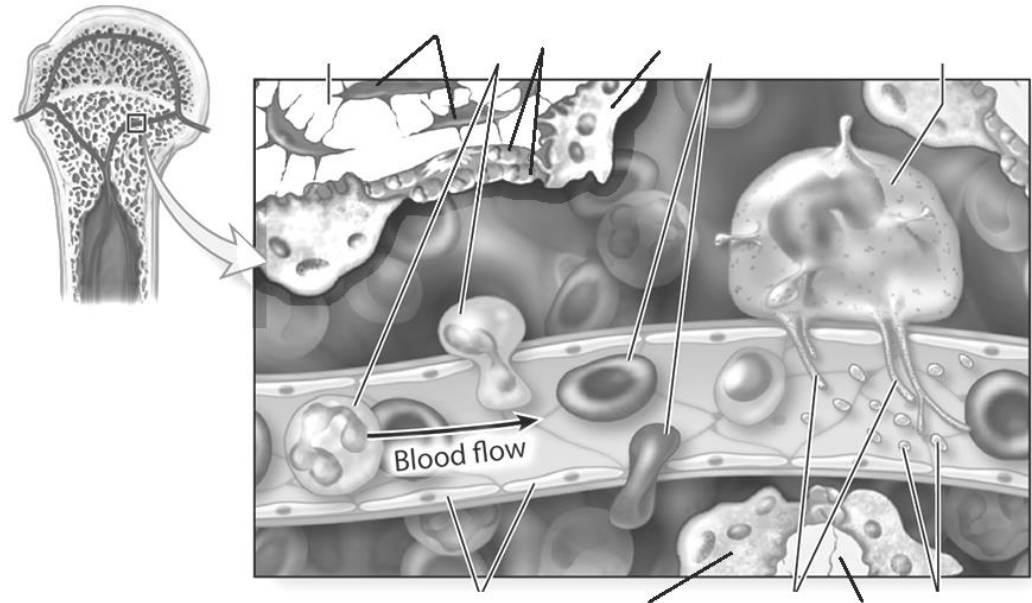
Topic 18. ORGANS OF HEMOPOIESIS AND IMMUNITY (LYMPHOID ORGANS)

1. General morphological and functional characteristics of the hemopoietic and immunity organs. Immune cells.
2. Red bone marrow: development, structure, function. Interaction of the stromal and hemopoietic elements.
3. Thymus: development, structure, function. Blood-thymic barrier. Thymic cells education. Conception of aging and accidental involution.
4. Lymph nodes: development, structure, function. Cortex, paracortex and medulla. T- and B-zones, their localization.
5. Spleen: development, structure, functions, blood supply features. T- and B-zones in white pulp. Red pulp and splenic sinusoids.
6. Lymphoid nodules of the mucous membranes. Appendix. Tonsils. Interaction of epitheliocytes and lymphocytes.

Revise: *leucocytes, lymphopoiesis.*

Home task: 18.1, 18.2, 18.4–18.6, 18.8.

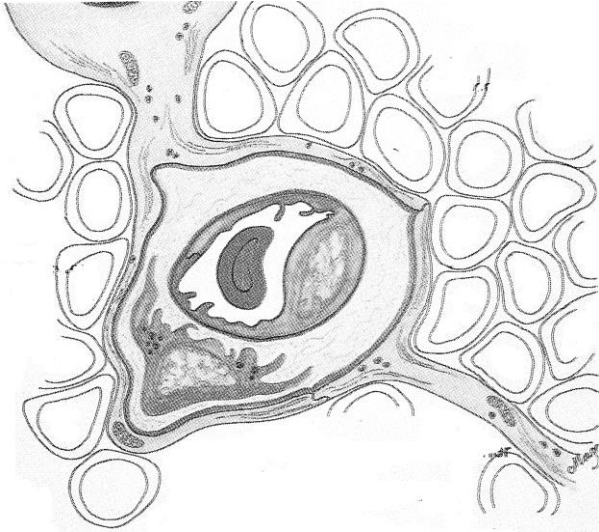
Task 18.1. SCHEME OF THE RED BONE MARROW



Designate:

- 1 — bone trabecula; 2 — osteocyte; 3 — osteoclast;
4 — osteoblast; 5 — leucocytes; 6 — erythrocytes;
7 — megakaryocyte; 8 — thrombocytes (platelets);
9 — pseudopodia of megakaryocyte; 10 — endothelial cell

Task 18.2. ELEMENTS OF BLOOD-THYMIC BARRIER



Color in the scheme:

processes of epithelial reticular cell **in green**; epithelial reticular cells' basal membrane **in red**; capillary basal membrane **in blue**.

Designate:

- 1 — lumen of capillary;
- 2 — capillary basal membrane;
- 3 — endothelial cell; 4 — macrophage;
- 5 — epithelial reticular cell;
- 6 — epithelial reticular cell's basal membrane;
- 7 — thymocytes

Task 18.3. THYMUS

Staining: Hematoxylin-eosin

Magnification: 80×, 400×

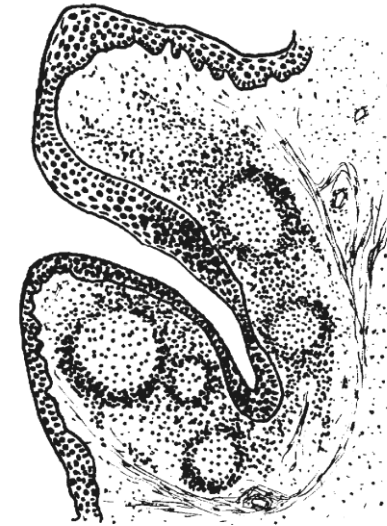Draw and designate:

- 1 — thymic lobules;
- 2 — interlobular connective tissue;
- 3 — cortex;
- 4 — medulla;
- 5 — thymic corpuscle;
- 6 — stromal epithelial reticular cells;
- 7 — blood vessels;
- 8 — thymocytes

Task 18.4. PALATINE TONSIL

Staining: Hematoxylin-eosin

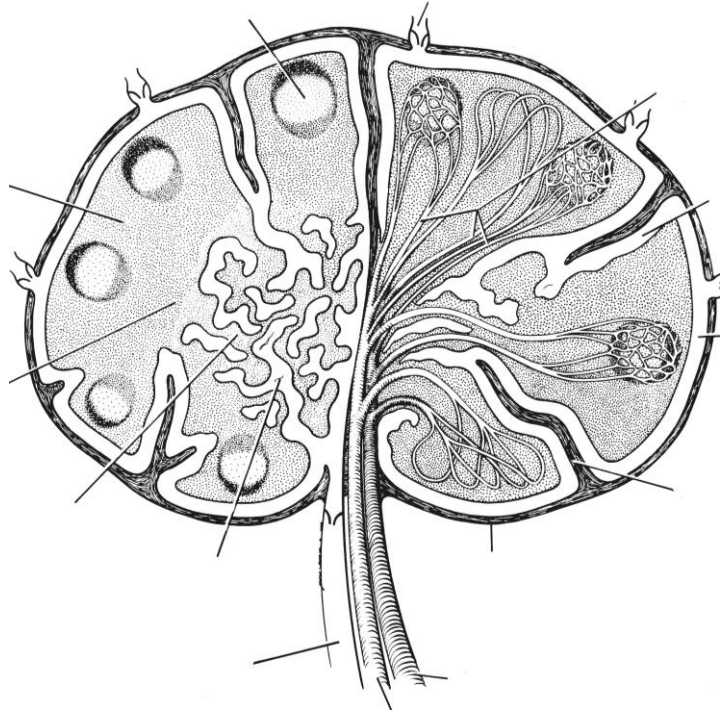
Magnification: 80×, 400×



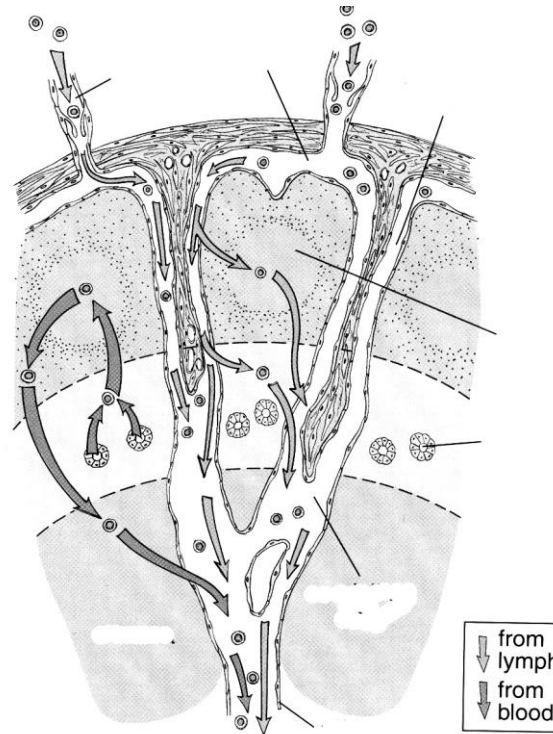
Designate:

- 1 — stratified squamous nonkeratinized epithelium;
- 2 — crypt;
- 3 — subepithelial area;
- 4 — lymphoid nodules;
- 5 — internodular areas;
- 6 — capsule;
- 7 — lymphocytes, infiltrating epithelium;
- 8 — T-zone (internodular and subcapsular);
- 9 — B-zone (nodules and subepithelial area)

Task 18.5. STRUCTURAL ORGANIZATION OF THE LYMPH NODE



Task 18.6. SCHEMATIC DIAGRAM OF LYMPHOCYTE CIRCULATION WITHIN a LYMPH NODE



Task 18.7. LYMPH NODE

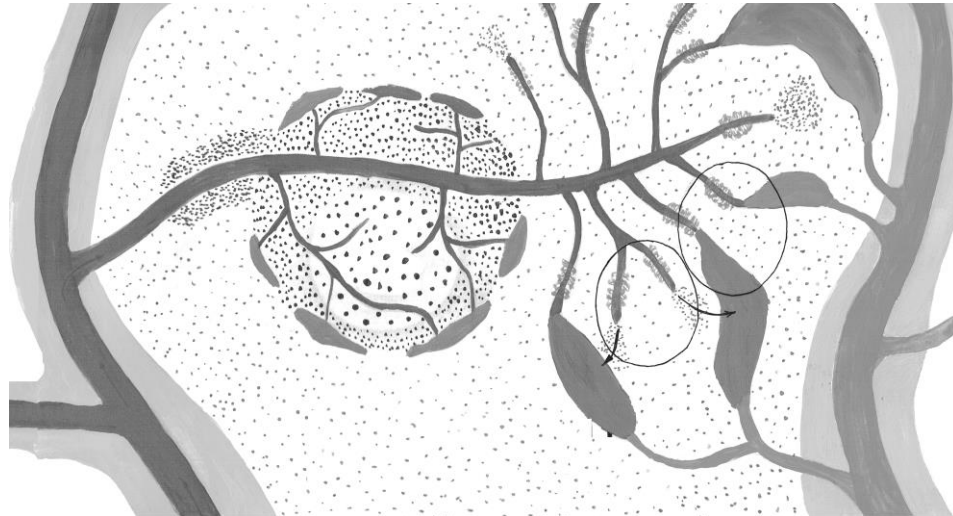
Staining: Hematoxylin-eosin
Magnification: 80×, 400×

Color in the scheme: capsule and trabeculae — **in green**; blood vessels — **in red**; B-area — **in blue**; T-area — **in brown**; lymphatic vessels and sinuses — **in yellow**.

Designate in the tasks 18.5, 18.6, 18.7:

1 — capsule; 2 — trabecular; 3 — subcapsular sinus; 4 — internodular sinus; 5 — medullary sinus; 6 — cortex; 7 — lymphoid nodule: 7a — germinal centre; 7b — mantle zone; 8 — paracortex; 9 — high endothelial venules; 10 — medulla; 11 — medullary cords; 12 — artery; 13 — vein; 14 — afferent lymphatic vessel; 15 — efferent lymphatic vessel.

Task 18.8. STRUCTURAL ORGANIZATION OF THE SPLENIC BLOOD SUPPLY



Designate:

- 1 — trabeculae; 2 — trabecular artery;
- 3 — pulp artery and central artery; 4 — T-zone;
- 5 — B-zone (lymphoid nodule): 5a — germinal center;
- 5b — mantle layer;
- 6 — marginal area with marginal sinuses;
- 7 — penicillar arterioles; 8 — sheathed capillaries;
- 9 — splenic sinusoid in red pulp; 10 — pulp veins;
- 11 — trabecular veins; 12 — open and 13 — close type of blood circulation

Task 18.9. SPLEEN

Staining: Hematoxylin-eosin

Magnification: 80×, 400×

Draw and designate:

- 1 — capsule; 2 — trabeculae; 3 — trabecular artery;
- 4 — trabecular vein; 5 — element of **white pulp**;
- 6 — central artery; 7 — T-area;
- 8 — B-area (lymphoid nodule): 8a — germinal centre;
- 8b — mantle layer; 9 — marginal area; 10 — **red pulp**;
- 11 — lymphocytes; 12 — erythrocytes

Correct tasks № _____

Lecturer _____

Date « ____ » _____

Topic 19. ENDOCRINE SYSTEM

1. General characteristics of the endocrine system. The conceptions of hormones, target cells and hormone receptors.
2. Classification of the endocrine organs. Regulatory mechanisms in the endocrine system.
3. Hypothalamus: Structure, functions. Neurosecretory cells of the nucleus of the hypothalamus.
4. Hypophysis: Source of the development. Cellular structure of the adeno- and neurohypophysis.
5. Hypothalamo-adenohypophyseal and hypothalamo-neurohypophyseal systems.
6. Pineal gland: Structure, function. Role of the pineal gland in the endocrine system.
7. Thyroid gland: Structure, function. Peculiarities of the secretory process in the thyrocytes, its regulation.
8. Parathyroid gland: Structure, function. role in the regulation of the calcium homeostasis.
9. Adrenal glands: Source and stages of development. Structure of the cortex and medulla of the gland. Regulation of the function.
10. Disperse endocrine system: Origin of development, localization. Characteristics of the neuroendocrine cells.

Revise: glandular epithelium.

Home task: 19.1, 19.2, 19.3, 19.6.

COMPONENTS OF THE ENDOCRINE SYSTEM

I. Central part:

- 1.
- 2.
- 3.

II. Peripheral part:

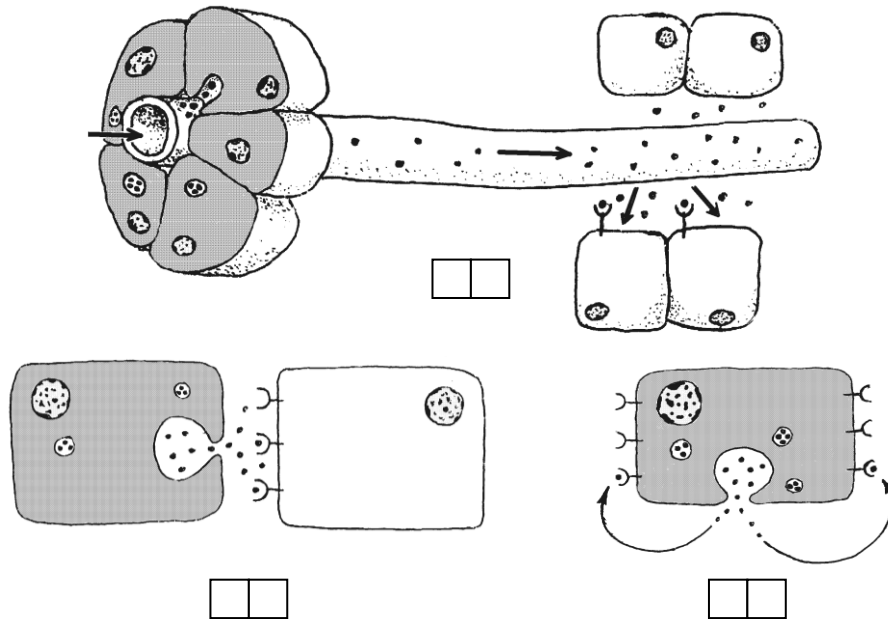
- 1.
- 2.
- 3.

III. The organs with endocrine and non-endocrine functions

- 1.
- 2.

IV. Diffuse (disperse) endocrine system.

Task 19.1. SCHEME OF HORMONAL EFFECTS ON THE TARGET CELLS



Designate:

1 — autocrine; 2 — paracrine; 3 — endocrine (distant) regulation.

Designate with letters:

A — inherent to anuclear embryonic and tumor cells;

B — provide the regulation of the activity level and proliferation processes in the epithelial layer;

C — provide the integral regulation of the whole body

Task 19.2. TERMINOLOGY

Learn the following terms and concepts:

ENDOCRINE — universal method of interaction between cells due to the signal molecules — hormones, produced by the endocrine cells.

HORMONE — a biologically active substance, circulating in the body and indicating the regulatory effect on the target-cells.

TARGET CELL — a cell able to recognize the presence of a hormone by means of a specific receptor and to respond by changing the function mode.

RECEPTORS — genetically determined macromolecules (proteins, glyco- and lipoproteids), localized in different parts of the cell (plasmolemma, cytoplasm, nucleus) and specialized in perceiving biologically important signals of the chemical and physical origin.

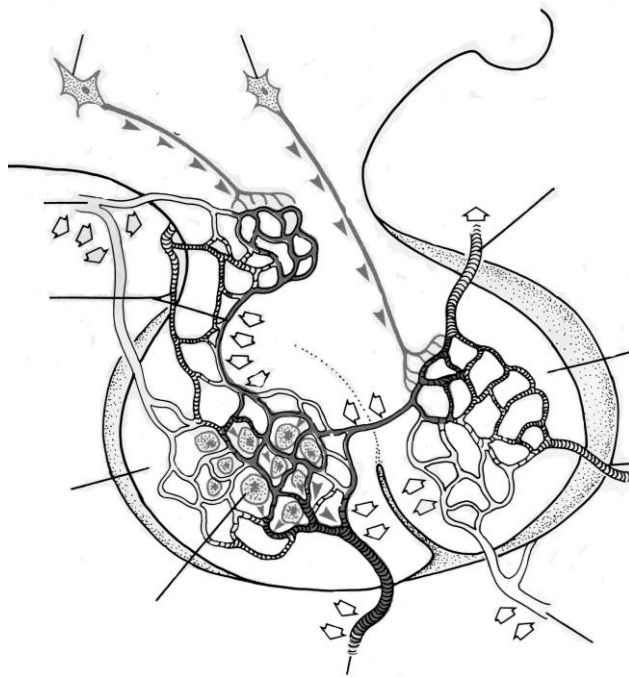
LIGAND — a molecule (hormone, growth factor, cytokine), specifically binding to the receptor.

Give the definition of the terms:

Autocrine — _____

Paracrine — _____

Task 19.3. HYPOTHALAMO-HYPOPHYSIAL SYSTEM



Designate:

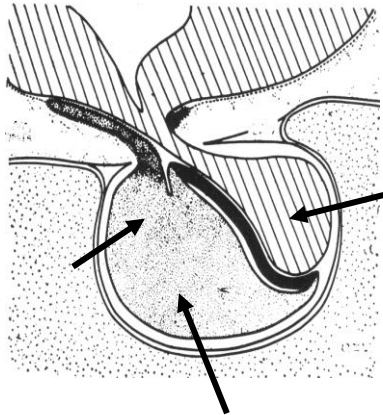
- 1 — neurosecretory cells of anterior hypothalamus;
- 2 — neurosecretory cells of medium hypothalamus;
- 3 — primary capillary plexus;
- 4 — axons of the neurosecretory cell;
- 5 — median eminence;
- 6 — secondary capillaries plexus;
- 7 — cells of adenohypophysis;
- 8 — pars posterior of hypophysis;
- 9 — axovasal synapse

Hormones of adenohypophysis	Target organs	Hormones of neurohypophysis	Target organ
Basophilic cells		1.	
1.			
2.			
Acidophilic cells		2.	
1.			
2.			
Adrenocorticotropocytes			

Task 19.4. HYPOPHYSIS

Staining: Hematoxylin-eosin

Magnification: 400×



Draw and designate:

- I. Anterior lobe:**
1 — pars distalis;
1a — oxyphilic adenocytes;
1b — basophilic adenocytes;
1c — chromophobic adenocytes;
2 — pars intermedia.
II. Posterior lobe

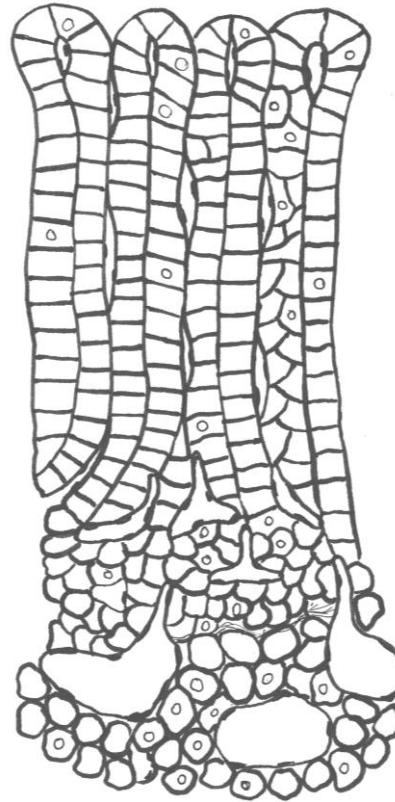
Designate:

- 1 — anterior lobe;
1a — pars distalis;
1b — pars intermedia;
2 — posterior lobe;
3 — hypothalamus

Task 19.5. ADRENAL GLAND

Staining: Hematoxylin-eosin

Magnification: 400×



Regulation of the adrenal gland

1. Zona glomerulosa —

2. Zona fasciculata —

3. Zona reticularis —

Medulla

Draw, designate and enumerate hormones:

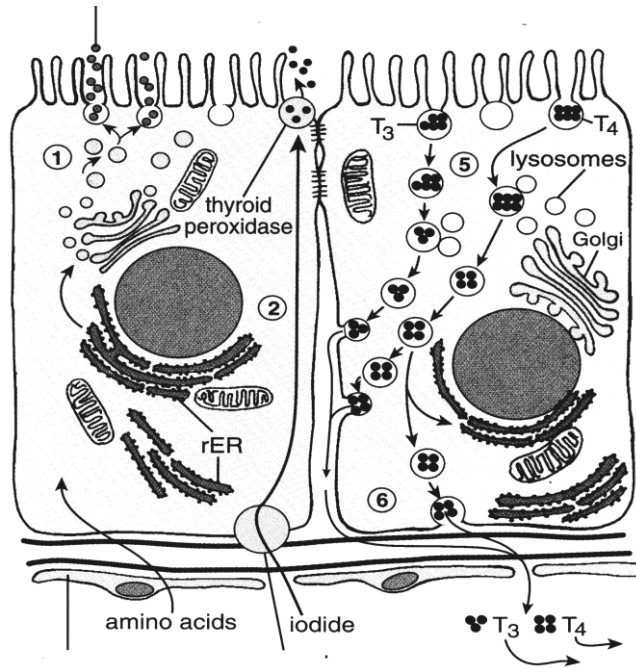
- 1 — capsule;
2 — zona glomerulosa

3 — zona fasciculata

4 — zona reticularis

5 — medulla

Task 19.6. SCHEME OF HORMONOGENESIS IN THE THYROID GLAND



Designate:

- 1 — uptake of circulating iodide;
- 2 — synthesis of thyroglobulin;
- 3 — iodination of thyroglobulin;
- 4 — intrafollicular colloid phagocytosis;
- 5 — fusion of a colloid drop with lysosome;
- 6 — excretion of thyroxin into the capillary;
- 7 — closing lamina (tight junction)

Task 19.7. THYROID AND PARATHYROID GLANDS

Staining: Hematoxylin-eosin
Magnification: 80×, 400×

Regulation of the thyroid gland

Organ _____ Hormones _____
↓
Organ _____ Hormone _____
↓
Organ thyroid gland Hormones _____
↓
Effect on the organ target cells _____ _____ _____ _____

Correct tasks № _____
Lecturer _____
Date « ____ » _____

Designate:

- 1 — glandular capsule;
- 2 — follicular epithelium;
- 3 — interfollicular epithelium;
- 4 — colloid;
- 5 — resorption vacuoles;
- 6 — parathyroid glandular cell cords

Topic 20. NERVOUS SYSTEM. PERIPHERAL NERVOUS SYSTEM. SPINAL CORD

1. General morphological and functional characteristics of the nervous system. Sources of the development.
2. Neuronal theory. Conception of the nerve centers, their classification, principles of the structural organization of the nervous system.
3. Reflex arch, its structural unit. Types of reflex arcs.
4. Peripheral nervous system. Spinal ganglia: sources of the development, structure, function.
5. Peripheral nerve, its structure and regeneration.
6. Autonomous (vegetative) nervous system: extra- and intramural ganglia.
7. Spinal cord. Its development. The structure of the grey and white matter. Neural composition.

Revise the nervous tissue.

Home task: 20.1, 20.5.

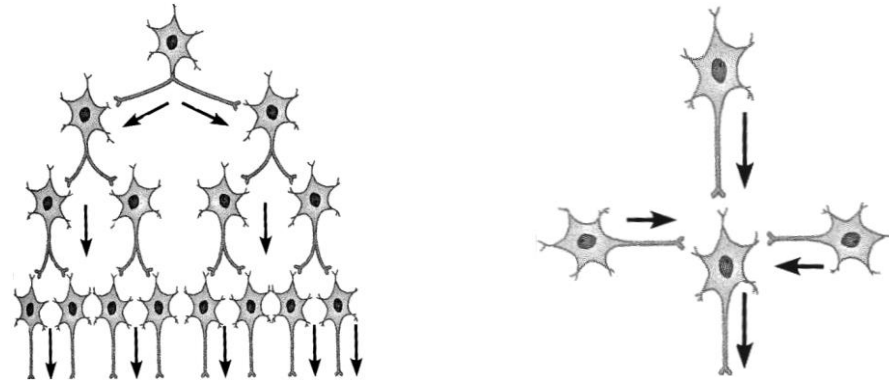
Task 20.1. NEURON INTEGRATION

Interaction between neurons is **neuron integration**.

Neuron integration occurs on the basis of such processes as

DIVERGENCE (A) _____

CONVERGENCE (B) _____



Neuron integration proposes the formation of the **nerve center**.

NERVE CENTER is a structural and functional union of the neurons. Synaptic transmission takes place here.

The nerve centers are divided into a nuclear nerve center and a screen nerve centers.

NUCLEAR NERVE CENTER (*vegetative ganglions in PNS, and nuclei in CNS*)

1. Neurons form compact groups.
2. There are processes of convergence from an afferent system .
3. There is only one type of neuron.

SCREEN (PLAN) NERVE CENTER (*cerebral cortex, cerebellum cortex, retina*)

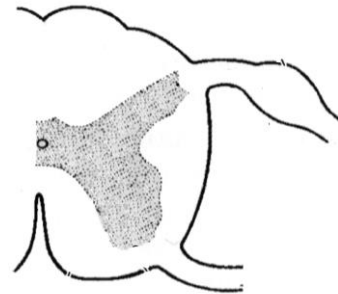
1. Neurons are placed regularly, by layers.
2. There are predominant processes of divergence.
3. There are functionally different types of neurons

Task 20.2. REFLEX ARCS

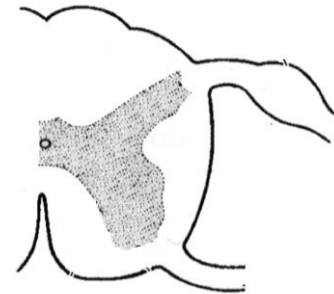
REFLEX ARC is a chain of the neurons, it consists of:

- 1) receptor (dendrite of sensory neurons);
- 2) afferent neurons;
- 3) associative neurons;
- 4) efferent neurons;
- 5) efferent nerve endings (axon of efferent neurons: motor end plate).

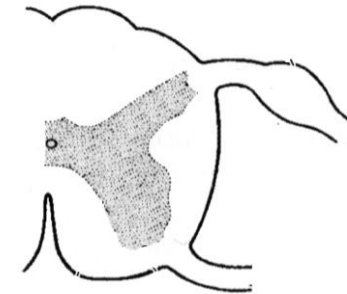
A



B



C



Draw and designate:

A — somatic reflex arc, **B** — sympathetic reflex arcs, **C** — parasympathetic reflex arcs.

- 1 — sensory nerve ending; 2 — sensory neuron of the spinal ganglion; 3 — intercalated multipolar neuron; 4 — motor neurons; 5 — motor nerve endings, 6 — central preganglionic multipolar neuron of the lateral horn nucleus; 7 — efferent multipolar neuron (Dogel I type); 8 — preganglionic fibres (in red); 9 — postganglionic fibres (in blue)

Task 20.3. SPINAL GANGLION

Staining: Hematoxylin-eosin
Magnification: 400×

Draw and designate:

- 1 — pseudounipolar neuron;
- 2 — blood vessels;
- 3 — oligodendroglia nuclei (satellite cell)
- 4 — nerve fibers

Correct tasks № _____

Lecturer _____

Date « ____ » _____

Task 20.4. CROSS SECTION OF PERIPHERAL NERVE

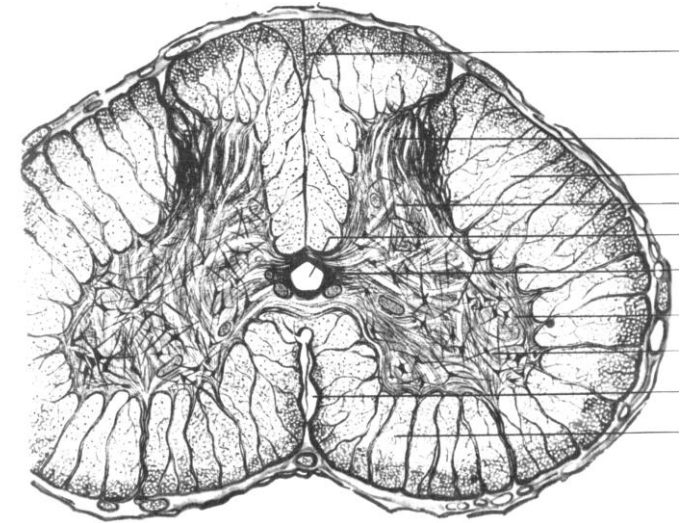
Staining: Hematoxylin-eosin
Magnification: 400×

Draw and designate:

- 1 — bundles of the nerve fibers;
- 2 — endoneurium;
- 3 — perineurium;
- 4 — epineurium;
- 5 — adipose cells.

Task 20.5. SPINAL CORD

Staining: Silver impregnation
Magnification: 400×



Designate:

I — gray matter

- 1 — posterior horn;
- 2 — lateral horn;
- 3 — anterior horn;
- 4 — central channel;
- 5 — neurons in anterior horn;

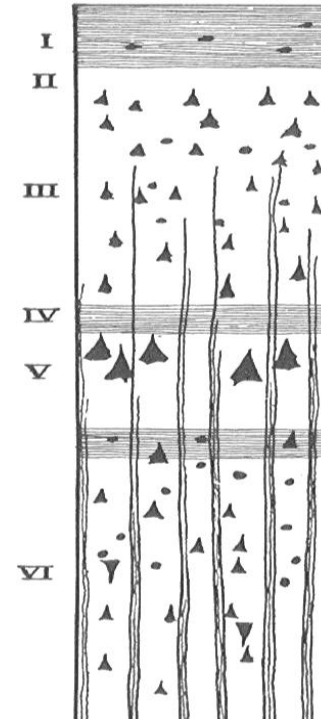
II — white matter

Topic 21. NERVOUS SYSTEM. CENTRAL NERVOUS SYSTEM

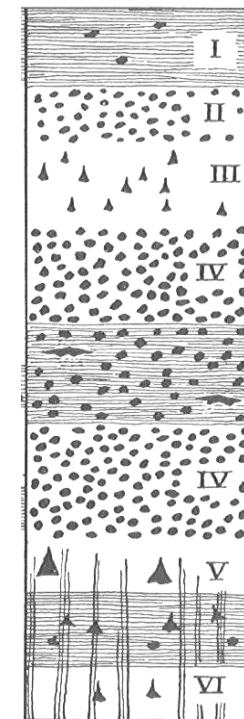
1. Embryonic development of the brain
2. Brain. Cerebral hemispheres. Neuronal organization of the cerebral cortex.
3. Cyto- and myeloarchitecture. Conception of the modules and columns.
4. Cerebellum. Structure and functional characteristics.

Home task: 21.1, 21.3, 21.5, 21.6.

Task 21.1. TYPE OF CORTEX CEREBRAL HEMISPHERES



**Characteristic
of the agranular cortex**



**Characteristic
of the granular cortex**

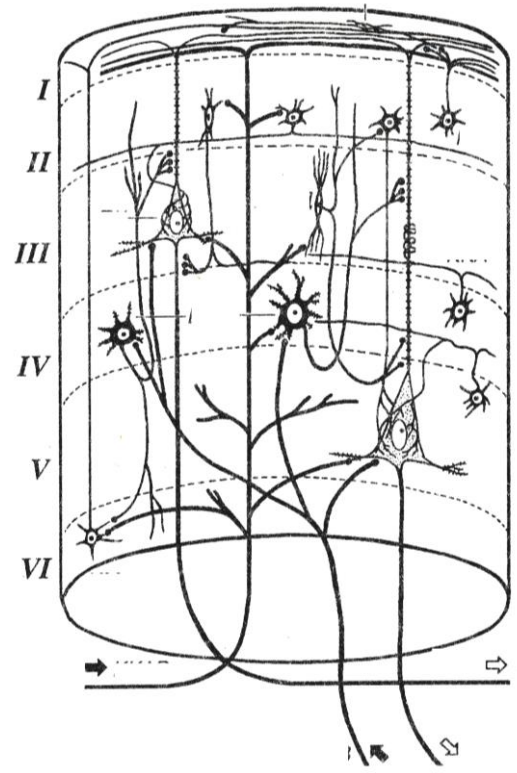
Task 21.2. CEREBRAL CORTEX

Staining: Impregnation with silver
Magnification: 80×, 400×

Draw and designate:

- 1 — molecular layer;
- 2 — external granular layer;
- 3 — external pyramidal layer;
- 4 — internal granular layer;
- 5 — internal pyramidal layer;
- 6 — polymorphic (multiform) cell layer;
- 7 — white matter of the hemispheres

Task 21.3. DIAGRAM OF THE CEREBRAL CORTEX COLUMN (MODULE)



Draw and designate:

- 1 — stellate neuron; 2 — pyramidal neuron; 3 — afferent fibers (**green**);
- 4 — efferent pathway (**red**).

Structural component of the module

Input of the information	
Zone of the information treatment	Inhibition neurons Exciting neurons
Exit of the analyzed information	

Task 21.4. TRANSVERSE SECTION OF CEREBELLUM

Staining: Impregnation with silver
Magnification: 400×

Draw and designate:

I — molecular layer: 1 — basket cell;
2 — stellate cell; 3 — dendrite Purkinje cell;
4 — climbing fibers; 5 — parallel fibers;

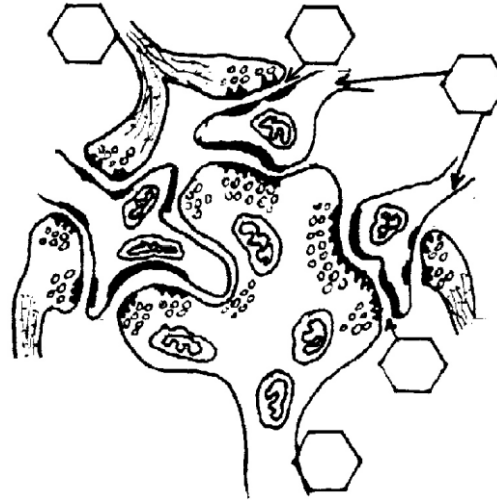II — Purkinje cells layer:

6 — Purkinje cell bodies;
7 — baskets of the nerve fibers;

III — granular layer:

8 — nuclei of granule-cells and Golgi's cells;
9 — mossy fiber

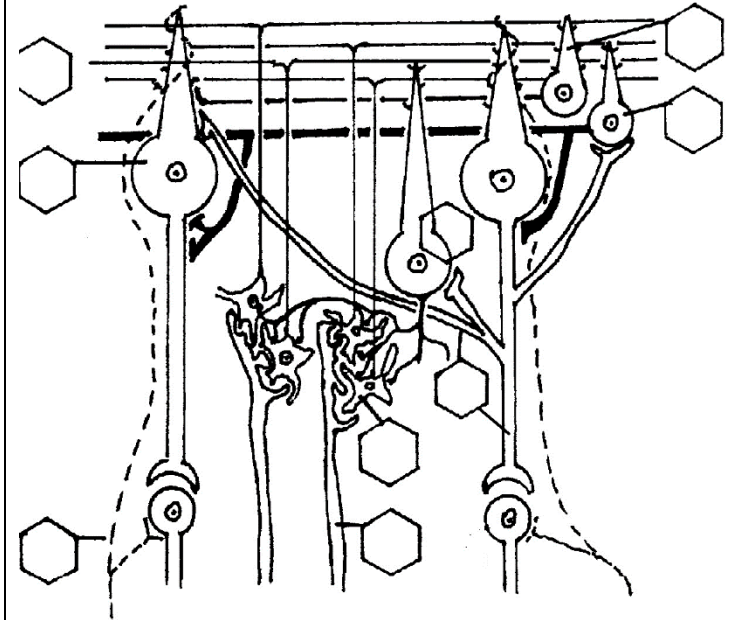
Task 21.5 CEREBELLAR GLOMERULUS



Color and designate:

1 — the rosette of the mossy fibers (**brown**); 2 — dendrites of granule cells (**green**); 3 — the axon of Golgi cells; 4 — exciting axo-dendritic synapse; 5 — inhibition synapse

Task 21.6 INTERACTION BETWEEN NEURONS AND AFFERENT FIBRES IN CEREBELLAR CORTEX (after J. Eccles)



Designate:

1 — Purkinje cell; 2 — basket cell; 3 — stellate cell;
4 — granule cell; 5 — Golgi cell; 6 — climbing fiber;
7 — mossy fiber; 8 — Purkinje cell axons; 9 — parallel fibers of the molecular layer

Correct tasks № _____

Lecturer _____

Date « ____ » _____

Topic 22. SENSE ORGANS

1. Sense organs. General morphological and functional characteristics. Conception of the analyzer, its structure.
2. Classification, structure and cytophysiology of the receptor cells.
3. The organ of smell: structure, sources of development, cytophysiology of neurosensory receptor cells.
4. The organ of vision. Sources of the development and basic stages of the embryogenesis.
5. The main functional apparatuses of the eye. Structure of the refractive and accommodative apparatuses of the eye ball. Their age-specific changes.
6. The receptive apparatus: development, structure, and adaptation of the retina to the level of light. Specialized regions of the retina. Types of neurosensory receptor cells.
7. The organ of taste: source of the development, structure, cytophysiology of the taste receptor cells.
8. The organ of hearing. Morphological and functional characteristics. Sources of the development, structure, cytophysiology of sensoepithelial receptor cells of the spiral organ.
9. The organ of equilibrium. Sources of the development, structure, functions. Morphological and functional characteristic of sensoepithelial receptor cells.

Home task: 22.1, 22.4–22.7.

Definition of Sense organ: _____

The main functional apparatuses of the eye:

1 — refractive apparatus

includes:

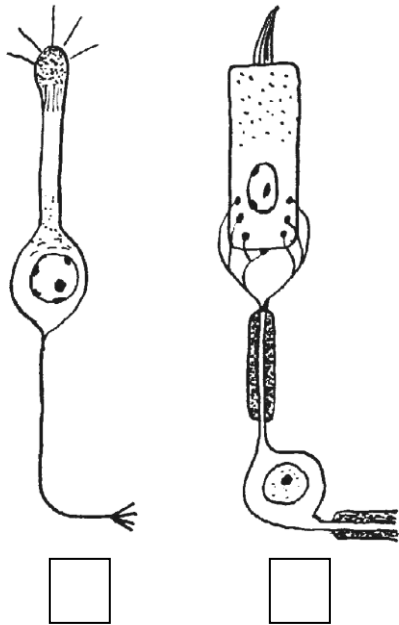
2 — accommodative apparatus

includes:

3 — receptive apparatus

includes:

Task 22.1. RECEPTOR CELLS




Designate neurosensory (1) and sensoepithelial (2) cells.

Indicate their location:

- I. 1 –
- 2 –
- II. 1 –
- 2 –
- 3 –

Task 22.2. CORNEA

Staining: Hematoxylin-eosin
Magnification: 80×, 400×

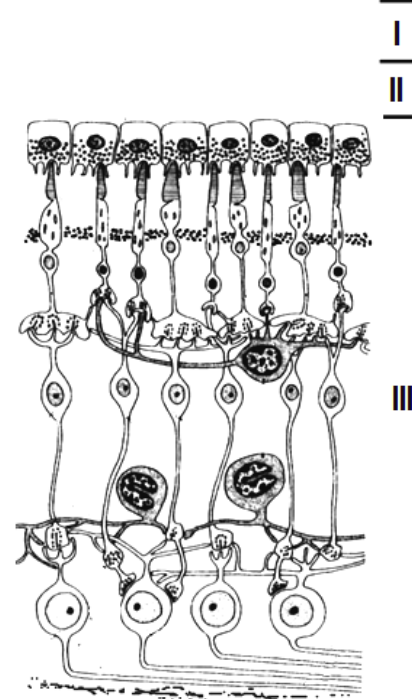


Designate:

- 1 — nonkeratinized stratified squamous epithelium;
- 2 — anterior basement membrane (Bowman's membrane);
- 3 — substantia propria of the cornea;
- 4 — posterior basement membrane (Descemet's membrane);
- 5 — posterior epithelium of the cornea (endothelium)

Task 22.3. POSTERIOR WALL OF THE EYE

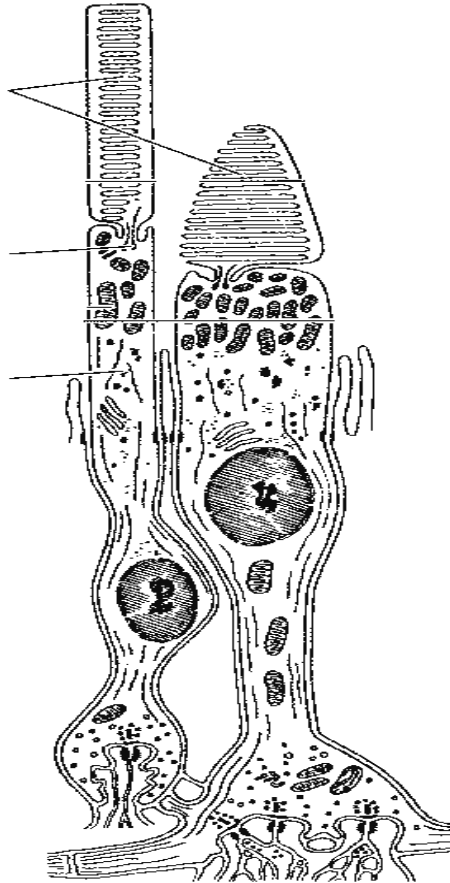
Staining: Hematoxylin-eosin
Magnification: 80×, 400×



Draw eye wall sections (in darkness and in light) and designate in the picture and in the diagram:

- I — sclera; II — choroid:** II a — blood vessels; II b — pigmental tissue; **III — retina:**
- 1 — pigmental epithelium; 2 — layer of rods and cones;
- 3 — external limiting membrane; 4 — outer nuclear layer;
- 5 — outer plexiform layer; 6 — inner nuclear layer;
- 7 — inner plexiform layer; 8 — layer of ganglion cells;
- 9 — nerve fiber layer; 10 — internal limiting membrane

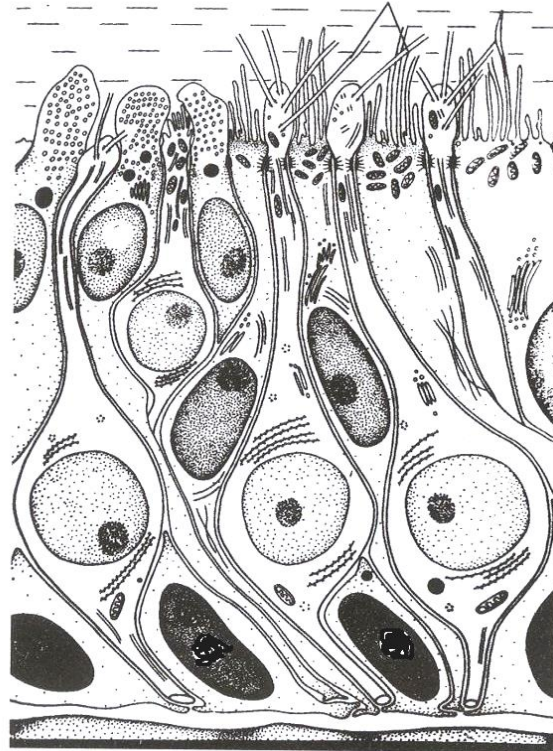
Task 22.4. ULTRASTRUCTURE OF THE ROD AND THE CONE



Designate:

I — rod: 1 — outer segments; 2 — inner segment 3 — mitochondria; 4 — nuclei;
II — cone: 5 — cilium; 6 — synapses with bipolar cells.

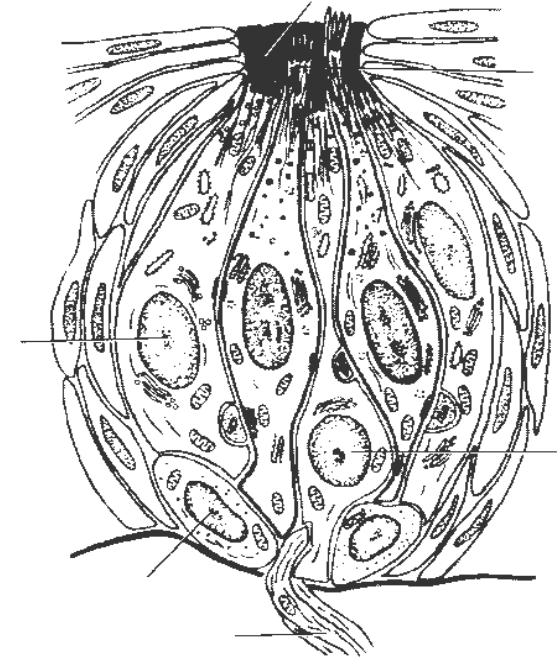
Task 22.5. OLFACTORY AREA OF THE NASAL CAVITY



Designate:

1 — olfactory cell;
 2 — apices with cilia;
 3 — supporting cells;
 4 — microvilli;
 5 — basal cells

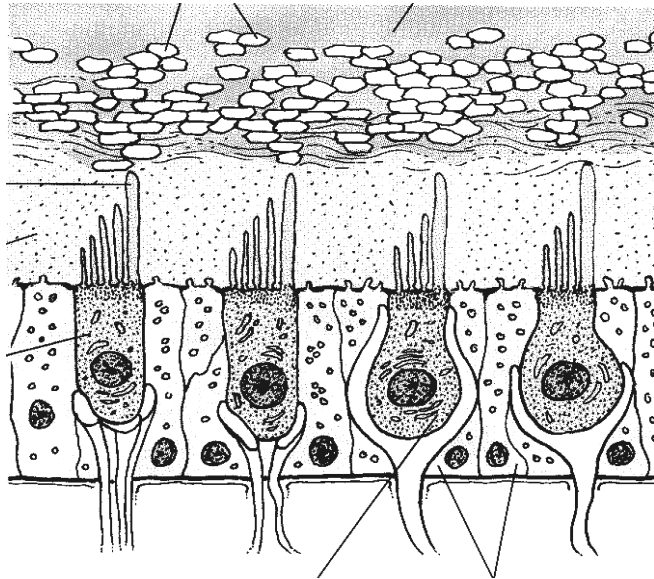
Task 22.6. SCHEME OF A TASTE BUD



Designate:

1 — taste pore;
 2 — microvilli;
 3 — taste cell;
 4 — supporting cell;
 5 — basal cell;
 6 — afferent nerve fiber

Task 22.7. SCHEME OF A MACULA WITHIN THE UTRICLE



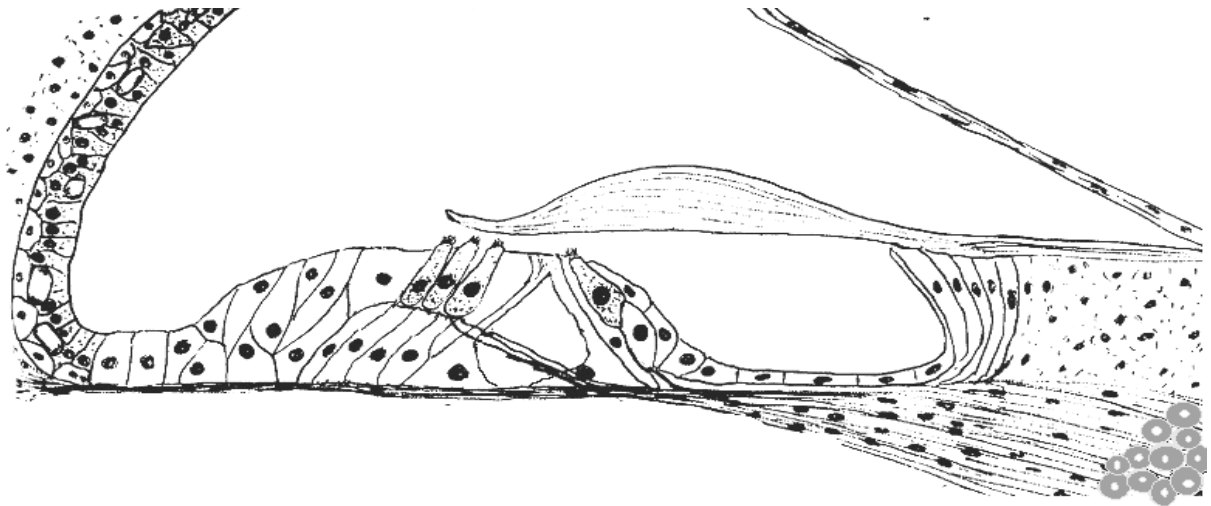
Designate:

- 1 — type I hair (sensory) cell;
- 2 — type II hair cell;
- 3 — supporting epithelial cells;
- 4 — kinocilium;
- 5 — nerve endings;
- 6 — otolithic membrane;
- 7 — otoconia;
- 8 — endolymph

Task 22.8. SPIRAL ORGAN

Staining: Hematoxylin-eosin

Magnification: 400×



Designate:

- 1 — outer hair cells;
- 2 — inner hair cells;
- 3 — outer supporting cells;
- 4 — inner supporting cells;
- 5 — outer pillar cell;
- 6 — inner pillar cell;
- 7 — tunnel;
- 8 — tectorial membrane;
- 9 — basilar membrane;
- 10 — vestibular membrane;
- 11 — epithelium of stria vascularis;
- 12 — capillaries of stria vascularis;
- 13 — spiral ligament;
- 14 — dendrites of receptor neurons;
- 15 — receptor neurons of spiral ganglion

Correct tasks № _____

Lecturer _____

Date « ____ » _____

Topic 23. URINARY SYSTEM

1. The sources of embryonic development and the principal stages of ontogenesis of the kidney (pronephros, mesonephros and metanephros).
2. The structure of the kidney (cortical and medullary substances). Nephrons and urinary tracts. The structure and function of cortical and juxtamedullary nephrons.
3. Histophysiology of the glomerulus. Glomerular filtration barrier, its structural organisation.
4. Histophysiology of different portions of the nephron (proximal part, thin tubule, distal part) and collecting ducts.
5. Renal endocrine complexes and its histophysiology.
6. Blood supply of the kidney. Characteristics of the cortical and juxtamedullary circulation. The lymphatic system of the kidney. Innervation of the kidney.
7. Kidney of a newborn. Age-related characteristics of the kidney.
8. The urinary tract. Development and structure of the renal pelvis, ureter, urinary bladder and urethra. Their functional significance.

Revise:

1. The epithelial tissue.
2. Smooth muscle tissue.

Home task: 23.1–23.5.

The main function of the kidney

The principal stages of embryonic kidney's development:

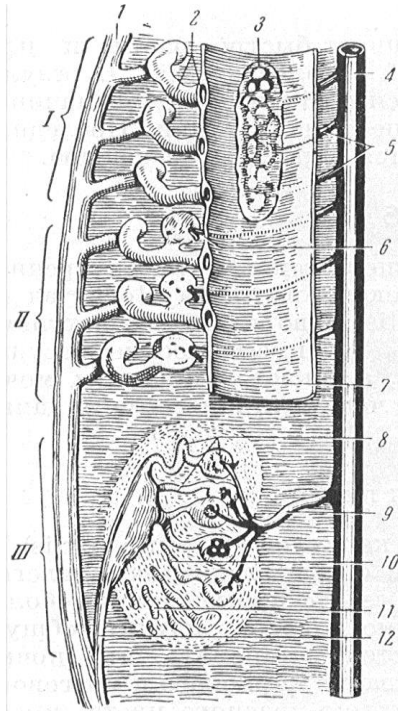
- 1.
- 2.
- 3.

Definition of the term Nephron:

The types of nephrons:

- 1.
- 2.
- 3.

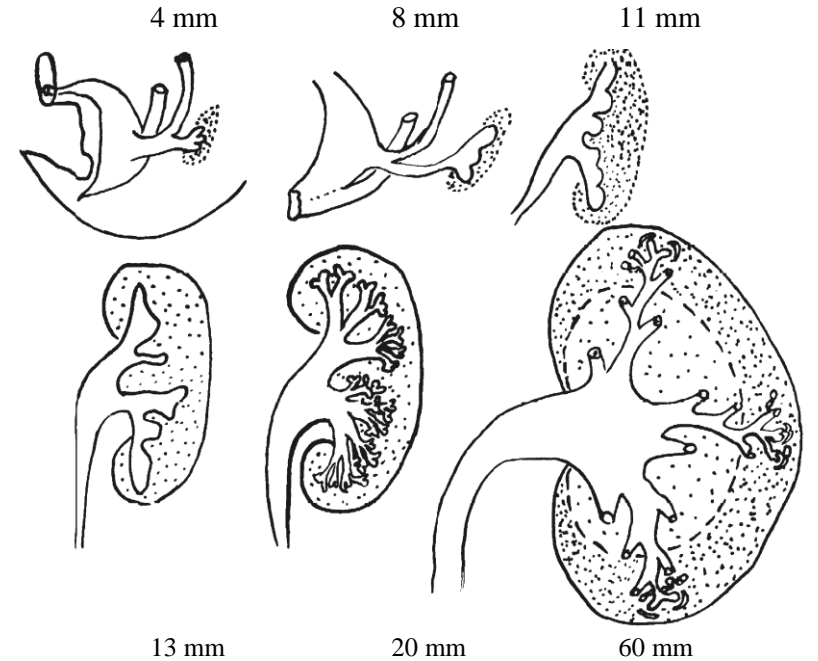
Task 23.1. EMBRYONAL DEVELOPMENT OF A KIDNEY



A. Three generations of the kidneys

Designate and color:

- I — pronephros (**in red**);
- II — mesonephros (**in green**);
- III — metanephros (**in blue**);
- 1 — mesonephric (Wolffian) duct (**in yellow**);
- 2 — aorta;
- 3 — coelom



↑ B. Development of the human metanephros:

Designate and color:

- 1 — cloaca;
- 2 — Wolffian duct;
- 3 — diverticulum of Wolffian duct (**in yellow**);
- 4 — nephrogenic tissue (**in blue**)

Task 23.2. EMBRYONIC SOURCES OF THE URINARY SYSTEM STRUCTURES

Learn the origin of different structures of the kidney

Embryonic sources	Structures of the urinary system
1. Nephrogenic tissue (metanephric blastema)	Epithelium of capsule of the renal corpuscles and nephron tubules
2. Ureteric bud (diverticulum of Wolffian duct)	Epithelium of: 1) collecting and papillary ducts; 2) major and minor calyces; 3) renal pelvis; 4) ureters
3. Mesenchyme	Kidney interstitium (connective tissue), vessels, smooth muscle tissue

Task 23.3. SCHEME OF NEPHRON STRUCTURE

*Designate and color:
in picture A:*

Nephron structures:

- 1 — renal corpuscle;
- 2 — proximal convoluted renal tubule (**in dark green**);
- 3 — proximal straight renal tubule (**in light green**);
- 4 — thin tubule of Henle's loop (**in brown**): a) descending part; b) ascending part;
- 5 — distal straight tubule of Henle's loop (**in grey**);
- 6 — distal convoluted tubule (**in lilac**);

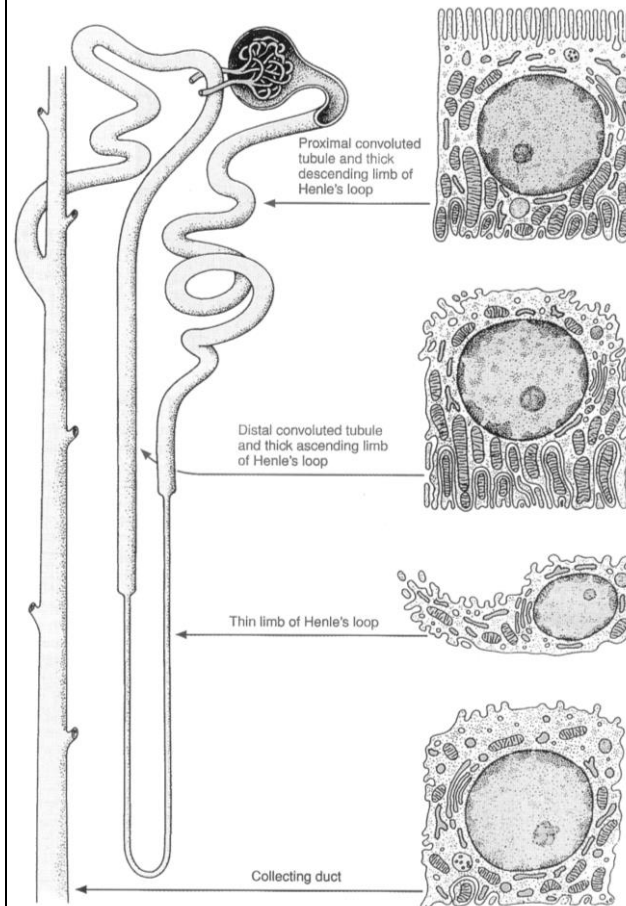
Structures of urinary tracts:

- 7 — collecting duct (**in yellow**).

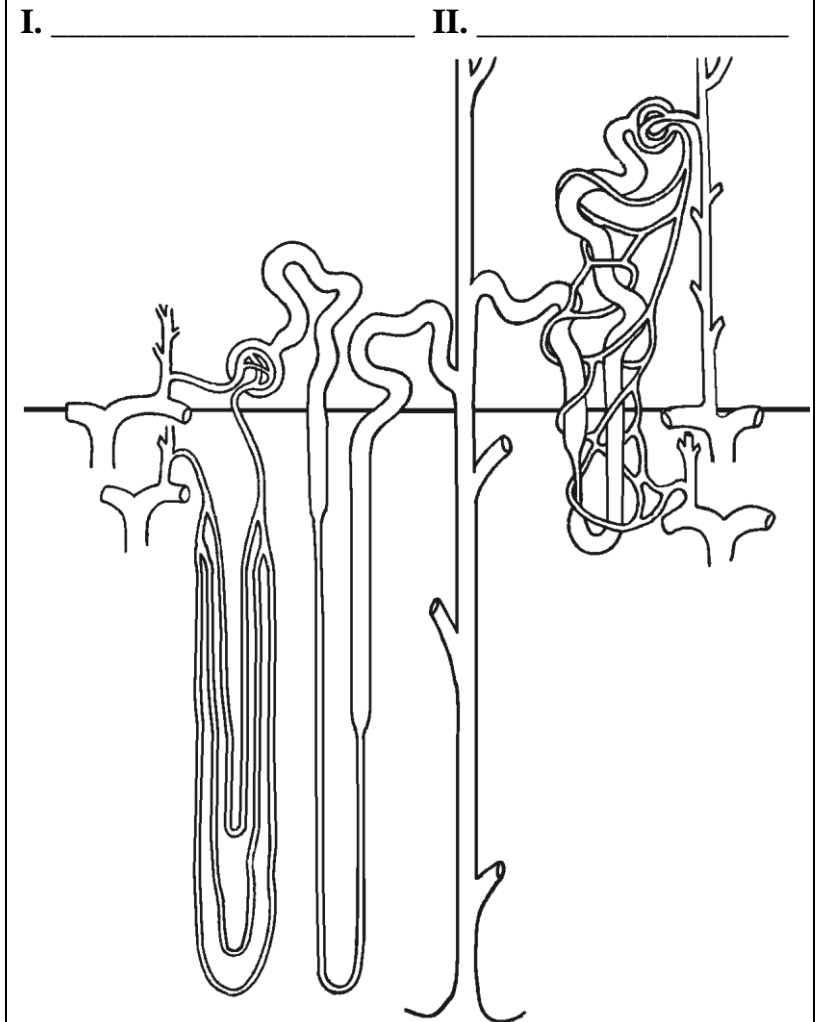
In picture B:

- 1) write down the types of nephrons;
- 2) mark cortical and medullary substances

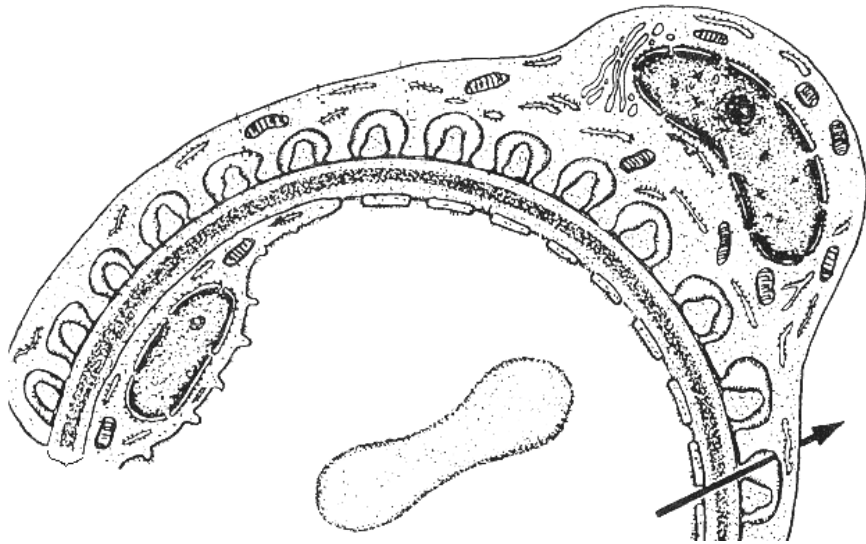
A. Cellular ultrastructure of different parts of nephron



B. Types of nephrons and their blood supply



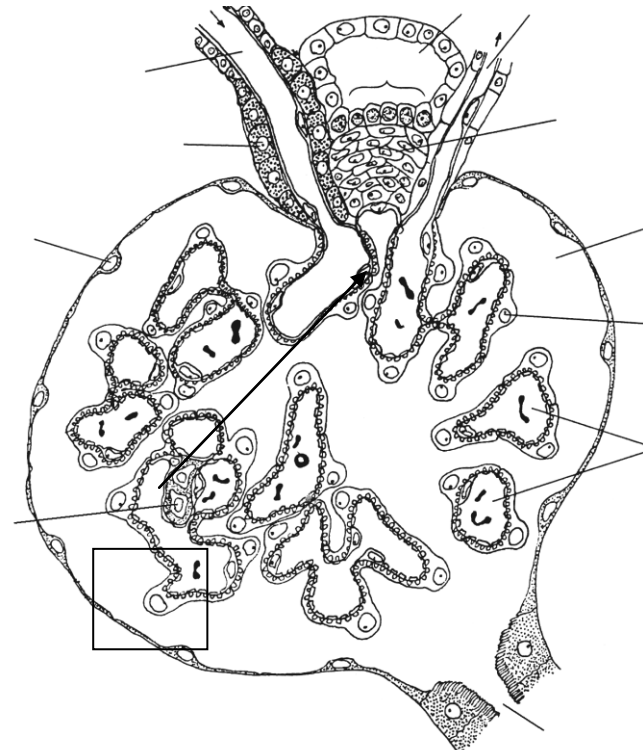
Task 23.4. GLOMERULAR FILTRATION BARRIER
(scheme)



Designate and color:

- 1 — endothelial capillary cells of vascular glomerulus with fenestras (**in pink**);
- 2 — basal membrane (**in yellow**);
- 3 — podocyte of internal layer in glomerular capsule (**in grey**);
- 4 — blood capillary lumen (**in red**);
- 5 — capsule cavity of renal corpuscle (**in green**)

Task 23.5. RENAL CORPUSCLE AND JUXTA-GLOMERULAR APPARATUS (scheme)



Designate and color:

- Vessels — **in red**, capsule cavity — **in green**, juxtaglomerular apparatus units — **in blue**.
- 1 — afferent arteriole; 2 — efferent arteriole; 3 — glomerular capillaries; 4 — parietal layer of glomerular capsule; 5 — visceral layer of glomerular; 6 — capsule cavity; 7 — proximal tubule; 8 — distal convoluted tubule; 9 — juxtaglomerular cells; 10 — cells of macula densa; 11 — juxtavascular cells; 12 — mesangial cells

Task 23.6. KIDNEY

Staining: Hematoxylin-eosin
Magnification: 400×

Draw and designate:

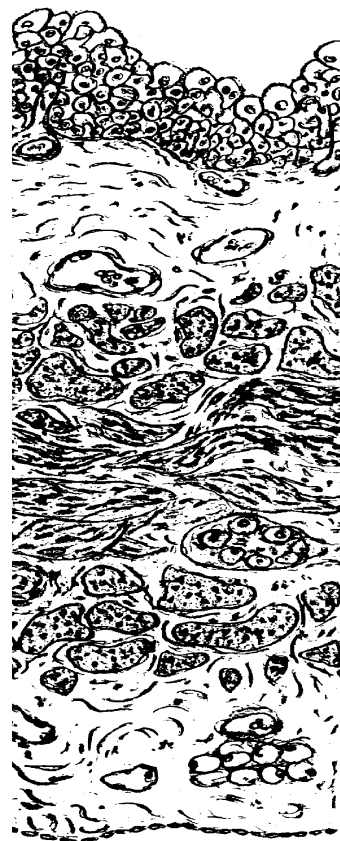Renal corpuscle: 1 — cells of external capsular layer; 2 — capsule cavity;
3 — vascular glomerulus;

Renal tubules: 4 — proximal renal tubule; 5 — brush border of proximal renal tubule cells; 6 — thin tubule of Henle's loop; 7 — distal straight renal tubule; 8 — distal convoluted renal tubule; 9 — collecting ducts.

Vessels: 10 — artery; 11 — vein

Task 23.7. URINARY BLADDER

Staining: Hematoxylin-eosin
Magnification: 80×



Correct tasks № _____

Lecturer _____

Date « ____ » _____

Task 23.8. URETER

Staining: Hematoxylin-eosin
Magnification: 80×

Designate in the tasks Urinary bladder and Ureter:

I — **Mucous membrane:** 1 — transitional epithelium; 2 — proper lamina of mucous membrane.

II — **Submucous membrane:**
3 — blood vessels.

III — **Muscular membrane:** 4 — internal longitudinal layer; 5 — external circular layer; 6 — external longitudinal layer (task 23.7); 7 — nerve intramural ganglion.

IV — **External connective tissue (serous) membrane:** 8 — adipose cells

Topic 24. REPRODUCTIVE SYSTEM. MALE REPRODUCTIVE SYSTEM

1. Male reproductive system, its structure and functions.
2. Development of the male reproductive organs.
3. Testis: development, structure, generative and endocrine functions of the testis. Age-related change. Blood-testis barrier.
4. Spermatogenesis, stages, regulation.
5. Seminal ducts of the male reproductive system: straight tubules, rete testis, efferent ductules, epididymis, ductus deferens, ejaculatory duct. Development, structure, functions.
6. Accessory glands of the male reproductive system: prostate (prostatic gland), seminal vesicles, bulb-urethral glands. Development, structure, functions. Age-related changes. Seminal fluid, composition, functions.

It is recommended to revise:

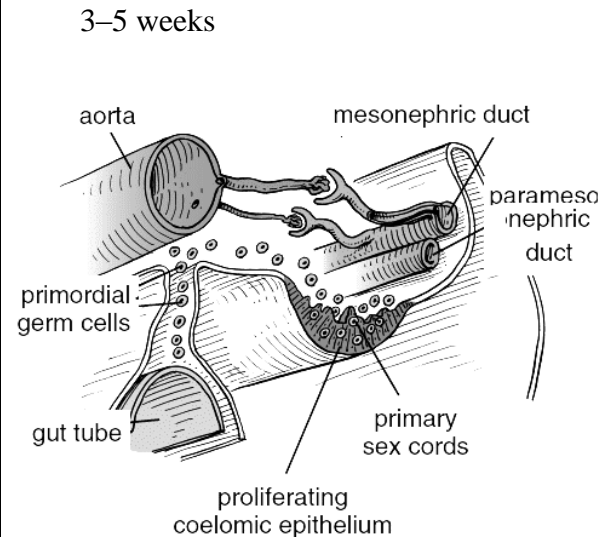
1. Cell division: meiosis.
2. Development of the excretory system.
3. Structural basis of the hypophysis gonadotropic regulation.

Home task: 24.1–24.3, 25.5.

Task 24.1. EMBRYONIC SOURCES OF MALE REPRODUCTIVE SYSTEM

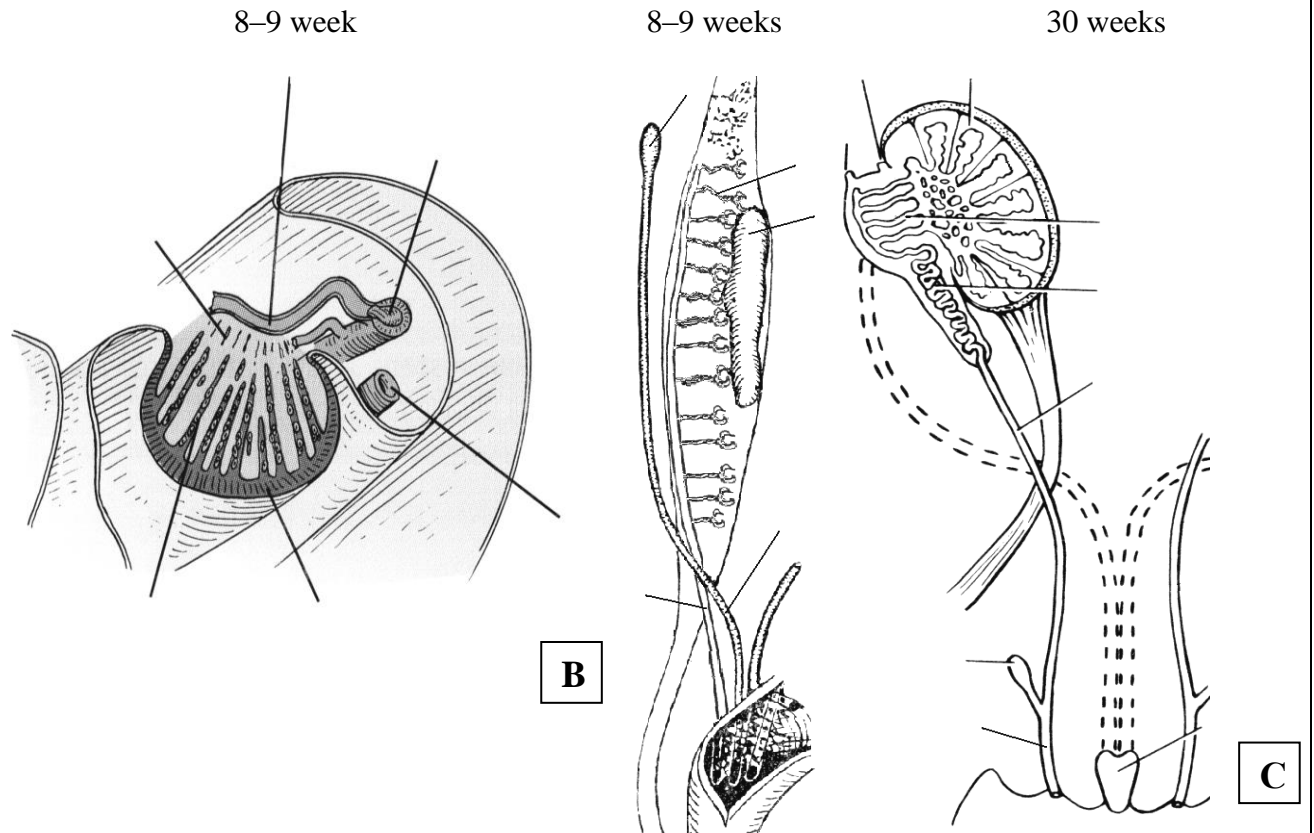
Embryonic source	Structures of male reproductive system
Primary sex cords	1. a) b) 2. 3.
Mesonephric tubule	1.
Mesonephric ducts (Wolf's ducts)	1. 2. 3.
Mesenchyme	1. 2.

Task 24.2. MIGRATION OF GONOCYTES (SCHEME)



A

Task 24.3. DEVELOPMENT OF INTERNAL MALE REPRODUCTIVE ORGANS



B

C

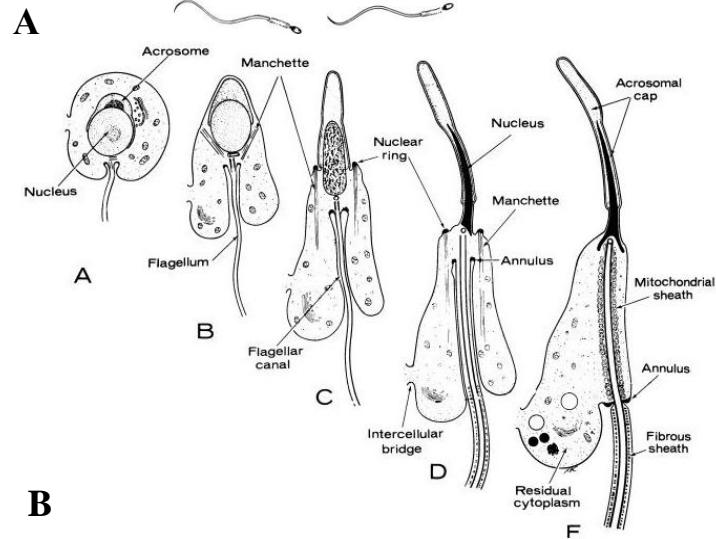
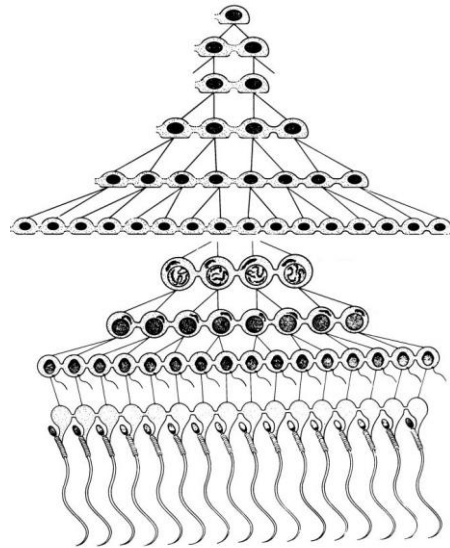
Designate:

- 1— degenerating mesonephric tubule;
- 2 — mesonephric duct;
- 3 — developing rete testis;
- 4 — paramesonephric duct;
- 5 — seminiferous cord;
- 6 — tunica albuginea

Designate:

- 1 — genital ridges; 2 — mesonephric tubules;
- 3 — mesonephric duct; 4 — paramesonephric duct; 5 — testis; 6 — efferent ductules;
- 7 — ductus epididymis; 8 — ductus deferens;
- 9 — ejaculatory canal; 10 — seminal vesicles;
- 11 — prostatic utricle

Task 24.5. SPERMATOGENESIS

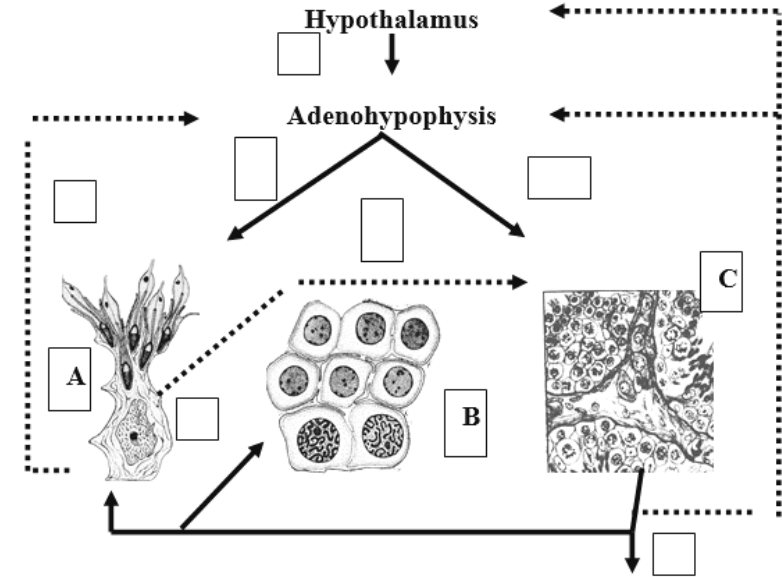


Designate:

- A**
I — proliferation stage (spermatogonial phase):
 1 — spermatogonia type A dark;
 2 — spermatogonia type A pale;
 3 — spermatogonia type B.
II — growth stage:
 4 — primary spermatocytes;
III — maturation stage:
 5 — secondary spermatocytes;
 6 — spermatids;
IV — formation stage (spermatid phase, spermiogenesis).

- B**
 Formation stage includes 4 phases:
 A — Golgi phase;
 B — cap phase;
 C — acrosomal phase;
 D, E — maturation phase

Task 24.6. HORMONAL REGULATION OF MALE REPRODUCTIVE FUNCTION



- A** — Sertoli cell; **B** — spermatocytes; **C** — Leydig cell.
 1. Gonadoreleasing hormone
 2. FSH
 3. LH
 4. ABP
 5. Inhibin
 6. Estrogen
 7. Testosterone

Task 24.7. TESTIS

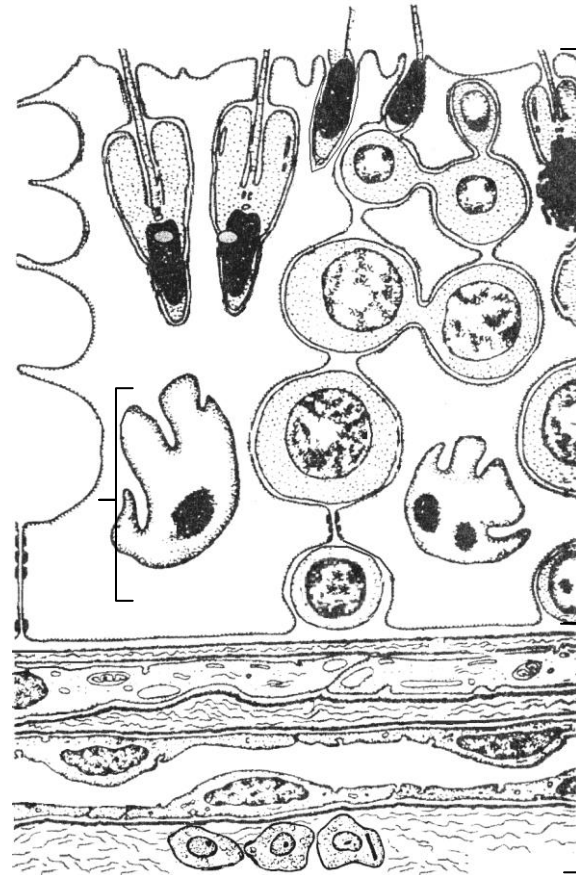
Staining: Hematoxylin-eosin

Magnification: 400×

Draw and designate:

- 1 — mesothelium; 2 — albugineous membrane;
- 3 — connective tissue between tubules;
- 4 — Leydig's interstitial cells; 5 — blood capillaries;
- 6 — basal membrane; 7 — Sertoli's supporting cells (sustentocytes); 8 — spermatogonia; 9 — primary and secondary spermatocytes; 10 — spermatids;
- 11 — spermatozoa at the stage of formation;
- 12 — mature spermatozoa

Task 24.8. STRUCTURE OF THE CONVOLUTED SEMINIFEROUS TUBULE WALL AND BLOOD-TESTIS BARRIER (scheme)



Color and designate:

I — spermatogenic epithelium: basal part — **in yellow**, adluminal part — **in blue**;

- 1 — sustentocytes — **in green**;
- 2 — spermatogonia;
- 3 — primary spermatocytes;
- 4 — secondary spermatocytes;
- 5 — spermatids;
- 6 — spermatozoa.

II — interstitium:

7 — Leydig's interstitial cells (glandulocytes).

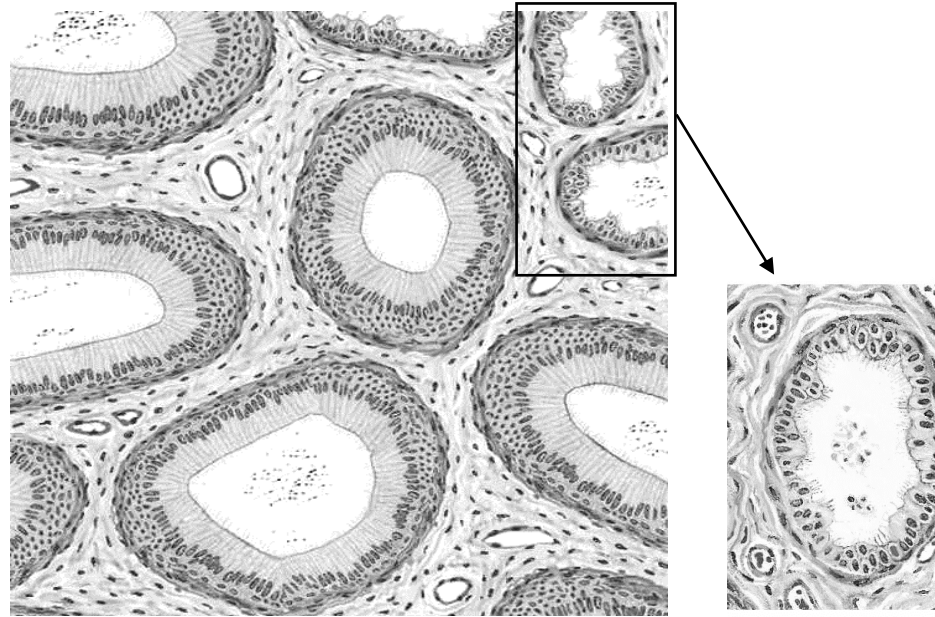
III — structures of blood-testis barrier:

basal membrane — **in orange**, connective (fibrous) coat — **in violet**, myoid layer — **in red**

- 8 — dense contacts between processes of sustentocytes; 9 — basal membrane of spermatogenic epithelium; 10 — basal (internal fibrous) layer; 11 — internal basal membrane of myoid cells; 12 — myoid cells; 13 — external basal membrane of myoid cells; 14 — external fibrous coat; 15 — basal membrane of blood capillary; 16 — endotheliocyte of blood capillary

Task 24.9. EFFERENT DUCTULES AND DUCTUS EPIDIDYMIS

Staining: Hematoxylin-eosin
Magnification: 400×



Colour and designate:

- I — ductuli efferentes
(in the cross-section):
1 — epithelial cells;
2 — fibrous muscular layer.
II — ductus epididymis
(in the cross-section):
3 — epithelium;
4 — muscular elastic layer

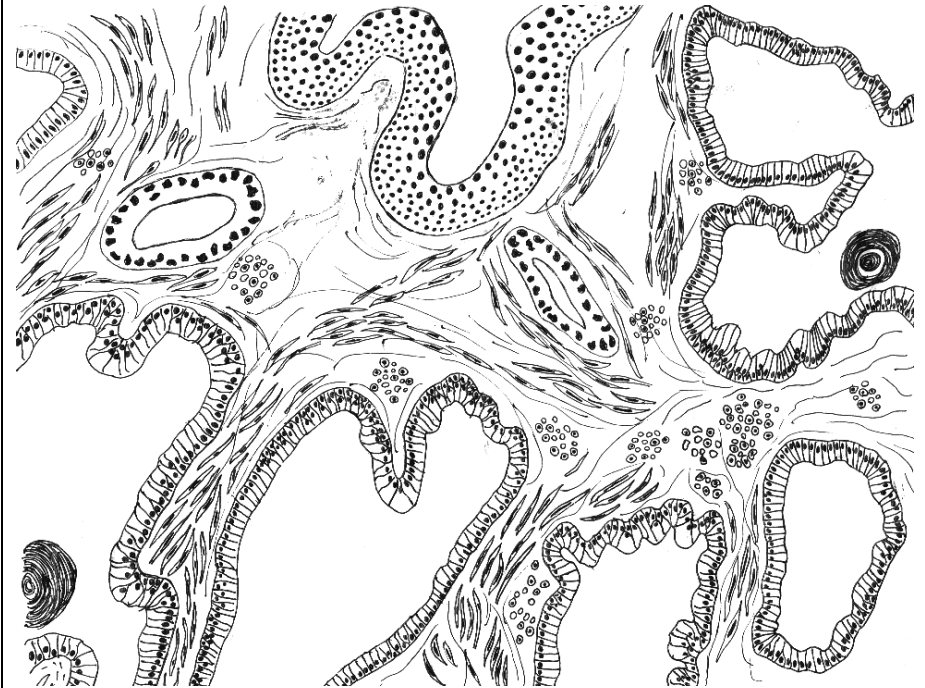
Correct tasks № _____

Lecturer _____

Date « ____ » _____

Task 24.10. PROSTATIC GLAND

Staining: Hematoxylin-eosin
Magnification: 80×, 400×



Colour and designate:

- 1 — secretory portions of the gland;
2 — excretory ducts of the gland;
3 — bands of smooth muscular cells;
4 — connective tissue septa;
5 — blood vessels;
6 — prostatic concretions;
7 — transitional epithelium of the urethra

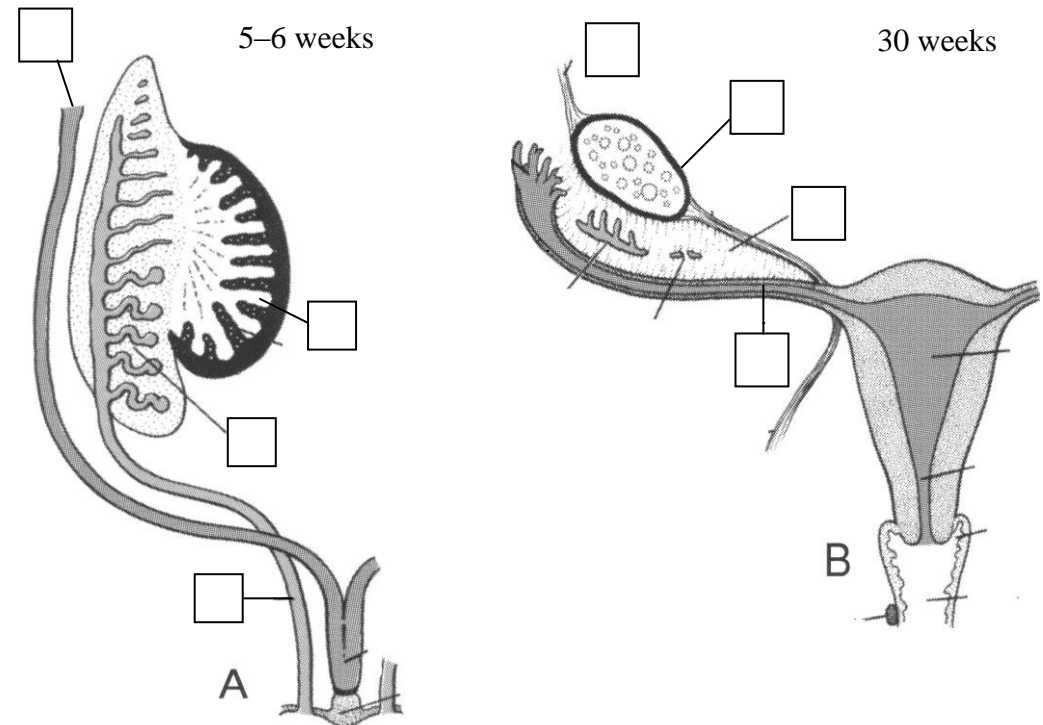
Topic 25. REPRODUCTIVE SYSTEM. FEMALE REPRODUCTIVE SYSTEM

1. Female reproductive system, its structure and functions.
2. Development of the female reproductive organs.
3. Ovary, general characteristics, structural organization of the cortex and the medulla. Age-related changes.
4. Oogenesis, its stages. Differences between oogenesis and spermatogenesis.
5. Ovarian follicles, structure, development. Mature follicle.
6. Ovulation. Development, structure and functions of the corpus luteum.
7. Follicular atresia. Structure of the atretic body.
8. Ovarian cycle and its hormonal regulation. Endocrine function of ovaries, female sex hormones.
9. Uterus, structure, function. Menstrual cycle, its phases. Relationship of cyclical changes in the endometrium and ovary. Age-related changes.
10. Uterine tubes, vagina, structure, functions, cyclic changes of the mucosa membrane.

It is recommended to revise the notes of the lecture "Male reproductive system".

Home task: 25.1–25.3, 25.5.

Task 25.1. DEVELOPMENT OF FEMALE REPRODUCTIVE ORGANS



Designate:

A — Indifferent stage

- 1 — primary sex cord;
- 2 — mesonephric tubule;
- 3 — paramesonephric duct;
- 4 — mesonephric duct

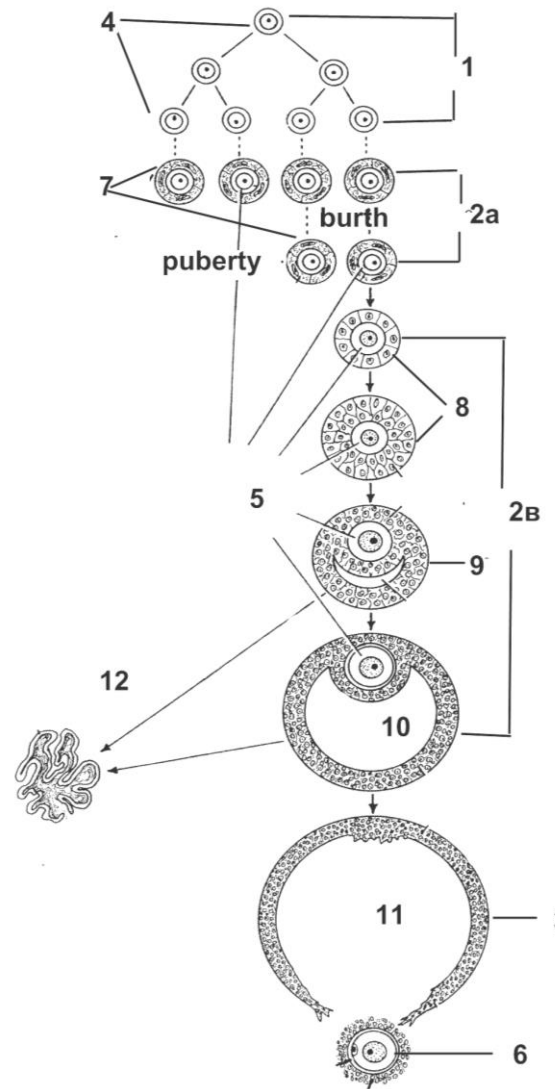
B — Differentiated stage

- 5 — suspensory ligament of ovary;
- 6 — ovary;
- 7 — mesovarium;
- 8 — uterine tube

Task 25.2. DEVELOPMENT OF THE FEMALE REPRODUCTIVE SYSTEM

Embryonic source	Structures of the male reproductive system
Primary sex cords	1. a) b)
Paramesonephric ducts (Mullerian duct)	1. 2. 3.
Mesenchyme	1. 2.

Task 25.3. SCHEME OF OVOGENESIS AND FOLLICULOGENESIS



Designate:

Stage of the oogenesis:

1 —

2a —

2b —

3 —

Name of the germ cells:

4 —

5 —

6 —

Stage of the follicles' development:

7 —

8 —

9 —

10 —

11 — ovulation

12 — atretic body

Task 25.4. OVARY

Staining: Hematoxylin-eosin

Magnification: 80×, 400×

Draw and designate:

I — ovarian membranes:

- 1 — germinal epithelium;
- 2 — albugineous membrane.

II — primordial follicles:

- 3 — primary oocyte;
- 4 — flattened follicular cells.

III — growing (primary) follicle:

- 5 — primary oocyte;
- 6 — zona pellucida;
- 7 — cuboidal follicular cells.

IV — secondary follicle

V — mature follicle:

- 8 — primary oocyte;
- 9 — zona pellucida
- 10 — cumulus oophorus;
- 11 — granulosa layer of cells;
- 12 — corona radiata;
- 13 — antrum with follicular fluid;
- 14 — theca interna;
- 15 — theca externa.

VI — atretic body

VII — corpus luteum:

- 16 — lutein cells;
- 17 — blood capillaries

Task 25.5. UTERINE TUBE

Staining: Hematoxylin-eosin

Magnification: 80×

Designate

Fig. A:

I — mucous membrane:

- 1 — columnar ciliated epithelium;
- 2 — lamina propria of the mucous membrane.

II — muscular membrane:

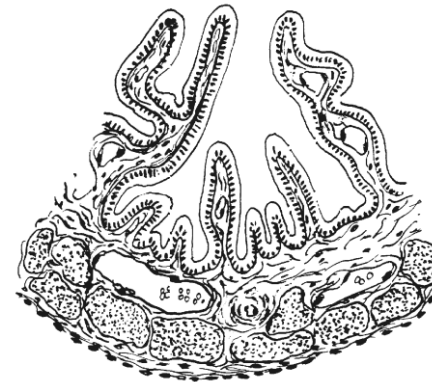
- 3 — circular layer;
- 4 — longitudinal layer.

III — serous membrane:

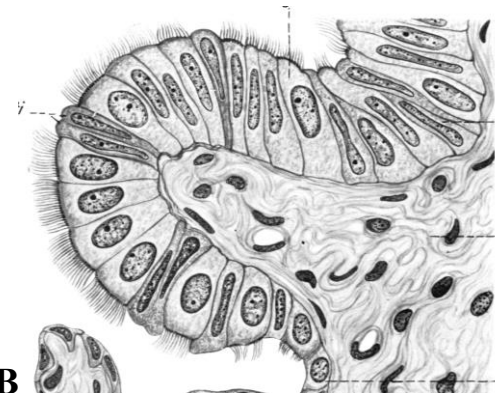
- 5 — connective tissue;
- 6 — mesothelium.

B — columnar epithelium:

- 7 — ciliated cells;
- 8 — nonciliated cells



A



B

Task 25.6. UTERUS OF THE CAT

Staining: Hematoxylin-eosin

Magnification: 80×, 400×

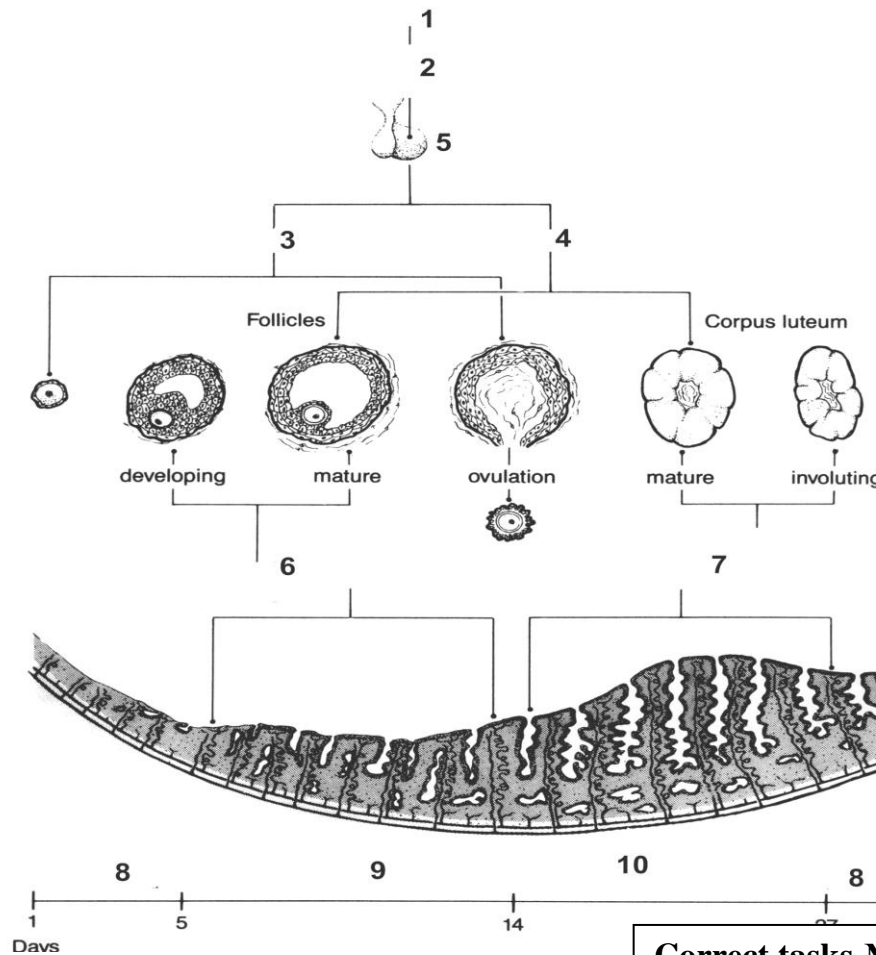
Draw and designate:

I — endometrium:
 1 — columnar epithelium;
 2 — lamina propria of the mucous membrane;
 3 — uterine gland.

II — myometrium:
 4 — submucosal layer;
 5 — vascular layer;
 6 — supravascular layer;
 7 — blood vessels.

III — perimetrium

Task 25.7. OVARIO-MENSTRUAL CYCLE



Write organs and hormones:

- 1 — Hypothalamus
 - 2 —
 - 3 —
 - 4 —
 - 5 —
 - 6 —
 - 7 —
- Name the phase of the menstrual cycle
- 8 —
 - 9 —
 - 10 —

Correct tasks № _____

Lecturer _____

Date « ____ » _____

**Topic 26. HUMAN EMBRYOLOGY. ORGANO- AND HISTOGENESIS.
CRITICAL PERIODS OF DEVELOPMENT**

1. Organo- and histogenesis. Definition.
2. The components and regulation mechanisms of the embryonic development.
3. Embryo by the end of the 3rd – beginning of the 4th week. The primordial formation and the development of the main system organs on the 4th – 8th weeks of the embryogenesis.
4. Critical periods of the development. The highly and low sensitive periods of the development. The role of exo- and endogenous factors in the occurrence of anomalies and malformations.
5. Mammary gland, sources of the development, structure, function. Morphological differences between the lactating and the inactive mammary gland.

Home task: 26.1–26.3, 26.5, 26.6.

Revise:

1. Fertilization
2. Cleavage
3. Gastrulation
4. Differentiation of germ layers.

Task 26.1. Define:

The type of human oocyte:

- 1) _____
- 2) _____

Fertilization is _____

The phases of fertilization:

- 1) _____
- 2) _____
- 3) _____

Cleavage is _____

The type of cleavage:

- 1) _____
- 2) _____
- 3) _____

The type of blastula — _____

Gastrulation is _____

The mechanisms of gastrulation:

- 1) _____
- 2) _____

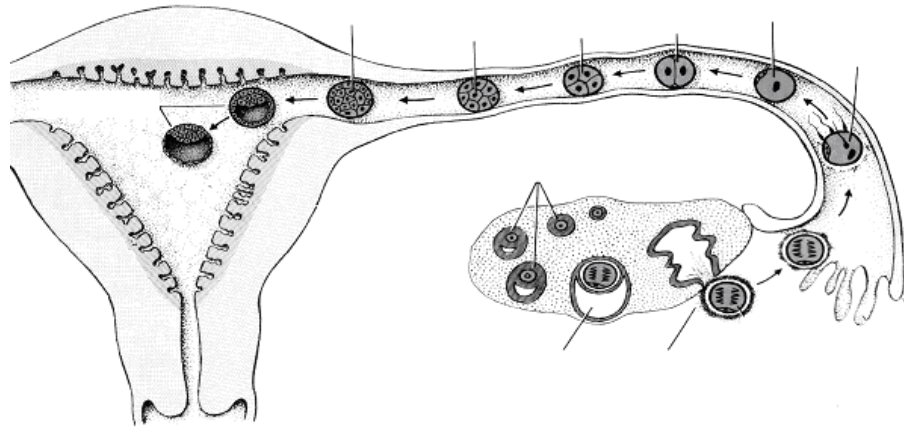
Organogenesis _____

Histogenesis _____

Task 26.2. SCHEME OF CONCEPTUS MIGRATION
(the first week)

Designate:

1 — immature follicles; 2 — mature follicle; 3 — secondary oocyte during ovulation; 4 — fertilization; 5 — zygote; 6 — two-cell stage (30 hours); 7 — four-cell stage (40–50 hours); 8 — eight-cell stage (60 hours); 9 — morula; 10 — blastocyst



Task 26.3. PERIODS OF HUMAN EMBRYOGENESIS AND PHASES OF THE MENSTRUAL CYCLE

Learn:

Period of embryogenesis	Organism	Time of embryonic development	Days of a menstrual cycle
Fertilization		1 st day	14 th –15 th
Cleavage		2 nd –5 th day	16 th –19 th (beginning of secretory phase)
Gastrulation early	Conceptus	6 th –13 th day	20 th –27 th (middle of a secretory phase, secretion of the corpus luteum, implantation)
late	Embryo	14 th –21 st day	28 th –35 th (beginning of placentation, absent of a menstrual flow)
Organo- and histogenesis		4 th –8 th week	≥ 36 th (following development of the placenta)
	Fetus	9 th –38 th (40 th) week	

Task 26.4. LATERAL AND AMNIOTIC FOLDS OF CHICKEN'S EMBRYO

Staining: Hematoxylin

Magnification: 80×, 400×

Designate:

1 — ectoderm; 5 — nephrotome; 8 — forming intestine;
 2 — neural tube; 6 — layers of mesoderm 9 — blood vessels;
 3 — notochord; (splanchnotome); 10 — amniotic fold;
 4 — somite; 7 — endoderm; 11 — lateral fold

The definition of the concept “CRITICAL PERIODS OF THE DEVELOPMENT”: _____

The reasons of the critical periods:

1. Activation of genetic information (determination of the development).
2. Changes of the trophic types.
3. Changes of regulating mechanisms in the course of the development.

A

Task 26.5. CRITICAL PERIODS OF DEVELOPMENT (CPD) IN ONTOGENESIS

A — write down the definition of CPD;
 B — enumerate CPD of the human ontogenesis;
 C — write down the processes and periods of high and low sensitivity of the developing organism

Enumerate the critical periods of the human ontogenesis:

- 1.
- 2.
- 3.
- 4.
- 5.
- 6.
- 7.
- 8.
- 9.
- 10.

B

C

The organism is **highly sensitive** to damaging factors during the processes of

- 1) proliferation;
- 2) differentiation;
- 3) determination.

The process of growth is low sensitive to damaging factors.

The developing organism ...

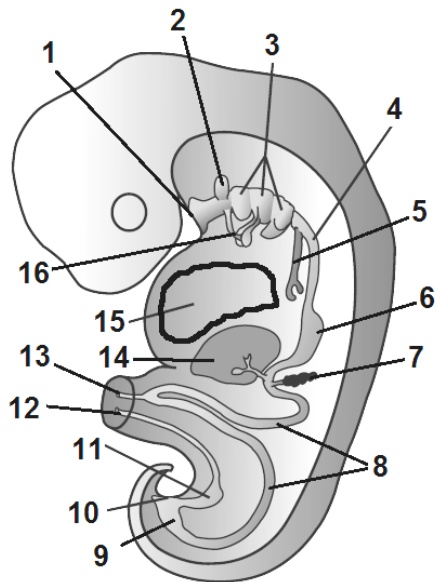
is acted as “all or nothing” to damaging factors during 1–2 weeks.

is highly sensitive to damaging factors during 3–8 weeks.

is low sensitive to damaging factors after 8 week.

Task 26.6. SECTION OF THE EMBRYO AT THE 5th WEEK

Development of the digestive and respiratory systems



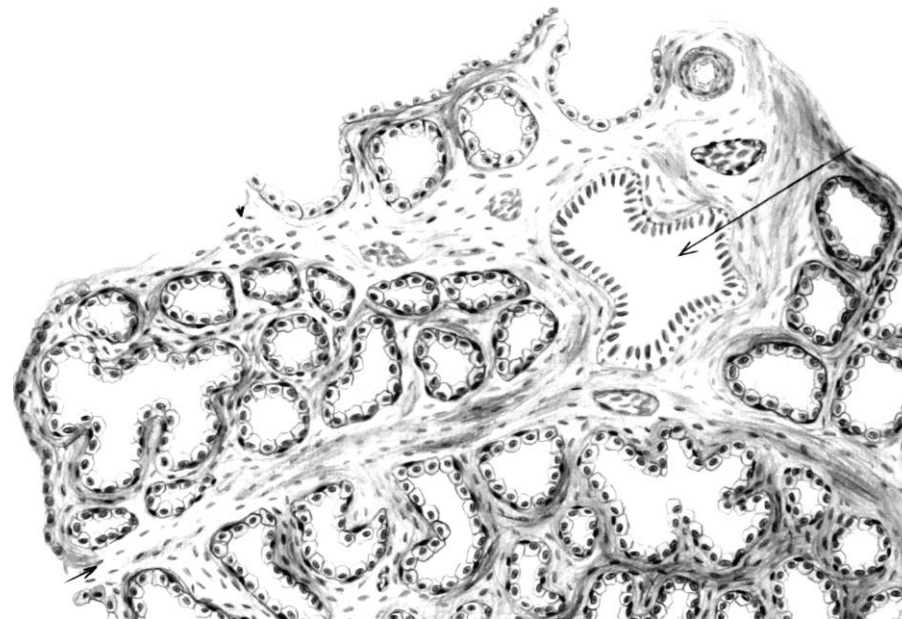
Learn:

- | | |
|--|------------------------------------|
| 1 — oropharyngeal membrane; | 9 — hindgut; |
| 2 — primordia of adenohypophysis; | 10 — cloacal membrane; |
| 3 — pharyngeal porches; | 11 — primordia of urinary bladder; |
| 4 — primordia of the esophagus; | 12 — allantois; |
| 5 — trachea and primordia of the lung; | 13 — vitelline duct; |
| 6 — primordia of the stomach; | 14 — primordia of liver; |
| 7 — primordia of the pancreas; | 15 — heart; |
| 8 — midgut; | 16 — primordia of thyroid gland |

Task 26.7. MAMMARY GLAND

Staining: Hematoxylin-eosin

Magnification: 80×



Draw and designate:

- I — glandular lobe (acinus):** 1 — lumen of secretory parts (alveoli); 2 — lactocytes; 3 — myoepithelial cells;
- II — interlobular septum:** 4 — interlobular connective tissue; 5 — interlobular lacteal duct; 6 — blood vessels

Correct tasks № _____

Lecturer _____

Date « ____ » _____

Topic 27. HUMAN EMBRYONIC DEVELOPMENT. IMPLANTATION. EXTRAEMBRYONIC ORGANS

1. Implantation. Definition. Time. Phases.
2. Differentiation of the trophoblast during the implantation. Changes in the uterus mucosa structure during the implantation.
3. Differentiation of the embryoblast. Formation and functions of the amnion, yolk sac, allantois.
4. Chorion. Structure of the chorionic villi. Chorion frondosum and chorion leave. Development and structure of the fetal membranes.
5. Placenta. Fetal part. Placental barrier. Structure and functions.
6. Placenta. Maternal part. Functional layer of the endometrium during pregnancy. Decidua basalis, capsularis and parietalis. Topography of the fetus and its membranes in the uterus during pregnancy.
7. Functions of the placenta.

Home task: 27.1–27.4, 27.6.

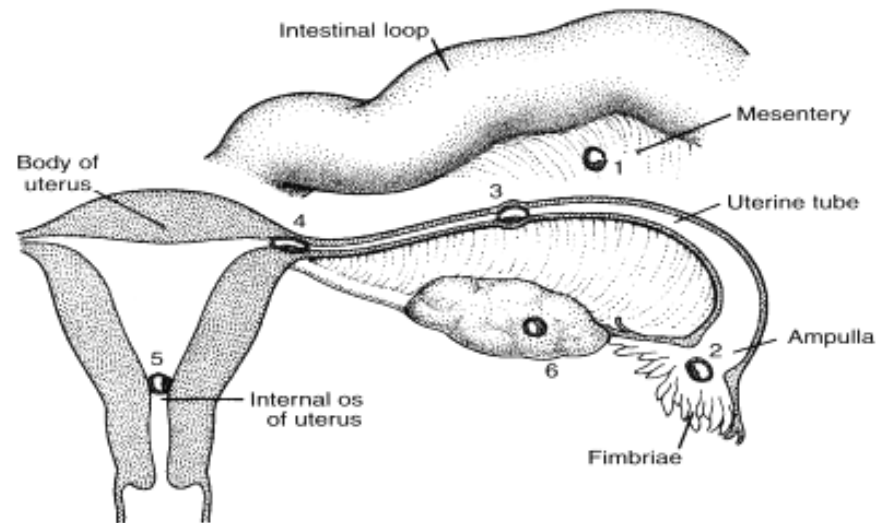
Revise:

- Structure of endometrium
- Menstrual cycle
- Structure of the exocrine glands

Task 27.1. SITES OF THE BLASTOCYST ABNORMAL IMPLANTATION

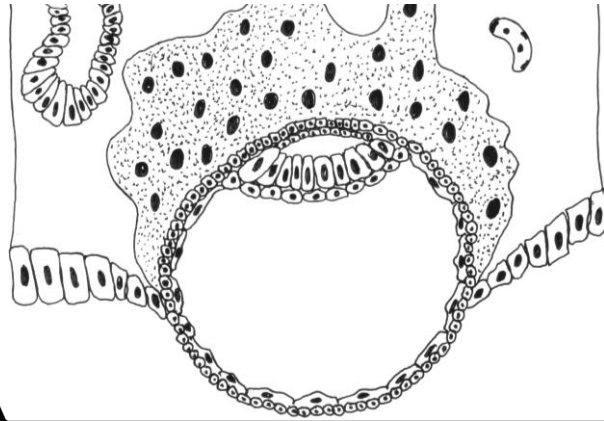
Write down the possible sites of the abnormal implantation:

- 1.
- 2.
- 3.
- 4.
- 5.
- 6.

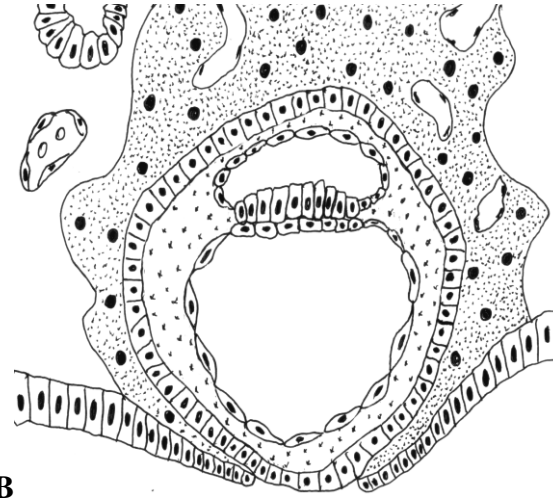


Task 27.2. SCHEME OF EXTRAEMBRYONIC ORGANS FORMATION

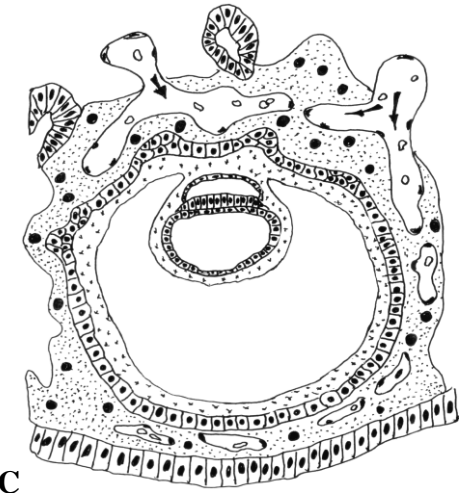
A — beginning of the implantation, 6th day; B — end of the implantation, 7–8th days; C — 13th day; D — 16th day; E — beginning of the placental blood flow, 20th day



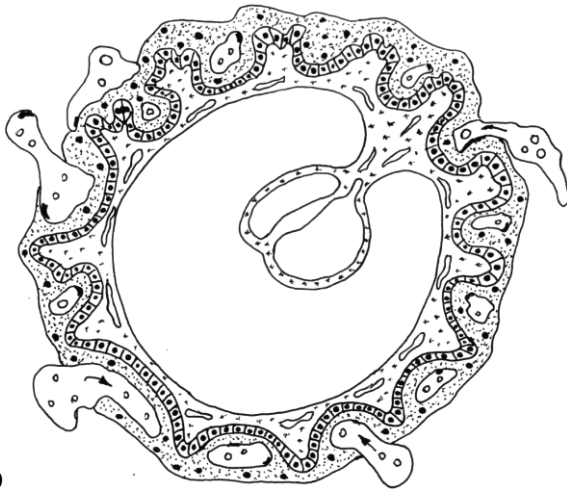
A



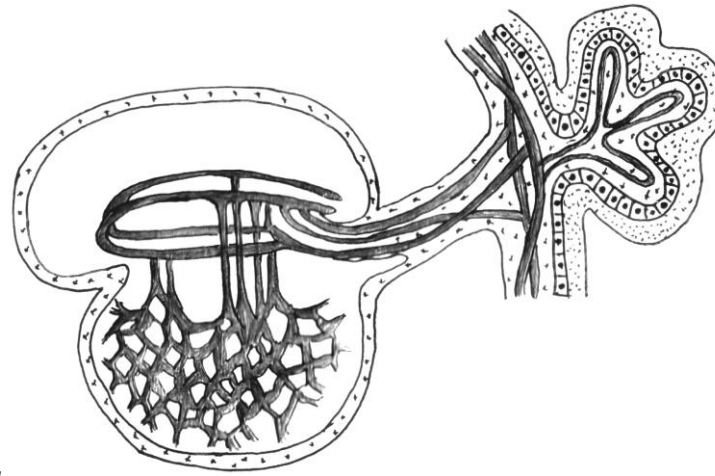
B



C



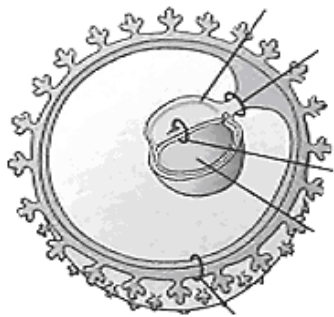
D



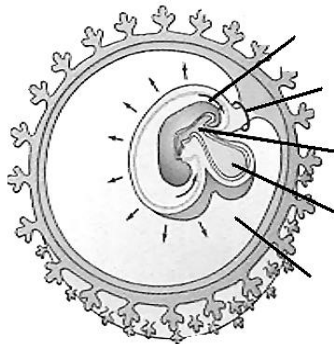
E

Designate:

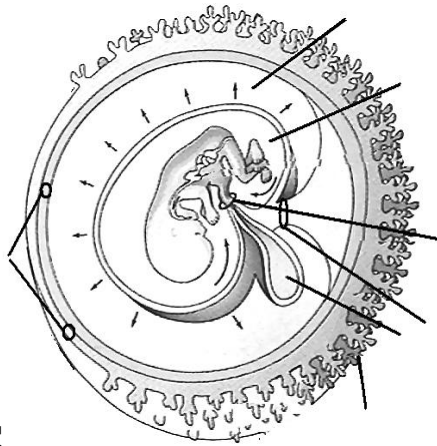
- 1 — embryonic disc: 1a — epiblast;
- 1b — hypoblast; 2 — amniotic sac;
- 3 — yolk sac; 4 — cytotrophoblast;
- 5 — syncytiotrophoblast;
- 6 — uterine blood vessels;
- 7 — uterine glands;
- 8 — extraembryonic mesoderm (or mesenchyme);
- 9 — chorionic wall; 10 — chorionic villi;
- 11 — allantois;
- 12 — connecting stalk; 13 — blood vessels of the chorionic villi;
- 14 — umbilical blood vessels



A



B

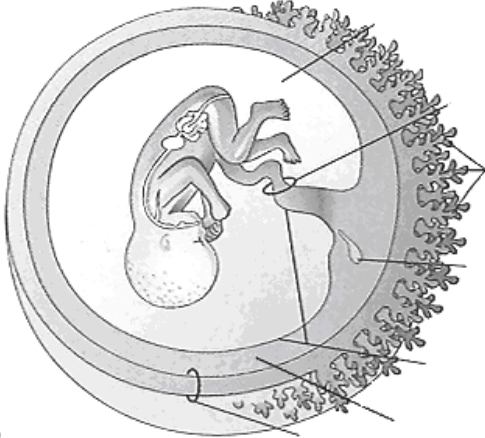


C

Task 27.3. SCHEME OF EXTRAEMBRYONIC ORGANS INTERPOSITION

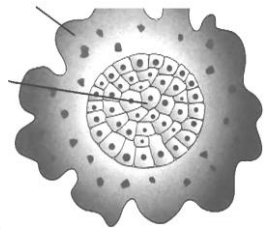
A — 3^d week; B — 4th week; C — 10th week; D — 20th week.

- Designate:**
- 1 — embryonic disc;
 - 2 — amnion (wall or cavity);
 - 2a — amniotic epithelium (on Fig. D)
 - 3 — yolk sac;
 - 4 — connecting stalk;
 - 5 — chorionic wall:
 - 5a — chorion frondosum;
 - 5b — chorion laeve;
 - 6 — chorionic cavity;
 - 7 — chorionic plate;
 - 8 — umbilical cord

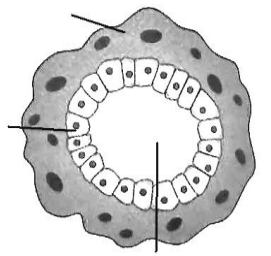


D

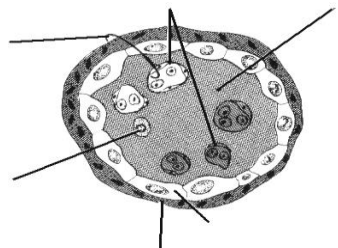
Task 27.4. SCHEME OF CHORIONIC VILLUS STRUCTURE



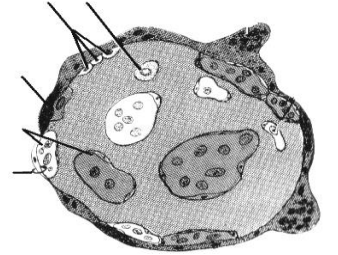
A



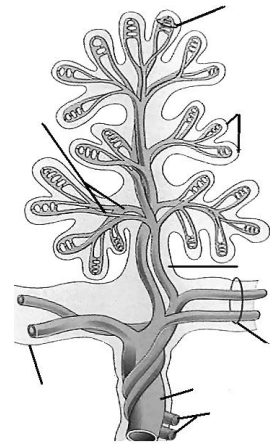
B



C



- Designate:**
- A — primary villus;**
 - B — secondary villus;**
 - C — tertiary villus during the Ist and IInd half of pregnancy.**
 - 1 — cytotrophoblast; 2 — syncytiotrophoblast; 3 — connective tissue (stroma) of villus; 4 — capillaries of villus; 5 — cells of villus' stroma; 6 — placental barrier.
 - D — main stem villus.**
 - 1 — umbilical vein; 2 — umbilical arteries; 3 — epithelium of amnion; 4 — chorionic plate with vessels; 5 — stroma of the villus; 6 — blood vessels of the villus; 7 — terminal branching of the villus; 8 — capillaries of the villus



D

Task 27.5. HUMAN PLACENTA (fetal and maternal parts)

Staining: Hematoxylin-eosin

Magnification: 80×, 400×

Draw a picture on the basis of two slides.

Designate:

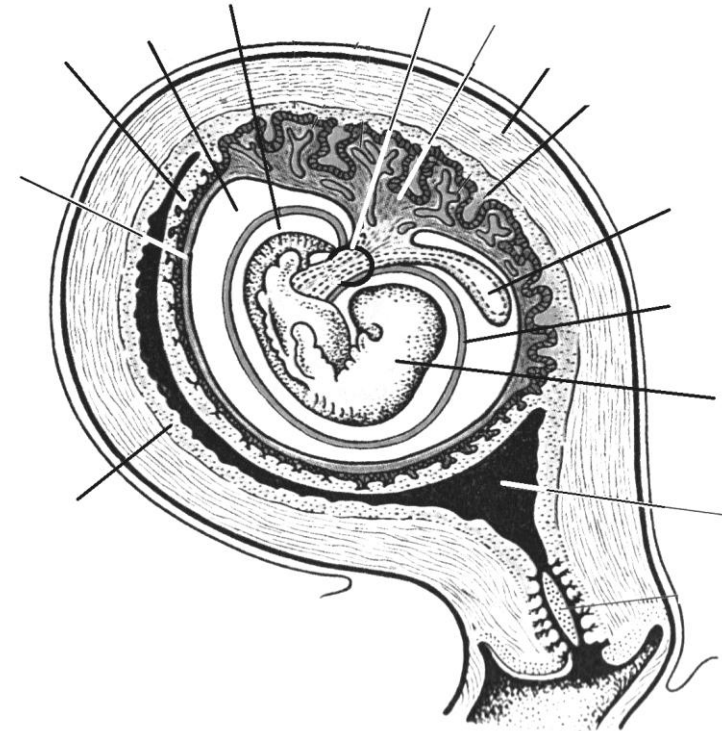
- 1 — epithelium of the amnion;
- 2 — chorionic plate;
- 3 — epithelium of villi (epithelium of trophoblast: CTB and STB);
- 4 — connective tissue of villi;
- 5 — blood vessels of villi;
- 6 — fibrinoid;
- 7 — lacunar spaces with maternal blood;
- 8 — decidua basalis (endometrium);
- 9 — decidual cells

Correct tasks № _____

Lecturer _____

Date « ____ » _____

Task 27.6. SCHEME OF INTERACTION AMONG FETUS, FETAL MEMBRANE AND UTERUS



Designate:

- 1 — uterus cavity;
- 2 — fetus;
- 3 — amniotic wall;
- 4 — yolk sac;
- 5 — decidua basalis;
- 6 — myometrium;
- 7 — chorion frondosum;
- 8 — chorion laeve;
- 9 — umbilical cord;
- 10 — amniotic cavity;
- 11 — chorionic cavity;
- 12 — decidua capsularis;
- 13 — decidua parietalis

LIST OF CONTROL HISTOLOGICAL SLIDES

Spring term

2nd intermediate assessment

1. Мезенхима зародыша курицы. **Mesenchyme in embryonal section**
2. Рыхлая соединительная ткань. **Loose connective tissue**
3. Жировая ткань сальника кошки. **White adipose tissue**
4. Сухожилие теленка в продольном разрезе. **Dense regular connective tissue of the tendon**
5. Гиалиновый хрящ ребра кролика. **Hyaline cartilage**
6. Эластический хрящ ушной раковины свиньи. **Elastic cartilage**
7. Развитие кости на месте хряща. **Endochondral ossification**
8. Развитие кости из соединительной ткани. **Intramembranous ossification**
9. Берцовая кость человека в поперечном разрезе. **Cross section of compact substance of the long bone**
10. Волокнистый хрящ. Межпозвоночный диск теленка. **Fibrocartilage**
11. Гладкая мышечная ткань в поперечном и продольном разрезе. **Smooth muscle tissue of the urinary bladder**
12. Поперечно-полосатая мышечная ткань языка. **Skeletal muscle tissue of the tongue**
13. Миокард. Сердце лошади. **Cardiac muscle tissue**
14. Тигроид в нервных клетках спинного мозга. **Basophilic substance of the spinal cord's neurons**
15. Безмякотные нервные волокна. **Unmyelinated nerve fibers**
16. Мякотные нервные волокна. **Myelinated nerve fibers**
17. Артериолы, вены, капилляры. **Arterioles, venules, capillaries**
18. Артерия мышечного типа. **Muscular artery**
19. Артерия эластического типа. Аорта. **Elastic artery**
20. Бедренная вена. **Vein (femoral vein)**
21. Волокна Пуркинье. Сердце быка. **Cardiac wall**
22. Трахея собаки. **Trachea**
23. Легкое кошки. **Lung**
24. Кожа пальца человека. **Finger skin**
25. Кожа с волосом. **Skin and its appendage**

Autumn semester

3rd intermediate assessment

1. Развитие зуба, эмалевый орган. **Tooth development. Enamel organ.**
2. Развитие зуба. Образование дентина, эмали. **Tooth development. Late stage**
3. Листовидные сосочки языка. **The tongue of rabbit. Foliate papillae**
4. Поперечный разрез пищевода. **Cross section of the esophagus**
5. Переход пищевода в желудок собаки. Дно желудка. **Fundus of the stomach**
6. Пилорическая часть желудка. **Pyloric portion of the stomach**
7. Тонкая кишка щенка. **Jejunum**
8. Толстая кишка собаки. **Large intestine**
9. 12-перстная кишка **Duodenum**
10. Печень свиньи. **Liver of the pig**
11. Печень человека **Human liver**
12. Поджелудочная железа. **Pancreas**
13. Подчелюстная железа **Submandibular gland**
14. Околоушная железа. **Parotid gland**
15. Красный костный мозг. **Red bone marrow**
16. Селезенка кошки. **Spleen**
17. Зобная железа. Тимус. **Thymus**
18. Небная миндалина. **Palatine tonsil**
19. Лимфатический узел. **Lymph node**
20. Паращитовидная железа. **Parathyroid gland**
21. Щитовидная железа. **Thyroid gland**
22. Гипофиз. **Hypophysis**
23. Надпочечник. **Adrenal gland**

4th intermediate assessment

1. Спинальный ганглий. **Spinal ganglion**
2. Спинной мозг. **Spinal cord**
3. Поперечный срез седалищного нерва. **Cross-section of peripheral nerve**
4. Кора полушарий собаки. **Cerebral cortex**
5. Мозжечок. **Cerebellum. Transverse section**
6. Задняя стенка глаза собаки. **Posterior wall of the eye**
7. Многослойный плоский неороговевающий эпителий роговицы. **Cornea**
8. Кортиев орган. **Spiral organ**
9. Мочевой пузырь. **Urinary bladder**
10. Мочеточник. **Ureter**
11. Почка. **Kidney**
12. Простата. **Prostatic gland**
13. Придаток семенника. **Efferent ductuli and ductus epididymis**
14. Семенник. **Testis**
15. Матка. **Uterus**
16. Яичник. **Ovary**
17. Желтое тело яичника. **Corpus luteum**
18. Плацента человека. Материнская часть. **Human placenta. Maternal part of placenta**
19. Плацента человека. Плодная часть. **Human placenta. Fetal part of placenta**
20. Молочная железа. **Mammary gland**
21. Туловищная и амниотическая складки зародыша курицы. **Amniotic and lateral folds of chicken's embryo**

LITERATURE

1. *Studenikina, T. M.* Histology, cytology, embryology : text-book / T. Studenikina, T. Vylegzhanina, T. Ostrovskaya. Minsk : Novoe znanie, 2022. 326 p.
2. *Eroschenko, V. P.* diFiore's Atlas of histology with functional correlations / V. P. Eroschenko. 12th ed. Lippincott Williams & Wilkins, 2013. 602 p.
3. *Kuznetsov, S. L.* Histology, cytology and embryology (a course of lectures) / S. Kuznetsov, T. Boroniknina, N. Gorychkina. Moscow : Medical Informational Agency, 2019. 239 p.
4. *Junqueira, L. K.* Junqueira's Basic Histology. Text and atlas / L. K. Junqueira. 13 ed. Antony L. Mescher. International edition, 2013. 694 p.
5. *Ross, M. H.* Histology : a text and atlas / M. H. Ross, W. Paulina. 6th ed. Lippincott Williams & Wilkins, 2021. 1023 p.
6. *Singh, I.* Text book of Human Histology / I. Singh. 5th ed. Jaypee Brothers medical Publisher LTD, 2006. 364p.
7. *Singh, I.* Human Embryology / I. Singh. 7th ed. Macmillan, Indian LTD, 2001. 577 p.
8. *Vylegzhanina, T.* Nervous tissue and the nervous system / T. Vylegzhanina, T. Ostrovskaya. Minsk : BGMU, 2014. 40 p.

CONTENT

The results of intermediate assessment.....	3
The Instructions of the Histology, Cytology and Embryology Department for the students to follow.....	4
1. Overview of objects, microscopic and histological technique. Overview of the cell structure.....	5
2. Cytology. Structural organization of cellular surface.....	11
3. Embryology. Progenesis. Stages of human embryonic development. Fertilization, cleavage.....	15
4. Embryology. Gastrulation. Differentiation of the embryonic germ layers.....	18
5. Overview of tissues. Epithelial tissue.....	23
6. Blood and lymph.....	28
7. Blood and lymph. Hemopoiesis.....	32
8. Connective tissue. Connective tissue proper.....	36
9. Connective tissue. Skeletal tissue.....	40
10. Muscle tissues.....	44
11. Nerve tissue.....	49
12. Cardiovascular system.....	54
13. Respiratory system.....	58
14. Integumentary system.....	62
15. Digestive system. Anterior part.....	65
16. Digestive system. Middle and posterior part.....	69
17. Digestive system. Glands.....	75
18. Organs of hemopoiesis and immunity (lymphoid organs).....	79
19. Endocrine system.....	83
20. Nervous system. Peripheral nervous system. Spinal cord.....	88
21. Nervous system. Central nervous system.....	91
22. Sense organs.....	94
23. Urinary system.....	98
24. Reproductive system. Male reproductive system.....	103
25. Reproductive system. Female reproductive system.....	108
26. Human embryology. Organo- and histogenesis. Critical periods of development.....	112
27. Human embryonic development. Implantation. Extraembryonic organs.....	116
List of control histological slides.....	120
Literature.....	121

Учебное издание

Студеникина Татьяна Михайловна
Вылегжанина Тамара Александровна
Островская Тереза Иосифовна
Юзефович Наталья Анатольевна

ГИСТОЛОГИЯ, ЦИТОЛОГИЯ, ЭМБРИОЛОГИЯ. ПРАКТИКУМ

HISTOLOGY, CYTOLOGY, EMBRYOLOGY. PRACTICUM

Учебное пособие

На английском языке

4-е издание

Ответственная за выпуск Т. М. Студеникина
Переводчики Т. М. Студеникина, Т. А. Вылегжанина, Т. И. Островская, Н. А. Юзефович
Компьютерный набор Т. М. Студеникиной, Т. А. Вылегжаниной, Т. И. Островской, Н. А. Юзефович
Компьютерная вёрстка Н. М. Федорцовой

Подписано в печать 24.02.26. Формат 60×84/8. Бумага «Снегурочка». Ризография. Гарнитура «Times».
Усл. печ. л. 14,41. Уч.-изд. л. 6,74. Тираж 171 экз. Заказ 110.

Издатель и полиграфическое исполнение: учреждение образования
«Белорусский государственный медицинский университет».
Свидетельство о государственной регистрации издателя, изготовителя,
распространителя печатных изданий № 1/187 от 24.11.2023.
Ул. Ленинградская, 6, 220006, Минск.