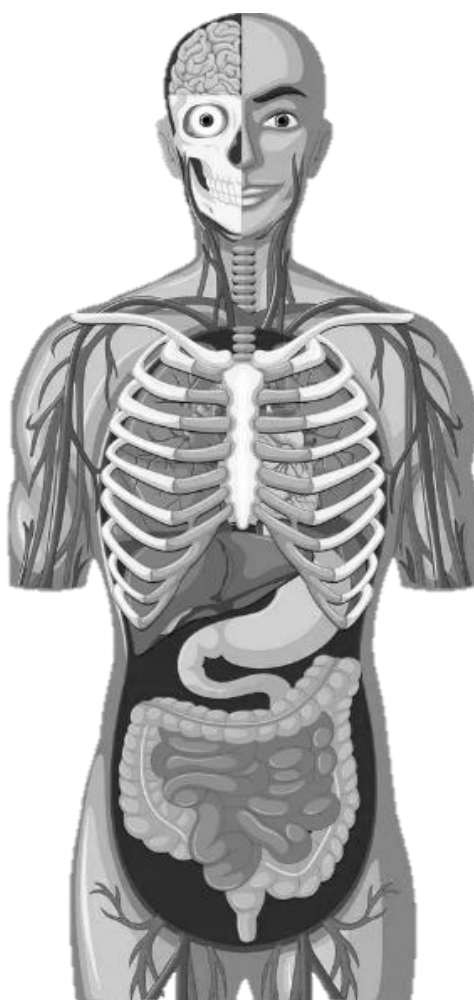

S. L. KABAK, N. V. ZHURAVLEVA, V. V. ZATOCHNAYA

# **CARDIOVASCULAR SYSTEM. NERVOUS SYSTEM. INTERNAL ORGAN SYSTEMS**



Minsk BSMU 2026

МИНИСТЕРСТВО ЗДРАВООХРАНЕНИЯ РЕСПУБЛИКИ БЕЛАРУСЬ  
БЕЛОРУССКИЙ ГОСУДАРСТВЕННЫЙ МЕДИЦИНСКИЙ УНИВЕРСИТЕТ  
КАФЕДРА МОРФОЛОГИИ ЧЕЛОВЕКА

**С. Л. КАБАК, Н. В. ЖУРАВЛЁВА, В. В. ЗАТОЧНАЯ**

**СЕРДЕЧНО-СОСУДИСТАЯ СИСТЕМА. НЕРВНАЯ СИСТЕМА.  
СИСТЕМЫ ВНУТРЕННИХ ОРГАНОВ**

**CARDIOVASCULAR SYSTEM. NERVOUS SYSTEM.  
INTERNAL ORGAN SYSTEMS**

Практикум

*4-е издание*



Минск БГМУ 2026

УДК 611.1:611.8:616.1/4(075.8)-054.6  
ББК 54.1я73  
К12

Рекомендовано Научно-методическим советом университета в качестве  
практикума 19.11.2025 г., протокол № 3

Р е ц е н з е н т ы: канд. мед. наук, доц. каф. топографической анатомии и оперативной хирургии Белорусского государственного медицинского университета Е. А. Ключ; каф. анатомии человека с курсом топографической анатомии и оперативной хирургии Гомельского государственного медицинского университета

**Кабак, С. Л.**

К12 Сердечно-сосудистая система. Нервная система. Системы внутренних органов = Cardiovascular system. Nervous system. Internal organ systems : практикум / С. Л. Кабак, Н. В. Журавлёва, В. В. Заточная. – 4-е изд. – Минск : БГМУ, 2026. – 91 с.

ISBN 978-985-21-2118-7.

Содержит контрольные вопросы к лабораторным и итоговым занятиям, глоссарий, материалы для самостоятельной работы в виде рисунков и таблиц, тесты для самоконтроля по разделам анатомии человека, изучаемым на первом курсе во 2-м семестре согласно тематическому плану. Первое издание вышло в 2023 году.

Предназначен для студентов 1-го курса медицинского факультета иностранных учащихся, обучающихся на английском языке по специальности «Стоматология».

УДК 611.1:611.8:616.1/4(075.8)-054.6  
ББК 54.1я73

ISBN 978-985-21-2118-7

© Кабак С. Л., Журавлёва Н. В., Заточная В. В., 2026  
© УО «Белорусский государственный медицинский университет», 2026

# CARDIOVASCULAR SYSTEM

## LABORATORY CLASS № 1

### GENERAL INFORMATION ABOUT THE STRUCTURE OF CARDIOVASCULAR SYSTEM. ANATOMY OF THE HEART. AORTA

#### Control questions:

1. General characteristics and function of cardiovascular system. Systemic and pulmonary circulation.
2. The external structure of the heart: surfaces, edges, grooves.
3. The heart chambers: morphofunctional characteristics of atria and ventricles.
4. The right and left atrioventricular valves; the aortic valve; valve of pulmonary trunk: location, structure, purpose.
5. The layers of the heart wall. The structure of the muscular layer of the atria and ventricles.
6. The cardiac conducting system. Nodes and bundles of the cardiac conducting system; their location, function.
7. The structure of the pericardium. Pericardial cavity.
8. The blood supply of the heart: the right and left coronary arteries; their branches, areas of blood supply. Lymphatic and venous drainage from the heart.
9. Aorta: parts, bifurcations, terminal branches.
10. The branches of the aortic arch in the order of its origin (right to left), the areas of blood supply.
11. Parietal and visceral branches of the thoracic aorta.
12. Parietal and visceral (paired and unpaired) branches of abdominal aorta.
13. General principles of location and the names of the main arteries of the upper limb. Place of palpation of radial artery pulsation.
14. The principles of location and the names of the main arteries of the lower extremities.

#### Students should be able to find on anatomical preparations and visual aids following structures and to know their Latin names:

1. Heart.
2. The right (left) atrium.
3. The right (left) auricle.
4. Right (left) atrioventricular valve.
5. Right (left) ventricle.
6. The valve of the aorta.
7. The valve of pulmonary trunk.
8. The base, sternocostal, diaphragmatic surface of the heart.
9. Coronary sulcus.
10. The anterior (posterior) interventricular sulcus.
11. The right (left) coronary artery.
12. The coronary sinus.
13. Aorta.
14. Aortic arch.
15. Ascending, thoracic, abdominal aorta.
16. Brachiocephalic trunk.
17. Common carotid artery.
18. Subclavian artery.

**Repeat:** chest skeleton, vertebral column, lower limb skeleton.

## GLOSSARY

**Arteries** — blood vessels that carry blood from the heart to the organs and tissues.

**Veins** — blood vessels that carry blood back to the heart.

**Microvasculature** provides interaction of blood and tissues; including arterioles, capillaries, venules.

**Heart** — a hollow muscular organ, it consists of four chambers: *the left atrium, the right atrium, left ventricle, right ventricle*. Heart chambers are separated by interatrial and interventricular septa respectively. The aorta arises from the right ventricle and the pulmonary trunk arises from the left ventricle. The superior and inferior vena cava carry oxygen-poor blood from the body and flow into the right atrium, and the four pulmonary veins carry oxygen-rich blood from the lungs to the left atrium.

**The left atrioventricular valve (mitral)** located in the left atrioventricular orifice, has anterior and a posterior cusps.

**Right atrioventricular valve (tricuspid)** is in the right atrioventricular orifice, has anterior, posterior and septal cusps.

**Endocardium** — is the innermost layer of the heart. It lines the inner surfaces of the heart chambers, including the heart valves. The endocardium has two layers. The inner layer lines the heart chambers and is made of endothelial cells. Behind this is the second layer: a subendocardial connective tissue which is continuous with the connective tissue of the myocardium. Branches of the heart's conduction system are immersed into the subendocardial layer.

**Myocardium** — the middle layer of the heart composed of cardiac striated muscle tissue. There are contractile, conducting and secretory cardiomyocytes.

**Epicardium** — the outer layer of the heart. It is actually the visceral layer of the serous pericardium, which adheres to the myocardium of the heart.

**Pericardium** — closed serous sac around the heart, it the fibrous serous pericardium. The last is divided into two layers: the visceral, or epicardium, and parietal, the fibrous pericardium. Between the two layers of the serous pericardium is the pericardial cavity.

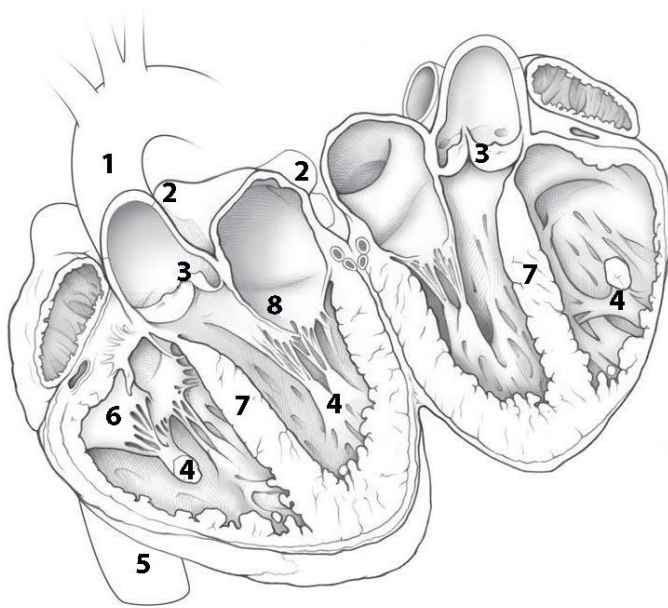
**Oval fossa** — small oval depression in the atrial septum. In prenatal period of development, there was an oval hole through which the two atriums connected.

**Aorta** — the largest unpaired arterial vessel of a great circulation. The aorta is divided into ascending part, aortic arch and the descending part (thoracic and abdominal aorta). From the ascending part of the aorta, the right and left coronary arteries depart, from the aortic arch - the brachiocephalic trunk (right), the left common carotid and left subclavian arteries. The branches of the descending part of the aorta come to the thoracic walls and abdominal cavities (parietal branches) and to organs (visceral branches).

**Arteries of the extremities:** the number and name of the main arteries of the free upper and lower extremities corresponds to the number and name of the bones that form its skeleton. In this case, vascular networks are formed in the area of the joints, on the hand and foot, the terminal branches of the arteries form arches.

**SELF-INSTRUCTIONAL MATERIALS**

**Sectioned heart (opened like a book)**



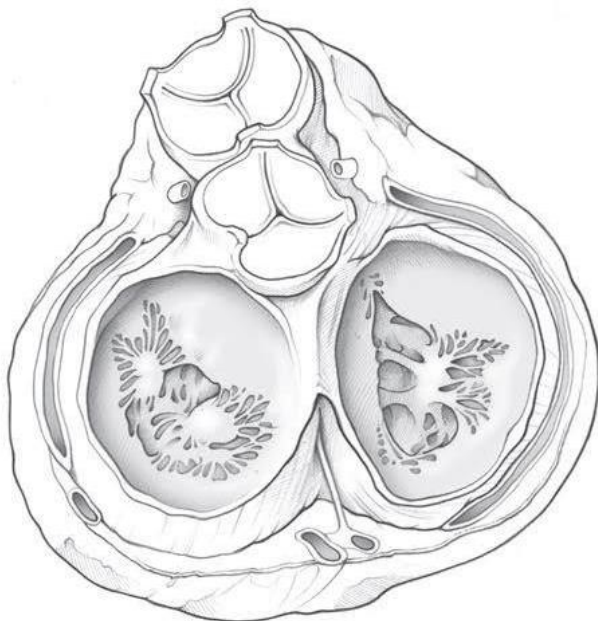
**COLOR** the following features of the heart chambers, using a different color for each feature, except where a color is suggested:

- Left atrium
- Right atrium
- Right ventricle
- Left ventricle

**WRITE** the names of structures labeled by the number:

1.		5.	
2.	veins	6.	valve
3.	valve	7.	
4.		8.	valve

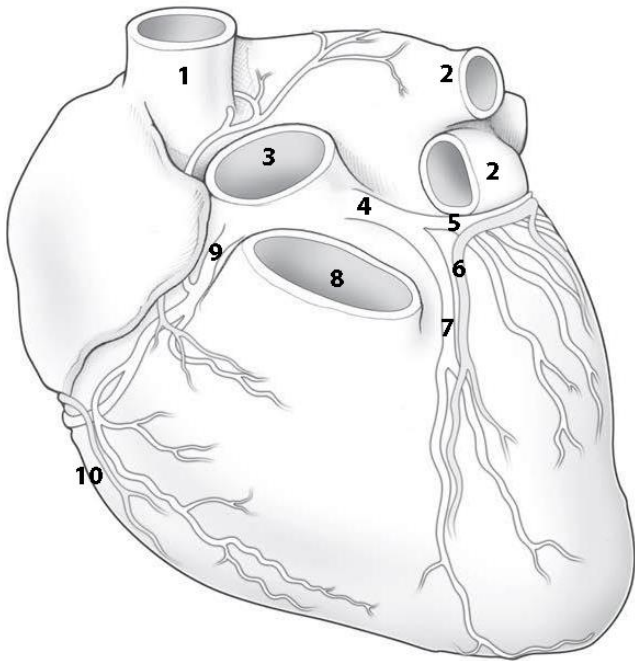
**Heart in diastole: viewed from base with atria removed**



**COLOR** the cusps of the following heart valves in different colors:

- Pulmonary semilunar valve
- Aortic semilunar valve
- Tricuspid valve
- Mitral valve

## Coronary arteries and veins

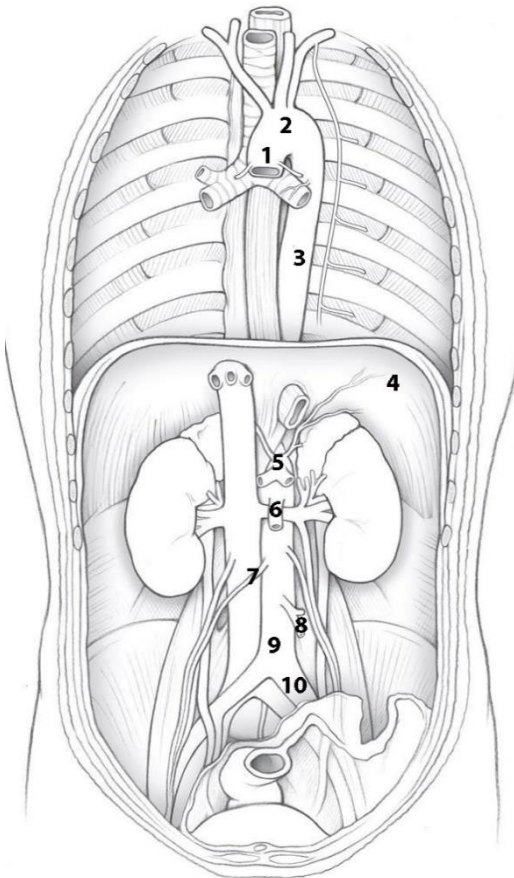


**COLOR** the coronary arteries (red) and cardiac veins, using red and blue colors.

**WRITE** the names of structures labeled by the number:

- |     |              |
|-----|--------------|
| 1.  | _____        |
| 2.  | _____        |
| 3.  | _____        |
| 4.  | _____        |
| 5.  | _____ branch |
| 6.  | _____ vein   |
| 7.  | _____ branch |
| 8.  | _____        |
| 9.  | _____        |
| 10. | _____ viens  |

## Thoracic and Abdominal Aorta



**WRITE** the name of structures labeled by the number:

- |     |              |
|-----|--------------|
| 1.  | _____        |
| 2.  | _____        |
| 3.  | _____        |
| 4.  | _____        |
| 5.  | _____        |
| 6.  | _____ artery |
| 7.  | _____        |
| 8.  | _____ artery |
| 9.  | _____        |
| 10. | _____        |

**COLOR** the branches of aortic arch:

- Brachiocephalic trunk
- Left common carotid artery
- Left subclavian artery
- Thoracic aorta
- Abdominal aorta

## CONTROL QUIZ

1. Pulmonary circulation starts from \_\_\_\_\_ by \_\_\_\_\_

---
2. Systemic circulation starts from \_\_\_\_\_ by \_\_\_\_\_

---
3. Specify the place of the origin of the coronary arteries

---
4. The soft skeleton of the heart is formed by

---
5. How many myocardial layers have-ventricles of the heart

---
6. The heart conduction system is formed by

---
7. Specify the visceral branches of the thoracic aorta

---
8. Specify the parietal branches of the abdominal aorta

---
9. The superior mesenteric artery starts \_\_\_\_\_ (level of vertebra)

---
10. Specify the coeliac trunk branches

---

## LABORATORY CLASS № 2

### ARTERIES OF THE HEAD AND NECK

#### Control questions:

1. Common carotid artery: the place of origin of the right and left common carotid arteries; bifurcation, terminal branches.
2. External carotid artery: branches, areas of blood supply. Anterior, middle and posterior divisions of the external carotid artery.
3. Maxillary artery: branches of mandibular, pterygoid and pterygopalatine parts; their areas of blood supply.
4. Internal carotid artery, segments, the terminal branches.
5. The ophthalmic artery: branches and areas of blood supply.
6. Subclavian artery: the place of origin of the right and left subclavian arteries. The course of the subclavian artery, the division into parts.
7. The branches of the 1<sup>st</sup> part of the subclavian artery, the blood supply area.
8. The arterial (Willis) circle of the brain: localization, formation sources anastomoses, significance.
9. The branches of the 2<sup>nd</sup> and 3<sup>rd</sup> parts of the subclavian artery and the blood supply area.

#### Students should be able to find on anatomical preparations and visual aids following structures and to know their Latin names:

1. Common carotid artery.
2. External carotid artery.
3. Superior thyroid artery.
4. Lingual artery.
5. Facial artery.
6. Occipital artery.
7. Posterior auricular artery.
8. Ascending pharyngeal artery.
9. Superficial temporal artery.
10. Maxillary artery.
11. Inferior alveolar artery.
12. Submental artery.
13. Middle meningeal artery.
14. Posterior superior alveolar artery.
15. Infraorbital artery.
16. Anterior superior alveolar artery.
17. Descending palatine artery.
18. Sphenopalatine artery.
19. Internal carotid artery.
20. Ophthalmic artery.
21. Anterior (middle) cerebral artery.
22. Anterior (posterior) communicating artery.
23. Subclavian artery.
24. Vertebral artery.
25. Basilar artery.
26. Posterior cerebral artery.
27. Internal thoracic artery.
28. Thyrocervical trunk.
29. Costocervical trunk.
30. Axillary artery.
31. Brachial, radial, ulnar arteries.

**Repeat:** cervical part of vertebral column, upper limb skeleton, muscles and neck triangles.

### GLOSSARY

**Common carotid artery** is a large artery, which provides the main blood supply to the head and neck region. There is one common carotid artery on either side of the body and these arteries differ in their origin. The left common carotid artery arises from the aortic arch, whilst the right common carotid artery arises from the brachiocephalic trunk. The common carotid artery generally bifurcates into the internal and external carotid arteries at the level of the superior border of the laryngeal thyroid cartilage.

**External carotid artery** is one of the two branches of the common carotid artery, gives off eight main branches, which supply regions of the head and neck. Branches go on several directions: the ventral branches include *superior thyroid artery, lingual and facial arteries*; the dorsal branches — *occipital and posterior auricular arteries*; the medial branches — *ascending pharyngeal artery* and **terminal branches** of the external carotid artery: *maxillary and superficial temporal arteries*.

**Maxillary artery** — is the largest branch of the external carotid artery and supplies deep structures on the face. The course of the maxillary artery has three parts by the lower head of the lateral pterygoid muscle: mandibular part — posterior to lateral pterygoid muscle (*deep auricular, anterior tympanic, middle meningeal, inferior alveolar*), pterygoid (muscular) part — within lateral pterygoid muscle (*anterior and posterior deep temporal arteries, pterygoid branches, masseteric, buccal arteries*), pterygopalatine part — anterior to lateral pterygoid muscle (*posterior superior alveolar, infra-orbital arteries, artery of pterygoid canal, descending palatine, sphenopalatine arteries*).

**Internal carotid artery** starts from the bifurcation of the common carotid artery. It does not give branches in the neck, goes up through carotid canal, and penetrates to the cranial cavity. Terminal branches of the internal carotid arteries supply brain, organ of vision, mucous membrane of the tympanic cavity. Internal carotid artery is divided into seven segments according to the areas through which it passes. There are *cervical, petrous, lacerum, cavernous, clinoid, ophthalmic, communicating segments*.

**Ophthalmic artery** moves away from the trunk of the internal carotid artery at the beginning of the optic canal through it enters to orbit. It supplies the eyeball and its muscles, lacrimal gland, ethmoid cells, dura mater, eyelids, skin and muscles of the forehead area.

**Anterior cerebral artery** — the branch of the internal carotid artery, supplies the anterior parts of the cerebral hemisphere. The anterior communicating artery connects the right and left artery.

**Middle cerebral artery** — the branch of the internal carotid artery, supplies superolateral surface of the frontal, parietal, temporal, and insular lobes of the cerebral hemispheres.

**Posterior communicating artery** — the branch of the internal carotid artery goes backwards towards the pons and connects with the posterior cerebral artery.

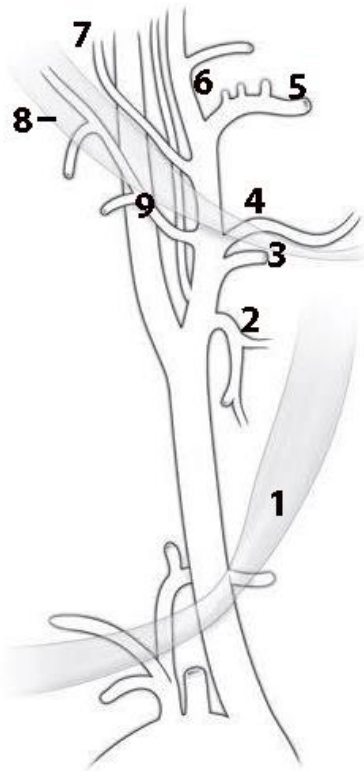
**Subclavian artery** is paired artery that supply blood to the posterior cerebrum, cerebellum, posterior neck, upper limbs and the superior and anterior chest wall. Right and left subclavian arteries classically have different origins: the left subclavian artery originates directly from the aortic arch, while the right subclavian artery originates from the brachiocephalic trunk. The artery turns the dome of the pleura and leaves the chest cavity through the upper aperture, suited to the clavicle and falls into the subclavian groove of the 1<sup>st</sup> rib; starting from the outer edge of the 1<sup>st</sup> rib, it continues to the axillary artery. Topographically subclavian artery is divided into three sections in relation to anterior scalene muscle: 1<sup>st</sup> — from the beginning to the interscalene space, 2<sup>nd</sup> — inside the interscalene space and 3<sup>rd</sup> — after this space. In the first part of the subclavian artery depart vertebral, internal thoracic artery and thyrocervical trunk; from the second division — costocervical trunk, from the third — the dorsal scapular artery.

**Vertebral artery** starts from the subclavian artery, follows up through transverse foramina of the VI-I cervical vertebrae and enters the cranial cavity through foramen magnum. Near the posterior edge of the pons by connecting the right and left vertebral artery basilar artery is formed. The branches of the vertebral artery supply the spinal cord, brainstem, cerebellum, the dura mater, the deep muscles of the neck.

**Cerebral arterial circle [Willis' circle]** is an anastomotic ring of arteries located at the base of the brain. It is formed by the anterior and posterior cerebral arteries, internal carotid artery, anterior and posterior communicating artery. Arterial circle is able to compensate for insufficient of blood supply to the brain due to redistribution of the blood from other vascular systems.

## SELF-INSTRUCTIONAL MATERIALS

### Right external carotid artery branches



**COLOR** the following arteries, using a different color for each of them:

- Common carotid artery
- External carotid artery
- Internal carotid artery

**WRITE** the names of structures labeled by the number:

1. Superior belly of omohyoid muscle

2. \_\_\_\_\_

3. \_\_\_\_\_

4. \_\_\_\_\_

5. \_\_\_\_\_

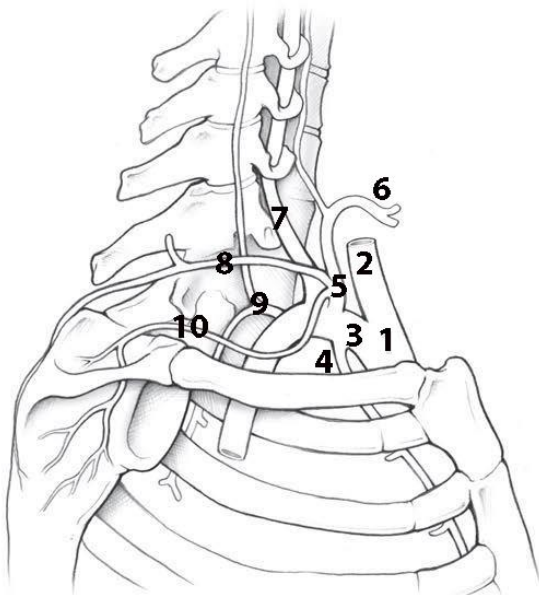
6. \_\_\_\_\_

7. \_\_\_\_\_

8. Posterior belly of digastric muscle

9. \_\_\_\_\_

### Branches of the subclavian artery



**COLOR** the thyrocervical trunk (red).

**WRITE** the names of structures labeled by the number:

1. \_\_\_\_\_

2. \_\_\_\_\_

3. \_\_\_\_\_

4. \_\_\_\_\_

5. \_\_\_\_\_

6. \_\_\_\_\_

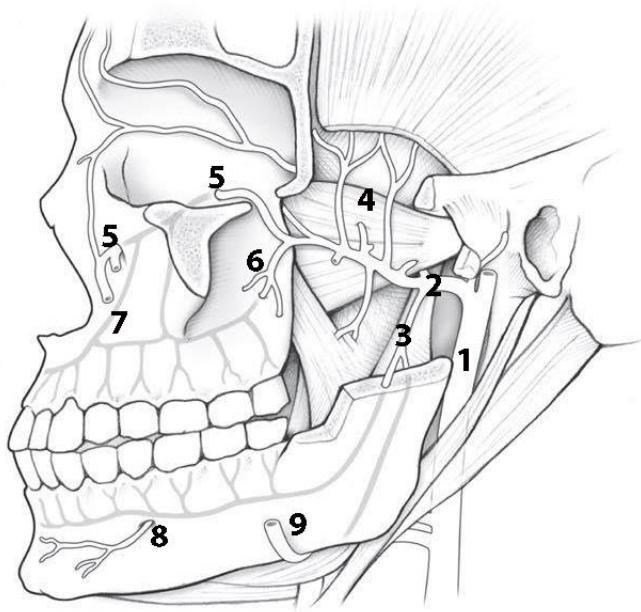
7. \_\_\_\_\_

8. \_\_\_\_\_

9. \_\_\_\_\_

10. \_\_\_\_\_

## Left maxillary artery

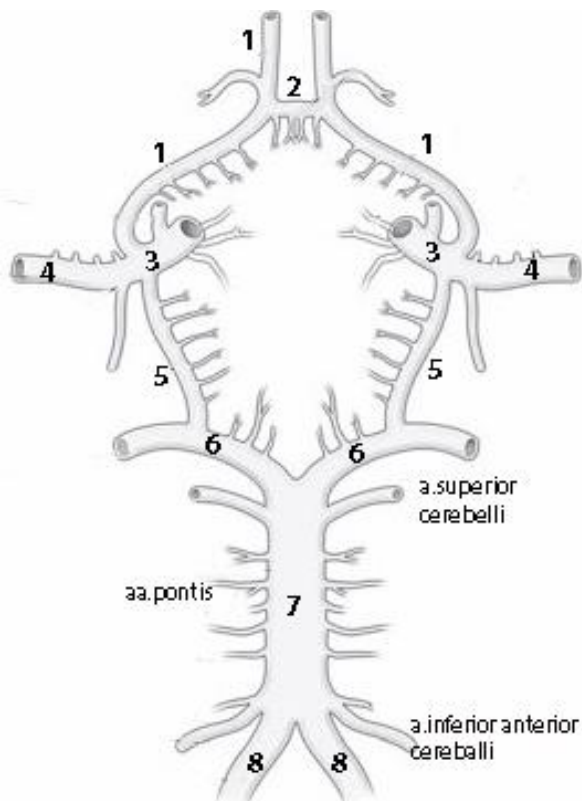


**WRITE** the names of arteries labeled by the number:

1. \_\_\_\_\_
2. \_\_\_\_\_
3. \_\_\_\_\_
4. \_\_\_\_\_
5. \_\_\_\_\_
6. \_\_\_\_\_
7. Anterior
8. \_\_\_\_\_
9. \_\_\_\_\_

**COLOR** the buccal artery (blue).

## Arteries of the brain (inferior view)



**WRITE** the names of arteries labeled by the number:

1. \_\_\_\_\_
2. \_\_\_\_\_
3. \_\_\_\_\_
4. \_\_\_\_\_
5. \_\_\_\_\_
6. \_\_\_\_\_
7. \_\_\_\_\_
8. \_\_\_\_\_

**COLOR** the internal carotid artery and its branches (blue) and the basilar artery branches (red).

## CONTROL QUIZ

1. Carotid body locates at

---

2. Where the level of bifurcation of common carotid artery are founded?

---

3. Ophthalmic artery passes into the orbit through

---

4. Terminal branches of external carotid artery are

---

5. Terminal branches of basilar artery are

---

6. Name the branches of mandibular part of maxillary artery

---

7. Name the anterior (ventral) branches of external carotid artery

---

8. Specify parts of the internal carotid artery

---

9. Name the branches of ophthalmic artery

---

10. Name the branches of the second part of subclavian artery

---

## LABORATORY CLASS № 3

### VEINS. LYMPHATIC VESSELS, TRUNKS AND DUCTS

#### Control questions:

1. Sources of formation and topography of the superior vena cava. Azygos and hemiazygos veins, its tributaries.
2. Internal jugular vein. Intracranial tributaries: diploic, emissary, superior and inferior ophthalmic veins. Dural venous sinuses.
3. Extracranial tributaries of internal jugular vein. The course and tributaries of facial and retromandibular veins. Pterygoid plexus.
4. External and anterior jugular veins. Jugular venous arch. Subclavian vein.
5. Inferior vena cava. Parietal and visceral tributaries.
6. Hepatic portal vein system. Its functional significance.
7. Portocaval and cava-caval anastomoses. Examples, significance.
8. The principles of organization venous system of upper and lower extremities.
9. Lymphatic trunks and ducts. Sources of formation, direction, the confluence to the venous system.
10. Classification and topography of the regional lymph nodes of the head and neck.

#### Students should be able to find on anatomical preparations and visual aids following structures and to know their Latin names:

1. *Superior vena cava*. 2. Azygos vein. 3. Hemiazygos vein. 4. Brachiocephalic vein (right, left). 5. Internal jugular vein. 6. Diploic veins. 7. Emissary veins. 6. Superior (inferior) ophthalmic vein. 7. Pharyngeal veins. 8. Lingual vein. 9. Superior thyroid vein. 10. Facial vein. 11. Retromandibular vein. 12. Pterygoid plexus. 13. External jugular vein. 14. Anterior jugular vein. 15. Jugular venous arch. 16. Subclavian vein. 17. Lateral (medial) subcutaneous vein of hands. 18. Axillary, brachial, radial, ulnar veins.

1. *Inferior vena cava*. 2. Lumbar veins. 3. Inferior diaphragmatic veins. 4. Testicular (ovarian) vein. 5. Renal vein. 6. Hepatic veins. 7. Portal vein. 8. Superior (inferior) mesenteric vein. 9. Splenic vein. 10. Common (internal, external) iliac veins. 11. Great (small) saphenous vein. 12. Thoracic duct. 13. Right lymphatic duct. 14. Jugular, subclavian, bronchomediastinal, lumbar, intestinal trunks. 15. The occipital, mastoid, parotid, submandibular, submental lymph nodes. 16. Anterior, superficial and deep cervical lymph nodes. 17. Lateral superficial and deep cervical nodes.

**Repeat:** internal base of the skull, infratemporal and pterygopalatine fossa. Regions and triangles of neck.

## GLOSSARY

**The superior vena cava** is a large, valveless vein that arises from the union of the left and right brachiocephalic veins. The superior vena cava contains venous blood from the head, neck, both upper limbs and from structures within the thorax. At the level of T4, the superior vena cava receives the azygos vein, which drains the upper lumbar region and thoracic wall.

**Azygos vein** — the tributary of the superior vena cava, it originates from the right ascending lumbar vein. It has tributaries: the *right posterior intercostal veins*, *the upper diaphragmatic veins*, the veins from the organs of thoracic cavity and *hemiazygos vein*.

**Hemiazygos vein** originates from the left ascending lumbar vein, passes to the left from the spinal cord and at the level of T9 - T10, it flows into the azygos vein. Collects venous blood from the left posterior intercostal veins.

**Accessory hemiazygos vein** is formed by the confluence of the middle left posterior intercostal veins. It descends to the left of midline, adjacent to the thoracic vertebrae and crosses posteriorly to the aorta at the level of T7-8 to drain into the azygos vein. It drains the left superior hemithorax.

**Brachiocephalic vein** — paired vessel forming by subclavian and internal jugular veins; collects blood from the head, neck and upper limbs. Right and left brachiocephalic veins form superior vena cava.

**Internal jugular vein** is a direct continuation of the sigmoid sinus and collects blood from the brain, orbit, the inner ear, cranium. On the neck, it goes down as a part of the neurovascular bundle and takes *lingual, pharyngeal, superior and middle thyroid, facial veins and retromandibular veins*.

**Diploic veins** — thin-walled veins, located in the spongy bone of the calvaria. In the skull cavity, they communicate with dura mater sinuses, but by emissary veins — with superficial head veins.

**Emissary veins** are located in the corresponding foramina and canals bone of the skull: *condylar, mastoid, parietal emissary veins*. Connect the dural venous sinuses with superficial veins of head.

**Pterygoid plexus** locates in the infratemporal fossa, its forms by veins that accompany the branches of the maxillary artery, and have, as a rule, the same name.

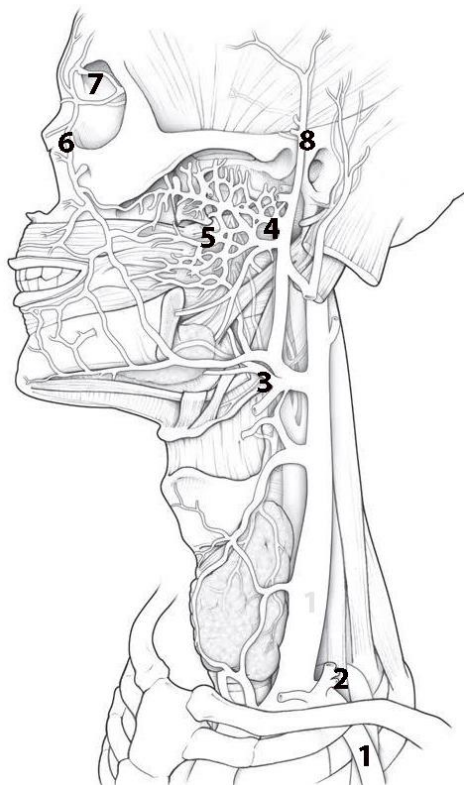
**External jugular vein** is a superficial vein of the neck that is formed by the union of the *occipital and posterior auricular veins*. It has anastomosis with retromandibular vein. Tributaries of the external jugular veins: *suprascapular vein, transverse cervical vein, anterior jugular vein*.

**Jugular venous arch** — anastomosis of the left and right anterior jugular veins in the suprasternal space.

**Hepatic portal vein** forms by the fusion of the superior mesenteric and splenic veins that carry venous blood from the unpaired abdominal organs to the liver. Inside the liver, the portal vein splits into intralobular capillaries that flow into the central veins. The central veins continue into the sublobular veins, which join into several hepatic veins, which are tributaries of the inferior vena cava.

## SELF-INSTRUCTIONAL MATERIALS

### Veins of the neck



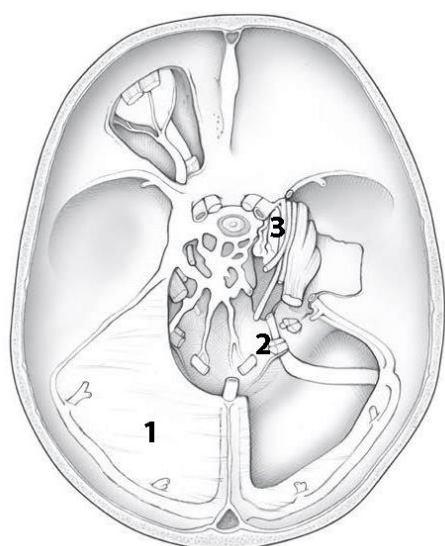
**COLOR** the following veins and its tributaries, using the different color for each of them:

- Facial
- Superior, middle, and inferior thyroid
- Retromandibular
- Internal jugular

**WRITE** the names of structures labeled by the number:

1. \_\_\_\_\_
2. \_\_\_\_\_
3. \_\_\_\_\_
4. \_\_\_\_\_
5. \_\_\_\_\_ plexus
6. \_\_\_\_\_
7. \_\_\_\_\_
8. \_\_\_\_\_

### Dural venous sinuses



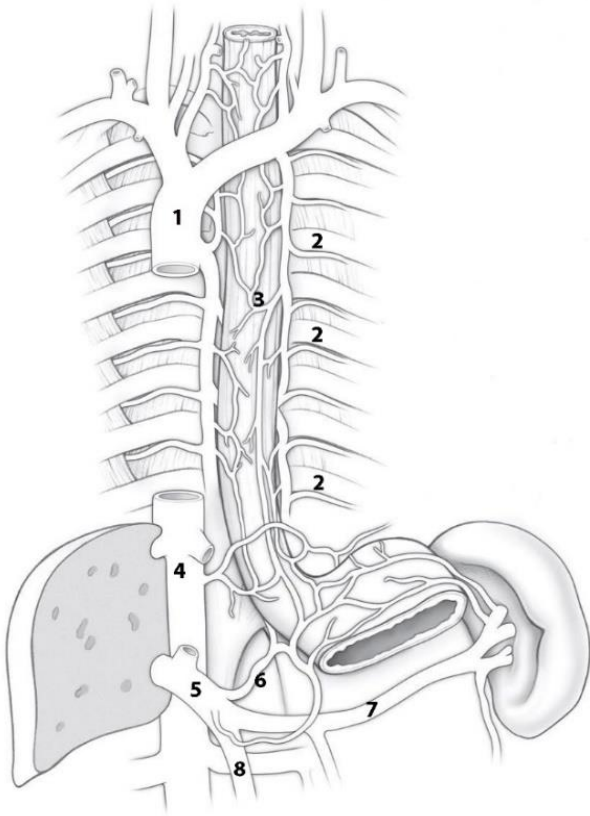
**COLOR** the following venous sinuses, using a different color for each sinus:

- Cavernous sinus
- Sigmoid sinus
- Transverse sinus
- Superior sagittal sinus
- Straight sinus
- Superior petrosal sinus

**WRITE** the name of structures labeled by the number:

1. \_\_\_\_\_
2. \_\_\_\_\_ foramen
3. \_\_\_\_\_ artery

## Azygos venous system



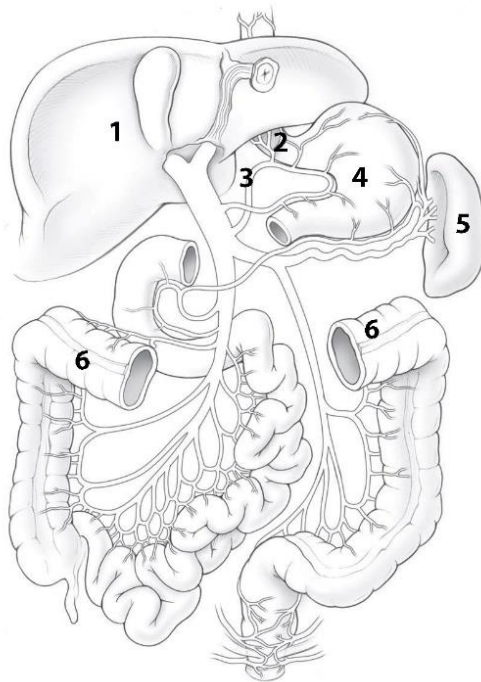
**COLOR** the following veins, using a different color for each vein:

- Right brachiocephalic
- Superior vena cava (SVC)
- Azygos
- Left brachiocephalic
- Accessory hemiazygos
- Hemiazygos

**WRITE** the name of structures labeled by number:

1. \_\_\_\_\_
2. \_\_\_\_\_
3. \_\_\_\_\_ plexus
4. \_\_\_\_\_
5. \_\_\_\_\_
6. \_\_\_\_\_
7. \_\_\_\_\_
8. \_\_\_\_\_

## Hepatic portal system



**COLOR** the following veins that contribute to the portocaval anastomotic system, using the colors suggested for each vein: *Portal* (dark blue). *Superior mesenteric* (purple). *Splenic* (dark red). *Inferior mesenteric* (light blue).

**WRITE** the name of structures labeled by number.

1. \_\_\_\_\_
2. \_\_\_\_\_
3. \_\_\_\_\_
4. Stomach
5. Spleen
6. Transverse colon

## CONTROL QUIZ

1. Hemiazygos vein drains into

---

2. The jugular venous arch forms between

---

3. Hepatic veins drain to

---

4. Which veins drains to the hemiazygos vein?

---

5. External jugular vein drains to

---

6. Name the emissary veins

---

7. Name the diploic veins

---

8. Name the parietal tributaries of inferior vena cava

---

9. Right subclavian trunk drains to

---

10. Right lymphatic trunks forms by

---

# LYMPHOID ORGANS, ENDOCRINE GLANDS

## LABORATORY CLASS № 4

### MORPHOFUNCTIONAL CHARACTERISTICS OF SECONDARY LYMPHOID ORGANS. LYMPH NODES OF THE HEAD AND NECK. ENDOCRINE GLANDS. FINAL LESSON ON «ANGIOLOGY»

#### Control questions:

1. Lymph node (capsule, trabeculae, gates, cortex and medulla).
2. Single and group lymphoid nodules of the mucous membranes of the digestive and respiratory systems.
3. Tonsils.
4. Topography of occipital, mastoid, superficial and deep parotid, facial, submandibular, submandibular nodes. Anterior and lateral cervical lymph nodes.
5. Classification of endocrine glands. Morphofunctional characteristics of the pituitary gland, pineal gland, thyroid gland, parathyroid glands, adrenal gland.

#### Students should be able to find on anatomical preparations and visual aids following structures and to know their Latin names:

1. Lymph nodes of the head.
2. Waldeyer's ring.
3. Lymph nodes of the neck.
4. Pituitary gland.
5. Pineal gland.
6. Thyroid gland.
7. Parathyroid glands.
8. Adrenal gland.

**Repeat:** lymphatic vessels, trunks and ducts.

## GLOSSARY

**Lymphatic system** includes the lymphatic vessels and lymphatic organs. The lymphatic system runs parallel to the venous system and it consists of lymphatic capillaries which start peripherally as blind-ended vessels, the lymphatic vessels and lymph nodes, the major lymphatic trunks (thoracic duct and right lymphatic duct).

**The right lymphatic duct** drains lymph from the right upper quadrant of the body (right side of the head, neck, thorax and right upper limb). It enters the junction of the right internal jugular and right subclavian veins, which is called the right venous angle.

**The thoracic duct** drains lymph from the remainder of the body. The lymphatic trunks draining the lower half of the body merge in the abdomen sometimes forming a dilated collecting sac, which is called the cisterna chyli. From this sac the thoracic duct ascends and enter the left venous angle.

**Lymph nodes** — small, bean-shaped masses of lymphoid tissue enclosed by a capsule of connective tissue that occur in association with the lymphatic vessels, its parenchyma consists of cortex and medulla.

**Waldeyer's ring** consists of four tonsillar structures (namely, the pharyngeal, tubal, palatine and lingual tonsils) as well as small collections of lymphatic tissue disbursed throughout the mucosal lining of the pharynx (mucosa-associated lymphoid tissue, MALT).

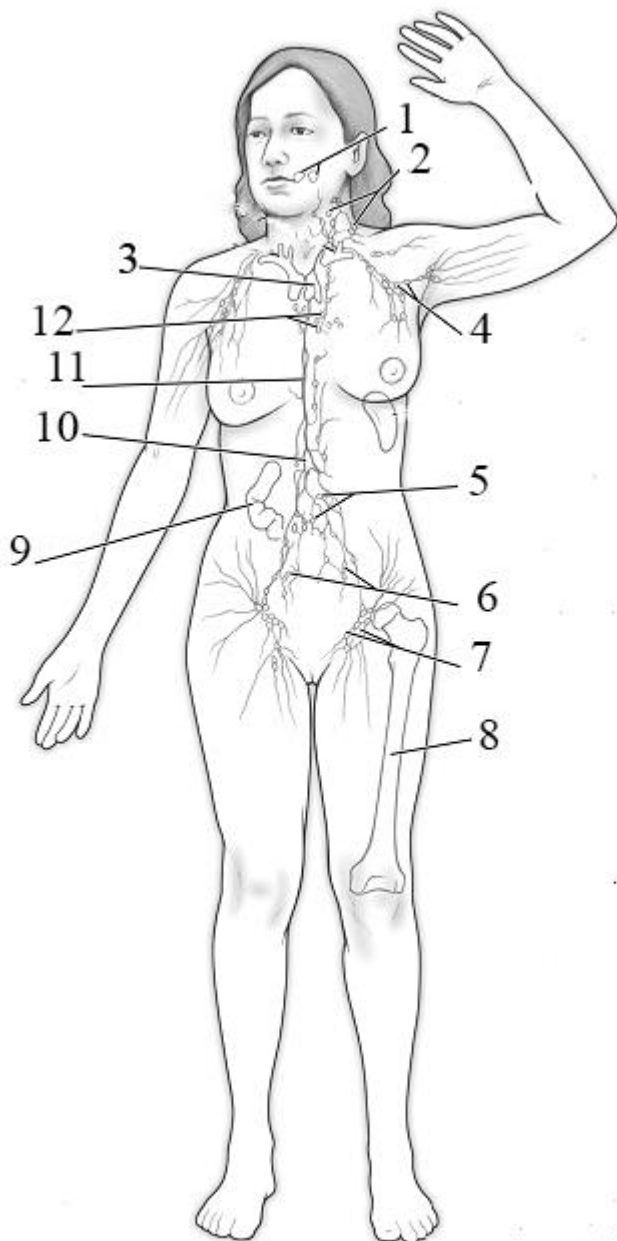
**Endocrine glands** — ductless glands of the endocrine system that secrete their products, hormones, directly into the blood. The major glands of the endocrine system are divided into central and peripheral.

**The central endocrine glands** regulate the activity of other endocrine glands (stimulate or suppress). These include: hypothalamus, pituitary gland, epiphysis.

**Peripheral endocrine glands** affect the receptors of the target organ. These include: thyroid gland, parathyroid glands, adrenal glands.

**Glands that perform endocrine and non-endocrine functions:** gonads, placenta, thymus, pancreas, kidneys.

### SELF-INSTRUCTIONAL MATERIALS



**COLOR** the following structures, using the different color for each of them:

- Spleen
- Thoracic duct
- Right lymphatic duct

**WRITE** the name of structures labeled by the number:

1. Tonsils	
2.	lymph nodes
3.	gland
4.	lymph nodes
5.	lymph nodes
6.	lymph nodes
7.	lymph nodes
8. Bone marrow	
9. Lymphoid nodules of	
10. Cisterna chyli	
11.	duct
12.	lymph nodes

## CONTROL QUIZ TO THE FINAL LESSON ON «ANGIOLOGY»

1. General characteristics and function of cardiovascular system. Systemic and pulmonary circulation.
2. The external structure of the heart. The heart chambers: morphofunctional characteristics of atria and ventricles.
3. The right and left atrioventricular valves; the aortic valve; valve of pulmonary trunk: location, structure, purpose.
4. Tunics of heart wall. The structure of the myocardium. The structure of the pericardium. Pericardial cavity.
5. The cardiac conduction system. Nodes and bundles of the cardiac conduction system; location, function.
6. The blood supply of the heart: the right and left coronary arteries; its branches, areas of blood supply. Ways of outflow of venous blood from the heart.
7. Aorta: parts, bifurcations, terminal branches. The branches of the aortic arch in the order of its origin (right to left), the areas of blood supply.
8. Parietal and visceral branches of the thoracic aorta.
9. Parietal and visceral (paired and unpaired) branches of abdominal aorta.
10. The principles of location and the name of the main arteries of the upper and lower extremities. At what point can determine the radial artery pulsation?
11. Common carotid artery: the place of origin of the right and left common carotid artery; bifurcation, terminal branches.
12. External carotid artery: branches, areas of blood supply. Division of the external carotid artery into anterior (ventral), medial and posterior (dorsal) branches.
13. Maxillary artery: branches of mandibular, pterygoid and pterygopalatine parts; areas of blood supply.
14. Internal carotid artery, segments, the terminal branches. The ophthalmic artery: branches and areas of blood supply.
15. Subclavian artery: the place of origin of the right and left subclavian arteries. The course of the subclavian artery, the division into parts.
16. The arterial (Willis') circle of the brain: localization, formation sources anastomoses, significance.
17. Sources of formation and topography of the superior vena cava. Azygos and hemiazygos veins, their tributaries.
18. Internal jugular vein. Intracranial tributaries: diplopic, emissary, superior and inferior ophthalmic veins. Dural venous sinuses.
19. Extracranial tributaries of internal jugular vein. The course and tributaries of facial and retromandibular vein. Pterygoid plexus.
20. External and anterior jugular veins. Jugular venous arch. Subclavian vein.
21. The system of the inferior vena cava. Parietal and visceral tributaries.
22. Hepatic portal vein system. Its functional significance.
23. Portocaval and cava-caval anastomoses. Examples, significance.
24. The principles of organization veins of upper and lower extremities.
25. Lymphatic trunks and ducts. Sources of formation, direction, the confluence to the venous system.
26. Classification and topography of the regional lymph nodes of the head and neck.

# NERVOUS SYSTEM

## LABORATORY CLASS № 5

### NERVOUS SYSTEM. STRUCTURE, GENERAL DATA. CENTRAL NERVOUS SYSTEM. SPINAL CORD

#### Control questions:

1. Nervous system: the classification: topographical and anatomical, functional principles for the body.
2. Spinal cord: boundaries, parts.
3. The external structure of the spinal cord: fissures, grooves. Anterior and posterior roots, cauda equina. Spinal cord segment.
4. The structure of white and gray matter of the spinal cord. The central canal.
5. The brain: parts.
6. Borders and the structure of the medulla oblongata. Topography of gray matter nuclei.
7. Pons: borders, external and internal structure, the nucleus.
8. Rhomboid fossa: a relief, projection of cranial nerves nuclei. The fourth ventricle: walls, connection to other cavities of the brain and the subarachnoid space.
9. Cerebellum: parts, fissures, folium cerebellum. Cerebellum peduncles. Gray and white matter.
10. The midbrain: peduncle, tectum, cerebral aqueduct. Topography of nuclei gray matter.
11. The reticular formation of the brain, the localization and functional significance.

#### Students should be able to find on anatomical preparations and visual aids following structures and to know their Latin names:

1. Spinal cord. 2. Cervical, lumbosacral enlargement. 3. Anterior median fissure. 4. Posterior median fissure. 5. Anterior (posterior) lateral sulcus. 6. Anterior (lateral, posterior) funiculus. 7. Anterior (lateral, posterior) horn. 8. The central canal. 9. Medulla oblongata. 10. Pyramid. 11. Oliva. 12. Pons. 13. Basilar sulcus. 14. Cerebellum. 15. Cerebellar hemispheres. 16. Vermis. 17. Anterior (middle, posterior) cerebellar peduncle. 18. Midbrain. 19. Cerebral peduncles. 20. Superior (inferior) colliculus of tectum. 21. Cerebral aqueduct.

**Repeat:** vertebral column; base of the skull.

## GLOSSARY

**Nervous system** is a complex of anatomically and functionally interconnected nervous structures that regulate and coordinate the activity of the human body and its interaction with the environment. According to the topographic principle nervous system conventionally divided into central (CNS) (brain and spinal cord) and peripheral (PNS) (includes 12 pairs of cranial nerves, 31 pairs of spinal nerves and its branches, plexus and ganglia).

**Spinal cord** — is a long, thin, tubular structure made up of nervous tissue, which located in the spinal canal. At the upper edge of the atlas spinal cord goes into the medulla oblongata, and at the level of the 2nd lumbar vertebra it ends by cauda equina. The spinal cord consists of central grey matter surrounded by columns of white matter.

**The anterior/ventral (motor) root (radix anterior)** contains efferent nerve fibers, which carry stimuli away from the CNS towards their target structures. The cell bodies of the anterior root neurons are located in the anterior horns grey matter of the spinal cord.

**The posterior/dorsal (sensitive) root (radix posterior)** consists of the central processes of the pseudounipolar neurons of which are located in the spinal ganglion. The anterior and posterior roots fuse and form spinal nerve. There are 62 pairs of roots (31 anterior and 31 posterior).

**Cauda equina** — is a bundle of spinal nerve roots, beginning of the lower lumbar, sacral and coccygeal segments of the spinal cord below the 2nd lumbar vertebra.

**Spinal cord segment** — is a section of the spinal cord corresponding to two pairs of roots (2 anterior and 2 posterior). There are the following groups of segments: cervical, thoracic, lumbar, sacral and coccygeal.

**The brain (encephalon)** presents three main divisions: *forebrain* (prosencephalon), *mid-brain* (mesencephalon), and *hindbrain* (rhombencephalon). The *forebrain* in turn has two subdivisions, *telencephalon* and *diencephalon*. The *hindbrain* likewise has two subdivisions, *metencephalon* and *myelencephalon*. The *metencephalon* contains structures such as the *pons* and *cerebellum*. The *myelencephalon* is composed of the *medulla oblongata*. The *midbrain* and the *pons* and *medulla oblongata* together make up the *brainstem*. The brain is contained in, and protected by, the skull bones of the head.

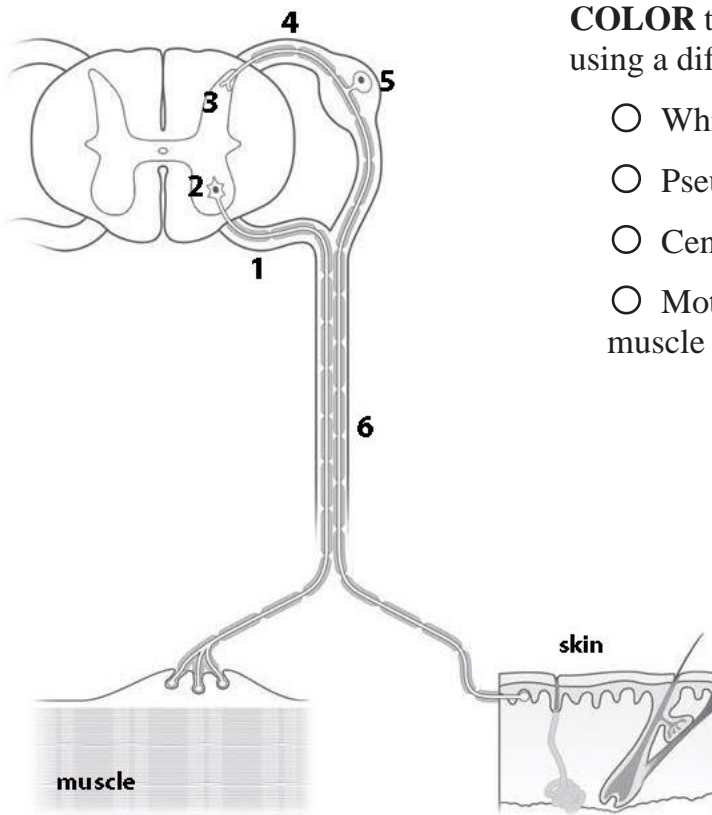
**The fourth ventricle** — is one of the four connected fluid-filled cavities within the human brain. It is the most inferiorly located ventricle, draining directly into the central canal of the spinal cord. Superiorly, it connects to the third ventricle through a thin canal called the cerebral aqueduct of Sylvius. Three holes in the roof of the fourth ventricle (medial and paired lateral paired apertures) provide communicating with the subarachnoid space of the brain.

**Rhomboid fossa** — is the shallow, diamond shaped depression on the dorsal surface of the pons and medulla oblongata that forms the floor of the fourth ventricle. Here lie the nuclei of cranial nerves V-XII.

**The reticular formation** — is a complex network of brainstem nuclei and neurons. The reticular formation is associated with all the senses, mobility and sensitivity areas of the cerebral cortex of the brain, the thalamus and the hypothalamus, spinal cord. It adjusts the level of excitability and tone different parts of the central nervous system.

## SELF-INSTRUCTIONAL MATERIALS

### Somatic nerve



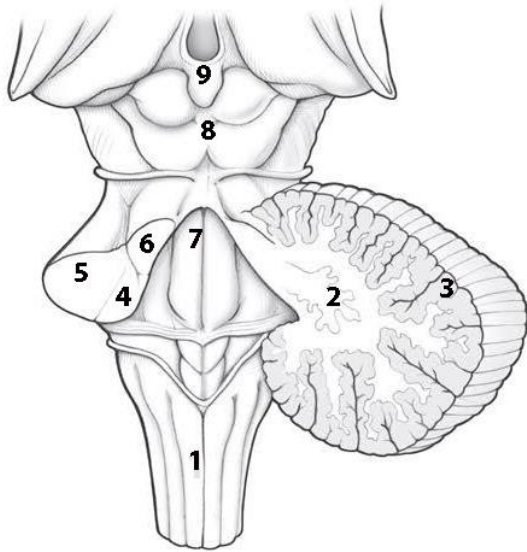
**COLOR** the following structures of the spinal cord, using a different color for each feature:

- White matter of spinal cord
- Pseudounipolar neuron and its axon
- Central gray matter of the spinal cord
- Motor neuron and its axon to the skeletal muscle

**WRITE** the names of structures labeled by the number:

1.	root
2.	horn
3.	horn
4.	root
5.	
6.	

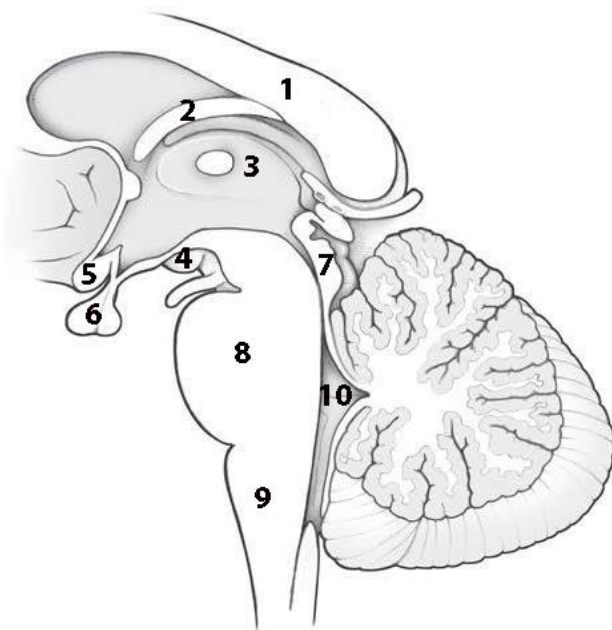
### Brain stem and cerebellum (posterior view)



**WRITE** the names of structures labeled by the number:

- |    |              |
|----|--------------|
| 1. |              |
| 2. | nucleus      |
| 3. | cortex       |
| 4. |              |
| 5. |              |
| 6. |              |
| 7. |              |
| 8. | plate        |
| 9. | Pineal gland |

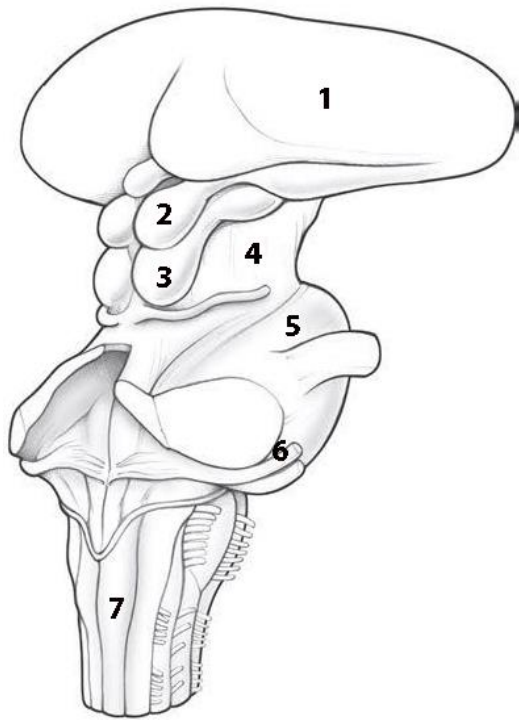
### Brain stem (Median sagittal section)



**WRITE** the names of structures labeled by the number:

- |     |                |
|-----|----------------|
| 1.  |                |
| 2.  | Body of fornix |
| 3.  |                |
| 4.  | body           |
| 5.  | Optic chiasm   |
| 6.  | Hypophysis     |
| 7.  |                |
| 8.  |                |
| 9.  |                |
| 10. |                |

## Brain stem (posterolateral view)



**WRITE** the names of structures labeled by the number:

1. Thalamus

2.

3.

4.

5.

6.

nerve

7.

## CONTROL QUIZ

1. Spinal cord consists of

2. Spinal ganglia are located at

and contain

neurons

3. Brainstem consists of

4. The ventral surface of the medulla oblongata contains

5. Name the sulcus at the ventral surface of the pons

6. The main nuclei of midbrain are

7. The cavity of the midbrain is

and contain

8. Quadrigeminal plate contain

9. Cerebellum has

pairs of peduncles

10. Name the cerebellar nuclei

## LABORATORY CLASS № 6

### BRAIN. PATHWAYS OF BRAIN AND SPINAL CORD

#### Control questions:

1. Diencephalon (thalamus, epithalamus, metathalamus, hypothalamus): morphological and functional characteristic.
2. The third ventricle: walls, connections to other brain cavities.
3. Cerebral hemispheres: the surfaces, fissures, lobes, gyri.
4. Location of somatomotor and somatosensory cortex, the nuclei of the auditory, visual and olfactory analyzers.
5. Basal nuclei and related structures. The white matter of the cerebral hemisphere, commissural, association, and projection nerve fibers.
6. The lateral ventricle: localization, parts, the functional significance of the choroid plexus.
7. Classification of nerve pathways of the brain and spinal cord. General plan of structure of the ascending (afferent) and descending (efferent) pathways.
8. The nerve pathways of general sensitivity from head and neck.
9. The nerve pathway of proprioceptive sensitivity from the head muscles and temporomandibular joint.
10. The motor pathway to the head and neck muscles.

#### Students should be able to find on anatomical preparations and visual aids following structures and to know their Latin names:

1. Cerebral hemispheres. 2. Frontal, parietal, temporal, occipital lobes, insula. 3. The lateral sulcus. 4. The central sulcus. 5. Precentral sulcus. 6. The superior (inferior) frontal sulcus. 7. Precentral gyrus. 8. Superior (middle, inferior) frontal gyrus. 9. Parieto-occipital sulcus. 10. Postcentral sulcus. 11. Postcentral gyrus. 12. The superior (middle, inferior) temporal sulcus. 13. The superior (middle, inferior) temporal gyrus. 14. Sulcus of corpus callosum. 15. Hippocampal sulcus. 16. Cingulate gyrus. 17. Parahippocampal gyrus. 18. Fornicate gyrus. 19. Calcarine sulcus. 20. Caudate nucleus. 21. Lentiform nucleus. 22. Claustrum. 23. External capsule. 24. Internal capsule. 25. Corpus callosum. 26. Lateral ventricle. 27. Interventricular foramina. 28. Diencephalon. 29. Thalamus. 30. Metathalamus. 31. Epithalamus. 32. Hypothalamus. 33. The third ventricle.

**Repeat:** muscles of the head; temporomandibular joint.

## GLOSSARY

**Diencephalon** is the central portion of the brain located around the third ventricle, superior to the brainstem (medulla, pons and midbrain), and inferior to the corpus callosum and cerebral cortex. It is divided into four main parts including the epithalamus, thalamus, subthalamus, and hypothalamus.

**The third ventricle** — is the narrow vertical cavity of the diencephalon. The third ventricle communicates with the lateral ventricles of hemispheres by paired interventricular foramen; through the opening of the cerebral aqueduct — with the IV ventricle. The *lateral walls* of the third ventricle are formed by the medial surfaces of the thalamus. The *anterior wall* of the ventricle is formed from below by a thin plate, lamina terminalis, and columnae fornicis. The *roof* of the third ventricle, lying under the fornix and corpus callosum, is the tela choroidea.

**Telencephalon** consists of the right and left hemispheres, which are separated by deep longitudinal groove and connected by corpus callosum. Each hemisphere is divided into frontal, parietal, temporal, occipital lobes and the insula by interlobar sulcus (central, lateral, parieto-occipital). Small furrows divide hemispheres into gyrus.

**Cerebral cortex** — grey matter, covering the outside of the cerebral hemisphere. The structure and the relative positions of neurons are differently in different areas of the cortex. It determines localization centers that regulate various functions.

**The white matter of the cerebral hemispheres** — consists mostly of glial cells and myelinated nerve fibers (axons) that connect the cerebral cortex with other departments of the central nervous system (*projection fibers*), parts of the cortex within one hemisphere (*association fibers*), the cerebral cortex of the right and left hemispheres together (*commissural fibers*).

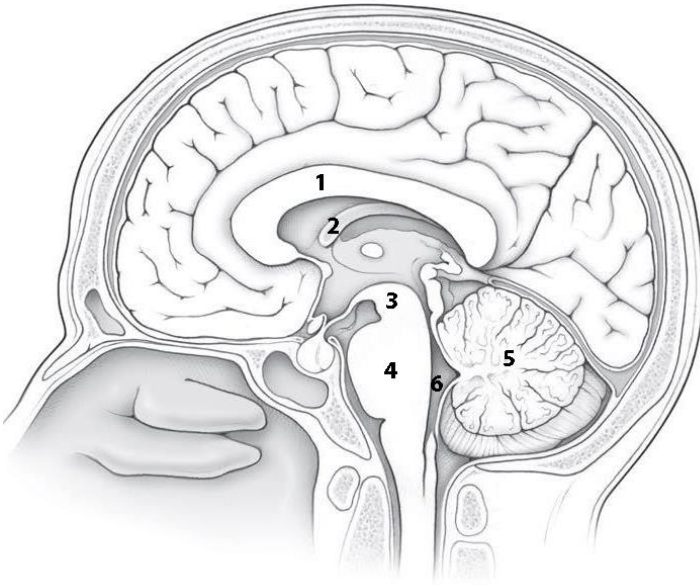
**The lateral ventricles** are two c-shaped cavities one on each side of cerebral hemisphere — It consists of a central part called body (in the parietal lobe) and three extensions: anterior (frontal horn in the frontal lobe), posterior (occipital horn in the occipital lobe), and inferior (temporal horn in the temporal lobe). Through the interventricular foramen lateral ventricle communicates with the third ventricle.

**The basal nuclei** — clusters of gray matter inside the cerebral hemispheres. There are three nuclei: *corpus striatum*, *claustrum* and *amygdaloid body*. *Corpus striatum* consists of two parts — caudate nucleus and lentiform nucleus, which are separated by white matter — *internal capsule*. Medially caudate nucleus locates near thalamus. Lentiform nucleus is laterally to the caudate nucleus and thalamus. It's divided into three segments: *putamen* (outside) and two *globus pallidus* (inside). Caudate and lentiform nuclei are striopallidar system, which is the main part of the extrapyramidal system and the main center of autonomic functions (thermoregulation and carbohydrate metabolism). *Claustrum* is a thin plate of gray matter, in the insula, separated from putamen by layer of white matter, from insula cortex by extreme capsule. The amygdaloid body is located under putamen in the anterior part of temporal lobe. It is subcortical olfactory and limbic center.

**Neural pathways** of the brain and spinal cord - anatomically and functionally interconnected neurons that providing transmission of nerve impulses in a determine direction. They are divided into ascending (afferent, sensory) and descending (efferent, motor). Ascending tracts transmit impulses from the skin, mucous membranes, internal organs and organs of movement to the nuclei of the brain stem, basal nuclei and the cerebral cortex of the brain. The descending pathways conduct impulses from the cerebral cortex to the brainstem nuclei and motor nuclei of anterior horns of the spinal cord and divided into pyramidal and extrapyramidal.

## SELF-INSTRUCTIONAL MATERIALS

### Midsagittal section of the head



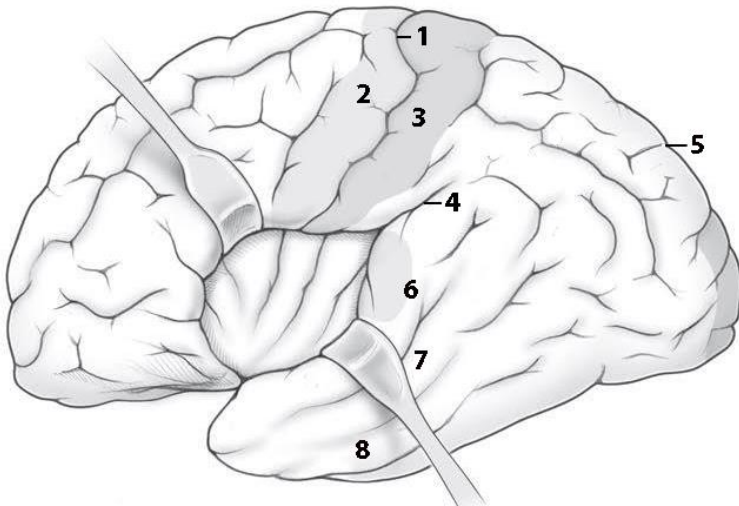
**COLOR** each of the following structures, using a different color for each of them:

- Pineal gland
- Optic chiasm
- Mammillary bodies
- Thalamus
- Medulla oblongata

**WRITE** the names of structures labeled by the number:

1.	4.
2. Fornix	5.
3.	6.

### Cerebral hemisphere (lateral view)



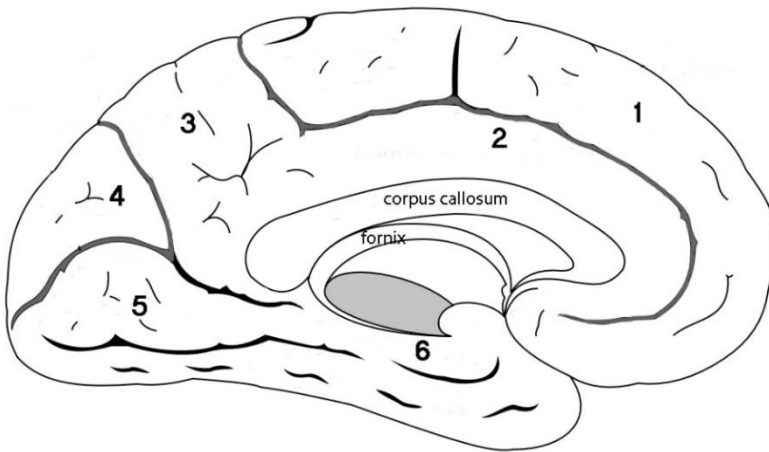
**COLOR** the five lobes of the cerebral cortex, using a different color for each lobe:

- Frontal lobe
- Parietal lobe
- Occipital lobe
- Temporal lobe
- Insula

**WRITE** the names of structures labeled by the number:

1.	sulcus	5.	sulcus
2.	gyrus	6.	gyrus
3.	gyrus	7.	gyrus
4.	sulcus	8.	gyrus

### Cerebral hemisphere (medial view)



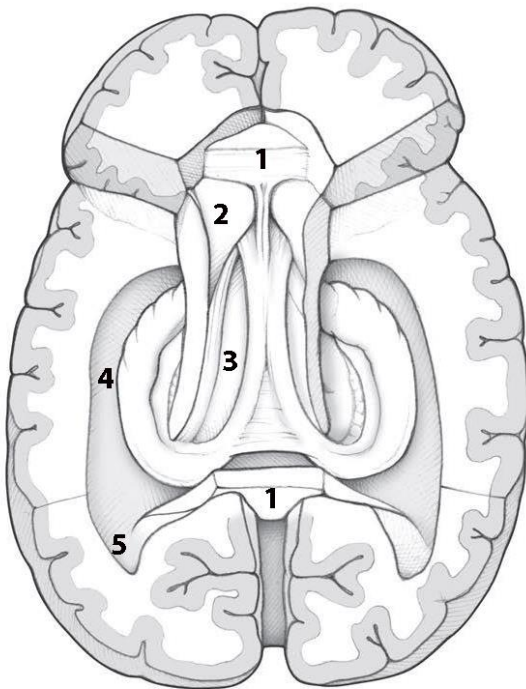
**COLOR** the following sulci, using a different color for each of them:

- Calcarine sulcus
- Parieto-occipital sulcus
- Cingulate sulcus

**WRITE** the names of structures labeled by the number:

1.	gyrus	4.	
2.	gyrus	5.	gyrus
3.		6.	gyrus

### Horizontal dissection of the brain



**COLOR** the following structures, using a different color for each of them:

- Body of the fornix
- Crura («legs») of the fornix
- Dentate gyrus
- Hippocampus

**WRITE** the name of structures labeled by the number:

1.	Corpus
2.	Head of
3.	
4.	
5.	horn of ventricle

## CONTROL QUIZ

1. Metathalamus consists of

---

2. Hypothalamus consists of

---

3. Epithalamus consists of

---

4. Name the surfaces of cerebral hemisphere

---

5. The calcarine sulcus is cortical center of

---

6. The basal ganglia are responsible for

---

7. Neural pathways of nervous system divided into

---

8. Cortical center of olfactory analyzer locates at

---

9. Cortical center of general sensitivity locates at

---

10. Name the horns of lateral ventricle

---

## LABORATORY CLASS № 7

### MENINGES. THE PERIPHERAL NERVOUS SYSTEM

#### Control questions:

1. Dura, arachnoid and pia mater of brain and spinal cord.
2. Localization of dura mater folds.
3. Sinuses of dura mater. Confluence of sinuses.
4. Arachnoid and pia mater. Subarachnoid space. Arachnoid granulations.
5. Production and circulation of cerebrospinal fluid.
6. Blood supply of the brain. The circle of Willis.
7. The peripheral nervous system: ganglions, nerves, plexus.
8. Spinal nerve: sources of formation; branches and the area of innervation. General principles innervation of skin and skeletal muscles.
9. Cervical plexus: sources of formation; topography of motor and sensitive branches; innervation area.
10. Phrenic nerve: fiber composition, topography, areas of innervation.

#### Students should be able to find on anatomical preparations and visual aids following structures and to know their Latin names:

1. Dura mater of the brain.
2. Falx cerebri (cerebellum).
3. Tentorium cerebelli.
4. Arachnoid mater of the brain (spinal cord).
5. Pia mater of the brain.
6. Subarachnoid space.
7. Cerebrospinal fluid.
8. The superior (inferior) sagittal sinus.
9. Straight sinus.
10. Transverse sinus.
11. Occipital sinus.
12. Sigmoid sinus.
13. Cavernous sinus.
14. The superior (inferior) petrosal sinuses.
15. Confluence of sinuses.
16. Cervical plexus.
17. Lesser occipital nerve.
18. Great auricular nerve.
19. Transverse cervical nerve.
20. Supraclavicular nerves.
21. Ansa cervicalis.
22. Phrenic nerve.

**Repeat:** muscles and fascia of the neck. Diaphragm.

## GLOSSARY

**The dura mater** is a thick membrane made of dense irregular connective tissue that surrounds the brain and spinal cord. It is the outermost of the three layers of membrane called the meninges that protect the central nervous system. The dura mater surrounds and supports the dural venous sinuses. Cranial dura mater has *two layers* called lamellae, a *superficial layer* (also called the periosteal layer), which serves as the skull's inner periosteum, called the endocranium and a *deep layer* called the meningeal layer. Unlike cranial dura mater, spinal dura mater only has one layer, known as the meningeal layer. The potential space between these two layers is known as the epidural space.

**Dural venous sinuses** — are endothelial-lined sinuses, which lie between the two layers of dura (meningeal and endosteal layers). Unlike veins, their walls do not collapse or contain muscle layer. Sinuses collect blood from veins of the brain, and involved the reabsorption of cerebrospinal fluid from the subarachnoid space of the brain. Blood enters into the internal jugular vein from sinuses. Cerebrospinal fluid from the subarachnoid space of the brain reabsorb to the sinuses.

**The arachnoid mater** of the spinal cord/brain is the middle layer of meninges, is located inner from the dura mater and separated from it by the *subdural space*. It is separated from the pia mater by the *subarachnoid space* containing the cerebrospinal fluid

**Cerebrospinal fluid (CSF)** is a clear, colorless body fluid found the brain ventricles the and subarachnoid space surrounds the brain and spinal cord. CSF is produced by specialized ependymal cells in the choroid plexus of the ventricles of the brain, and absorbed in the arachnoid granulations.

**The pia mater** is the inner layer of the meninges. It fits to the surface of the brain, goes into all the sulci. It consists of loose connective tissue, in the thickness of which there are blood vessels that provide nutrition to the brain.

**Spinal nerve** is a mixed nerve, formed from the combination of nerve fibers from its dorsal and ventral roots. The spinal nerve emerges from the vertebral column through an intervertebral foramen. This is true for all spinal nerves except for the first spinal nerve pair (C1), which emerges between the occipital bone and the atlas (the first vertebra). Outside the vertebral column, the nerve divides into branches. The *posterior ramus* contains nerves that serve the posterior portions of the trunk carrying visceral motor, somatic motor, and somatic sensory information to and from the skin and muscles of the back. The *anterior ramus* contains nerves that serve the remaining anterior parts of the trunk and the upper and lower limbs. Some anterior rami merge with adjacent anterior rami to form a nerve plexus. Major plexuses include the *cervical, brachial, lumbar, and sacral plexuses*. The *meningeal branch* from the spinal nerve and re-enter the intervertebral foramen to serve the ligaments, dura, blood vessels, intervertebral discs, facet joints, and periosteum of the vertebrae. The *rami communicans* contain autonomic nerves that serve visceral functions carrying visceral motor and sensory information to and from the visceral organs.

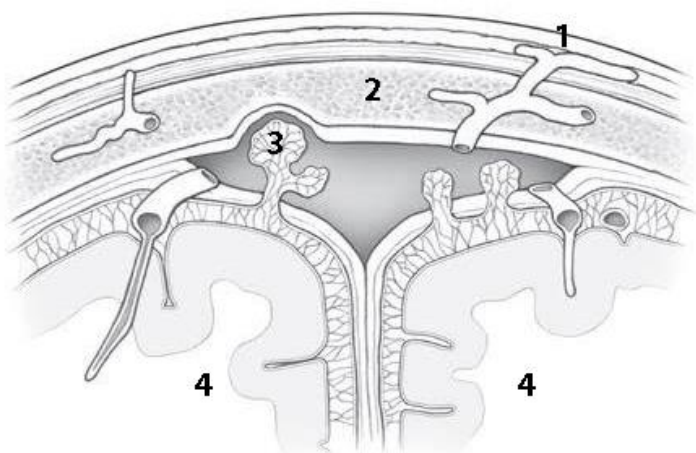
**Cervical plexus** — is a network of the anterior rami of the first four cervical spinal nerves from C<sub>1</sub> to C<sub>4</sub>. Located on the anterolateral surface of the deep muscles of the neck; outside it is covered sternocleidomastoid muscle. Plexus has cutaneous, muscular and mixed branches. The cutaneous branches of the plexus are the lesser occipital nerve, the great auricular nerve, the transverse cervical nerve, and the supraclavicular nerves. The exit point of these nerves into the subcutaneous tissue is projected to the middle of the posterior edge of the sternocleidomastoid muscle (Erb's point).

**Ansa cervicalis** formed by the inferior and superior roots, which originate from the cervical plexus and the hypoglossal nerve, respectively; it innervates infrahyoid muscles.

**Phrenic nerve** — mixed branch of the cervical plexus. Innervate the diaphragm (motor fibers), pericardium, pleura, peritoneum, liver and its ligaments (sensory fibers).

## SELF-INSTRUCTIONAL MATERIALS

### Arachnoid granulations



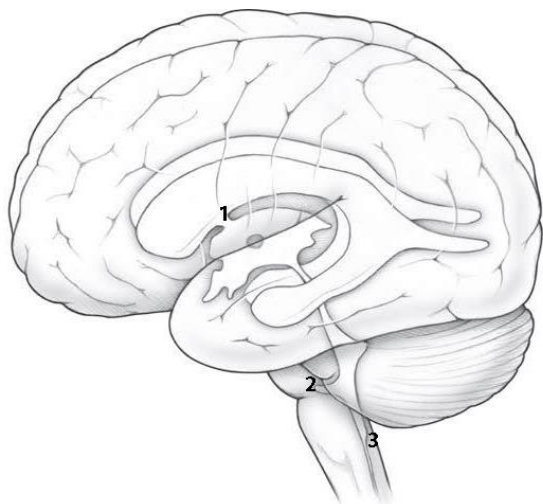
**COLOR** the features of the arachnoid granulations, using the following color scheme:

- Pia mater covering the cerebrum (green)
- Arachnoid mater and its granulations (red)
- Dura mater splitting to create the dural venous sinus (yellow)

**WRITE** the name of structures labeled by the number:

1.	vein
2.	bone
3.	
4.	hemisphere

### Schematic lateral view of ventricles of the brain



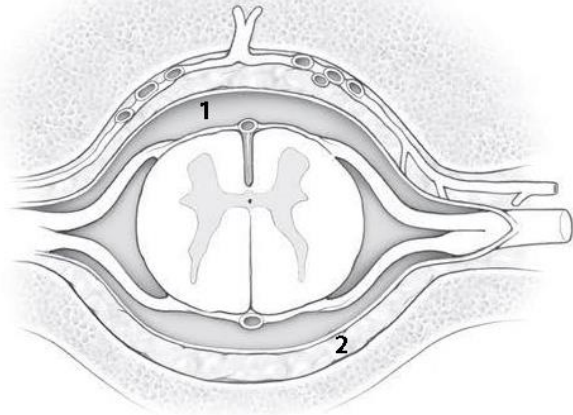
**COLOR** the following structures of the ventricular system, using a different color for each structure:

- Lateral ventricles
- 3rd ventricle
- Cerebral aqueduct (of Sylvius)
- Fourth ventricle

**WRITE** the name of structures labeled by the number:

1.	foramen
2.	aperture
3.	aperture

## Space surrounding the spinal cord (cross section)



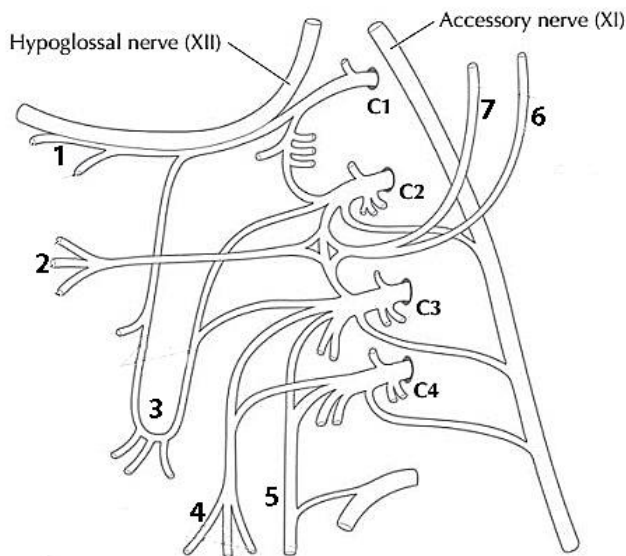
**COLOR** all three meningeal layers of the spinal cord as seen in section, using a different color for each layer:

- Dura mater
- Arachnoid mater
- Pia mater

**WRITE** the name of structures labeled by the number:

- |    |       |
|----|-------|
| 1. | space |
| 2. | space |

## Cervical plexus: schema



**COLOR** the following branches of the cervical plexus using the following color scheme: motor branches (red), sensory branches (blue), mixed branch (yellow).

**WRITE** the name of structures labeled by the number:

- |  |
|--|
| 1. Nerves to the geniohyoid and thyrohyoid muscles |
| 2.   |
| 3.   |
| 4.   |
| 5.   |
| 6.   |
| 7.   |

## CONTROL QUIZ

1. Peripheral nervous system are \_\_\_\_\_
2. Between the dura mater and arachnoid locates \_\_\_\_\_ space
3. Ansa cervicalis is formed by \_\_\_\_\_
4. Phrenic nerve innervates \_\_\_\_\_
5. Ansa cervicalis innervates \_\_\_\_\_
6. Which meninges does not have blood vessels? \_\_\_\_\_
7. Straight sinus located along line \_\_\_\_\_
8. Name the folds of dura mater \_\_\_\_\_
9. Name the sinus of dura mater where III<sup>d</sup>, IV<sup>th</sup>, V<sup>th</sup> cranial nerves locate \_\_\_\_\_
10. Cervical plexus forms by the \_\_\_\_\_ rami of C<sub>1</sub> - C<sub>4</sub> spinal nerves

## LABORATORY CLASS № 8

### CRANIAL NERVES. ANATOMY OF THE OCULOMOTOR, TROCHLEAR, TRIGEMINAL AND ABDUCENT NERVES

#### Control questions:

1. Cranial nerves: general characteristics; classification.
2. Oculomotor nerve [III]: the nucleus, localization and function; place the nerve exit from the brain and the cranial cavity; innervation area.
3. Trochlear [IV] a nerve: nucleus, localization and function; the place of exit of the brain and the cranial cavity; innervation area.
4. Trigeminal nerve [V]: nucleus, localization and function; motor and sensory root; place the nerve exit from the brain; trigeminal ganglion.
5. The branches of the trigeminal nerve and exit place from the cranial cavity.
6. Ophthalmic nerve [V1]: branches, area of innervation.
7. Maxillary nerve [V2]: branches, area of innervation.
8. Mandibular nerve [V3]: the branches, the qualitative composition of nerve fibers; area of innervation.
9. Abducent nerve [VI]: nucleus, localization and function; places it emerges from brain and cranial cavity; innervation area.

#### Students should be able to find on anatomical preparations and visual aids following structures and to know their Latin names:

1. Oculomotor nerve.
2. Ciliary ganglion.
3. Trochlear nerve.
4. Trigeminal nerve.
5. Trigeminal ganglion.
6. Optic nerve.
7. Lacrimal nerve.
8. The frontal nerve.
9. Nasociliary nerve.
10. Maxillary nerve.
11. Zygomatic nerve.
12. Infraorbital nerve.
13. Superior alveolar nerves (anterior, middle and posterior upper alveolar branch).
14. Inferior alveolar nerve.
15. Buccal nerve.
16. Auriculotemporal nerve.
17. Lingual nerve.
18. Inferior alveolar nerve.
19. Mental nerve.
20. Abducens nerve.

**Repeat:** orbit. Foramina and canals of cranial base. Masticatory muscles.

## GLOSSARY

**Cranial nerves** — are the 12 pairs of nerves that emerge directly from the brain. They are described with Roman numerals I–XII. By functional composition cranial nerves combined in the three groups. **Motor** nerves are oculomotor [III], trochlear [IV], abducent [VI], accessory [XI] and hypoglossal [XII] nerves that contain in its composition mainly motor nerve fibers. **The group of sensitive:** olfactory [I], optic [II] and vestibulocochlear [VIII] nerves, respectively providing the sense of smell, sight, hearing and vestibular function. **Mixed nerves** are trigeminal [V], facial (with intermediate nerve) [VII], glossopharyngeal [IX] and vagus [X] nerves, containing afferent, efferent somatic and preganglionic parasympathetic nerve fibers.

**Oculomotor nerve** — the third pair of cranial nerves. It emerges from the brainstem at the medial edge of the brain, from the skull — through the *superior orbital fissure*. It has *two* nuclei. Somatic motor fibers begin from neurons of the nucleus of the oculomotor nerve, which lies on superior colliculus of midbrain. It innervates the external muscles of the eyeball (superior, inferior, medial rectus, inferior oblique muscle, levator palpebrae superioris). From the accessory nucleus of the oculomotor nerve begin preganglionic parasympathetic fibers finished in the ciliary ganglion cells. Postganglionic fibers begin from ciliary ganglion (short ciliary nerves) and innervate the ciliary muscle and the sphincter pupillae.

**Trochlear nerve** — the fourth pair of cranial nerves. It goes on the dorsal surface of the brainstem, then from the lateral side turns the cerebral peduncle and through the *superior orbital fissure* goes into the orbit. It contains somatic motor fibers, which start from the nucleus of the trochlear nerve, lying in inferior colliculus of midbrain. It innervates the superior oblique muscle of the eyeball.

**Trigeminal nerve** — the fifth pair of cranial nerves. It emerges from the brain between pons and the middle peduncle of the cerebellum, from the cranial cavity — through the *superior orbital fissure* (the first branch), *foramen rotundum* (the second branch) and the *foramen ovale* (the third branch). The nerve has sensory and somatic motor fibers. The bodies of sensory neurons are in the *trigeminal ganglion*. Their central processes finished in mesencephalic nucleus, principal sensory nucleus and spinal nucleus of trigeminal nerve located in the dorsal regions of the midbrain, pons and medulla oblongata, respectively. Motor fibers originate from neurons in the motor nucleus of the trigeminal nerve, which lies in the dorsal part of the pons.

**Ophthalmic nerve [V1]** — the first branch of the trigeminal nerve. It supplies the skin of forehead, upper eyelid, dorsum of nose, the medial conjunctiva of the eye, eyeball layers, lacrimal gland, mucosa of anterior part of nasal cavity and the ethmoid cells.

**The maxillary nerve [V2]** — the second branch of the trigeminal nerve. It supplies the dura mater of the brain, the skin of the lower eyelid, zygomatic, anterior temporal region, cheeks, upper lip and nose wings, lateral angle of the eye, mucous of palate, nasal cavity, sphenoid and maxillary sinuses, as well as the teeth and gums of the upper jaw.

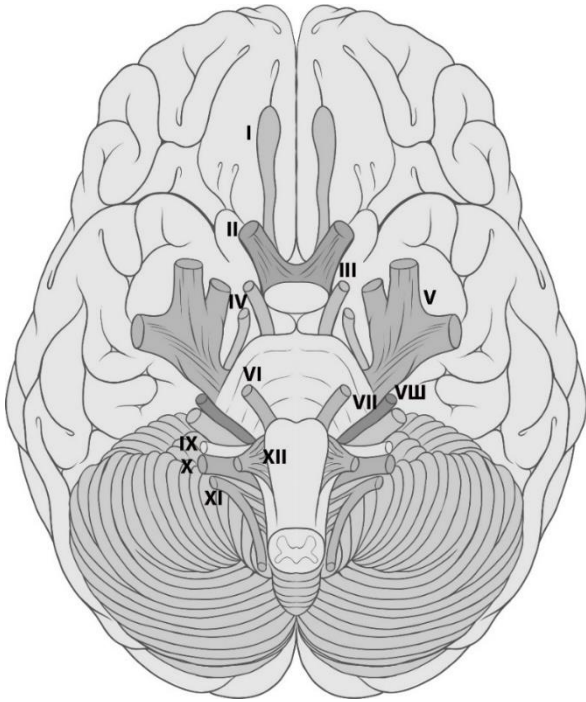
**Mandibular nerve [V3]** — the third branch of the trigeminal nerve. The composition with sensory fibers innervates the dura mater of the brain, the skin of the lower lip, chin, cheek, ear and the external auditory canal, part of the tympanic membrane, buccal mucosa, floor of the mouth and the anterior two-thirds of the tongue, the teeth and gums of the lower jaw. Motor fibers innervate all the masticatory muscles, mylohyoid muscle, anterior belly of the digastric muscle and tensor tympani and veli palatini muscles.

**Abducent nerve** — the sixth pair of cranial nerves. It appears from the brain between the pyramid and pons, from the cranial cavity — through the *superior orbital fissure*. It contains somatic motor fibers, which start from the abducent nucleus lying in the dorsal part of pons. It innervates lateral rectus muscle.

## SELF-INSTRUCTIONAL MATERIALS

### The location of the cranial nerves on the cerebrum and brainstem

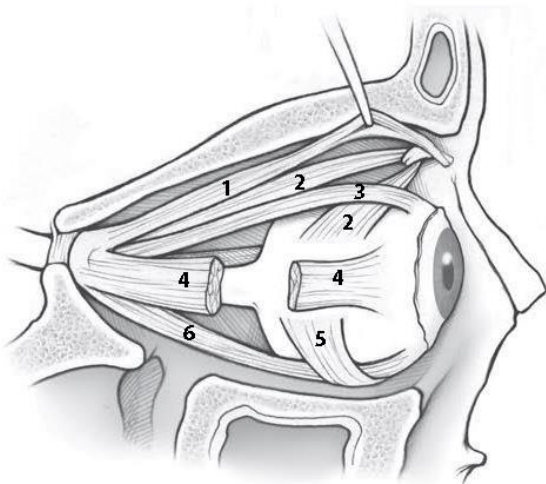
**COLOR** the following cranial nerve, using the following color scheme: motor nerve (red), sensory nerves (blue), mixed nerve (yellow).



**WRITE** the names of structures labeled by the number:

1. \_\_\_\_\_
2. \_\_\_\_\_
3. \_\_\_\_\_
4. \_\_\_\_\_
5. \_\_\_\_\_
6. \_\_\_\_\_
7. \_\_\_\_\_
8. \_\_\_\_\_
9. \_\_\_\_\_
10. \_\_\_\_\_
11. \_\_\_\_\_
12. \_\_\_\_\_

### Extraocular muscle innervation



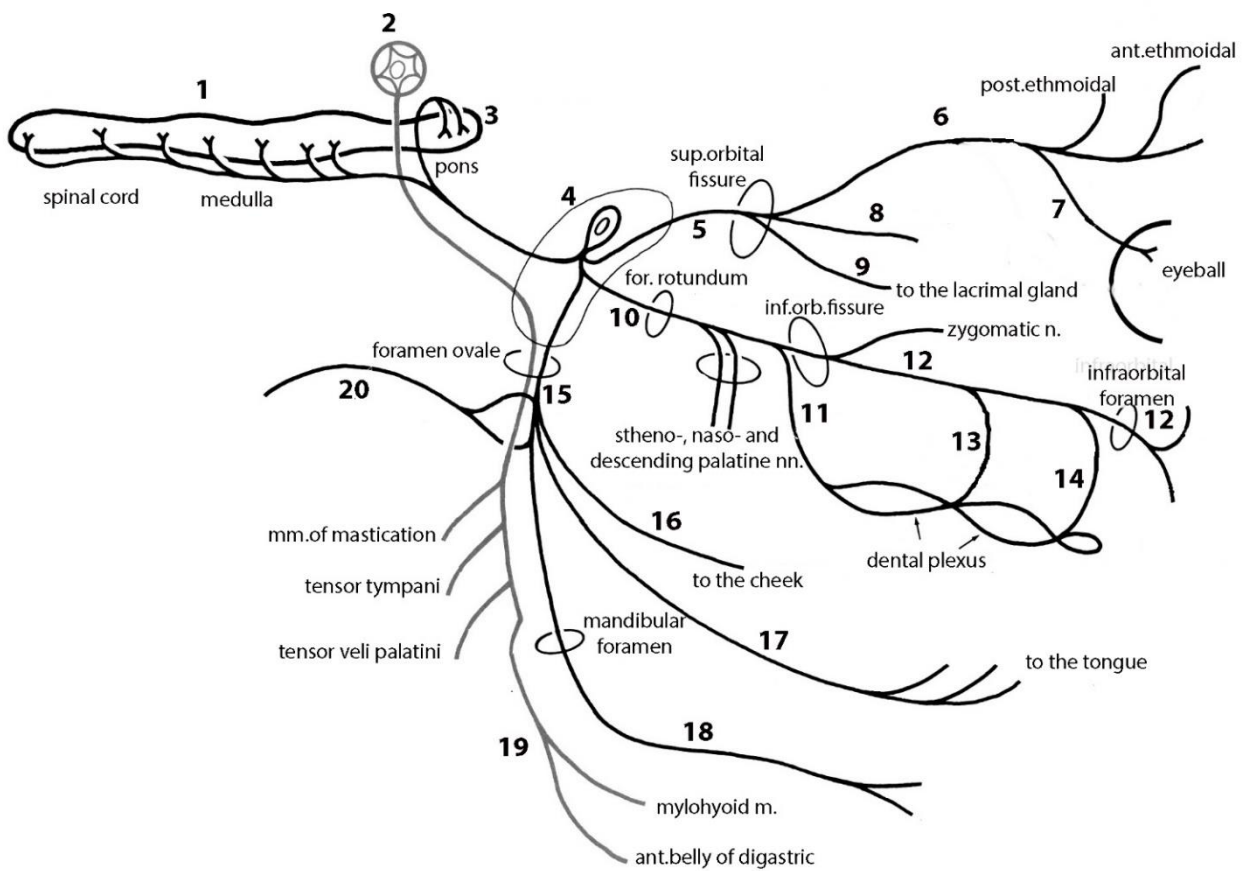
**COLOR** the extra-ocular muscles, using the following color a scheme: muscles supply by *oculomotor nerve* (red), *trochlear nerve* (blue), *abducens nerve* (yellow).

**WRITE** the name of structures labeled by the number

- |    |        |
|----|--------|
| 1. | muscle |
| 2. | muscle |
| 3. | muscle |
| 4. | muscle |
| 5. | muscle |
| 6. | muscle |

## Three divisions of the trigeminal nerve (scheme)

**COLOR** (in red) somatic motor axon and nerve cell body.



**WRITE** the name of structures labeled by the number:

1.	nucleus of	11.	branches
2.	nucleus	12.	
3.	nucleus	13.	branches
4.	ganglion	14.	branches
5.		15.	
6.		16.	
7.		17.	
8.		18.	
9.		19.	
10.		20.	

## CONTROL QUIZ

1. Name the ganglion of trigeminal nerve  
\_\_\_\_\_
2. Name the branches of ophthalmic nerve  
\_\_\_\_\_
3. Which branches of ophthalmic nerve innervate nasal cavity  
\_\_\_\_\_
4. Name the branches of maxillary nerve  
\_\_\_\_\_
5. Which branches of maxillary nerve innervate maxillary teeth?  
\_\_\_\_\_
6. Name the sensory branches of mandibular nerve  
\_\_\_\_\_
7. Where locates inferior alveolar nerve?  
\_\_\_\_\_
8. Name the terminal branch of inferior alveolar nerve  
\_\_\_\_\_
9. Name the sinus of dura mater where III<sup>d</sup>, IV<sup>th</sup>, V<sup>th</sup> cranial nerves locate  
\_\_\_\_\_
10. Lingual nerve innervated the \_\_\_\_\_ part of the tongue  
\_\_\_\_\_

## LABORATORY CLASS № 9

### CRANIAL NERVES. ANATOMY OF THE FACIAL, GLOSSOPHARYNGEAL, VAGUS, ACCESSORY AND HYPOGLOSSAL NERVES

#### Control questions:

1. Facial nerve [VII]: the nucleus of the facial nerve, its localization and function; place the nerve exit from the brain and the skull cavity.
2. Motor branches of the facial nerve, innervation area.
3. Intermediate nerve: nuclei, localization and function, geniculate ganglion; branches, fiber composition, innervation area.
4. Glossopharyngeal nerve [IX]: nuclei, localization and function; place where the nerve exit from the brain and the skull cavity; sensory ganglia; branches, fiber composition, innervation area.
5. Vagus nerve [X]: the nuclei, localization and function; nerve exit site of the brain and the cranial cavity; parts.
6. The branches of the vagus nerve: fiber composition, areas of innervation.
7. Accessory nerve [XI]: nuclei, localization and function; place the nerve exit from the brain and the cranial cavity; innervation area.
8. Hypoglossal nerve [XII]: the nuclei, its localization and function; nerve exit site of the brain and the cranial cavity; innervation area; connection with the cervical plexus.

#### Students should be able to find on anatomical preparations and visual aids following structures and to know their Latin names:

1. Facial nerve.
2. Intermediate nerve.
3. Parotid plexus: temporal, zygomatic, buccal branch, marginal mandibular branch, cervical branch.
4. Greater petrosal nerve.
5. Chorda tympani.
6. Glossopharyngeal nerve.
7. Tympanic nerve.
8. Lesser petrosal nerve.
9. Otic ganglion.
10. Vagus nerve.
11. Superior laryngeal nerve.
12. Recurrent laryngeal nerve.
13. Accessory nerve.
14. Hypoglossal nerve.

**Repeat:** foramina and canals of cranial base. Facial muscles. Suprahyoid muscles.

## GLOSSARY

**Facial nerve** — the VII<sup>th</sup> cranial nerve. He emerges from the brain between pons and oliva, it goes to the facial nerve canal at petrosal part of the temporal bone, and exits through *stylomastoid foramen*. Somatic motor fibers innervate the facial muscles. They originated from the facial nerve nucleus neurons located in the dorsal part of pons. Intermediate nerve is the part of facial nerve.

**Intermediate nerve** contains sensory (taste) and parasympathetic (secretory) fibers. The bodies of sensory neurons are in the geniculate ganglion. The central processes of sensory neurons end at the solitary tract nucleus. The peripheral processes of afferent neurons form chorda tympani which joins with lingual nerve (from V<sub>3</sub>) and ends with taste receptors in the mucosa of the anterior 2/3 of the tongue. Preganglionic parasympathetic fibers origin from the superior salivatory nucleus neurons. Some of these fibers through chorda tympani and lingual nerve reach the submandibular and sublingual ganglions. Postganglionic parasympathetic fibers innervate the same name glands from the neurons of these

ganglions. Another part of the preganglionic parasympathetic fiber passes like greater petrosal nerve, then the nerve of the pterygoid canal and ends on neurons pterygopalatine ganglion. Postganglionic parasympathetic fibers that originate from the neurons of the ganglion. Postganglionic parasympathetic fibers that originate from the neurons of this ganglion innervate the lacrimal gland and gland of mouth mucosa and nasal cavity.

**The glossopharyngeal nerve** — the IX<sup>th</sup> pair of cranial nerves, mixed nerve. It contains somatic motor, sensory and parasympathetic fibers. The nuclei of the glossopharyngeal nerve lie in the dorsal part of medulla oblongata. The nerve comes from the brain behind the olive, from the cranial cavity — through the *jugular foramen*. Motor fibers originate from neurons of *nucleus ambiguus* and innervate stylopharyngeus muscle. The bodies of sensory neurons are in the superior and inferior ganglions, located on both sides of the jugular foramen. Their peripheral processes end by receptors in the mucosa of the isthmus of fauces, soft palate, posterior 1/3 of tongue (provide general and taste sensitivity), the pharynx, the auditory tube, the walls of the tympanic cavity, carotid body and palatine tonsil. The central processes of sensory neurons end in the *solitary tract nucleus*. The third nucleus of the glossopharyngeal nerve is *inferior salivatory nucleus*. Preganglionic parasympathetic fibers originate from this nucleus, it ends in the neurons of *otic ganglion* and form tympanic nerve and then lesser petrosal nerve, go to *otic ganglion* where it finishes. Postganglionic parasympathetic fibers are the processes of otic ganglion innervate the parotid gland, forming auriculotemporal nerve (with the third branch of the trigeminal nerve).

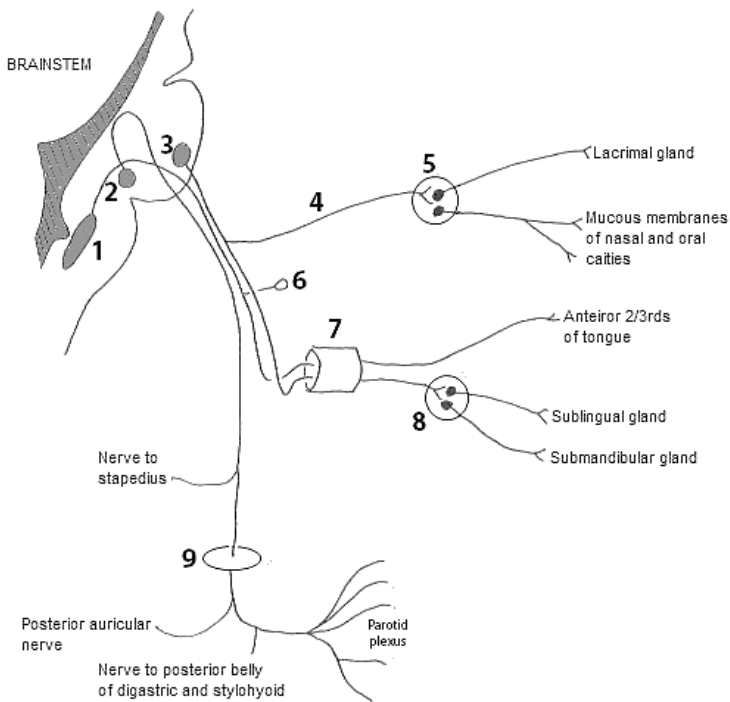
**Vagus nerve** — the X<sup>th</sup> pair of cranial nerves, mixed nerve. It contains somatic motor, sensory and parasympathetic fibers. The nuclei of nerve locate in the dorsal part of medulla oblongata. The nerve exits from the brain behind the olive below the glossopharyngeal nerve, from the cranial cavity — through the *jugular foramen*. Motor fibers originate from neurons of *ambiguus nucleus* and innervate striated muscles of pharynx, soft palate and larynx (except stylopharyngeus muscle and tensor veli palatini muscle), as well as the upper part of the esophagus. Body of sensory neurons are in the superior and inferior ganglions, locate on both sides from jugular foramen. Their peripheral processes form sensory nerve in dura mater of posterior fossa of the cranium, the skin of the ear and the external acoustic meatus, the mucosa of the posterior 1/3 of tongue, pharynx and larynx, and the walls of internal organs in thoracic and abdominal cavities. The central processes of sensory neurons end in the solitary tract nucleus. The parasympathetic preganglionic fibers are processes of neurons of the dorsal nucleus of the vagus nerve end in nerve cells, which lie within the nerve trunk and in ganglia located in the part of extraorganic or intramural autonomic plexuses. The parasympathetic postganglionic fibers (processes of cells of the vegetative ganglia) innervate cardiac muscle, smooth muscle of the wall of the esophagus, stomach, small intestine and colon, biliary system, the trachea and bronchi.

**Accessory nerve** — the XI<sup>th</sup> pair of cranial nerves. It formed by confluence of the cranial and spinal roots, which contain somatic motor fibers — the processes of neurons of *nucleus ambiguus* and the *nucleus of the accessory nerve*. Cranial root goes from the brain behind the olive, connected with spinal roots and leaves the cranial cavity through the *jugular foramen*. The nerve supplies the sternocleidomastoid and trapezius muscles.

**Hypoglossal nerve** — the XII<sup>th</sup> pair of cranial nerves. It contains somatic motor fibers originating from the nucleus of the hypoglossal nerve, which locate at the dorsal part of the medulla oblongata. From brain nerve emerges from the fissure between the pyramid and oliva, from the cranial cavity — through the *hypoglossal canal*. Hypoglossal nerve innervates muscles of the tongue and infrahyoid muscles.

## SELF-INSTRUCTIONAL MATERIALS

### Facial nerve (schema)

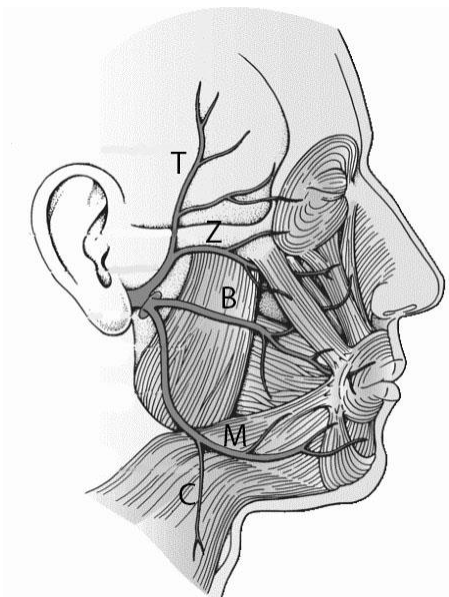


**COLOR** somatic motor fibers in red, sensory fibers in blue and parasympathetic fiber in green.

**WRITE** the names of structures labeled by the number:

1. Nucleus of	
2.	nucleus
3.	nucleus
4.	
5.	ganglion
6.	ganglion
7.	
8.	ganglion
9.	foramen

«To Zanzibar by Motor Car». What does this mnemonic phrase mean?



This is popular neuroanatomy mnemonic for \_\_\_\_\_  
(branches of the parotid plexus)

T

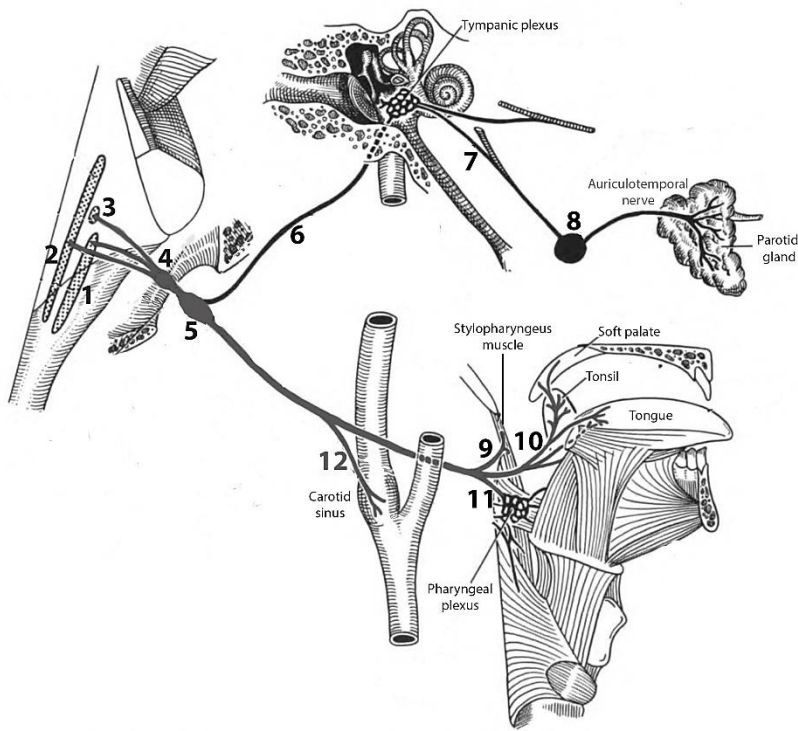
Z

B

M

C

## Glossopharyngeal nerve (schema)



**WRITE** the name of structures labeled by the number:

1. Nucleus

2. Nucleus

3. nucleus

4. ganglion

5. ganglion

6.

7.

8.

9.

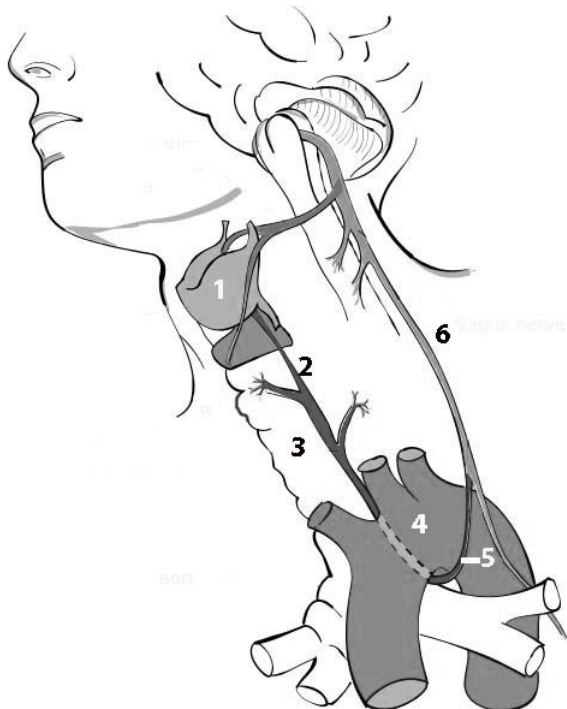
10.

11.

12.

## Branches of the vagus nerve

**WRITE** the name of structures labeled by the number:



1.

2. nerve

3.

4.

5.

6. nerve

## CONTROL QUIZ

1. Motor branches of facial nerve innervate

---

2. Facial canal has \_\_\_\_\_ bends

---

3. Parasympathetic fibers of facial nerve innervate

---

4. Name the parasympathetic nucleus of glossopharyngeal nerve

---

5. Name the parasympathetic branch of glossopharyngeal nerve

---

6. Glossopharyngeal nerve has \_\_\_\_\_ sensory ganglia

---

7. What does the vagus nerve innervate in the head?

---

8. Hypoglossal nerve with cervical plexus forms

---

9. Name the branches of vagus nerve innervated the larynx

---

## LABORATORY CLASS № 10

### AUTONOMIC NERVOUS SYSTEM

#### Control questions:

1. Autonomic nervous system: the general principles of the structure and function, innervation area.
2. Differences between the structure of autonomic and somatic divisions of the peripheral nervous system.
3. Division of the autonomic department of the peripheral nervous system into sympathetic and parasympathetic parts, its structural and functional differences.
4. Morphofunctional characteristic of parasympathetic part of the autonomic division of the peripheral nervous system. The parasympathetic ganglia of head.
5. Morphofunctional characteristic of sympathetic part of the autonomic division of the peripheral nervous system. The parasympathetic ganglia of head.
6. Cervical part of sympathetic trunk.

**Students should be able to find on anatomical preparations and visual aids following structures and to know their Latin names:**

1. Sympathetic trunk.
2. Superior (middle, inferior) cervical ganglia (sympathetic trunk).
3. The parasympathetic nuclei of the oculomotor, facial, glossopharyngeal and vagus nerve.
4. Ciliary, pterygopalatine, otic, sublingual and submandibular ganglia.

**Repeat:** oculomotor, facial, glossopharyngeal, vagus nerves.

### GLOSSARY

**Autonomic nervous system (ANS)** — efferent system that delivers a subconscious regulation of organ functions. It innervates *smooth muscle cells, cardiomyocytes and glandular epithelium*. It consists of the sympathetic (SNS) and parasympathetic (PNS) divisions; includes sympathetic trunk, preganglionic and postganglionic autonomic fibers in the composition of the cranial and spinal nerves, autonomic ganglia and plexus.

**Autonomic ganglia** contain the bodies of the second (effector) neurons located on the way to the innervated organs. They are located in the head region, and also are part of the sympathetic trunk, autonomic plexuses of the abdominal cavity and pelvis, inside or near the organs of the digestive and respiratory systems, as well as the urinary and reproductive system.

**Preganglionic fibers of the sympathetic division of ANS** origin from the neurons, which locate in the lateral horn of the lumbar-thoracic part of spinal cord (C<sub>8</sub> - L<sub>2</sub>) (the first neuron), postganglionic fibers — from neurons of the sympathetic trunk (the second neuron).

**Preganglionic fibers of the parasympathetic of the ANS** originate from neurons of autonomic nuclei III<sup>d</sup>, VII<sup>th</sup>, IX<sup>th</sup> and X<sup>th</sup> pairs of cranial nerves, as well as neurons, which lie in the sacral segments of spinal cord (S<sub>2</sub>-S<sub>4</sub>); postganglionic fibers — in peripheral autonomic ganglia located near organs or in the wall of organ.

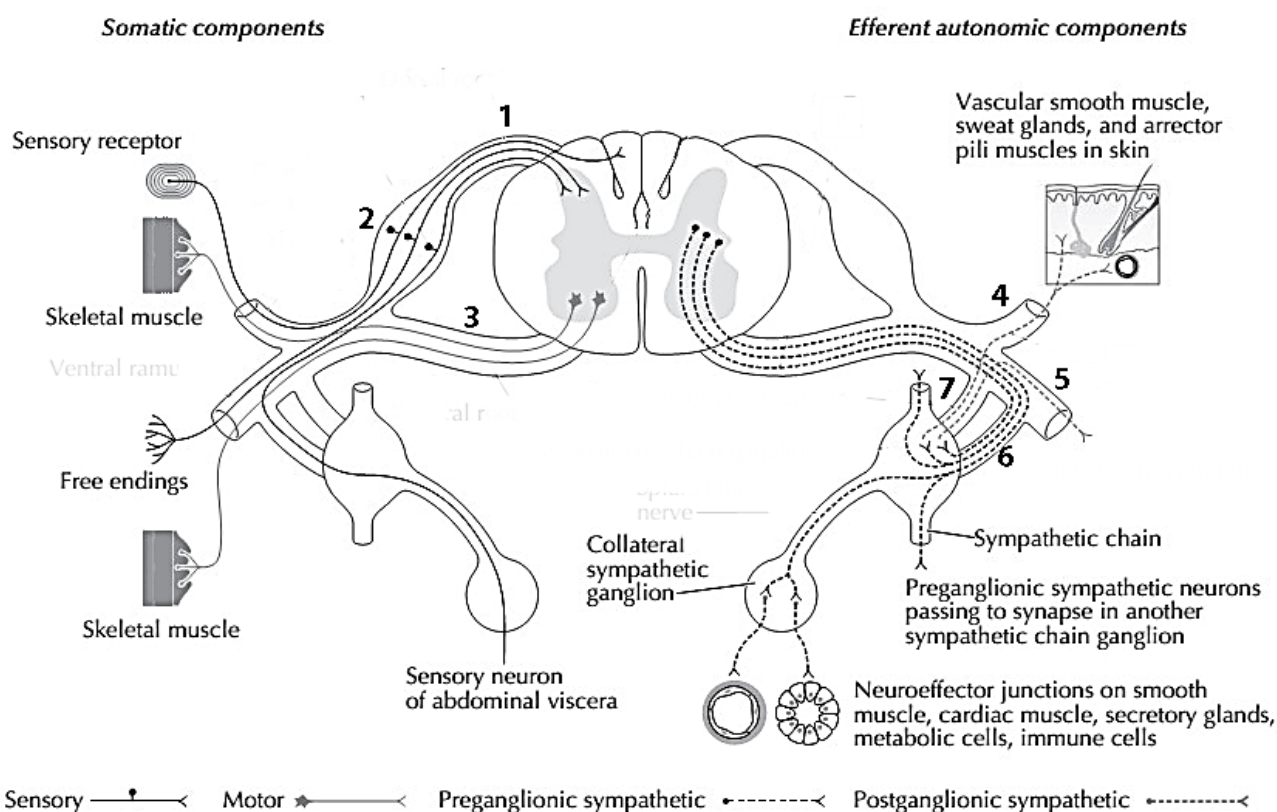
**Autonomic (visceral) plexuses** located around the major blood vessels and their branches and in the wall of the tubular organs (submucosal and intermuscular plexus). Plexuses include afferent, preganglionic and postganglionic fibers of sympathetic and parasympathetic divisions of the ANS, as well as numerous autonomic (visceral) ganglia. There are cervical, thoracic, abdominal and pelvic autonomic plexuses.

## SELF-INSTRUCTIONAL MATERIALS

### Schematic of elements of PNS

**COLOR** the following features of the PNS, using a different color for each feature:

- Sensory axon and nerve cell body in a dorsal root ganglion
- Somatic motor axon and nerve cell body in anterior horn
- Autonomic preganglionic fiber in ventral root (efferent autonomic components) passing to a sympathetic trunk ganglion (ANS ganglion)
- Autonomic postganglionic fiber passing from a sympathetic trunk ganglion to the skin.



**WRITE** the name of structures labeled by the number:

1.		root
2.		ganglion
3.		root
4.		ramus
5.		ramus
6.	ramus	
7.	ramus	

**NAME** the specific functions of the parasympathetic division of the ANS:

<b>STRUCTURE</b>	<b>EFFECT</b>
Eyes	
Ciliary body	
Lacrimal glands	
Heart	
Coronary arteries	
Lungs	
Digestive tract	
Liver	
Salivary glands	
Reproductive system	
Urinary system	

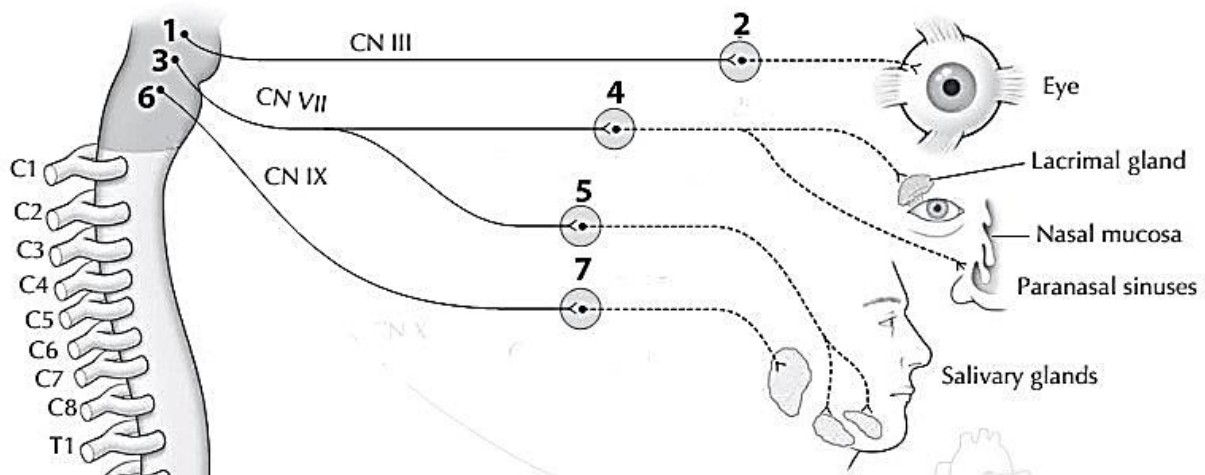
**NAME** the specific functions of the sympathetic division of the ANS:

<b>STRUCTURE</b>	<b>EFFECT</b>
Eyes	
Lacrimal glands	
Skin	
Sweat glands	
Peripheral vessels	
Heart	
Coronary arteries	
Lungs	
Digestive tract	
Liver	
Salivary glands	
Reproductive system	
Urinary system	
Adrenal medulla	

## Parasympathetic ganglia of the head

**WRITE** the name of structures labeled by the number:

1.	nucleus
2.	ganglion
3.	nucleus
4.	ganglion
5.	ganglion
6.	nucleus
7.	ganglion



### CONTROL QUIZ

1. Name the parasympathetic nucleus of facial nerve

---

2. Name the divisions of sympathetic trunk

---

3. Name the structures of the central division of the autonomic nervous system

---

4. Name the structures of the peripheral division of the autonomic nervous system

---

5. How many efferent neurons are included in the reflex arc of the autonomic reflex?

---

6. Where is the afferent neuron located in the autonomic reflex arch?

---

7. What type of nerve fibers are characteristic of the somatic and autonomic nervous system?

---

8. Parasympathetic preganglionic fibers are usually \_\_\_\_\_ than sympathetic preganglionic fibers

---

9. Sympathetic postganglionic fibers (by type of neurotransmitter) are \_\_\_\_\_ and parasympathetic \_\_\_\_\_

---

10. Where is the body of the first efferent neuron in the sympathetic and parasympathetic division of the autonomic nervous?

---

# SENSE ORGANS

## LABORATORY CLASS № 11

### SENSE ORGANS. STRUCTURE AND FUNCTIONS OF THE ORGAN OF HEARING AND EQUILIBRIUM

#### Control questions:

1. External ear: pinna and external auditory canal; structure, blood supply, innervation, lymphatic drainage.
2. Tympanic membrane: part, layer by layer structure.
3. Middle ear: tympanic cavity, auditory ossicles.
4. Auditory tube, mastoid cells. Blood supply, innervation, lymphatic drainage.
5. Inner ear: parts; the structure of the bony and the membranous labyrinth.
6. Vestibulocochlear nerve: the name and location of the nuclei; entry in the cranial cavity and the brain.
7. Auditory pathways and vestibular system.

**Students should be able to find on anatomical preparations and visual aids following structures and to know their Latin names:**

1. Pinna. 2. The external acoustic meatus. 3. Tympanic membrane. 4. The tympanic cavity. 5. Oval window. 6. Round (cochlear) window. 7. Auditory ossicles: malleus, incus, stapes. 8. The tensor tympani muscle. 9. Stapedius muscle. 10. Auditory tube. 11. Cochlea. 12. Semicircular canals (anterior, posterior, lateral). 13. Vestibulocochlear nerve.

**Repeat:** temporal bone.

## GLOSSARY

**The external ear** consists of the pinna, the external acoustic meatus and tympanic membrane; supplied by posterior auricular artery, branches of the maxillary and the superficial temporal arteries; innervated by the branches of great auricular, lesser occipital, vagus, auriculotemporal nerves; lymph drainage is carried out in the mastoid and deep parotid lymph nodes.

**The tympanic cavity** is part of the middle ear, contains the auditory ossicles (malleus, incus and stapes), as well as the muscles of the auditory ossicles — the stapedius muscle, tendon of tensor tympani muscle. The cavity has superior (tegmental), inferior (jugular), anterior (carotid), posterior (mastoid), lateral (membranous) and medial (labyrinthine) walls.

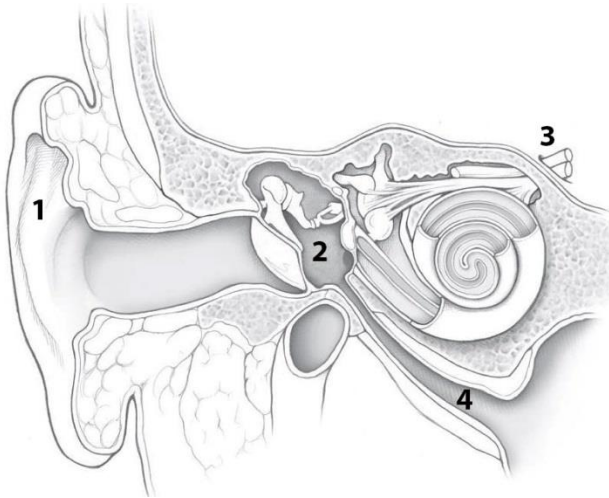
**The inner ear** presented bony and membranous labyrinth. Membranous labyrinth is located inside the bony labyrinth, surrounded by perilymph. Inside the membranous labyrinth is endolymph.

**Bony labyrinth** forming by three semicircular canals, vestibule and cochlea.

**The membranous labyrinth** consists of three semicircular ducts, utricle and saccule, ducts of utricle and saccule, endolymphatic duct and sac, and connects the cochlear duct.

**SELF-INSTRUCTIONAL MATERIALS**

**Three parts of the ear (frontal section of the head)**



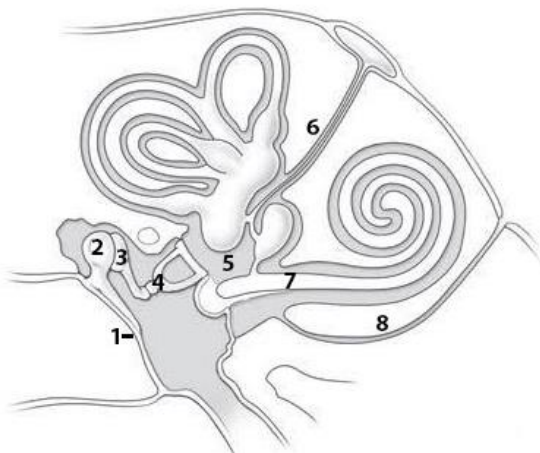
**COLOR** the following structures of the ear, using a different color for each structure:

- Auditory ossicles (malleus, incus, and stapes)
- Cochlea
- Tympanic membrane
- External acoustic meatus

**WRITE** the name of structures labeled by the number:

1. \_\_\_\_\_
2. \_\_\_\_\_
3. \_\_\_\_\_ nerve
4. \_\_\_\_\_ tube

**Bony and membranous labyrinths (schema)**



**COLOR** the following structures of the bony and membranous labyrinths of the cochlea and vestibular apparatus, using a different color for each structure:

- Semicircular ducts (anterior, lateral, and posterior)
- Utricle
- Saccule
- Round (cochlear) window: closed by a secondary tympanic membrane

**WRITE** the name of structures labeled by the number:

1. \_\_\_\_\_
2. \_\_\_\_\_
3. \_\_\_\_\_
4. \_\_\_\_\_
5. \_\_\_\_\_
6. \_\_\_\_\_ duct
7. \_\_\_\_\_ duct
8. \_\_\_\_\_ aqueduct

## CONTROL QUIZ

1. Name the cartilage structures of pinna  
\_\_\_\_\_
2. External auditory canal consists of \_\_\_\_\_ parts  
\_\_\_\_\_
3. Tympanic membrane consists of pars \_\_\_\_\_ and pars \_\_\_\_\_  
\_\_\_\_\_
4. Name the muscles of middle ear  
\_\_\_\_\_
5. Auditory (Eustachian) tube connects middle ear with  
\_\_\_\_\_
6. Organs of equilibrium locates at  
\_\_\_\_\_
7. Cochlea contain scala \_\_\_\_\_ and scala \_\_\_\_\_ and \_\_\_\_\_ duct  
\_\_\_\_\_
8. Where is locate crista ampullaris?  
\_\_\_\_\_
9. Utricle and saccule responsible for \_\_\_\_\_ equilibrium and semicircular canals for equilibrium  
\_\_\_\_\_
10. Cortical center of hearing locates at  
\_\_\_\_\_

## LABORATORY CLASS № 12

### STRUCTURAL AND FUNCTIONAL CHARACTERISTICS OF THE EYE. FINAL CLASS ON «NERVOUS SYSTEM», «SENSE ORGANS»

#### Control questions:

1. Organ of vision: a general plan of structure, function.
2. Fibrous layer of eyeball: parts, structure and function.
3. Vascular layer: parts and functions. The mechanism of accommodation.
4. The internal (smooth) muscles of the eyeball: localization, blood supply and innervation.
5. The retina: parts. Normal floor at ophthalmoscopy.
6. The inner core of the eye: the aqueous humor eye chambers, lens, vitreous body. Production and ways of outflow of aqueous humor.
7. Accessory structures of the eye. The extraocular muscles of the eyeball: origin and insertion, functional significance; blood supply and innervation.
8. Eyelids: structure; functional value. Conjunctiva.
9. Lacrimal apparatus: lacrimal gland; lacrimal ways; lacrimal sac; nasolacrimal duct.
10. The visual pathway. The optic nerve.
11. Blood supply and innervation of the eyeball, the extraocular muscles and lacrimal gland.

#### Students should be able to find on anatomical preparations and visual aids following structures and to know their Latin names:

1. Eyeball.
2. Fibrous layer of eyeball.
3. Cornea.
4. Sclera.
5. Vascular layer.
6. Ciliary body.
7. Ciliary muscle.
8. Iris.
9. Pupil.
10. Sphincter pupillae.
11. Dilator pupillae.
12. Retina.
13. Lens.
14. Vitreous body.
15. Superior, inferior, lateral, medial rectus muscles.
16. Superior (inferior) oblique muscles.
17. Levator palpebrae superior muscle.
18. Superior (inferior) eyelid.
19. Conjunctiva.
20. Lacrimal gland.
21. Lacrimal sac.
22. Nasolacrimal duct.
23. Optic nerve.

**Repeat:** orbit.

## GLOSSARY

**Eye (greek Ophthalmos)** consists of the eyeball and the optic nerve with tunic around it.

Eyeball						
Eyeball layer						Inner core of the eye
External (fibrous) layer		Middle (vascular) layer (uveal tract)			Inner layer (retina)	
Cornea	Sclera	Iris	Ciliary body	Choroid	Blind part	Optic part
					Pigment layer	Nervous layer
						lens vitreous body aqueous humor

**Cornea** — anterior transparent part of fibrous layer; a protective and light-refracting function.

**Sclera** — white dense connective tissue structure; protective function and serves as the attachment of the extraocular muscles of the eyeball.

**Iris** — anterior part of the choroid with a round hole in the center, which is called the pupil. Its dimensions vary due to contract of two muscles — sphincter and dilatator pupillae, formed by smooth muscle cells. The pigment in the iris determines eye color.

**Ciliary body** — middle thickened choroid department. The main part of it is ciliary muscle, which provides accommodation of the eye. Another function of ciliary body is production of aqueous humor of the eyeball chambers.

**Choroid** — the posterior portion of vascular layer, contains many blood vessels and pigment; it provides oxygen and nutrients to the retina.

**Retina** — the inner layer of the eyeball; adjacent to the choroid in its entirety, from the exit site of the optic nerve to the edge of the pupil. There are two parts. Nonvisual retina (blind part) is in contact with the ciliary body and iris. The optic part of the retina extends to the point of transition the choroid to ciliary body. It adjacent to the vitreous body and contains photosensory cells (rods and cones).

**The inner core of the eye** complex of light refracting tissues, located inside the eyeball. It includes aqueous humor of the eyeball cambers, lens and vitreous body.

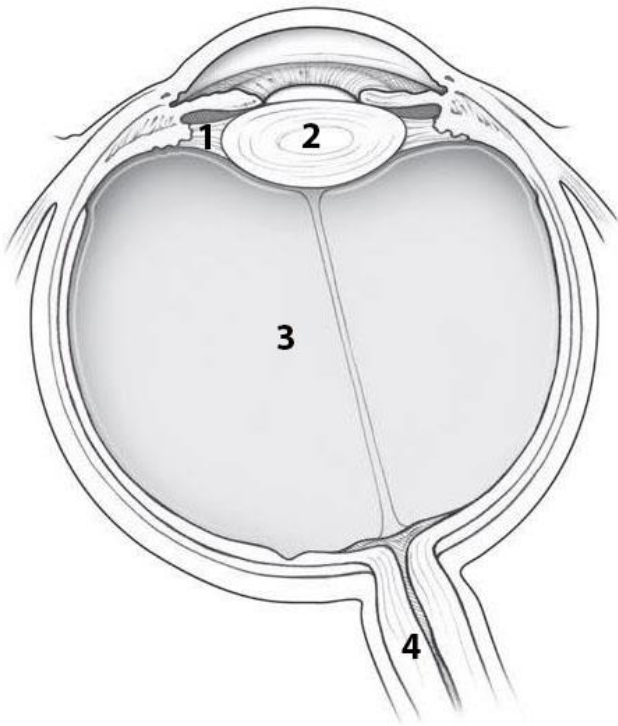
**Lens** — transparent elastic biconvex structure, which is located inside the eyeball behind the pupil. His capsule using fixed to the ciliary body by zonular fibers. The thickness of the lens varies depending on the degree of tension of zonular fibers.

**Accommodation** — the ability to see objects locate at different distances from the eye. It is carried out by changing the curvature of the lens. With the contraction of the ciliary muscle the zonular fibers relax, which is accompanied by a decrease the tension of the lens capsule. Due to its elastic properties, the lens becomes more convex. Relaxation of the ciliary muscle is accompanied by tension of zonular fibers and flattening of the lens.

**The vitreous body** (corpus vitreum) is a colorless transparent mass behind the lens and ciliary angle, which makes up the majority (65%) of the contents of the eyeball. It contacts with the ciliary body, retina and optic nerve disc.

**SELF-INSTRUCTIONAL MATERIALS**

**Eyeball**



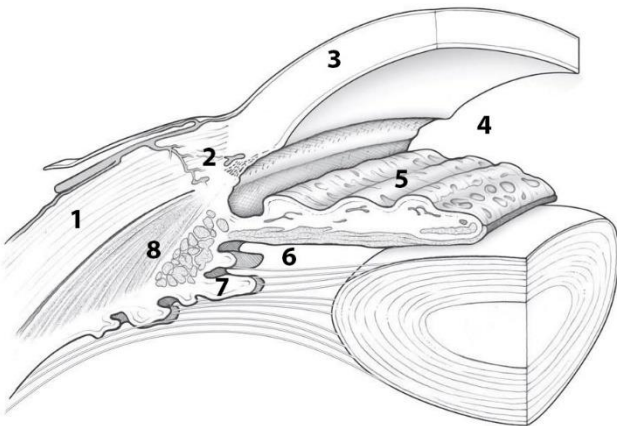
**COLOR** the following layers of the eyeball, using a different color for each layer:

- Cornea
- Sclera
- Iris
- Ciliary body
- Choroid
- Retina

**WRITE** the name of structures labeled by the number:

- 1. \_\_\_\_\_
- 2. \_\_\_\_\_
- 3. \_\_\_\_\_
- 4. \_\_\_\_\_

**Chambers of the eye**



**COLOR** the following structures of the anterior portion of the eyeball, using a different color for each structure:

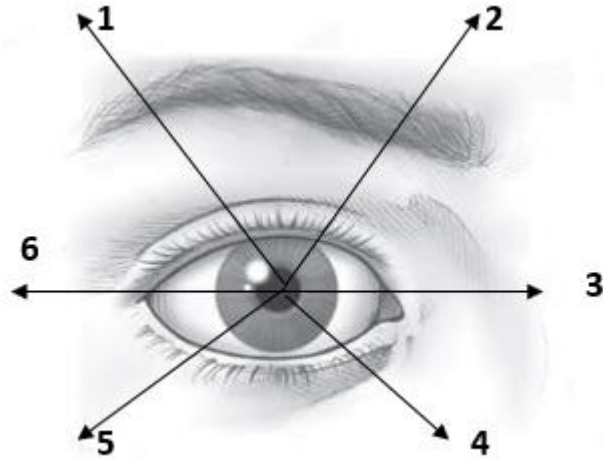
- Sphincter pupillae
- Lens
- Dilator pupillae
- Ciliary zonule

**WRITE** the name of structures labeled by the number:

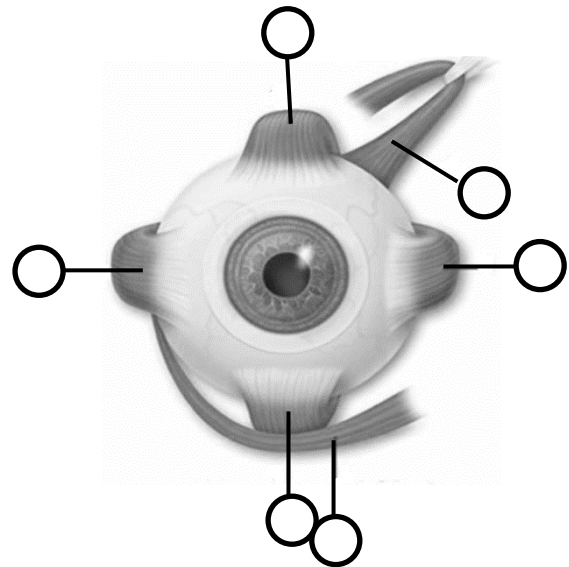
- |    |       |    |
|----|-------|----|
| 1. |       | 5. |
| 2. | sinus | 6. |
| 3. |       | 7. |
| 4. |       | 8. |

## Extraocular muscle movements

**NAME** the extraocular muscles that provide the corresponding movements (Fig. 1) and **NUMBER** the named muscles (Fig. 2):



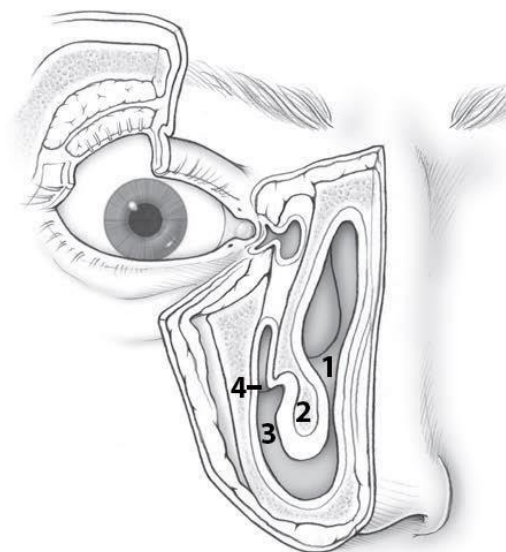
**Fig. 1**



**Fig. 2**

1. \_\_\_\_\_
2. \_\_\_\_\_
3. \_\_\_\_\_
4. \_\_\_\_\_
5. \_\_\_\_\_
6. \_\_\_\_\_

## Lacrimal apparatus



**COLOR** the following structures of the lacrimal apparatus, using a different color for each structure:

- Lacrimal gland
- Lacrimal sac
- Nasolacrimal duct

**WRITE** the name of structures labeled by the number:

- |               |        |
|---------------|--------|
| 1.            | cavity |
| 2.            | concha |
| 3.            | meatus |
| 4. Opening of |        |

## CONTROL QUIZ

1. Ciliary body composed of \_\_\_\_\_
2. Ciliary muscles innervated by \_\_\_\_\_
3. Function of ciliary processes is \_\_\_\_\_
4. Name the muscles of iris which has radial direction \_\_\_\_\_
5. Rods is responsible for \_\_\_\_\_ and cons for \_\_\_\_\_
6. Which part of the retina contains the most cones? \_\_\_\_\_
7. There are no photoreceptors at the \_\_\_\_\_
8. Where locates the posterior chamber of eyeball? \_\_\_\_\_
9. Nasolacrimal duct opens into \_\_\_\_\_
10. Which nerves innervate extrinsic muscles of eyeball? \_\_\_\_\_

## CONTROL QUESTIONS FOR THE SECTIONS «NERVOUS SYSTEM», «SENSE ORGANS»

1. Spinal cord: skelelotopy, division into segments, the structure of gray and white matter. Ventral and dorsal roots, sensory ganglia of spinal nerves.
2. The brain: parts. Medulla oblongata: boundaries, external and internal structure.
3. Pons: boundaries, external structure, nuclei of gray matter.
4. Cerebellum: hemisphere of cerebellum, vermis, cerebellar peduncles. The nuclei of the cerebellum.
5. Fourth ventricle: walls, connections with other cavities of the brain and subarachnoid space. Rhomboid fossa: the projection of nuclei of cranial nerves.
6. Midbrain: superior and inferior colliculi, cerebral peduncles. Topography of nuclei of gray matter. The aqueduct of midbrain.
7. Diencephalon: thalamus, metathalamus, epithalamus, hypothalamus. The third ventricle.
8. Telencephalon: surfaces, lobes, basic sulcus and gyrus of the hemispheres of the brain. Localization of functions in the cortex of the hemispheres of the brain.
9. Telencephalon: basal nuclei. White matter of hemispheres of the brain. Lateral ventricle.
10. The general principle of the structure of the sensory (afferent) and motor (efferent) nerve pathways of brain and spinal cord.
11. Meninges: the macroscopic structure. The sinuses of the dura mater. The subarachnoid space. The formation and ways of circulation of cerebrospinal fluid.
12. Spinal nerves: the sources of formation, branches. Cervical plexus: branches, areas of innervation.

13. Cranial nerves: classification, general morphofunctional characteristic. Oculomotor [III], trochlear [IV] and abducent [VI] nerves.
14. Trigeminal nerve [V]: a general overview. Ophthalmic [V<sub>1</sub>] nerve: branches, areas of innervation.
15. The maxillary nerve [V<sub>2</sub>], branches and area of innervation.
16. The mandibular nerve [V<sub>3</sub>]: branches, areas of innervation.
17. Facial nerve [VII]: nuclei, localization in the brain stem. The course of the nerve, branches, area of innervation.
18. Glossopharyngeal nerve [IX]: nuclei, places of exit from the brain, cavity of the skull, ganglions, branches, areas of innervation.
19. Vagus nerve [X]: nuclei, places of exit from the brain and cranial cavity, ganglia, branches, areas of innervation.
20. Accessory [XI], and hypoglossal [XII] nerves: nuclei, places of exit from the brain and cranial cavity, branches, area of innervation.
21. Autonomic part of the peripheral nervous system: general principles of structure and function.
22. Sympathetic part of the ANS. Cervical part of the sympathetic trunk, branches, areas of distribution.
23. Parasympathetic part of the ANS: cranial and pelvic parts.
24. External ear: pinna and external acoustic meatus; structure, blood supply, innervation, lymphatic drainage. Tympanic membrane: parts, layer by layer structure.
25. Middle ear: tympanic cavity, auditory ossicles, auditory tube, mastoid cells. Blood supply, innervation, lymphatic drainage.
26. Inner ear: parts; the structure of the bony, and the membranous labyrinth. Vestibulocochlear nerve. The auditory pathway and vestibular system.
27. The organ of vision: fibrous layer, vascular layer and retina. Lens, anterior and posterior chambers.
28. Accessory structures of the eye. Extraocular muscles of the eyeball, eyelids, conjunctiva, lacrimal apparatus. Pathway of visual analyzer. The optic nerve.

# DIGESTIVE SYSTEM

## LABORATORY CLASS № 12

### DIGESTIVE SYSTEM: GENERAL CHARACTERISTICS. STRUCTURE OF ORAL ORGANS AND GREAT SALIVARY GLANDS

#### Control questions:

1. Oral cavity: boundaries, parts (oral vestibule and the oral cavity proper).
2. The structure of the lips. Blood supply, innervation, the regional lymph nodes.
3. The hard palate: bony base; mucosal relief. Blood supply, innervation.
4. Soft palate: uvula, palatoglossal and palatopharyngeal arches, palatine fossa and palatine tonsil, blood supply, innervation, regional lymph nodes.
5. The muscles of the soft palate and pharynx: origin and insertion; function; blood supply and innervation.
6. The floor of the oral cavity: the relief of the mucous membrane, blood supply and innervation, regional lymph nodes.
7. Tongue: part; surface; relief of the mucosa, blood supply and innervation; regional lymph nodes.
8. Tongue muscles: origin and insertion, function; blood supply and innervation.
9. General morpho-functional characteristics of the teeth. Primary and permanent teeth: structure, groups of teeth; blood supply, innervation, regional lymph nodes.
10. Parotid, submandibular, sublingual salivary glands: locations; structure; ducts. Blood supply, innervation, regional lymph nodes.

#### Students should be able to find on anatomical preparations and visual aids following structures and to know their Latin names:

1. Oral vestibule. 2. Oral cavity proper. 3. Gums. 4. Frenulum of upper (lower) lip. 5. Cheek. 6. Hard (soft) palate. 7. Velum. 8. Palatoglossal (palatopharyngeal) arch. 9. Palatine tonsil. 10. Palatopharyngeal, palatoglossus muscles. 11. Levator veli palatini. 12. Tensor veli palatine. 13. Uvula. 14. Fauces. 15. Tongue. 16. Palatine tonsil. 17. Genioglossal, hyoglossus, styloglossus muscles. 18. Superior longitudinal muscle. 19. Transverse muscles of the tongue. 20. The vertical muscles of the tongue. 21. Frenulum linguae. 22. Sublingual papilla. 23. Sublingual fold. 24. Parotid gland. 25. Parotid duct. 26. Submandibular gland. 27. Submandibular canal. 28. Sublingual glands. 29. Major and minor sublingual ducts. 30. Teeth. 31. Incisors. 32. Canine. 33. Premolar. 34. Molar.

**Repeite:** maxilla, hard palate, mandible.

## GLOSSARY

**Hard palate** is the 2/3 of the superior-anterior wall of the oral cavity. The palatine processes of maxilla anteriorly and the horizontal plates of the palatine bones behind are formed its base. The mucous membrane of the hard palate is firmly fused with the periosteum in sutures and in the place of transition to the gum.

**Soft palate** is the posterior 1/3 of the upper wall of the oral cavity and during swallowing separates the nasopharynx from the oropharynx. Palatal aponeurosis forms the base of the soft palate, which is attached to the hard palate by its anterior edge. On each side of the soft palate, palatoglossal

and palatopharyngeal arches locate. From the side of oral cavity mucous membrane of the soft palate is covered by stratified squamous epithelium, and from the nasopharynx — ciliated, pseudostratified epithelium.

**Palatine aponeurosis** — thin fibrous plate forming buccopharyngeal fascia laterally. The aponeurosis is the attachment place for muscles: levator velum palatini and tensor velum palatini, palatoglossus, palatopharyngeus, uvula muscle.

**Gums (gingiva)** — the mucous membrane that covers the tooth neck and partially covering the alveolar process of the maxilla and the alveolar part of the mandible. Free (mobile) part of the gums adjacent by the tooth. On one side it ends by the gum edge, forming the gingival (interdental) papillae on the other side — continues in the non-mobile (alveolar) part of the gums, which is fused with the periosteum of the jaws.

*Transitional fold* separates non-mobile pale pink part of the gingiva of the mucous membrane from dark red color, which is also covered bone, but does not fuse with its periosteum.

**Mouth diaphragm** — the bottom of the oral cavity. It is based on the muscles located between the hyoid bone, tongue and mandible: mylohyoid, digastric and geniohyoid muscles. Under the tongue of the mucous membrane are sublingual papilla, sublingual folds and frenulum linguae.

**The salivary glands** are exocrine glands. The salivary glands of the mouth include *small* and *large* glands. The small salivary glands have short ducts and lie in the mucosa of the lips, *cheek, tongue, and palate*. The large salivary glands include the **parotid gland**, the **submandibular gland**, and the **sublingual gland**. The *parotid gland* is the largest. It lies in front of the ear on the ramus of the mandible. Its duct, 3 mm thick and 5–6 cm long, pierces the buccinator muscle and ends in the oral cavity at the level of **the second upper molar**. The *submandibular gland* is closely applied to the mandible and extends a fairly long process around the posterior border of the mylohyoid muscle. Its duct runs anteriorly and joins the duct of the sublingual gland, which lies laterally on the mylohyoid muscle under the tongue. The common duct ends in a small projection (*sublingual caruncle*) under the apex of the tongue. Several small accessory ducts from the sublingual gland open on each side of the sublingual papilla.

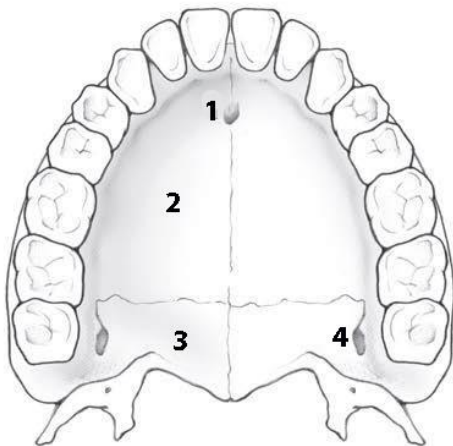
**Sublingual fold** is elongate crest of mucous membrane on the floor of the mouth between the tongue and the inner surface of the mandible, which corresponds with location of sublingual gland. It has minor sublingual ducts.

**The teeth** are located in the dental alveoli; participate in the mechanical processing of food, speech articulation and perform an aesthetic function. The thickened portion of the tooth protruding from the alveoli and covered with enamel of the tooth is called the *crown*. *The neck* of the tooth — it narrowed portion located between the crown and the root. *The root* of the tooth is inside the dental alveoli and covered with cement.

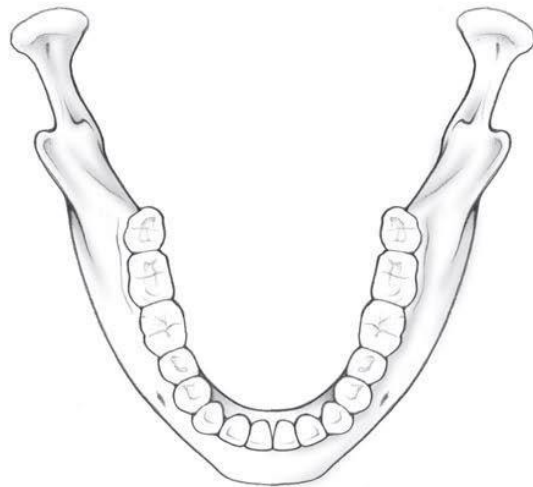**The tongue** is a muscular organ. The muscles of the tongue are divided into *intrinsic and extrinsic* muscles. The most important and strongest extrinsic tongue muscle is the **genioglossus muscle**. The **intrinsic tongue muscles** traverse the organ in all three directions. The *dorsum* of the tongue contains numerous papillae of various kinds, subserving the sensations of touch and taste. The *filiform* papillae are distributed over the whole dorsum of the tongue and serve especially the perception of touch, pressure, temperature, and pain. The taste papillae include *fungiform* papillae, *vallate* papillae and *foliate* papillae. They contain taste buds. Behind the V-shaped arrangement of vallate papillae, the palatine part of the tongue is bounded by the *lingual tonsil*. In the midline, immediately behind the apex of the V, lies the *foramen caecum*, where the thyroid gland has developed.

**SELF-INSTRUCTIONAL MATERIALS**

**Hard palate**



**Permanent teeth**



**COLOR** different groups of teeth, using a different color for each of them:

- Incisors
- Canine
- Premolars
- Molars

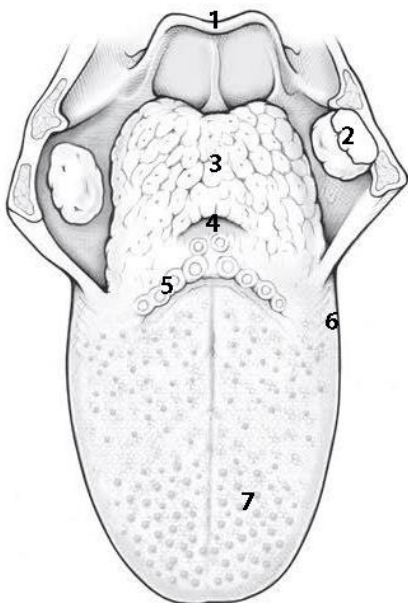
**WRITE** the name of structures labeled by the number:

- 1. \_\_\_\_\_ foramen
- 2. \_\_\_\_\_ process
- 3. \_\_\_\_\_
- 4. \_\_\_\_\_ foramen

**Dorsum of tongue**

**COLOR**

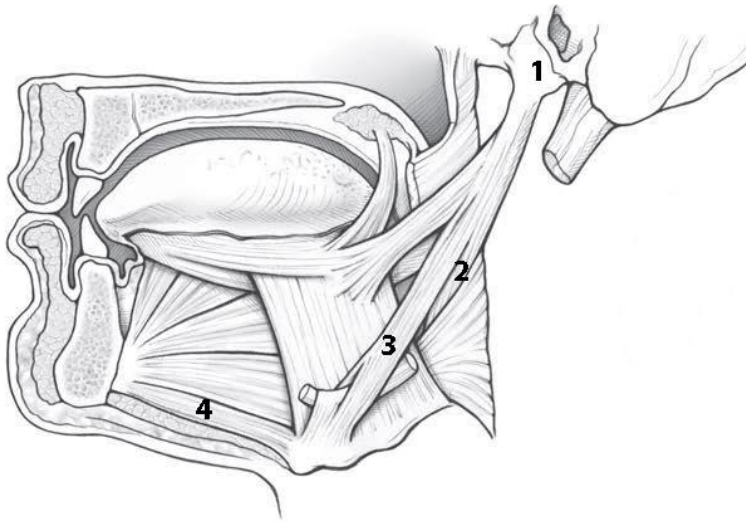
- Presulcal part of tongue
- Postsulcal part of tongue



**WRITE** the name of structures labeled by the number:

- 1. \_\_\_\_\_
- 2. \_\_\_\_\_ tonsil
- 3. \_\_\_\_\_ tonsil
- 4. \_\_\_\_\_
- 5. \_\_\_\_\_ papillae
- 6. \_\_\_\_\_ papillae
- 7. \_\_\_\_\_ papillae

## Muscles of the tongue



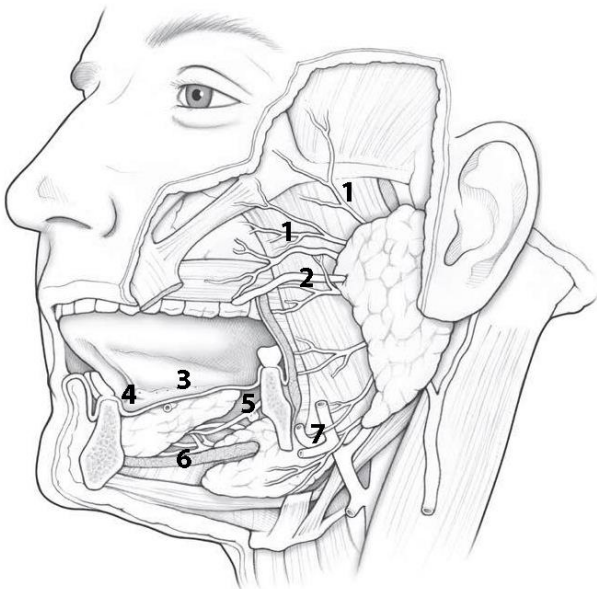
**COLOR** the following muscle, using a different color for each of them:

- Genioglossus
- Hyoglossus
- Palatoglossus
- Styloglossus

**WRITE** the name of structures labeled by the number:

1. \_\_\_\_\_ process
2. \_\_\_\_\_
3. \_\_\_\_\_
4. \_\_\_\_\_

## Glands of mouth



**COLOR** the following features of the oral cavity, using a different color for each feature:

- Sublingual glands
- Submandibular gland
- Parotid gland

**WRITE** the name of structures labeled by the number:

1. Branches of \_\_\_\_\_
2. \_\_\_\_\_
3. \_\_\_\_\_ fold
4. \_\_\_\_\_
5. \_\_\_\_\_
6. \_\_\_\_\_ muscle (cut)
7. \_\_\_\_\_ artery and vein

## CONTROL QUIZ

1. Name the borders of oral cavity proper

---

2. Which nerve innervate the muscles of the lips?

---

3. Sensory innervation of the lips realized by

---

4. Which division has the mucosa of hard palate?

---

5. Parasympathetic innervation of the palatine salivary glands are

---

6. Muscles of tongue innervates by

---

7. Mucosa of tongue innervates by

---

8. Origin of foramen caecum in embryogenesis

---

9. Parotid duct opens at the level of

---

10. Parotid gland innervated by

---

## LABORATORY CLASS № 13

### PHARYNX, ESOPHAGUS, STOMACH, SMALL AND LARGE INTESTINE

#### Control questions:

1. Pharynx: functions, parts; syntopy and skeletopy; stratified structure of the wall. Connection of pharynx with nasal cavity, middle ear, cavity of the larynx and esophagus. Pharyngeal lymphoid ring.
2. The muscles and fascia of the pharynx: origin and insertion, functions; pterygomandibular raphe. Blood supply, innervation of the pharynx mucosa and muscles. The regional lymph nodes of the pharynx.
3. Esophagus: parts, topography, structure of wall. Blood supply, innervation, regional lymph nodes.
4. Stomach: function, syntopy, skeletopy, golotopy.
5. Parts of the stomach, opening, layer by layer structure of the walls; blood supply, innervation, the regional lymph nodes.
6. Location and the functional significance of the sphincter of the stomach.
7. Morphofunctional characteristic of the small intestine; layered structure of the wall.
8. Duodenum: topography, relation to peritoneum, parts; duodenojejunal flexure. Blood supply, innervation, regional lymph nodes.
9. Relief of the small intestine mucosa in the various parts of it. Localization and the functional significance of large and small duodenal papilla.
10. Large intestine: functions, parts, features a wall of the structure. Blood supply, innervation, regional lymph nodes.

**Students should be able to find on anatomical preparations and visual aids following structures and to know their Latin names:**

1. Pharynx. 2. Nasal, oral, laryngeal part of the pharynx. 3. Pharyngeal tonsil. 4. Palatine tonsil. 5. Pharyngobasilar fascia. 6. Pterygomandibular raphe. 7. Superior (middle, inferior) pharyngeal constrictor. 8. Palatopharyngeal muscle. 9. Stylopharyngeus muscle. 10. Bucco-pharyngeal fascia. 11. Esophagus. 12. Stomach. 13. Large (small) curvature of the stomach. 14. Cardiac, fundus (vault), body, the pyloric part of the stomach. 15. The small intestine. 16. Duodenum. 17. Jejunum. 18. Ileum. 19. Colon. 20. Cecum. 21. Vermiform appendix. 22. Ascending, transverse, descending, sigmoid colon. 23. Rectum. 24. Anal canal.

**Repeat:** glossopharyngeal and vagus nerves.

## GLOSSARY

**Tubular** organs look like tubes of different diameters and lengths; its wall consists of four layers: the mucous membrane, the submucosa, the muscular membrane, the serous membrane or adventitia.

**The throat** is the common portion of the respiratory and digestive tracts adjoining the nasal and oral cavities. It is a tube, about 12 cm long, attached to the base of the skull. The nasal cavity opens into the upper part (*nasopharynx*), the oral cavity into the middle part (*oropharynx*), and the larynx and into the lower part (*laryngopharynx*). The pharyngeal wall consists of *mucosa, striated muscle, and a connective tissue fascia*. The pharyngeal muscles include the muscles taking part in swallowing, the *pharyngeal constrictors* and the *pharyngeal levators*.

**Pharyngeal tonsil** (adenoidal tonsil) — unpaired cluster of lymphoid tissue located in the submucosa of the posterior pharyngeal wall.

**Tubular tonsils** — cluster of lymphoid tissue in the submucous base of the nasopharynx near the pharyngeal opening of the auditory tube.

**The pharyngeal lymphoid ring** [the Pirogov-Valdeier ring] is located around the entrance to the pharynx at oral and nasal cavities. Includes *two palatine, two tubular, lingual and pharyngeal tonsils*.

**Pharyngobasilar fascia** is a fibrous plate located between the mucosa and the muscular membrane of the pharynx and especially develops in the nasopharynx.

**Pterygomandibular raphe** is a fibrous fold stretched between the pterygoid hamulus and mandible; origin place of the upper constrictor of the pharynx and the buccal muscle.

**Buccopharyngeal fascia** covers the buccinator muscle and at the anterior edge of the masticatory muscle passes to the inner surface of the mandibular ramus and on the medial pterygoid muscle, and also covers the superior constrictor of pharynx.

**The esophagus** transports the bolus from the pharynx into the stomach. In the adult, the esophagus is about 25–30 cm long. It runs through the thorax behind the trachea and in front of the spine. Below, the esophagus penetrates the diaphragm through the esophageal hiatus to empty directly into the stomach. The esophagus can be divided into a short *cervical* part, a *thoracic* part, and an *abdominal* part. In certain places the esophagus is narrowed by esophageal constrictions. The highest constriction is at the cricoid cartilage. In the middle the closely related *aortic arch* causes a constriction. The *lowest constriction* corresponds to the diaphragmatic.

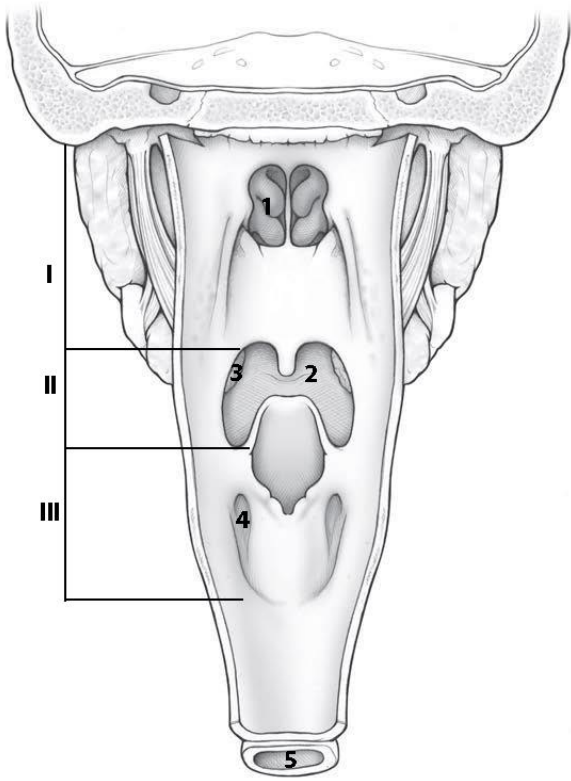
**The stomach** is located in the left upper quadrant of the abdomen under the diaphragm. It consists of cardia, fundus, body, pyloric antrum, pylorus. At the cardia, the esophagus opens into the stomach directly below the diaphragm. The upper border of the body of the stomach is formed by *the lesser curvature*, the lower border by the *greater curvature*. Where the stomach meets the duodenum it expands to form the *pyloric antrum* and immediately behind it lies the pylorus, a circular sphincter muscle. On the outer surface the stomach is covered by peritoneum.

**The small intestine** is located between the stomach and the large intestine. Includes the *duodenum, jejunum and ileum*. The *duodenum* is located behind the peritoneum, the jejunum and ileum are covered with the peritoneum from all sides (there is no anatomical border between them).

**The large intestine** is the terminal part of the digestive tract. Anatomically consists of *cecum* with a vermiform appendix, *ascending colon, transverse colon, descending colon, sigmoid colon and rectum*, and anal canal. In addition to the larger diameter, the large intestine differs from the small intestine by the presence of the *haustra and taenia coli*, as well as *the epiploic appendices and semilunar folds* on the mucosa.

**SELF-INSTRUCTIONAL MATERIALS**

**Pharynx and Esophagus**

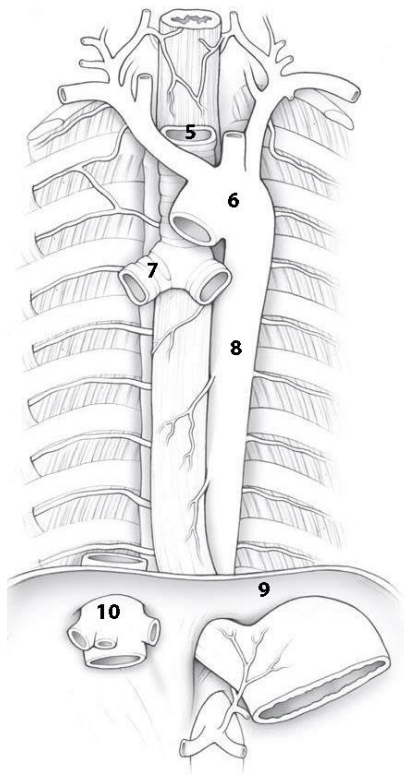


**COLOR** the following features of the pharynx and esophagus, using a different color for each feature:

- Soft palate
- Uvula
- Epiglottis
- Esophagus

**WRITE** the name of structures labeled on the diagram:

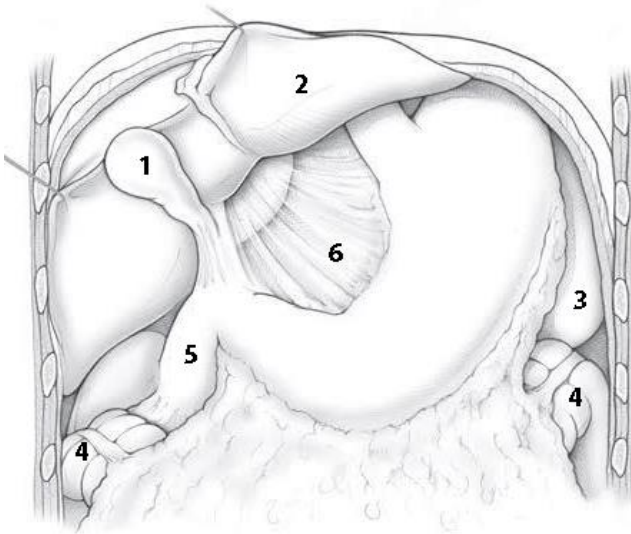
I	_____
II	_____
III	_____
1.	_____
2. Root of	_____
3.	_____ tonsil
4.	_____ recess
5.	_____



**WRITE** the name of structures labeled on the diagram:

5.	_____
6.	_____
7.	_____
8.	_____
9.	_____
10.	_____

## Stomach



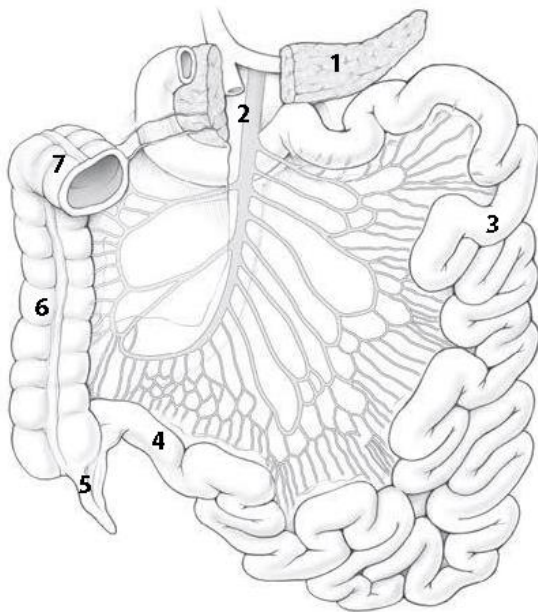
**COLOR** the following features of the pharynx and esophagus, using a different color for each feature:

- Fundus of stomach
- Body of stomach
- Pyloric antrum
- Pyloric canal

**WRITE** the name of structures labeled on the diagram:

1.	4. Colic flexure
2.	5.
3.	6. ligament

## Small and Large Intestine



**COLOR** the following features of the small intestine, using a different color for each feature:

- Superior part of the duodenum
- Descending part of the duodenum
- Horizontal part of the duodenum
- Ascending part of the duodenum

**WRITE** the name of structures labeled on the diagram:

1.	5.
2. artery/vein	6.
3.	7.
4.	

## CONTROL QUIZ

1. Location of pharynx relation to vertebral column

---
2. Nasopharynx communicates with nasal cavity through

---
3. Name the muscles elevated the pharynx

---
4. Innervation of pharynx realized by

---
5. Name the narrowest parts of the esophagus

---
6. How many layers in the muscle layer of the wall of the esophagus and stomach?

---
7. Location of stomach relation to vertebral column

---
8. Parts of stomach

---
9. Sources of blood supply of the abdominal organs

---
10. Differences between jejunum and ileum are

---

## LABORATORY CLASS № 14

### LIVER AND PANCREAS.PERITONEUM AND ITS DERIVATIVES

#### Control questions:

1. Liver: functions, topography, surfaces, edges, lobes. The ligaments of the liver.
2. Grooves of the visceral surface of the liver and its contents. Porta hepatis.
3. Structural and functional unit of the liver: classical and portal hepatic lobules. Blood supply, innervation and regional lymph nodes.
4. Gall bladder: the function, localization, parts. Excretion ways of bile from the liver.
5. Pancreas: function; topography; structure; ducts; blood supply, innervation and regional lymph nodes.
6. The parietal and visceral peritoneum. The ratio of abdominal organs to peritoneum.
7. Derivative of peritoneum: mesentery, ligaments, omentum, folds, omental bursa, grooves, subhepatic space, lateral canals and mesenteric sinuses.
8. The topography of the peritoneum in the upper and lower floors of the peritoneal cavity. The peritoneum in the pelvic cavity in male and female.
9. Planes, lines, and abdomen. Surface anatomy of the abdomen (the projection of the gastrointestinal tract to the skin). Layer by layer structure of the anterolateral wall of the abdomen.
10. Inguinal canal and its contents, holes, walls.

**Students should be able to find on anatomical preparations and visual aids following structures and to know their Latin names:**

1. Liver.
2. Right, left, quadrate, caudate lobes of liver.
3. Coronary, falciform, round ligaments, ligamentum venosum.
4. Porta hepatis.
5. Gallbladder.
6. Cystic duct.
7. Common hepatic duct.
8. Common bile duct.
9. Pancreas.
10. Head, the body, the tail of the pancreas.
11. The pancreatic duct.
12. Accessory pancreatic duct.
13. Peritoneum.
14. Peritoneal cavity.
15. Greater and lesser omentum.
16. Mesentery of the small intestine.
17. Transverse mesocolon.
18. Sigmoid mesocolon.
19. Inguinal canal.

**Repeat:** abdominal muscles, diaphragm.

## GLOSSARY

**Abdominal cavity** is bounded above the diaphragm, anteriorly and laterally — abdominal muscles, posteriorly — back muscles, inferiorly it continues to the pelvic cavity. Abdominal wall covered with the parietal peritoneum.

**Peritoneum** — serous membrane covering the abdominal wall and continued on the organs (visceral peritoneum). Organs covered by peritoneum by all sides, are intraperitoneal (stomach, ileum and jejunum, spleen, gall bladder, cecum with vermiform appendix, transverse and sigmoid colon); peritoneum covered by three sides — mesoperitoneal (liver, ascending and descending colon); covered by peritoneum only anteriorly — have retroperitoneal position (duodenum, pancreas, kidneys).

**Peritoneal cavity** — slit-like space between the parietal and visceral peritoneum. Mesentery of the transverse colon divides the peritoneal cavity in the upper and lower floors. In the upper floor there are omental bursa, subphrenic and subhepatic recess, in the lower floor — the lateral canals and mesenteric sinuses.

**Retroperitoneal space** located at the posterior wall of the abdomen, between the parietal peritoneum and intraabdominal fascia covering the back muscles; It extends from the diaphragm to the entrance of the pelvis.

**Greater omentum** is the dorsal mesentery fold of the stomach. It consists of four sheets of the peritoneum, between which there is fatty tissue. Two leaves of peritoneum start at greater curvature of the stomach, down to the umbilicus (sometimes lower), bent backward and lifted up in front of the transverse colon and small intestine, heading for the back wall of the abdomen.

**Lesser omentum** derived from the ventral mesentery of the stomach. It consists of hepatophrenic, hepatoesophageal, hepatogastric and hepatoduodenal ligament. In clinical practice, lesser omentum is: hepatogastric and hepatoduodenal ligaments, which are clearly visible during the surgical intervention.

**Mesentery** — duplication of the peritoneum through which abdominal organs attached to the back wall of the abdomen. The mesentery transmits the neurovascular structures that supply the intraperitoneal organs.

**Omental bursa** — relatively isolated space of the upper floor of the peritoneal cavity. It is located behind the stomach and looks like frontally positioned slots. The anterior wall of omental bursa is formed by the lesser omentum, stomach and gastrocolic ligament; the superior wall — the caudate lobe of the liver; the inferior wall — by the mesentery of the transverse colon; the posterior wall — the parietal peritoneum; left wall — the spleen and its ligaments.

**Subphrenic recess** — slot-like space on both sides of the falciform ligament between the diaphragm and the upper surface of the liver.

**Subhepatic recess** — the space between the visceral surface of the liver superiorly and transverse colon with its mesentery inferiorly.

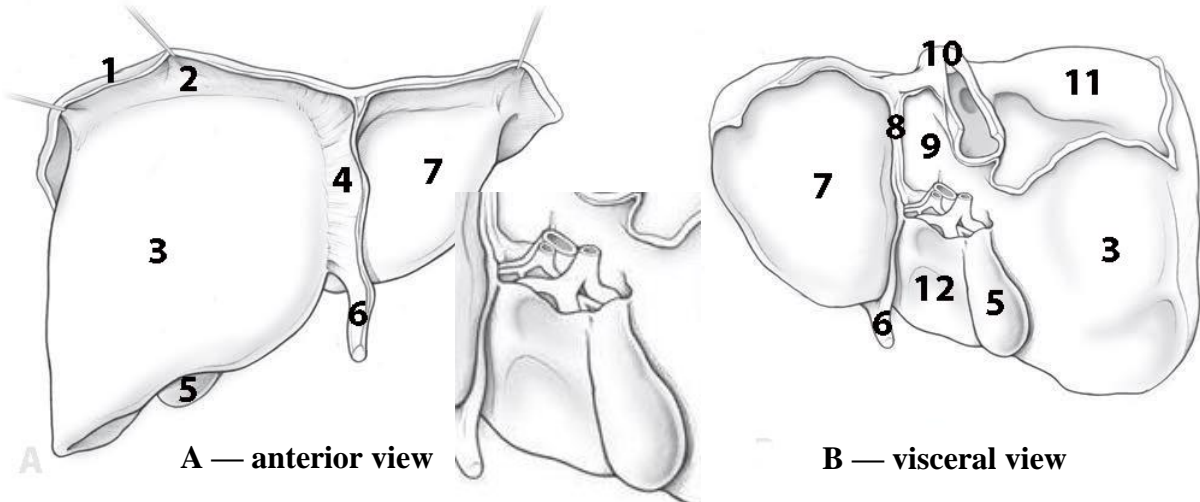
**Liver lobes.** Liver separates into the right and left lobes by the *falciform ligament* on the *diaphragmatic surface*, *round* (contains fetal umbilical vein) and *venous* ligament on the *visceral surface*. The surgical lobe of the liver forms by separating it by the right or left branch of the portal vein of the liver. On the *visceral surface* of the liver lies the **porta hepatis**, the entrance and exit of blood vessels (entering: *portal veins*, *hepatic artery*; exiting: *bile duct*, *lymph vessels*) and nerves. In front of the porta hepatis bulges the *quadrate lobe* of the liver, and behind it the *caudate lobe*. On the right side, the right lobe of the liver is bordered by a groove, in the front of which lies the *gallbladder*, while the *inferior vena cava* runs behind.

**Inguinal canal** — slot-like space in the lower part of the anterolateral wall of the abdomen. It contains spermatic cord in men, in women — the round ligament of the uterus. It is the place of forming of inguinal hernias.

SELF-INSTRUCTIONAL MATERIALS

Liver

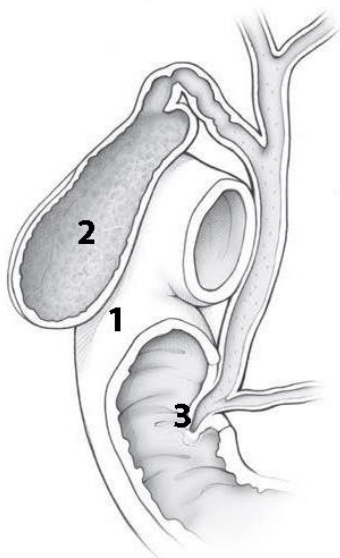
**COLOR** the following features of the portal triad, using the suggested colors for each feature: Hepatic artery branch (red); Portal vein (blue); Bile duct (green).



Portal triad

**WRITE** the name of structures labeled on the diagram:

1.		7.	
2.	ligament	8.	Ligament
3.		9.	
4.	ligament	10.	
5.		11.	area
6.	ligament	12.	



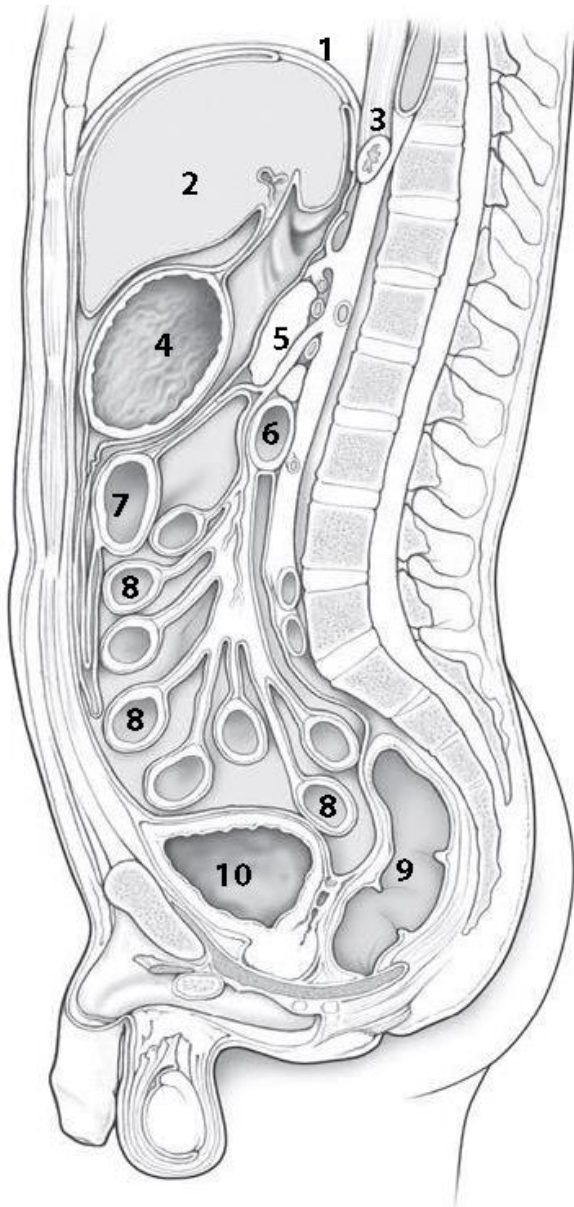
**COLOR** the following features, using a different color for each feature:

- Right/left hepatic duct
- Cystic duct,
- Common hepatic duct,
- Common bile duct,
- Main pancreatic duct

**WRITE** the name of structures labeled on the diagram:

1.	
2.	part
3.	papilla

## Peritoneal Cavity and Mesenteries



**COLOR** the following features of the peritoneal cavity, using a different color for each feature:

- Lesser omentum
- Transverse mesocolon
- Mesentery of the small intestine
- Greater omentum
- Omental bursa
- Rectovesical pouch

**WRITE** the name of structures labeled by the number:

1. \_\_\_\_\_
2. \_\_\_\_\_
3. \_\_\_\_\_
4. \_\_\_\_\_
5. \_\_\_\_\_
6. Inferior part of \_\_\_\_\_
7. \_\_\_\_\_
8. \_\_\_\_\_
9. \_\_\_\_\_
10. \_\_\_\_\_

## CONTROL QUIZ

1. Name ligaments of the diaphragmatic surface of liver are \_\_\_\_\_
2. Lobes of visceral surface of liver \_\_\_\_\_
3. Portal triad (at the porta hepatis) are \_\_\_\_\_
4. Types of hepatic lobules are \_\_\_\_\_
5. Where does the pancreatic duct open? \_\_\_\_\_
6. Topography of pancreas \_\_\_\_\_
7. Peritoneal spaces in women and men pelvic cavity \_\_\_\_\_
8. Colon attached to the posterior wall of the abdomen by \_\_\_\_\_
9. Greater omentum consists of \_\_\_\_\_ sheets of the peritoneum \_\_\_\_\_
10. Inguinal canal contains \_\_\_\_\_ in men, \_\_\_\_\_ in women

# RESPIRATORY SYSTEM

## LABORATORY CLASS № 15

### FUNCTIONAL ANATOMY OF RESPIRATORY SYSTEMS. PLEURA. MEDIASTINUM

#### Control questions:

1. General characteristics of the respiratory system: functions, division into the upper and lower respiratory tract.
2. External nose. The nasal cavity, the bones forming its walls. Nasal meatuses, communication with the paranasal sinuses and the orbit. Blood supply and innervation of the skin of the external nose, the mucous membrane of the walls of the nasal cavity.
3. Topography of the paranasal sinuses. Maxillary sinus: walls; blood supply and innervation of the mucous membrane.
4. Olfactory organ. The conductive path of the olfactory analyzer.
5. Larynx: topography, functions. Cartilages and larynx ligaments. Joints and muscles of the larynx.
6. Muscles of the larynx: classification, functions.
7. Departments of the larynx cavity: laryngeal vestibule, ventricle, infraglottic cavity. Blood supply and innervation of the mucous membrane and muscles of the larynx.
8. Trachea and bronchi: topography, wall structure; Blood supply and innervation. Differences between the right and left main bronchi; level of tracheal bifurcation.
9. Lungs: functions, surfaces, borders, fissures, lobes; bronchopulmonary segments. Features of blood flow. Innervation, blood supply and regional lymph nodes.
10. Bronchial and alveolar tree. Structural and functional unit of the lung.
11. Pleura: parts, borders. Pleural cavity and pleural recesses.
12. Mediastinum: boundaries, division into parts; Organs of the mediastinum.
13. Superficial anatomy of the thorax.

#### Students should be able to find on anatomical preparations and visual aids following structures and to know their Latin names:

1. External nose. 2. Root, dorsum, tip, ala of the nose. 3. The nasal cavity. 4. Choanae. 5. Nasal septum. 6. Superior (middle, inferior) nasal concha. 7. Superior (middle, inferior) nasal meatus. 8. Paranasal sinuses: maxillary, sphenoidal, frontal, ethmoidal cells. 9. Semilunar hiatus. 10. Larynx. 11. Thyroid cartilage. 12. Cricoid cartilage. 13. Arytenoid cartilage. 14. Epiglottis. 15. Cricothyroid ligament. 16. Vocal cords. 17. Laryngeal cavity. 18. Laryngeal inlet. 19. Laryngeal ventricle. 20. Vestibular fold. 21. Vocal fold. 22. Lungs (right, left). 23. Base of the lung. 24. The border. 25. Cardiac notch. 26. Hilum of the lung. 27. The root of the lung. 28. Superior (middle, inferior) lobe. 29. Oblique fissure. 30. Horizontal fissure. 31. Pleura. 32. Costodiaphragmatic recess. 33. Costomediastinal recess. 34. Phrenicomediastinal recess. 35. Mediastinum (superior, inferior). 36. Trachea. 37. Bifurcation of the trachea. 38. The main bronchus (right, left).

**Repeat:** bone nasal cavity, thoracic skeleton, thoracic muscles.

## GLOSSARY

**The upper respiratory tract** consists of the nasal cavity, the nasal and oral part of the pharynx. Some authors also consider vestibule of larynx (up to the level of the vocal cords) is the upper respiratory tract.

**The voice apparatus (glottis)** is represented by a vocal fold and a rima glottidis; formed the voice.

**The lower respiratory tracts** are formed by the larynx, trachea, bronchial and alveolar tree.

**Bronchial tree** — all extrapulmonary and intrapulmonary branching of the bronchi, including the terminal bronchioles.

**Bronchi** begin from the bifurcation of the trachea. The trachea divides into the right and left primary bronchi. The *primary bronchi* divide into *lobar bronchi* that divide into smaller *segmental bronchi* and then into the *subsegmental* (first, second, third generation — only 9–10), *interlobular and intralobular bronchi*. In the smallest bronchi (diameter of 1–2 mm) cartilage plates and glands gradually **disappear, and the muscular plate of the mucous membrane becomes relatively thicker.**

**Bronchioles** are the smallest branching of the respiratory tract with diameter of 0.5 to 1 mm. There are about 20 generations of bronchioles, the last of which is *terminal bronchioles*. There are no cartilages in the walls of bronchioles.

**Pulmonary acinus** is a structural and functional unit of the lung, includes *respiratory bronchioles, alveolar ducts, alveolar sacs and alveoli*.

**Respiratory parenchyma** of the lung provides diffusion exchange of gases between the gas mixture of the cavity of the pulmonary acinus and the blood of the surrounding blood vessels.

**Lobe of the lung** — the pyramidal form section of lung tissue, consisting of 16–18 acini. The base of the pyramid directs to the surface of the lung. The lobules are separated from each other by connective tissue septa, in which the vessels and nerves pass.

**The bronchopulmonary segment** has pyramidal form ventilating by the segmental bronchus and supplying with blood from the corresponding branch of the pulmonary artery. On the periphery, the segments are fused to each other and, in contrast to the pulmonary lobules, which don't have interlayers of connective tissue. Each segment has a conical shape, the tip of which is facing the gates of the lung, and the base — to its surface. Each lung includes 10 segments.

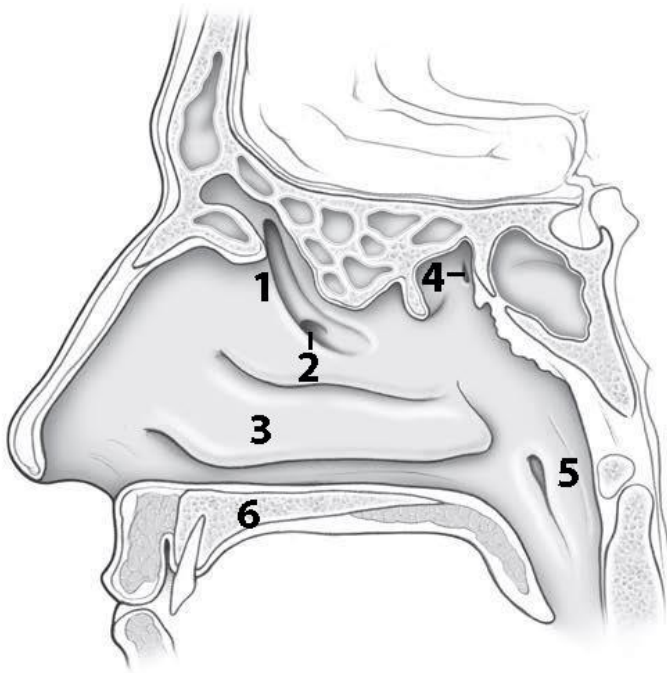
**The cavity of the pleura** is a hermetically closed space between the parietal and visceral pleura with negative pressure. Preservation of the hermetic of the pleural cavity is one of the prerequisites for normal breathing. The pleural cavity around the right and left lungs does not communicate with each other.

**Pleural sinuses** — spaces in the pleural sac along the lower and inferior portions of the lung that the lung does not occupy. There are costomediastinal, costodiaphragmatic, phrenicostomediastinal recesses.

**Mediastinum** - the space between the right and left pleural cavities, where complex of organs, including the heart, trachea, esophagus, vessels and nerves locate. Anteriorly the mediastinum is confined to the sternum, laterally — to the mediastinal parts of the parietal pleura, posteriorly — the spine, inferiorly — the diaphragm.

**SELF-INSTRUCTIONAL MATERIALS**

**Paranasal sinuses**



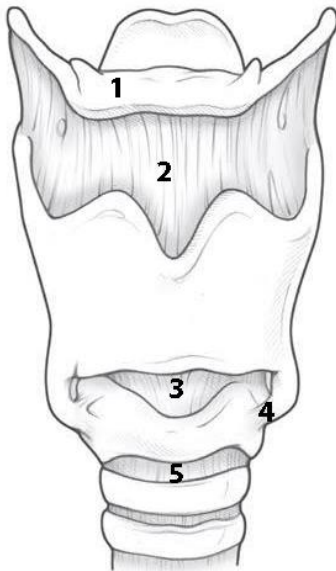
**COLOR** the following paranasal sinuses, using a different color for each sinus:

- Frontal sinus
- Ethmoid air cells (sinuses)
- Sphenoid sinus
- Maxillary sinus

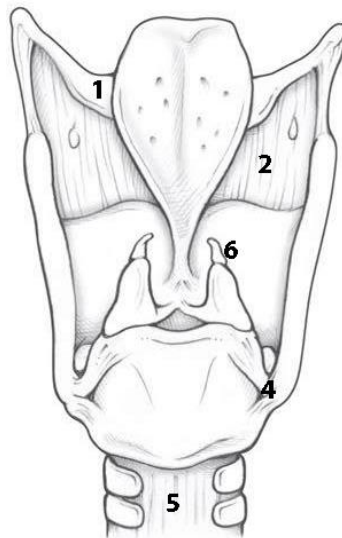
**WRITE** the name of structures labeled by the number:

1. \_\_\_\_\_ hiatus
2. Opening of \_\_\_\_\_
3. \_\_\_\_\_
4. Opening of \_\_\_\_\_
5. \_\_\_\_\_
6. \_\_\_\_\_

**Laryngeal cartilage**



**A — anterior view**



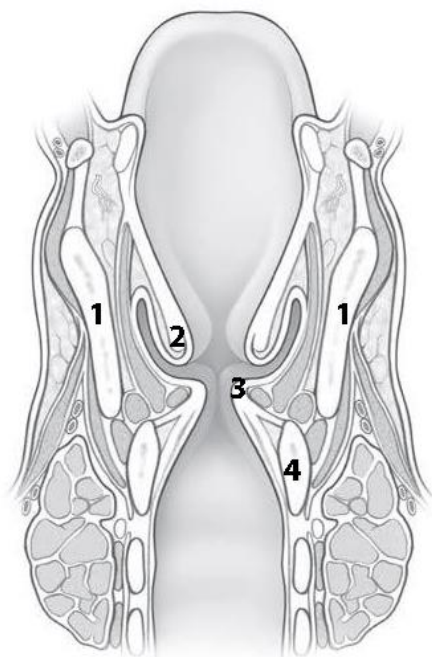
**B — posterior view**

**COLOR** the following features of the larynx, using a different color for each cartilage:

- Epiglottis
- Thyroid cartilage
- Cricoid cartilage
- Arytenoid cartilage

**WRITE** the name of structures labeled by the number:

1. \_\_\_\_\_ bone
2. \_\_\_\_\_ membrane
3. \_\_\_\_\_ ligament
4. \_\_\_\_\_
5. \_\_\_\_\_ joint
6. \_\_\_\_\_ cartilage



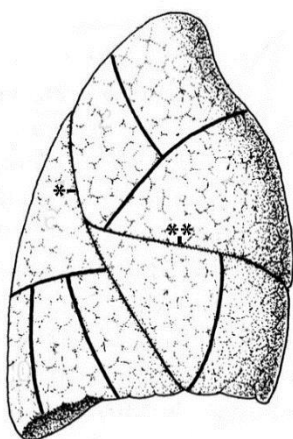
**COLOR** the following features of the larynx, using a different color for each feature:

- Laryngeal vestibule
- Ventricle
- Infraglottic cavity

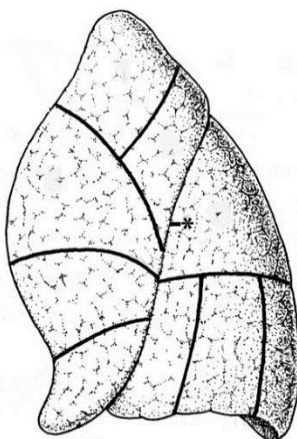
**WRITE** the name of structures labeled by the number:

1.	cartilage
2.	fold
3.	fold
4.	cartilage

**Right and Left lung (costal surface)**



**A — right lung**



**B — left lung**

**COLOR** the lobes of the lungs, using a different color for each of them:

- Superior lobe
- Middle lobe of right lung
- Inferior lobe

**WRITE** the name of fissures labeled by symbols:

1.	_____
2.	_____

**LABEL** the segments of the lung with numbers from 1 to 10.

## CONTROL QUIZ

1. Name the cartilage of external nose  
\_\_\_\_\_
2. The olfactory region of nasal cavity locates at the  
\_\_\_\_\_
3. Cortical center of olfactory organ locates  
\_\_\_\_\_
4. Blood supply of nasal cavity  
\_\_\_\_\_
5. Name the laryngeal joints  
\_\_\_\_\_
6. Innervation of larynx:  
\_\_\_\_\_
7. The right main bronchus is \_\_\_\_\_ and shorter then left one  
\_\_\_\_\_
8. The tracheal bifurcation is at the level of  
\_\_\_\_\_
9. The topography of the apex of lungs  
\_\_\_\_\_
10. What are the differences between bronchi and bronchioles?  
\_\_\_\_\_

# **URINARY SYSTEM AND MALE REPRODUCTIVE SYSTEM**

## **LABORATORY CLASS № 16**

### **ANATOMY OF THE URINARY TRACT. STRUCTURE OF EXTERNAL AND INTERNAL MALE REPRODUCTIVE ORGANS**

#### **Control questions:**

1. General plan of structure and function of the urinary system.
2. Kidneys: topography, structure (surfaces, borders, the poles, hilum of kidney, renal sinus). Fixing apparatus of the kidney.
3. Nephron as a structural and functional unit of the kidney. Blood supply and innervation of kidney.
4. Ureter, urinary bladder: topography, wall structure. Male urethra: parts, constrictions, bends, wall structure.
5. Localization of sphincters, providing voluntary and involuntary retention of urination.
6. General plan of the structure of the male genital system.
7. Structure and function of the testis. Ways of excretion of seminal fluid.
8. Prostate. Seminal vesicle and bulbourethral gland.
9. External male reproductive organs: penis, scrotum.

#### **Students should be able to find on anatomical preparations and visual aids following structures and to know their Latin names:**

1. Kidney.
2. Borders, surfaces, kidney borders, hilum of kidney, renal sinus.
3. Renal cortex.
4. Minor and major renal calices.
5. Renal pelvis.
6. Ureter.
7. Urinary bladder.
8. Male (female) urethra.
9. Testis.
10. Epididymis.
11. Seminiferous tubules.
12. Vas deferens.
13. The seminal vesicle.
14. The ejaculatory duct.
15. Spermatic cord.
16. Prostate.
17. Penis.
18. Scrotum.

## GLOSSARY

**Urinary system** forms by the organs performing the function of producing and excretion of urine. Urine is formed in the kidneys, is excreted along the ureters, accumulates in the urinary bladder and enters through the urethra.

**Renal fascia** — part of the retroperitoneal fascia, which at the lateral border of the kidney is divided into two plates, covering the suprarenal glands, kidney, ureter with their vessels.

**Perirenal fat capsule** is located between two plates of the renal fascia.

**Fibrous capsule** is thin dense connective tissue plate, which is attached to the parenchyma of the kidney and gives interlobular interlayers to the renal cortex.

A longitudinal section through **the kidney** reveals the division of the kidney tissue into *renal cortex* and *renal medulla*. The cortex is a dark red stripe, about 8 mm wide, lying directly under the capsule of the organ. The color of the cortex can be seen with a lens to be due to the numerous small renal corpuscles, each containing a capillary tuft (glomerulus). The *renal cortex* borders on the *renal medulla*, which is formed by **10–12 renal pyramids**. The broad base of a pyramid is directed toward the cortex and they run from there in *medullary rays* (bundles of collecting ducts). Between the renal pyramids, columns of cortex penetrate deep into the medulla. The apices of the pyramids form the *renal papillae*, into which drain the *collecting ducts*. The renal papillae drain into the *renal calices*, which together form a large part of the *renal pelvis*. Between the calyces lies loose areolar and fatty tissue (*renal sinus*), which contains the renal vessels.

**Nephrons** form the structural and functional units of the **kidney** and consist of a **renal corpuscle** (*malpighian body*) and its associated **renal tubule**. The renal tubule consists of *convoluted* and *straight* segments, and the whole tubule is surrounded by a network of blood vessels in its entire course: *a proximal tubule*, initially convoluted, then straight, *a thin transition (Henle's loop)*, *a distal tubule*, initially straight, then convoluted, *a short initial collecting tubule*. While the convoluted tubules are found mainly in the cortex, the straight segments of the tubules as well as Henle's loop run into the medulla. The collecting tubules join the tubule to the system of collecting ducts. The collecting ducts drain into the *renal pelvis* at the apex of the renal papillae.

**Kidney lobe** — pyramid with adjacent renal cortex.

**Ureter** — a tube about 30 cm long that connects the renal pelvis with the urinary bladder. It has the abdominal, pelvic and intra-wall parts and three constrictions are distinguished: at the place of their origin, when they intersect with the iliac vessels and in the wall of the urinary bladder. Ureter transports urine from the renal pelvis to the bladder. It is shaped like a flattened tube with a diameter of about 5 mm and a length of about 25 cm. The two ureters begin at the renal pelvis and run downward along the posterior abdominal wall, each crossing the psoas major muscle and, at the entrance to the true pelvis, the great pelvic vessels (common iliac artery and vein). Along the ureter there are *three physiological constrictions* where urinary stones are most likely to become lodged. They are located at the *ureteropelvic junction*, at the point where the ureter crosses the common iliac vessels, and in its course through the bladder wall.

**Urinary bladder** — extraperitoneal hollow organ situated in the true pelvis, with *body* (roof) of the bladder, *apex* (attached to the anterior abdominal wall), *base* (next to the pelvic floor), and *bladder neck* (transition to the urethra). The bladder muscle (detrusor) forms a network and is lined internally by mucosa (transitional epithelium). The muscular layer of *the trigone* (triangle between the openings of the ureters and the urethra) forms mechanisms for the closing and opening the ureteral orifices and for the *internal urethral orifice* at the bladder neck (**internal sphincter of the urethra** = involuntary smooth sphincter muscle; **external urethral sphincter** = voluntary striated sphincter).

**System of reproductive organs** is formed by the sex glands, genital tract, accessory glands, copulatory organs and fetal bearing organs.

**Male system of reproductive organs** includes internal male organs (*testis, epididymis, vas deferens and ejaculatory duct, seminal vesicle, prostate, bulbourethral glands*) and external male organs (*penis and scrotum*).

**Testis** — the male gonads located in the scrotum. Each testis is surrounded by a dense white connective tissue capsule (*tunica albuginea*), from which connective tissue septa run inward. In this way the tissue of the testis is subdivided in-completely into more than 200 compartments (*lobuli testis*). Each lobule is made up of two to four extensively convoluted seminiferous tubules that measure 350 m in total and the epithelium of which forms the spermatozoa. The connective tissue between the seminiferous tubules contains the endocrine interstitial cells of Leydig (*Leydig cells*) that produce the male sex hormones (*testosterone*).

**Epididymis** located along the posterior border of the testis. This structure serves as a store for sperm. The epididymis is divided into a head, a body, and a tail. It includes the efferent ductules of the testis and the duct of the epididymis, which is about 5 m in length. The ducts are markedly convoluted and are packed tightly into a single mass by connective tissue. In the tail of the epididymis the duct of the epididymis continues into the vas deferens.

**Vas deferens** is 50–60 cm long. It transports the spermatozoa during ejaculation. It is sheathed in connective tissue together with the testicular vessels and nerves, forming the *spermatic cord*, which runs through the inguinal canal and on into the pelvis. Toward its end, the vas deferens widens into a spindle-shaped *ampulla*, is joined by the *duct of the seminal vesicle* to form the *ejaculatory duct*, pierces the *prostate*, and opens into the prostatic part of the urethra.

**Seminal vesicle** are large thin-walled glands, about 10 cm long, that lie on the posterior wall of the urinary bladder, abutting on the rectum. The excretory duct of the seminal vesicle runs at an acute angle into the vas deferens below the ampulla. The secret of the seminal vesicle is formed the seminal fluid.

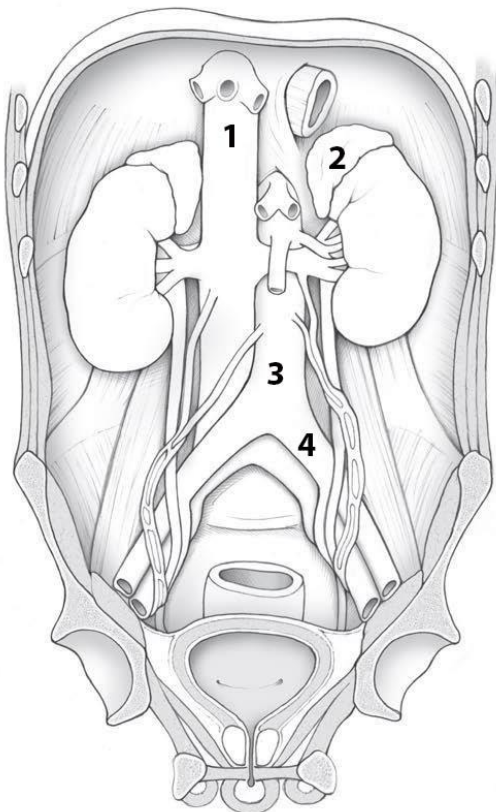
**The ways of excretion of the seminal fluid** are the convoluted and straight tubules of the testis, the rete testis, efferent ductuli, epididymis duct, the vas deferens, ejaculatory duct, the male urethra.

**Prostate** is a glandular-muscular organ that covers the proximal part of the urethra. The glandular component is represented by prostatic glands, the excretory ducts of which open into the prostatic part of the urethra. The secret of the glands activates the spermatozoa and dilutes the sperm. Reduction of smooth muscle cells of the prostate provides release of the secretion of the gland into the urethra.

**Spermatic cord** — passes in the inguinal canal, includes the *vas deferens*, the *cremaster muscle*, the artery / veins, the lymph vessels and the nerve plexuses. The spermatic cord is formed during the process of lowering the testicle from the abdominal cavity into the scrotum.

## SELF-INSTRUCTIONAL MATERIALS

### Kidney and ureter



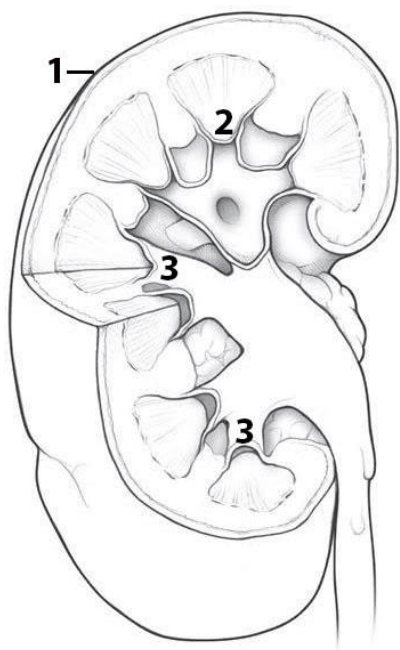
**COLOR** each of the following structures, using a different color for each structure:

- Kidney
- Ureter
- Urinary bladder
- Urethra

**WRITE** the name of structures labeled by the number:

1. \_\_\_\_\_
2. \_\_\_\_\_ gland
3. \_\_\_\_\_
4. \_\_\_\_\_ artery

### Sectioned right kidney



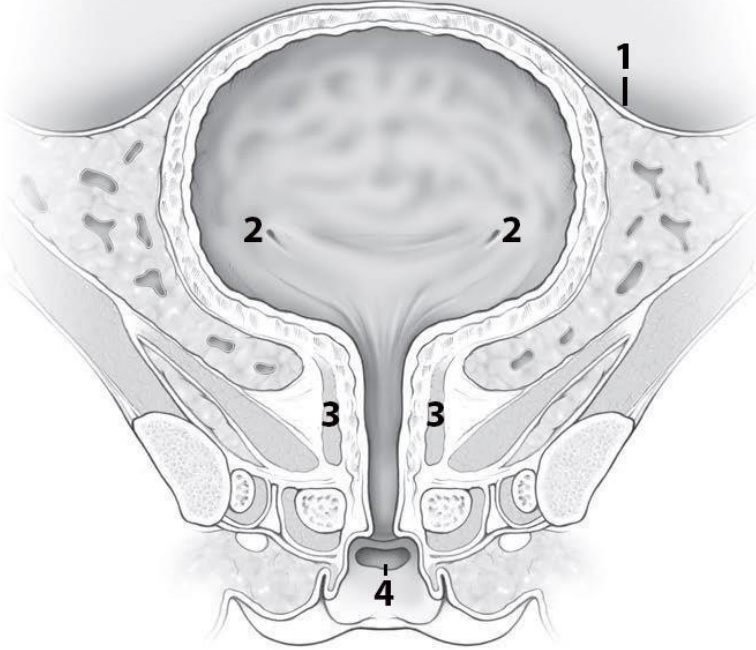
**COLOR** each of the following features of the kidney, using a different color for each feature:

- Ureter
- Renal cortex
- Renal pyramids (medulla)
- Major calices
- Renal pelvis

**WRITE** the name of structures labeled by the number:

1. \_\_\_\_\_ capsule
2. Renal \_\_\_\_\_
3. Minor \_\_\_\_\_

## Female urinary bladder (frontal section)



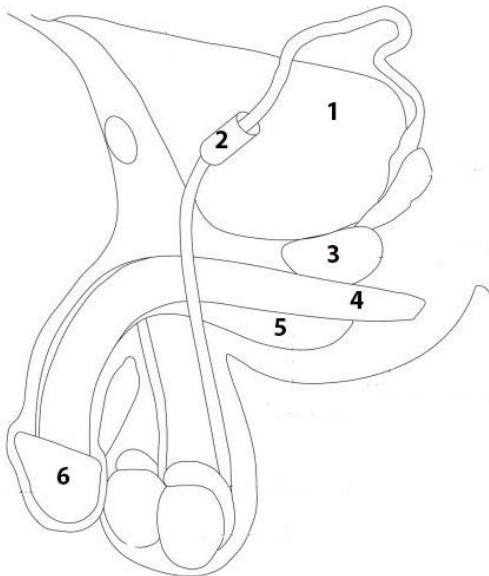
**COLOR** the following features of the urinary bladder and urethra, using a different color for each feature:

- Detrusor muscle
- Trigone of bladder
- Female urethra

**WRITE** the name of structures labeled by the number:

1.	
2.	orifice
3.	muscle
4.	

## Male reproductive system



**COLOR** the following features of the urinary bladder and urethra, using a different color for each feature:

- Ductus deferens
- Seminal vesicle
- Epididymis
- Testis

**WRITE** the name of structures labeled by the number:

1.	
2.	canal
3.	
4.	Corpus
5.	Corpus
6.	

## CONTROL QUIZ

1. Topography of kidney

---

2. The external layer of kidney is \_\_\_\_\_ and the internal layer of kidney is \_\_\_\_\_

---

3. Kidney has \_\_\_\_\_ (number) minor calyces and \_\_\_\_\_ major calyces

---

4. Nephron consists of \_\_\_\_\_

---

5. Name the layers of the ureter wall

---

6. Name the 3 orifices of trigone of bladder

---

7. Compare male and female urethra

---

8. Ejaculatory ducts forms \_\_\_\_\_ and opens into \_\_\_\_\_

---

9. Prostate contains \_\_\_\_\_ tissues

---

10. Blood supply of testes

---

# FEMALE REPRODUCTIVE ORGANS

## LABORATORY CLASS № 17

### STRUCTURE OF FEMALE REPRODUCTIVE ORGANS

#### **Control questions:**

1. Functions and general plan of the structure of the female reproductive system.
2. Ovary: functions, topography, structure, relation to the peritoneum; blood supply, innervation.
3. Uterus: function, topography, structure. Ligament of the uterus, relation to the peritoneum; blood supply, innervation.
4. Uterine tube: structure, relation to the peritoneum.
5. Vagina: structure of wall.
6. External female genitalia: pubis, labia majora and minora, greater vestibular glands, clitoris; structure.

**Students should be able to find on anatomical preparations and visual aids following structures and to know their Latin names:**

1. Ovary.
2. Uterine tube.
3. Uterus.
4. Fundus, body, cervix.
5. Endometrium.
6. Myometrium.
7. Perimetrium.
8. Parametrium.
9. Broad and round ligament of the uterus.
10. The vagina.
11. Labia majora and minora.
12. The clitoris.
13. Greater vestibular glands.

## GLOSSARY

**The female reproductive system:** the two ovaries, the two fallopian tubes, the uterus, and the vagina. The external organs include the major and minor labia, the clitoris, the vestibule, the vestibular glands.

**The ovary is attached** by ligaments to the pelvic wall (*suspensory ligament of the ovary*) and the uterus (*ovarian ligament*). Anteriorly they are loosely attached to the broad ligament of the uterus (*ligamentum latum uteri*) by a suspending ligament (*mesovarium*). In size and shape the ovaries resemble two almonds. After maturation and preparation of the ovum, the ovary secretes hormones into the bloodstream that coordinate the processes in the uterus and vagina (*estrogen, progesterone*).

**The ovary consists** of a *cortex and a medulla*. The medulla contains blood vessels that enter the ovary through the mesovarium. The cortex of an ovary in a woman during her reproductive years lies directly under the surface. It contains *ovarian follicles* in various stages of maturation (*primary, secondary, and tertiary or graafian follicles*), involuted follicles (*atretic follicles*), usually no more than one yellow body (*corpus luteum*), and the scarred remains of old corpora lutea (*corpora albicantia*).

**The fallopian tubes** are about 10–15 cm long and are incorporated into the broad ligament of the uterus by a ligament (mesosalpinx). It begins at the level of the ovary at the abdominal ostium (opening) as a funnel lined with fringes (*infundibulum, fimbriated end*) and runs into the uterus at an angle. It is usually divided into the narrow uterine end (*isthmus*) and the wider outer part (*ampulla*) in which fertilization takes place

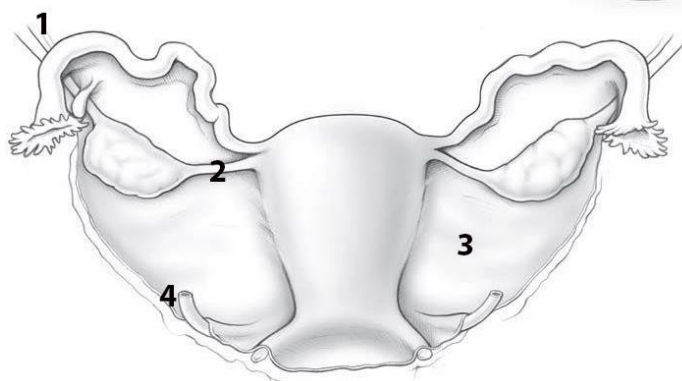
During pregnancy, the **uterus** supports the fertilized ovum. In shape and size, it resembles a pear, and it lies between the urinary bladder and the rectum. It is divided into a body, a fundus situated between the tubal ostia, and a narrow isthmus. The cervix is conical and below is directed backward into the vaginal vault. There is an external opening in the part projecting into the vagina, the external os. The uterine cavity is a narrow slit lined with mucous membrane (*endometrium*). The rest of the wall consists of a muscular layer (*myometrium*) up to 2 cm thick and a peritoneal covering over the corpus and fundus (*perimetrium*). The connective tissue space on each side of the uterus is called the *parametrium*. Depending on the phase of the cycle, the uterine mucosa is 2–8 mm thick and is lined by a simple epithelium. The mucosal connective tissue contains numerous tubular glands with ducts opening into the uterine cavity. The cyclic changes of the uterine mucosa affect chiefly the functional layer.

**The vagina** is a thin-walled tube, about 10 cm long, with a weakly developed muscle layer. Its blind end surrounds the vaginal portion of the uterus, forming the vaginal vault. Its anterior end opens into the vaginal vestibule. It is lined with a stratified squamous epithelium that shows changes with the menstrual cycle: during the second phase of the cycle, the superficial epithelial cells, which in this phase have an especially high glycogen content, are increasingly desquamated.

**Perineum** — a complex of soft tissues located between the pubic symphysis anteriorly, ischial tubercles from the lateral sides and the coccyx posteriorly. The anterior region of the perineum is occupied by the urogenital diaphragm, the posterior region — by the pelvic diaphragm. The urethra and vagina (in women) pass through the urogenital diaphragm. The final section of the rectum locates in the diaphragm of the pelvis. The muscles of the perineum form the external (voluntary) sphincters of the urethra and rectum. In obstetrics, the perineum refers to the gap between the posterior commissure of the labia majora and the anus.

## SELF-INSTRUCTIONAL MATERIALS

### Uterus: posterior view



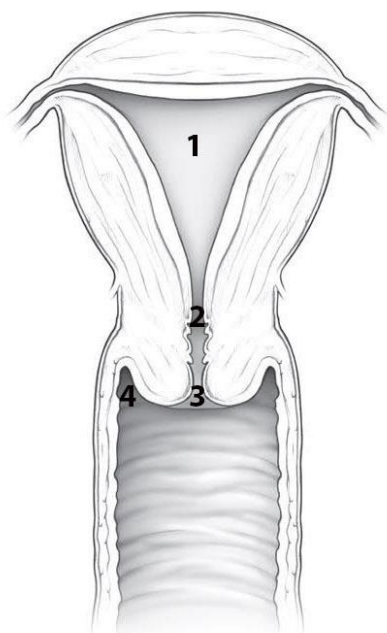
**COLOR** the following features of the female reproductive system, using a different color for each feature:

- Uterine tube
- Ovary
- Uterus

**WRITE** the name of structures labeled by the number:

1.	ligament	3.
2.	Ligament	4.

### Uterus & vagina



**COLOR** the following features of the uterus and vagina, using a different color for each feature:

- Fundus of the uterus
- Body of the uterus
- Cervix of the uterus
- Vagina

**WRITE** the name of structures labeled by the number:

1.	cavity
2.	Anatomical internal
3.	External
4.	Vaginal

## CONTROL QUIZ

1. Ligaments of ovary

---

2. The parts of uterus

---

3. Myometrium consists of \_\_\_\_\_ layers

---

4. Topography of uterus

---

5. Name the ligaments of uterus

---

6. Name the pouches of the female pelvic cavity

---

7. Name the parts of uterine tubes

---

8. The abdominal ostium of the tube at the infundibulum is surrounded by

---

9. The vaginal mucosa has transverse folds

---

10. After ovulation on the surface of ovary forms

---

## LABORATORY CLASS № 18

### FINAL CLASS FOR THE «INNER ORGANS SYSTEMS»

#### Control questions:

1. Oral cavity. The structure of the oral vestibule: arches, folds of mucous membrane. The lips of the mouth. Innervation, blood supply, regional lymph nodes.
2. Oral cavity propria: boundaries, walls. The structure of the hard palate: innervation, blood supply of the mucous membrane of the hard palate, the regional lymph nodes.
3. Soft palate: structure, functions. Muscles of the soft palate. Innervation, blood supply of the mucous membrane and muscles of the soft palate; the regional lymph nodes.
4. Tongue: functions, sources development, part. Muscles of the tongue. Innervation, blood supply, regional lymph nodes.
5. The oral cavity floor: the relief of the mucous membrane. Innervation, blood supply, regional lymph nodes.
6. General morphofunctional characteristics of the teeth. Innervation, blood supply, teeth; regional lymph nodes.
7. Pharynx: function, topography, divisions. The structure of the pharyngeal wall. Lymphoepithelial pharyngeal ring. Innervation, blood supply, regional lymph nodes.
8. Esophagus: topography, divisions, the structure of the wall. Innervation, blood supply, regional lymph nodes.
9. Stomach: topography, structure. Innervation, blood supply, regional lymph nodes.
10. Small intestine: functions, divisions, structure. Innervation, blood supply, regional lymph nodes.
11. Large intestine: functions, divisions, structure. Innervation, blood supply, regional lymph nodes.
12. Liver: function, structure. The gallbladder: ways of excretion of bile. Innervation, blood supply of the liver and gallbladder, regional lymph nodes.
13. Pancreas: topography, structure. Excretory ducts. Innervation, blood supply.
14. The parietal and visceral peritoneum, peritoneal cavity. Derivatives of the peritoneum: the greater and lesser omentum, fossa, folds.
15. External nose: part of the cartilage of the nose. The nasal cavity: the structure of the walls, conches and nasal passages, the message paranasal sinuses. Innervation, blood supply of the mucous membrane; the regional lymph nodes.
16. Structural-functional characteristics of the olfactory organ. The olfactory nerves pathway of the olfactory analyzer.
17. Larynx: functions, topography, structure. Cavity of the larynx. Innervation, blood supply, regional lymph nodes.
18. Trachea, bronchi: function, structure. Innervation, blood supply, regional lymph nodes.
19. Lungs: function, structure. Innervation, blood supply, regional lymph nodes.
20. The visceral and parietal pleura, the pleural cavity. Pleural recess. Mediastinum: the division into parts, the mediastinum.
21. Kidney: topography, function, structure, blood supply, innervation of the kidney.
22. The ureter, urinary bladder, urethra (male and female). Function, structure, blood supply, innervation.
23. Functional morphology of the male internal and external reproductive organs. The way of the excretion of the seminal fluid.
24. Functional morphology of the internal and external female reproductive organs. Structure and function of the ovary. Uterus: function, structure.

## CONTENTS

CARDIOVASCULAR SYSTEM.....	4
Laboratory class № 1. General information about the structure of cardiovascular system. Anatomy of the heart. Aorta.....	4
Laboratory class № 2. Arteries of the head and neck.....	9
Laboratory class № 3. Veins. Lymphatic vessels, trunks and ducts .....	14
LYMPHOID ORGANS, ENDOCRINE GLANDS.....	19
Laboratory class № 4. Morphofunctional characteristics of secondary lymphoid organs. Lymph nodes of the head and neck. Endocrine glands. Final lesson on «Angiology».....	19
NERVOUS SYSTEM.....	22
Laboratory class № 5. Nervous system. Structure, general data. Central nervous system. Spinal cord.....	22
Laboratory class № 6. Brain. Pathways of brain and spinal cord .....	27
Laboratory class № 7. Meninges. The peripheral nervous system.....	32
Laboratory class № 8. Cranial nerves. Anatomy of the oculomotor, trochlear, trigeminal and abducent nerves .....	37
Laboratory class № 9. Cranial nerves. Anatomy of the facial, glossopharyngeal, vagus, accessory and hypoglossal nerves .....	42
Laboratory class № 10. Autonomic nervous system.....	47
SENSE ORGANS.....	51
Laboratory class № 11. Sense organs. Structure and functions of the organ of hearing and equilibrium.....	51
Laboratory class № 12. Structural and functional characteristics of the eye. Final class on «Nervous system», «Sense organs» .....	54
CONTROL QUESTIONS FOR THE SECTIONS «NERVOUS SYSTEM», «SENSE ORGANS».....	58
DIGESTIVE SYSTEM.....	60
Laboratory class № 12. Digestive system: general characteristics. Structure of oral organs and great salivary glands .....	60
Laboratory class № 13. Pharynx, esophagus, stomach, small and large intestine .....	65
Laboratory class № 14. Liver and pancreas. Peritoneum and its derivatives.....	70
RESPIRATORY SYSTEM.....	75
Laboratory class № 15. Functional anatomy of respiratory systems. Pleura. Mediastinum .....	75
URINARY SYSTEM AND MALE REPRODUCTIVE SYSTEM .....	80
Laboratory class № 16. Anatomy of the urinary tract. Structure of external and internal male reproductive organs .....	80
FEMALE REPRODUCTIVE ORGANS.....	86
Laboratory class № 17. Structure of female reproductive organs .....	86
Laboratory class № 18. Final class for the «Inner organs systems».....	90

Учебное издание

**Кабак** Сергей Львович  
**Журавлёва** Наталья Викторовна  
**Заточная** Валентина Владимировна

**СЕРДЕЧНО-СОСУДИСТАЯ СИСТЕМА. НЕРВНАЯ СИСТЕМА.  
СИСТЕМЫ ВНУТРЕННИХ ОРГАНОВ**

**CARDIOVASCULAR SYSTEM. NERVOUS SYSTEM.  
INTERNAL ORGAN SYSTEMS**

Практикум

На английском языке

*4-е издание*

Ответственный за выпуск С. Л. Кабак  
Переводчики Н. В. Журавлёва, В. В. Заточная  
Компьютерная верстка О. В. Лавникович

Подписано в печать 11.12.25. Формат 60×84/8. Бумага «Снегурочка».  
Ризография. Гарнитура «Times».  
Усл. печ. л. 10,69. Уч.-изд. л. 4,99. Тираж 74 экз. Заказ 10.

Издатель и полиграфическое исполнение: учреждение образования  
«Белорусский государственный медицинский университет».  
Свидетельство о государственной регистрации издателя, изготовителя,  
распространителя печатных изданий № 1/187 от 24.11.2023.  
Ул. Ленинградская, 6, 220006, Минск.