

**L. A. KAZEKO, I. S. KARMALKOVA,
E. L. KOLB**

**OBTURATION TECHNIQUES
OF ROOT CANAL SYSTEM**

Minsk BSMU 2015

МИНИСТЕРСТВО ЗДРАВООХРАНЕНИЯ РЕСПУБЛИКИ БЕЛАРУСЬ
БЕЛОРУССКИЙ ГОСУДАРСТВЕННЫЙ МЕДИЦИНСКИЙ УНИВЕРСИТЕТ
1-я КАФЕДРА ТЕРАПЕВТИЧЕСКОЙ СТОМАТОЛОГИИ

Л. А. КАЗЕКО, И. С. КАРМАЛЬКОВА, Е. Л. КОЛБ

МЕТОДИКИ ОБТУРАЦИИ КОРНЕВЫХ КАНАЛОВ

OBTURATION TECHNIQUES OF ROOT CANAL SYSTEM

Учебно-методическое пособие



Минск БГМУ 2015

УДК 616.314.163-085(811.111)-054.6(075.8)
ББК 56.61(81.2 Англ-923)
К14

Рекомендовано Научно-методическим советом университета в качестве
учебно-методического пособия 20.05.2015 г., протокол № 9

Рецензенты: канд. мед. наук, доц. Н. М. Полонейчик; канд. мед. наук, доц.
А. Г. Третьякович; ст. преп. Т. А. Проволоцкая

Казеко, Л. А.

К14 Методики obturation корневых каналов = Obturation technics of root canal system :
учеб.-метод. пособие / Л. А. Казеко, И. С. Кармалькова, Е. Л. Колб. – Минск :
БГМУ, 2015. – 44 с.

ISBN 978-985-567-280-8.

Изложены различные методы obturation корневых каналов зубов, также кратко представлена ин-
формация о стоматологических материалах для пломбировки корневых каналов.

Предназначено для студентов 3-го курса 6-го семестра медицинского факультета иностранных
учащихся, обучающихся на английском языке.

УДК 616.314.163-085(811.111)-054.6(075.8)
ББК 56.61(81.2 Англ-923)

Учебное издание

Казеко Людмила Анатольевна
Кармалькова Ирина Сергеевна
Колб Екатерина Леонидовна

МЕТОДИКИ ОБТУРАЦИИ КОРНЕВЫХ КАНАЛОВ
OBTURATION TECHNIQUES OF ROOT CANAL SYSTEM

Учебно-методическое пособие
На английском языке

Ответственная за выпуск Л. А. Казеко
Переводчики: И. С. Кармалькова, Е. Л. Колб
Компьютерная верстка Н. М. Федорцовой

Подписано в печать 21.05.15. Формат 60×84/16. Бумага писчая «Снегурочка».
Ризография. Гарнитура «Times».
Усл. печ. л. 2,56. Уч.-изд. л. 2,54. Тираж 40 экз. Заказ 442.

Издатель и полиграфическое исполнение: учреждение образования
«Белорусский государственный медицинский университет».
Свидетельство о государственной регистрации издателя, изготовителя,
распространителя печатных изданий № 1/187 от 18.02.2014.
Ул. Ленинградская, 6, 220006, Минск.

ISBN 978-985-567-280-8

© Казеко Л. А., Кармалькова И. С., Колб Е. Л., 2015
© УО «Белорусский государственный
медицинский университет», 2015

OBTURATION TECHNIQUES OF THE ROOT CANAL SYSTEM

Success in endodontic treatment was originally based on the triad of debridement, thorough disinfection, and obturation with all aspects equally important.

After the root canal system has been appropriately prepared, it must be obturated with a material capable of completely preventing communication between the oral cavity and the periapical tissue wound.

Nearly 60 % of the failures in endodontic treatment are apparently caused by incomplete obliteration of the radicular space.

Purpose of obturation:

1. To achieve total obliteration of the root canal spaces so as to prevent ingress of bacteria's and body fluids into root canal space as well as egress of bacteria's which are left in canal.

2. To attain fluid tight seal so as to prevent bacterial microleakage.

3. To replace the empty root canal space with an inert filling material so as to prevent recurrent infection.

4. To seal the root canal space as well as to have coronal seal for long term success of root canal therapy.

Root canal filling materials may be divided into three types:

– cones (cores);

– sealers;

– combination of the two.

Cones are prefabricated root canal filling materials of a given size and shape (taper).

Sealers are pastes and cements that are mixed and hardened by a chemical setting reaction after a given amount of time. Setting time varies between the various preparations, from minutes up to days. Combination of cones and sealers is currently recommended.

CORE MATERIALS

Properties of an Ideal Obturation Material:

1. Easily manipulated and provides ample working time.

2. Dimensionally stable with no shrinkage once inserted.

3. Seals the canal laterally and apically, conforming to its complex internal anatomy.

4. Nonirritating to the periapical tissues.

5. Impervious to moisture, and nonporous.

6. Unaffected by tissue fluids — no corrosion or oxidization.

7. It should be bacteriostatic or at least not encourage bacterial growth.

8. It should not shrink after being inserted.

9. Radiopaque and easily discernible on radiographs.

10. Does not discolor tooth structure.

11. Sterile or easily and quickly sterilized immediately before insertion.

12. Easily removed from the canal if necessary.

GUTTA-PERCHA

Gutta-percha is the most commonly used root canal filling material.

Modern gutta-percha cones that are used for root canal fillings contain only about 20 % gutta-percha. The major component is zinc oxide (60 % to 75 %). The remaining 5 % to 10 % consists of various resins, waxes, and metal sulfates.

Chemically pure gutta-percha (or balata) exists in two distinctly different crystalline forms (alpha and beta) that can be converted into each other. The alpha form comes directly from the tree. Most commercial gutta-percha, however, is the beta crystalline form.

There are few differences in physical properties between the two forms, merely a difference in the crystalline lattice depending on the annealing and/or drawing process used when manufacturing the final product.

Traditionally, the beta form of gutta-percha was used to manufacture endodontic gutta-percha points to achieve an improved stability and hardness and reduce stickiness. However, through special processing and/or modifications to the formulation of the gutta-percha compound, more alpha-like forms of gutta-percha have been introduced, resulting in changes in the melting point, viscosity, and tackiness of the gutta-percha point. Gutta-percha with low viscosity will flow with less pressure or stress, while an increase in tackiness will help create a more homogeneous filling. Various manufacturers have introduced products to take advantage of these properties (e. g., Thermafil, Densfil, Microseal).

The advantages of gutta-percha as a filling material are these:

1. It is compactible and adapts excellently to the irregularities and contour of the canal by the lateral and vertical condensation method.
2. It can be softened and made plastic by heat or by organic solvents (eucalyptol, chloroform, xylol, turpentine).
3. It is inert.
4. It has dimensional stability; when unaltered by organic solvents, it will not shrink.
5. It is tissue tolerant (nonallergenic).
6. It will not discolor the tooth structure.
7. It is radiopaque.
8. It can be easily removed from the canal when necessary.

Disadvantages:

1. It lacks rigidity. The smallest, standardized gutta-percha cones are relatively more difficult to use unless canals are enlarged above size 25. Because of their greater taper, nonstandardized cones of smaller sizes are more rigid than small standardized cones and are often used to better advantage as primary cones in small canals.

2. It lacks adhesive quality. Gutta-percha does not adhere to the canal walls; consequently, sealer is required. The necessary use of a cementing agent introduces the risk of using tissue-irritating sealers.

3. It can be easily displaced by pressure. Gutta-percha permits vertical distortion by stretching. This characteristic may tend to induce overextension during the condensing process. Unless it meets an obstruction or is packed against a definite apical constriction, it can be easily pushed beyond the apical foramen.

Gutta-percha points (or cones) are supplied in two shapes. The traditional form is cone shaped to conform to the perceived shape of the root canal (fig. 1).




Fig 1. Cone shaped gutta-percha points

Today these cones are preferred by dentists who use the warm gutta-percha vertical compaction technique of filling. Also, because the original spreaders used in the lateral compaction technique were shaped to match these cone shapes and sizes, traditional cones have long been used as the accessory cones in the lateral compaction technique.

The other shape of gutta-percha points is standardized to the same size and shape as the standardized (ISO) endodontic instruments (fig. 2).




Fig. 2. Standard gutta-percha cone

These points are available in the standardized .02 taper as well as in increased taper sizes (.04, .06, etc.) to correspond to the newer tapered instrument sizes.

Color coding the numbered points to match ISO instrument color has become routine and it is now rare to find the standardized points without these convenient markings.

Gutta-percha cones are available in non- standardized form (fig. 3). The non-standardized cones have relatively small diameter tips compared to their larger bodies. Their nomenclature refers to these two dimensions — a «fine-medium» cone has a fine tip and a medium body.



Fig. 3. Nonstandardized (top) and standardized (bottom) cones

The accessory gutta-percha points have a pointed shape. They are available in assorted sizes and are used to supplement the standardized master point to fill the coronal flared part of the root canal.

Table 1

Dimensions of gutta-percha cones

Type of cone	Size
Standardized cones	Corresponds in diameter and taper (2 %) to root canal shaping instruments according to ISO 6877. The sizes of the gutta-percha cones range from ISO 10 to ISO 140
Accessory cones	Larger taper, descriptive size, may be used for lateral compaction
Greater taper cones	Cones with a 4 % or 6 % (and up to 12 %) taper or cones with varying taper used together with special engine-driven root canal shaping instruments
Compaction cones	Taper corresponds to the taper of finger-spreaders

Because gutta-percha cannot be heat sterilized, other decontamination methods must be used.

The most practical method is to disinfect gutta-percha in NaOCl before use. This can be done for 1 minute if the cone is submerged in a 5 % solution of NaOCl. However, after this disinfection and before its use for obturation, it is imperative that the gutta-percha be rinsed in ethyl alcohol to remove crystallized NaOCl; such crystals may impair the obturation seal.

Recently, gutta-percha cones that are «free of living germs» (declaration of the manufacturer) have been marketed.

Gutta-percha cones should be stored in cool and dark conditions in order to prevent hardening and brittleness due to further crystallization and/or oxidation.

Gutta-percha cannot be used as the sole filling material; it lacks the adherent properties necessary to seal the root canal space. Therefore, a sealer (cement) is always needed for the final seal.

Coated gutta-percha. Gutta-percha is now available that may achieve bonding between the solid core and a resin sealer. The uniform layer is placed on the gutta-percha cone by the manufacturer. When the material comes in contact with the resin sealer, a resin bond is formed.

Medicated gutta-percha. The melding of an antibacterial substance to a gutta-percha cone or other solid-core obturation materials may have utility in preventing root canal therapy failures due to coronal or apical microleakage. Medicated gutta-percha cones are not used on a regular basis.

Calcium hydroxide containing gutta-percha: calcium hydroxide containing gutta-percha is made by combining 58 % of calcium hydroxide in matrix of 42 % gutta-percha. They are available in ISO size of 15-140. Action of Ca(OH)_2 is activated by moisture in canal.

Advantages:

1. Easy to insert and remove.
2. Minimal or no residue left.
3. Firm for easy insertion.

Disadvantages:

1. Short-lived action.
2. Radiolucent.
3. Lack of sustained release.

Iodoform containing gutta-percha. Iodoform containing gutta-percha remains inert till it comes in contact with the tissue fluids. On coming in contact with tissue fluids, free iodine is released which is antibacterial in nature.

Chlorhexidine diacetate containing gutta-percha. In this gutta-percha matrix embedded in 5 % chlorhexidine diacetate. This material is used as an intracanal medicament.

Active gutta-percha. Active GP (Brasseler, USA) consists of gutta-percha cones impregnated on the external surface with glass ionomer. Single cones are used with a glass ionomer sealer. Available in .04 and .06 tapered cones, the sizes are laser verified to ensure a more precise fit. The single cone technique is designed to provide a bond between the dentinal canal wall and the master cone.

THE RESIN-BASED OBTURATION SYSTEMS

The resin-based obturation systems Epiphany (Pentron Clinical Technologies), RealSeal (Sybronendo), and Resinate (Obtura Spartan, earth City, Mo) have been introduced as alternatives to gutta-percha (fig. 4).

Resilon is a high performance industrial polyurethane that has been adapted for dental use. The resin sealer bonds to a resilon core, and attaches to the etched root surface. Whether a monoblock is achievable, remains controversial.

The system resembles gutta-percha and can be placed by lateral compaction, warm lateral or vertical compaction, or thermoplastic injection. It consists of

a resin core material (resilon) composed of polyester, difunctional methacrylate resin, bioactive glass, radiopaque fillers, and a resin sealer. Resilon is nontoxic, nonmutagenic, and biocompatible.

The core material is available in nonstandard and standard cones and pellets for use in thermoplastic techniques.

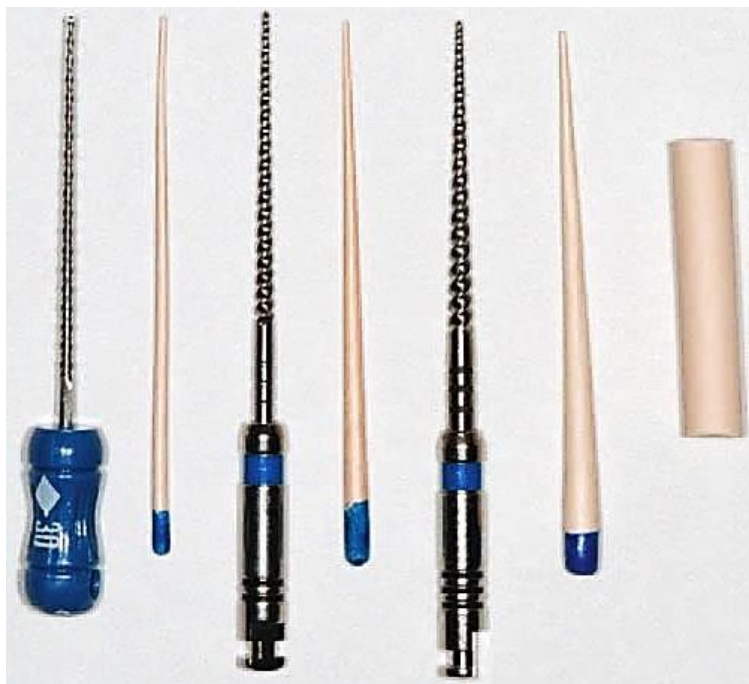

Fig. 4. Resilon #.02, #.04, and #.06 tapered points and a thermoplastic plug for use in the Obtura II system (Obtura Spartan, earth City, Mo)

SILVER CONES

Silver points are the most widely used solid-core metallic filling material, although points of gold, iridium-platinum, and tantalum are also available.

Silver points cannot conform with the shape of root canal because they lack plasticity; the use of silver points is not indicated in filling of large, triangular canals as in maxillary anterior teeth.

Silver cones do not possess adhering qualities, so a sealer is required to adequately seal the canal.

The rigidity provided by the silver cones makes them easy to place and permits more predictable length control; however, their inability to fill the irregularly shaped root canal system permits leakage.

When silver points contact tissue fluids or saliva, they corrode. It has been seen that silver corrosion products are toxic in nature and thus may cause tissue injury.

The use of silver cones today is considered to be below the standard of care in contemporary endodontic practice.

SEALERS

Root canal sealers are necessary to seal the space between the dentinal wall and the obturating core interface. Sealers also fill voids and irregularities in the root canal, lateral and accessory canals, and spaces between gutta-percha points used in lateral condensation. Sealers also serve as lubricants during the obturation process.

Functions of root canal sealers. Root canal sealers are used in conjunction with filling materials for the following purposes:

1. Antimicrobial agent: All the commonly used sealers contain some antibacterial agent; so a germicidal quality is excreted immediately after its placement.

2. Sealers are needed to fill in the discrepancies between the filling material and the dentin walls.

3. Binding agent: Sealers act as binding agent between the filling material and the dentin walls.

4. As lubricant: With the use of semisolid materials, the most important function for the sealer to perform is its action of lubrication.

5. Radiopacity: All sealers display some degree of radiopacity; thus they can be detected on a radiograph. This property can disclose the presence of auxiliary canals, resorptive areas, root fractures, and the shape of apical foramen.

6. Certain techniques dictate the use of a particular sealer. The choropercha technique, for instance, uses materials as sealer as well as a solvent for the master cone. It allows the shape of normal gutta-percha cone to be altered according to the shape of the prepared canal.

Acceptable methods of placing the sealer into the canal include the following:

1. Placing the sealer on the master cone and pumping the cone up and down in the canal.

2. Placing the sealer on a file and spinning it counterclockwise.

3. Placing the sealer with a lentulospiral.

4. Using a syringe.

Properties of an ideal sealer:

1. Exhibits tackiness when mixed to provide good adhesion between it and the canal wall when set.

2. Establishes a hermetic seal.

3. Radiopaque, so that it can be seen on a radiograph.

4. Very fine powder, so that it can mix easily with liquid.

5. No shrinkage on setting.

6. No staining of tooth structure.

7. Bacteriostatic, or at least does not encourage bacterial growth.

8. Exhibits a slow set.

9. Insoluble in tissue fluids.

10. Tissue tolerant; that is, nonirritating to periradicular tissue.

11. Soluble in a common solvent if it is necessary to remove the root canal filling.

12. The sealer also must have cohesive strength to hold the obturation material together.

13. It should not provoke an immune response in periradicular tissue.
14. It should be neither mutagenic nor carcinogenic.

There are numerous classifications of root canal sealers:

Sealers may be broadly classified according to their composition:

1. Eugenol.
2. Non-eugenol.
3. Medicated.

I. Eugenol group may be divided into subgroups, namely:

Silver containing cements:

- a) Kerr sealer (Rickert, 1931);
- b) Procosol radiopaque silver cement (Grossman, 1936).

Silver free cements:

- a) Procosol nonstaining cement (Grossman, 1958);
- b) Grossman's sealer (Grossman, 1974);
- c) Tubliseal (Kerr, 1961);
- d) Wach's paste (Wach).

II. Non-eugenol. These sealers do not contain eugenol and consist of a wide variety of chemicals. (Examples: Chloropercha, glass ionomer sealers, polycarboxylate sealers).

III. Medicated. These include the group of root canal sealers which have therapeutic properties.

Classification of sealer according to Grossman:

1. Zinc oxide resin cements.
2. Calcium hydroxide cements.
3. Paraformaldehyde cements.
4. Pastes.

Classification of sealer according to Cohen (ADA and ANSI). According to the intended use:

Type I: Material's intended to be used with core material.

Class I: Includes materials in the form of powder and liquid that set through a non-polymerizing process.

Class II: Includes materials in the form of two pastes that set through a non-polymerizing process.

Class III: Includes polymers and resin systems that set through polymerization.

Type II: Intended for use with or without core material or sealer.

Class I: Powder and liquid- non-polymerizing.

Class II: Paste and paste- non-polymerizing.

Class III: Metal amalgams.

Class IV: Polymer and resin systems polymerization.

Classification of sealer according to Clark:

1. Absorbable.

2. Non-absorbable.

Classification of sealer according to Ingle:

1. Cements.

2. Pastes.

3. Plastic.

4. Experimental sealers.

The most popular sealers are zinc oxide — eugenol formulations, calcium hydroxide sealers, glass ionomers, and resins.

ZINC OXIDE EUGENOL CEMENTS

Many endodontic sealers are simply zinc oxide eugenol (ZnOE) cements that have been modified for endodontic use.

Zinc oxide eugenol sealers will absorb if extruded into the periradicular tissues. They exhibit a slow setting time, shrinkage on setting, solubility, and they can stain tooth structure.

ZnOE sealers have demonstrated antimicrobial properties on a variety of microorganisms, including *Enterococcus faecalis* suspensions and anaerobic bacteria even 7 days after mixing. Apparently, eugenol is the main antimicrobial agent.

Formaldehyde-releasing ZnOE root canal sealers should not be used anymore because of their inherent toxic potential.

ZnOE-based sealers are easy to handle. They can be mixed to a smooth paste, which allows enough time for obturation and control radiography before setting. Removal can be performed with organic solvents. The radiopacity of different ZnOE sealers can be regarded as sufficient.

Advantages of ZnOE-based sealers:

1. Easy to manipulate.
2. Shows only slight dimensional change.
3. Radiopaque.
4. Germicidal properties.
5. Minimal staining.
6. Ample working time.

Disadvantages of ZnOE-based sealers:

1. Irritant to periapex.
2. Not easily absorbed from the apical tissues.

Examples: Endofill (Dentsply-Mallefer) and Endométhasone (Septodont).

CALCIBIOTIC ROOT CANAL SEALER (CRCS)

CRCS is a zinc oxide, eugenol-eucalyptol sealer to which calcium hydroxide has been added for its osteogenic effect. CRCS takes three days to set fully in either dry or humid environment. Because of little water resorption property, it is quite stable. Though sealing is improved, but since calcium hydroxide is not released from the cement, its main role (osteogenic effect) becomes questionable.

Advantages of CRCS:

1. Biocompatible.
2. Takes three days to set.
3. Stable in nature.
4. Shows little water resorption.
5. Easily disintegrates in tissues.

Disadvantages of CRCS:

1. Extruded sealer is resistant to resorption by tissue fluids.
2. Shows minimal antibacterial activity.

CHLOROPERCHA

Chloropercha was another type of sealer used for many years.

It is made by mixing white gutta-percha (i. e., alba) with chloroform. This allowed gutta-percha root filling to fit better in the canal. However, chloropercha has no adhesive properties and is no longer used as an obturation material in root canal therapy. The use of chloroform has been sharply curtailed for many years because of its demonstrated toxicity.

Modified chloropercha methods. There are two modifications:

1. Johnston–Callahan.
2. Nygaard–Ostby.

Johnston–Callahan method. In this method, the canal is repeatedly flooded with 95 percent alcohol and then dried. After this, it is flooded with Callahan resin chloroform solution for 2–3 minutes. A gutta-percha cone is inserted and compressed laterally and apically with a plugger until the gutta-percha is dissolved completely in the chloroform solution in the root canal. Additional points are added and dissolved in the same way.

Nygaard–Ostby. It consists of Canada balsam; colophonium and zinc oxide powder mixed with chloroform. In this technique, the canal walls are coated with Chloropercha, the primary cone dipped in sealer is inserted apically pushing partially the dissolved tip of the cone to its apical seal. Additional cones dipped in sealer are packed into the canal to obtain a good apical seal.

CALCIUM HYDROXIDE SEALERS

These sealers are promoted as having therapeutic effects because of their $\text{Ca}(\text{OH})_2$ content. It was thought that these sealers would exhibit antimicrobial activity and have osteogenic — cementogenic potential. The antimicrobial effect of $\text{Ca}(\text{OH})_2$ is thought to occur because of its ability to release hydroxyl ions and by having a high pH.

These materials have been shown to have similar sealing ability to zinc oxide and eugenol preparations; however, long-term exposure to tissue fluid may possibly lead to dissolution of the material as calcium hydroxide is leached out.

Handling properties of calcium hydroxide sealers are adequate; the radiopacity is regarded as sufficient. The material can be removed from the root canal with common rotary instruments.

Advantages of calcium hydroxide sealers:

1. Induce mineralization.
2. Induce apical closure via cementogenesis.
3. Inhibit root resorption subsequent to trauma.
4. Inhibit osteoclast activity via an alkaline pH.
5. Seal or prevent leakage as well as or better than ZOE sealers.
6. Less toxic than ZOE sealers.

Disadvantages of calcium hydroxide sealers:

1. Calcium hydroxide content may dissolve, leaving obturation voids.
2. There is no objective proof that a calcium hydroxide sealer provides any added advantage of root canal obturation or has any of its desirable biological effects.
3. Although calcium hydroxide has dentin regenerating properties, the formation of secondary dentin along the canal wall is prevented by the absence of vital pulp tissue.

Examples: SealApex (Sybron Endo/Kerr; Orange, Calif.), LIFE (Sybron Endo/Kerr; Orange, Calif.), Vitapex (NEO Dental, Japan), Apexit Plus (Ivoclar, Vivadent, Fürstentum, Schaan, Liechtenstein) and Sealapex (Sybron-Endo, Glendora, CA, USA).

HYDRAULIC CALCIUM SILICATE CEMENTS

Hydraulic calcium silicate cements (HCSCs), well known as MTA (mineral trioxide aggregate) sealers.

Hydraulic calcium silicate cements were developed more than 20 years ago. Their composition is largely based on Portland cement components (di- and tri-calcium silicate, Al- and Fe-silicate). Some hydraulic calcium silicate-based materials containing additional components (setting modulators, radiopacifying agents, drugs, etc.).

They have important properties such as the ability to set and to seal in moist and blood-contaminated environments, biocompatibility, adequate mechanical properties, etc.

Their principal limitations are long setting time, low radiopacity and difficult handling.

Hydraulic calcium silicate cements regulate the differentiation of osteoblast, fibroblasts, cementoblasts, odontoblasts, pulp cells and many stem cells. They can induce the chemical formation of a calcium phosphate/apatite coating when immersed in biological fluids. These properties have led to a growing series of innovative clinical applications such as root-end filling, pulp capping and scaffolds for pulp regeneration, root canal sealer, etc.

The material is rather difficult to place and the working time may be short. Special MTA endodontic carriers have been developed to facilitate placement and condensation.

Examples: ProRoot Endo Sealer (Dentsply, Tulsa, OK, USA), Endo-CPM-Sealer (EGEO SRL, Buenos Aires, Buenos Aires, Argentina) and MTA Fillapex (Angelus, Londrina, PR, Brazil).

GLASS IONOMER SEALERS

Glass ionomer cements were first introduced into dentistry in 1975 and since then they have been used in a wide range of clinical applications. The glass ionomers have been advocated for use in obturation because of their dentin-bonding properties.

Conventional glass ionomers are dispensed in a powder form supplied with its own liquid. The powder is formed of fluoroaluminosilicate glass, while the liquid is an aqueous solution of a polyalkenoic acid, such as polyacrylic acid, although in later formulations, the acid may be added to the powder in a dried polymer form.

Advantage:

1. Optimal physical qualities.
2. Shows bonding to dentin.
3. Shows a minimum number of voids.
4. Low surface tension.
5. Optimal flow property.

Disadvantage. It cannot be removed from the root canal in the event of retreatment as there is no known solvent for glass ionomer.

Examples: Ketac-Endo (3M/Espe; Minneapolis, Minn.).

RESIN

Resin sealers have a long history of use, provide adhesion, and do not contain eugenol. The use of dentin bonding agents in root canal filling was introduced to enhance the endodontic resin.

The use of dentin bonding agents in root canal filling was introduced to enhance the endodontic resin-based sealers adhesion to the root dentin. The newer endodontic methacrylate resin-based sealers (RealSeal, Epiphany) use a separate self-etching primer before application of flowable composites to the primed dentin; or else consist of a single product of the self-adhesive methacrylate sealer, incorporating a self-etching primer and a moderately filled flowable composite (MetaSEAL; RealSeal SE, Epiphany SE).

Epoxy-based sealers have been used for more than 40 years worldwide and their handling properties are usually considered to be good. Radiopacity is sufficient (6.6 mm Al). However, the materials set to a hard mass that, in a clinically

relevant time, is virtually insoluble even for organic solvents. Therefore, this material must be used together with gutta-percha cones.

Examples: Diaket (3M/Espe; Minneapolis, Minn.), AH-26 (Dentsply/Maillefer, Tulsa, Okla).

EPIPHANY

Epiphany is a dual curable dental resin composite sealer composed of BisGMA, ethoxylated BisGMA, UdMA, and hydrophilic difunctional methacrylates with fillers of Ca(OH)_2 , barium sulfate, barium glass, and silica (fig. 5). The total filler content of the sealer is approximately 70 % by weight.



Fig. 5. Epiphany system (Pentron Clinical Technologies, Wallingford, CT) with the primer, thinning resin, sealant, and standard resilon points (Courtesy SybronEndo, Orange, CA)

Epiphany was designed for use with resilon instead of gutta-percha, although it can also be used with either core material. Unlike other resin sealers, this system's sealer requires a self-etch primer before placement of the resin sealer.

Uniform application of a primer or an adhesive in root canals and removal of solvent are considered to be difficult, especially in the apical third. Massive air blowing into the canal should generally be avoided; the use of paper point is not very effective. Special delivery systems (e. g. microbrushes) are recommended for application of primers and sealers.

Step-by-step procedure:

1. The canal is prepared with a traditional preparation method.
2. Smear layer removal: Sodium hypochlorite should not be the last irrigant used within the root canal system due to compatibility issues with resins. Use 17 percent EDTA or 2 percent Chlorhexidine as a final rinse.
3. Placement of the primer: After the canal is dried with paper points, the primer is applied up to the apex. Dry paper points are then used to wick out

the excess primer from the canal. The primer is very important because it creates a collagen matrix that increases the surface area for bonding. The low viscosity primer also draws the sealer into the dentinal tubules.

4. Placement of the sealer: The sealer can be placed into the root canal system using a lentulospiral at low rpm or by generously coating the master cone.

5. Obturation: The root canal system is then obturated by the preferred method (lateral or warm vertical, etc.)

Advantages of Epiphany:

1. Biocompatible.
2. Good coronal seal, so less microleakage.
3. Non-toxic.
4. Non-mutagenic.
5. Forms monoblock.
6. Increases resistance to fracture in endodontically treated teeth.

Disadvantage: Does not retain its softness after heating.

SILICONE SEALERS

The first of those materials was based on C-silicones (condensation cross-linking silicones); newer materials are based on A-silicones (addition cross-linking). Silicone sealers are supplied in capsules and after mixing can easily be injected into the canal followed by the insertion of gutta-percha.

Advantages:

1. Easy to penetrate.
2. Adjustable working time.
3. Low working viscosity.
4. Rubbery consistency.
5. Non-resorbable.

Disadvantages:

1. Cannot be used in presence of hydrogen peroxide.
2. The canal must be absolutely dry.
3. Shrinks upon setting but has affinity for flowing into open tubuli.
4. Difficult to remove from the canals.

Examples: RoekoSeal (Coltène/Whaledent, Germany).

GuttaFlow (Coltène/Whaledent) is a cold flowable matrix that is triturated. It consists of gutta-percha added to RoekoSeal (fig. 6). The material is provided in capsules for trituration. The technique involves injection of the material into the canal, followed by placement of a single master cone. The material provides a working time of 15 minutes and it cures in 25 to 30 minutes.

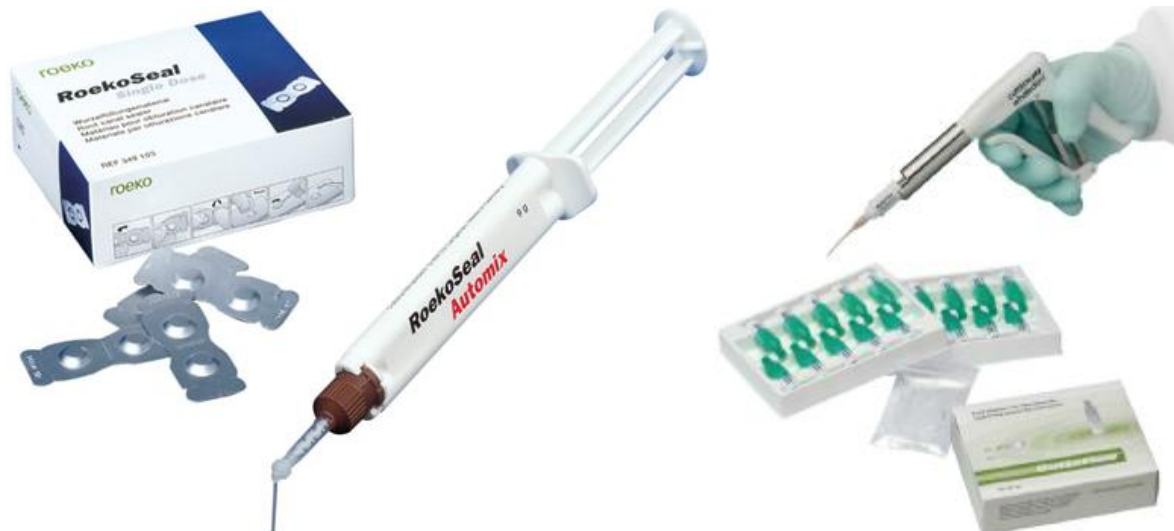

Fig. 6. RoekoSeal and GuttaFlow (Coltène/Whaledent, Germany)

BIOCERAMIC

Bioceramic sealer is composed of zirconium oxide, calcium silicates, calcium phosphate monobasic, calcium hydroxide, and various filling and thickening agents. The material is available in a premixed syringe with calibrated intracanal tips. As a hydrophilic sealer it utilizes moisture within the canal to complete the setting reaction and it does not shrink on setting. It is biocompatible and exhibits antimicrobial properties during the setting reaction. The manufacturer advocates expressing the sealer into the coronal one third to one half of the canal and then seating the master gutta-percha cone.

Table 2

Properties of different sealers

Zinc oxide-eugenol-based sealers	<ol style="list-style-type: none"> 1. Reasonable seal. 2. Dissolve in fluids. 3. Long-lasting cytotoxicity. 4. Sensibilization.
Resin-based sealers	<ol style="list-style-type: none"> 1. Good seal. 2. Initial cytotoxicity. 3. Once set, biocompatible. 4. Allergenic.
Gutta-percha-based sealers	<ol style="list-style-type: none"> 1. Moderate seal. 2. Initial cytotoxicity. 3. Shrinkage. 4. Plasticize gutta-percha.
Dentin-adhesive sealers	<ol style="list-style-type: none"> 1. Good seal. 2. Set very quickly. 3. Good biocompatibility. 4. Difficult to remove.
Calcium hydroxide-containing sealers	<ol style="list-style-type: none"> 1. Release calcium hydroxide, which may result in disintegration. 2. Once set and integrity is maintained, no calcium hydroxide leaches out and no effect can be expected. 3. Initial antibacterial effect.

	4. Risk of dissolution over time.
Formaldehyde-containing sealers	1. Zinc oxide-eugenol based. 2. Severe long-lasting cytotoxicity. 3. Sensibilization. 4. Not used now.

ARMAMENTARIUM FOR OBTURATION

Main armamentarium for obturation consists of:

1. Primary and accessory gutta-percha points.
2. Spreaders and pluggers for compaction of gutta-percha (fig. 7).
3. Endodontic locking tweezers (fig. 8).
4. Absorbent paper points for drying the prepared root canal before applying sealer (fig. 9).
5. Lentulospirals for placing sealer (fig. 10).
6. Scissors for cutting gutta-percha.
7. Endoblock for measuring gutta-percha points (fig. 11).
8. Endo organizer for arranging gutta-percha and accessory points of various sizes.



Fig. 7. Standardized finger and hand spreaders, sized and color coded to match ISO instrument sizes



Fig. 8. Endodontic locking tweezers




Fig. 9. Lentulospirals for placing sealer




Fig. 10. Absorbent paper points for drying the prepared root canal before applying sealer




Fig. 11. Endoblock for measuring gutta-percha points

METHODS OF OBTURATION

Today, most root canals are being filled with gutta-percha and sealers (fig. 12).

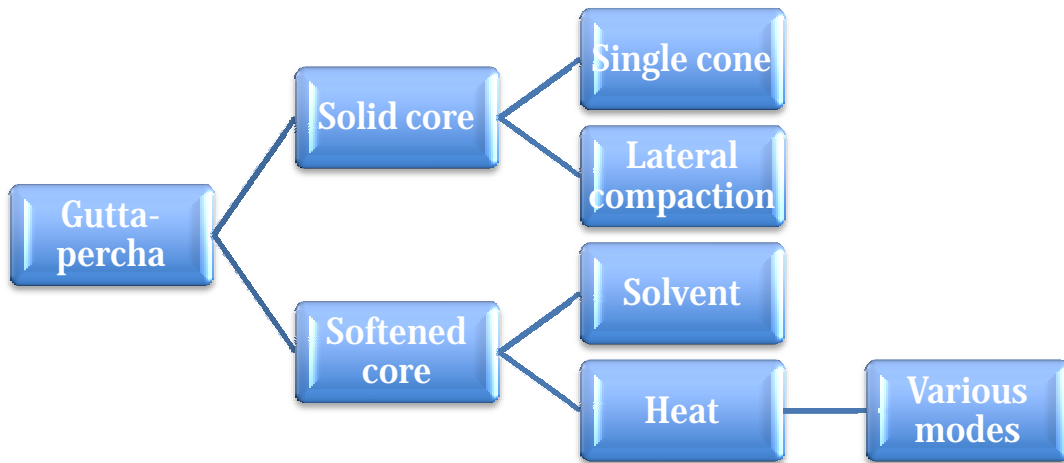


Fig. 12. Outline of techniques to fill root canals with gutta-percha

These are the two basic procedures: lateral compaction of cold gutta-percha or vertical compaction of warmed gutta-percha. Other methods are variations of warmed gutta-percha.

The methods are listed as follows.

According to Grossman:

- Lateral condensation method.
- Vertical condensation method.
- Sectional method.
- Compaction method (mcSpadden).
- Metal-core obturation.
- Silver-cone method.
- Stainless steel file method.
- Chemically plasticized gutta-percha.
- Injection techniques of obturating canals.
- Hydron.
- Thermoplasticized gutta-percha method.
- Obtura II, Ultrafil.

According to Stock:

- Sectional.
- Single cone.
- Multiple cone: cold/warm lateral condensation.
- Warm vertical condensation.
- Custom made.
- Gutta-percha with solvents.
- Thermal compaction.
- Injection molded thermo plasticized.
- Pastes alone.

According to Ingle:

- Apical third fillings.
- Light speed simplifill.

- Dentin-chip.
- Calcium-hydroxide.
- Injection or «spiral» filling.
- Cements.
- Pastes.
- Plastics.
- Calcium phosphate.

OBTURATION WITH SILVER CONE

Silver cones are not usually a preferred method of canal obturation mainly because of their corrosion. Their use is restricted to teeth with fine, tortuous, curved canals, which makes the use of gutta-percha difficult.

Indications:

1. In sound and straight canals.
2. In mature teeth with small calcified canals.

Contraindications:

1. Teeth with open apex.
2. Large ovoid shaped canals.

Advantages:

1. Easy handling and placement.
2. Negotiates extremely curved canals.
3. Radiopaque in nature.
4. Mild antibacterial property.

Disadvantages:

1. Prone to corrosion resulting in loss of apical seal.
2. Difficult to retrieve if it is snugly fitting.
3. Non-adaptable, so does not seal accessory canals.

Step-by-step procedure:

1. Select a silver cone conforming the final shape and size of the prepared canal. Check its fitting radiographically.

If found satisfactory, remove it from the canal and sterilize it over an alcohol flame.

2. Dry the canal and coat the canal walls with sealer.

3. Insert the cone into the canal with a sterile cotton plier or Stieglitz forceps (fig. 13).

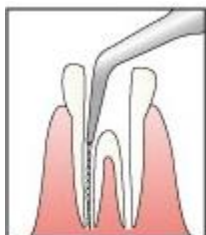


Fig. 13. Stieglitz forceps, used to insert the cone into the canal

4. Take a radiograph to see the fitting of the cone.
5. If satisfactory, fill the remaining canal with accessory gutta-percha cones.
6. Remove excess of sealer with cotton pellet and place restoration in the pulp chamber.

SINGLE GUTTA-PERCHA POINT AND SEALER

With the tendency to preparation techniques of greater taper, gutta-percha points of matching taper may be used. These fit the prepared canal so well that some operators are using a single gutta-perch point and sealer. The only advantage of this technique is its simplicity. The disadvantage is that the majority of sealers are soluble. As the canal will not be fully filled in three dimensions, tissue fluids may leach out the sealer over time. The use of single gutta-percha point and sealer technique today is considered to be below the standard of care in contemporary endodontic practice.

LATERAL COMPACTION

The lateral compaction of cold gutta-percha points with sealer is the technique most commonly taught in dental schools and used by practitioners and has long been the standard against which other methods of canal obturation have been judged. The technique can be used in most clinical situations and provides length control during compaction. The procedure can be accomplished with any of the acceptable sealers.

Step-by-step procedure of lateral compaction:

1. The canal should be irrigated, cleaned and dried.
2. A master point is selected and fitted to the canal.

If cone is going beyond apical foramen, cut the cone to working length or use (fig. 14). It should be marked at working length, or grasped securely in endodontic locking tweezers larger number cone.

Master cone selection is done by visual test, by tactile method, by radiographs (prefered).

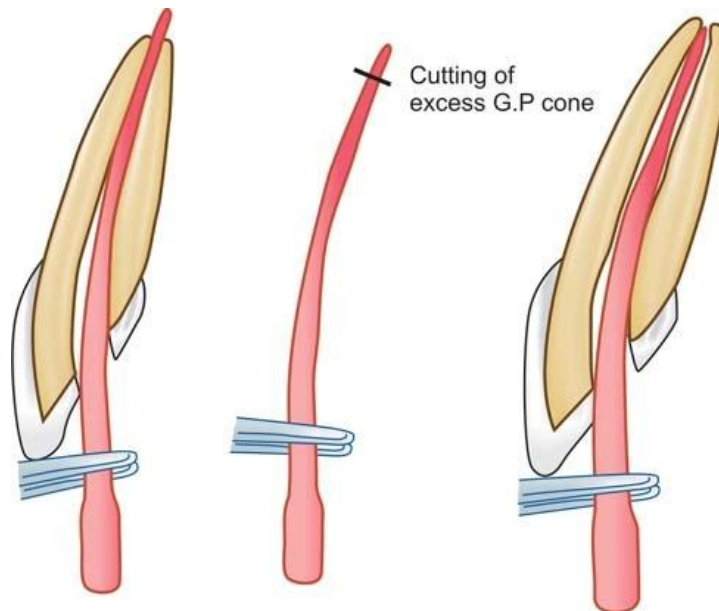


Fig. 14. If cone is going beyond apical foramen, cut the cone to working length or use larger number cone

3. The master point is coated with sealer and used to paste the canal walls with the sealer, using an in-out movement, before seating the point home into the canal at full working length.

4. A fine finger spreader is selected and the rubber stop set to working length. Place the spreader alongside the master point and compact using firm apical finger pressure only.

5. Leave the spreader in situ for 30 seconds. This is important as continuous pressure from the spreader is required to deform the gutta-percha point against the canal walls and to overcome its elasticity.

6. Select an accessory point with locking tweezers and dip its tip into sealer (fig. 15).

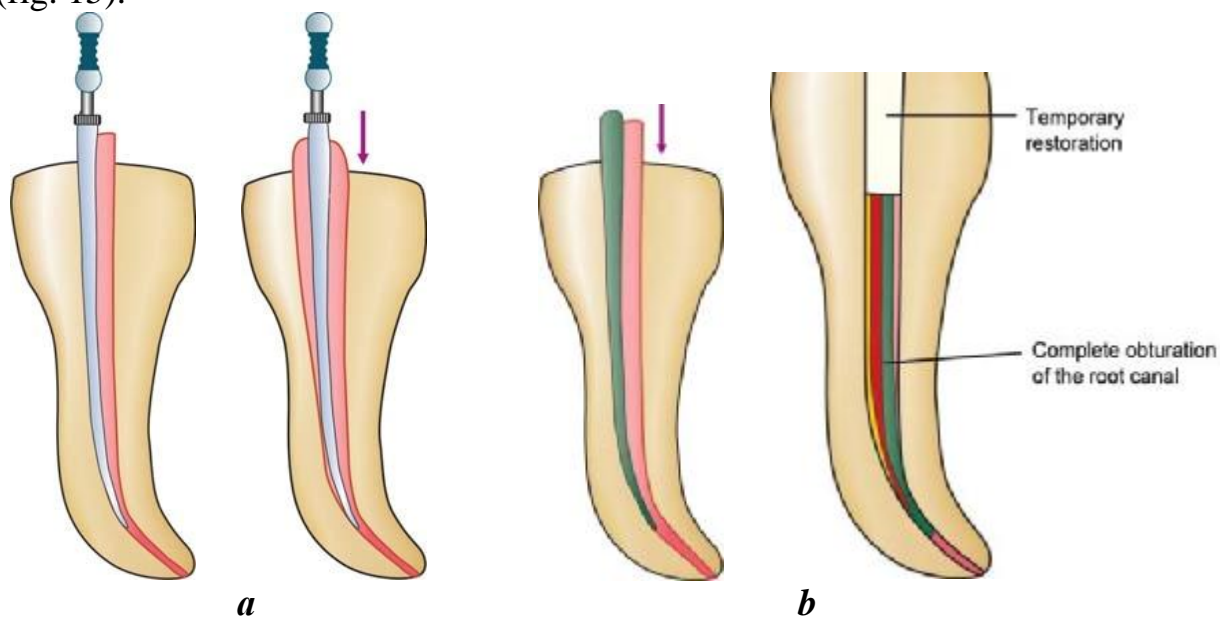


Fig. 15. Placing and compaction of gutta-percha using spreader (a). Placing accessory cone along master cone (b)

7. Immediately place the accessory point alongside the master point. Any delay will allow the master point to relax and the space will be lost. Reinsert the spreader and laterally compact both points.

8. Repeat the sequence using gradually larger spreaders and gutta-percha points until the canal is filled.

9. Remove excess gutta-percha from the canal orifice with a heated plugger or another heated instrument, and firmly compact the remaining gutta-percha to seal the coronal access to the canal.

If post-space preparation is required; it may be carried out at this stage. If not, a layer of resin-modified glass ionomer cement should be applied over the gutta-percha and the floor of the access cavity, completing the coronal seal.

A periapical radiograph should be taken on completion, using a long-cone parallel technique.

Advantages of lateral compaction technique:

1. Can be used in most clinical situations.
2. During compaction of gutta-percha, it provides length control, thus decreases the chances of overfilling.

Disadvantages of lateral compaction technique:

1. May not fill the canal irregularities efficiently.
2. Does not produce homogenous mass.
3. Space may exist between accessory and master cones. It is considered that the space between each of the cones is filled with sealer (fig. 16).

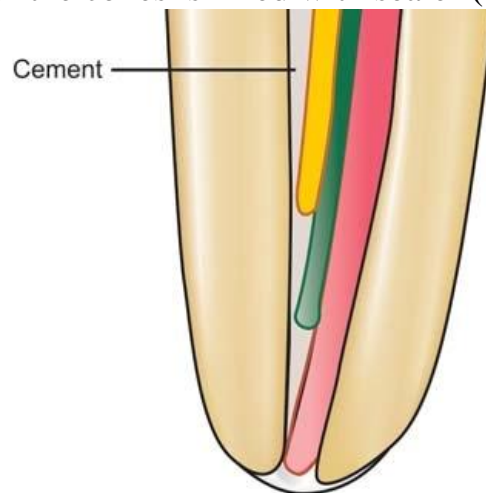


Fig. 16. In lateral compaction of gutta-percha, cones never fit as homogeneous mass, sealer occupies the space in between the cones

Apical modification with solvent. A disadvantage to lateral condensation of gutta-percha is that the material does not conform to the irregularities of the canal. Although lateral condensation reduces the space between the obturating cones, unfilled areas («voids») remain as potential paths for leakage. Because the prepa-

ration of a completely round canal is impossible and because the crucial apical area of the canal is likely to contain lateral canals, the tug-back experienced and the image displayed on a two-dimensional radiograph may give a misleading impression of a dense fill. In reality, only point contact may exist between the core and the walls of the canal. This situation is often discovered when an accessory point extends into the periapical area despite a seemingly well-placed master cone.

To overcome this shortcoming, the clinician can temporarily soften the tip of the point by dipping the master cone in a solvent (chloroform, halothane, or eucalyptol) for several seconds and placing the softened point into the canal (fig. 17).



Fig. 17. Adaptation of the master cone can be accomplished by softening the point in a solvent such as chloroform

This produces an impression of the apical portion of the canal in the material. The clinician then removes the cone from the canal for a few moments to allow the solvent to evaporate, applies the sealer, and replaces it so that it is oriented in the same direction as when the impression was made. Although concerns have been raised about the use of chloroform in the dental operator, evidence indicates that it is safe to use the material for fabricating custom cones and for retreatment.

Although standardized cones are available from size 15 (0.15 mm) to 140 (1.40 mm), occasionally a canal is encountered that exceeds these dimensions. In such cases a customized gutta-percha point can be created by rolling several warmed gutta-percha points together with a cement spatula on a glass slab. The point is cooled with water and the size is tested in the canal and rerolled until an approximate fit is achieved. Solvent dip may then be used to further adapt it to the walls of the canal.

Cold gutta-percha compaction technique

Gutta flow. Gutta flow is eugenol free radiopaque form which can be injected into root canals using an injectable system. It is a self-polymerizing filling system in which gutta-percha in powder form is combined with a resin sealer in one capsule.

Composition. Gutta flow consists of polydimethyl siloxan matrix filled with powdered gutta-percha, silicon oil, paraffin oil, palatinum, zirconium dioxide and nano silver.

Advantages:

1. Easy to use.
2. Time saving.
3. Does not require compaction.
4. Does not require heating.
5. Biocompatible.
6. Can be easily removed for retreatment.

LATERAL COMPACTION OF WARM GUTTA-PERCHA

A simple modification to the cold lateral compaction technique is to apply heat to gutta-percha. Heat can be applied to gutta-percha using:

1. A heat carrier.
2. An electrically heated tip.
3. An ultrasonic tip.

The softened material is easier to compact and will result in a denser root filling. Specially designed heat carriers should be used. The instruments illustrated in fig. 18 have a sharp tip for lateral compaction, and a blunt plugger tip for limited vertical compaction of the softened gutta-percha. Electrically heated spreaders are also available.

It is important that the instruments are only gently warmed. If the spreader is too hot it will melt the gutta-percha, which will adhere to the instrument and be withdrawn from the canal.

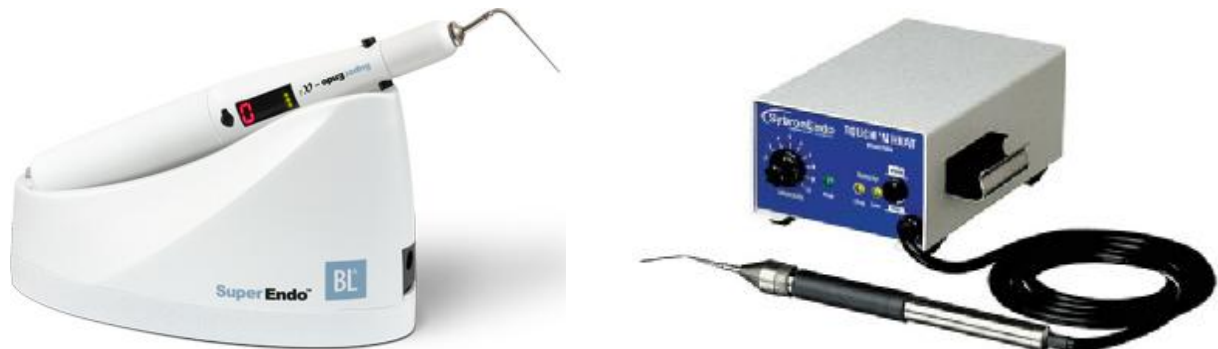

Fig. 18. Heated carriers for lateral compaction of warm gutta-percha

Step-by-step procedure of warm lateral compaction:

1. Make space for a heated instrument with a cold spreader.
2. Place a heated spreader into the canal and laterally condense until cool.

Remove the spreader cold (thereby allowing contraction and reducing the risk of removing the gutta-percha with the instrument).

3. Insert an accessory cone and sealer. Repeat the process until the canal is filled.

Warm lateral condensation has many advantages. Since it follows cold lateral condensation, heat is not introduced to the apex of the tooth. The technique also allows precise length control in the placement of gutta-percha and permits filling of voids, isthmuses, C-shaped canals, lateral and accessory canals, and internal

resorptive areas. The potential for root fracture is reduced because the thermoplasticized gutta-percha mass flows easily into the anatomic variations with light spreader pressure.

It is an easy technique to learn, and requires only a relatively inexpensive addition to the armamentarium. Warm lateral condensation does not require pre-heating or special gutta-percha. In addition, cleaning and sterilization procedures are not complex.

Use of ultrasound. Ultrasonic scaling unit (Cavitron (Dentsply), Enac Ultrasonic unit (OSADA) and others) can be used to supply heat for plasticizing gutta-percha to obtain better compaction (fig. 19).

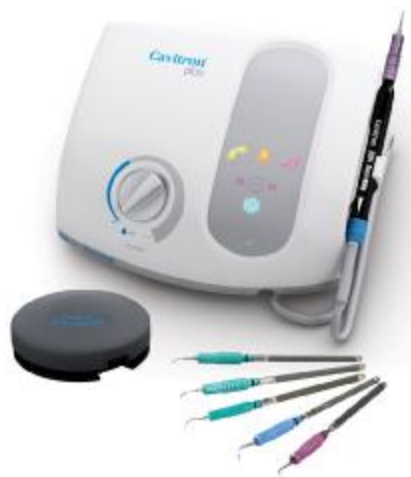


Fig. 19. Cavitron (Dentsply) and Enac (OSADA) ultrasonic units

Step-by-step procedure:

1. The # 25 file is attached to the insert of the ultrasonic unit spreader and placed alongside the primary gutta-percha point and sealer to a depth of about 5 mm short of the working length.

2. The ultrasonic unit with the rheostat is activated for 3 to 4 seconds.

The ultrasound thermal energy released by vibratory motion of the ultrasonically activated file plasticizes the gutta-percha.

3. Upon removal of the file, the spreader is inserted immediately to create room for auxiliary cones.

The softened primary cone allows a deeper penetration of the spreader, and a greater number of auxiliary cones can therefore be used to obtain better compaction.

THERMATIC COMPACTION OF GUTTA-PERCHA

The technique is particularly useful for the rapid and effective obturation of the coronal part of a root canal after placement of an accurate apical seal.

In 1979, McSpadden devised a handpiece-driven compactor, which is effectively an inverted Hedstroem file. Although no longer made, other similar devices, such as the gutta condensor (fig. 20).




Fig. 20. Gutta condenser

The frictional heat from the compactor plasticises gutta-percha and the blades drive the softened material into the root canal under pressure.

The main problem found was lack of control over the apical portion of gutta-percha, which may be extruded through the apex in its softened state. To overcome this problem, the technique was modified by Tagger, who recommended laterally condensing a master point and two or three accessory points, and then using the condenser to plasticize gutta-percha in the coronal part of the canal. The laterally compacted material in the apical half effectively prevents any apical extrusion.

Another innovation using the thermo-mechanical principle to compact gutta-percha in the root canal has been introduced as the **J. S. Quick-Fill** (J. S. Dental Co., Sweden/USA).

This system consists (fig. 21) of titanium core devices that come in ISO sizes 15 to 60, resemble latch-type endodontic drills, coated with alpha-phase gutta-percha. These devices are fitted to the prepared root canal and then, following the sealer, are spun into the canal with a regular low-speed, latch-type handpiece. Friction heat plasticizes the gutta-percha and it is compacted to place by the design of the Quick-Fill core. After compaction, there are two choices: either the compactor may be removed while it is spinning and final compaction completed with a hand plugger, or the titanium solid core may be left in place and separated in the coronal cavity with an inverted cone bur.



VERTICAL COMPACTION OF WARM GUTTA-PERCHA

Over 30 years ago, Schilder introduced a concept of cleaning and shaping root canals in a conical shape and then obturating the space «three-dimensionally» with gutta-percha, warmed in the canal and compacted vertically with pluggers.

Heated gutta-percha has been shown to flow extremely well into all canal irregularities. It is particularly useful in situations such as internal resorption, C-shaped canals, and those with fins or webs.

This technique is now considered the gold standard for endodontic obturation.

Basic requirements of a prepared canal to be filled by this technique are:

1. Continuous tapering funnel shape from orifice to apex.
2. Apical opening kept as small as possible.
3. Decreasing the cross-sectional diameter at every point apically and increasing at each point as the canal is approached coronally.

The warm vertical compaction was originally practised with a heat carrying instrument and open flame. Today, dentists use an electrical, temperature controlled device such as Touch'n Heat (Kerr/SybronEndo, Orange, CA, USA) or System B (Analytic/SybronEndo, Orange, CA, USA) and others.

In addition to these two classic methods of obturation, there are many newly developed applicators to place heat-plasticized gutta percha into the root canal such as Thermafil (Tulsa Dental Products, Tulsa, OK, USA), JS QuickFill (J.S.Dental, Ridgefield, CT, USA) and MicroSeal (Kerr/SybronEndo).

There are three phases of the vertical compaction technique:

1. Cone fit.
2. Down pack.
3. Back fill.

Step-by-Step Procedure of Vertical Compaction of Warm Gutta-percha:

1. Dry the root canal.
2. Fit the appropriate gutta-percha cone to the patent radiographic terminus.
 - a. It should visually go to full working length and exhibit tug-back.
3. Confirm the position radiographically.
4. Cut off the butt end of the cone at the incisal or occlusal reference point.
5. Remove the cone and cut back 0.5 to 1.0 mm of the tip, reinsert, and check the length and tug-back. The cone's apical diameter should be the same diameter as the last apical instrument to reach the radiographic terminus of the preparation (fig. 22, B).
6. Remove the cone, dip it in alcohol, and curve it slightly by drawing it through a folded 2×2 gauze so that it will more easily follow the probable curved shape of the canal. Set the cone aside.
7. Prefit the three pluggers to the canal preparation: first the widest plugger to a 10 mm depth (fig. 22, C); next, the middle plugger to a 15 mm depth (fig. 22,

D); finally, the narrowest plugger to within 3 to 4 mm of the terminus (fig. 22, E). Record the lengths of the desired plugger depth.

8. Deposit a small amount of root canal sealer in the canal with a lentulospiral. Lightly coat all of the walls.

9. Coat the apical third of the gutta-percha cone with a thin film of sealer.

10. Grasp the butt-end of the cone with cotton pliers and slide the cone approximately halfway down the canal. Then gently follow it fully into place with the closed tip of the cotton pliers (fig. 22, F). In a curved canal, the cone will rotate as it responds to the curvature.

11. Using the heat carrier, sear off the cone surplus in the pulp chamber down to the cervical level (fig. 22, G). This transfers heat to the coronal third of the gutta-percha cone and creates a platform to begin the first wave of compaction.

12. Using the widest vertical plugger that has previously been coated with cement powder as a separating medium, the gutta-percha is folded into a mass and compacted in an apical direction with sustained 5- to 10-second pressure (fig. 22, H). This is the first heat wave. The temperature of the gutta-percha has been raised 5 to 8 °C above body temperature, which allows deformation from compaction. At this temperature (42 to 45 °C), the gutta-percha retains its same crystalline beta form with minimal shrink-age as it cools back to body temperature.

13. The second heat wave begins by introducing the heat carrier back into the gutta-percha, where it remains for 2 to 3 seconds (fig. 22, I) and, when retrieved, carries with it the first selective gutta-percha removal (fig. 22, J).

14. Immediately, the mid-sized coated plugger is submerged into the warm gutta-percha. The vertical pressure also exerts lateral pressure. This filling mass is shepherded apically in 3 to 4 mm waves created by repeated heat and compaction cycles (fig. 22, K).

15. The second heating of the heat carrier warms the next 3 to 4 mm of gutta-percha and again an amount is removed on the end of the heat carrier (fig. 22, L).

16. The narrowest plugger is immediately inserted in the canal and the surplus material along the walls is folded centrally into the apical mass so that the heat wave begins from a flat plateau. The warmed gutta-percha is then compacted vertically, and the material flows into and seals the apical portals of exit (fig. 22, M).

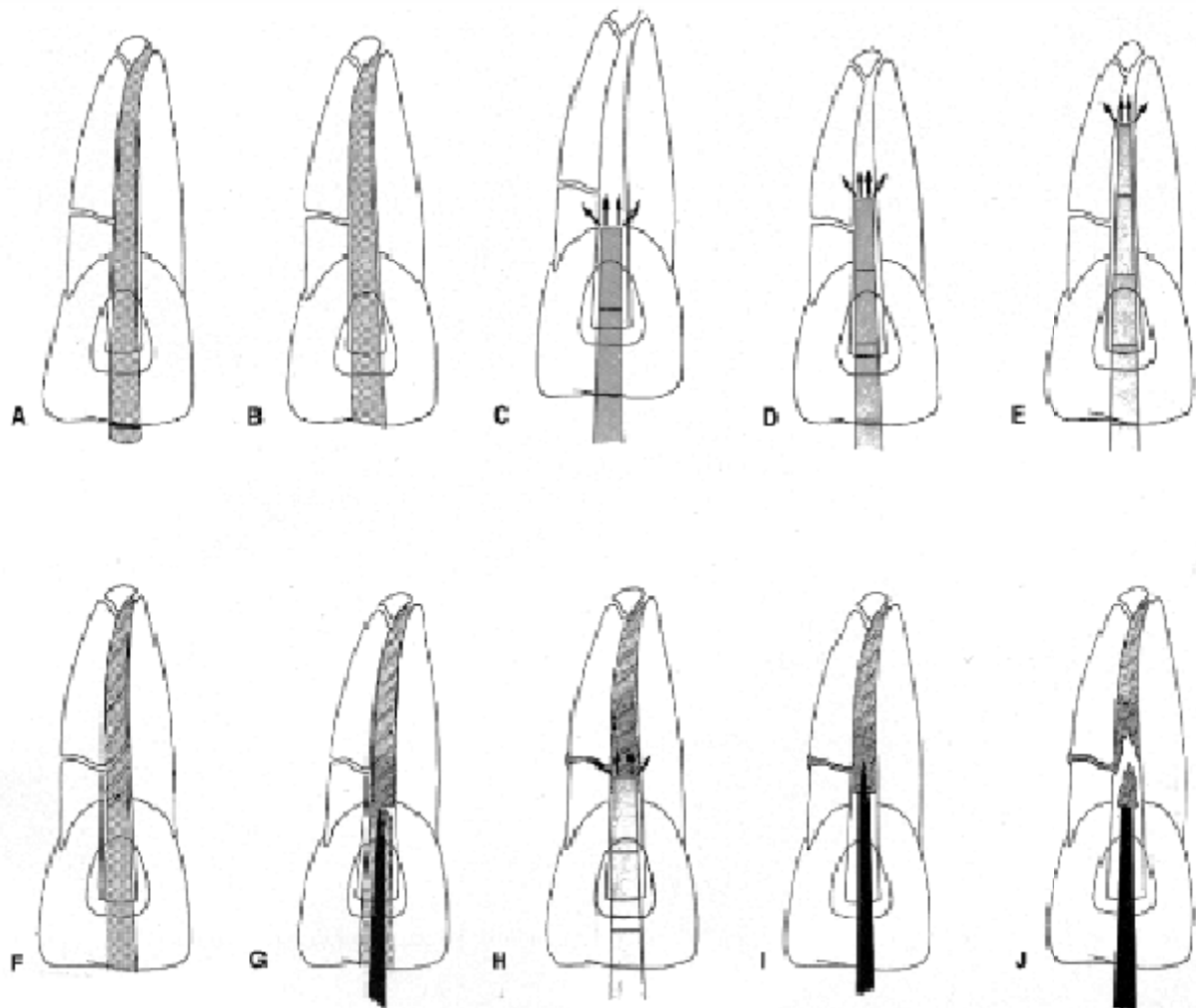


Fig. 22. Technique of warm gutta-percha/vertical compaction:

A — master gutta-percha cone fits tightly to radiographic apex; marked at the incisal edge to establish length reference; B — master cone cut back 0.5 to 1.0 mm at tip and retried in canal. Trimmed incisal reference remains the same; C — largest plugger prefitted to coronal third of the canal; D — midsize plugger prefitted to midcanal without touching the walls; E — smallest plugger prefitted to within 3 to 4 mm of radiographic apex; remains free in the canal; F — Kerr Sealer deposited in midcanal with Handy Lentulo spiral; apical third of master cone is lightly coated with sealer and gently teased to place; incisal reference checked; G — surplus gutta-percha removed with heat carrier down to the canal orifice; H — largest plugger compacts warmed gutta-percha into bolus; midroot lateral canal being obturated; I — heat carrier transfers heat 3 to 4 mm into middle third of mass; wiping carrier against the walls softens excess gutta-percha; J — first selective gutta-percha removal

17. The apical «down-pack» is now completed, and if a post is to be placed at this depth, no more gutta-percha need be used (fig. 22, N).

18. «Backpacking» the remainder of the canal completes the obturation. The classic method of backpacking consists of placing 5 mm pre-cut segments of gutta-percha in the canal, cold welding them with the appropriate plugger to the apical material (fig. 22, O), warming them with the heat-carrier (fig. 22, P), and then compacting. It should be noted that no selective removal of gutta-percha is attempted in the backpacking (fig. 22, Q). This sectional procedure is continued with heat and the next wider plugger until the entire canal is obturated (fig. 22, R).

An alternative method of backpacking may be done by injecting plasticized gutta-percha from one of the syringes, such as Obtura II (Obtura/Spartan, USA). In any event, the plasticized gutta-percha must be compacted with vertical pluggers to ensure its flow against canal walls, to weld it to the apical materials, and to minimize shrinkage (fig. 22, S).

The final act involves the thorough cleansing of the pulp chamber, the addition of an appropriate barrier, and the placement of a permanent restoration (fig. 22, T). In molar teeth, extra sealer should be placed in the chamber area, warm gutta-percha is syringed into the chamber flow, and the gutta-percha is compacted with large amalgam pluggers to ensure that any furcal portals of exit will be filled prior to final restoration.

Advantages: excellent seal apically and laterally.

Disadvantage: time consuming and risk of vertical fracture due to undue force.

Table 3

Intracanal temperature and tooth surface temperature rise in different obturation techniques

Technique	Intracanal temperature (°C)	Tooth surface temperature rise (°C)
Thermomechanical compaction	55–100	14–35
Warm vertical condensation	45–80	3–7
Obtura II	Max. 61	Max. 8.9
Ultrafil	70	–

Continuous wave technique. Buchanan recently introduced the continuous wave of condensation technique as a modification of the warm vertical compaction technique for canal obturation. «Continuous Wave Technique» requires a good canal shape and meticulous gutta-percha cone fitting.

Step-by-step procedure:

1. An appropriate size gutta-percha cone, matching the completed preparation shape, is tested in the canal to be sure it goes fully to place. This is confirmed radiographically. The cone must fit in its last 1 mm, and fit to full length before minimal cutback (less than 0.5 mm).

2. The cone is then removed and the corresponding plugger is tried for size in the canal. It should stop at its «binding-point», about 5 to 7 mm short of the working length. The stop attachment is then adjusted at the coronal reference point and the plugger is removed and attached to the heat source.

3. The canal is dried.

4. The primary point is coated with sealer and pushed into place, all the way to the apical stop.

5. The heat source is activated, and the temperature is set for 200 °C.

6. The cone is then seared at the orifice with the preheated plugger tip, and the preheated plugger is then «driven» smoothly through the gutta-percha to within 3 to 4 mm of its binding point in the canal. This will take about 2 seconds.

Maintaining apical pressure, the plugger will continue to move apically, and at this time the heat switch is released.

7. The plugger is held there, cold, under sustained pressure, for an additional 10 seconds. It is during this period that the gutta-percha flows to the apical matrix and into accessory canals. The pressure also compensates for the shrinkage that might occur as the mass cools.

8. Remove the plugger: while still maintaining apical pressure, the heat switch is activated for only 1 second followed by a 1-second pause. The «cold» plugger is then quickly withdrawn.

9. Following radiographic confirmation, the remainder of the canal is now ready for backfill.

System B. System-B heat source (fig. 23) delivers a precise heat to the tip of the plugger.




Fig. 23. Temperature controlled device for vertical compaction of warm gutta-percha. System B (Analytic/SybronEndo, Orange, CA, USA)

A non-standardized (4 %, 6 % or feathered tip) gutta-percha cone is carefully fitted to the canal. Using a selected plugger, a continuous wave of heat is applied to soften and downpack a cone, resulting in very well-compacted obturation of the apical portion of the canal.

Step-by-step procedure:

1. Fit a gutta-percha cone and mark it at the working length.
2. Select one of the System-B pluggers that binds in the canal 5–7 mm short of the working length. Set a rubber stop at this level, and select a conventional plugger to fit at this length as well.
3. Dry the canal with paper points.
4. Apply a thin layer of sealer to the apical third of the selected cone, and insert it to the working length.

5. Set the temperature of the System-B at 200 °C, with full power. Heat is applied to the plugger via the finger-tip micro switch, and the part of the cone extruding from the canal orifice is seared off.

6. The tip of the plugger is placed in the center of the gutta-percha cone, heat applied, and the plugger is carefully pushed down the canal in one slow, even movement to the depth marked. This should take about 3 seconds. The heat is turned off, and the plugger held in place for a further 10 seconds.

7. With a brief burst of heat to separate the plugger from the gutta-percha, the plugger is removed from the canal. It is usually found to bring with it the coronal portion of the gutta-percha as well.

8. The apical part may now be further compacted with conventional hand pluggers.

9. The coronal part of the canal may now be obturated with either injectable gutta-percha, described later, or further use of the System-B as follows.

10. A small length of gutta-percha, about 7 mm, is cut from a further accessory point, coated with sealer and inserted into the canal.

11. With the heat source turned down to 100 °C, otherwise this gutta-percha will not stay in the canal, a short burst of heat is applied, the gutta-percha compacted, and the plugger removed as before. Hand pluggers may be used to further compact this and any subsequent increments required.

The remainder of the canal may be obturated by further increments, or by another method.

A layer of resin-modified glass-ionomer cement is applied over the obturation, and a post-operative radiograph is exposed as normal.

Advantages of System B:

1. It creates a single wave of heating and compacting, thereby compaction of filling material can be done at the same time when it was heat softened.

2. Excellent apical control.

3. Less technique sensitive.

4. Fast, easy, predictable.

5. Condensation of the main canal and lateral canals.

6. Compaction of obturating materials occurs at all levels simultaneously throughout the momentum of heating and compacting the instrument apically.

WARM SECTIONAL GUTTA-PERCHA OBTURATION

The use of small warmed pieces of gutta-percha, the so-called sectional obturation technique, is one of the earliest modifications of the vertical compaction method described earlier.

1. The method begins like other methods: fitting the plugger to the prepared tapered canal (fig. 24, A). It should fit loosely and extend to within 3 mm of

the working length. A silicone stop is then set on the shaft marking this length (fig. 24, B).

2. Next, the primary gutta-percha point is blunted and carried to place. It should be fitted 1 mm short of the working length and confirmed radiographically (fig. 24, C). Upon removal, 3 mm of the tip of the point are cleanly excised with a scalpel (fig. 24, D) and this small piece is then luted to the end of the warmed plugger (fig. 24, E).

3. Sealer is placed, lining the canal, the gutta-percha tip is warmed by passing it through an alcohol flame, and it is then carried to place.

4. Under apical pressure, the plugger is rotated to separate the gutta-percha (fig. 24, F) and it is thoroughly packed in place. At this point, it is best to expose a radiograph to be sure the initial piece is in position (fig. 24, G).

5. If so, the remainder of the canal is filled in a like manner, compacting additional pieces of warmed gutta-percha until the canal is filled to the coronal orifice (fig. 24, H).

If a post is planned, the compaction can stop after the second piece, leaving 5 to 6 mm of the apical canal filled. Another variation of heat-softening the gutta-percha is to soften each piece in chloroform or halothane in a quick «dip».

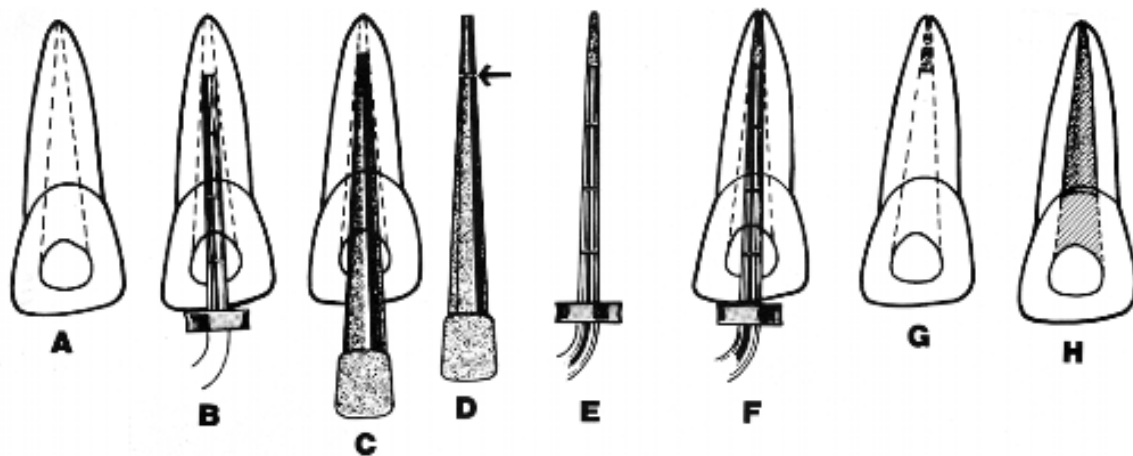


Fig. 24. Sectional gutta-percha obturation:

A — canal prepared with flare; B — plugger preselected to fit loosely in the canal and extend to within 3 mm of the working length; C — master gutta-percha point fitted to within 1 mm of the working length. Confirm by radiograph; D — gutta-percha is removed and 3 mm of the apical point are excised (arrow); E — plugger is warmed in alcohol flame and the point is luted to plugger; gutta-percha is warmed by passing through alcohol flame and quickly coated with cement; F — warm gutta-percha is carried to place; the plugger is rotated to loosen and then used for compaction; G — radiograph should confirm well-condensed apical filling; H — remainder of canal is filled by lateral or vertical condensation, by Compactor or Obtura (courtesy of

Dr. Ahmad Fahid)

APICAL THIRD FILLING

SimpliFill obturation technique. SimpliFill (Courtesy of LightSpeed Technol) is a two-phased obturation method that advocates the use of a stainless steel

carrier to place and compact a 5 mm segment of gutta-percha into the apical portion of canal (fig. 25).

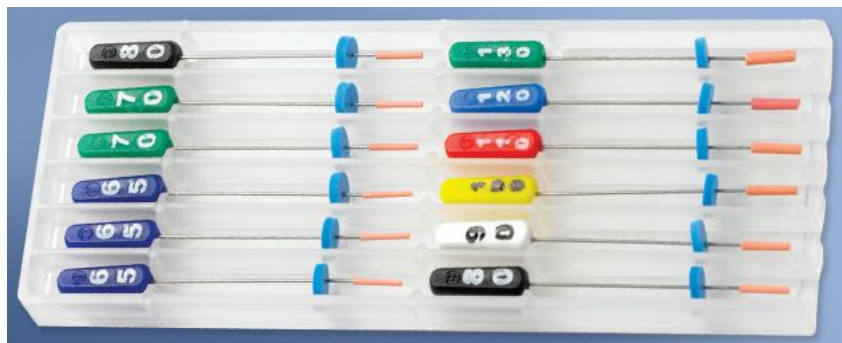

Fig. 25. SimpliFill obturation delivery device

Once placed, the carrier is removed, leaving a plug of gutta-percha. If a post is not desired, the second phase uses a specially designed syringe to backfill the remainder of the canal with sealer along with accessory cones of gutta-percha.

The clinician can also choose any other method to backfill the remaining portion of the canal.

According to the manufacturer, the overall advantages of SimpliFill are that its use helps to conserve dentin because of the light-speed instrumentation technique (less flaring); it eliminates additional internal forces since no spreader or plugger is used to compact the apical plug; it is simple to master; and, in contrast to other core-carrier systems, no carrier is left in the canal.

Step-by-step procedure:

1. Following the completion of the canal preparation, the specially designed Apical GP Plug Carrier (fig. 26) is trial fitted without sealer into the dry canal. Before insertion, however, the rubber stopper on the carrier, with its attached gutta-percha, is set 2 mm short of the working length.



Fig. 26. SimpliFill GP Plug Carrier

2. The carrier is then inserted into the canal and slowly advanced, until it should start to bind at the length indicated by the rubber.

3. Once the fit has been verified, the Apical Plug carrier is removed and the canal is coated with an appropriate sealer. The rubber stopper on the carrier is now advanced 2 mm to the working length.

4. The GP Plug Carrier is subsequently coated with sealer, inserted into the canal, and advanced until resistance is felt, about 2 mm short of the working length.

5. Using the carrier, the GP Plug is now vertically compacted to the working length with firm apical pressure. The carrier must not be rotated during insertion or compaction.

6. Once the GP Plug Carrier is snugly fit, the GP Plug is released by rotating the carrier handle counterclockwise. During this rotation, the carrier must not be pushed or pulled. If the GP Plug does not release, the carrier sleeve is grasped with cotton pliers and, while pushing apically on the sleeve, the handle of the carrier is rotated counterclockwise and withdrawn.

7. Phase 2 consists of backfilling the remaining canal if no post is desired. The clinician has a number of options for backfilling, including the method advocated by the manufacturer described as follows. A SimpliFill syringe is loaded with a sealer and the sealer is slowly injected into the canal space as the tip of the needle, equivalent to size #40 file, contacts the GP Plug and is slowly withdrawn. Inserting the needle all the way to the top of the plug will help eliminate formation of air bubbles during the backfill. An ISO standardized gutta-percha cone, equivalent in size to the Apical GP Plug used to fill the apical segment, is then coated with sealer and placed into the sealer-filled canal until it contacts the compacted GP Plug. Accessory gutta-percha cones can be added as space fillers. As stated earlier, the clinician can also backfill using traditional warm-vertical compaction or may simply backfill using the Obtura II.

Advantages:

1. Easy to use.
2. Time saving.
3. Does not require compaction.
4. Does not require heating.
5. Biocompatible.
6. Can be easily removed for retreatment.

SOLID-CORE CARRIER: MANUAL INSERTION

In 1978, Johnson described a unique yet simple method of canal obturation with thermoplasticized alpha-phase gutta-percha carried into the canal on an endodontic file. What was a curiosity in 1978 has become today a popular and respected technique of canal obturation.

ThermaFil (fig. 27) is considered the major core-carrier technique, and through a licensing agreement with Dentsply, a duplicate product, Densfil was created. Recently, two similar products were introduced: Soft-Core, and its European version, Three Dee GP.




Fig. 27. Thermafil and Termaprep Plus heating system (special electric device designed for the heating requirements of Thermafil)

ThermaFil (Dentsply/Tulsa) is a patented endodontic obturator consisting of a flexible central carrier, sized and tapered to match variable tapered files (.04/.06) endodontic files. The central carrier is uniformly coated with a layer of refined and tested alpha-phase gutta-percha. The use of the variable tapered files in canal preparation has enhanced the fit, placement, movement, and compaction of the gutta-percha delivered by the ThermaFil core carrier.

Likewise, the ThermaFil system now comes with metallic size verifiers that are used to determine, with greater precision, the size and shape of the prepared canal prior to choosing the correct ThermaFil carrier. Initially, the central carrier was a newly designed stainless steel device. Contemporary carriers are made of radiopaque plastic that is grooved along 60 degrees of their circumference.

While the gutta-percha covering the original carriers was heated in a flame, the new plastic core carriers are heated in a controlled oven environment called the ThermaPrep Plus heating system (Dentsply/Tulsa; Tulsa, Okla.) (fig. 27). The heating time is well delineated and is dependent on the size of the core carrier. The use of the oven, according to the manufacturer's directions, is essential for success with this technique.

Soft-Core (Soft-Core System, Inc.), or its counterpart, Three Dee GP (Deproco UK Ltd.), is similar to ThermaFil; however, it contains a bipolymer compound and a tungsten core that is radiopaque. It has an easily detachable handle, referred to as a metallic insertion pin, that is removed with a slight twisting action. This leaves the coronal portion of the plastic core hollow, thus facilitating postspace preparation. The presence of the metallic insertion pin also allows a curving of the coronal portion of the carrier, thus facilitating the angle of core insertion. It is supplied in a sterile blister pack that also contains a matching size verifier. The carriers are thinner in taper than the ThermaFil carriers but are ISO sized at the apex. This was done to facilitate their use in small canals that are difficult to shape. Heating of the gutta-percha on the Soft-Core carrier is done in a halogen oven that is thermostatically controlled.

Step-by-step procedure (fig. 28):

1. Careful cleaning and shaping of the canal are essential, as is the development of a continuously tapering preparation. Contemporary approach favors

the use of the variable tapered endodontic files to achieve this goal and to enhance the obturation afforded by the ThermaFil technique.

2. Prior to obturation, it is recommended that the smear layer be removed with appropriate agents. This will promote the movement of the softened material into the dentinal tubules and enhance the seal.

3. Select a ThermaFil obturator of the size and shape which fits passively at the working length. Establish the length by taking a radiograph. Set at the proper length position rubber stop.

4. Now disinfect the obturator in 5.25 % sodium hypochlorite for one minute and then rinse it in 70 % alcohol.

5. Pre heat the «ThermaPrep» oven for some time.

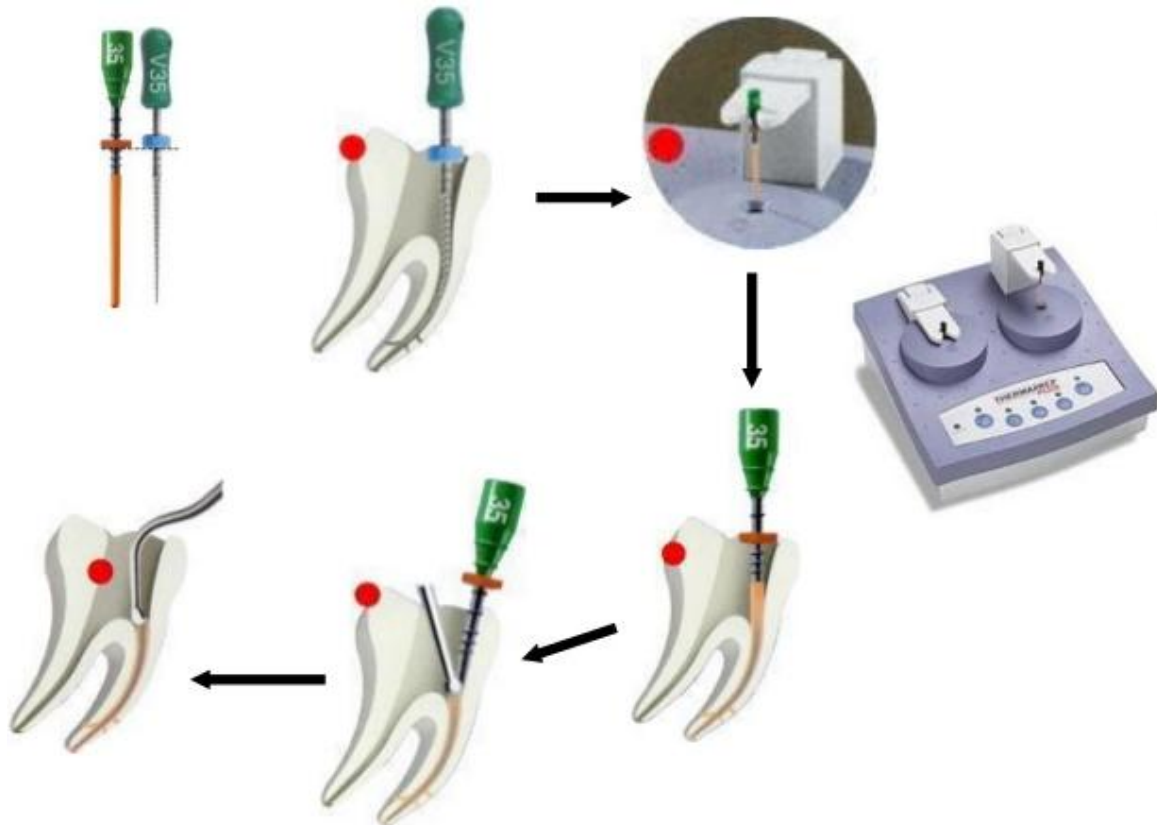


Fig. 28. Step-by-step procedure of filling root canal using ThermaFil obturators

6. After the canal is dried, a very light coat of sealer is applied to all of the walls. It acts as an adhesive as well as a lubricant. Preferred sealers include Thermaseal (Dentsply/Tulsa; Tulsa, Okla), AH-Plus (Dentsply/Maillefer; Tulsa, Okla.), Sealapex (Kerr/Analytic; Orange, Calif.), or ZOE cements. Quick-setting cements such as Tubliseal, or cements that contain natural gutta-percha softeners, such as Sealex, should be avoided with this technique. In the case of the former, the sealer sets up too rapidly when warmed. In the case of the latter, the chemical softening of the gutta-percha makes it too tacky and adherent to the dentin walls, thereby reducing its flow apically and into the canal irregularities.

7. Immediately after the sealer is applied, the warmed obturator is removed from the ThermaPrep Plus heater and carried slowly to the full working length in

the canal. Previously, the built-in rubber stop, on the calibrated shaft, was set at the proper length position. The carrier is not twisted during placement, and attempts to reposition the carrier should be avoided to prevent disruption of the gutta-percha that was initially positioned through the compacting action of the core carrier.

8. Once it is ensured radiographically that the canal has been filled to the desired position, the shaft is severed in the coronal cavity. While the handle is firmly held aside, a # 37 inverted cone bur is used to trim off the shaft 2 mm above the coronal orifice.

Specific burs have also been developed for this task: Prepi Bur (Prepost Preparation Instrument) (Dentsply/Tulsa; Tulsa, Okla.). The Prepi Bur, a noncutting metal ball, is run in a handpiece and is also used to create postspace safely and efficiently when needed. This space can be created immediately or on a delayed basis without altering the apical seal.

Advantages:

1. Requires less chairside time.
2. Provides dense three dimensional obturation as gutta-percha flows into the canal irregularities such as fins, anastomoses, and lateral canals, etc.
3. No need to precurve obturators because of flexible carriers.
4. Since this technique requires minimum compaction, so less strain while obturation with this technique.

INJECTABLE GUTTA-PERCHA

Instead of introducing gutta-percha into the root canal and applying heat to cause it to flow, the material can be heated outside the tooth and injected in a thermoplasticized state.

The Obtura system (fig. 29) is currently the most commonly used injection delivery system for gutta-percha.



Fig. 29. The Obtura system

The Obtura system consists of a handheld gun that contains a chamber surrounded by a heating element into which pellets of gutta-percha are loaded and heated. Silver needles are attached to deliver the thermoplasticized material to the canal. The gun is connected by a cord to a control unit that allows the operator to adjust the temperature and therefore the viscosity of the gutta-percha. To use the system, the clinician prepares the canal in the same manner as for lateral con-

densation. Because the needles are small and the thermoplasticized material flows readily, the clinician should not create too much flare in the preparation. The apical terminus must remain as small as possible to prevent extrusion.

The machine resembles a glue-gun. Pellets of alpha-phase gutta-percha are softened at about 200 °C in the handpiece, and extruded through a heated silver needle. Although the temperature of the gutta-percha in the Obtura injection gun is as high as 302 °f to 338 °f (150 °C to 170 °C), the temperature of the extruded material may range from 140 °f (60 °C) to 280 °f (138 °C).

Indications:

1. Roots with straight or slightly curved canals.
2. For backfilling of canals.
3. For obturation of roots with internal resorption, perforations, etc.

Step-by-step procedure:

1. Before starting the obturation, applicator needle and pluggers are selected. The needle tip should reach ideally 3–5 mm of the apical terminus passively.

2. Apply sealer along the dentinal walls to fill the interface between gutta-percha and dentinal walls.

3. The gutta-percha is preheated, and the needle is placed in the canal within 3 to 5 mm short of apex, as warm gutta-percha flows and fills the canal, back pressure pushes the needle out of the canal.

4. Now use pluggers to compact the gutta-percha, pluggers are dipped in isopropyl alcohol or sealer to prevent sticking of the gutta-percha. Continuous compaction force should be applied throughout the obturation of whole canal to compensate shrinkage and to close any voids if formed.

Alternatively, the clinician may use a segmental technique, in which 3 to 4 mm segments of gutta-percha are sequentially injected and condensed. In either case, condensation should continue until the gutta-percha cools and solidifies, which takes 3 to 5 minutes. This compensates for the contraction that takes place when it cools.

ULTRAFIL SYSTEM

UltraFill system (fig. 30) uses low temperature (i. e. 70 °C) plasticized alpha phase gutta-percha. Here gutta-percha is available in three different viscosities for use in different situations. Regular set and the firm set with highest flow properties primarily used for injection and need not be compacted manually. Endoset is more of viscous and can be condensed immediately after injection.

Step-by-step procedure:

1. Cannula needle is checked in the canal for fitting. It is hold 6–7 mm from the apex. After confirmation, it is placed in heater (at 90 °C) for minimum of 15 minutes before use.

2. Apply sealer in the canal and passively insert the needle into the canal. As the warm gutta-percha fills the canal, its backpressure pushes the needle out of the canal.

3. Once needle is removed, prefitted plugger dipped in alcohol is used for manual compaction of gutta-percha.



Fig. 30. UltraFill root canal obturation system (Hygenic)

Table 4

Difference between Obtura II and Ultrafil

Obtura II	Ultrafil
Uses high temperature Uses gun with heating element Uses needles of gauge 18, 20, 22 and 25 Working time is 3–10 minutes Digital display of temperature	Uses low temperature There is no heating element Uses needles of gauge 22 Working time is less than one minute No digital read out

Table 5

Main advantages and disadvantages of different root canal obturation methods

Different root canal obturation methods		Main advantages and disadvantages
Solid core techniques	Single cone	1. Simple. 2. Quick. 3. Good length control. 4. Round standard preparation required.
	Lateral compaction	1. Good length control. 2. Not one compact mass of gutta-percha. 3. Time-consuming technique. 4. Supposed risk of root fracture.
Softened core techniques	Warm lateral compaction	1. Moderate length control. 2. Time-consuming technique. 3. Heat may damage periodontium.
	Warm vertical compaction	1. Excellent seal apically and laterally. 2. Poor length control. 3. Sealer extrusion. 4. Heat may damage periodontium.

Different root canal obturation methods		Main advantages and disadvantages
	Injection-molded gutta-percha	1. Quick technique. 2. Poor length control. 1. Heat may damage periodontium.
	Thermo-mechanical compaction	1. Quick technique. 2. Poor length control. 3. Heat may damage periodontium. 2. Instrument fracture risk.
	Core carrier	3. Provides dense three dimensional obturation. 4. Quick technique. 5. Sealer extrusion. 6. Gutta-percha may be stripped off carrier in curvature. 7. Difficult to remove for retreatment. 8. In combination with posts, inconvenient technique.

PATIENT INSTRUCTION AFTER CANAL OBTURATION

The patient should be advised that the tooth may be slightly tender for a few days. The discomfort may be due to sensitivity to the possible excess of filling materials pushed beyond the apical foramen. Excess sealer is usually absorbed in a few months. Pain from temporary apical inflammation may be relieved by non-steroidal anti-inflammatory drugs, analgesics, and frequent warm saline rinses (1 level teaspoon salt per 8-ounce glass of very warm water). The patient is advised to hold the warm water in the affected area for 10 seconds, empty the mouth, and repeat the procedure until the entire glass of warm salt water has been used. If swelling occurs, cold compresses or an ice bag should be applied on the face over the affected area: on 10 minutes, off 5 minutes, for several hours. This intraoral warming and extraoral chilling is usually effective in relieving post-endodontic swelling and discomfort.

Anti-inflammatory drugs such as corticosteroids together with an antibiotic may be prescribed in severe cases. The patient should be advised not to chew unduly on the tooth until it is protected by a permanent restoration.

RECALL CHECKUP

A recall checkup for clinical evaluation of tissue repair and healing progress should be arranged before the patient is dismissed. If bone loss is extensive or the therapy was unusual or prolonged, the first recall checkup should be within 3 months; in most cases, patients are recalled in 6 months. A comparison of the new radiograph with the preceding one should show continued regeneration of bone.

Complete bone regeneration and healing require a few months to more than one year. The periapical tissue of an endodontically treated tooth without an area of rarefaction should continue to appear normal at the recall checkup.

The radiograph of a successful root canal filling should show the periodontal ligament with a uniform thickness and the lamina dura continuous along the lateral surfaces of the root and around the apex. A break in the continuity of the lamina dura around the apex should be questioned as evidence of possible pathologic disturbance. The root canal filling should appear homogeneously dense and filled to the dentin-cementum junction. The tooth should be entirely comfortable to the patient and be serviceable as a useful member of the masticating apparatus.

REFERENCES

1. *Carrote, P.* Endodontics. Part 8. Filling the root canal system / P. Carrote // *British Dental Journal*. 2004. № 197. P. 667–672.
2. *Clinical Endodontics* / eds. L. Tronstad. 2th ed. New York : Thieme, 2003. 271 p.
3. *Cohen's pathways of the pulp* / eds. : K. M. Hargreaves, S. Cohen, L. H. Berman. 10th ed. China : Elsevier, 2011. 986 p.
4. *Endodontics : principle and practice* / eds. : M. Torabinejad, R. E. Walton. 4th ed. China : Elsevier, 2008. 598 p.
5. *Endodontics* / eds. : S. Cohen, R. C. Burns. 8th ed. New York : Elsevier, 2002. 1021 p.
6. *Endodontics* / eds. : C. J. R. Stock, R. T. Walker. China : Elsevier, 2014. 388 p.
7. *Larz, S. W. Spångberg & Markus Haapasalo. Rationale and efficacy of root canal medicaments and root filling materials with emphasis on treatment outcome* / S. W. Larz // *Endodontic Topics*. 2002. № 2. P. 35–58.
8. *Problems Solving in Endodontics : Prevention, Identification and Management* / eds. : J. L. Gutmann, P. E. Lovdahl. 5th ed. China : Elsevier, 2010. 482 p.
9. *Schwartz, R. S. Adhesive Dentistry and Endodontics. Part 2. Bonding in the Root Canal System — The Promise and the Problems : A Review* / R. S. Schwartz // *JOE*. 2006. Vol. 32, № 12. P. 1125–1134.
10. *Textbook of Endodontology* / eds. : G. Bergenholtz, P. Hørsted-Bindslev, C. Reit. 2th ed. United Kingdom : Blackwell Publishing, 2010. 402 p.
11. *Textbook of Endodontics* / eds. : N. Garg, A. Garg. 2th ed. New Delhi : Jaypee Brothers Medical Publishers, 2010. 555 p.

CONTENTS

CORE MATERIALS	3
Gutta-percha.....	4
The resin-based obturation systems	7
Silver cones	8
SEALERS.....	8
Zinc oxide eugenol cements.....	11
Calcibiotic root canal sealer.....	11
Chloropercha	12
Calcium hydroxide sealers	12
Hydraulic calcium silicate cements	13
Glass ionomer sealers.....	14
Resin.....	14
Epiphany	14
Silicone sealers.....	16
Bioceramic	17
ARMAMENTARIUM FOR OBTURATION	17
METHODS OF OBTURATION	19
Obturation with silver cone.....	20
Single gutta-percha point and sealer.....	21
Lateral compaction.....	22
Lateral compaction of warm gutta-percha	25
Thermatic compaction of gutta-percha	27
Vertical compaction of warm gutta-percha	28
Warm sectional gutta-percha obturation	34
APICAL THIRD FILLING	35
Solid-core carrier: manual insertion.....	36
Injectable gutta-percha.....	39
UltraFil system.....	40
PATIENT INSTRUCTION AFTER CANAL OBTURATION.....	42
RECALL CHECKUP.....	42
REFERENCES	43