

# MINIMAL INVASIVE METHODS OF TOOTH OPERATIVE TREATMENT

Minsk BSMU 2016

МИНИСТЕРСТВО ЗДРАВООХРАНЕНИЯ РЕСПУБЛИКИ БЕЛАРУСЬ  
БЕЛОРУССКИЙ ГОСУДАРСТВЕННЫЙ МЕДИЦИНСКИЙ УНИВЕРСИТЕТ  
1-я КАФЕДРА ТЕРАПЕВТИЧЕСКОЙ СТОМАТОЛОГИИ

**МИНИМАЛЬНО ИНВАЗИВНЫЕ МЕТОДЫ  
ОПЕРАТИВНОГО ЛЕЧЕНИЯ ЗУБОВ**

**MINIMAL INVASIVE METHODS OF TOOTH  
OPERATIVE TREATMENT**

Учебно-методическое пособие



Минск БГМУ 2016

УДК 616.314-002-08(811.111)-054.6(075.8)  
ББК 56.6 (81.2 Англ-923)  
М61

Рекомендовано Научно-методическим советом университета в качестве  
учебно-методического пособия 17.02.2016 г., протокол № 6

А в т о р ы: Л. А. Казеко, Ю. В. Модринская, И. С. Кармалькова, Е. Л. Колб

Р е ц е н з е н т ы: канд. мед. наук, доц. Н. М. Полонейчик; канд. мед. наук, доц.  
А. Г. Третьякович; канд. филол. наук, доц. М. Н. Петрова

**Минимально инвазивные методы оперативного лечения зубов = Minimal invasive methods of tooth operative treatment** : учеб.-метод. пособие / Л. А. Казеко [и др.].  
– Минск : БГМУ, 2016. – 20 с.

ISBN 978-985-567-426-0.

Рассматриваются вопросы минимального инвазивного лечения кариеса зубов. Описаны методы, материалы и инструменты, необходимые для минимального инвазивного лечения кариеса зубов. Материал базируется на имеющихся в отечественной и зарубежной литературе современных представлениях по данной проблеме.

Предназначено для студентов 3-го курса медицинского факультета иностранных учащихся, обучающихся на английском языке.

УДК 616.314-002-08(811.111)-054.6(075.8)  
ББК 56.6 (81.2 Англ-923)

ISBN 978-985-567-426-0

© УО «Белорусский государственный  
медицинский университет», 2016

## DEFINITION

### Minimum intervention dentistry

● Minimum intervention dentistry is a concept based on a better understanding of the caries process and development of the carious process and the development of new diagnostic technologies and adhesives, bioactive restorative materials.

● Minimum (or minimal) intervention dentistry (MI) can be defined as a philosophy of professional care concerned with the first occurrence, earliest detection, and earliest possible cure of disease on micro (molecular) levels, followed by minimally invasive and patient-friendly treatment to repair irreversible damage caused by such disease

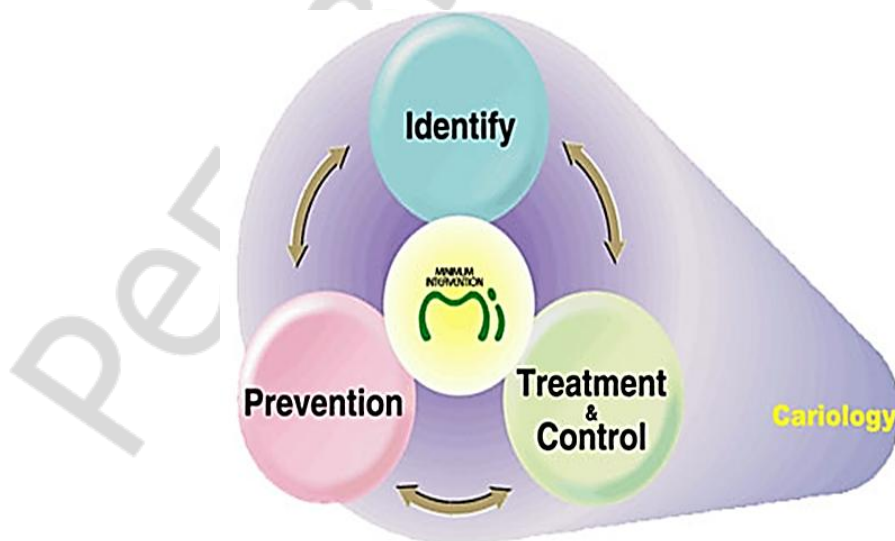
### Key-points of minimum intervention dentistry

● Minimum intervention can be defined as an approach for dentists to base their treatment plans on four key-points.

- Comprehensive diagnosis of the disease.
- The possibility to prevent caries and to remineralise early lesions.
- Minimally invasive operative treatment including repair of previous restorations rather than their systematic replacement.
- Patient education.

### Concepts of minimally intervention dentistry

- Early caries diagnosis.
- Classification of caries depth and progression.
- Assessment of individual caries risk (high, moderate, low).
- Reduction in cariogenic bacteria to eliminate the risk of further demineralization and cavitation and arresting of active lesions.
- Remineralization of early lesions.
- Minimal surgical intervention of caries lesions.
- Repair rather than the replacement of defective restorations.
- Assessing disease management outcomes at intervals.



Pic. 1. Key-points of minimum intervention dentistry

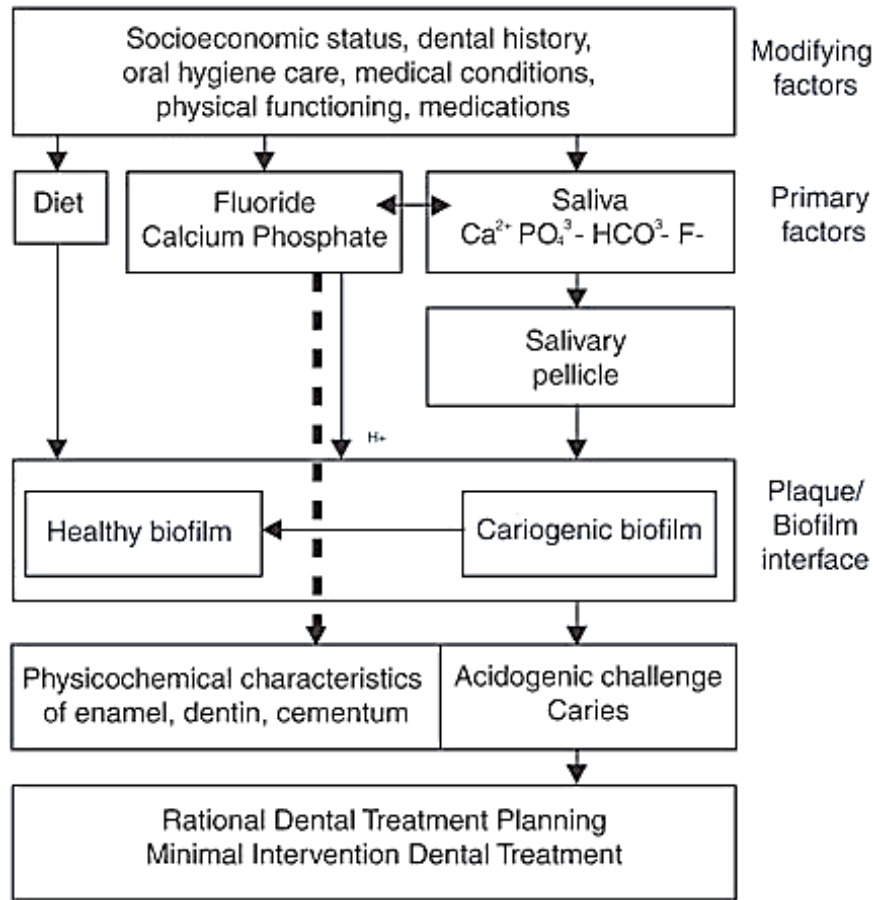
## Minimally Invasive Treatment Options for cavitated Lesions

Atraumatic restorative technique (ART).

Sandwich technique.

Pit and fissure sealants and preventive resin restorations.

Tunnel, box and slot preparation.



Pic. 2. MI caries management (modified from Ngo in Mount and Hume, 2005)

## ATRAUMATIC RESTORATIVE TECHNIQUE

### ART: INDICATIONS

- Only in small cavities.
- In those cavities that are accessible to hand instruments.
- Public health programs.

### ART: CONTRAINDICATIONS

- There is presence of swelling or fistula near the carious tooth.
- The pulp of tooth is exposed.
- Teeth have been painful for a long time and there may be chronic inflammation of the pulp.

### ART: ADVANTAGES

1. Easily available inexpensive hand instruments are used rather than the expensive electrically driven dental equipment.

2. As it is almost a painless procedure the need for local anesthesia is eliminated or minimized.

3. ART involves the removal of only decalcified tooth tissues, which results in relatively small cavities and conserves sound tooth tissues as much as possible.

4. Sound tooth tissue need not be cut for retention of filling material.

5. The leaching of fluoride from glass-ionomer cement probably remineralizes sterile demineralized dentin and prevents development of secondary caries.

#### ART: DISADVANTAGES

– ART restorations are not long lasting. The average life is two years depending upon the rate of caries activity of the individual oral cavity.

– Because of the low wear resistance and low strength of the existing glass ionomer materials their use is limited.

– A relatively unstandardized mix of glass ionomer may be produced due to hand mixing.

– The continuous use of hand instruments over long period of time may result in hand fatigue.

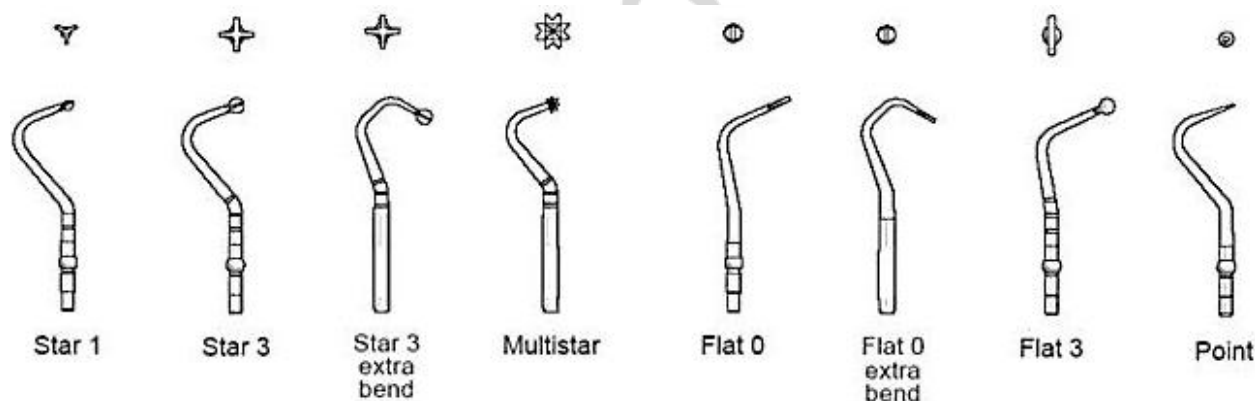
– As fundamental principles of cavity preparation are not followed all oral health workers may not accept it.

#### ART: INSTRUMENTS

1. Hand excavation.

2. Micro-preparation rotary instruments.

3. Non rotary cutting tools.



Pic. 3. ART: Hand excavation

### TUNNEL PREPARATION

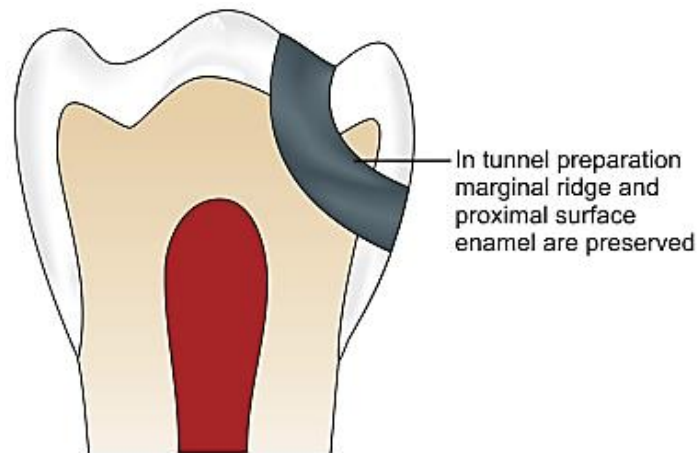
● If the lesion is more than 2.5 mm from the marginal ridge, a tunnel preparation is indicated.

● We preserve the marginal ridge and the proximal surface enamel.

Access to the lesion through the occlusal surfaces should be limited to the extent required to achieve visibility and should be undertaken from an area that is not under direct occlusal load (Knight, 1984).

Fossa immediately next to medial marginal ridge is the most suitable position for entry.

Glass ionomer is best suited for such cavities as it readily flows into a small cavity and has the ability to remineralize the enamel margins and any dentin on axial wall.



*Pic. 4. Tunnel preparation*

Two variations of tunnel preparation are described:

**Closed “tunnel”**: which leaves the demineralized approximal enamel intact.

**Open “tunnel”**: which is accessed from occlusal and exits through the approximal surface.

Advantages of tunnel preparation:

- Preserves the marginal ridge — conservative approach.
- Less potential for a restorative overhang.
- Perimeter of the restoration is reduced, decreasing the potential for micro leakage.
- Potential for disturbance of the adjacent tooth is reduced.

Disadvantages of tunnel preparation:

- Highly technique sensitive, demanding careful control of the preparation by the operator.
- Angulations of preparation often passes close pulp.
- Visibility is decreased and caries removal is more uncertain — caries detecting solution.
- Fragile marginal ridge — at least 2.5 mm apical to crest of the marginal ridge.

### **PROXIMAL CAVITY PREPARATION**

- This is a very conservative approach used when the proximal surface of a tooth becomes accessible at the time of cavity preparation in an adjacent tooth.
  - The lesion may have been revealed through radiographs or it may be noted only during cavity preparation.
  - The larger cavity in the adjacent tooth will normally need to be of reasonably generous proportions to allow room to maneuver, but when such an approach is possible, it leads to considerable conservation of natural tooth structure.

- It is only necessary to remove enamel that is broken down beyond remineralisation.

### **Slot Preparation**

- indicated for lesions which are less than 2.5 mm from the marginal ridge;
- there is removal of the marginal ridge, but the preparation does not include the occlusal pits and fissures if caries removal in these areas is not required.

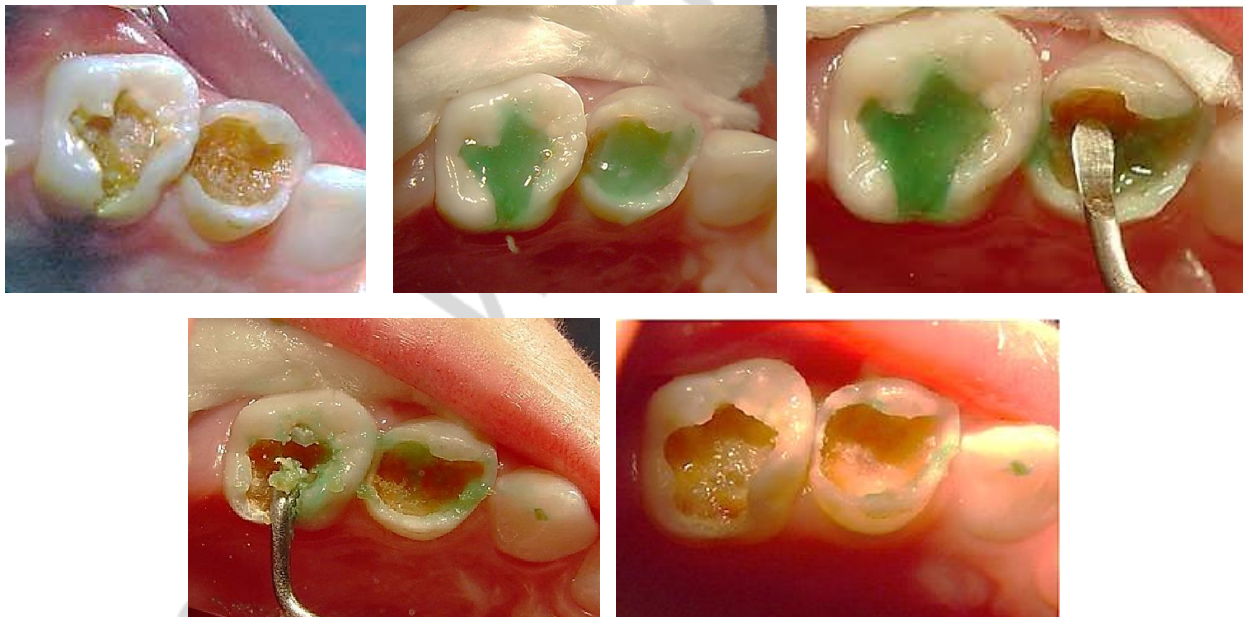
## **ALTERNATIVE PREPARATION METHODS**

1. Chemo-mechanical.
2. Ultrasonic.
3. Air abrasion.
4. Laser.

### **Chemomechanical caries removal**

Chemomechanical caries removal techniques are one of the recently documented alternatives to traditional mechanical rotary techniques and mechanical non-rotary techniques.

Chemomechanical caries removal involves the application of a gel or liquid to tooth tissue. This selectively softens the carious dentine, thus facilitating its removal. Removal of sound tooth structure, the cutting of open dentinal tubules, pulpal irritation and pain are all reduced when compared with conventional mechanical methods.



*Pic. 5. Chemomechanical caries removal*

**The clinical situations in which chemomechanical caries removal could be considered the preferred method include:**

1. When the preservation of tooth structure is important (this should be every case).
2. The removal of root/cervical caries, *where access and visibility are good.*



3. The management of coronal caries with cavitation, thus avoiding the use of dental handpieces.

4. The removal of caries at the margins of crowns and bridge abutments, thus decreasing the likelihood of replacing the entire crown/bridge.

5. The completion of tunnel preparations (where access to approximal caries is gained via the occlusal surface, leaving the marginal ridge intact).

6. Ensuring complete caries removal.

7. Where local anaesthesia is contraindicated.

8. The care of caries in dentally anxious patients (needle phobics).

9. Management of primary carious lesions in deciduous teeth.

10. Atraumatic restorative technique (ART) procedures.

11. Caries management in special needs patients.

#### **Contraindications:**

1. Sessions that necessitate short treatment time.

2. Pit and fissure caries that are not deep where rotary preparation will suffice to remove caries with little discomfort and the removal of hard eburnated part of the lesion.

3. Patient allergic to components.

#### ***Caridex***


The first commercially launched product for chemomechanical caries removal was Caridex (National Patent Medical Products Inc.), initially introduced on the US market in 1985. It was presented as a two-bottle system; the first contained sodium hypochlorite and the second, glycine, aminobutyric acid, sodium chloride and sodium hydroxide. Both solutions were mixed immediately before use to give the reagent with a pH approximately equal to 11 that was stable for one hour. The delivery system of Caridex consisted of a reservoir for the solution, heater and pump which passed the liquid warmed to the body temperature through a tube to a hand piece and applicator tip (20 gauge hypodermic needle, the tip of which had been modified into spoon shape). However, the unpleasant taste indicated by patients and the lengthy procedure (10–15 min), in addition to the large volumes of solution needed (200–500 ml) and to the fact that the delivery system was no longer commercially available, limited the use of Caridex clinically.

#### ***Carisolv***

During the 1990s a more efficient and effective chemomechanical caries removal system was developed called Carisolv (Medi Team).

The formulation of Carisolv is isotonic in nature and consists of the following:

- Sodium hypochlorite (0.5 %).
- Three amino acids (glutamic acid, leucine, lysine).
- Gel substance (carboxymethylcellulose).
- Sodium chloride/sodium hydroxide.
- Saline solution.
- Colouring indicator (red).



Pic. 6. Carisolv (Medi Team)

**Mode of action.** The softening effect on the carious tissue is the result of several reactions that act in concert to disrupt the fiber structure of collagen. The three amino acids are differently charged, which allows for an electrostatic attraction to different areas of the proteins in the carious dentine. The peptide chains of all proteins, including collagen, are made up of hydrophilic (positively or negatively charged) and hydrophobic (non-charged) patches. So each of the three chloro-amino acids in Carisolv electrostatically attract one of these patches, effectively bringing reactive power to the full length of the collagen fiber, while minimizing unwanted side- reactions from hypochlorite. The chemical result of these processes is a breakdown of degraded collagen characteristically found in the demineralised portion of a carious lesion. The gel only softens the carious dentine, while healthy tissue is unaffected. The degraded collagen has an open structure and is therefore more susceptible to penetration by CARISOLV and this dentin can be easily scraped off.

Carisolv can be used in the management of the majority of caries lesions, either in isolation or in conjunction with a handpiece, which may be required to gain access or remove existing restorations. The clinical technique employed can be quickly and easily mastered. However, careful case selection is initially required.

**Disadvantages:**

- Extensive training and registration of professionals.
- Customised instruments which increased the cost of the solution.

Carisolv is available in two forms:

1. Single mix system. The original Carisolv red gel contained three differently charged amino acids which were mixed with sodium hypochlorite prior to treatment. The new gel has no colour agent. It contains half the concentration of amino acids and a higher concentration of sodium hypochlorite 0.475 %, almost twice the 0.250 % in the original Carisolv gel.

The system is available as 5 transparent syringes containing an uncoloured gel and 5 white syringes containing transparent liquid. The transparent liquid contains: sodium hypochlorite solution 0.95 %.

2. Multi mix system. Twin syringe containing an uncoloured gel, 1.7 ml, and a transparent liquid, 1.7 ml. Once the gel has been mixed, its effect will begin to decline after about 30 minutes.


Carisolv® hand instrument 1 (extra bend; star 3, flat 0)  
Primarily used for crown margins and areas that are difficult to access.



Carisolv® hand instrument 2 (multistar, star 3)  
The basic instrument to apply gel and start removing caries. The multistar tip promotes penetration of the gel. When getting closer to healthy dentine, use the star-shaped tip, scraping in all directions with its four-pronged design.



Carisolv® hand instrument 3 (star 2, star 1)  
To remove caries in smaller cavities; for example, root caries or deciduous teeth.



Carisolv® hand instrument 4 (flat 3, flat 2)  
To be used, for example, close to the pulp and to remove the softened carious dentine from the cavity.



Carisolv® hand instrument 5 (flat 1, flat 0)  
Flat 0 and flat 1 are used to remove caries at the dentinoenamel junction.



Pic. 7. Carisolv instruments

### **Procedure:**

1. Mix the two components of carisolv (NaOCl and amino acid solution) thoroughly according to the instructions included with the package. Put the required amount of gel into a suitable container.
2. Use a carisolv instrument to pick up the gel and apply it to the carious dentine.
3. Soak the caries generously.
4. Wait for at least 30 seconds, for the chemical process to soften the caries.
5. Select a power drive tip or a Carisolv hand instrument to match the size, position and accessibility of the cavity.
6. Scraped off the superficial softened carious dentine. The hand instrument with the multistar tip may facilitate the early penetration of the gel. Work carefully using scraping or rotating movements.
7. Remove the softened carious dentine with the instrument. Avoid flushing or drying the cavity.
8. Keep the lesion soaked with the gel and continue scraping.
9. 30 seconds of waiting time is needed.
10. Repeat until the gel no longer turns cloudy and the surface feels hard using the instrument.

11. Check extra carefully for caries at the dentinoenamel junction. If you are using a drill to adjust the periphery before filling, this can be done while the gel is still in the cavity.

12. When the cavity feels free from caries, remove the gel and wipe the cavity with a moistened cotton pellet or rinse it with lukewarm water, inspect and check it with a sharp probe.

13. If the cavity is not free from caries, apply new gel and continue scrapping.

14. If necessary the periphery of the cavity should be adjusted using hand instruments or the drill.

15. Restore the tooth with a suitable filling material according to the manufacturer's instructions for use.

From a patient perspective the response to the technique has been almost universally positive, with patients reporting less pain, discomfort and shorter perceived treatment times when compared with traditional drilling. The avoidance of both slow-speed cutting and, in many cases, the use of a high-speed handpiece, makes the experience relatively pleasant for the patient. However in some instances, it is still necessary to use the high-speed handpiece with water coolant to gain access.

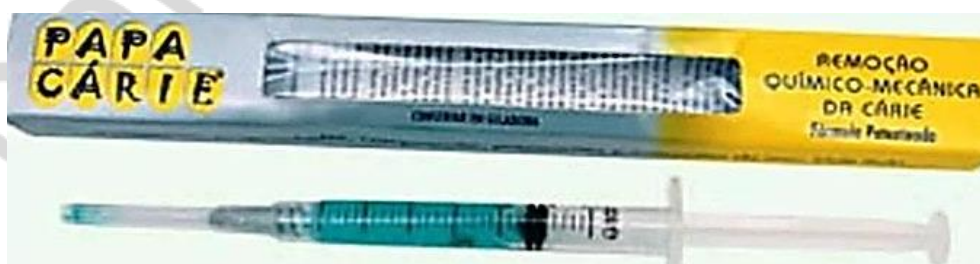A number of theories have been postulated as to why there may be reduced pain and need for local anaesthesia. These include the lack of cutting into caries-free dentine, relatively few dentine tubules are exposed, no vibrations from drilling, no great temperature variations and the dentine is constantly covered with an isotonic gel at body temperature. The possible psychological input of a quiet and less traumatic experience may also play an important role. In certain cases it is necessary to administer a local anaesthetic to complete deep cavity preparation or where existing restorations, crown and bridge-work require removal before cavity preparation.

### ***Papacarie***

In 2003, a research project in Brazil led to the development of a new formula to universalise the use of chemo-mechanical method for caries removal and promote its use in public health. The new formula was commercially known as Papacarie.

Formulation. The Papacarie is presented in the form of a gel containing in its composition and papain 10 %, chloramine-T — 0.5 %.

The composition basically contains papain gel — a protein extracted from the papaya — Chloramine, thickener and toluidine blue.



*Pic. 8. Papacarie*

### **Papain Gel: Mechanism of action**

1) Antitrypsin inhibits protein digestion but infected tissues do not usually show antitrypsin.

2) Since Papain can digest only dead cells, it acts breaking the partially degraded collagen molecules, contributing to the degradation and elimination of the fibrin “mantle” formed by the carious process.

3) Right after the degradation, oxygen is freed, bubbles appear on the surface, and a blurring of the gel is thus noted.

4) These signs demonstrate that the removal process can be started.

Papain acts only in the necrotic tissue due the occurrence of a plasma antiprotease, 1-antitrypsin, which prevents the action of proteolytic papain in normal tissues. The infected tissue did not present the 1-antitrypsin, hence papain acts to degrade the denatured collagen molecules.

### **Papain Gel: Procedure**

1) Proper diagnostic of the target tooth.

2) Prophylaxis of the region using rubber cup and slurry of pumice.

3) Rinsing with air/water spray or cotton pellet with water.

4) Isolation of target tooth.

5) Application of Papacarie, allowing the chemistry to work for 30 to 40 seconds.

6) Removal of the softened carious dentin using the opposite side of the excavator and promoting a pendulum movement; the softened tissue must be scraped, not cut.

7) Application of gel, if necessary.

8) The vitreous aspect of the cavity appears when the cavity feels free from caries.

9) Rinsing 0.12 %, 1 % or 2 % chlorhexidine or waterspray.

10) Drying with moisture-free and oil-free air.

11) Restoration with a suitable filling material according to manufacturer's instructions.

### **Papain Gel: Tips**

1) For removal, we recommended the use of the opposite side of an excavator, like a pendulum movement and without cutting.

2) The instrument should scrap the carious tissue without promoting any kind of stimulus or pressure.

3) The main characteristics of the complete removal of the infected dental tissue is the vitreous aspect of the cavity which appears after using Papacarie.

### **The ultrasonic preparation**

High frequency ultrasonic vibrations have been recommended since the 1950s to remove proximal carious lesions in both anterior and posterior teeth, with the aim of achieving a more conservative cavity preparation. This technique does not physically excise the dentine, but abrades it using a diamond-coated tip oscillating at a frequency of about 6.5 kHz ranging to a maximum frequency of 20–40 kHz.



Recently, sono-abrasion has been developed as a modification of the original ultrasonic method. Sono-abrasion is a technique for the selective preparation of enamel and dentine offering excellent efficacy, quality and safety. This technique utilizes high frequency, sonic, airscalers with modified abrasive tips which describe an elliptical motion with a transverse distance of 0.08–0.15 mm and a longitudinal movement ranges from 0.055 to 0.135 mm. These tips are diamond coated on the cutting side, cooled using water at a flow rate of 20–30 ml/min and operated by 305 bar air pressure for cavity finishing. Other tips shaped length ways halved torpedo, small hemisphere and large hemisphere are currently available.

Using the different shapes of the tips helps in preparing predetermined cavity outlines, and also works well in removing softened, carious dentine.

**Advantages:**

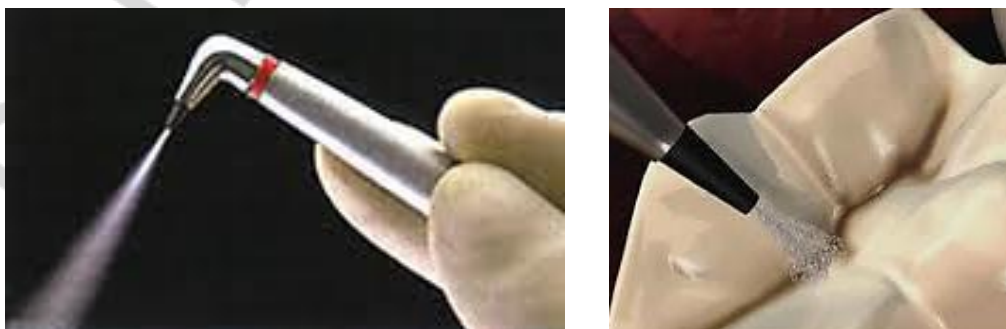
- The ultrasonic procedure has the advantage of minimising or eliminating noise, vibration, heat and pressure.
- The use of the ultrasonic technique can be helpful to modify the approximal preparation procedure in order to protect adjacent teeth against iatrogenic damage caused by the use of dental burs.

**Disadvantages:** relatively low abrasion and high hub excursion (0.4 mm) of the tips and the weakening of enamel rods with the associating cracks adjacent to the prepared sites.

**Air abrasion**

Air abrasion was originally developed by Robert Black in 1945 as an alternative pseudo-mechanical method for dental tissue removal and the first air abrasion unit marketed was called the Airdent by SS White

Air abrasion has also been revisited in recent years in light of developments in restorative materials and changes in cavity preparation design. Most units work by delivery of a jet of aluminium oxide particles at a pressure of 40–149 psi (276–1028 kPa) through a fine nozzle. It is these spray particles that effectively cut the tooth tissue and restorative materials. However, dentists are used to the parameters of tactile feedback and an appreciation of finite cutting depth when using rotary tooth-cutting techniques, both of which the end-cutting alumina air abrasive jet lacks. This makes the use of alumina air abrasion highly operator-sensitive and requires careful education of clinicians to realise its potential for minimally invasive preparation and the prevention of cavity over-preparation.



*Pic. 9. Air abrasion*

### **Air abrasion is best suited to the treatment of**

1. Cervical caries and recurrent caries around existing restorations.
2. Removal of superficial enamel defects.
3. Detection of pit and fissure caries.
4. Removal of pit and fissure surface stain.
5. Preparation of conservative cavities.
6. Surface preparation of abfractions and abrasions.

**Contraindications.** It should be avoided in cases involving severe dust allergy, asthma, chronic obstructive lung disease, recent extraction or other oral surgery, open wounds, advanced periodontal disease, recent placement of orthodontic appliances and oral abrasions, or subgingival caries removal. Many of these conditions increase the risk of air embolism in the oral soft tissues.

This method is not very effective for removal of soft caries, therefore manual excavation or slow handpiece removal is required. Some practitioners use chemo-mechanical caries removal in conjunction with air abrasion. Air abrasion cannot be used for precise cavity preparations, such as inlays or crowns.

### **The advantages of such a system include:**

1. A local anaesthetic is usually not required.
2. Several lesions in different quadrants can be completed at one visit.
3. Saucer-shaped preparations can be produced and these are ideal for resin-bonded restorations.
4. And there is less noise and vibration compared with the slow handpiece. It is painless.
5. Local anesthesia is rarely needed.
6. It works quickly and the tooth with a small lesion is ready to restore in seconds.
7. It work quietly without the whine of the all too familiar dental handpiece.
8. There is no vibration or pressure to cause microfractures that weaken tooth.
9. There is no production of heat to damage the dental pulp and lesser sound tooth structure is removed.

### **Air-abrasion: Precautions**

1. Need to protect patient with glasses, rubber dam if possible.
2. Dental team needs masks and glasses.
3. Stop frequently to check the progress.
4. Start with low pressure and low power then increase as needed.
5. Hold tip 1–2 mm away from tooth at a 45 degree angle then activate.
6. Always keep tip moving.
7. Requires external suction and air evacuation for the room.
8. Use disposable mirrors.
9. Like any air stream air abrasion can cause subcutaneous emphysema.

However, over-spray can contaminate the surgery, clog the handpiece bearings, block the suction units and damage unprotected adjacent teeth. It is claimed that newer air abrasion units eliminate these problems with high volume

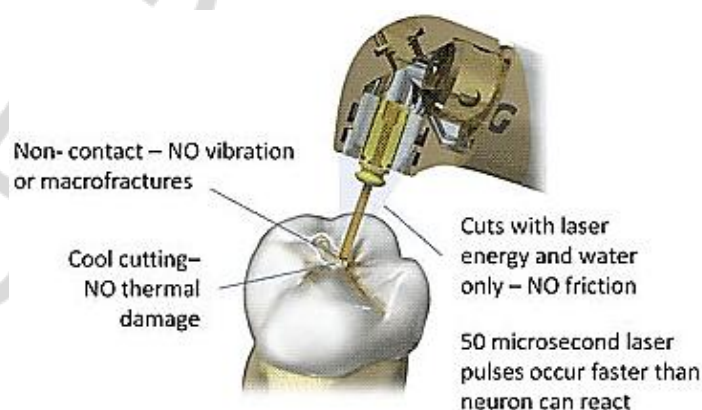
suction and water to reduce the over-spray. This method is not very effective for removal of soft caries, therefore manual excavation or slow handpiece removal is required. Some practitioners use chemomechanical caries removal in conjunction with air abrasion. Air abrasion cannot be used for precise cavity preparations, such as inlays or crowns.



Pic. 10. Tools of air-abrasion

### Air-abrasion: Procedure

- 1) Isolate preferably with rubber dam.
- 2) Clean the tooth.
- 3) Use caries detecting dye to know the carious lesions.
- 4) Using air abrasive unit with high volume evacuation placed in the proximity of the tooth prepare cavity.
- 5) After a few seconds of initial preparation examine the preparation for decay.
- 6) Re-apply caries detecting dye.
- 7) Complete the preparation using the caries detecting dye until all caries is removed.



### Lasers

The field of laser technology has developed considerably over recent years, and many types of lasers are available for cutting of dental hard tissue. Utilisation



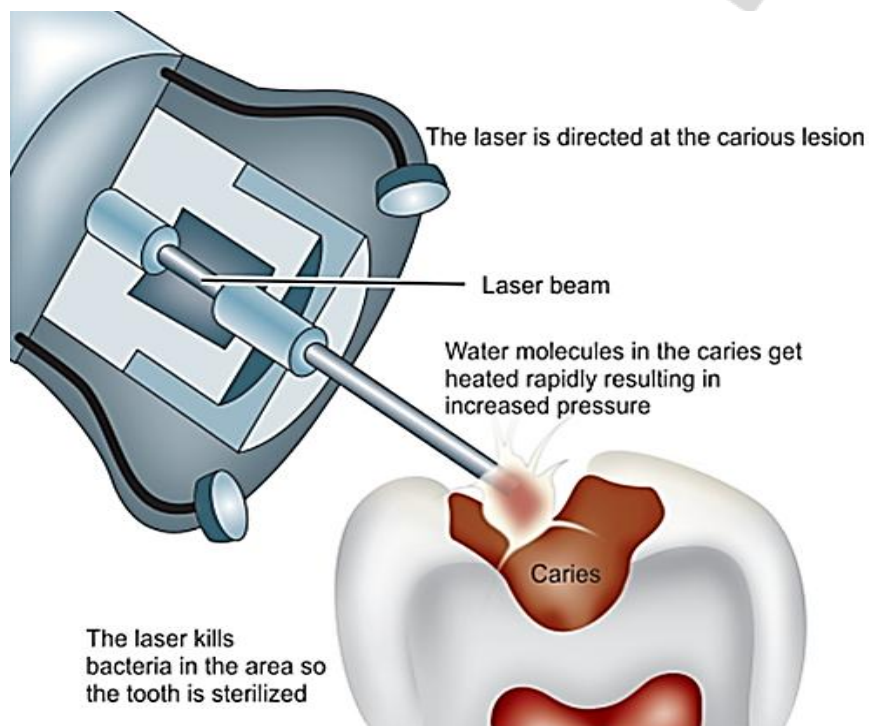
of the Er:YAG laser has been considered an effective instrument for cavity preparation and is able to cut as high-speed turbines, stimulate the secondary dentin and have an antibacterial effect. The radiation with Er:YAG laser may modify the dentin structure removes the smear layer of the dentin and exposes the dentinal tubules, which theoretically makes the surface more favorable to adhesion with the adhesive systems and consequently improving sealing of the restorations.

#### **Advantages**

- 1) Can be used without application of local anesthetics.
- 2) No vibration.
- 3) Little noise.
- 4) No smell.
- 5) Tooth preparation almost similar to that prepared by using air abrasion technique.

#### **Commonly used lasers for tooth preparation are:**

- erbium: yttrium-aluminum-garnet lasers;
- erbium, chromium: yttrium-scandium-gallium-garnet lasers.



*Pic. 11. Laser technology*

#### **Ozone**

During the last few years, reversal of caries using Ozone has also been suggested based on the fact that the remineralised tooth tissues are known to be more resistant to decay than sound tooth structure. Ozone therapy causes remineralisation of incipient pit and fissure caries as well as incipient root caries. Its usefulness in open lesions has also been demonstrated.

Ozone readily penetrates through decayed tissue, eliminating the ecological niche of cariogenic microorganisms as well as priming the carious tissue for remineralisation. As ozone readily penetrates through decayed tissue, eliminating

any bacteria, fungi and viral contamination, it would be expected that this “clean” lesion would remineralise. The remineralisation process will then take place with the aid of a topically applied remineralising solution and the recommended patient’s maintenance kit. Ozone has the effect, through its powerful oxidizing properties, of not only removing the protein protection and being bactericidal, but also oxidising the biomolecules that allow the niche to survive and expand. For example, the acid Pyruvate, one of the strongest naturally occurring acids manufactured by bacteria, and implicated in the progression of caries, is oxidised by ozone to acetate acid and carbon dioxide. Acetate acid is less acidic than pyruvate, and this de-carboxylation reaction leads to mineral uptake due to the more alkaline conditions in a carious lesion. The lesion will become populated with normal mouth commensals which do not produce acid, after ozone therapy.

This simple fast novel approach avoids the need for local anaesthesia, drilling and filling, however, its application is restricted to treat the superficial enamel and root caries.

One important factor that needs to be remembered is that during the initial stages, the treated areas of decay will be relatively soft and will not support any restoration. Therefore, if a restoration is planned after ozone treatment, it should be planned at the review appointment at 2–3 months after the initial ozone treatment by which time, the research data suggests, the remineralisation process will be well advanced, the lesion static and reversed, and the tissue hard enough to support a transitional restoration.

Using ozone treatment as their primary approach to the treatment of many incidences of dental caries completely removes any potential stressors. There is no local anaesthesia to give, no use of the drill and no packing of restorative material. The time spent on providing the actual treatment is also minimal in the extreme.

Treatment is simple, fast (the average ozone time for practitioners using the Ozident® dental ozone unit is 30s) and involves little preparatory work. The loose debris is first cleaned away, until a leathery base is reached. This can be done with hand instruments. Ozone is applied, the lesion wetted with a remineralising wash and then the glass ionomer (Fuji VII) can be applied. This modified ART technique has been reported by Holmes.

## REFERENCES

1. *Banerjee, A.* Minimal intervention dentistry. Part 7. Minimally invasive operative caries management : rationale and techniques / A. Banerjee // *Br. Dent. J.* 2013. Vol. 214, № 3. P. 107–111.
2. *Banerjee, A.* Minimally invasive caries removal using bio-active glass air-abrasion / A. Banerjee, I. D. Thompson, T. F. Watson // *J. Dent.* 2011. Vol. 39, № 2. P. 7.
3. *Burke, F. J.* From extension for prevention to prevention of extension (minimal intervention dentistry) / F. J. Burke // *J. Am. Dent. Assoc.* 2003. Vol.134, № 1. P. 87–95.
4. *Chalmers, J. M.* Minimal intervention dentistry. Part 2. Strategies for addressing restorative challenges in older patients / J. M. Chalmers // *J. Can. Dent. Assoc.* 2006. Vol. 72, № 5. P. 435–440.
5. *Restoring proximal caries lesions conservatively with tunnel restorations* / C. H. Chu [et al.] // *Clin. Cosmet. Investig. Dent.* 2013. Vol. 30, № 5. P. 43–50.
6. *Minimally Invasive Dentistry — concepts and techniques in cariology* / D. Ericson [et al.] // *Oral Health Prev. Dent.* 2003. Vol. 72, № 1. P. 59–72.
7. *Ericson, D.* The concept of minimally invasive dentistry / D. Ericson // *Dent Update.* 2007. Vol. 34, № 1. P. 9–10, 12–14, 17–18.
8. *Ericson, D.* What is minimally invasive dentistry? / D. Ericson // *Oral Health Prev. Dent.* 2004. № 2, Suppl 1. P. 287–292.
9. *Featherstone, J. D.* Minimal intervention dentistry. Part 1. From “compulsive” restorative dentistry to rational therapeutic strategies / J. D. Featherstone, S. Doméjean // *Br. Dent. J.* 2012. Vol. 213, № 9. P. 441–445.
10. *Malterud, M. I.* Minimally invasive restorative dentistry : a biomimetic approach / M. I. Malterud // *Compend. Contin. Educ. Dent.* 2008. Vol. 29, № 6. P. 338–346.
11. *Murdoch-Kinch, C. A.* Minimally invasive dentistry / C. A. Murdoch-Kinch, M. E. McLean // *J. Am. Dent. Assoc.* 2003. Vol. 134, № 1. P. 87–95.
12. *Murdoch-Kinch, C. A.* Minimally invasive dentistry / C. A. Murdoch-Kinch, M. E. McLean // *Pract. Proced. Aesthet. Dent.* 2006. Vol. 18, № 7. P. 409–414.
13. *Nový, B. B.* The material science of minimally invasive esthetic restorations / B. B. Nový, C. E. Fuller // *J. Conserv. Dent.* 2013. Vol. 16, № 4. P. 282–283.
14. *Minimal intervention dentistry : a review.* FDI Commission Project 1-97 / M. J. Tyas [et al.] // *Int. Dent. J.* 2000. Vol. 50. № 1. P. 1–12.
15. *Wiegand, A.* Treatment of proximal caries lesions by tunnel restorations / A. Wiegand, T. Attin // *Dent/ Mater.* 2007. Vol. 23. № 12. P. 1461–1467.

## CONTENTS

Definition .....	3
Atraumatic restorative technique .....	4
Tunnel preparation .....	5
Proximal cavity preparation .....	6
Alternative preparation methods .....	7
References .....	18

РЕПОЗИТОРИЙ БГМУ

Учебное издание

**Казеко Людмила Анатольевна**  
**Модринская Юлия Владимировна**  
**Кармалькова Ирина Сергеевна**  
**Колб Екатерина Леонидовна**

**МИНИМАЛЬНО ИНВАЗИВНЫЕ МЕТОДЫ  
ОПЕРАТИВНОГО ЛЕЧЕНИЯ ЗУБОВ**

**MINIMAL INVASIVE METHODS OF TOOTH  
OPERATIVE TREATMENT**

Учебно-методическое пособие

На английском языке

Ответственная за выпуск Л. А. Казеко  
Переводчик И. С. Кармалькова  
Компьютерная верстка Н. М. Федорцовой

Подписано в печать 17.02.16. Формат 60×84/16. Бумага писчая «Снегурочка».  
Ризография. Гарнитура «Times».  
Усл. печ. л. 1,16. Уч.-изд. л. 0,96. Тираж 40 экз. Заказ 135.

Издатель и полиграфическое исполнение: учреждение образования  
«Белорусский государственный медицинский университет».  
Свидетельство о государственной регистрации издателя, изготовителя,  
распространителя печатных изданий № 1/187 от 18.02.2014.  
Ул. Ленинградская, 6, 220006, Минск.